

On the Role of Artificial Intelligence in Medical Imaging of COVID-19

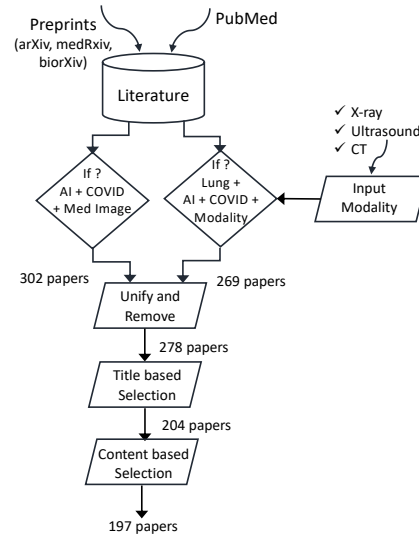
1. Appendices

Appendix A. Details on meta-review

Workflow of manual review.

Fig. A1 shows how the set of 197 papers for manual review was created. First, a search of the keywords “AI + Medical imaging + COVID-19” revealed 302 matches across the 4 servers *PubMed*, *arXiv*, *bioRxiv* and *medRxiv*. Those papers were not specific to lung imaging and thus, a second set of keyword searches were made using “AI + Lung + Imaging + COVID-19 + Modality” where Modality was from {CT, X-Ray, Ultrasound}. This revealed 269 publications (visualized in Fig. 2B). Duplicates were removed and subsequently, the titles were scanned manually and papers that only touched peripherally on AI (or one of the other aspects) were removed. This led to a set of 178 papers. Next the complement of this set in the initial 197 papers on medical imaging were taken which added another 100 papers. After another round of title-based selection of those papers, 26 papers were added to the initial 178 for manual review. From the 204 manually reviewed papers, 7 were excluded during in-depth analysis since they did not involve any work on AI, leading to the final set of 197 papers.

The manual review was split across 7 authors of this paper (AC, DB, DR, EK, JB, MG, VM) and every paper was evaluated by: primary location of authors, primary location of COVID-19 data, imaging modality, task performed, overall quality of work, maturity of AI technology and data origin (external or internal).



Software

for keyword search.

The number of publications per keyword were fetched via a Python package that can be used to reproduce the figures and is publicly available at: https://github.com/PhosphorylatedRabbits/paper_scraper. The queries to the APIs of *PubMed*, *arXiv*, *bioRxiv* and *medRxiv* were made using synonyms for each keyword where a paper was considered a match when title or abstract contained at least one of the synonyms for each keyword (see Table A1). The reference date for all calculations was 30.06.2020

* Corresponding author. Tel.: +0-000-000-0000 ; fax: +0-000-000-0000.

E-mail address: author@institute.xxx

Peer review under responsibility of xxxxx.



Hosting by Elsevier

Table A1 – List of considered synonyms per search keyword

Keyword	Synonyms
COVID-19	SARS-CoV-2, corona
Imaging	Image, screen, screening, scan
Medical imaging	Medical image
AI	Artificial intelligence, deep learning, machine learning, neural network, computer vision
Lung	Chest, pulmonary
Breast	Mammography
CT	Computed tomography
X-Ray	XRy, CXR, radiography
Ultrasound	Sonography, LUS

Details of Fig. 1.

All numbers in Fig. 1 were computed based on un-reviewed keyword searches on publisher APIs as described in *Software keyword search*. However, the intersection of AI, COVID-19 and Medical imaging initially revealed 302 papers. Since fully automatic keyword search is suboptimal, we made a union of this set with the 269 publications obtained from the modality specific keyword search. This led to our total result of 376 publications as shown in Fig 1. of the manuscript.

Distributions of modality, task and maturity

Figure A2 provides details from the meta-review and quantifies how task and maturity are distributed by modality. For example, 88% of all 104 CXR works performed diagnosis whereas this was only the case for 65% of CT papers, where a richer set of papers was found (almost 15-20% of works on segmentation and severity assessment, whereas this was 1-3% for CXR). Projects using X-Ray for diagnosis were on average of much lower quality (71% low quality) compared to CT (62%). High-quality works where only observed using CT data and almost exclusively on diagnosis.

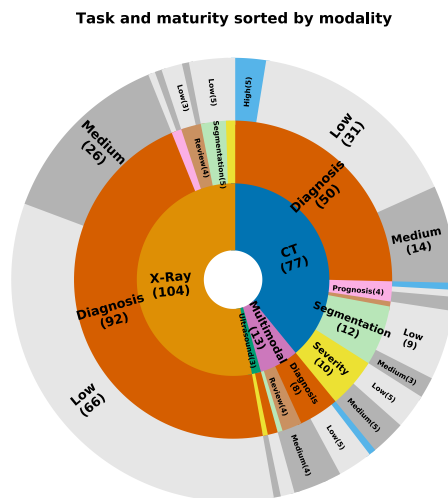


Fig. A2. Sunburst plot on the quality of AI papers distributed by task and modality. The root is in the center and layers are added hierarchically towards the periphery. Hence, the plot should be

read inside-out. E.g. From the 77 papers on CT imaging, 50 were dedicated to diagnosis with 31 having low, 14 middle and 5 high maturity. Labels are omitted for fields with less than 5 publications.

Appendix B. Additional Imaging Modalities

While the main body of the paper discusses the modalities of CT, X-ray and Ultrasound, in this appendix we also include a discussion of MRI and digital pathology.

Magnetic Resonance Imaging (MRI)

While SARS-CoV-2 induced pathologies have been identified on other imaging modalities outside CXR and chest CT tomography, the use of these other modalities is not aimed in the diagnosis, prognostic or severity assessment of COVID-19. MRI is not part of the standard clinical routine for COVID-19 patients and explicitly discouraged by the ACR due to contagiousness although asymptomatic patients are still receiving outpatient MRIs and findings of SARS-CoV-2 have been found incidentally like on breast MRIs [1]. MRI of the thoracic cavity for evaluation of the lung parenchyma is rarely used, though deemed a viable alternative to CT for detecting a variety of conditions and recommended for patients with increased radiosensitivity or other contraindications [2], [3]. Ultrashort-echo-time MRI (UT-MRI) is inferior to multidetector CT in detecting GGOs [4], but it was found on-par with standard CT in assessing signs of COVID-19 [5] and thus might resemble a tool for patients with CT contraindications. Standard MRI is also known to identify signs of viral pneumonia in COVID-19 patients [6]. In addition, cardiac or neurologic complications are among the more frequent extrapulmonary manifestations of COVID-19 that can be detected via MRI [7]. For example, brain MRI has helped diagnosing conditions like encephalopathy or encephalitis [7] and found a wide range of neuroradiologic patterns [8]. Moreover, studies using AI techniques on thoracic MRI are scarce [9] and studies involving COVID-19 are, to the best of our knowledge, absent.

Digital Pathology

It is noteworthy that AI has numerous applications for COVID outside the medical imaging domain [10]. Image analysis is progressively leveraged with the prevalence of digital pathology. Related to the COVID-19 disease, in several studies [11]–[14], post-mortem needle core biopsy samples were taken from lung, liver, and heart tissues of, verified by an RT-PCR test, COVID-19 patients. Post-mortem histological examination has shown that the COVID-19 pneumonia is mostly evidenced in lung tissues with the presence of diffuse alveolar damage (DAD) and superimposed bacterial pneumonia phenotypes [11]–[13]. GGOs in CT scans are consistent with DAD observed in COVID-19 patients with respiratory failure [11]–[13]. Other phenotypes in lung tissues include additional inflammatory responses [11], or fibroblastic proliferation [12], [13]. In more acute-phase cases, vascular congestion or abundant intra-alveolar neutrophilic infiltration were observed which are consistent with bronchopneumonia of a superimposed bacterial infection [12], [13]. The limited availability of data and the variability and initial uncertainty in the observed phenotypes, induces potential limitations in leveraging image analysis technologies, and in particular DL-based analysis of the scanned tissue images. To that end, we have not identified such a study. More data and studies are needed to identify their potential impact in the disease understanding, and the potential role of AI in their analysis. In one feasibility study using machine

learning on liquid biopsies [15], blood test analyses were shown as a viable alternative to RT-PCR (accuracy 85%, sensitivity 93%). Interestingly, aside from the transaminase count, the white blood cell count was an important predictor [16].

Imaging market sizes

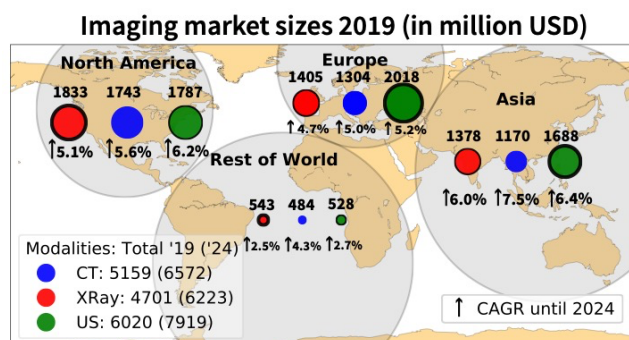


Fig. A3: Regional sizes of medical imaging markets. Overall, US has the largest market across all modalities and is especially dominant in Europe. CT instead is dominant in North America, but CAGR for US are higher and a turn-around is predicted until 2024. The circle radius is proportional to the market size, but for visual clarity, thickness of black borders resembles the regional rank per modality. Figure was created with data from: <https://www.marketsandmarkets.com/>, Diagnostic Imaging Market - Forecast To 2024.

REFERENCES

- [1] A. Brown, S. Dluzewski, and A. Malhotra, "Presumed pulmonary COVID-19 infection detected incidentally on breast MR," *Radiol. Case Reports*, vol. 15, no. 9, pp. 1629–1632, Sep. 2020.
- [2] J. Biederer *et al.*, "MRI of the lung (2/3). Why... when ... how?," *Insights Imaging*, vol. 3, no. 4, pp. 355–371, Aug. 2012.
- [3] G. Serra *et al.*, "Lung MRI as a possible alternative to CT scan for patients with primary immune deficiencies and increased radiosensitivity," *Chest*, vol. 140, no. 6, pp. 1581–1589, 2011.
- [4] C. Romei *et al.*, "The use of chest magnetic resonance imaging in interstitial lung disease: A systematic review," *European Respiratory Review*, vol. 27, no. 150. European Respiratory Society, 31-Dec-2018.
- [5] S. Yang *et al.*, "Clinical Potential of UTE-MRI for Assessing COVID-19: Patient- and Lesion-Based Comparative Analysis," *J. Magn. Reson. Imaging*, vol. 52, no. 2, pp. 397–406, Aug. 2020.
- [6] Y. Vasilev *et al.*, "MRI of the lungs in patients with COVID-19: clinical case," *medRxiv*, 2020.
- [7] A. Gupta *et al.*, "Extrapulmonary manifestations of COVID-19," *Nat. Med.*, vol. 26, no. 7, pp. 1017–1032, Jul. 2020.
- [8] S. Kremer *et al.*, "Brain MRI Findings in Severe COVID-19: A Retrospective Observational Study," *Radiology*, p. 202222, Jun. 2020.
- [9] M. A. Mazurowski, M. Buda, A. Saha, and M. R. Bashir, "Deep learning in radiology: An overview of the concepts and a survey of the state of the art with focus on MRI," *J. Magn. Reson. Imaging*, vol. 49, no. 4, pp. 939–954, Apr. 2019.
- [10] D. S. W. Ting, L. Carin, V. Dzau, and T. Y. Wong, "Digital technology and COVID-19," *Nature Medicine*, vol. 26, no. 4. Nature Research, pp. 459–461, 01-Apr-2020.
- [11] Z. Xu *et al.*, "Pathological findings of COVID-19 associated with acute respiratory distress syndrome," *Lancet Respir. Med.*, vol. 8, no. 4, pp. 420–422, Apr. 2020.
- [12] S. Tian *et al.*, "Pathological study of the 2019 novel coronavirus disease (COVID-19) through postmortem core biopsies," *Mod. Pathol.*, vol. 33, no. 6, pp. 1007–1014, Jun. 2020.
- [13] H. Zhang *et al.*, "Histopathologic Changes and SARS-CoV-2 Immunostaining in the Lung of a Patient With COVID-19," *Ann. Intern. Med.*, vol. 172, no. 9, pp. 629–632, May 2020.
- [14] P. Wenzel *et al.*, "Evidence of SARS-CoV-2 mRNA in endomyocardial biopsies of patients with clinically suspected myocarditis tested negative for COVID-19 in nasopharyngeal swab," *Cardiovasc. Res.*, vol. 116, no. 10, pp. 1661–1663, Aug. 2020.
- [15] D. Brinati, A. Campagner, D. Ferrari, M. Locatelli, G. Banfi, and F. Cabitza, "Detection of COVID-19 Infection from Routine Blood Exams with Machine Learning: A Feasibility Study," *J. Med. Syst.*, vol. 44, no. 8, p. 135, Aug. 2020.
- [16] X. Mei *et al.*, "Artificial intelligence-enabled rapid diagnosis of patients with COVID-19," *Nat. Med.*, pp. 1–5, 2020.