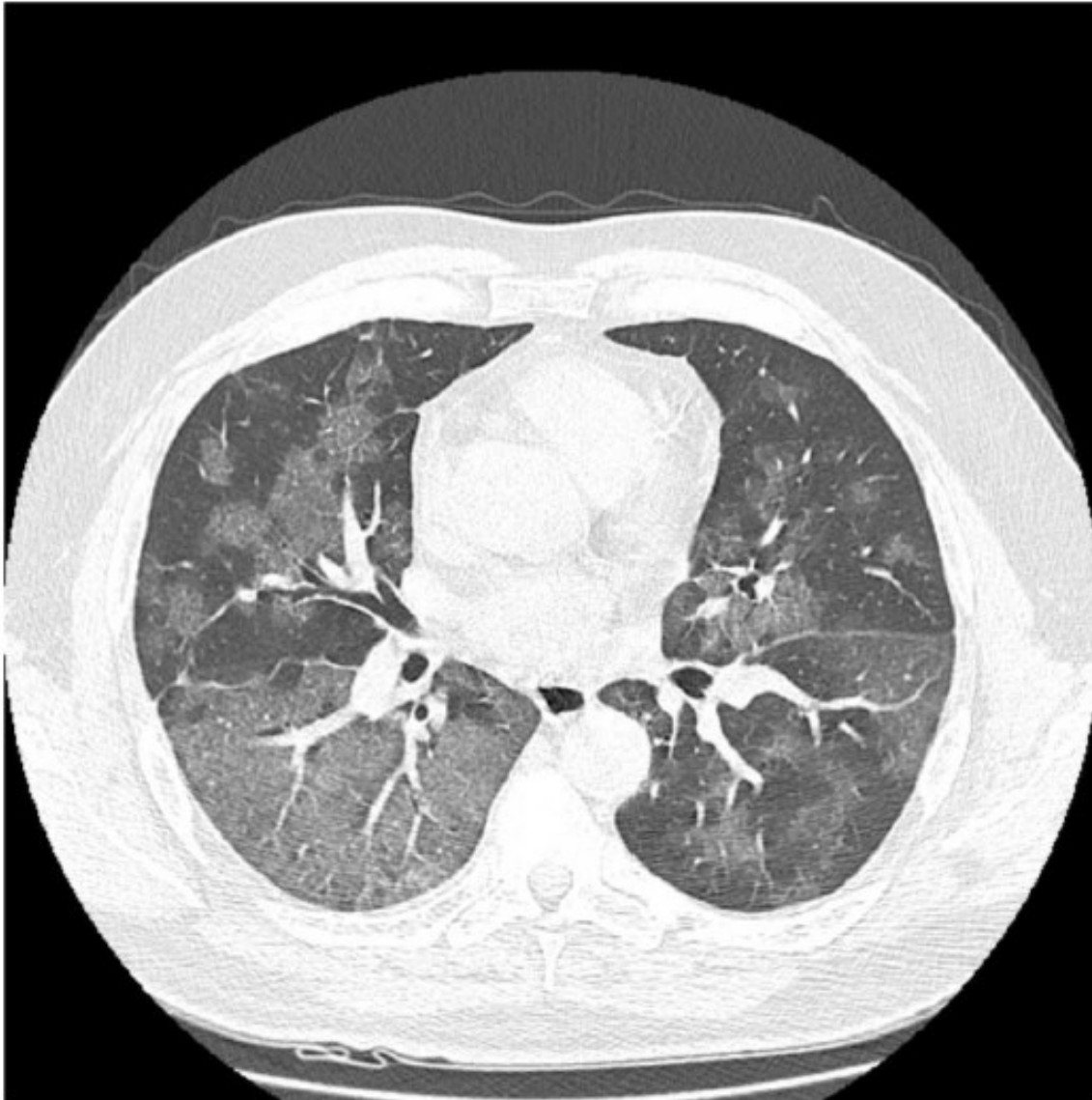


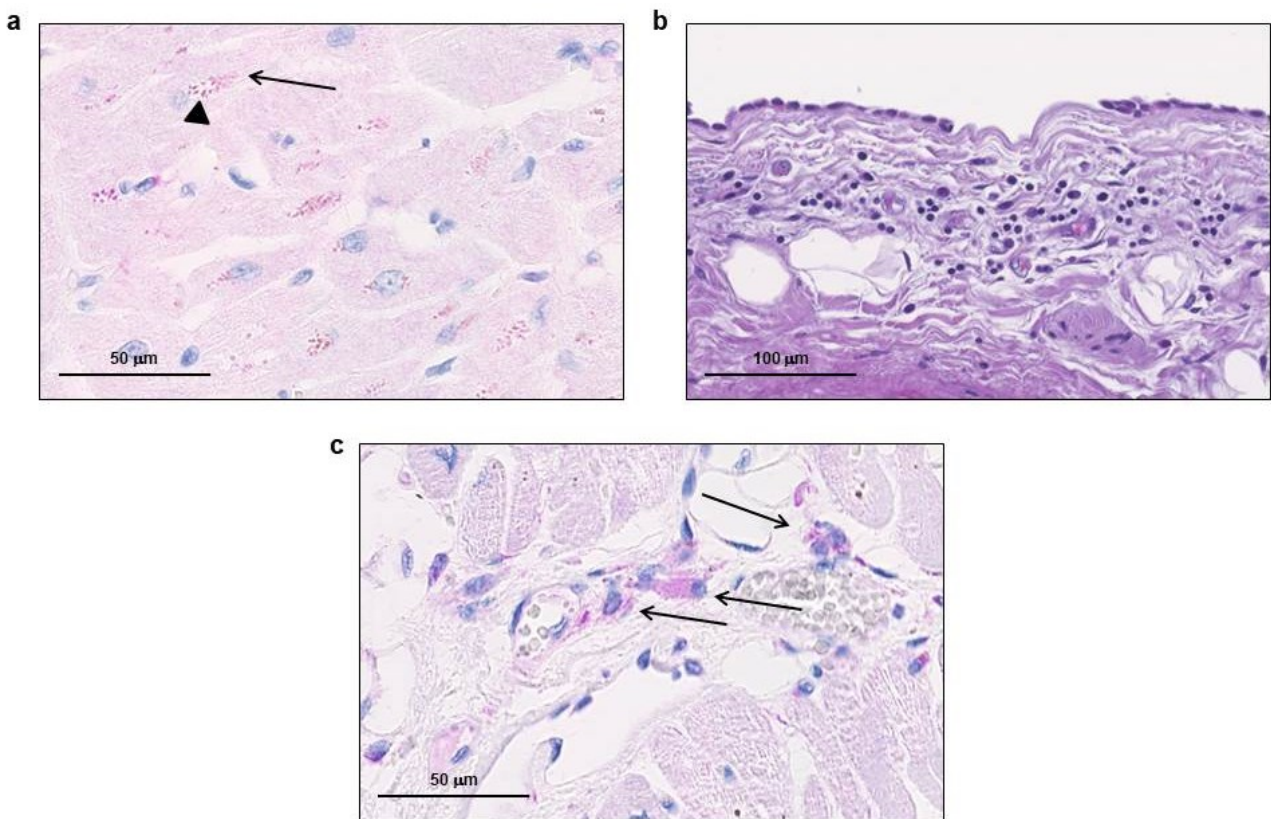
Evidence of SARS-CoV-2 transcriptional activity in cardiomyocytes of COVID-19 patients without clinical signs of cardiac involvement

Gaetano Pietro Bulfamante^{*}, Gianluca Lorenzo Perrucci^{*✉}, Monica Falleni, Elena Sommariva, Delfina Tosi, Carla Martinelli, Paola Songia, Paolo Poggio, Stefano Carugo, and Giulio Pompilio

Supplementary Figures



Supplementary Figure 1 – Representative Computed Tomography image of a COVID-19 patient. Bilateral pathognomonic lung lesion patterns typical of Covid-19 pneumonia are visible.



Supplementary Figure 2 – SARS-CoV-2 nucleoprotein localization in lipofuscin granule area of cardiomyocytes and macrophages, and inflammatory infiltrates in heart samples of COVID-19 patients. **a)** Representative image of immunohistochemistry on 3 μ m-slides of formalin-fixed paraffin-embedded left ventricle specimens from COVID-19-positive patient for SARS-CoV-2 nucleoprotein. The lipofuscin granules (in light brown) are indicated with arrowhead, while viral nucleoprotein (in red), localized in same sub-cellular area, is indicated with black arrow. **b)** Haematoxylin-eosin staining on left ventricle specimens from COVID-19-positive patient. The inflammatory infiltrate is clearly localized in sub-epicardial region. **c)** Representative image of immunohistochemistry on left ventricle specimens from COVID-19-positive patient for SARS-CoV-2 nucleoprotein (in red). The high immunoreactive interstitial macrophages are indicated with black arrows. Magnification as scale bars.