

1

2

3

4 Efficacy and safety of ethanolamine oleate in sclerotherapy in patients with

5 difficult-to-resect venous malformations: A multicenter, open-label,

6 single-arm study

7 Running head: Ethanolamine oleate sclerotherapy in difficult-to-resect venous

8 malformations

9

10

11 Mine Ozaki^{1*}, Tadashi Nomura², Keigo Osuga³, Masakazu Kurita⁴, Ayato Hayashi^{5,6},

12 Shunsuke Yuzuriha⁷, Noriko Aramaki-Hattori⁸, Makoto Hikosaka⁹, Taiki Nozaki¹⁰,

13 Michio Ozeki¹¹, Junko Ochi¹², Shimpei Akiyama¹³, Yasumasa Kakei^{14,15}, Keiko

14 Miyakoda¹⁵, Naoko Kashiwagi¹⁵, Takahiro Yasuda^{15,16}, Yuki Iwashina¹, Tsuyoshi

15 Kaneko⁹, Kiyoko Kamibepu¹⁷, Takafumi Soejima¹⁸, Kiyonori Harii¹

16

17 ¹ Department of Plastic Surgery, Kyorin University Faculty of Medicine, Tokyo, Japan

18 ² Department of Plastic Surgery, Kobe University Graduate School of Medicine, Hyogo,

19 Japan

20 ³ Department of Diagnostic Radiology, Osaka Medical and Pharmaceutical University,

21 Osaka, Japan

22 ⁴ Department of Plastic and Reconstructive Surgery, The University of Tokyo Hospital,

23 Tokyo, Japan

24 ⁵ Department of Plastic and Reconstructive Surgery, Yokohama City University,

25 Kanagawa, Japan

26 ⁶ Department of Plastic and Reconstructive Surgery, Juntendo University School of

27 Medicine, Tokyo, Japan

28 ⁷ Department of Plastic and Reconstructive Surgery, Shinshu University School of

29 Medicine, Nagano, Japan

30 ⁸ Department of Plastic and Reconstructive Surgery, Keio University School of Medicine,

31 Tokyo, Japan

32 ⁹ Department of Plastic and Reconstructive Surgery, National Center for Child Health and

33 Development, Tokyo, Japan

34 ¹⁰ Department of Radiology, Keio University School of Medicine, Tokyo, Japan

35 ¹¹ Department of Pediatrics, Graduate School of Medicine, Gifu University, Gifu, Japan

36 ¹² Department of Diagnostic Radiology, Suita Tokushukai Hospital, Osaka, Japan

37 ¹³ Department of Radiology, Kyoto Prefectural University of Medicine, Kyoto, Japan

38 ¹⁴ Department of Oral and Maxillofacial Surgery, Kobe University Graduate School of

39 Medicine, Hyogo, Japan

40 ¹⁵ Department of Medical Devices, Kobe University Graduate School of Medicine,

41 Hyogo, Japan

42 ¹⁶ Advanced Medical-Engineering Development Center, Kobe University, Hyogo, Japan

43 ¹⁷ Division of Health Sciences and Nursing, Graduate School of Medicine, the

44 University of Tokyo, Tokyo, Japan

45 ¹⁸ Department of Child Health Nursing, Kobe University Graduate School of Health

46 Sciences, Hyogo, Japan

47

48 * Corresponding author:

49 E-mail: zakimin@nifty.com (MO)

50

51 **Abstract**

52 **Objective**

53 To evaluate the efficacy and safety of sclerotherapy in patients with difficult-to-resect
54 venous malformations treated with ethanolamine oleate.

55 **Design and setting**

56 This investigator-initiated clinical trial employed a multicenter, single-arm, open-label
57 design and was conducted in Japan.

58 **Patients**

59 Overall, 44 patients with difficult-to-resect venous malformations were categorized into
60 two cohorts: 22 patients with cystic-type malformations and 22 patients with diffuse-type
61 malformations.

62 **Interventions**

63 Patients received injections of 5% ethanolamine oleate solution, double diluted with
64 contrast or normal saline, with a maximum dose of 0.4 mL/kg. The same method of
65 administration was used for children (<15 years old). The maximum volume of the
66 prepared solution in one treatment was 30 mL.

67 **Evaluation methods**

68 Treatment efficacy was assessed by evaluating changes in lesion volume using magnetic
69 resonance imaging and changes in pain using a visual analog scale.

70 **Results**

71 Among the 45 patients who consented, one was excluded owing to potential intracranial
72 involvement of venous malformations during screening. Regarding the primary outcome,
73 26 of 44 patients (59.1%, 95% confidence interval: 44.41–72.31%) achieved $\geq 20\%$
74 reduction in malformation volume, with 16 patients having cystic lesions (72.7%,
75 51.85–86.85%) and 10 patients having diffuse lesions (45.5%, 26.92–65.34%). Both
76 cohorts showed significant improvement in self-reported pain scores associated with
77 lesions 3 months post-sclerotherapy. No death or serious adverse events occurred.
78 Hemoglobinuria was observed in 23 patients (52%), a known drug-related adverse event.
79 Prompt initiation of haptoglobin therapy led to full recovery within a month for these
80 patients.

81 **Conclusions**

82 Ethanolamine oleate shows potential as a therapeutic sclerosing agent for patients with
83 difficult-to-resect venous malformations.

84

85 **Keywords:** sclerotherapy, ethanolamine oleate, venous malformation, cavernous

86 hemangioma, hemoglobinuria

87

88 **Introduction**

89 Venous malformations (VMs) are vascular developmental abnormalities that
90 arise during fetal life and are associated with pain, movement disorders, and other
91 symptoms [1-3]. A study conducted by the Ministry of Health, Labor and Welfare in
92 Japan (Project on Intractable Hemangioma, Vascular Malformation, Lymphangioma,
93 Lymphangiomatosis and Related Diseases in Fiscal 2014) estimated that 20,000
94 individuals are affected by VMs, with half of them harboring difficult-to-resect lesions
95 due to extensive involvement or muscle infiltration [4,5]. For such cases, sclerotherapy is
96 the treatment of choice [2,6-9].

97 Sclerotherapy is a globally recognized treatment for VMs, described as among
98 the most effective options available. Ethanolamine oleate, a sclerosing agent, has been
99 extensively documented in this regard [10]. American guidelines for percutaneous
100 sclerotherapy for head and neck venous and lymphatic malformations [11] and European
101 guidelines for sclerotherapy in chronic venous disorders both acknowledge the
102 effectiveness of sclerotherapy in chronic venous disorders, including VMs [12]. However,
103 to the best of our knowledge, sclerotherapy for VMs remains uncovered by health
104 insurance policies, with no pharmaceutical approval for any sclerosing agent across
105 countries to date.

106 In Japan, ethanolamine oleate, absolute ethanol, and polidocanol have been used
107 as off-label sclerosing agents for VM treatment [13-17]. While absolute ethanol and
108 polidocanol are associated with serious, life-threatening adverse events [11,18,19],
109 ethanolamine oleate is considered a safer option with minimal adverse events [20].
110 Horbach et al.'s article [20], which analyzed five studies encompassing 188 patients
111 treated with ethanolamine oleate for venous or lymphatic malformations, reported skin

112 ulceration and skin necrosis (six cases, 3%) as adverse events. However, systemic
113 adverse events, facial nerve disorders, or other adverse events were absent [20]. In
114 another study that evaluated the cytotoxicity of each sclerosing agent in muscle tissue,
115 absolute ethanol was the most cytotoxic, with ethanolamine oleate and polidocanol
116 exhibiting comparably lower cytotoxicity [14]. Conversely, efficacy studies have shown
117 promising results for ethanolamine oleate, which reduced lesions and improved
118 symptoms in 88–100% of cases evaluated in a systematic review [20]. Furthermore, a
119 pediatric-centered study examined its application in children (mean age: 15.1 years,
120 range: 3 months to 21 years) among 83 patients (comprising 85 procedures), resulting in
121 complete symptom resolution for 79 lesions and notable enhancements for six lesions
122 [21]. Although ethanolamine oleate is currently approved as a sclerosing agent for
123 esophageal and gastric varices in Japan [22,23], its use has not been indicated for
124 pediatric patients. This is particularly relevant considering the congenital nature of VMs,
125 often requiring treatment in children. Nevertheless, existing evidence suggests its
126 efficacy in pediatric patients.

127 Given its efficacy and safety profile, ethanolamine oleate is regarded as the most
128 appropriate candidate for initial regulatory approval as a sclerosing agent for VMs. A
129 limited number of well-designed clinical trials have investigated treatment options for
130 difficult-to-resect VMs; we initiated a phase III, multicenter, open-label, single-arm
131 clinical trial to aid the Japanese government in approving health insurance coverage.
132 Based on their morphological characteristics, VMs can be broadly categorized into cystic
133 and diffuse lesions. Cystic lesions are more likely to shrink with sclerotherapy, whereas
134 diffuse lesions are less likely to respond [24]. Consequently, the study design employed
135 volume reduction and pain improvement as the evaluation criteria for cystic and diffuse

136 lesions, respectively. This clinical trial aimed to characterize the clinical impact of
137 ethanolamine oleate injection in patients with difficult-to-resect VMs.

138

139 **Materials and methods**

140 **Study design and procedure**

141 This non-randomized, prospective, open-label, multicenter clinical trial was
142 conducted at eight hospitals from January 1, 2021 to the end of April 2023 (the last
143 patient's visit). The recruitment period for Kyorin University Hospital, Kobe University
144 Hospital, Osaka Medical and Pharmaceutical University Hospital, The University of
145 Tokyo Hospital, Juntendo University Urayasu Hospital, and National Center for Child
146 Health and Development Hospital was from 1/1/2021 to 31/3/2023; for Shinshu
147 University Hospital, the recruitment period was from 1/2/2021 to 31/3/2023; for Keio
148 University Hospital, the recruitment period was from 19/3/2021 to the 31/3/2023. A
149 summary of this study is presented in Fig 1. The observation period continued for 3
150 months following the intervention. Participants were instructed to visit at designated
151 times during the observation period and provided with reimbursement for travel expenses
152 to reduce the burden on patients. Written informed consent was obtained from all patients
153 or their parents/guardians if the patient was under 20 years old. This clinical trial was
154 approved by the Institutional Review Board of each facility (Kyorin University Hospital,

155 Kobe University Hospital, Osaka Medical and Pharmaceutical University Hospital,
156 Shinshu University Hospital, The University of Tokyo Hospital, Juntendo University
157 Urayasu Hospital, Keio University Hospital, National Center for Child Health and
158 Development Hospital). The study protocol adhered to the SPIRIT statement. All data
159 were stored and archived at the Data Center of DOT World Co., Ltd., Tokyo, Japan.

160

161 **Fig 1. Summary of the study protocol.** MRI, magnetic resonance imaging; CT,
162 computed tomography

163

164 **Sample size calculation**

165 Considering cystic lesions, the threshold for volume reduction was set at a
166 minimum of 20%. This was based on the assumption that successful treatment should
167 improve the conditions of a proportion of patients, achieving either complete response
168 (target lesion resolved) or partial response ($\geq 20\%$ target lesion volume reduction).
169 Limited data exist regarding magnetic resonance imaging (MRI)-based evaluations for
170 ethanolamine oleate in difficult-to-resect VMs. Kaji et al. [7] reported a median
171 MRI-based lesion reduction rate of approximately 25% in 60 participants with VMs.
172 Because the median corresponds to the 50th percentile of the data distribution, more than
173 50% of patients are expected to experience a reduction rate $\geq 20\%$, as shown in the figure
174 presented by Kaji et al. A study conducted by Alexander et al. [25] reported on
175 MRI-based reduction rates for VMs and demonstrated that at least 50% of participants
176 achieved a reduction rate $\geq 20\%$ [25].

177 It should be noted that Kaji et al. [7] calculated the lesion reduction rate from the
178 measured area of the lesion. Although Kaji’s method differs from that used in the current
179 study, we considered the reduction rate reported in these previous studies to be suitable
180 since the expected threshold and complete response and partial response values in the
181 present study would be at least 50% [25].

182 It was estimated that the present trial required the inclusion of 19 cases per group
183 to obtain 80% statistical power to detect significant between-group differences based on a
184 binomial distribution with a one-sided 2.5% significance level. Considering potential
185 dropout cases, the target number of patients with cystic lesions was set to 22. The same
186 target was used for cases with diffuse lesions, and a total of 44 cases were targeted for
187 recruitment.

188

189 **Participant inclusion criteria**

190 Participants were selected according to the inclusion criteria set by investigators
191 collecting patient information during outpatient consultations at each facility among the
192 patients with VMs introduced at each facility. The inclusion criteria were any age;
193 informed consent, either directly or through their legal guardians if under 20 years old;
194 and VMs considered challenging to surgically remove, with sclerotherapy identified as
195 the primary treatment option. Difficulty in resection was defined by the investigator or
196 sub-investigator as a high risk of lifestyle dysfunction due to potential complications
197 from excision or the risk of aesthetic impairment.

198 Moreover, patients needed to exhibit at least one target VM with a major axis
199 diameter ≥ 30 mm in the extremities or ≥ 20 mm in the head and neck, as determined on
200 MRI or computed tomography. Additionally, inclusion criteria stipulated the absence of a

201 thrombus or organized tissue that could interfere with the evaluation of images or the
202 judgment of treatment effectiveness in target VMs.

203

204 **Participant exclusion criteria**

205 The exclusion criteria included multiple organ failure or disseminated
206 intravascular coagulation; currently taking or recently started taking medications known
207 to influence lesion resolution, such as propranolol or specific herbal medicines like
208 Kamishoyosan or Ninjinyoeito; diabetes mellitus (HbA1c ≥ 8.0) or autoimmune
209 disorders; Child–Pugh Class C liver dysfunction; renal dysfunction (estimated
210 Glomerular Filtration Rate < 60 mL/min/1.73 m²); or cardiac dysfunction (New York
211 Heart Association Class ≥ 2).

212 Further exclusions encompassed patients who had undergone sclerotherapy
213 within 6 months preceding signing of the informed consent, with a history of allergy to
214 ethanolamine oleate or angiography contrast agents, and those who had undergone
215 surgery exceeding 45 min within 2 weeks preceding signing of the informed consent.
216 Additionally, participation in other clinical studies within 4 weeks preceding signing of
217 the informed consent, pregnancy, potential pregnancy, or lactation rendered individuals
218 ineligible. Lastly, patients deemed ineligible by the investigator or sub-investigator were
219 not enrolled.

220

221 **Intervention**

222 The following procedures were performed by the investigator from each facility
223 under general anesthesia in the operating room. Patients received injections of 5%
224 ethanolamine oleate solution, double diluted with contrast or normal saline (Fig 2), with a

225 maximum dose of 0.4 mL/kg. The same method of administration was used for children
226 (<15 years old). The maximum volume of the prepared drug in one treatment was 30 mL.
227 The safety of this dose is within the range approved for gastric variceal treatment in Japan
228 [22], and its efficacy has been reported in previous studies [7,13,15-17]. The drug is
229 administered only once; however, for patients with diffuse lesions, if there is little
230 improvement in symptoms such as pain even after 4 weeks from administration, and the
231 principal investigator deems it necessary for treatment, additional dosing is permitted. In
232 such cases, the dosage should be the same as the initial dose.

233

234 **Fig 2. Sclerotherapy procedure for venous malformations.** (A) Adjust the position of
235 the fluoroscopy device. (B) Insert a needle under ultrasound guidance. (C) Ultrasound
236 image at the time (B-mode). The inserted needle is visible (arrow). (D) Apply negative
237 pressure to confirm the presence of back flow (arrow). (E) During digital subtraction
238 angiography, contrast is injected to confirm the location of the lesion and outflow
239 pathways. Once it is confirmed that the needle is in the appropriate position and the
240 injection volume is verified, inject the sclerosing agent diluted with contrast. (F)
241 Fluoroscopy after multiple iterations of this process showing the persistence of the
242 sclerosing agent within the lesion due to the contrast mixture. (G) Ultrasound imaging
243 confirming the presence of a sclerosing agent under ultrasound guidance.

244

245 **Endpoints**

246 The primary endpoint was achieving a $\geq 20\%$ VM volume reduction 3 months
247 post-intervention. This endpoint was chosen based on the assumption that a positive
248 correlation between VM symptoms and lesion volume translates to clinical efficacy [26].

249 MRI scans were outsourced to an external institution for lesion volume analysis.
250 Afterwards, the images were separately evaluated by two independent board-certified
251 radiologists using the image analysis software OsiriX (PixMeo SARL, Geneva,
252 Switzerland) (Fig 3). The final value was determined by averaging the measurements
253 obtained by each evaluator. The interobserver correlation coefficient (2,1) was calculated
254 to assess the reproducibility of the measurements between the evaluators.

255 The key secondary endpoint was improvement in symptoms, particularly
256 self-reported, lesion-associated pain scores, 3 months post-intervention. Patients aged 2
257 to 5 years were evaluated using the face scale (range: 1–6), developed by Wong-Baker
258 [27], whereas those aged ≥ 6 years were evaluated using a visual analog scale (VAS)
259 (range: 0–100). Two-time scales were assessed using the VAS: maximum pain within 24
260 h and maximum pain within 1 week.

261 Adverse events and adverse drug reactions were documented to evaluate safety
262 endpoints. The severity of adverse events was determined based on the following criteria:
263 grade 1 denoted mild signs or symptoms that were easily tolerable, grade 2 denoted
264 moderate signs or symptoms that interfered with daily activities, and grade 3 denoted
265 severe signs or symptoms that significantly impacted daily life.

266

267 **Fig 3. A woman in her thirties with a painful intramuscular VM in the right thigh.**

268 (A,B) Magnetic resonance imaging (MRI) before sclerotherapy (T2-weighted images:
269 axial and coronal views). (C) One slide of the image subjected to segmentation using
270 OsiriX (image analysis software) on MRI before sclerotherapy. (D) Digital subtraction
271 angiography during sclerotherapy showing the administration of the sclerosing agent
272 diluted with contrast. (E,F) MRI 3 months after sclerotherapy (T2-weighted images: axial

273 and coronal views), confirming lesion volume reduction. The patient reported the
274 resolution of pain at this time.

275

276 **Statistical analysis of endpoints**

277 The full analysis set comprised all patients who underwent the study intervention,
278 ensuring a comprehensive evaluation of treatment outcomes. In contrast, the per-protocol
279 set excluded patients deemed ineligible post-enrollment and those exhibiting severe
280 protocol violations. This approach aimed to uphold the integrity of the analysis by
281 focusing on patients who adhered closely to the study protocol. The safety analysis set
282 was identical to the full analysis set.

283 Primary analyses compared the number of patients who achieved $\geq 20\%$ VM
284 volume reduction 3 months after sclerotherapy relative to the baseline value using a
285 one-sided binomial test with a significance level of $p < 0.025$ (one-sided). The 95%
286 confidence intervals (CIs) for the proportion of patients achieving this reduction were
287 estimated using the scoring method. This analysis was performed separately according to
288 VM type.

289 Secondary analyses evaluated lesion-associated pain scores 3 months after
290 sclerotherapy by estimating the median change from that at baseline with corresponding
291 95% CIs. The Wilcoxon signed-rank test was conducted to test the null hypothesis: “The
292 median change from baseline to 3 months after sclerotherapy in the population was
293 greater than 0.” The significance level was set at $p < 0.025$ (one-sided). This analysis was
294 performed separately according to VM type and patient age (<6 years and ≥ 6 years old).
295 The occurrence of adverse events was assessed for safety evaluation.

296 All descriptive statistical analyses were performed using the SAS statistical
297 software (version 9.4; SAS Institute, NC).

298

299 **Results**

300 **Participant selection, baseline demographics, and clinical** 301 **characteristics**

302 Fig 1 illustrates the participant selection flowchart. Of the 45 patients who
303 provided informed consent, one was excluded owing to potential intracranial VM traffic
304 during screening. The remaining 44 patients fulfilled the inclusion criteria. All patients
305 were evaluated for the primary endpoint, and none of them discontinued treatment. Table
306 1 summarizes the baseline demographic and clinical characteristics of the patients. It is
307 noteworthy that for both cohorts, the full analysis set, per-protocol set, and safety analysis
308 set encompassed the same population under analysis for this study. This ensured
309 consistency and comparability across the various analyses conducted throughout the
310 research.

311

312 **Table 1. Baseline Demographics and Clinical Characteristics of the Included**
313 **Patients.**

		Cystic Type	Diffuse Type	All
		n = 22	n = 22	n = 44
Age (year)	Mean	22.5	23.3	22.9
	SD	18.8	16.9	17.6
	Min	3	5	3

	Median	16.5	16.5	16.5
	Max	78	59	78
Sex (%)	Male	13 (59.1)	9 (40.9)	22 (50.0)
	Female	9 (40.9)	13 (59.1)	22 (50.0)
Body weight (kg)	Mean	45.73	49.02	47.37
	SD	24.32	15.60	20.26
	Min	14.7	20.3	14.7
	Median	49.1	50.5	49.1
	Max	92.0	75.2	92.0
Location of venous malformations (%)	Trunk	5 (22.7)	4 (18.2)	9 (20.5)
	Upper limb	3 (13.6)	8 (36.4)	11 (25.0)
	Lower limb	5 (22.7)	10 (45.5)	15 (34.1)
	Face	5 (22.7)	0 (0.0)	5 (11.4)
	Oral	1 (4.5)	0 (0.0)	1 (2.3)
	Neck	3 (13.6)	0 (0.0)	3 (6.8)
Previous treatment for venous malformations (%)	Yes	10 (45.5)	12 (54.5)	22 (50.0)
	No	12 (54.5)	10 (45.5)	22 (50.0)
Treatment history of sclerotherapy for target lesion	Initial treatment	17 (77.3)	13 (59.1)	30 (68.2)

	Retreatme	5 (22.7)	9 (40.9)	14 (31.8)
	nt			

314 Max, maximum; min, minimum; n, number; SD, standard deviation.

315

316 **Primary endpoint**

317 All 44 patients underwent sclerotherapy, and none of the patients with diffuse
 318 VMs required additional treatment. Overall, a total of 26 patients (59.1%) achieved a VM
 319 volume reduction $\geq 20\%$, including 16 patients with cystic lesions (72.7%, 95% CI:
 320 51.85–86.85%) and 10 patients with diffuse lesions (45.5%, 26.92–65.34%). For both
 321 cohorts, the percentage of patients achieving a reduction rate $\geq 20\%$ was statistically
 322 significant compared with the pre-specified criterion of 20% (cystic lesions: $p < 0.001$,
 323 diffuse lesions: $p = 0.001$). Data of patients who achieved a reduction rate $\geq 20\%$ are
 324 shown in Table 2, and the percentage change in lesion volume for each patient is shown in
 325 Fig 4. The interobserver correlation coefficient (2,1) for the MRI analysis was 0.999 ($n =$
 326 88, 99.8–100%).

327

328 **Fig 4. Waterfall plot of the evaluated lesion volume.** (A) Diagrams of cystic lesions
 329 and diffuse lesions. (B) Diagrams for all cases.

330

331 **Table 2. Patients Who Achieved $\geq 20\%$ Venous Malformation Volume Reduction 3**
 332 **Months After the Intervention.**

Venous	No. of	Achieving a Reduction of at Least 20%	P
--------	--------	---------------------------------------	---

Malformati ons	Patients	No. of Achievers	Percenta ge	95% Confidence Intervals	Value
Cystic type	22	16	72.7	51.85–86.85	<0.001
Diffuse type	22	10	45.5	26.92–65.34	0.001
All	44	26	59.1	44.41–72.31	—

333 The null hypothesis of this test: “The proportion of patients achieving $\geq 20\%$ venous

334 malformation volume reduction 3 months after sclerotherapy is $< 20\%$.”

335 The significance level of the test was 0.025 (on one side).

336 Test method: Test based on a binomial distribution.

337 Calculation method for confidence intervals: based on the score test.

338

339 **Secondary endpoint**

340 The key secondary endpoint was the change in self-reported, lesion-associated
341 pain scores from baseline to 3 months after sclerotherapy using the VAS or face scale.

342 Significant improvements in VAS scores were observed for both cohorts (cystic lesions

343 vs. diffuse lesions; 24-h maximum pain: $n = 18$, median: -2.0 , $p = 0.014$ vs. $n = 21$,

344 median: -7.0 , $p = 0.013$; 1-week maximum pain: $n = 13$, median: -2.0 , $p = 0.010$ vs. n

345 $= 20$, median: -28.5 , $p < 0.001$). Due to the limited sample size of patients aged ≤ 5

346 years, some statistical estimations and tests using the face scale-derived data could not

347 be conducted. Changes in pain scores are presented in Table 3.

348

349 **Table. 3 Changes in Self-Reported, Lesion-Associated Pain Scores 3 Months After**

350 **Sclerotherapy.**

Venous Malformations	Scale	Age	Type of Pain	No. of Patients	Median Change From Baseline	95% Confidence Intervals	P Value
Cystic type	VAS \geq 6 years		Maximum pain in 24 h	18	-2.0	-25.00 to 0.00	0.014
			Maximum pain for 1 week	13	-2.0	-51.00 to 0.00	0.010
	Face scale	2-5 years	Maximum pain in 24 h	2	0.0	0.00 to 0.00	—
			Maximum pain for 1 week	2	-0.5	-1.00 to 0.00	0.500
Diffuse type	VAS \geq 6 years		Maximum pain in 24 h	21	-7.0	-31.00 to -1.00	0.013
			Maximum pain for 1 week	20	-28.5	-34.00 to -16.00	<0.001
	Face scale	2-5 years	Maximum pain in 24 h	1	0.0	—	—

Maximum 1 0.0 — —
pain for 1
week

351 The null hypothesis of the test: “The median change in self-reported, lesion-associated

352 pain scores from baseline to 3 months after sclerotherapy is ≥ 0 .”

353 The significance level of the test was 0.025 (on one side).

354 Method of testing: Wilcoxon signed-rank test.

355 Confidence intervals were calculated according to the method described by Hahn and

356 Meeker [28].

357

358 **Safety evaluations**

359 No cases of death or serious adverse events were reported. Adverse events of

360 particular interest, defined as skin necrosis and visual impairment (for facial lesions)

361 following administration, were not observed during the study period. Adverse events

362 were documented in 42 patients (95.5%). Among them, one patient experienced a grade 3

363 adverse event related to pain, while nine patients experienced grade 2 adverse events.

364 These grade 2 events included three cases of pain; two of hemoglobinuria; and one each

365 of swelling, increased fibrin D-dimer, increased serum creatinine phosphokinase, and

366 ulnar nerve paralysis. Additionally, 32 patients reported grade 1 adverse events. Notably,

367 hemoglobinuria occurred in 23 patients (52%), including nine with cystic lesions

368 (40.9%) and 14 with diffuse lesions (63.6%). All cases of hemoglobinuria occurred on

369 the day of drug administration, and haptoglobin therapy was initiated on the same or

370 subsequent day; all patients recovered within 1 month.

371

372 **Discussion**

373 **Strengths of this study**

374 This clinical trial is the first well-designed study to provide robust evidence
375 regarding the efficacy and safety of ethanolamine oleate for patients with
376 difficult-to-resect VMs. The rarity of VMs makes it challenging to conduct large-scale
377 trials, and the lack of clinically robust evidence hinders the pharmaceutical approval of
378 ethanolamine oleate in some countries, including Japan [11]. This high-quality study,
379 demonstrating positive outcomes, has the potential to pave the way for regulatory
380 approval in such regions. Patients affected by VMs face great challenges due to the rarity
381 of their disease and inadequate national-level support; therefore, this study holds promise
382 for the global recognition of ethanolamine oleate treatment.

383

384 **Interpretation of the study endpoints**

385 Regarding the primary endpoint, the majority of patients achieved $\geq 20\%$ VM
386 volume reduction 3 months after sclerotherapy. Specifically, 16 patients (72.7%) with
387 cystic lesions and 10 patients (45.5%) with diffuse lesions demonstrated a volume
388 reduction $\geq 20\%$. These findings suggest the utility of ethanolamine oleate administration
389 in reducing VM volume for both cystic and diffuse lesions, consistent with previous
390 reports [7,25]. Given that thrombus formation and lesion enlargement can induce diverse
391 symptoms in patients with VMs, a volume reduction $\geq 20\%$ is clinically significant. As
392 such, patients who achieved this reduction have reported improvements in symptoms
393 such as pain.

394 Regarding the secondary endpoint, significant improvements in self-reported,
395 lesion-associated pain scores were observed 3 months after sclerotherapy, which aligned
396 with the findings of previous studies [14,21,29-32]. Although the mechanism through
397 which pain is alleviated by sclerotherapy for VM is not currently well understood, the
398 following mechanisms are hypothesized. Upon injection into the blood vessel, the
399 sclerosing agent damages the endothelium, causing the vessel to contract, which
400 obstructed the blood flow. This may reduce abnormal blood flow and pressure,
401 potentially alleviating pain. Additionally, the sclerosing agent can strengthen the vessel
402 walls, reducing their leakage and dilation, which can also alleviate pain. Furthermore, the
403 reduced frequency of thrombus formation decreases the likelihood of thrombophlebitis,
404 contributing to pain reduction.

405

406 **Safety of this method**

407 Regarding safety, hemoglobinuria was reported in approximately 52% of the
408 patients in our study, which was comparable to the prevalence reported in previous
409 Japanese clinical observational studies (27.7–50.0%) [7,14,33]. In cases where
410 hemoglobinuria occurs during sclerotherapy with ethanolamine oleate, there is a potential
411 risk of progression to acute renal failure [34]. Therefore, clinicians should be aware of the
412 importance of early administration of haptoglobin, a plasma fraction preparation [35]. In
413 a study by Fujiki et al. [33], early haptoglobin administration for hemoglobinuria
414 prevented renal damage in all cases, and these authors identified that a 5% ethanolamine
415 oleate dose ≥ 0.18 mL/kg was a predictive factor for gross hematuria. To avoid acute renal
416 failure, it is essential to disseminate information regarding the risk of hemoglobinuria
417 with ethanolamine oleate use through guidelines or similar resources. Interestingly, no

418 cases of skin ulceration or skin necrosis were observed in the present study, whereas
419 previous studies have reported incidence rates of 3.0–14.7% [7,21,36]. The absence of
420 these complications implies a safer treatment profile with our regimen.

421

422 **Limitations of this study**

423 Some limitations were noted in the present study. First, the study employed a
424 single-arm design and included a relatively limited sample size. Although this reflected
425 the rarity of the studied disease, this also limits the generalizability of our findings.
426 Nevertheless, our study population was comparable to that included in the trial that
427 served as the basis for approval (44 patients), and our study employed a post-intervention
428 evaluation period of 3 months. Larger scale studies with longer follow-up periods are
429 needed to clarify our findings. Second, while no age restrictions were imposed in this
430 study, we were unable to recruit children ≤ 2 years of age, which is a significant
431 population affected by VMs. Lastly, the inclusion of some patients who lacked baseline
432 pain assessment data and the presence of age-related variations in pain scale
433 comprehension limited the applicability of a single pain assessment tool.

434

435 **Conclusion**

436 To the best of our knowledge, this is the first prospective clinical trial to expound
437 the indications for ethanolamine oleate administration in patients with difficult-to-resect
438 VMs in Japan. In our study population of 44 patients, ethanolamine oleate significantly
439 reduced VM lesion volume and improved pain. Regarding safety, clinicians should be
440 aware of the significance of early haptoglobin administration for drug-induced
441 hemoglobinuria. Our results highlight the potential of ethanolamine oleate as a treatment

442 option for patients with difficult-to-resect VMs. Further studies with larger sample sizes
443 and longer follow-up durations are warranted to evaluate the long-term clinical outcomes
444 of this approach.

445

446 **Acknowledgments**

447 This study was supported by the Kobe Clinical and Translational Research Centre. We
448 thank all the staff for their involvement in this clinical trial.

449

450 **Data sharing statement**

451 Individual participant data underlying the results (text, tables, and figures) reported in this
452 article after de-identification will be shared following article publication. Requests will
453 be honored by researchers who provide a methodologically sound proposal and execute a
454 data-use agreement with Kyorin University. Requests should be directed to the
455 corresponding author by email.

456

457 **Declaration of interest**

458 Fuji Chemical Industries Co., Ltd. provided ethanolamine oleate for treatment during the
459 study period; however, the company had no role in this clinical trial. The authors declare
460 no conflict of interest.

461

462 **Role of sponsor**

463 The funders had no role in study design, data collection and analysis, decision to publish,
464 or preparation of the manuscript.

465

466 **Ethics**

467 This study was conducted using good clinical practice and adhered to the principles of the
468 Declaration of Helsinki. It was approved by the ethics committee of each hospital and
469 registered with the Japan Registry of Clinical Trials (Identifier: jRCT2051200046) under
470 the recommendations of the International Committee of Medical Journal Editors
471 (Registered on August 25, 2020). (<https://jrct.niph.go.jp/latest-detail/jRCT2051200046>).

472 Written informed consent was obtained from all patients or their parents/guardians. This
473 registry is independent of for-profit interests.

474

475 **Contributors' statement**

476 Tadashi Nomura conceptualized, designed, managed, and conducted the clinical trial and
477 collected the data.

478 Yasumasa Kakei conceptualized, designed, and managed the clinical trial and drafted the
479 manuscript.

480 Keiko Miyakoda conceptualized and designed the clinical trial and was responsible for
481 statistical analyses as a biostatistician.

482 Masakazu Kurita, Ayato Hayashi, Noriko Aramaki, Makoto Hikosaka, Shunsuke

483 Yuzuriha, Keigo Osuga, Yuki Iwashina, Taiki Nozaki, and Michio Ozeki conducted the

484 clinical trial and collected the data.

485 Mine Ozaki conceptualized, designed, managed, and conducted the clinical trial and
486 collected the data.
487 All authors approved the final manuscript and agreed to be accountable for all aspects of
488 this study.
489

490 **References**

- 491 1. Mulliken JB, Glowacki J. Hemangiomas and vascular malformations in infants
492 and children: a classification based on endothelial characteristics. *Plast Reconstr*
493 *Surg.* 1982;69: 412-422. doi: 10.1097/00006534-198203000-00002.
- 494 2. Hein KD, Mulliken JB, Kozakewich HP, Upton J, Burrows PE. Venous
495 malformations of skeletal muscle. *Plast Reconstr Surg.* 2002;110: 1625-1635.
496 doi: 10.1097/01.PRS.0000033021.60657.74.
- 497 3. Carabin J, Bouhamama A, Vaz G, Cuinet M, Ricoeur A, Thibaut A, et al.
498 Percutaneous cryoablation of symptomatic intramuscular venous malformation. *J*
499 *Vasc Interv Radiol.* 2020;31: 558-563.e3. doi: 10.1016/j.jvir.2019.10.024.
- 500 4. Kang GB, Bae YC, Nam SB, Bae SH, Sung JY. The usefulness of surgical
501 treatment in slow-flow vascular malformation patients [published correction
502 appears in *Arch Plast Surg.* 2017;44: 575-576]. *Arch Plast Surg.* 2017;44:
503 301-307. doi: 10.5999/aps.2017.44.4.301.
- 504 5. Roh YN, Do YS, Park KB, Park HS, Kim YW, Lee BB, et al. The results of
505 surgical treatment for patients with venous malformations. *Ann Vasc Surg.*
506 2012;26: 665-673. doi: 10.1016/j.avsg.2011.12.004.
- 507 6. Lee BB, Do YS, Byun HS, Choo IW, Kim DI, Huh SH. Advanced management of

- 508 venous malformation with ethanol sclerotherapy: mid-term results. *J Vasc Surg.*
509 2003;37: 533-538. doi: 10.1067/mva.2003.91.
- 510 7. Kaji N, Kurita M, Ozaki M, Takushima A, Harii K, Narushima M, et al.
511 Experience of sclerotherapy and embolosclerotherapy using ethanolamine oleate
512 for vascular malformations of the head and neck. *Scand J Plast Reconstr Surg*
513 *Hand Surg.* 2009;43: 126-136. doi: 10.1080/02844310902840296.
- 514 8. Górriz E, Carreira JM, Reyes R, Gervás C, Pulido JM, Pardo MD, et al.
515 Intramuscular low flow vascular malformations: treatment by means of direct
516 percutaneous embolization. *Eur J Radiol.* 1998;27: 161-165. doi:
517 10.1016/s0720-048x(97)00045-4.
- 518 9. Mimura H, Akita S, Fujino A, Jinnin M, Ozaki M, Osuga K, et al. Japanese
519 clinical practice guidelines for vascular anomalies 2017. *J Dermatol.* 2020;47:
520 e138-e183. doi: 10.1111/1346-8138.15189.
- 521 10. Mulliken JB, Burrows PE, Fishman SJ. Mulliken and Young's vascular
522 anomalies: hemangiomas and malformations. 2nd ed. New York: Oxford
523 University Press; 2013. pp. 662-672. doi:
524 10.1093/med/9780195145052.001.0001.
- 525 11. Heit JJ, Do HM, Prestigiacomo CJ, Delgado-Almandoz JA, English J, Gandhi

- 526 CD, et al. Guidelines and parameters for percutaneous sclerotherapy for the
527 treatment of head and neck venous and lymphatic malformations.
528 *NeuroIntervent Surg.* 2017;9: 611-617. doi: 10.1136/neurintsurg-2015-012255.
- 529 12. Rabe E, Breu FX, Cavezzi A, Smith PC, Frullini A, Gillet JL, et al. European
530 guidelines for sclerotherapy in chronic venous disorders. *Phlebology.* 2014;29:
531 338-354. doi: 10.1177/0268355513483280.
- 532 13. Uehara S, Osuga K, Yoneda A, Oue T, Yamanaka H, Fukuzawa M. Intralesional
533 sclerotherapy for subcutaneous venous malformations in children. *Pediatr Surg*
534 *Int.* 2009;25: 709-713. doi: 10.1007/s00383-009-2414-y.
- 535 14. Ozaki M, Kurita M, Kaji N, Fujino T, Narushima M, Takushima A, et al. Efficacy
536 and evaluation of safety of sclerosants for intramuscular venous malformations:
537 clinical and experimental studies. *Scand J Plast Reconstr Surg Hand Surg.*
538 2010;44: 75-87. doi: 10.3109/02844310903569725.
- 539 15. Mimura H, Kanazawa S, Yasui K, Fujiwara H, Hyodo T, Mukai T, et al.
540 Percutaneous sclerotherapy for venous malformations using polidocanol under
541 fluoroscopy. *Acta Med Okayama.* 2003;57: 227-234. doi: 10.18926/AMO/51909.
- 542 16. Nakahata K, Uehara S, Zenitani M, Nakamura M, Osuga K, Okuyama H. Patient
543 satisfaction after sclerotherapy of venous malformations in children. *Pediatr Int.*

- 544 2016;58: 721-725. doi: 10.1111/ped.12880.
- 545 17. Yamaki T, Nozaki M, Sasaki K. Color duplex-guided sclerotherapy for the
546 treatment of venous malformations. *Dermatol Surg.* 2000;26: 323-328. doi:
547 10.1046/j.1524-4725.2000.99248.x.
- 548 18. Jo JY, Chin JH, Park PH, Ku SW. Cardiovascular collapse due to right heart
549 failure following ethanol sclerotherapy: A case report. *Korean J Anesthesiol.*
550 2014;66: 388-391. doi: 10.4097/kjae.2014.66.5.388.
- 551 19. Marrocco-Trischitta MM, Guerrini P, Abeni D, Stillo F. Reversible cardiac arrest
552 after polidocanol sclerotherapy of peripheral venous malformation. *Dermatol*
553 *Surg.* 2002;28: 153-155. doi: 10.1046/j.1524-4725.2002.00344.x.
- 554 20. Horbach SER, Lokhorst MM, Saeed P, de Goüyon Matignon de Pontouraude
555 CMF, Rothová A, van der Horst CMAM. Sclerotherapy for low-flow vascular
556 malformations of the head and neck: A systematic review of sclerosing agents. *J*
557 *Plast Reconstr Aesthet Surg.* 2016;69: 295-304. doi: 10.1016/j.bjps.2015.10.045.
- 558 21. Hoque S, Das BK. Treatment of venous malformations with ethanolamine
559 oleate: a descriptive study of 83 cases. *Pediatr Surg Int.* 2011;27: 527-531. doi:
560 10.1007/s00383-010-2824-x.
- 561 22. Kobayakawa M, Kokubu S, Hirota S, Koizumi J, Nishida N, Yasumoto T, et al.

- 562 Short-term safety and efficacy of balloon-occluded retrograde transvenous
563 obliteration using ethanolamine oleate: Results of a prospective, multicenter,
564 single-arm trial. *J Vasc Interv Radiol.* 2017;28: 1108-1115.e2. doi:
565 10.1016/j.jvir.2017.03.041.
- 566 23. Masaki M, Obara K, Suzuki S, Orikasa K, Mitsuhashi H, Iwasaki K, et al. The
567 destructive effects of sclerosant ethanolamine oleate on mammalian vessel
568 endothelium. *Gastroenterol Jpn.* 1990;25: 230-235. doi: 10.1007/BF02776821.
- 569 24. Bagga B, Goyal A, Das A, Bhalla AS, Kandasamy D, Singhal M, et al.
570 Clinicoradiologic predictors of sclerotherapy response in low-flow vascular
571 malformations. *J Vasc Surg Venous Lymphat Disord.* 2021;9: 209-219.e2. doi:
572 10.1016/j.jvsv.2020.03.011.
- 573 25. Alexander MD, McTaggart RA, Choudhri OA, Marcellus ML, Do HM.
574 Percutaneous sclerotherapy with ethanolamine oleate for venous malformations
575 of the head and neck. *J Neurointerv Surg.* 2014;6: 695-698. doi:
576 10.1136/neurintsurg-2013-010924.
- 577 26. Rautio R, Saarinen J, Laranne J, Saleniui JP, Keski-Nisula L. Endovascular
578 treatment of venous malformations in extremities: Results of sclerotherapy and
579 the quality of life after treatment. *Acta Radiol.* 2004;45: 397-403. doi:

- 580 10.1080/02841850410004913.
- 581 27. Wong DL, Baker CM. Pain in children: Comparison of assessment scales.
582 Pediatr Nurs. 1988;14: 9-17.
- 583 28. Hahn GJ, Meecker WQ. Statistical intervals: A guide for practitioners. New York:
584 John Wiley & Sons; 1991.
- 585 29. Das BK, Hoque S. Treatment of venous malformations with ethanolamine oleate.
586 Asian J Surg. 2008;31: 220-224. doi: 10.1016/S1015-9584(08)60091-3.
- 587 30. Ribeiro MC, de Mattos Camargo Grossmann S, do Amaral MBF, de Castro WH,
588 Navarro TP, Procopio RJ, et al. Effectiveness and safety of foam sclerotherapy
589 with 5% ethanolamine oleate in the treatment of low-flow venous malformations
590 in the head and neck region: A case series. Int J Oral Maxillofac Surg. 2018;47:
591 900-907. doi: 10.1016/j.ijom.2017.12.004.
- 592 31. Mimura H, Fujiwara H, Hiraki T, Gobara H, Mukai T, Hyodo T, et al. Polidocanol
593 sclerotherapy for painful venous malformations: evaluation of safety and efficacy
594 in pain relief. Eur Radiol. 2009;19: 2474-2480. doi: 10.1007/s00330-009-1442-2.
- 595 32. Nagata S, Tanaka N, Kuhara A, Kugiyama T, Tanoue S, Koganemaru M, et al.
596 Value of fat-suppressed T2-weighted imaging for predicting short-term pain relief
597 after sclerotherapy for venous malformations in the extremities. Jpn J Radiol.

- 598 2023;41: 1157-1163. doi: 10.1007/s11604-023-01442-x. Epub 2023 May 12.
- 599 33. Fujiki M, Ozaki M, Kurachi I, Iwashina Y, Takushima A. Risk factors for
600 macroscopic haemoglobinuria after sclerotherapy using ethanolamine oleate for
601 venous malformations. *Eur J Vasc Endovasc Surg.* 2019;58: 105-111. doi:
602 10.1016/j.ejvs.2018.12.018.
- 603 34. Yamaki T, Nozaki M, Sakurai H, Takeuchi M, Soejima K, Kono T. Prospective
604 randomized efficacy of ultrasound-guided foam sclerotherapy compared with
605 ultrasound-guided liquid sclerotherapy in the treatment of symptomatic venous
606 malformations. *J Vasc Surg.* 2008;47: 578-584. doi: 10.1016/j.jvs.2007.11.026.
- 607 35. Hashizume M, Kitano S, Yamaga H, Sugimachi K. Haptoglobin to protect against
608 renal damage from ethanolamine oleate sclerosant. *Lancet.* 1988;2: 340-341. doi:
609 10.1016/s0140-6736(88)92400-2.
- 610 36. Costa JR, Torriani MA, Hosni ES, D'Avila OP, de Figueiredo PJ. Sclerotherapy
611 for vascular malformations in the oral and maxillofacial region: treatment and
612 follow-up of 66 lesions. *J Oral Maxillofac Surg.* 2011;69: e88-e92. doi:
613 10.1016/j.joms.2010.06.204.
- 614

Obtain consent

45 patients

Eligibility assessment

e.g., venous malformations deemed difficult-to-resect, one or more target venous malformations with a major axis of ≥ 30 mm in extremities and ≥ 20 mm in the head and neck region on MRI or CT

Excluded one patient who was deemed ineligible by the investigator

Enrollment

Target number: 44 patients (Cystic type: 22, Diffuse type: 22)

Enrolment period: 2 years from January 2021

Follow-up period: 3 months

Intervention

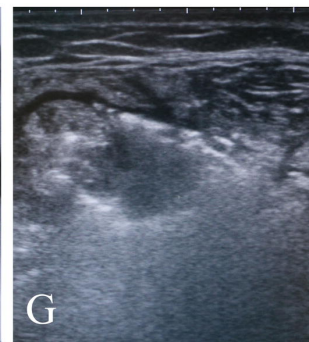
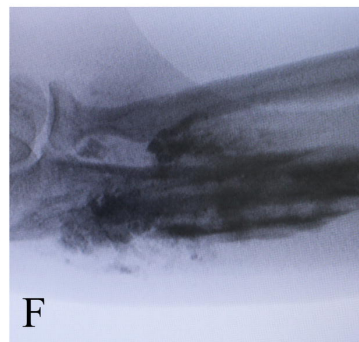
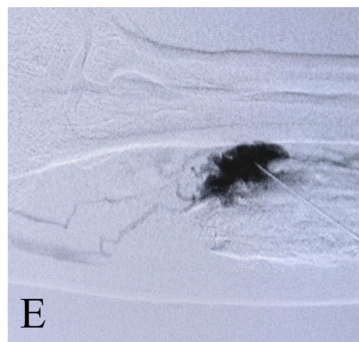
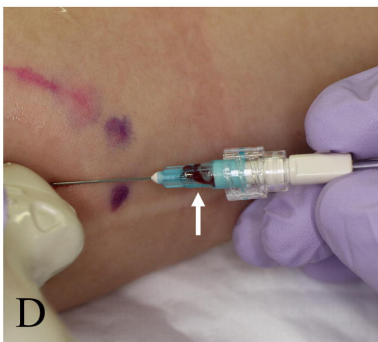
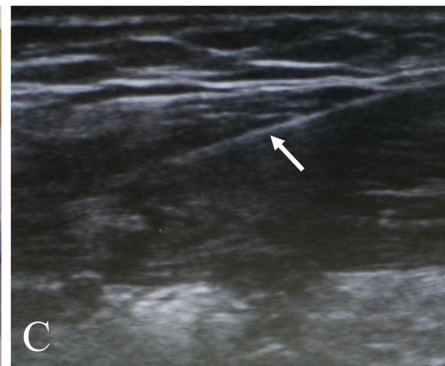
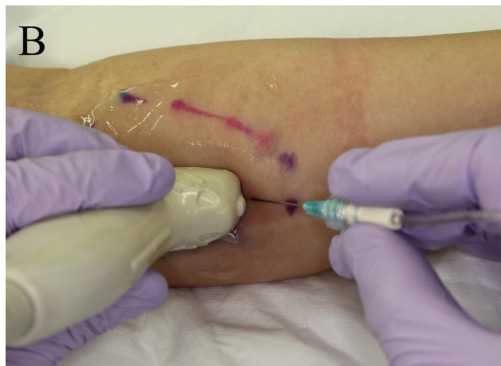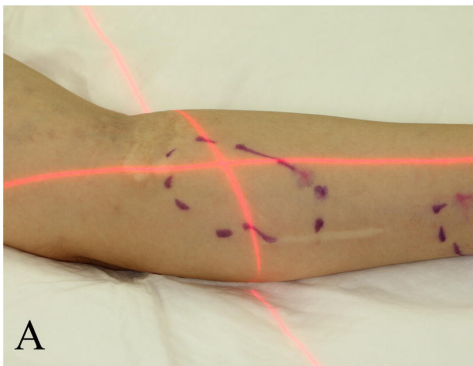
44 patients (Cystic type: 22, Diffuse type: 22)

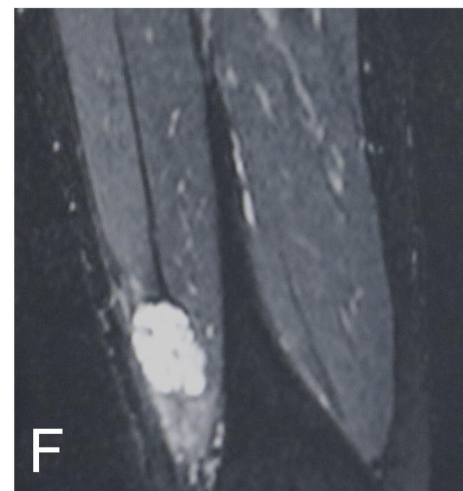
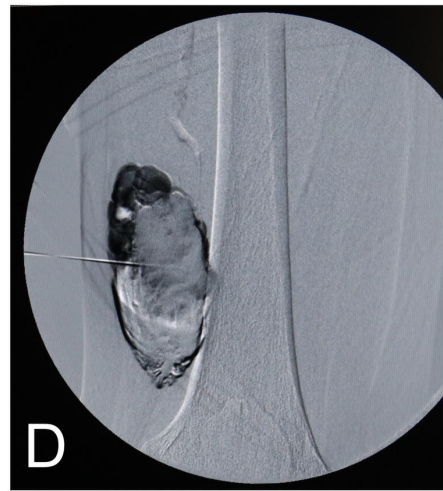
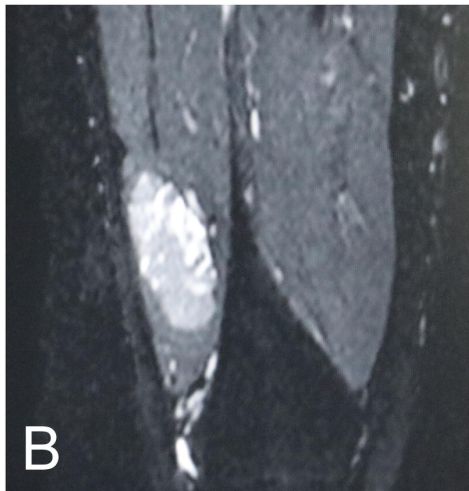
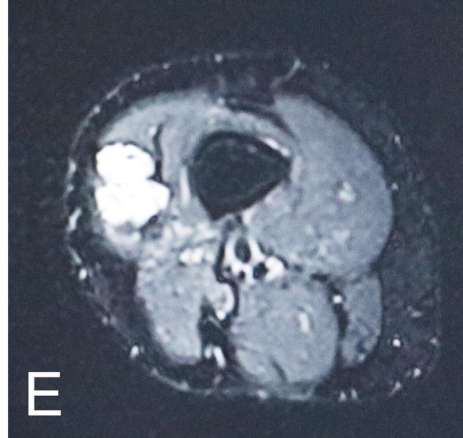
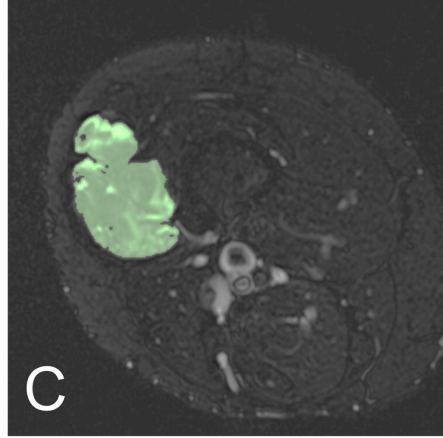
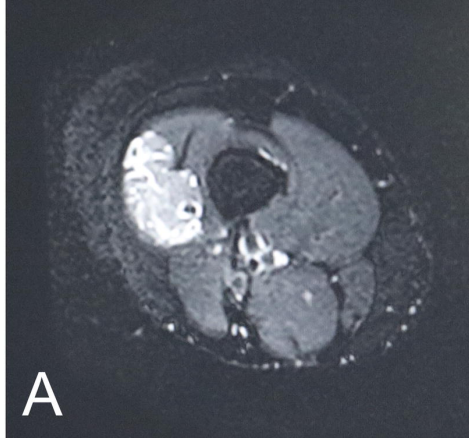
Single administration of ethanolamine oleate

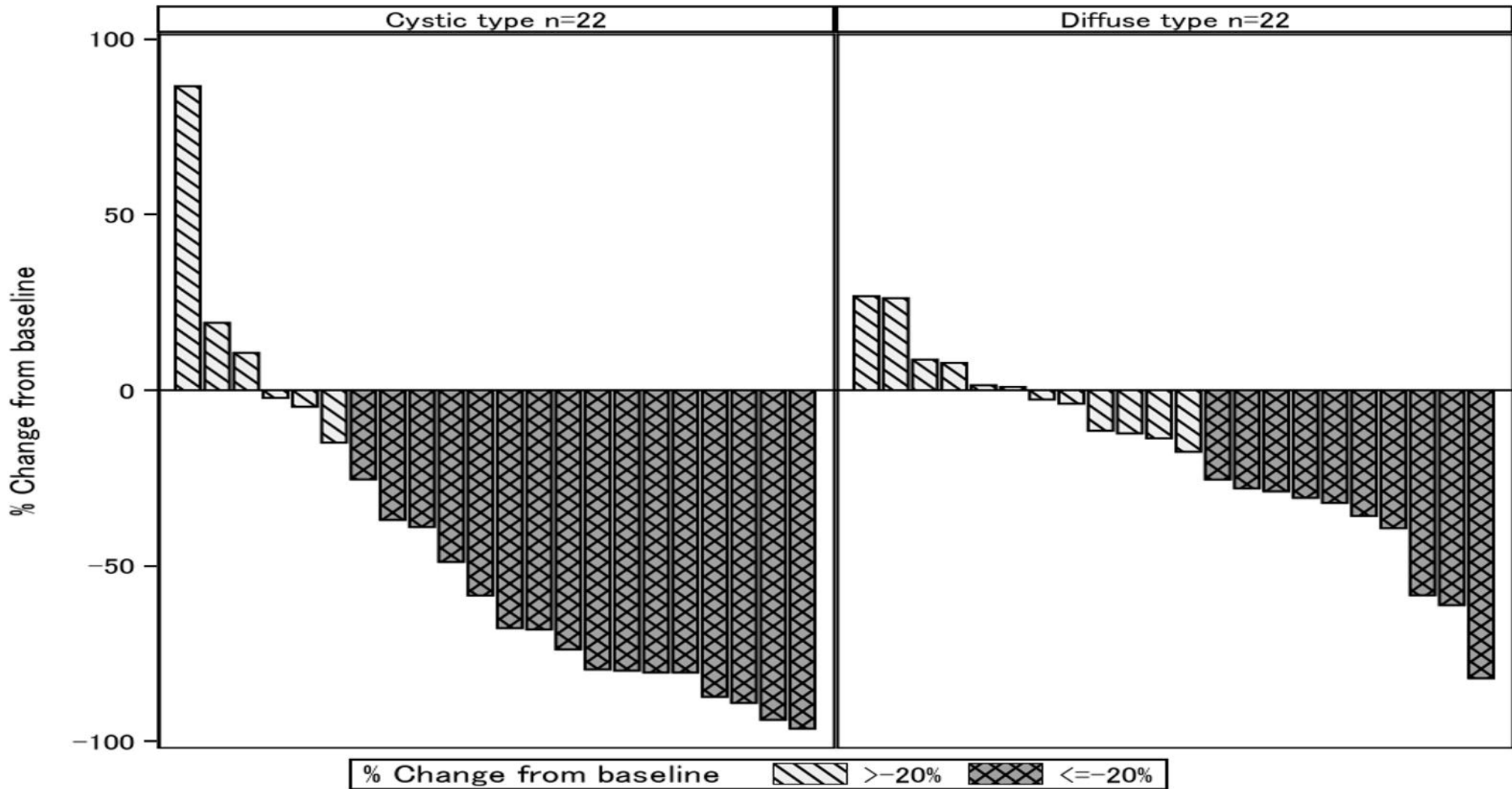
Efficacy assessment

44 patients (Cystic type: 22, Diffuse type: 22)

Primary endpoint: $\geq 20\%$ reduction in the venous malformation volume from the time of enrolment to 3 months post-treatment



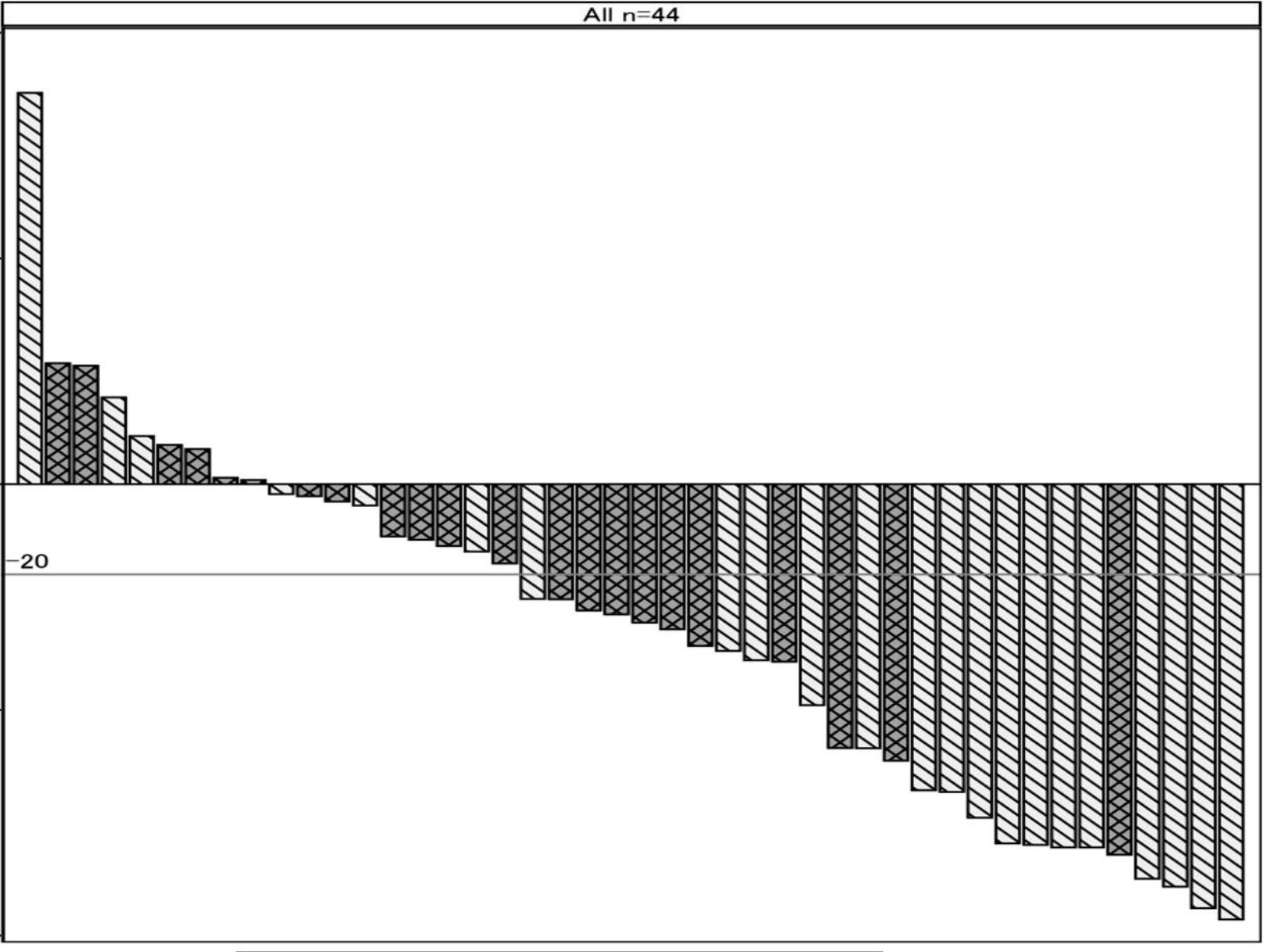




All n=44

% Change from baseline

100
50
0
-20
-50
-100



Lesion Cystic type Diffuse type