

1        **DIAGNOSIS IN BYTES: COMPARING THE DIAGNOSTIC ACCURACY OF**  
2                    **GOOGLE AND CHATGPT 3.5 AS DIAGNOSTIC SUPPORT TOOLS**

3

4                    **Running title: Accuracy Comparison: Google vs. ChatGPT 3.5**

5

6                    **Authors:**

7

8        **Guilherme R Guimaraes<sup>1</sup>, Caroline Santos Silva<sup>1</sup>, Jean Carlos Z**  
9        **Contreras<sup>1</sup>, Ricardo G Figueiredo<sup>1</sup>, Uros - Grupo de Pesquisa<sup>2</sup>, Ricardo B**  
10       **Tiraboschi<sup>1</sup>, Cristiano M Gomes<sup>3</sup>, and Jose de Bessa Junior<sup>1</sup>**

11

12       **1 – Universidade Estadual de Feira de Santana – UEFS**

13       **2 – Collaborative Research Group (undergraduate students) – Medical**  
14       **School Universidade Estadual de Feira de Santana – UEFS**

15       **3 – Universidade de São Paulo - USP**

16

17       **ABSTRACT**

18

19       **Objective:** Adopting digital technologies as diagnostic support tools in medicine  
20       is unquestionable. However, the accuracy in suggesting diagnoses remains  
21       controversial and underexplored. We aimed to evaluate and compare the  
22       diagnostic accuracy of two primary and accessible internet search tools: Google  
23       and ChatGPT 3.5.

24       **Method:** We used 60 clinical cases related to urological pathologies to evaluate  
25       both platforms. These cases were divided into two groups: one with common  
26       conditions (constructed from the most frequent symptoms, following EAU and  
27       UpToDate guidelines) and another with rare disorders - based on case reports  
28       published between 2022 and 2023 in Urology Case Reports. Each case was  
29       inputted into Google Search and ChatGPT 3.5, and the results were

30 categorized as "correct diagnosis," "likely differential diagnosis," or "incorrect  
31 diagnosis." A team of researchers evaluated the responses blindly and  
32 randomly.

33 **Results:** In typical cases, Google achieved 53.3% accuracy, offering a likely  
34 differential diagnosis in 23.3% and errors in the rest. ChatGPT 3.5 exhibited  
35 superior performance, with 86.6% accuracy, and suggested a reasonable  
36 differential diagnosis in 13.3%, without mistakes. In rare cases, Google did not  
37 provide correct diagnoses but offered a likely differential diagnosis in 20%.  
38 ChatGPT 3.5 achieved 16.6% accuracy, with 50% differential diagnoses.

39 **Conclusion:** ChatGPT 3.5 demonstrated higher diagnostic accuracy than  
40 Google in both contexts. The platform showed acceptable accuracy in common  
41 cases; however, limitations in rare cases remained evident.

42

43 **Keywords:** Medical Informatics Applications; Artificial Intelligence; Diagnosis;  
44 Urology.

45 **INTRODUCTION**

46

47         The advent of the first data processing machines in the 1940s piqued the  
48 interest of experts from various fields for their potential applications, and  
49 medicine was no exception (1). As early as 1959, Brodman and colleagues  
50 demonstrated that a trained computerized system could identify patterns in a  
51 group of symptoms reported by patients and suggest possible diagnoses,  
52 performing comparably to physicians receiving the same information (2). Since  
53 then, data analytics technologies and Artificial Intelligence (AI) have gained  
54 prominence in various medical fields, including public health, medical image  
55 analysis, clinical trials, and more (3).

56         The increasing capability of these tools to integrate information has  
57 allowed researchers to envision diagnostic applications far beyond what  
58 Broadman presented. It is now possible to input a patient's symptoms into  
59 everyday search tools and receive a list of likely diagnoses (3,4). Such utility  
60 was already explored by Tang and Ng in 2006, who assessed the frequency of  
61 accurate diagnoses provided when specific symptoms of specific diseases were  
62 searched on Google, the leading internet search site (5).

63         In addition to search tools, new chatbots have been explored for this  
64 purpose, merging AI with messaging interfaces, such that recent initial studies  
65 have attempted to evaluate the diagnostic accuracy of these instruments (6).  
66 The most famous of these is the Generative Pre-Trained Transformer -  
67 ChatGPT 3.5, developed by OpenAI, whose operational model is not solely  
68 based on delivering pages with more terms matching the search, like traditional  
69 search tools, but instead on providing real-time AI-generated text based on the  
70 extensive database on which the AI was trained (7,8).

71         In this context of evolving information technologies and their increasingly  
72 pervasive integration in medicine, this study aimed to evaluate and compare the  
73 diagnostic accuracy for urological cases of two leading internet search tools:  
74 Google and ChatGPT 3.5.

75

76 **METHODS**

77

78           This diagnostic evaluation study was conducted between April and June  
79 2023, in which the diagnostic accuracy of the platforms Google and ChatGPT  
80 3.5 was assessed. These tools were evaluated based on the responses to 60  
81 clinical cases related to urological pathologies, divided into "common" and  
82 "rare" conditions. Questions were formulated in Portuguese Language.

83           In the first group, 30 descriptions summarized the typical clinical  
84 presentation of common urological diseases, written under the European  
85 Association of Urology and UpToDate guidelines. In the second group, the  
86 remaining 30 cases were based on reports published between 2022 and 2023  
87 in Urology Case Reports, selected based on the typicality of their manifestations  
88 (Supplementary File 1). Questions requiring extensive evaluation for specific  
89 diagnoses were excluded.

90           Each clinical case was inputted into Google Search and ChatGPT 3.5,  
91 and the results were categorized as "correct," likely and plausible," and  
92 "incorrect" according to the blind and random judgment of a panel of 3  
93 researchers. For Google Search, an incognito tab in the browser was used, with  
94 no linked account, to minimize any influence from previous search history, and  
95 the first three displayed results were considered for diagnostic categorization.  
96 For ChatGPT 3.5, a specific "account" was created to reduce the influence of  
97 prior searches.

98           The results were described in absolute numbers and percentages. The  
99 Chi-square test was used for proportion comparison, and the Kappa test was  
100 employed to assess agreement between the instruments. GraphPad Prism  
101 version 10.0.0 for Windows, GraphPad Software, Boston, Massachusetts, USA,  
102 was used for analysis and graphs.

103

104 **RESULTS**

105

106 Both platforms showed promising results when dealing with more typical  
107 or "common" urological cases. Google Search demonstrated a diagnostic  
108 accuracy rate of 16 (53.3%). It correctly identified the disease in over half of the  
109 topics and provided likely differential diagnoses in seven more (23.3%).  
110 However, it failed to produce the correct response in the remaining cases.

111 In contrast, ChatGPT 3.5 outperformed Google, achieving a correct  
112 response in 26 (86.6%) cases and offering likely differential diagnoses in  
113 another four (13.3%) cases, with no incorrect diagnoses.

114 Regarding the rarer urological conditions, the performances of the two  
115 platforms significantly diverged. Google could not produce correct diagnoses  
116 but offered likely differential diagnoses in six (20%) cases. Google's  
117 suggestions were incorrect in the remaining 24 (80%) cases. On the other hand,  
118 ChatGPT 3.5 showed moderate success in diagnosing rare conditions, with a  
119 correct diagnostic rate of five (16.6%). Impressively, it provided a likely  
120 differential diagnosis in half of the cases, 15 (50%). However, it should be noted  
121 that the platform made diagnostic errors in the remaining instances (Figure 1).

122 When analyzed together, ChatGPT 3.5 was significantly superior to  
123 Google. It got it right or suggested an acceptable differential diagnosis in 50  
124 (83.3%), while Google did so in 29 (48.3%).  $RR=1.46$   $p< 0.001$ . Both tools did  
125 not respond correctly to ten questions (rare cases). There was low agreement  
126 between the two tools.  $Kappa=0.315$ .

127

128 **DISCUSSION**

129

130 We can demonstrate that ChatGPT 3.5 outperformed Google in this  
131 experiment, simulating real-life urological scenarios. Both platforms vary in  
132 performance depending on the complexity and rarity of urological conditions.  
133 While Google remained moderately effective in ordinary cases, its performance  
134 dropped significantly in the context of rarer diseases. On the other hand,  
135 ChatGPT 3.5 showed a high degree of accuracy in diagnosing common  
136 urological diseases and a moderate level of success in rare and uncommon  
137 conditions.

138 These findings indicate the need to acknowledge the variable  
139 performance of these tools in different clinical scenarios, highlighting their  
140 strengths and areas where improvements are needed. The results also raise  
141 essential questions about the role of AI-based platforms like ChatGPT 3.5 in  
142 clinical decision-making and education. The explosive growth of medical  
143 knowledge exacerbates the challenges faced by healthcare professionals.  
144 Estimates indicate that the time required for medical knowledge to double has  
145 drastically decreased - from 50 years in 1950 to 73 days in 2020(9). These  
146 rapid advances mean medical students must master 342 potential diagnoses for  
147 37 frequently presented signs and symptoms before graduating(10). This  
148 volume of information can be overwhelming and underscores the growing need  
149 for accurate and efficient diagnostic tools to assist physicians and other  
150 healthcare providers.

151 General search engines like Google have existed for some time and  
152 have gradually found applications in the medical field(11,12). In 1999, Graber  
153 and colleagues assessed the use of search engines to answer medical  
154 questions, finding that these platforms could correctly answer half of the  
155 questions (11). By 2006, Google had already become the dominant search tool,  
156 providing correct diagnoses in 58% of cases in Tang and Ng's study(5). Another  
157 study evaluated the diagnostic accuracy of medical students before and after  
158 consulting Google and PubMed, noting a statistically insignificant but interesting  
159 9.9% increase in diagnostic accuracy(13).

160 More recently, chatbots, which combine AI with messaging interfaces,  
161 have emerged as precise tools for generating direct responses(14,15). A

162 Japanese study showed that ChatGPT 3 achieved a correct diagnostic rate of  
163 93.3% when considering a list of ten probable differential diagnoses(16). The  
164 same platform demonstrated an accuracy rate of 80% in questions about  
165 cirrhosis and hepatocellular carcinoma and an accuracy of 88% in breast  
166 cancer prevention and screening(17,18).

167 In the field of urology, ChatGPT 3.5's performance has been variable. In  
168 one study, the platform correctly answered 92% of pediatric urology  
169 questions(19). However, the platform's performance dropped to 52% in another  
170 assessment focused on general urology(20). As illustrated by Huynh and  
171 colleagues, ChatGPT 3.5 performed poorly in the American Urological  
172 Association's 2022 self-assessment study program, scoring below 30%(21).  
173 Studies evaluating the quality of information provided to the general population  
174 about urological pathologies presented good information but not without  
175 bias(22,23).

176 The current study expands on existing research by directly comparing the  
177 diagnostic effectiveness of Google and ChatGPT 3.5 for urological conditions.  
178 Our results indicate that ChatGPT 3.5 outperformed Google in common and  
179 rare cases. While the platform showed high precision in diagnosing common  
180 urological conditions, it demonstrated moderate success with rarer diseases.  
181 These findings offer promising perspectives for integrating such tools in  
182 educational and clinical workflows.

183 These platforms can assist urological researchers in analyzing and  
184 interpreting data, writing articles, and creating educational material. Their use  
185 today should be considered complementary to the experience of doctors and  
186 healthcare professionals involved in care. Given the identified limitations, it is  
187 evident that both platforms require improvements. The potential for access to  
188 more specialized medical databases and continuous algorithmic training  
189 promises even more incredible future utility. Ethical considerations cannot be  
190 overlooked either. There must be extensive discussion about the quality of  
191 information these platforms provide and how user privacy is ensured, as  
192 sensitive data may be involved. As these platforms evolve, their utility as  
193 diagnostic tools may become more robust, promoting more innovative and  
194 secure healthcare applications.

195            This research paves the way for future investigations into how AI-based  
196 tools, like ChatGPT, could be more effectively integrated into clinical practice,  
197 offering more reliable and swift diagnoses and potentially enhancing patient  
198 outcomes, complementing the human experience.

199            Our study contributes to a broader conversation about the evolving role  
200 of technology in healthcare, specifically in the field of urology, where accurate  
201 and timely diagnosis is often critical to treatment success and patient well-  
202 being.

203



204 **CONCLUSION**

205

206 We can demonstrate that ChatGPT 3.5 exhibited superior diagnostic  
207 accuracy compared to Google in both common and rare urological scenarios.  
208 ChatGPT 3.5 displayed acceptable accuracy in habitual conditions cases but  
209 was still relatively limited in rare cases. Such findings allow us to glimpse some  
210 use of these tools in educational and training processes. Access to medical  
211 databases and ongoing development can bring considerable advances,  
212 enabling even more robust, innovative, secure, and possibly assisting us in  
213 caring for people.

214

215 **REFERENCES**

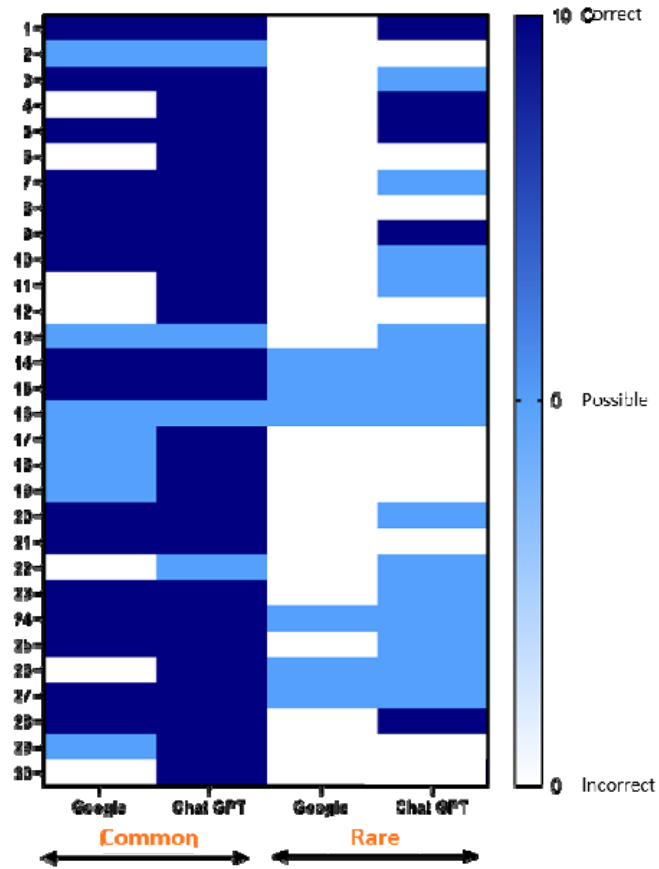
216

- 217 1. Mahoney MS. The History of Computing in the History of Technology. *Ann*  
218 *Hist Comput.* 1988;10(2):113–25.
- 219 2. Brodman K, Van Woerkom AJ, Erdmann AJ, Goldstein LS. Interpretation  
220 of Symptoms with a Data-Processing Machine. *Arch Intern Med.*  
221 1959;103.
- 222 3. Haug CJ, Drazen JM. Artificial Intelligence and Machine Learning in  
223 Clinical Medicine, 2023. *N Engl J Med.* 2023;388(13):1201–8.
- 224 4. Al-Antari MA. Artificial Intelligence for Medical Diagnostics - Existing and  
225 Future AI Technology! *Diagnostics.* 2023;13(4).
- 226 5. Tang H, Ng JHK. Googling for a diagnosis - Use of Google as a diagnostic  
227 aid: Internet based study. *Br Med J.* 2006;333(7579):1143–5.
- 228 6. Gupta R, Pedraza AM, Gorin MA, Tewari AK. Defining the Role of Large  
229 Language Models in Urologic Care and Research. *Eur Urol Oncol.* 2023;
- 230 7. Drazen JM, Kohane IS, Leong T-Y, Lee P, Bubeck S, Petro J. Chatbot for  
231 Medicine. *N Engl J Med.* 2023;388(13).
- 232 8. Reis LO. ChatGPT for medical applications and urological science. *Int*  
233 *Brazilian J Urol.* 2023;49(5):652–6.
- 234 9. Densen P. Challenges and opportunities facing medical education. *Trans*  
235 *Am Clin Climatol Assoc.* 2011;122.
- 236 10. Urushibara-Miyachi Y, Kikukawa M, Ikusaka M, Otaki J, Nishigori H. Lists  
237 of potential diagnoses that final-year medical students need to consider: a  
238 modified Delphi study. *BMC Med Educ.* 2021;21(1).
- 239 11. Graber MA, Bergus GR, York C. Using the World Wide Web to Answer  
240 Clinical Questions: How Efficient Are Different Methods of Information  
241 Retrieval? *J Fam Pract.* 1999;49(7).
- 242 12. Giustini D. How Google is changing medicine. *Br Med J.*  
243 2005;331(7531):1487–8.
- 244 13. Falagas ME, Ntziora F, Makris GC, Malietzis GA, Rafailidis PI. Do  
245 PubMed and Google searches help medical students and young doctors  
246 reach the correct diagnosis? A pilot study. *Eur J Intern Med.*  
247 2009;20(8):788–90.
- 248 14. Adamopoulou E, Moussiades L. Chatbots: History, technology, and  
249 applications. *Mach Learn with Appl.* 2020;2.
- 250 15. Laranjo L, Dunn AG, Tong HL, Kocaballi AB, Chen J, Bashir R, et al.  
251 Conversational agents in healthcare: a systematic review. *J Am Med*  
252 *Informatics Assoc [Internet].* 2018 [citado 8 de Setembro de  
253 2023];25(9):1248–58. Disponível em:  
254 <https://academic.oup.com/jamia/article/25/9/1248/5052181>

- 255 16. Hirosawa T, Harada Y, Yokose M, Sakamoto T, Kawamura R, Shimizu T.  
256 Diagnostic Accuracy of Differential-Diagnosis Lists Generated by  
257 Generative Pretrained Transformer 3 Chatbot for Clinical Vignettes with  
258 Common Chief Complaints: A Pilot Study. *Int J Environ Res Public Health*.  
259 2023;20(4).
- 260 17. Yeo YH, Samaan JS, Ng WH, Ting P-S, Trivedi H, Vipani A, et al.  
261 Assessing the performance of ChatGPT in answering questions regarding  
262 cirrhosis and hepatocellular carcinoma. *Clin Mol Hepatol*. 2023;29(3).
- 263 18. Haver HL, Ambinder EB, Bahl M, Oluyemi ET, Jeudy J, Yi PH.  
264 Appropriateness of Breast Cancer Prevention and Screening  
265 Recommendations Provided by ChatGPT. *Radiology*. 2023;307(4).
- 266 19. Caglar U, Yildiz O, Meric A, Ayranci A, Gelmis M, Sarilar O, et al.  
267 Evaluating the performance of ChatGPT in answering questions related to  
268 pediatric urology. *J Pediatr Urol*. 2023;
- 269 20. Cocci A, Pezzoli M, Lo Re M, Russo GI, Asmundo MG, Fode M, et al.  
270 Quality of information and appropriateness of ChatGPT outputs for  
271 urology patients. *Prostate Cancer Prostatic Dis*. 2023;1–6.
- 272 21. Huynh LM, Bonebrake BT, Schultis K, Quach A, Deibert CM. New Artificial  
273 Intelligence ChatGPT Performs Poorly on the 2022 Self-assessment  
274 Study Program for Urology. *Urol Pract*. 2023;10(4):409–15.
- 275 22. Szczesniewski JJ, Tellez Fouz C, Ramos Alba A, Diaz Goizueta FJ,  
276 García Tello A, Llanes González L. ChatGPT and most frequent urological  
277 diseases: analysing the quality of information and potential risks for  
278 patients. *World J Urol*. 2023;
- 279 23. Whiles BB, Bird VG, Canales BK, DiBianco JM, Terry RS. Caution! AI bot  
280 has entered the patient chat: ChatGPT has limitations in providing  
281 accurate urologic healthcare advice. *Urology*. 2023;
- 282
- 283

284 **Figure 1:** Comparison of Diagnostic Accuracy between Google and ChatGPT

285 3.5



286

287

## Supplementary file 1: Clinical Cases

**Table 1: Common Urological Conditions**

Pathology	Clinical Case
<b>Case 1: UTI (Urinary Tract Infection)</b>	Woman, 27 years old, complains of dysuria, polyuria, and hematuria for about 6 days. Reports episodes of unmeasured fever and right flank pain. What is the likely diagnosis?
<b>Case 2: Nephrolithiasis (Kidney Stones)</b>	35-year-old man with left flank pain for 3 days, colicky, of strong intensity radiating to the inguinal region on the same side, presents nausea, fever, and dysuria. What is the likely diagnosis?
<b>Case 3: BPH (Benign Prostatic Hyperplasia)</b>	45-year-old man presents dysuria associated with increased urinary frequency, urinary incontinence, and an enlarged prostate.
<b>Case 4: Prostate Cancer</b>	62-year-old man reports urinary incontinence, blood in the urine, and discomfort when sitting for the past 1 and a half months. Lost 2kg during this period. What is the likely diagnosis?
<b>Case 5: Stress Urinary Incontinence</b>	62-year-old man reports stress urinary incontinence, without complaints of urinary urgency. What is the likely diagnosis?
<b>Case 6: Bladder Cancer</b>	82-year-old man presents painless hematuria, associated with bladder irritability, increased urinary frequency, and urinary urgency. What is the diagnosis?
<b>Case 7: Erectile Dysfunction</b>	50-year-old man with frequent difficulty in achieving a satisfactory erection for sexual intercourse and difficulty in maintaining a satisfactory erection for penetration. What is the correct diagnoses?

<b>Case 8: Varicocele</b>	25-year-old man with a left scrotum resembling a bag of worms, scrotal pain, testicular atrophy, and difficulty in conceiving. What is the likely diagnosis?
<b>Case 9: Interstitial Cystitis</b>	45-year-old woman complains of pain and discomfort for 3 months in the suprapubic region, related to bladder filling, with relief upon urination. What is the correct diagnosis?
<b>Case 10: Priapism</b>	22-year-old sickle cell anemia patient complains of a rigid and painful erection for 5 hours. What is the likely diagnosis?
<b>Case 11: Kidney Cancer</b>	63-year-old man reports moderate pain in the lower back, hematuria, sensation of incomplete emptying, and palpable abdominal mass. What is the diagnosis?
<b>Case 12: Testicular Cancer</b>	16-year-old boy complains of a solid lump palpated in the right testicle. He denies pain but reports a sensation of scrotal heaviness. What is the probable diagnosis?
<b>Case 13: Urethral Stricture</b>	45-year-old man complains of weak stream, polyuria, incomplete emptying, and post-micturition dribbling. What is the likely diagnosis?
<b>Case 14: Phimosis</b>	Pre-adolescent, 12 years old, comes to the outpatient clinic with his mother, complaining of excess preputial skin, with compromised retraction. He reports post-micturition balanitis, accompanied by erythema on the glans. What is the likely diagnosis?
<b>Case 15: Hypospadias</b>	Male newborn presents with dorsal hooded foreskin, abnormal penile curvature, and double urethral opening, one terminal and the other subcoronal. What is the likely diagnosis?
<b>Case 16: Prostatitis</b>	60-year-old man with high fever, dysuria, chills, irritating urinary symptoms, and cloudy urine. What is the likely diagnosis?
<b>Case 17: Gonorrhea</b>	23-year-old man, unmarried, sexually active with multiple partners, experiences burning during urination, greenish purulent discharge, and erythema. What is the possible diagnosis?
<b>Case 18: Polycystic</b>	54-year-old newly diagnosed hypertensive man reports hematuria and compromised renal function. He

<b>Kidney Disease</b>	mentions altered renal ultrasound and similar family history. What is the probable diagnosis?
<b>Case 19: Nocturnal Enuresis (Bedwetting)</b>	7-year-old boy presents with multiple episodes of nocturnal enuresis, started after his parents' divorce 3 months ago. He denies other changes. What is the likely diagnosis?
<b>Case 20: Urethritis</b>	24-year-old man reports pain during urination, increased urinary frequency, urinary urgency, and transparent urethral discharge. What is the probable diagnosis?
<b>Case 21: Male Infertility</b>	26-year-old married man, trying to have children for over 18 months without success. Wife underwent tests with negative results for health problems. He underwent a semen analysis and obtained a count of 3 million sperm. What is the possible diagnosis?
<b>Case 22: Urethral Diverticulum</b>	34-year-old woman complains of urinary dribbling after urination, dysuria, and dyspareunia for 1 year, associated with palpable vaginal mass. She reports a history of pelvic surgery and denies other conditions. What is the probable diagnosis?
<b>Case 23: Paraphimosis</b>	23-year-old man presents with glandular edema and intense pain in the penis. Physical examination reveals a constricting band of tissue in the coronal sulcus. What is the probable diagnosis?
<b>Case 24: Penile Cancer</b>	60-year-old man presents with a palpable tumor in the glans of the penis, ulceration, and skin irritation for over six weeks. What is the probable diagnosis?
<b>Case 25: Peyronie's Disease</b>	17-year-old man complains of severe dorsal penile curvature during erection, preventing penetration, associated with a palpable plaque on the dorsal side of the penis and pain. What is the probable diagnosis?
<b>Case 26: Traumatic Kidney Injury</b>	25-year-old man reports presence of blood in the urine, decreased urine volume, and mild abdominal pain after 24 hours of hospitalization due to a motorcycle accident with lower rib fractures. What is the probable diagnosis?

<b>Case 27: Cryptorchidism</b>	4-month-old male child comes for a medical examination because the testicles were not noticed after birth and not at 2 months of age. What is the probable diagnosis?
<b>Case 28: Female Sexual Dysfunction</b>	29-year-old woman reports reduced sexual desire, anorgasmia, and dyspareunia for 5 years. She denies other associated conditions. What is the probable diagnosis?
<b>Case 29: Neurogenic Bladder</b>	70-year-old man complains of urinary incontinence, burning in the bladder region, and frequent urge to urinate in small amounts after a stroke. What is the probable diagnosis?
<b>Case 30: Genital Herpes</b>	19-year-old man reports the sudden appearance of multiple erythematous-based vesicles on the glans and dorsal side of the penis, painful and pruritic, for seven days. States progression to ulcers with scalloped borders. What is the probable diagnosis?

**Table 2: Rare Urological Conditions**

<b>Pathology</b>	<b>Clinical Case</b>
<b>Case 1: Melanoma in situ on the glans</b>	28-year-old man complains of a brownish spot of about 8 mm on the penile glans, with an irregular central black point. He denies pain, and no alterations were found on physical examination. What is the likely diagnosis?
<b>Case 2: Renal Papillary Hyperplasia</b>	58-year-old man complains of urinating blood after exercise, denies coagulopathies, mentions NSAID use. What is the likely diagnosis?
<b>Case 3: Urethral Stone</b>	10-year-old child presents with acute urinary retention accompanied by penile pain, pelvic pressure, and a rigid, movable urethral mass.



<b>Case 4: Penile Necrosis associated with Aortic Dissection</b>	30-year-old man with lower limb paralysis, darkening of the scrotal sac and penis for 2 weeks, with loss of the urge to urinate and defecate. No hematuria or cloudy urine. Legs were blue.
<b>Case 5: Renal Mucormycosis</b>	56-year-old man presents with painful exophthalmos. Orbital tissue sampling revealed polymicrobial infection. Fungal polymerase test also revealed <i>Rhizopus oryzae</i> . A CT scan revealed an abscess in the lower right pole of the kidney. The abscess was drained, and the pus contained extended-spectrum beta-lactamase-producing enterobacteria. What is the likely diagnosis?
<b>Case 6: Urachal Sinus (atypical case)</b>	23-year-old woman is seen in the emergency room reporting lower abdominal pain and scant, foul-smelling umbilical discharge for 3 days. She does not report hematuria. Blood tests showed mild infection, and urinalysis and urine culture came back negative. What is the likely diagnosis?
<b>Case 7: Ureterocoele Hernia with Gluteal Abscess</b>	90-year-old woman with right buttock and hip pain, laboratory results showing signs of inflammation and mild renal dysfunction. Contrast-enhanced abdominal and pelvic CT scan reveals gluteal mass, hydronephrosis, and left-sided ureteral dilation with ureteral disconnection in the pelvis. Retrograde urography shows ureter folded in the left sciatic foramen. What is the likely diagnosis?
<b>Case 8: Testicular Neoplasm</b>	40-year-old man with symptoms of hyperandrogenism, absence of findings in the testicles on ultrasound and initial scrotal examination, and adrenal alteration. What is the possible diagnosis?
<b>Case 9: Penile Fracture with Urethral Injury</b>	37-year-old man arrives at the emergency room with complaints of pain, acute edema of the penis, rapid detumescence, blood discharge from the urethral meatus, and inability to urinate, with onset 3 hours after sexual activity. Significant hematoma observed on penis during physical examination. Lab tests are normal. What is the likely diagnosis?
<b>Case 10: Emphysematous Cystitis</b>	78-year-old woman presents in the emergency room with signs of peritonitis associated with urinary incontinence and fever. Contrast-enhanced CT scan of the abdomen and pelvis reveals pneumoperitoneum, free fluid in the cavity, and air within the urinary bladder. What is the likely diagnosis?

<b>Case 11: Urethral Diverticulum without Urethral Stricture</b>	34-year-old man reports ejaculatory difficulty, urine loss after urination, and presents with penile-scrotal mass that increases during urination on physical examination. What is the likely correct diagnosis?
<b>Case 12: Scrotoschisis</b>	Male newborn, 2 days old, is brought to the emergency room with complete evisceration of the right testicle through a small defect in the right hemiscrotum wall. What is the likely diagnosis?
<b>Case 13: Xanthogranulomatous Orchitis</b>	77-year-old man presenting with right scrotal mass. He reports increasing scrotal swelling on the right side accompanied by pain for two days. Imaging exams revealed heterogeneous lesion involving the testicle, with collection in the underlying scrotal wall. What is the likely diagnosis?
<b>Case 14: Laughing Urinary Incontinence</b>	16-year-old female adolescent presenting with total and unstoppable urinary incontinence when laughing, normal menstrual pattern, and no other urinary complaints. Not responsive to previous anticholinergic therapy. What is the likely diagnosis?
<b>Case 15: Wunderlich Syndrome</b>	66-year-old man, without history of trauma and using antiplatelet medication, arrives at the emergency room with severe generalized abdominal pain and hemodynamic instability. Contrast-enhanced abdominal CT scan reveals perirenal and retroperitoneal hyperdensity, indicating hematoma. What is the likely diagnosis?
<b>Case 16: Spermatocele Torsion</b>	A 25-year-old man presented to the emergency room with sudden-onset right scrotal pain. On physical examination, he had a swollen and tender right hemiscrotum. Scrotal ultrasonography revealed testicular edema and a cystic mass originating from the right epididymis. What is the likely diagnosis?
<b>Case 17: Testicular Tuberculosis</b>	41-year-old man, pain and swelling in the right testicle, fever of 38° for 3 months, without ulcers. Painless, palpable, firm hypertrophied lymph nodes. Left scrotum normal, right scrotum painful with inflammatory signs, 2cm swelling, painful, solid, not adhered to scrotal skin. What is the diagnosis?
<b>Case 18: Duplicated Urethra</b>	47-year-old man reports urinary incontinence, noticed double stream during urination, and frequent urinary infections. What is the possible diagnosis?

<b>Case 19: Penile Sarcoidosis</b>	A healthy man in his forties reports progressive inability to retract the foreskin over the past three weeks, associated with paresthesia in the glans and diffuse abdominal pain. On physical examination, a hardened area is noted on the proximal penile shaft, with multiple palpable nodules. He denies fever, dysuria, hematuria, and alterations in lab and imaging tests. What is the likely diagnosis?
<b>Case 20: Proximal Ureter Rupture from Ureteral Catheterization</b>	76-year-old woman with a history of right-sided abdominal pain, persistent fever, and vomiting for 1 day. He reports onset of symptoms after changing the routine of her long-term Foley catheter. He develops sepsis and acute kidney injury. What is the likely diagnosis?
<b>Case 21: Urethral Diverticulum</b>	23-year-old man with recurrent urinary infections, with dysuria associated with late dribbling, examination after micturition revealed floating penoscrotal pouch collapsing completely the urine output through the urethral meatus. What is the possible diagnosis?
<b>Case 22: Penile Calciphylaxis</b>	54-year-old man presents with penile and scrotal necrosis with a one-month evolution. He reports initial onset of penile pain and darkening of the glans, progressing to the penile shaft and scrotum. He reports a history of diabetes mellitus, hypertension, diabetic retinopathy, and chronic kidney disease on dialysis. What is the likely diagnosis?
<b>Case 23: Hydronephrosis in Pelvic Kidney</b>	18-year-old man with colicky lower abdominal pain and progressive inability to urinate, reaching anuria. He reports strong desire, but little elimination. What is the likely diagnosis?
<b>Case 24: Acute Vasitis</b>	Healthy 27-year-old man presents with left scrotal pain associated with inguinoscrotal swelling and nausea. Physical examination reveals edema extending along the left inguinal area. What is the likely diagnosis?
<b>Case 25: Scrotal Basal Cell Carcinoma</b>	58-year-old man presents with anterior scrotal lesion, 19 mm in its greatest diameter, for eight months. He reports that the lesion initially resembled a "pimple," evolving with erosion and ulceration. He denies associated pruritus and reports a past medical history of condyloma acuminatum, smoking, intravenous drug use, stabilized psoriasis on biologic therapy, and two previously excised basal cell carcinomas on

	the back. What is the likely diagnosis?
<b>Case 26: Castleman's Disease (Lymphadenopathy) in the scrotum</b>	79-year-old man reports the appearance of a painless mass in the right scrotum with significant growth in the past year. What is the likely diagnosis?
<b>Case 27: Prolapsed Ectopic Ureterocele into the Vulva</b>	12-month-old girl presents with red, smooth, prolapsed vulvar swelling through the urethral orifice. What is the likely diagnosis?
<b>Case 28: Periurethral Abscess of the Corpus Spongiosum</b>	42-year-old man presents with painful, floating, and tender mass in the proximal lower part of the penis, associated with dysuria, with a 20-day evolution. What is the likely diagnosis?
<b>Case 29: Persistent Müllerian Duct Syndrome (PMDS)</b>	38-year-old man was referred to the urology clinic due to left-sided hydronephrosis secondary to an abdominal mass. On physical examination, the patient had a hypoplastic empty scrotum, without palpable testicle and without surgical scars. Imaging exams revealed rudimentary uterus attached to a large mass that is replacing the left testicle. What is the likely diagnosis?
<b>Case 30: Partial Thrombosis of the Corpus Cavernosum</b>	25-year-old man reports pain and swelling in the penis and perineum, with penile sensitivity to touch especially on the left proximal side, and a seven-day evolution. He denies previous trauma. What is the likely diagnosis?