

Early detection of mandible osteoradionecrosis risk in a high comorbidity Veteran population

David Chamberlayne Wilde MD ¹; Sagar Kansara MD ¹; Lucas Gomez Sapienza MD ²; Logan Banner MD ³; Rickey Morlen MD ³; David Hernandez MD ^{1,4}; Andrew Tsao Huang MD ^{1,4}; Weiyuan Mai MD ²; Clifton David Fuller MD PhD ⁵; Stephen Lai MD PhD ⁶; Vlad Constantin Sandulache MD PhD ^{1,4,7}

1. Bobby R. Alford Department of Otolaryngology- Head and Neck Surgery, Baylor College of Medicine, Houston, TX
2. Radiation Oncology Section, Radiology Care Line, Michael E. DeBakey VAMC, Houston, TX
3. Oral and Maxillofacial Section, Dental Section, Operative Care Line, Michael E. DeBakey VAMC, Houston, TX
4. ENT Section, Operative Care Line, Michael E. DeBakey Veterans Affairs Medical Center, Houston, TX
5. Department of Radiation Oncology, University of Texas MD Anderson Cancer Center, Houston, TX
6. Department of Head and Neck Surgery, University of Texas MD Anderson Cancer Center, Houston, TX
7. Center for Translational Research on Inflammatory Diseases, Michael E. DeBakey Veterans Affairs Medical Center, Houston, TX

Funding source: This material is the result of work supported with resources and the use of facilities of the Michael E. DeBakey VA Medical Center. VCS is supported by a Career Development Award from the Veterans Administration Clinical Science Research and Development division (1K2CX001953).

Running title: Osteoradionecrosis risk in Veterans

Conflicts of interest: Contents do not represent the views of the US Department of Veterans Affairs or the US Government. The authors report no conflicts of interest for the existing work.

Keywords: osteoradionecrosis, oropharynx, head and neck cancer, comorbidities, Veterans

Author contributions:

Wilde, David Chamberlayne: collected data, performed data analysis, drafted manuscript; Kansara, Sagar: collected data, performed data analysis, drafted manuscript; Sapienza, Lucas Gomez: collected data, performed data analysis, drafted manuscript; Banner, Logan: collected data, reviewed manuscript; Morlen, Rickey: collected data, reviewed manuscript; Hernandez, David: collected data, reviewed manuscript; Huang, Andrew Tsao: collected data, reviewed manuscript; Mai, Weiyuan: collected data, reviewed manuscript; Fuller, Clifton David: collected data, reviewed manuscript; Lai, Stephen: collected data, reviewed manuscript; Sandulache, Vlad Constantin: collected data, analyzed data, reviewed manuscript, completed final manuscript draft

Corresponding author:

Vlad Constantin Sandulache MD PhD

Assistant Professor

Bobby R. Alford Department of Otolaryngology – Head and Neck Surgery

Baylor College of Medicine

1977 Butler Blvd. 5th Floor, Ste E5.200

Houston, TX 77030

Office: (713) 798-7218

Fax: (713) 798-5841

Email: vlad.sandulache@bcm.edu

Abstract

Objective: Osteoradionecrosis (ORN) of the mandible is a devastating complication of external beam radiation therapy (EBRT) for head and neck squamous cell carcinoma (HNSCC). We sought to ascertain ORN risk in a Veteran HNSCC population treatment with definitive or adjuvant EBRT and followed prospectively.

Study design: Retrospective analysis of prospective cohort.

Setting: Tertiary care Veterans Health Administration (VHA) medical center.

Methods: Patients with HNSCC who initiated treatment at the Michael E. DeBakey Veterans Affairs Medical Center (MEDVAMC) are prospectively tracked for quality of care purposes through the end of the cancer surveillance period (5 years post treatment completion). We retrospectively analyzed this patient cohort and extracted clinical and pathologic data for 164 patients with SCC of the oral cavity, oropharynx, larynx and hypopharynx who received definitive or adjuvant EBRT (2016-2020).

Results: Most patients were dentate and 80% underwent dental extractions prior to EBRT of which 16 (16%) had complications. The rate of ORN was 3.7% for oral cavity SCC patients and 8.1% for oropharyngeal SCC patients. Median time to ORN development was 156 days and the earliest case was detected at 127 days post EBRT completion. All ORN patients were dentate and underwent extraction prior to EBRT start.

Conclusion: ORN development can occur early following EBRT in a Veteran population with significant comorbid conditions but overall rates are in line with the general population. Prospective tracking of HNSCC patients throughout the post-treatment surveillance period is critical to early detection of this devastating EBRT complication.

Introduction

Osteoradionecrosis (ORN) of the craniofacial skeleton is a feared complication of external beam radiation therapy (EBRT) that can lead to devastating health effects for patients treated for a diagnosis of head and neck squamous cell carcinoma (HNSCC).¹ Precise definitions vary, but all describe an area of chronically exposed bone in the irradiated field that does not heal in the absence of recurrent neoplastic disease.² The pathophysiology of ORN was once believed to stem from a triad of radiation, trauma, and infection.³ Reports of the development of disease in the absence of one or more of these factors prompted investigation of other explanations.⁴ Revised theories on the etiology of ORN take into consideration a multifactorial generation of tissue hypoxia stemming from small vessel compromise and hypocellularity along with induction of fibrosis by reactive oxygen species as a late complication of high dose radiation leading to replacement of parenchymal tissue with dense extracellular matrix. Imaging studies conducted by the Joint Head and Neck Radiotherapy-MRI Development Cooperative at the University of Texas MD Anderson Cancer Center and collaborating institutions strongly support a hypothesis of radiation-altered bone vascularity as a critical contributor to ORN development.⁵⁻⁷

Reported ORN rates range from 0-16%.⁸⁻¹⁰ This discrepancy in disease incidence may be partially explained by the evolution of radiation delivery from three dimensional conformal strategies to intensity-modulated radiation therapy (IMRT), which can deliver comparable doses to tumors with lower radiation delivery to surrounding tissues.¹¹ This assumption, though widely described, is challenged by several retrospective analyses.^{10,12} Although more conformal radiation planning would be expected to provide improved bone sparing, it is unclear whether or not *any* dose conformation can spare the ipsilateral body and angle of the mandible for oropharyngeal tumors with concomitant nodal disease.¹³ It is therefore unlikely that technical improvements in dose delivery alone can eliminate ORN risk, particularly in high risk patient populations with a high comorbidity burden that could impact soft tissue and bony healing.^{14,15}

For the current analysis we leveraged a tracking tool of treatment delivery for high-comorbidity (complicated diabetes mellitus, hypertension, peripheral vascular disease)^{16,17}, high-risk Veterans with a

diagnosis of HNSCC as previously reported by our group.¹⁸ We sought to characterize the incidence of ORN at a tertiary Veterans Health Administration (VHA) institution with on-site Dental and Oral and Maxillofacial Surgery services integrated into a multi-disciplinary treatment planning group and identify correlates of ORN development.

Materials and methods

We retrospectively analyzed prospectively collected data from an institutional cohort of patients treated with curative intent EBRT for HNSCC in the definitive or adjuvant setting. Following approval from Baylor College of Medicine and Michael E. DeBakey Veterans Affairs Medical Center (MEDVAMC) Institutional Review Boards, we reviewed the records of patients who were diagnosed and initiated radiation therapy at the MEDVAMC between January 2016 and December 2020 captured in our treatment tracking registry.¹⁸ Patient demographics, dental records and procedures, tumor and treatment characteristics, and data pertaining to the development and treatment of ORN were retrospectively obtained from the existing electronic medical record and the registry. T, N, M classification were recorded according to the American Joint Commission on Cancer (AJCC Staging Manual 8th Edition) staging system. Associations between clinical variables and the development of ORN were investigated using two-directional Fisher's exact tests for nominal and Mann-Whitney U for ordinal data. Charlson Comorbidity Index (CCI) was calculated using criteria published by Charlson *et al.*¹⁹

Results

Patient characteristics. Our study encompassed 164 HNSCC patients with an average age of 65 years (**Table 1**); 158 (96.3%) were male. The median follow-up time was 725 days (range 49-1817 days). Most patients (142; 87%) were current or former smokers, with a mean pack year history of 47.2; 119 had a history of alcohol consumption (73%). The average CCI was 5.47 and 40 (24%) patients had a documented history of diabetes mellitus. Only 122 (74.4%) patients were dentate.

Tumor and treatment characteristics. Primary tumor site distribution was as follows: 27 (16.4%) oral cavity, 78 (47.5%) oropharynx, 6 (3.7%) hypopharynx, and 53 (32.3%) larynx. The majority of patients (79, 52.6%) presented with T1-T2 tumors, largely driven by a high frequency of early T-classification laryngeal disease (**Table 2**). Concomitantly, most (113, 68.9%) patients had N0 or N1 nodal disease at the time of diagnosis. All patients underwent primary or adjuvant treatment with EBRT as recommended by the institutional multidisciplinary tumor board and relevant National Comprehensive Cancer Network (NCCN) guidelines; all patients were treated with IMRT with a mean dose of 65.4Gy. While almost all (96.3%) oral cavity tumors underwent surgical resection, 70 (89.7%) oropharyngeal tumors were treated with primary EBRT with or without chemotherapy depending on extent of disease (**Table 3**).

Dental status pre-EBRT. Of the 122 patients that were dentate prior to initiation of EBRT, 98 (80.3%) underwent prophylactic dental extractions; 74 of these consisted of removal of all remaining teeth. The mean number of teeth extracted was 13.7. Sixteen patients had documented post-extraction wound complications ranging from food impaction to exposed bone. The mean time from dental extraction to the initiation of EBRT was 30.4 days (range 5-83 days).

ORN development. The overall rate of development of ORN in our cohort was 4.27%. Of the 7 patients who developed ORN (**Table 4**), one had an oral cavity primary with the rest originating in the oropharynx and one p16+ SCC defined as a carcinoma of unknown primary (CUP). The rate of ORN development by subsite was 3.7% for oral cavity, 8.1% for oropharynx, and 0% for hypopharyngeal and laryngeal tumors. The mean time from the start of EBRT to development of ORN was 196 days with a median of 156 days (range 127-368 days). All 7 patients had involvement of the mandible and all patients with known primary tumor laterality had involvement of the ipsilateral mandible (**Figure 1**). Six patients had radiographic evidence of ORN at the time of clinical appearance; four patients demonstrated significant bony erosion (**Figure 2**) Five were smokers with an average of 47.2 pack years; 1 patient

continued to smoke during EBRT. Three had documented complications with pre-radiation dental extractions with exposed bone that slowly re-mucosalized prior to initiation of treatment.

ORN treatment. All patients were treated with aggressive oral hygiene and were evaluated by the Otolaryngology-Head and Neck Surgery (Oto-HNS) and Oral Maxillofacial Surgery (OMFS) teams. Two patients underwent hyperbaric oxygen (HBO), and a third was offered this therapy, but had a distant recurrence at the time of diagnosis and opted to forgo it. Three patients underwent segmental mandibulectomy reconstructed as follows: fibula free flap (n=1), soft tissue free flap (n=1), pectoralis flap (n=1) (aborted fibula free flap due to inadequate recipient vessels). A fourth patient underwent operative debridement and reconstruction of the mucosal defect with a facial artery myomucosal flap (**Figure 2**). There were no free flap failures. The patient reconstructed with a pectoralis flap had a post-operative course complicated by orocutaneous fistula which healed with local wound care.

Discussion

Over the last three decades, a new epidemic of human papilloma virus (HPV) driven oropharyngeal squamous cell carcinoma (SCC) has changed the landscape of patients receiving head and neck EBRT.²⁰ This has led to both increasing numbers of patients receiving EBRT at time of diagnosis, as well as more patients surviving long enough to be effected by late complications of this therapy.^{21,22} It is now clear that HPV+OPSCC patients are generally younger and healthier compared to their HPV-counterparts.²³ When superimposed on a substantially lower tobacco exposure, it is likely that HPV+OPSCC patients may constitute a “low-risk” cohort for EBRT related complications, particularly development of ORN.²¹ In contrast, Veteran patients present not only with a disproportionately higher incidence of HPV- disease including OPSCC but a disproportionately higher comorbidity burden.^{16,17,24-28} This is particularly relevant to ORN development which may be impacted by comorbidities for which Veterans are particularly enriched such as peripheral vascular disease and diabetes mellitus.^{26,28}

The overall rate of ORN in our cohort is within the range of reported incidence in the literature. As shown here, no patients with laryngeal SCC developed ORN, as would be expected with a fairly high complement of early-stage disease resulting in narrower radiation fields and complete sparing of the mandible. This finding is important because it has allowed us to tailor both our pre-treatment patient counseling and our post-EBRT bone surveillance algorithms accordingly. In contrast, 8% of patients with OPSCC developed ORN. Despite the promise of IMRT and even intensity-modulated proton beam therapy (IMPT), it is not technically possible to protect the mandible when delivering curative doses of radiation to the primary tumor and nodal areas.²⁹ Comparisons among patient cohorts therefore must account for primary disease site, subsite, and T- and N-classification as ORN rates are likely to be very significantly impacted by these parameters. In contrast to our cohort, many recent datasets are skewed towards less locally advanced disease.³⁰⁻³² A recent study from the University of Texas MD Anderson Cancer Center described an ORN rate of 13.7% among all HNSCC patients with a 5% rate of grade 4 ORN. A subset analysis generated for the current manuscript demonstrated that 123/826 oropharyngeal cancer patients (14.9%) developed all grade ORN and 42/825 (5.1%) developed grade 4 ORN.³³ In the current cohort, Veterans who developed ORN were more likely to have pre-EBRT extractions (Table 3). No other variables reached statistical significance (Tables 1, 3).

Given the high burden of comorbidities relevant to mandibular vascularity and tobacco exposure in our Veteran cohort, it is somewhat re-assuring to uncover an ORN rate within the reported literature range. A notable finding in our cohort is the short interval between the delivery of EBRT and the development of ORN (median time to ORN = 156 days). This is substantially more rapid than intervals reported in other studies.¹⁰ Although our median time to ORN is undoubtedly impacted by our short median follow up time as is the rate potentially, it is important to note that time to earliest ORN (127 days) is unlikely to change and strongly suggests the need for careful and proactive tracking of patients throughout both treatment delivery and the surveillance period following treatment completion.

A possible explanation for early ORN development is the underlying poor dental health of our patients. As previously stated, one of the factors that puts patients at highest risk for the development of ORN is the breakdown of barrier mechanisms from infection by the extraction of teeth in the irradiated field. All ORN patients were dentate pre-EBRT, underwent extractions and 3/7 developed post extraction complications. Perhaps either the poor pre-existing state of the mucosal and/or alveolar structures of the jaw or the maladaptive oral hygiene habits of our patients initiated a more rapid evolution of disease. A decreased time to insult of these local tissues could have started an earlier cascade of demucosalization and infection leading to bone death. Alternatively, since our HNSCC patients are tracked prospectively pre- and post-treatment, this time to development could in fact be more accurate compared to other purely retrospective analyses. All of our dentate HNSCC patients at the MEDVAMC undergo evaluation by the Dental and OMFS teams for optimization of oral health and possible extractions prior to initiation of radiation therapy. Although very few patients develop complications from extractions, these complications can result in treatment initiation delays and correlate with ORN risk. Nevertheless, because patients are tracked prospectively in real time, continued communication between the treatment teams can still minimize treatment delays and interruptions.

There are several limitations to the currently study, chiefly the sample size of patients enrolled. Although the MEDVAMC contains the highest volume Otolaryngology-Head and Neck Service Line within the VHA, a single institution study is inherently limited by a smaller number of patients that can be accrued compared to a multi-institutional study design. This limitation is magnified with the relative rarity of ORN. A second important consideration is the duration of or follow up period. Given that ORN is a late complication of EBRT, there are likely additional patients in our cohort that may go on to develop this disease in the future. This has possibly skewed our analysis of the interval of time from the initiation of EBRT to diagnosis of ORN as those with longer intervals would not be captured by our study. We believe that the most accurate risk modelling for ORN development will need to account for disease site (oral cavity and oropharynx with greatest ORN risk) and stage, overall dental status and health, radiation dose and also time from radiation in order to counsel patients in the most effective manner.

References

1. Wong ATT, Lai SY, Gunn GB, et al. Symptom burden and dysphagia associated with osteoradionecrosis in long-term oropharynx cancer survivors: A cohort analysis. *Oral Oncol.* Mar 2017;66:75-80. doi:10.1016/j.oraloncology.2017.01.006
2. Chronopoulos A, Zarra T, Ehrenfeld M, Otto S. Osteoradionecrosis of the jaws: definition, epidemiology, staging and clinical and radiological findings. A concise review. *Int Dent J.* Feb 2018;68(1):22-30. doi:10.1111/idj.12318
3. Meyer I. Infectious diseases of the jaws. *J Oral Surg.* Jan 1970;28(1):17-26.
4. Marx RE. Osteoradionecrosis: a new concept of its pathophysiology. *J Oral Maxillofac Surg.* May 1983;41(5):283-8. doi:10.1016/0278-2391(83)90294-x
5. Joint H, Neck Radiation Therapy MRIDC, Mohamed ASR, et al. Quantitative Dynamic Contrast-Enhanced MRI Identifies Radiation-Induced Vascular Damage in Patients With Advanced Osteoradionecrosis: Results of a Prospective Study. *Int J Radiat Oncol Biol Phys.* Dec 1 2020;108(5):1319-1328. doi:10.1016/j.ijrobp.2020.07.029
6. Head MDA, Neck Cancer Symptom Working G. Dose-volume correlates of mandibular osteoradionecrosis in Oropharynx cancer patients receiving intensity-modulated radiotherapy: Results from a case-matched comparison. *Radiother Oncol.* Aug 2017;124(2):232-239. doi:10.1016/j.radonc.2017.06.026

7. Joint H, Neck Radiotherapy MRIDC. Dynamic contrast-enhanced MRI detects acute radiotherapy-induced alterations in mandibular microvasculature: prospective assessment of imaging biomarkers of normal tissue injury. *Sci Rep*. Aug 8 2016;6:29864. doi:10.1038/srep29864
8. Beaumont S, Bhatia N, McDowell L, et al. Timing of dental extractions in patients undergoing radiotherapy and the incidence of osteoradionecrosis: a systematic review and meta-analysis. *Br J Oral Maxillofac Surg*. Jun 2021;59(5):511-523. doi:10.1016/j.bjoms.2020.10.006
9. De Felice F, Thomas C, Patel V, et al. Osteoradionecrosis following treatment for head and neck cancer and the effect of radiotherapy dosimetry: the Guy's and St Thomas' Head and Neck Cancer Unit experience. *Oral Surg Oral Med Oral Pathol Oral Radiol*. Jul 2016;122(1):28-34. doi:10.1016/j.oooo.2016.01.007
10. Beadle BM, Liao KP, Chambers MS, et al. Evaluating the impact of patient, tumor, and treatment characteristics on the development of jaw complications in patients treated for oral cancers: a SEER-Medicare analysis. *Head Neck*. Nov 2013;35(11):1599-605. doi:10.1002/hed.23205
11. Ben-David MA, Diamante M, Radawski JD, et al. Lack of osteoradionecrosis of the mandible after intensity-modulated radiotherapy for head and neck cancer: likely contributions of both dental care and improved dose distributions. *Int J Radiat Oncol Biol Phys*. Jun 1 2007;68(2):396-402. doi:10.1016/j.ijrobp.2006.11.059
12. Maesschalck T, Dulguerov N, Caparrotti F, et al. Comparison of the incidence of osteoradionecrosis with conventional radiotherapy and intensity-modulated radiotherapy. *Head Neck*. Nov 2016;38(11):1695-1702. doi:10.1002/hed.24505
13. Nguyen NP, Vock J, Chi A, et al. Effectiveness of intensity-modulated and image-guided radiotherapy to spare the mandible from excessive radiation. *Oral Oncol*. Jul 2012;48(7):653-7. doi:10.1016/j.oraloncology.2012.01.016
14. Sathasivam HP, Davies GR, Boyd NM. Predictive factors for osteoradionecrosis of the jaws: A retrospective study. *Head Neck*. Jan 2018;40(1):46-54. doi:10.1002/hed.24907
15. Kuhnt T, Stang A, Wienke A, Vordermark D, Schweyen R, Hey J. Potential risk factors for jaw osteoradionecrosis after radiotherapy for head and neck cancer. *Radiat Oncol*. Jul 30 2016;11:101. doi:10.1186/s13014-016-0679-6
16. Florez HJ, Ghosh A, Pop-Busui R, et al. Differences in complications, cardiovascular risk factor, and diabetes management among participants enrolled at veterans affairs (VA) and non-VA medical centers in the glycemia reduction approaches in diabetes: A comparative effectiveness study (GRADE). *Diabetes Res Clin Pract*. Feb 2022;184:109188. doi:10.1016/j.diabres.2021.109188
17. Betancourt JA, Granados PS, Pacheco GJ, et al. Exploring Health Outcomes for U.S. Veterans Compared to Non-Veterans from 2003 to 2019. *Healthcare (Basel)*. May 18 2021;9(5)doi:10.3390/healthcare9050604
18. Hudson C, Wilde DC, Huang AT, et al. Development of a Low Resource Tool for Optimizing Head and Neck Cancer Treatment Delivery Within an Integrated Health Care Delivery System. *Journal of Clinical Pathways*. 2019;5(8):42-47. doi:10.25270/jcp.2019.10.00098
19. Charlson ME, Pompei P, Ales KL, MacKenzie CR. A new method of classifying prognostic comorbidity in longitudinal studies: development and validation. *J Chronic Dis*. 1987;40(5):373-83. doi:10.1016/0021-9681(87)90171-8
20. Sedaghat AR, Zhang Z, Begum S, et al. Prognostic significance of human papillomavirus in oropharyngeal squamous cell carcinomas. *Laryngoscope*. Aug 2009;119(8):1542-9. doi:10.1002/lary.20533
21. Ang KK, Harris J, Wheeler R, et al. Human papillomavirus and survival of patients with oropharyngeal cancer. *N Engl J Med*. Jul 1 2010;363(1):24-35. doi:10.1056/NEJMoa0912217

22. Worsham MJ, Stephen JK, Chen KM, et al. Improved survival with HPV among African Americans with oropharyngeal cancer. *Clin Cancer Res.* May 1 2013;19(9):2486-92. doi:10.1158/1078-0432.CCR-12-3003
23. Young D, Xiao CC, Murphy B, Moore M, Fakhry C, Day TA. Increase in head and neck cancer in younger patients due to human papillomavirus (HPV). *Oral Oncol.* Aug 2015;51(8):727-30. doi:10.1016/j.oraloncology.2015.03.015
24. Elrefaey S, Massaro MA, Chiocca S, Chiesa F, Ansarin M. HPV in oropharyngeal cancer: the basics to know in clinical practice. *Acta Otorhinolaryngol Ital.* Oct 2014;34(5):299-309.
25. Kane NS, Bloor LE, Michaels J. Enhancing Diabetes Self-Management Education and Psychological Services for Veterans With Comorbid Chronic Health and Mental Health Conditions. *Fed Pract.* Apr 2021;38(4):e22-e28. doi:10.12788/fp.0106
26. Avramovic S, Alemi F, Kanchi R, et al. US veterans administration diabetes risk (VADR) national cohort: cohort profile. *BMJ Open.* Dec 4 2020;10(12):e039489. doi:10.1136/bmjopen-2020-039489
27. Byrne SP, McCarthy E, DeViva JC, Southwick SM, Pietrzak RH. Prevalence, risk correlates, and health comorbidities of insomnia in US military veterans: results from the 2019-2020 National Health and Resilience in Veterans Study. *J Clin Sleep Med.* Jun 1 2021;17(6):1267-1277. doi:10.5664/jcsm.9182
28. Nieh C, Powell TM, Gackstetter GD, Hooper TI. Smoking Among U.S. Service Members Following Transition From Military to Veteran Status. *Health Promot Pract.* Jan 2020;21(1_suppl):165S-175S. doi:10.1177/1524839919881478
29. Blanchard P, Garden AS, Gunn GB, et al. Intensity-modulated proton beam therapy (IMPT) versus intensity-modulated photon therapy (IMRT) for patients with oropharynx cancer - A case matched analysis. *Radiother Oncol.* Jul 2016;120(1):48-55. doi:10.1016/j.radonc.2016.05.022
30. Park YM, Eo TS, Koh YW, Kim SH, Choi EC. Prognostic Significance of Lymph Node Status in p16+ Oropharyngeal Cancer After Surgical Treatment. *Laryngoscope.* Aug 2020;130(8):1973-1979. doi:10.1002/lary.28665
31. Adrian G, Gebre-Medhin M, Kjellen E, Wieslander E, Zackrisson B, Nilsson P. Altered fractionation diminishes importance of tumor volume in oropharyngeal cancer: Subgroup analysis of ARTSCAN-trial. *Head Neck.* Aug 2020;42(8):2099-2105. doi:10.1002/hed.26142
32. Bu DD, Ferrandino R, Robinson EM, et al. Lymph Node Ratio in HPV-Associated Oropharyngeal Cancer: Identification of a Prognostic Threshold. *Laryngoscope.* Jan 2021;131(1):E184-E189. doi:10.1002/lary.28689
33. van Dijk LV, Abusaif AA, Rigert J, et al. Normal Tissue Complication Probability (NTCP) Prediction Model for Osteoradionecrosis of the Mandible in Patients With Head and Neck Cancer After Radiation Therapy: Large-Scale Observational Cohort. *Int J Radiat Oncol Biol Phys.* Oct 1 2021;111(2):549-558. doi:10.1016/j.ijrobp.2021.04.042

Table 1. Patient characteristics

Table 1. Patient characteristics				
		All patients	non-ORN	ORN
Age	Mean/SD (years)	65.3 / 7.82	65.3 / 7.72	64.9 / 10.5
CCI	Mean/SD	5.47 / 1.99	5.51 / 2.01	4.57 / 1.13
Tobacco exposure		N (%)	N (%)	N (%)
	former	142 (86.6)	137 (87.3)	5 (71.4)
	current	69 (42.1)	67 (42.7)	2 (28.6)

Alcohol consumption	former	119 (72.6)	113 (72.0)	6 (85.7)
	current	62 (37.8)	59 (37.6)	3 (42.9)
HPV/p16 status	positive	66 (40.2)	61 (38.9)	5 (71.4)
	negative	98(59.8)	96 (61.1)	2 (28.6)
Diabetes mellitus		40 (24.4)	37 (23.6)	3 (42.9)
Dentate		122 (74.4)	115 (73.2)	7 (100)

Note- ORN: osteoradionecrosis. SD: standard deviation. HPV: human papillomavirus. CCI: Charlson Comorbidity Index.

Table 2. Tumor Characteristics and Treatment by Site

Table 2. Tumor Characteristics and Treatment by Site							
	T1-T2 N (%)	T3-T4 N (%)	N0-N1 N (%)	>N1 N (%)	Primary Surgery N (%)	Primary EBRT N (%)	Chemotherapy N (%)
All sites	79 (48.2)	85 (51.8)	113 (68.9)	51 (31.1)	47 (28.7)	117 (71.3)	101 (61.6)
OC	10 (37.0)	17 (63.0)	16 (59.3)	11 (40.7)	26 (96.3)	1 (3.70)	13 (48.1)
OP	31 (39.7)	47 (60.3)	48 (61.5)	30 (38.5)	8 (10.3)	70 (89.7)	72 (92.3)
HP	2 (33.3)	4 (66.7)	3 (50)	3 (50)	1 (16.7)	5 (83.3)	5 (83.3)
LA	36 (67.9)	17 (32.1)	46 (86.8)	7 (13.2)	12 (22.6)	41 (77.4)	11 (20.8)

Note- OC = oral cavity; OP = oropharynx; HP = hypopharynx; LA = nasopharynx

Table 3. Extraction Data

Table 3. Extraction Data				
		All patients (%)	Non-ORN (%)	ORN (%)
Dentate (pre-EBRT)		122 (74.4)	115 (73.2)	7 (100)
Pre-EBRT extraction		98 (59.8)	91 (58.0)	7 (100)
Extraction complications		16 (9.76)	13 (8.28)	3 (42.6)
Teeth Extracted	Mean/SD	13.7 / 8.96	13.7 / 9.08	13.7 / 7.93

Extraction to EBRT	Mean/SD (days)	30.4 / 11.5	30.7 / 11.6	26.6 / 9.29
--------------------	----------------	-------------	-------------	-------------

Note- EBRT: external-beam radiation therapy. ORN: osteoradionecrosis. Bold italicized numbers indicated significant differences between ORN and non-ORN cohorts ($p < 0.05$, Z-score).

Table 4. ORN cases

Table 4. ORN cases										
Patient	Site	Subsite Stage	ORN	p16	Pack-years	Extractions	Dental complications	EBRT dose primary/neck (Gy)	EBRT – ORN (days)	Treatment
1	OC	buccal T2N0M0	mandibular ramus (ipsilateral)	-	55	y		60/60	148	HBO, surgery
2	OP	tonsil T4N3M0	mandibular body (ipsilateral)	+	10	y	y	70	368	HBO, surgery
3	OP	Tonsil T3N3bM0	mandibular body (ipsilateral)	-	100	y		66/59	156	surgery
4	OP	Tonsil T1N1M0	mandibular angle (ipsilateral)	+	11	y	y	70/63	205	surgery
5	OP	tonsil T4N1M0	mandibular body (ipsilateral)	+	0	y	y	70	127	non-surgical
6	OP	tongue base T4N1M0	mandibular body (ipsilateral)	+	0	y		70/63	224	surgery
7	OP	CUP	mandibular angle (NA)	+	60	y		70/63	147	surgery

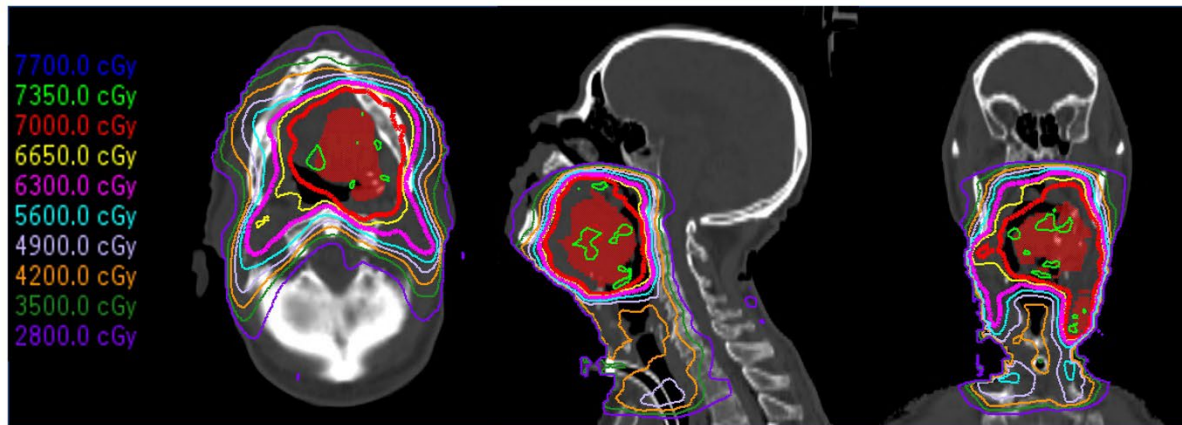


Figure 1. Radiation plan for oropharyngeal cancer. Dosimetric plan for T4N2M0 OPSCC which developed right mandibular ORN. Approximately 75% of the mandibular volume falls within 56Gy dose and approximately 90% falls within 35Gy dose.

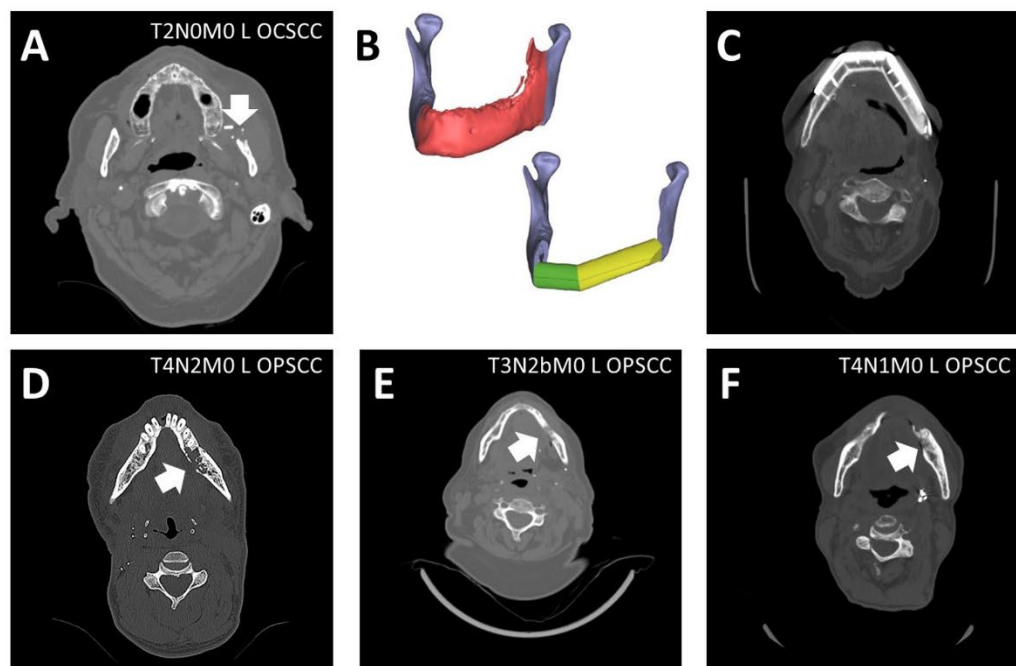


Figure 2. ORN development. A) Erosion of the mandibular body, reconstructed using a fibular free flap. B) Operative planning for reconstruction. C) Imaging of reconstructed mandible. D-F) Bony erosion at the time of diagnosis.