

Supplementary Table 1

General physical examination				Muscle examination														
ID	Sex	Height	Head circumference	Muscle bulk			Facial weakness			EOM			Ptosis			Absent/Reduced reflexes		
				B	12	24	B	12	24	B	12	24	B	12	24	B	12	24
1	M	168	55	N	N		N	Ab		N	N		Absent	Present		N	N	
2	M	174	57	N	N		N	N		N	N		Absent	Absent		N	N	
3	F	U	54	N			N			N			Absent			N		
4	F	132	53	Atrophy	Atrophy	Atrophy	Ab	Ab	N	Ab	Ab	Ab	Present	Present	Present	N	N	N
5	F	158	54	N	N		N	N		N			Absent	Absent		N	N	
6	M	172	57	N	N	N	N	N	Ab	N	N		Absent	Absent	Present	Reduced	Absent	N
7	M	178	56	N	N	N	N	N	N	N	N	N	Absent	Absent	Present	N	N	N
8	F	156	56	N	N	N	N	N	N	N	N	N	Present	Absent	Absent	Reduced	Reduced	Reduced
9	F	163	54	N	N		N	N		N	N		Absent	Absent			N	
10	F	149	58	N	N		N	N		N	N		Absent	Present		Absent	N	
11	F	160	54	N	N	N	N	N	N	N	N	N	Present	Present	Present	N		N
12	M	170	55	N		N	N	N	N	N	N	N	Present	Absent	Absent	Reduced	Reduced	Absent
13	M	180	60	N	N	N	N	N	Ab	N	N	N	Absent	Absent	Present	N	N	N
14	F	160	U	N	N		Ab			N	N		Present	Absent		N	N	
15	M	160	54	N		N	N	N		N	N		Absent	Absent		Reduced	Reduced	
16	M	162	U	N			n	N	N	N	N	N	Absent	Absent	Absent	Reduced	Reduced	Reduced
17	F	150	56	N			N			N			Absent			Increased		
18	F	151	53	N			N			N			Absent			Reduced		
19	F	159	53	N	N		N	N		N	N		Absent	Absent		Reduced	N	
20	M	159	U	N	N		N	N		N	N		Absent	Absent		N	N	
21	M	172	55	N	N		N	N		N	N		Absent	Absent		N	N	
22	M	172	58	N			N			N			Absent			N		
23	M	163	56	N	N		N	N		N	N		Absent	Absent		N	N	
24	M	160	55	N			N	N		N	N		Absent	Absent		N	N	
25	F	151	60	N	A		N	N		N	N		Absent	Absent		N		
26	M	170	58	N	N		N	N		N	N		Absent	Absent		N	Reduced	
27	F	U	49	N			N			N			Absent			N		
28	M	171	53	N			N			N			Absent			N		

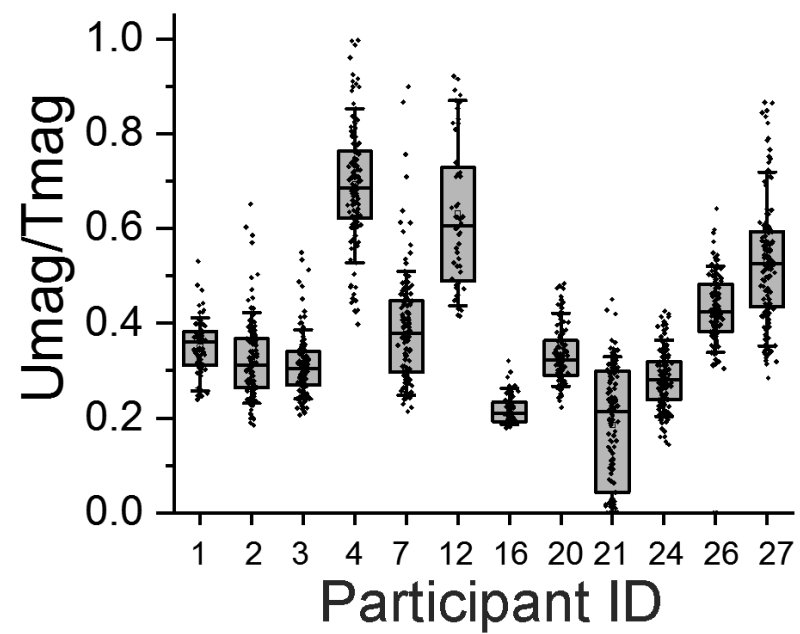
**Supplementary Table 2**

KCNJ2-negative participants					
	Participant 3	Participant 9	Participant 14	Participant 17	Participant 22
Sex	F	F	F	F	M
Short Stature	NA	No	No	Yes	No
Mandibular hypoplasia	Yes	Yes	No	Yes	Yes
Low-set ears	Yes	Yes	No	No	Yes
Hypertelorism	Yes	No	No	No	Yes
High-arched palate	No	No	Yes	Yes	Yes
Micromelia	No	No	No	Yes	Yes
Clinodactyly	Yes	No	No	Yes	Yes
Syndactyly	No	No	No	No	No
Scoliosis	No	No	No	No	Yes
Prominent U wave	No	No	Yes	Yes	No
Prolonged QTc interval	Yes	No	Yes	Yes	No
Pacemaker	Yes	No	Yes	Yes	No
Non-fatal cardiac arrest	No	No	No	Yes	No
Episodes of periodic paralysis	Yes	Yes	Yes	Yes	Yes
Positive long exercise test	NA	Yes	Yes	Yes	Yes

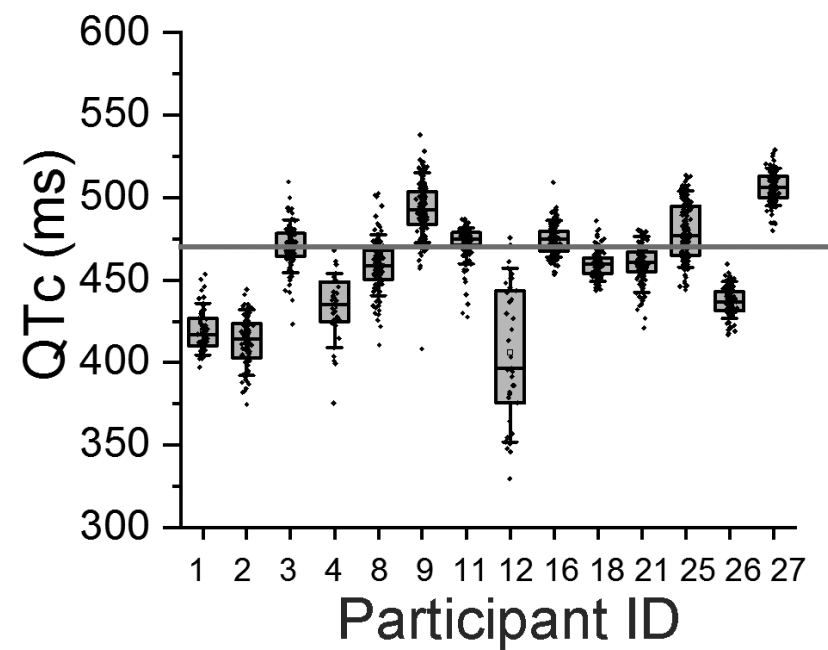
**Supplementary Table 3**

<b>CINCH Investigators</b>	<b>Affiliation</b>
Anthony A. Amato	Harvard / Brigham and Women's Hospital
Richard J. Barohn	University of South Florida
Brian N. Bundy	University of South Florida
Stephen C Cannon	University of Texas Southwestern
Emma Ciafaloni	University of Rochester
James Cleland	University of Rochester
Liz Dewar	MRC Centre for Neuromuscular Disease, UCL Institute of Neurology
Joseph Gomes	University of South Florida
Robert C. Griggs	University of Rochester
Michael G. Hanna	MRC Centre for Neuromuscular Disease, UCL Institute of Neurology
Kimberly Hart	University of Rochester
Barbara Herr	University of Rochester
Laura Herbelin	University of Kansas Medical Centre
Dipa Jayaseelan	MRC Centre for Neuromuscular Disease, UCL Institute of Neurology
Jeffrey Krischer	University of South Florida
Giovanni Meola	University of Milan
Louis Ptacek	University of California, San Francisco
Bonnie Patterson	University of South Florida
Sanjeev Rajakulendran	MRC Centre for Neuromuscular Disease, UCL Institute of Neurology
Valeria Sansone	University of Milan
Reza Seyedsadjadi	Harvard / Brigham and Women's Hospital
Rabi N. Tawil	University of Rochester
Martin Tristani-Firouzi	University of Utah
Veronica Tan	MRC Centre for Neuromuscular Disease, UCL Institute of Neurology
Jaya Trivedi	University of Texas Southwestern
Shannon Venance	University of Western Ontario

Supplementary Figure 1



Supplementary Figure 2



### Supplementary Figure 3

