

THERAPEUTIC MAMMOPLASTY AUDIT FROM A SINGLE INSTITUTIONAL COHORT FROM INDIA

Chaitanyanand B. Koppiker^{1,2*}, Nutan Gangurde^{1,2}, Santosh Dixit^{1,2}, Pragnya Chiguruapati¹, Gautam Sharan³, Upendra Dhar¹, HariKiran Allampati⁴, Laleh Busheri^{1,2}, Smeeta Nare^{1,2}, Sneha Joshi^{1,2}, Sanket Nagarkar^{1,2}

AUTHORS' AFFILIATIONS

¹Orchids Breast Health Centre, Prashanti Cancer Care Mission, 1&2, Kapilvastu, Senapati Bapat Road, Pune, Maharashtra, Post code :411016, India.

²Center for Translational Cancer Research, Pune-411016, India.

³Department of Radiation Oncology, Inlaks and Budhrani Hospital, Pune-411001, India.

⁴Ruby Hall Clinic, Pune, Maharashtra-411040.

Email: dr.nutang@gmail.com; lalehBusheri@gmail.com; sgdixit@gmail.com; pragnyac89@gmail.com; dr.gautamsharan@gmail.com; upendradhar@hotmail.com; dr.harikiran89@gmail.com; smeeetnare@hotmail.com, , snehajoshi@pimpalkhare@gmail.com, n.sanket13@gmail.com,

The Article Type: Original Article (Clinical Original)

***CORRESPONDING AUTHOR**

Chaitanyanand B. Koppiker M.D.

Medical Director, Orchids Breast Health Centre,

Prashanti Cancer Care Mission,

1-2, Kapilavastu, Senapati Bapat Road,

Pune, Maharashtra, Post code: 411016, India.

Phone: +91 98226 74040 (M)

Email: obs.koppiker@gmail.com

ABBREVIATIONS (arranged alphabetically)

Breast Cancer: BC

Breast Conservation Surgery: BCS

Breast Conservation Therapy: BCT

Ductal Carcinoma In situ: DCIS

Extreme Oncoplasty: EO

Intraductal Carcinoma: IDC

Nipple Areolar Complex: NAC

Oncoplastic Breast Surgery: OBS

Patient Reported Outcome Measures: PROMs

Quality of Life: QoL

Radiation Therapy: RT

Simultaneous Integrated Boost: SIB

Therapeutic Reduction Mammoplasty: TRM

Upper Outer Quadrant: UOQ

ABSTRACT

Introduction

Therapeutic Mammoplasty (TM) is a Oncoplastic Breast Surgery (OBS) technique suitable for medium-to-large breasts with ptosis with large or multifocal/multicentric (MF/MC) tumors. Several studies have indicated that TM expands the scope, extent, and application of breast conservation surgery. This report describes in detail TM outcomes in Indian breast cancer (BC) patients.

Methods

From our single institutional cohort (n = 211), we present data related to surgical techniques, clinical management, oncological safety, cosmetic and patient reported outcomes (PROMs, based on Breast-Q questionnaire) from BC patients who underwent TM (categorized as simple, complex, extreme and split-reduction type)

Results

Mean age at diagnosis was 48.7 years. Majority of these patients had advanced stage (II/III) disease. 178 patients consented and 171 completed 1 year follow-up from 3 main groups (a) simple (n=87) (b) complex (n =39) and (c) extreme TM (n = 49). The post-operative complication rates were low (<10%) without any delay in adjuvant treatment. Cosmetic scores were good-to-excellent (n = 154). Post- 1-year PROMs (n =149) revealed good-to-excellent score for satisfaction with breast, cosmetic outcome and psychosocial well-being for all TM types.

Conclusion

Our study is a first detailed report describing a multi-factorial audit in TM single institutional cohort in Indian BC patients. We propose that our TM technique/s may be optimally suited for BC scenarios common in India namely (a) advanced stage BC patients with moderate-to-large breasts with mild/severe ptosis (b) multifocal, multicentric tumors (c) LABC at initial presentation.

INTRODUCTION

Breast conservation therapy (BCT) which involves breast conservation surgery (BCS) followed by adjuvant radiotherapy (RT) is now established as a standard of care for Breast Cancer (BC) (Fisher *et al.* 1989; Silverstein *et al.* 2015a). Several studies have shown equivalent survival rates between BCS and mastectomy after a 20-year follow-up (Losken *et al.* 2014; De La Cruz *et al.* 2016; Campbell and Romics 2017). Recent studies have suggested a better disease free and overall survival with improvement in quality of life (QoL) in patients undergoing BCT as compared with mastectomy (van Maaren *et al.* 2016; de Boniface *et al.* 2021).

However, unsatisfactory post-BCT cosmetic outcomes were observed in 30% cases in which large size (~10-20%) of the breast tissue was excised (Egro *et al.* 2015). Such poor cosmesis has been attributed to post-BCS breast defect or asymmetry between the breasts or nipples. As of today, BCT has limited applications in patients with multi-focal or multi-centric disease and/or with extensive microcalcifications. Conventionally, multifocal and multi-centric cancers have been labelled as a contraindication for BCS, though low recurrence rates have been observed in patients with multiple ipsilateral breast cancer treated with BCT (Winters and Bernaudo 2018).

The concept of Oncoplastic Breast Surgery (OBS) was first introduced in the 1990's by Prof. Audretsch when he described the technique of partial reconstruction of the breast, using plastic surgical technique (Losken and Ghazi 2012). OBS is now increasingly being accepted as standard-of-care in surgical management of BC cases across the world due to the benefits such as oncological safety with concurrent improvement in aesthetic results and Quality of Life (QoL) (Chen *et al.* 2015; Silverstein 2016; De La Cruz *et al.* 2016).

OBS procedures involving partial breast reconstruction are classified according to volume replacement or volume displacement techniques (Savalia and Silverstein 2016). Therapeutic Mammoplasty (TM) is a commonly used volume displacement technique suitable for OBS in women with medium/large breasts with ptosis. TM combines advantages of oncologically safe wide excision of tumor with breast reduction, mastopexy and contralateral symmetrisation techniques (Winters and Bernaudo 2018). This technique increases application of BCS and scope of BCT by facilitating larger tumors excision margins, lower re-excision rates, decreases rates of positive margins and reduction in rate of mastectomies (Macmillan *et al.* 2014; Potter *et al.* 2020). TM has been shown to achieve satisfactory outcomes by reducing the breast size thereby facilitating better delivery and distribution of RT regimens, achieving contralateral breast symmetry and improving the QoL. The oncological safety and efficacy of TM have been confirmed in early BC cases indicated by higher rates of overall survival (OS), disease free survival (DFS) with low recurrence, lower complication rates and

superior cosmesis (Iwuchukwu *et al.* 2012). Furthermore, TM offers a pragmatic option for BCS in women who present with LABCs (>5cms), multifocal or multicentric tumors or extensive microcalcifications wherein a mastectomy would be a surgical procedure of choice (Silverstein *et al.* 2015a; Losken *et al.* 2017). However, even though indicated for smaller ptotic breasts in selective cases, TM may not be effective due to paucity of breast tissue resulting in extremely small size and cosmesis of operated breast (Savalia and Silverstein 2016).

The Therapeutic Mammoplasty study (TEAM) is a large, international, multicentric cohort study to evaluate the safety and efficacy of TM in women undergoing BCS for invasive or pre-invasive BC as per consensus guidelines developed by European breast units (O'Connell *et al.* 2018). The TEAM study has reported that TM procedure is a safe and effective alternative to mastectomy or standard BCS. Recently, data from the national iBRA-2 and TEAM studies were combined to compare the safety and short-term outcomes of TM and mastectomy with or without immediate breast reconstruction. This data indicated that BCS was possible in 87 % TM cases without delay in adjuvant treatment indicating that TM may allow high-risk patients who are not candidates for IBR to avoid mastectomy safely (Dave *et al.* 2016; O'Connell *et al.* 2018).

Majority of Indian BC patients present with larger tumors in advanced stages (Doval *et al.* 2020). This limits the scope of upfront BCS with or without OBS, unless they have a favorable breast-to-tumor ratio. In such patients, OBS with the TM procedure has been shown to effectively extend the boundaries of surgical excisions (Silverstein 2016). However, the field of OBS is still nascent in India and is practiced predominantly by a handful of breast surgeons from Tier 1 cities. This limited OBS uptake could be attributed to multiple barriers such as lack of awareness, healthcare economics, logistics challenges at public and private sectors hospitals, psychological taboos for women to undergo a unilateral or bilateral BCS and paucity of well-trained OBS surgeons (Koppiker *et al.* 2019a).

With this background, we undertook the current study to investigate and analyze the outcomes of TM with focus on oncological safety and efficacy in Indian BC patients. From our single-institution TM cohort, we present data on 211 patients who were candidates for OBS or a mastectomy (based on their tumor characteristics) but finally underwent a TM after analyzing the feasibility and safety of the procedure along with careful counseling and Standard operating procedures (SOPs). Based on the guidelines of the TEAM protocol, we report the clinicopathological profiles of our cohort and experiences related to various TM surgical techniques (i.e., simple, complex, extreme oncoplasty and split reduction mammoplasty). We discuss in detail our observations on surgical and oncological outcomes, complication rates, time to adjuvant therapy, RT outcomes and patient reported outcomes (PROMs) amongst Indian BC patients undergoing TM.

METHODOLOGY

1 Types of Therapeutic Mammoplasty

1.1 Simple Therapeutic Mammoplasty

Simple Therapeutic Mammoplasty is a procedure in which the tumor lies within a normal reduction pattern. In these cases, the superior, inferior or superomedial pedicles are routinely used (Savalia and Silverstein 2016).

1.2. Complex Therapeutic Mammoplasty

This technique is used when the tumors are outside the primary reduction pattern. The reconstruction is carried out either by extensions of the primary pedicles or by the use of secondary pedicles. Extended or Secondary pedicles are the other parts of the breast that are generally excised, which are used to fill the defects. The later are preferred as they have better blood supply reaching the most distant areas of the pedicle as compared to extended ones (Savalia and Silverstein 2016).

1.3. Extreme Therapeutic Mammoplasty

Extreme Oncoplasty is the application of OBS to include extreme situations where conventionally a mastectomy would be advised. These include large multi-centric, multi-focal tumors, extensive DCIS and poor response to NACT requiring large areas of resection (Koppiker *et al.* 2019b).

1.4. Split Reduction Mammoplasty

Split Reduction is a TM procedure applicable when the tumor lies outside the reduction pattern and the skin over the tumor needs to be removed (Silverstein *et al.* 2015b).

2. Surgical Procedures

2.1 Pre-operative Markings

In the pre-operative planning, appropriate markings are placed on both breasts based on wise pattern or vertical scar incision. The nipple area complex is positioned between 19-23 cm from sternal notch, which is often determined by placing the fingers at the inframammary fold and projecting on the anterior surface of the breast in the meridian.

2.2 Wise Pattern or Vertical Scar Incision

The 1st step of the surgery begins by marking out the wise pattern incision. The area of the appropriate pedicle (based on the type of the therapeutic mammoplasty procedure) which carries the nipple is marked and de-epithelized. The next step is to localize the tumor and excise it with wide margins by going through one of the limbs of the wise pattern. This localization is performed either pre-operatively by stereotactic guide-wire placement or by placement of wire and needle on the operating table using a high-resolution ultrasonography.

2.3 Oncological Clearance and NAC Positioning

Nipple-Areola complex (NAC) is marked out, and the incision is made around the areola carefully. The tumor and its quadrant are then widely excised through one of the limbs of wise pattern incision. If required, further imaging of the specimen is performed using specimen mammography to ensure that the tumor is excised with wide margins. After this step, the shaved margins of the cavity are further excised and sent for frozen sections to assess margin positivity. If any positive margins are close to the tumor, they are re-excised. Once clarity about the tumor margins of the excision cavity is achieved, the decision is made to use one of the appropriate pedicles (based on the type of TM technique deployed).

2.4 Marking Out the Tumor Bed for Targeting Radiotherapy

The tumor bed is marked with Liga clips in the superior, inferior, medial and lateral, the base and anterior margins. Once the restructuring is completed, the margins of the tumor are determined. In our experience, the tumor margins remain contained in the initial tumor volume for targeted radiotherapy. The possibility of tumor margin getting repositioned in some other quadrant is less likely.

2.5 Choice of Pedicles for Various TM Techniques

After this step, the appropriate pedicles are marked out and dissected according to the location of the tumor. According to quadrant diagrams, if the tumor is at 12 O'clock position in UOQ, an extended inferior pedicle is used. If a tumor is present in outer quadrants (i.e., at 2,3 or 4 O'clock position of left breast or at 8,9 or 10 O'clock positions of the right breast), dual pedicle technique is preferentially used. In this technique, the inferior pedicle fills up the gap and the NAC are positioned on a superior, superomedial or lateral pedicle. The main aim of the dual pedicle technique is to contour the defect with one pedicle and position the NAC on the other, thereby providing a dual vascular supply.

Figure-2: please refer to figures section

2.6 Axillary Management

Once these wise pattern incisions are carried through to the chest wall, the lateral dissection is taken into the axilla and the axillary dissection or sentinel node excision is performed through the same incision. No separate incision is taken on the axilla. Care is taken to dissect out the lateral thoracic artery and to ensure that the lateral pillar is well perfused by various perforators. Thereafter, the incisions are closed. Drains are not inserted in the axilla unless an axillary clearance has been performed.

2.7 Split Reduction Therapeutic Mammoplasty Technique

In this technique, the lower limb of the wise pattern is shifted over the tumor site. Then the outer limb of the wise pattern is shifted upwards to lie over the tumor so that there is no incision in the IMF on the outer side (Silverstein *et al.* 2015b).

3. Clinical Management

BC diagnosis was based upon clinical examination and radiological evaluation of breast and axilla using Full Field Digital Mammography (FFDM) with 3-D Tomosynthesis (Siemens Mammomat InspirationTM) and Ultrasonography (Siemens Acuson S2000TM). Histopathological studies on tru-cut biopsy samples (majority of cases) or vacuum assisted biopsy (for index tumors, Encor UltraTM) samples were performed for confirming diagnosis of breast carcinoma. Similarly, ultrasonography and fine needle aspiration cytology was used for investigating axillary lymph node metastasis. Confirmed BC cases underwent breast surgery at a network hospital site. The oncologic management with chemo-radiation protocols was undertaken by a multi-disciplinary clinical team in accordance with the current NCCN guidelines (Koppiker *et al.* 2019b).

4. Radiation Therapy

The RT dose planning was aimed at achieving a Biologically Effective Dose (BED) of 50 Gy for all patients. The breast along with the supraclavicular region (if indicated) was irradiated by 6 MV photon beams using Forward Plan Field-in-Field Intensity Modulated Radiation Therapy (F-P FiF IMRT) or Volumetric Modulated Arc Therapy (VMAT). Two tangential fields along with multiple sub-fields were used for this treatment. CT images (5 mm thickness) were obtained with the patient immobilized in a vacuum cushion (Vacloc) at different transverse sections covering the region of interest with adequate margins to create a 3D image. Volume delineation (CTV, Contralateral breast, Lung and Heart) on CT images was performed on EclipseTM contouring station. Computerized treatment planning was performed on EclipseTM treatment planning system (TPS) (Version 13.5.35) for F-P FiF IMRT plans and Monaco® (Version 5.11) TPS for VMAT plans. High energy linear accelerator (Elekta Synergy, Elekta Medical SystemTM, UK) with 80 leaves Multi Leaf Collimator (MLCi) was used for tangential treatments to the breast field. RT plan was accepted if at least 95% of

prescribed dose covers the 100% of planning target volume (PTV). Hot spot in PTV was accepted up to 110% of prescribed dose. Tumor bed boost, wherever indicated, was performed using either an electron portal or Simultaneous Integrated Boost (SIB) technique.

5. Assessment of Post-Surgery Complications

Post-surgery outcomes were assessed by breast oncoplastic surgeons and radiation oncologists, respectively. As per the Clavien Dindo classification, post-surgery complications were classified as ‘major’ when they required surgical intervention and ‘minor’ when they were managed conservatively (Panhofer *et al.* 2014). We also noted the time between completion of surgery and start of adjuvant therapy to ascertain any delays in adjuvant therapy.

6. Patient Reported Outcome Measures (PROMs)

The PROMs were used to evaluate patient satisfaction and QoL after TM procedures. To assess PROMs, a standardized Breast-Q questionnaire was utilized. The Breast-Q module was divided into multiple independent scales. Higher scores indicate greater patient satisfaction and functionality (Koppiker *et al.* 2019b).

7. Data Analysis and Statistics

Proportional analysis was undertaken for determining cohort characteristics. Statistical analysis for inter and intra-group comparisons were undertaken using Students t-test ($p=0.05$).

RESULTS

A. Overview of TM Study Cohort

A1. Characteristics of Study Cohort

At our institution, 211 TM procedures have been performed on BC patients with moderate and large breasts with various grades of ptosis during the period of 2012-2019, Amongst these 211, 178 patients consented to data sharing. Only 171 patients were included in the final study cohort as they completed a minimum of 12 months post-surgery follow-up. Data collection was performed according to the recommendations of the TEAM protocol.

The BC cases reported in this cohort underwent various types of TM procedures namely (a) Simple (b) Complex (c) Extreme (d) Split-reduction. A representative case from each of these 4 TM categories are described in detail in the Supplementary section. The case description includes case summary alongwith images depicting pre-operative markings, intra-operative techniques and post-operative outcomes.

Demographic distribution of study participants and their clinico-pathological characteristics are summarized in Table 1a and 1b. In our study cohort, 166 patients had unilateral and 5 had bilateral breast cancers. Tumors were found in the UOQ in 74 (43.2%) patients, LOQ in 21 (12.3%) patients, UIQ in 33 (19.3%) patients and LIQ in 24 (14.2%) patients. The mean age of patients at diagnosis was 48.7 years. Majority of these patients were at Stage II or III. Majority cases were either IDC and/or DCIS. Clear margins were achieved in all the patients on the frozen section as well confirmed on final histopathology analysis. The average margin distance achieved was 12.5 mm. Axillary lymph node dissection was performed in 59 (33.3%) cases and sentinel node biopsy was performed in 113 (63.9%) cases.

Of the 40 (23.4%) patients who received NACT and 10 (5.9%) patients who received NAHT respectively, 14 (8.1%) patients achieved complete clinical response. In the post-operative period, adjuvant chemotherapy and/or RT was administered to patients according to clinical indications (Table 1a). 92 (54%) patients were administered adjuvant chemotherapy. Adjuvant RT data was available from 150 (88%) patients. None of the patients in our study cohort experienced any delays in their adjuvant therapies. While one case had local recurrence within 12 months, 2 cases recurred within 24 months (Table 1b).

Table 1a: Demography and Clinico-Pathological Profile of Study Participants

Characteristics		Case Distribution			
		Numbers, (%)			
		Total TM (n =171)	Simple TM (n=87)	Complex TM (n=39)	Extreme Oncoplasty (n=45)
Age, years	<=35	15 (8.7)	7 (4.0)	3 (1.8)	5 (2.9)
	36-49	77 (45)	38 (22.2)	18 (10.5)	21 (12.2)
	50-60	56 (32.6)	28 (16.3)	12 (7.0)	16 (9.3)
	Above 60	23 (13.4)	14 (8.1)	6 (3.5)	3 (1.8)
	Mean Age	48.7	49.4	48.9	47.9
BMI	Below (25 kg/m ²)	45 (26.3)	24 (14.0)	9 (5.3)	12 (7.0)
	Overweight (BMI 25-30kg/m ²)	59 (34.5)	29 (16.9)	10 (5.9)	20 (11.7)
	Obesity (BMI>30kg/m ²)	50 (29.2)	27 (15.7)	14 (8.2)	9 (5.3)
	Diabetes	29 (16.9)	13 (7.6)	6 (3.5)	10 (5.8)
Tumor	UOQ	74 (43.2)	24 (14.0)	26 (15.2)	24 (14.0)

Location	Upper Pole	11 (6.4)	9 (5.2)	2 (1.2)	0 (0)
	UIQ	33 (19.3)	17 (9.9)	9 (5.3)	7 (4.1)
	Central	5 (2.9)	3 (1.7)	0 (0)	2 (1.2)
	LOQ	21 (12.3)	12 (7.0)	2 (1.2)	7 (4.1)
	Lower Pole	2 (1.2)	2 (1.2)	0 (0)	0 (0)
	LIQ	24 (14.2)	15 (8.9)	0 (0)	9 (5.3)
	Others	2 (1.2)	1 (0.6)	0 (0)	1 (0.6)
Type of Tumor	IDC	66 (38.6)	32 (18.7)	14 (8.2)	20 (11.7)
	DCIS	3 (1.8)	0 (0)	1 (0.6)	2 (1.2)
	IDC + DCIS	69 (40.2)	37 (21.6)	16 (9.3)	16 (9.3)
	ILC	2 (1.2)	1 (0.6)	1 (0.6)	0 (0)
	Phyllodes	5 (2.9)	0 (0)	1 (0.6)	4 (2.3)
	Others (NOS, Papillary Ca, Mucinous Ca)	27 (15.8)	18 (10.5)	6 (3.5)	3 (1.8)
Receptor Status	ER+	110 (64.3)	56 (32.7)	22 (12.9)	32 (18.7)
	PR+	99 (57.9)	50 (29.2)	20 (11.6)	29 (17.1)
	Her -2+	45 (26.3)	19 (11.1)	11 (6.4)	15 (8.8)
	TNBC	34 (19.8)	17 (9.9)	11 (6.4)	6 (3.5)

Grade	I	11 (6.4)	5 (2.9)	2 (1.2)	4 (2.3)
	II	90 (52.6)	47 (27.5)	17 (9.9)	26 (15.2)
	III	38 (22.2)	18 (10.5)	12 (7.0)	8 (4.7)
Stage	0	20 (11.6)	11 (6.4)	5 (2.9)	4 (2.3)
	I	24 (14.0)	13 (7.6)	5 (2.9)	6 (3.5)
	II	85 (49.7)	50 (29.2)	17 (9.9)	18 (10.5)
	III	28 (16.3)	7 (4.1)	10 (5.8)	11 (6.4)
	IV	3 (1.7)	0 (0)	1 (0.6)	2 (1.2)
NACT	Total number of cases	40 (23.4)	13 (7.6)	12 (7.0)	15 (8.8)
	NACT→S _x →ACT	12 (7.0)	6 (3.5)	1 (0.6)	5 (2.9)
	NACT →S _x →ACT+AHT	5 (2.9)	1 (0.6)	1 (0.6)	3 (1.7)
	NACT → S _x →AHT	11 (6.4)	4 (2.3)	5 (2.9)	2 (1.2)
Surgery	S _x →ACT	42 (24.5)	28 (16.4)	11 (6.4)	3 (1.7)
	S _x →AHT	30 (17.5)	15 (8.7)	8 (4.7)	7 (4.1)
	S _x →ACT+AHT	34 (19.9)	19 (11.1)	8 (4.7)	7 (4.1)
NAHT	Total No. of Regimen	10 (5.9)	4 (2.4)	2 (1.2)	4 (2.4)
	NAHT →S _x →	1 (0.6)	0 (0)	0 (0)	1 (0.6)

	ACT + AHT				
	NAHT →Sx → AHT	8 (4.7)	4 (2.4)	2 (1.2)	2 (1.2)
	NAHT →Sx → ACT	1 (0.6)	0 (0)	0 (0)	1 (1.6)
RT	No. of RT Received	148 (87)	76 (44.4)	35 (21)	37 (21.6)

Table 1b: Salient Features of TM Cohort

Characteristics	Total TM	Simple TM	Complex TM	Extreme TM
N	171	87	39	45
Mean Age, years	48.7	49.3	48.9	47.2
Mean Volume (cc)	387	332.6	356.5	452.8
Underwent NACT	40 (23.4)	13 (7.6)	12 (7.0)	15 (8.8)
Underwent NAHT	10 (5.9)	4 (2.4)	2 (1.2)	4 (2.4)
Margins (<1mm) No tumor on inked margin	0 (0)	0 (0)	0 (0)	0 (0)
Margins (1-2 mm)	3(1.7)	3(1.7)	0(0)	0(0)
Margins (> 2 mm)	168 (98.2)	84 (49.1)	39 (22.8)	45 (26.3)
Average Margin Distance (approximately in mm)	12.2	12.1	12.3	12.4
Need for Re-excision (Margin Positive)	1 (0.6)	0 (0)	1 (0.6)	0 (0)
Mastectomy	1 (0.6)	1 (0.6)	0 (0)	0 (0)
Any Local Recurrence (Within 0-12 Months)	1 (0.6)	1 (0.6)	0 (0)	0 (0)
Any Local Recurrence (Within 12-24 Months)	2 (1.2)	1 (0.6)	0 (0)	1 (0.6)

Any Local Recurrence (Within 24-36 Months)	1 (0.6)	0 (0)	0 (0)	1 (0.6)
Any Local Recurrence (Within 36-48 Months)	0 (0)	0 (0)	0 (0)	0 (0)
Any Local Recurrence (Within 48-60 Months)	0 (0)	0 (0)	0 (0)	0 (0)
Any Local Recurrence (60 Months Onwards)	0 (0)	0 (0)	0 (0)	0 (0)
Any Distant Metastasis (Within 0-12 Months)	3 (1.7)	1 (0.6)	1 (0.6)	1 (0.6)
Any Distant Metastasis (Within 12-24 Months)	7 (4.1)	3 (1.7)	2 (1.2)	2 (1.2)
Any Distant Metastasis (Within 24-36 Months)	1 (0.6)	0 (0)	1 (0.6)	0 (0)
Any Distant Metastasis	0 (0)	0 (0)	0 (0)	0 (0)
Any Distant Metastasis	0 (0)	0 (0)	0 (0)	0 (0)
Any Distant Metastasis	1 (0.6)	0 (0)	1 (0.6)	0 (0)
Duration of Follow-up	Minimum 12 months, Maximum 60 months and above			

A2: Post-Operative Complications

Post-operative complications were classified based on grades as per Clavien Dindo Classification adapted for Breast Cancer (Panhofer *et al.* 2014). There were 15 cases of complications in Grade 3a including cases of seroma (requiring aspiration). There was 1 case of Grade 2 (wound infection) and 14 cases of Grade 1 complications such as seroma/ haematoma not requiring drainage, minor skin necrosis, fat necrosis, delayed wound healing. All complications were treated conservatively in the outpatient settings (Table 2).

Table 2: Summary of Post-Operative Complications

Characteristics	Complications, Number % (n=171)			
	Total (171)	Simple TM (87)	Complex TM (39)	Extreme Oncoplasty (45)
Grade 1 (seroma/hematoma not requiring drainage, minor skin necrosis, fat necrosis, delayed wound healing)	14 (8.1)	7 (4.1)	4 (2.3)	3 (1.7)
Grade 2 (Wound infection)	1 (0.6)	0 (0)	1 (0.6)	0 (0)
Grade 3a (seroma/hematoma which were drained under USG guidance, lymphoedema, nipple necrosis, skin necrosis undergoing debridement)	15 (8.7)	10 (5.8)	3 (1.7)	2 (1.2)
Grade 3b (seroma/hematoma which were drained under general anesthesia - major skin necrosis, wound infection requiring debridement, bleeding)	0(0)	0(0)	0(0)	0(0)
Grade 4 (life-threatening complication)	0(0)	0(0)	0(0)	0(0)
Grade 5 (Death)	0(0)	0(0)	0(0)	0(0)
Total	30 (17.4)	17 (9.9)	8 (4.6)	5 (2.9)

A3: Radiation Therapy

Of the 171 patients included in our study cohort, 150 patients underwent RT as clinically indicated (Table 3a). RT data on the remaining 21 cases (12%) was not available as these represented cases of phyllodes (n = 8), who rejected RT (n =11) or who were lost to follow-up (n =2). Out of the 148 cases 78 patients had left-sided lesions, 86 patients had right-sided lesion and 5 patients had bilateral lesions. While 73 of these 148 patients received RT to the whole breast alone, 65 received RT to the breast along with the supraclavicular region. Forward Plan Intensity Modulated Radiation Therapy (IMRT) was used to treat 123 patients. 16 patients were treated using Volumetric Modulated Arc Therapy (VMAT) and 1 patient received Simultaneous Integrated Boost (SIB). 113 patients received electron-boost. 9 patients underwent APBI. (Supplementary Table 1). The RT regimen for various types of TM procedures is depicted in Table 3b and was considered effectively safe.

Table 3a: RT Details of Therapeutic Mammoplasty Cohort

Features	Total TM cases (171)	Simple TM (87)	Complex TM (39)	Extreme TM (45)
Patients who received RT to whole breast	73 (42.6)	43 (25.1)	14 (8.2)	16 (9.3)
Patients who received RT to whole breast + SCF	65 (38)	26 (15.2)	18 (10.5)	21 (12.3)
Patients with Left sided lesion	83 (48.5)	39 (22.8)	20 (11.7)	24(14.0)
Patients with Right sided lesion	91 (53.2)	50 (29.2)	20 (11.7)	21 (12.3)
Patients treated by FP / FIF / IMRT	123 (71.9)	63 (36.8)	28 (16.4)	32 (18.7)
Patients treated by VMAT	16 (9.2)	7 (4.0)	5 (2.9)	4 (2.3)
Patients who were given electron boost	113 (66.0)	58 (33.9)	26 (15.2)	29 (16.9)

Patients who were given SIB	1 (0.6)	0 (0)	0 (0)	1 (0.6)
Patients who were not given electron boost / SIB	22 (12.8)	9 (5.2)	5 (2.9)	8 (4.7)
Patients undergone APBI	9 (5.2)	6 (3.5)	3 (1.7)	0 (0)

A4: Patient Reported Outcome Measures (PROMs)

Prom's data was collected from the study participants after minimum period of 12 months post-surgery with the Breast-Q questionnaire. Out of 171 study participants, 149 (87.1%) responded to the questionnaire. PROMs were used to assess patient reported satisfaction and QoL after various types of TM procedures (namely simple, complex and extreme oncoplasty). Table 4 indicates patient reported improvement in the four areas evaluated after surgery. While 76% patients expressed satisfaction with breasts, 83% reported satisfaction with overall outcome. Furthermore, majority patients reported satisfaction with psychosocial well-being (85%), and sexual well-being (75%) and physical well-being (73%). This trend of high percentage of patient satisfaction was observed from PROMs patients who have undergone all 3 types of therapeutic mammoplasty procedures, namely simple, complex and extreme oncoplasty (Table 4 and Figure 4).

Table 4: PROMs from TM Study Cohort Participants

S. No.	Breast-Q Parameters	Mean \pm SD (n=149)
1.	Satisfaction with Breast	76.7 \pm 15.4
2.	Satisfaction with Outcomes	83.9 \pm 11.5
3.	Psychosocial Well-being	85.8 \pm 17.4
4.	Sexual Well Being	75.3 \pm 24.7
5.	Physical Well Being	73.2 \pm 14.6

B5: Cosmetic Score Analysis

Out of 171 Therapeutic mastoplasty cases, cosmetic scores available for 154 patients based on independent assessment by 3 surgeons.

Table 5: Cosmetic Scores for TM Cohort

Category	Score	Classification	Number, (%)
1	0-3	Bad	0, (0)
2	4-5	Fair	7, (4.5%)
3	6-8	Good	96, (62.4%)
4	9-10	Excellent	51, (33.1%)

DISCUSSION

In this report, we present the first comprehensive, single-institutional study on TM outcomes in Indian breast cancer patients based on the recommendations of the TEAM protocol (O’Connell *et al.* 2018). We present best practices from our center on the feasibility and application of various TM procedures, experiences from surgical and oncological outcomes and PROMs to propose a wider acceptance of TM in various clinical indications.

1. Patient Selection

At our institution, routine pre-op counseling is performed by the surgeons to discuss options such as mastectomy, BCS and OBS. If the patient consents for TM, simultaneous contralateral breast reduction option for superior cosmetic outcomes is also discussed, especially, for women with ptotic breasts (Grades 1-3) and moderate-to-large sized breasts who would benefit significantly from this procedure.

2. Choice of TM Technique

TM-related decision-making algorithms are based on the tumor location and the breast sizes. In our practice, we have classified TM techniques into 4 categories with indications as follows:

Type	Description	References
Simple	<ul style="list-style-type: none"> • For tumors within the reduction pattern (i.e., at 6’O clock) • The nipple is placed on the superior, supero-medial and inferior pedicles, which are commonly used pedicles. 	(Savalia and Silverstein 2016)
Complex	<ul style="list-style-type: none"> • For tumors outside the pattern of reduction (i.e., between 12-3 O’ clock position (left breast) and 12-9 O clock (right breast) • Dual pedicle technique is applied in which extended and/or secondary pedicles (inferior, infero-lateral or infero-medial) act as fillers which enhance the vascularity as an added advantage. 	(Savalia and Silverstein 2016)
Extreme	<ul style="list-style-type: none"> • For larger (>5cm), multifocal/multicentric tumors, in which mastectomy would be the surgical procedure of choice. 	(Silverstein <i>et al.</i> 2015a), (Koppiker <i>et al.</i> 2019b)
Split Reduction	<ul style="list-style-type: none"> • For tumors which lie outside the reduction pattern wherein the skin needs to be resected due to involvement or close proximity with tumor • In contrast to the other techniques, the incisions on the IMF and the horizontal limb on the side of the skin excision are omitted to preserve the vascularity and restructure the breast. 	(Silverstein <i>et al.</i> 2015b)

Most of the cases in our study cohort have been operated using the dual pedicle technique in which NAC was carried on superior pedicle and the inferior pedicle was used to fill the defect caused by excision of the tumor.

In patients either with smaller breasts or with large excisions, we have frequently used the whole lower segments of the breast (i.e., inferomedial and inferolateral pedicles) so the breast mound is advanced into the defect and NAC is reimplanted onto the pedicle.

Owing to financial and logistical challenges, Indian patients have poor acceptance of a second operative procedure (Koppiker *et al.* 2019a). Therefore, we perform a single-step TM procedure that involves simultaneous reconstruction of the NAC and contralateral reduction mammoplasty for bilateral symmetrization in which the nipple may undergo resection with a NAC graft. If the patient does not consent for opposite symmetrization, alternative OBS procedures to TM are recommended.

3. Patient Demographics

Given that the medical, psycho-social-cultural and economic profiles of Indian BC patients are significantly different than western countries, we had to adapt our TM techniques accordingly.

In our TM cohort, the mean age of study participants was 48.7 years indicating a younger demography. In agreement with previous reports (Potter *et al.* 2020), majority of these BC patients (i.e., 109 (63.7%)) had comorbidities such as obesity and diabetes making them ineligible for mastectomy with immediate reconstruction. Our cohort demonstrates 45 (26.3%) patients underwent an upfront extreme oncoplasty and 50 (29.2%) patients received NACT followed by TM. Thus, TM may be a feasible surgical option for Indian BC cases with advanced stages with either a multifocal, multicentric tumors or LABC at initial presentation.

Typically, 50% of BCs affect the UOQ alone and the outer sector is known to harbor most of them (Clough *et al.* 2010). In our study, 118 (69%) patients had tumors in the upper quadrant, amongst which 74 (43.2%) were in the UOQ alone. Based on our experience, an extended inferior pedicle or a dual pedicle would provide optimal outcomes in such situations (Case Study #2-3?). However, TM (extreme or split reduction mammoplasty) would be a suitable option in cases with large excisions which were otherwise indicated for mastectomy (Case Study #4).

4. Surgical Outcomes/Complications

The complication rates of OBS procedures depend on the technique, length of the procedures, associated comorbidities and post-operative care (De La Cruz *et al.* 2016). In general, ~14% OBS cases demonstrate overall post-operative complications ranging from fat necrosis, skin necrosis, hematoma seroma, delayed wound healing, nipple necrosis and/or wound infection (Campbell and Romics 2017).

To avoid variable reporting, we used the validated Clavien Dindo classification system in our study cohort (Panhofer *et al.* 2014). In agreement with literature, we recorded a relatively low rate of overall complications (i.e., a total of 30 (17.4%). Of these, 15 (8.7%) required an intervention while the others were treated conservatively in the out-patient department. No readmissions were noted. In general, we observed low rate of Grade I/II complications after complex and extreme mammoplasty techniques in high-risk patients with comorbidities who are otherwise prone to developing post-op complications. Taken together, these observations indicate that TM could be a feasible option for Indian BC patients who present in advanced stages with either multifocal, multi-centric tumors or LABC at initial presentation.

In post NACT cases, we observed that TM technique was useful in removing large areas of residual calcifications or clinically large residual tumors, which could turn out to be just fibrosis. Hence, we have been able to improve our post-NACT BCS rate up to 70% (unpublished observations).

5. Post-Surgery Treatment

In our study, majority of patients had a average hospital stay of 2 days (including admission until discharge) consistent with the length of stay required for either a BCS or a mastectomy.

Majority of Indian BCs are diagnosed in advanced stages with node-positive status, thereby, necessitating adjuvant chemotherapy (PMID: 32246015). Duration of treatment for surgical complications is likely to affect the patient's QoL resulting in delay in adjuvant treatment, which in turn, would influence overall oncological outcomes. In our study, the mean duration from TM to start of adjuvant treatment was 50 days without any delay. This observation was consistent with several studies that indicate OBS does not result in delay in adjuvant treatment (Harvey *et al.* 2014).

The optimal duration between OBS and RT has not been established. In our practice, we prefer commencing RT within 6 months of treatment in which adjuvant chemotherapy has been administered. If no ACT is required, we start RT within 5-6 weeks.

6. Oncological Outcomes

6.1 Margin Positivity

One of the potential advantages of TM is wide margins of excision, thus, achieving lower rates of re- excision (Singh and Losken 2012). According to the NCCN guidelines, “no ink on margin” for invasive tumors and >2mm clear margins for DCIS are acceptable for negative margins (McIntosh *et al.* 2007). Literature reports indicate rates of positive margins (i.e., tumor extending to the inked surface) range from 0-36% with institutions reporting a 0% margin rate after conducting intra-operative frozen section analysis (McIntosh *et al.* 2007). When negative margins were considered as >2mm, the reported margin positivity rate was 8-16 % (Potter *et al.* 2020). In the TEAM protocol, 79% cases (of reported 385 TM procedures) have clear margins (O’Connell *et al.* 2018). We observed lower rates of margin positivity in our TM cohort which was consistent with previous reports (Silverstein *et al.* 2015a).

When margins are found to be positive following OBS, some units advocate a re-excision, while completion mastectomy is the procedure choice in the others (Savalia and Silverstein 2016). Further, based on the tumor biology, a RT boost to the tumor bed is another option for close margins (Ho *et al.* 2017). Re-excision in a case of OBS is challenging due to glandular re-arrangement during mammoplasty and should be considered carefully after discussing within the MDT, if the operating surgeon is confident of identifying the tumor bed and orientation (Jassem 2017).

In our study, only 3(1.7%) patients were reported to have close margins. Re-excision of margins were carried out in one patient, one patient underwent completion mastectomy and one received a boost to the tumour bed.

We attribute these encouraging results to our strict surgical SOPs as follows:

- (a) Careful placement of marking so that those closures are not tight
- (b) Maximum excision of the tumour achieved through one limb of the incision
- (c) Access to axilla through the same incision by identifying the lateral border of the Pectoralis major and minor. The Supero-lateral area and the lateral pillar is mobilized carefully to prevent devascularization from the lower lateral segment.
- (d) Sentinel lymph node biopsy performed through the same incision either with a nuclear dye or ICG
- (e) For sentinel node positive status, axillary dissection again carried out through the same incision.
- (f) Analysis of all tumor margins on frozen section and by a specimen mammogram.
- (g) Delay in breast restoration until the results on frozen section are negative.
- (h) Perform contralateral reduction while analysis of frozen sections is ongoing

- (i) Undertake interruptive sutures at the ‘T’ junction instead of continuous sutures to minimize necrosis.

6.2 Loco-regional Recurrence

In general, OBS is applicable in tumour sizes which are larger relative to patients that undergo traditional BCS (28350649)). Even though loco-regional recurrence has been attributed to failure of local control, recent reports indicate influence of tumour biology and size at presentation (De La Cruz *et al.* 2016).

In our study cohort, 66% BC patients were in Stage 2/3 and 46% were deemed high risk based on tumour biology (i.e, Her2 positive and TNBC status). These observations were in concurrence with reports that indicate 29-52% of BC cases in India are diagnosed at Stage 3 at initial presentation (Monica and Mishra 2020).

Hence, it was logical to expect a higher local recurrence rates with larger tumours. In our study, we observed 4 cases of local recurrences (2.3%) and 12 cases of distant metastases at 60 months of follow up (7%). Our results are consistent with previous reports of local recurrence rate of 3% and distant recurrence rate of 13%, with an overall survival rate of 92.5% over a median follow-up of 74 months (Rietjens *et al.* 2007). Based on these oncological outcomes, we conclude that TM is a oncologically safe procedure even in high-risk patients

7. RT related

In our opinion, in majority TM cases, margins around the tumor bed due not shift significantly due to following reasons:

- a. During TM, adequate care is taken to check whether tumor bed is well delineated with markings by Liga clips, as soon as tumor is removed.
- b. In some cases, the margins may get advanced into the tumor cavity to form the bed of the tumor cavity (such as in an extended inferior pedicle). Herein, for dealing with the tumor in the superior quadrant, the lower margin (which is the highest point of the extended pedicle) shifts into the tumor cavity, where exactly the boost is required.
3. In simple mammoplasty (or tumor in lower quadrant or superior quadrant), in which the tumor is in a tissue segment within the specimen, it is likely that some of the margins may shift into the tumor cavity but not shift away from it.
4. If the tumor is lying outside (i.e., in outer quadrant or supero-medial quadrant) and if the excision is large, central mound advancement can be performed to fill up these cavities. In this situation, even if the infero-medial margin may shift, being a supero-medial margin, but it will not go outside the tumor cavity.
5. For cavity on the outer side, if a dual pedicle technique is applied, even then inferior pedicle will be used only to fill in the gap.

Guidelines for optimal RT planning after TM are unclear and further methodical investigations are needed. Indeed, results are eagerly awaited from the MIAMI trial which is the first randomized trial design to address the clinical safety of TM associated with the excision of each cancer and the possibility of performing up to two tumor bed(s) boost(s) radiotherapy (ClinicalTrials.gov Identifier: NCT03514654).

Patient Reported Outcome Measures (PROMS)

In order to evaluate the patient acceptance of TM and improvement in QoL, we utilized Breast Q, a standard validated tool for assessment of patient reported outcome measures (PROMs). Previous reports have indicated that satisfaction with breasts was better in women who underwent OBS than in those who underwent a BCT alone (Dave *et al.* 2016).

Overall, we report high levels of satisfaction on PROMs, which is expected, as the aim of TM is to provide an aesthetically pleasing breast. In our study (Figure 4), a comparison of the PROMs amongst the 3 types of mammoplasties (i.e, simple, complex and extreme oncoplasty) demonstrates almost equal scores indicating that even complex techniques are well accepted. We have previously reported that in BC patients that have undergone mastectomy and immediate breast reconstruction, the lowest response rate was for ‘sexual well-being’ (Shekhawat *et al.* 2015; Koppiker *et al.* 2019b). It is well known that a cancer patient may suffer from sexual dysfunction, which is often under-reported. In the current study, we report a higher mean score of 75.3 for sexual wellbeing. This may be attributed to better body image and self-esteem arising from the satisfactory outcomes from TM procedure and contralateral reduction mammoplasty.

Our encouraging results could be credited to a multitude of factors at our institution such as adequate counselling, high level of patient involvement in the decision-making process, surgical expertise, lower complication rates, personalised hospital services and optimal post-operative care for a long duration.

Our study focus was to evaluate patient’s perception of the aesthetic results, which quite often are different than a clinician’s perspective. In support of the PROMs, independent assessment by 3 different surgeons indicated that over 90% cases exhibited good-to-excellent cosmetic outcomes

CONCLUSION

Our study represents a first detailed report on surgical, oncological and PROMs outcomes after TM surgery in Indian BC patients as observed in a single breast oncoplasty institution. We conclude that our TM technique(s) is best suited for even advanced stage patients with moderate-to-large breasts with mild/severe ptosis.

In general, our study observations are compliant with the guidelines of TEAM protocol except few non-compliances such as lack of MRI which has poor uptake in India due to cost barriers. Our conclusions are supported by availability of large study cohort, detailed surgical methodology, thorough data collection in pre-, intra and post-surgery phases along with PROMs and long-term follow-up. Furthermore, TM procedure may not be applicable for smokers, severe diabetics and morbidly obese women. In general, TM should not be performed if the patient does not consent for bilateral symmetrisation. Our PROMs data indicates excellent acceptance of the TM procedures as indicated by data from patient satisfaction even after RT regimens. These positive outcomes are well-attributed to detailed counseling of patients during various stages of their clinical management.

It may be inaccurate to extrapolate the study findings to the general Indian population due to the large variability in socio-cultural, psychological and economical ground realities across the country. Similar TM-focused studies from other Indian breast units will be needed in future to corroborate the observations from our study. Indeed, SOPs from our study inclusive of surgical techniques and PROMs would be useful for replications by other breast surgeons. However, it should be noted that only few breast units in India offer such OBS surgery choices due to paucity of well-trained breast surgeons. Therefore, anticipating this need, we have established special training initiatives for aspiring OBS surgeons in India. If the techniques and outcomes of OBS are popularized and the broad indications of TM are clearly defined, it is possible that more eligible BC patients will receive the benefits of this procedure over the alternative breast surgery options.

Table 3b : RT Doses Received by Different Anatomical Locations

No.	TM Technique	Anatomical Location	Volume, cc	Maximum Dose, cGy	Mean Dose, cGy
1	Simple TM	Planning Target Volume	587.5	4284.4	4078.7
		Breast, Contralateral	500.4	271.7	32.2
		Heart	436.4	4068.1	822.8
		Lung, Ipsilateral	923.3	4123.7	1219.5
		Lungs	946.2	4119.2	675.4
2	Complex TM	Planning Target Volume	1137.1	4383	4140
		Breast, Contralateral	1115.6	2799.6	315.7
		Heart	619.3	1475.5	597.7
		Lung, Ipsilateral	1049.4	3826.4	1261.1
		Lungs	1792.8	3826.4	865.9
3	Extreme TM	Planning Target Volume	847	4948.1	4232.3
		Breast, Contralateral	505.6	3040.2	401.4
		Heart	609.6	1684.7	636.5
		Lung, Ipsilateral	1245.5	4330.8	1809.4
		Lungs	2150.1	4330.8	1187.4

ACKNOWLEDGEMENT

The study authors would like to thank all participants who consented to participate in this study. We acknowledge Bajaj Auto Ltd. for providing support to research activities at Prashanti Cancer Care Mission, Pune. We are grateful to the MAPI Research Trust for permission to use BREAST-Q (<http://www.mapitrust.org>) and the support from the management and staff of Ruby Hall Clinic, Pune where all surgeries were performed.

CONSENT

The study was approved by an Independent Ethics Committee. All subjects gave their consent for the use of their personal and medical information including images in the publication of this study.

CONFLICT OF INTEREST STATEMENT

The author declares no competing interests.

References

1. de Boniface, J., R. Szulkin, and A. L. V Johansson, 2021 Survival After Breast Conservation vs Mastectomy Adjusted for Comorbidity and Socioeconomic Status: A Swedish National 6-Year Follow-up of 48 986 Women. *JAMA Surg.*
2. Campbell, E. J., and L. Romics, 2017 Oncological safety and cosmetic outcomes in oncoplastic breast conservation surgery, a review of the best level of evidence literature. *Breast cancer (Dove Med. Press.* 9: 521–530.
3. Chen, K., J. Liu, L. Zhu, F. Su, E. Song *et al.*, 2015 Comparative effectiveness study of breast-conserving surgery and mastectomy in the general population: A NCDB analysis. *Oncotarget* 6: 40127–40140.
4. Clough, K. B., G. J. Kaufman, C. Nos, I. Buccimazza, and I. M. Sarfati, 2010 Improving breast cancer surgery: a classification and quadrant per quadrant atlas for oncoplastic surgery. *Ann. Surg. Oncol.* 17: 1375–1391.
5. Dave, R., R. O’Connell, T. Rattay, Z. Tolkien, N. Barnes *et al.*, 2016 The iBRA-2 (immediate breast reconstruction and adjuvant therapy audit) study: protocol for a prospective national multicentre cohort study to evaluate the impact of immediate breast reconstruction on the delivery of adjuvant therapy. *BMJ Open* 6: e012678.
6. Doval, D. C., S. Radhakrishna, R. Tripathi, R. I. Kashinath, V. Talwar *et al.*, 2020 A multi-institutional real world data study from India of 3453 non-metastatic breast cancer patients undergoing upfront surgery. *Sci. Rep.* 10: 5886.
7. Egro, F. M., X. Pinell-White, A. M. Hart, and A. Losken, 2015 The use of reduction mammoplasty with breast conservation therapy: an analysis of timing and outcomes. *Plast. Reconstr. Surg.* 135: 963e-971e.
8. Fisher, B., C. Redmond, R. Poisson, R. Margolese, N. Wolmark *et al.*, 1989 Eight-year results of a randomized clinical trial comparing total mastectomy and lumpectomy with or without irradiation in the treatment of breast cancer. *N. Engl. J. Med.* 320: 822–828.

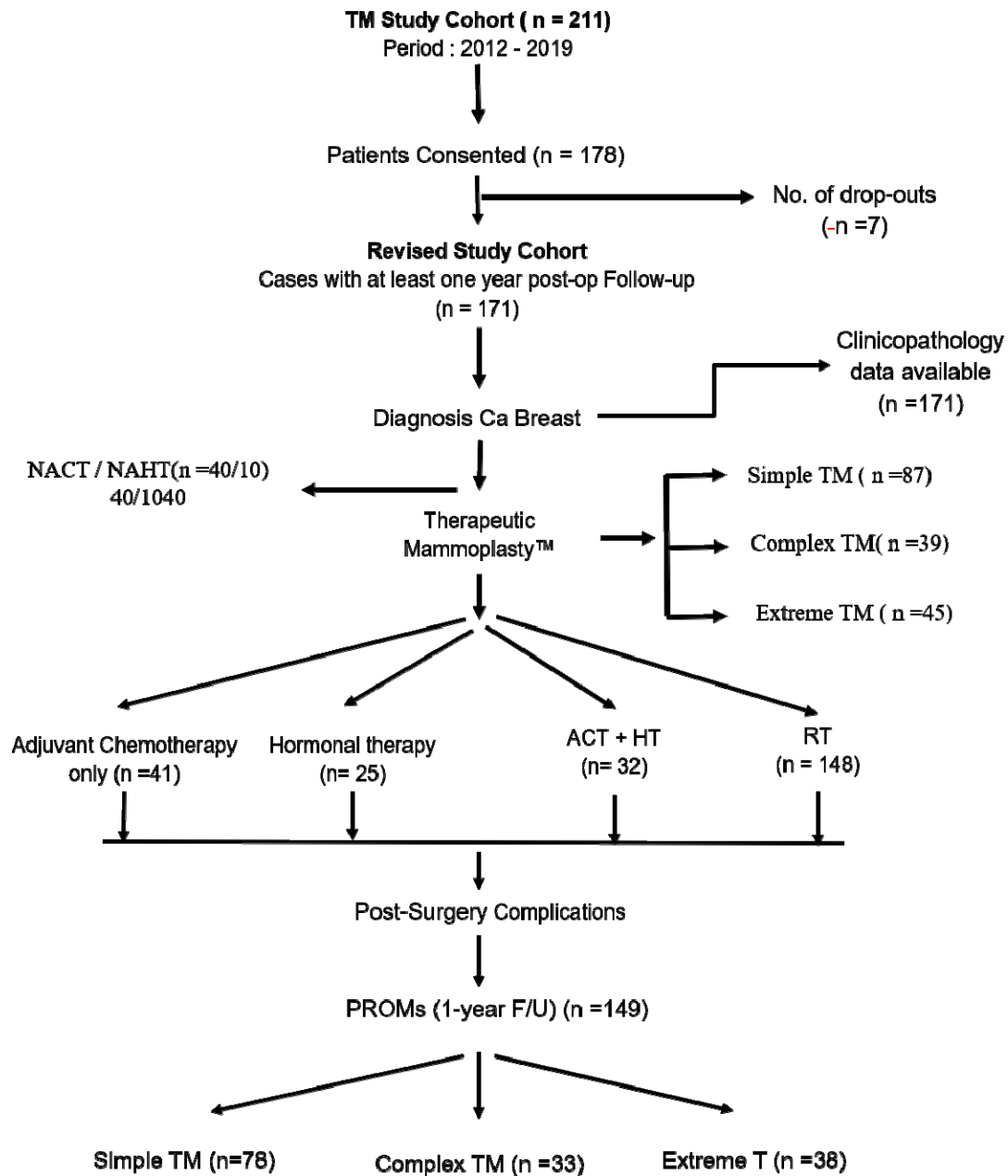
9. Harvey, J., J. Henderson, L. Patel, J. Murphy, and R. Johnson, 2014 Therapeutic mammoplasty - impact on the delivery of chemotherapy. *Int. J. Surg.* 12: 51–55.
10. Ho, A. Y., Z. I. Hu, B. J. Mehrara, and E. G. Wilkins, 2017 Radiotherapy in the setting of breast reconstruction: types, techniques, and timing. *Lancet. Oncol.* 18: e742–e753.
11. Iwuchukwu, O. C., J. R. Harvey, M. Dordea, A. C. Critchley, and P. J. Drew, 2012 The role of oncoplastic therapeutic mammoplasty in breast cancer surgery--a review. *Surg. Oncol.* 21: 133–141.
12. Jassem, J., 2017 Post-mastectomy radiation therapy after breast reconstruction: Indications, timing and results. *Breast* 34 Suppl 1: S95–S98.
13. Koppiker, C. B., Chintamani, and S. Dixit, 2019a Oncoplastic Breast Surgery in India: Thinking Globally, Acting Locally. *Indian J. Surg.* 81: 103–110.
14. Koppiker, C. B., A. U. Noor, S. Dixit, L. Busheri, G. Sharan *et al.*, 2019b Extreme Oncoplastic Surgery for Multifocal/Multicentric and Locally Advanced Breast Cancer. *Int. J. Breast Cancer* 2019: 4262589.
15. De La Cruz, L., S. A. Blankenship, A. Chatterjee, R. Geha, N. Nocera *et al.*, 2016 Outcomes After Oncoplastic Breast-Conserving Surgery in Breast Cancer Patients: A Systematic Literature Review. *Ann. Surg. Oncol.* 23: 3247–3258.
16. Losken, A., C. S. Dugal, T. M. Styblo, and G. W. Carlson, 2014 A meta-analysis comparing breast conservation therapy alone to the oncoplastic technique. *Ann. Plast. Surg.* 72: 145–149.
17. Losken, A., and B. Ghazi, 2012 An update on oncoplastic surgery. *Plast. Reconstr. Surg.* 129: 382e–383e.
18. Losken, A., A. M. Hart, J. S. Broecker, T. M. Styblo, and G. W. Carlson, 2017 Oncoplastic Breast Reduction Technique and Outcomes: An Evolution over 20 Years. *Plast. Reconstr. Surg.* 139: 824e–833e.
19. van Maaren, M. C., L. de Munck, G. H. de Bock, J. J. Jobsen, T. van Dalen *et al.*, 2016 10 year survival after breast-conserving surgery plus radiotherapy compared with mastectomy in early breast cancer in the Netherlands: a population-based study. *Lancet. Oncol.* 17: 1158–1170.
20. Macmillan, R. D., R. James, K. L. Gale, and S. J. McCulley, 2014 Therapeutic mammoplasty. *J. Surg. Oncol.* 110: 90–95.
21. McIntosh, A., G. Freedman, D. Eisenberg, and P. Anderson, 2007 Recurrence rates and analysis of close or positive margins in patients treated without re-excision before radiation for breast cancer. *Am. J. Clin. Oncol.* 30: 146–151.
22. Monica, and R. Mishra, 2020 An epidemiological study of cervical and breast screening in India: district-level analysis. *BMC Womens. Health* 20: 225.
23. O’Connell, R. L., E. Baker, A. Trickey, T. Rattay, L. Whisker *et al.*, 2018 Current practice and short-term outcomes of therapeutic mammoplasty in the international TeaM multicentre prospective cohort study. *Br. J. Surg.* 105: 1778–1792.
24. Panhofer, P., V. Ferenc, M. Schütz, A. Gleiss, P. Dubsy *et al.*, 2014 Standardization of morbidity assessment in breast cancer surgery using the Clavien Dindo Classification. *Int. J. Surg.* 12: 334–339.
25. Potter, S., A. Trickey, T. Rattay, R. L. O’Connell, R. Dave *et al.*, 2020 Therapeutic mammoplasty is a safe and effective alternative to mastectomy with or without immediate breast reconstruction. *Br. J. Surg.* 107: 832–844.
26. Rietjens, M., C. A. Urban, P. C. Rey, G. Mazzarol, P. Maisonneuve *et al.*, 2007 Long-term oncological results of breast conservative treatment with oncoplastic surgery. *Breast* 16: 387–395.
27. Savalia, N. B., and M. J. Silverstein, 2016 Oncoplastic breast reconstruction: Patient selection and

- surgical techniques. *J. Surg. Oncol.* 113: 875–882.
28. Shekhawat, L., L. Busheri, S. Dixit, C. Patel, U. Dhar *et al.*, 2015 Patient-Reported Outcomes Following Breast Reconstruction Surgery and Therapeutic Mammoplasty: Prospective Evaluation 1 Year Post-Surgery with BREAST-Q Questionnaire. *Indian J. Surg. Oncol.* 6: 356–362.
 29. Silverstein, M. J., 2016 Radical Mastectomy to Radical Conservation (Extreme Oncoplasty): A Revolutionary Change. *J. Am. Coll. Surg.* 222: 1–9.
 30. Silverstein, M. J., N. Savalia, S. Khan, and J. Ryan, 2015a Extreme oncoplasty: breast conservation for patients who need mastectomy. *Breast J.* 21: 52–59.
 31. Silverstein, M. J., N. B. Savalia, S. Khan, J. Ryan, M. Epstein *et al.*, 2015b Oncoplastic Split Reduction with Intraoperative Radiation Therapy. *Ann. Surg. Oncol.* 22: 3405–3406.
 32. Singh, K. A., and A. Losken, 2012 Additional benefits of reduction mammoplasty: a systematic review of the literature. *Plast. Reconstr. Surg.* 129: 562–570.
 33. Winters, Z. E., and L. Bernaudo, 2018 Evaluating the current evidence to support therapeutic mammoplasty or breast-conserving surgery as an alternative to mastectomy in the treatment of multifocal and multicentric breast cancers. *Gland Surg.* 7: 525–535.

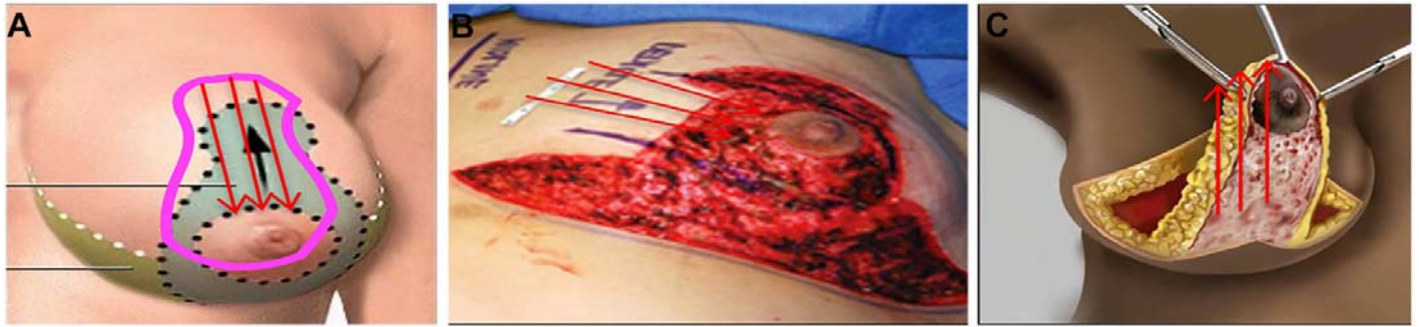

Fig. 2: The Pedicles. A. Superior pedicle mammoplasty, **B.** Superomedial pedicle mammoplasty, **C.** Inferior pedicle mammoplasty.

Figure 3: Study cohort details



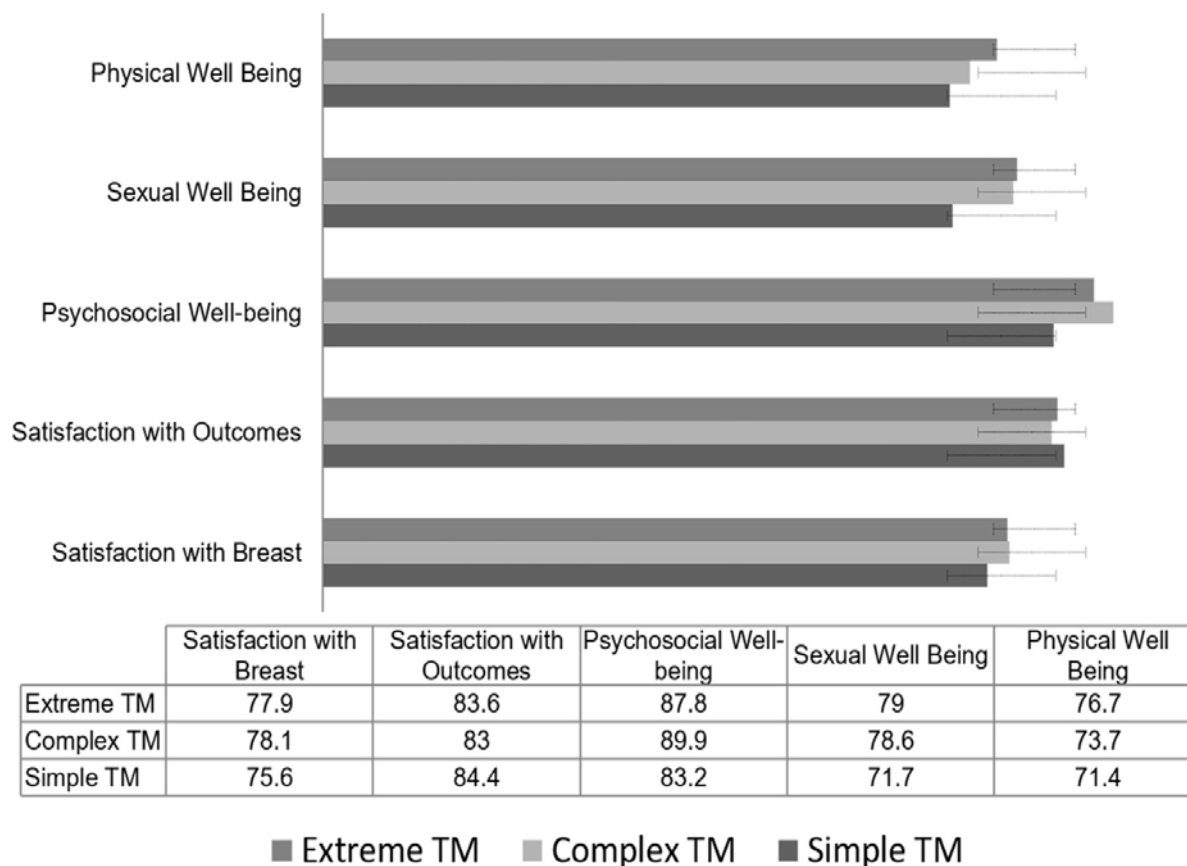


Figure. 4: Analysis of PROMs from TM cohort. Breast Q based PROMs were analyzed for BC cases that underwent simple/complex/extreme TM procedures.