

## **Title Page**

**Title: A Systematic Review of COVID - 19 Induced Myocarditis -**

**Symptomatology, Prognosis, and Clinical Findings**

**Authors:** *Vikash Jaiswal<sup>1</sup>, Shavy Nagpa<sup>2\*</sup>, Christine Angela E.Labitag<sup>1</sup>, Janelle Tayo<sup>5</sup>, Abhinav Patel<sup>4</sup> MBBS, Kevin Bryan Lo<sup>3</sup> MD, Rupalakshmi Vijayan<sup>1</sup>, Wanessa F Matos<sup>1</sup>, Sadia Yaqoob<sup>1,6</sup>, Priyanka Panday<sup>1</sup>, Saloni Savani<sup>1</sup>, Zeinab Alnahas<sup>1</sup>, Arushee Bhatnagar<sup>1</sup>, Yoandra Diaz<sup>1</sup>, John R. Dylewski<sup>1</sup> MD, FHRS.*

### **Institutions:**

- 1- Larkin Community Hospital, South Miami, Florida, USA
- 2- Department of Surgery, Associate: The Clinic – Innovation Lab, Michael G. De Groote, McMaster University, Canada
- 3- Department of Internal Medicine, Albert Einstein Medical Center - Philadelphia, USA
- 4- Terna Medical College, Navi Mumbai, India
- 5- Our Lady of Fatima University- College of Medicine, Philippines
- 6- Jinnah Medical And Dental College, Pakistan.

**Corresponding Author:** Vikash Jaiswal

**Address:** 7031 SW 62<sup>nd</sup> Ave, South Miami, FL 33143, USA

**Email ID:** vikash29jaxy@gmail.com

**Short title:** Systematic Review of COVID-19 and Myocarditis

**Keywords:** Myocarditis, COVID–19, SARS-CoV-2, Pandemic,

**Funding:** The authors have not declared a specific grant for this research from any funding agency in the public, commercial or not-for-profit sectors.

**Disclosures:** The authors have no conflict of interest to disclose.

**Total word count:** 4683 words.

## **Abstract**

### **Objective:**

With the advent of a novel coronavirus in December 2019, several case studies have reported its adversity on cardiac cells. We conducted a systematic review that describes the symptomatology, prognosis, and clinical findings of patients with COVID-19-related myocarditis.

### **Methods:**

Search engines including PubMed, Google Scholar, Cochrane Central, and Web of Science were queried for "SARS-CoV-2" or "COVID 19" and "myocarditis." PRISMA guidelines were employed, and peer-reviewed journals in English related to COVID-19 were included.

### **Results:**

This systematic review included 22 studies and 37 patients. Eight patients (36%) were confirmed myocarditis, while the rest were possible myocarditis. Most patients had elevated cardiac biomarkers, including troponin, CRP, CK, CK-MB, and NT-pro BNP. Electrocardiogram results noted tachycardia (47%), left ventricular hypertrophy (50%), ST-segment alterations (41%), and T wave inversion (18%).

Echocardiography presented reduced LVEF (77%), left ventricle abnormalities (34%), right ventricle aberrations (12%), and pericardial effusion (71%). Further, CMR showed reduced myocardial edema (75%), non-ischemic patterns (50%), and hypokinesis (26%). The mortality was significant at 25%.

### **Conclusions:**

Mortality associated with COVID-19 myocarditis appears significant but underestimated. Further studies are warranted to evaluate and quantify patients' actual prognosis and outcomes with COVID-19 myocarditis.

### **Keywords:**

COVID-19, myocarditis, cardiac, corticosteroids, SARS-CoV-2

## **Abbreviations:**

S/S signs and symptoms, HTN – hypertension, DM II – type II diabetes mellitus, RA – rheumatoid *arthritis*, NA-Not available.

## **1- Introduction:**

On 30 April 2021, there have been 149,910,744 confirmed cases of COVID-19, including 3,155,168 deaths reported globally<sup>1</sup>. COVID-19 is known to target multiple organ systems, inclusive of the respiratory tract. The Angiotensin-converting enzyme 2 (ACE2) receptor has been hypothesized as the receptor used by the receptor-binding domain of virus surface spike protein to enter the host cell. Such affinity could be why the lungs are affected most compared to other organs, as there is a high concentration of ACE2 receptors on the lung epithelial surface<sup>2</sup>. On the other hand, pericytes lining the microvasculature have the strongest ACE2 receptor expression in the heart. Furthermore, the receptor is also expressed in cardiomyocytes, fibroblasts, and vascular smooth muscle cells, explaining why up to 28% of COVID-19 patients harbor myocardial injury<sup>3,4</sup>.

Myocarditis, the inflammation of the myocardial tissue, has been identified as the major cause of myocardial injury in COVID-19. Myocarditis is perceived as an increased immune response (cellular or humoral) in cardiac cells. Clinical manifestations range from chest pain, dyspnea to life-threatening conditions such as cardiogenic shock and death<sup>5</sup>. Myocarditis is confirmed by laboratory testing, ECG, cardiac imaging, heart catheterization, and endomyocardial biopsies (EMB)<sup>6</sup>. So far, several case studies have been reported. A meta–summary of cases presenting coronavirus-induced myocarditis identified chest pain, ECG changes, elevated cardiac and inflammatory biomarkers, left ventricular dysfunction, and hypokinesia as hallmark features of COVID-19-related myocarditis<sup>7</sup>. Using the findings from earlier reports, we have created a conceptual framework of the pathophysiology of COVID-19-related-myocarditis (Figure 1). It highlights the entry of the SARS-COV-2 virus to the heart and the signs and symptoms associated with the cardiac injury.

Nevertheless, considering the limitations of published data (< 1 year of onset of COVID -19), more data is required to establish the symptomatology, prognosis, and

clinical findings of COVID-19-related myocarditis. Thus, we further discussed COVID-19 induced myocarditis and provided an in-depth review of its symptomatology.

## **2- Methods:**

**2.1- Protocol and Registration:** We have used the PRISMA guidelines (Fig. 2) to identify eligible articles in this review.

### **2.2- Eligibility Criteria:**

**A- Inclusion Criteria:** We included articles from peer-reviewed journals that have reported on COVID-19-induced myocarditis. It was limited to studies published only in English.

**B- Exclusion Criteria:** Studies like systematic review, meta-analysis, and letter to the editor were excluded. We also excluded studies that include patients younger than 50 years old and those with known heart problems.

**2.3- Information Sources and Search Strategies:** A comprehensive literature search was done using the search engines Pubmed, Google Scholar, Cochrane CENTRAL, and Web of Science database. The search terms were "SARS-CoV-2" or "COVID 19" and "myocarditis."

**2.4- Study Selection:** Two authors carried out an independent search and screened the titles and abstracts of the identified articles for inclusion. Afterward, full-text articles were reviewed to validate if they truly satisfy the inclusion criteria of this review. Any discrepancies were resolved by consulting a third author.

**2.5- Data Collection Process and Data Items:** Data extracted from articles included author/s, study design, number of patients, year of publication, country, setting, age in years, gender, comorbidities, symptoms, mortality, ECG findings, echocardiogram findings, laboratory results, imaging tests results, and myocardial biopsy. The data were analyzed and synthesized qualitatively using MS Excel PIVOT.

The quality of the included studies was rated using the 'Research and Quality Scoring Method' by Sackett and Haynes, the Jadad scale, and the items published by Cho and Bero<sup>8</sup>. Nine criteria were appraised to determine the overall quality of

each study. The score ranged from zero to nine. Those with scores of zero to three were considered low quality, scores of four to six were moderate quality, and seven to nine were considered high quality. (Supplementary Table 1 and 2)

### **3. Results:**

#### **3.1. Study Selection:**

The electronic search identified 974 potential studies. No additional studies were obtained using other sources. Most of the articles were duplicates; hence, only 624 articles were screened initially. The title and abstracts were reviewed against the inclusion criteria, and 492 articles were excluded on primary screening. Around 110 articles were not on COVID-19-related myocarditis, did not provide an English translation, were review articles, pregnant female and involved participants <50 years old and with known heart problems were excluded. A review of the full-text manuscript of the 22 articles revealed that all of them met the eligibility criteria. Hence, all 22 articles<sup>9-30</sup> were included in the systematic review illustrated according to PRISMA guidelines (Figure 2).

#### **3.2. Characteristics of the Selected Studies**

Twenty-two studies were selected for this systematic review, out of which twenty-one were case reports, and one was a retrospective study. All articles were published in the year 2020, and 41% were done within the US.

The reports included a total sample of 37 patients with COVID-19-related myocarditis. Cases were reported by patients aged between 50 to 81 years with male predominance (62%). The patients were primarily seen in the intensive care unit (41%) and emergency department (32%). In six studies (27%), the participants had no existing illness. In contrast, among those with existing morbidities, the most common diseases were hypertension (55%) and ischemic stroke (9%) (Table 1)

#### **3.3 Methodological Quality of the Selected Studies**

The 'Research and Quality Scoring Method' by Sackett and Haynes, the Jadad scale, and the items published by Cho and Bero were employed to appraise the quality of each study (Han et al., 2011)<sup>8</sup>. Out of 22 studies, 21 studies (96%) were

deemed moderate, and one study (4%) has poor quality. The study design is a potential source of bias. The majority were case studies (96%), and there was one retrospective study (4%). Given the inherent limitations of case studies, the sample size was small, and there were no inclusion or exclusion criteria. Similarly, the sample size for the retrospective study was small at 16 (Supplementary Tables 1 and 2 presents the findings and the description of each criterion).

### ***3.4 Results from the Selected Studies***

#### ***Signs and Symptoms***

Out of 22 studies, 17 articles reported the typical systemic symptoms of COVID-19 myocarditis, which included fever (77%), fatigue (41%), and myalgia (18%). Only 12 studies noted the cardiovascular complaints of the patients, such as chest pain (50%), tachycardia (25%), and hypotension (17%). Meanwhile, 21 studies discussed respiratory signs and symptoms, including shortness of breath (67%), cough (62%), acute respiratory distress syndrome (24%), hypoxia (19%), and tachypnea (14%). Out of 22 studies, only three reports examined the neurological presentation of COVID-19 myocarditis. All studies noted syncope (100%). Then, three studies documented the gastrointestinal complaints of the patients, wherein diarrhea (67%) was the most common presentation (Table 2).

#### ***Prognosis***

Out of 22 studies, only 16 articles (73%) reported mortality, while six studies (27%) did not mention any consequent prognosis. Variable outcomes were reported on COVID-19-related myocarditis with a mortality of 25% ( $n = 4$ ). Out of 16 patients, 12 of them (75%) recovered (Table 2).

#### ***Laboratory Finding:***

Most of the studies noted an increase in troponin (86%), NT-pro BNP (91%), ferritin (80%), WBC (80%), and D-dimer (67%) levels. The median troponin level was 290 (IQR = 3,543) ng/L, median NT-pro BNP was 4,639 (IQR = 4,678) pg/mL, median ferritin level was 948 (IQR = 244) ng/ml, mean WBC count was 17,500 ( $SD = 5,710.08$ ) per  $\mu\text{L}$ , and median D-dimer level was 949 (IQR = 742) ng/mL. Meanwhile, in the studies that examined creatine, 50% noted risen levels with a mean creatinine level of 1.31 ( $SD = 0.48$ ) mg/dL. On the other hand, all studies that evaluated CRP, CK level, CK-MB, ESR and procalcitonin noted elevated laboratory findings. The median CRP level was 18.01 (IQR = 14.09) mg/dL, median CK level was 1130 (IQR = 1005) U/L, median CK-MB level was 20.1 (IQR = 11.94) ng/ml, mean ESR was 80 ( $SD = 2.83$ ) mm/hr, and median procalcitonin level was 7.69 (IQR = 7.51) ng/ml (Table 3)

### ***Electrocardiogram:***

Tachycardia was noted in eight studies (47%). In terms of rhythm, normal sinus rhythm was noted in nine studies (75%) and atrial fibrillation in one study (8%). The ECG reports also revealed left ventricular hypertrophy (50%). The findings also noted alterations in the ST segments (41%) and T wave inversion (18%) (Table 4). All in all, these electrocardiogram findings vary pretty broadly.

**Echocardiogram:** The majority of studies (77%) observed a reduced left ventricular ejection fraction (LVEF). The mean LVEF was 33% ( $SD = 8.35$ ). Out of the 17 studies, there were also significant abnormalities in the left ventricle in six studies (34%) and right ventricle in two studies (12%). Pericardial effusion was noted in 5 studies, but most studies had no mention of this (Table 5).

**Radiology:** In terms of the coronary angiography results, only 1 study found a significant coronary artery disease, while of the ten studies, 8 (80%) had a chest CT noted with ground-glass changes, and 2 (20%) was noted with bilateral opacities. Similarly, in 14 studies with chest x-ray findings, 6 (43%) were noted with bilateral interstitial opacities, 2 (14%) with bilateral basal opacities, and 2 (14%) with bilateral pleural effusion (Table 6).

**CMR and EMB** The CMR and myocardial biopsy results were used to identify possible and confirmed cases of COVID-19-related myocarditis. Out of 22 studies,

eight studies performed CMR, and only two were able to provide histopathological findings through EMB. Eight were confirmed cases (36%), and the rest were suspected cases (Table 7).

Generally, myocarditis can be suspected with clinical presentations suggestive of acute coronary syndrome on ECG, laboratory testing (e.g., increase troponin levels), and/or wall motion abnormalities with no obstruction of coronary arteries on coronary angiography<sup>4</sup>.

Myocarditis diagnosed through CMR was based on Lake Louise Criteria, which includes signs of edema, T2-weighted imaging, and necrosis with late gadolinium enhancement (LGE), along with supportive findings of left ventricular dysfunction and pericardial effusion<sup>11</sup>. On T1-weighted imaging, two studies revealed diffuse biventricular hypokinesis, one discrete hypokinesis, and one mild hypokinesis in the lateral wall segment. On T2 weighted imaging, six studies with T2 mapping of myocardium illustrated myocardial edema, of which 2 of them revealed a diffuse, biventricular and interventricular region. Imaging on LGE results showed non-ischemic patterns in 4 studies and an ischemic pattern on the left ventricular septum wall in 1 study. Anterolateral, inferolateral, and biventricular walls were the most affected regions with subepicardial to transmural affectation. Supporting criteria in the Lake Louise consensus criteria, such as systolic dysfunction, was also noted in 3 studies, with a mean value LVEF of 42% and pericardial effusion in 1 study.

From the two studies that performed EMB, 1 study showed an increased number of T-lymphocytes infiltrates<sup>11</sup>. The result of the other study excluded other potential etiologies such as heart failure or arrhythmias, parvovirus B19, human herpesvirus, Epstein-Barr virus, enterovirus, cytomegalovirus, adenovirus, HIV, and hepatitis C virus. They have concluded that SARS-CoV-2 infection was most likely the cause<sup>17</sup>.

## **Discussion:**

This systematic review aimed to describe the symptomatology, prognosis, and clinical findings of patients with probable and confirmed COVID-19-related myocarditis. Frequent clinical findings of COVID-19 constitute fever, cough, shortness of breath, and fatigue<sup>31</sup>. WHO (World Health Organization) has also cited fever and cough as striking features of COVID-19<sup>32</sup>. Fever, dyspnea, and/or chest



pain are the typical manifestations of myocarditis that overlap with the symptoms of COVID-19, thus making diagnosis challenging<sup>33</sup>. However, laboratory investigations such as raised cardiac biomarkers and electrocardiogram may assist in diagnosing COVID-19 induced myocarditis.

Our study's mortality rate from COVID-19-related myocarditis was high as 25%, which is comparable with the previous meta-summary, which noted 27% fatalities in patients with COVID-19 related myocarditis<sup>34</sup>. Our results align with a prior case report which proposes that myocardial injury is a cardinal predictor of mortality in COVID-19<sup>35</sup>. Even though the majority of the patients in our review survived COVID-19-related myocarditis, the actual mortality rate may be higher as many of the included studies did not report a fatality.

COVID-19 symptoms can be minimal to severe<sup>36</sup>. This was evident in our sample, wherein the participants displayed a varied course of the disease. The immune system plays a vital role in the severity of the symptoms in an individual inflicted with COVID-19. Those individuals with strong immunity are found to have mild symptoms compared to those with weak immunity. In contrast, aged people who have multiple comorbidities show more signs and symptoms of COVID-19<sup>37</sup>. Some of these patients can progress to acute respiratory distress syndrome, a severe complication of COVID-19<sup>38</sup>.

Conventionally, serum biomarkers are used to confirm any suspected case of acute myocarditis. Patients infected with the COVID-19 exhibited elevated troponin levels<sup>39</sup>. However, their presence cannot be used to rule out the possibility of any specific types of myocarditis. High CK-MB and BNP levels may be associated with COVID-19 induced myocarditis but are relatively non-specific as any state of volume overload or demand ischemia may also present likewise<sup>40</sup>. However, inflammatory markers such as C- reactive protein, D-dimer, and ferritin are found to be significantly increased in severe illness<sup>41</sup>. ECG findings of included studies denoted tachycardia and left ventricular hypertrophy, which coincides with the study's conceptual framework.

Furthermore, the echocardiogram findings were positive for a reduced left ventricular ejection fraction (LVEF) varying between 20% to 47% and pericardial effusion.

Pericardial effusion appears to be a novel finding. Nevertheless, past literature on clinically suspected myocarditis and acute myocarditis recognized pericardial effusion as a concurrent finding in patients with myocarditis<sup>42,43</sup>. Nevertheless, reduced ejection fraction is not distinct in myocarditis. It can also occur in a myocardial injury secondary to systemic causes rather than a viral infection of the heart. Definitive findings can be ascertained in the endomyocardial biopsy and MRI, but we had a very small proportion of this cohort study. Despite such measures, we noticed mortality in one-fourth of cases during recovery in three-fourths. The authors addressed this as a limitation for this study.

### **Limitations**

COVID-19 and myocarditis can potentially present the same way and maybe hard to differentiate clinically. It may be underreported as many patients account for "new" diminished EF with elevated myocardial markers, but it is plausible that projected growth in severe outcomes might warrant special attention shortly. However, only a handful of myocarditis cases confirmed via MRI and/ or endomyocardial biopsy have been addressed. Patients were reluctant to undergo MRI and biopsy due to fear of contracting COVID-19, and available diagnostic tests such as echo and EKG were reliable for screening but not diagnostic purposes, except in the case of pericardial effusion. COVID-19 is associated with cardiovascular involvement, and patients with known cases of cardiovascular disease are prone to face severe outcomes with COVID-19. It is more toilsome to differentiate COVID-19 patients with and concomitant myocarditis based on clinical features. Biomarkers such as troponin, BNP, and CK-MB might aid in the diagnosis but are non-specific because their levels can also rise in other conditions such as acute heart failure and demand ischemia.

### **Conclusions**

COVID-19 related mortality from myocarditis appears significant and underestimated. Many cases of COVID-19 myocarditis have not been subjected to definitive diagnostic approaches, including endomyocardial biopsy and MRI. In addition, rates of poor outcomes such as mortality and the presence of myocarditis itself might be underreported. Further studies are needed to outline the trends of

symptoms, outcomes, and prognosis of patients with COVID-19 related myocarditis. Moreover, an upsurge in such cases necessitates establishing treatment guidelines since current treatment approaches in practice vary from case to case.

**Author's Role:**

**1- Research Project: A. Conception, B. Organization, C. Execution.**

**2- Statistical Analysis: A. Design, B. Execution, C. Review, and Critique.**

**3- Manuscript: A. Writing of the first draft, B. Review of Critique.**

**VJ: 1A, 1B, 1C, 2A, 2B, 2C, 3A, 3B**

**SN: 1B, 1C, 2C, 3A, 3B**

**JT, AP, CE: 1B, 1C, 2B, 2A, 3A**

**WM, ZA, YD, RV, SS, AB, PP: 2B, 2C, 3B**

**KB, SY: 1C, 2C, 3A, 3B.**

**JD: 2C, 3B.**

**Acknowledgment:** The authors of this article would like to thanks the sponsoring institution "Larkin Community Hospital" for helping and supporting throughout till final submission. w

**Funding:** The authors have not declared a specific grant for this research from any funding agency in public, commercial or not-for-profit sectors.

**Disclosures:** The authors have no conflicts of interest to disclose.

## References

1. World Health Organization (2021a). *WHO Coronavirus disease (COVID-19) dashboard*. <https://covid19.who.int/>.
2. Rothan, H. A., & Byrareddy, S. N. (2020). The epidemiology and pathogenesis of coronavirus disease (COVID-19) outbreak. *Journal of Autoimmunity*, *109* (102433). <https://doi.org/10.1016/j.jaut.2020.102433>.
3. Guo, T., Fan, Y., Chen, M., Wu, X., Zhang, L., He, T., Wang, H., Wan, J., Wang, X., & Lu, Z. (2020). Cardiovascular implications of fatal outcomes of patients with coronavirus Disease 2019 (COVID-19). *JAMA Cardiology*, *5*(7), 811-818. <https://doi.org/10.1001/jamacardio.2020.1017>.
4. Tucker, N. R., Chaffin, M., Bedi Jr., K.C., Papangeli, I., Akkad, A.D., Arduini, A., Hayat, S., Eraslan, G., Muus, C., Bhattacharyya, R., Stegmann, C., Human Cell Atlas Lung Biological Network, Margulies, K.B., & Ellinor, P. (2020). Myocyte-specific upregulation of ACE2 in cardiovascular disease: Implications for SARS-COV-2-mediated myocarditis. *Circulation*, *142*(7), 708-710. <https://doi.org/10.1161/CIRCULATIONAHA.120.047911>.
5. Tschöpe, C., Cooper, L., Torre-Amione, G., & Linthout, S.V. (2019). Management of myocarditis-related cardiomyopathy in adults. *Circulation Research*, *124*(11), 1568–1583. <https://doi.org/10.1161/CIRCRESAHA.118.313578>.
6. Ukena, C., Kindermann, M., Mahfoud, F., Geisel, J., Lepper, P.M., Kandolf, R., Bohm, M., Kindermann, I. (2014). Diagnostic and prognostic validity of different biomarkers in patients with suspected myocarditis. *Clinical Research in Cardiology*. <https://www.escardio.org/Working-groups/Working-Group-on-Myocardial-and-Pericardial-Diseases/Publications/Paper-of-the-Month/Diagnostic-and-prognostic-validity-of-different-biomarkers-in-patients-with-susp>

7. Ho, J.S., Sia, C.H., Chan, M.Y., Lin, W., & Wong, R.C. (2020). Coronavirus-induced myocarditis: A meta-summary of cases. *The Journal of Cardiopulmonary and Acute Care*, 49(6), 681-685  
<https://doi.org/10.1016/j.hrtlng.2020.08.013>.
8. Han, H.R., Kim, J., Lee, J.E., Hedlin, H.K., Song, H., Song, Y., & Kim, M.T. (2011). Interventions that increase use of Pap tests among ethnic minority women: A meta-analysis. *Psycho-Oncology*, 20, 341–351.  
<https://doi.org/10.1002/pon.1754>.
9. Cizgici, A. Y., Zencirkiran Agus, H., & Yildiz, M. (2020). COVID-19 myopericarditis: It should be kept in mind in today's conditions. *The American Journal of Emergency Medicine*, 38 (7), 1547.e5–1547.e6.  
<https://doi.org/10.1016/j.ajem.2020.04.080>. Result section starts
10. Yokoo, P., Fonseca, E., Sasdelli Neto, R., Ishikawa, W. Y., Silva, M., Yanata, E., Chate, R. C., Nunes Filho, A., Bettega, M., Fernandes, J., Tarasoutchi, F., & Szarf, G. (2020). COVID-19 myocarditis: a case report. *Einstein (Sao Paulo, Brazil)*, 18, eRC5876. [https://doi.org/10.31744/einstein\\_journal/2020RC5876](https://doi.org/10.31744/einstein_journal/2020RC5876)
11. Pietsch, H., Escher, F., Aleshcheva, G., Baumeier, C., Morawietz, L., Elsaesser, A., & Schultheiss, H. P. (2021). Proof of SARS-CoV-2 genomes in endomyocardial biopsy with latency after acute infection. *International Journal of Infectious Diseases: Official Publication of The International Society for Infectious Diseases*, 102, 70–72. <https://doi.org/10.1016/j.ijid.2020.10.012>.
12. Pavon, A. G., Meier, D., Samim, D., Rotzinger, D. C., Fournier, S., Marquis, P., Monney, P., Muller, O., & Schwitter, J. (2020). First documentation of persistent SARS-Cov-2 infection presenting with late acute severe myocarditis. *The Canadian Journal of Cardiology*, 36(8), 1326.e5–1326.e7.  
<https://doi.org/10.1016/j.cjca.2020.06.005>.
13. Khatri, A., & Wallach, F. (2020). Coronavirus disease 2019 (COVID-19) presenting as purulent fulminant myopericarditis and cardiac tamponade: A case report and literature review. *Heart & lung: The Journal of Critical Care*, 49 (6), 858–863. <https://doi.org/10.1016/j.hrtlng.2020.06.003>.
14. Hussain, H., Fadel, A., Alwaeli, H., & Guardiola, V. (2020). Coronavirus (COVID-19) Fulminant myopericarditis and acute respiratory distress syndrome (ards) in a middle-aged male patient. *Cureus*, 12 (6), e8808.  
<https://doi.org/10.7759/cureus.8808>.

15. Dalen, H., Holte, E., Guldal, A. U., Hegvik, J. A., Stensaeth, K. H., Braaten, A. T., Mjølstad, O. C., Rossvoll, O., & Wiseth, R. (2020). Acute perimyocarditis with cardiac tamponade in COVID-19 infection without respiratory disease. *BMJ Case Reports*, *13* (8), e236218. <https://doi.org/10.1136/bcr-2020-236218>.
16. Zeng, J. H., Liu, Y. X., Yuan, J., Wang, F. X., Wu, W. B., Li, J. X., Wang, L. F., Gao, H., Wang, Y., Dong, C. F., Li, Y. J., Xie, X. J., Feng, C., & Liu, L. (2020). First case of COVID-19 complicated with fulminant myocarditis: A case report and insights. *Infection*, *48*(5), 773–777. <https://doi.org/10.1007/s15010-020-01424-5>.
17. Doyen, D., Mocerri, P., Ducreux, D., & Dellamonica, J. (2020). Myocarditis in a patient with COVID-19: A cause of raised troponin and ECG changes. *Lancet (London, England)*, *395*(10235), 1516. [https://doi.org/10.1016/S0140-6736\(20\)30912-0](https://doi.org/10.1016/S0140-6736(20)30912-0).
18. Faircloth, E., Conner, C., Dougherty, K., Arora, S., & Thorevska, N. (2020). Viral heartbreak: A case of covid-19 myocarditis vs stress-induced cardiomyopathy. *Chest*, *158* (4), A173. <https://doi.org/10.1016/j.chest.2020.08.185>.
19. Coyle, J., Igbinomwanhia, E., Sanchez-Nadales, A., Danciu, S., Chu, C., & Shah, N. (2020). A recovered case of COVID-19 myocarditis and ARDS treated with corticosteroids, tocilizumab, and experimental AT-001. *JACC Case reports*, *2*(9), 1331–1336. <https://doi.org/10.1016/j.jaccas.2020.04.025>.
20. Luetkens, J. A., Isaak, A., Zimmer, S., Nattermann, J., Sprinkart, A. M., Boesecke, C., Rieke, G. J., Zchoval, C., Heine, A., Velten, M., & Duerr, G. D. (2020). Diffuse myocardial inflammation in COVID-19 associated myocarditis detected by multiparametric cardiac magnetic resonance imaging. *Circulation. Cardiovascular imaging*, *13* (5), e010897. <https://doi.org/10.1161/CIRCIMAGING.120.010897>.
21. Jain, A., Deval, N., & Paul, L. (2020). A recovered case of covid-19 myocarditis treated with IV immunoglobulin. *Chest*, *158* (4), A281. <https://doi.org/10.1016/j.chest.2020.08.282>.
22. Mustafa, S., Zafar, M., Agrawal, N., Shahbaz, A., & Al-khafaji, N. (2020). COVID-19-associated myocarditis mimicking ST elevation myocardial infarction. *Chest*, *158* (4), A572. <https://doi.org/10.1016/j.chest.2020.08.537>.

23. Mansoor, A., Chang, D., & Mitra, R. (2020). Rhythm, conduction, and ST elevation with COVID-19: Myocarditis or myocardial infarction? *HeartRhythm Case Reports*, 6 (10), 671-675. <https://doi.org/10.1016/j.hrcr.2020.08.001>.
24. Al-assaf, O., Mirza, M., & Musa, A. (2020). Atypical presentation of COVID-19 as subclinical myocarditis with persistent high-degree atrioventricular block treated with pacemaker implant. *HeartRhythm Case Reports*, 6 (11) 884-887. <https://doi.org/10.1016/j.hrcr.2020.09.003>.
25. Khalid, Y., Dasu, N., & Dasu, K. (2020). A case of novel coronavirus (COVID-19)-induced viral myocarditis mimicking a Takotsubo cardiomyopathy. *HeartRhythm Case Reports*, 6 (8), 473-476. <https://doi.org/10.1016/j.hrcr.2020.05.020>.
26. Ng, M. Y., Ferreira, V. M., Leung, S. T., Lee, J. C. Y., Fong, A. H. T., Liu, R. W. T, Chan, J. W. M., Ka Lun Wu, A., Lung, K. C., Crean, A., Fan-Ngai Hung, I., & Siu, C. W. (2020). Patients recovered from COVID-19 show ongoing subclinical myocarditis as revealed by cardiac magnetic resonance imaging. *JACC: Cardiovascular Imaging*, 13 (11), 2476-2478. <https://doi.org/10.1016/j.jcmg.2020.08.012>.
27. Inciardi, R. M., Lupi, L., Zacccone, G., Italia, L., Raffo, M., Tomasoni, D., Cani, D., Cerini, Manuel., Farina, Davide., Gavazzi, Emanuele., Maroldi, R., Adamo, M., Ammirati, E., Sinagra, G., Lombardi, C. M., & Metra, M. (2020). Cardiac involvement in a patient with coronavirus Disease 2019 (COVID-19). *JAMA Cardiology*, 5 (7), 819–824. <https://doi:10.1001/jamacardio.2020.1096>.
28. Fried, J. A., Ramasubbu, K., Bhatt, R., Topkara, V. K., Clerkin, K. J., Horn, E., Rabbani, L., Brodie, D., Jain, S. S., Kirtane, A. J., Masoumi, A., Takeda, K., Kumaraiah, D., Burkhoff, D., Leon, M., Schwartz, A., Uriel, N., & Sayer, G. (2020). The variety of cardiovascular presentations of COVID-19. *Circulation*, 141 (23), 1930–1936. <https://doi.org/10.1161/CIRCULATIONAHA.120.047164>.
29. Wehit, J., Sosa, F., Merlo, P., Roberti, J., Osatnik, J., (2020). Identification of COVID-19-associated myocarditis by speckle-tracking transesophageal echocardiography in critical care. *Acta Colombiana de Cuidado Intensivo*. <https://doi.org/10.1016/j.acci.2020.11.008>.

30. Radbel, J., Narayanan, N., & Bhatt, P. J. (2020). Use of tocilizumab for COVID-19-induced cytokine release syndrome: A cautionary case report. *Chest*, 158 (1), e15–e19. <https://doi.org/10.1016/j.chest.2020.04.024>
31. Fu L, Wang B, Yuan T, Chen X, Ao Y, Fitzpatrick T, Li P, Zhou Y, Lin Y, Duan Q, Luo G, Fan S, Lu Y, Feng A, Zhan Y, Liang B, Cai W, Zhang L, Du X, Li L, Shu Y, Zou H. Clinical characteristics of coronavirus disease 2019 (COVID-19) in China: a systematic review and meta-analysis. *J Infect* 2020; S0163-4453(20)30170-5.
32. Advice for the public on covid-19 – world health organization. Accessed May 6, 2021. <https://www.who.int/emergencies/diseases/novel-coronavirus-2019/advice-for-public>
33. Cooper LT Jr. Myocarditis. *N Engl J Med* 2009; 360(15): 1526–38.
34. Ho, J.S., Sia, C.H., Chan, M.Y., Lin, W., & Wong, R.C. (2020). Coronavirus-induced myocarditis: A meta-summary of cases. *The Journal of Cardiopulmonary and Acute Care*, 49(6), 681-685  
<https://doi.org/10.1016/j.hrtlng.2020.08.013>.
35. Zhou, F., Yu, T., Du, R., Fan, G., Liu, Y., Liu, Z., Xiang, J., Wang, Y., Song, B., Gu, X., Guan, L., Wei, Y., Li, H., Wu, X., Xu, J., Tu, S., Zhang, S., Chen, H., & Cao, B. (2020). Clinical course and risk factors for mortality of adult in patients with COVID-19 in Wuhan, China: A retrospective cohort study. *Lancet*, 395(10229), 1054-1062. [https://doi.org/10.1016/S0140-6736\(20\)30566-3](https://doi.org/10.1016/S0140-6736(20)30566-3).
36. Yuki, K., Fujiogi, M., & Koutsogiannaki, S. (2020). COVID-19 pathophysiology: A review. *Clinical Immunology*, 215, 108427.  
<https://doi.org/10.1016/j.clim.2020.108427>.
37. Brodin P. Immune determinants of COVID-19 disease presentation and severity. *Nature Medicine*. 2021 Jan;27(1):28-33. DOI: 10.1038/s41591-020-01202-8.
38. Hussain, H., Fadel, A., Alwaeli, H., & Guardiola, V. (2020). Coronavirus (COVID-19) Fulminant myopericarditis and acute respiratory distress syndrome (ARDS) in a middle-aged male patient. *Cureus*, 12 (6), e8808.  
<https://doi.org/10.7759/cureus.8808>.



39. Qin JJ, Cheng X, Zhou F, Lei F, Akolkar G, Cai J, Zhang XJ, Blet A, Xie J, Zhang P, Liu YM, Huang Z, Zhao LP, Lin L, Xia M, Chen MM, Song X, Bai L, Chen Z, Zhang X, Xiang D, Chen J, Xu Q, Ma X, Touyz RM, Gao C, Wang H, Liu L, Mao W, Luo P, Yan Y, Ye P, Chen M, Chen G, Zhu L, She ZG, Huang X, Yuan Y, Zhang BH, Wang Y, Liu PP, Li H. Redefining Cardiac Biomarkers in Predicting Mortality of Inpatients With COVID-19. *Hypertension*. 2020 Oct;76(4):1104-1112. doi: 10.1161/HYPERTENSIONAHA.120.15528. Epub 2020 Jul 14. PMID: 32673499; PMCID: PMC7375179.
40. Gaggin H.K. & Januzzi J.L. (2015). Cardiac Biomarkers and Heart Failure, Expert Analysis. *American College of Cardiology*. Feb,10, 2015.
41. Ho, J.S., Sia, C.H., Chan, M.Y., Lin, W., & Wong, R.C. (2020). Coronavirus-induced myocarditis: A meta-summary of cases. *The Journal of Cardiopulmonary and Acute Care*, 49(6), 681-685  
<https://doi.org/10.1016/j.hrtlng.2020.08.013>.
42. Ukena, C., Kindermann, M., Mahfoud, F., Geisel, J., Lepper, P.M., Kandolf, R., Bohm, M., Kindermann, I. (2014). Diagnostic and prognostic validity of different biomarkers in patients with suspected myocarditis. *Clinical Research in Cardiology*. <https://www.escardio.org/Working-groups/Working-Group-on-Myocardial-and-Pericardial-Diseases/Publications/Paper-of-the-Month/Diagnostic-and-prognostic-validity-of-different-biomarkers-in-patients-with-susp>.
43. Di Bella, G., Imazio, M., Bogaert, J., Pizzino, F., Camastra, G., Monti, L., Dellegrottaglie, S., Donato, R., Moro, C., Pepe, A., Lanzillo, C., Pontone, G., Marra, M.P., Fusco, A., Scatteia, A., Pingitore, A., & Aquaro, G.D. (2019). Clinical value and prognostic impact of pericardial involvement in acute myocarditis. *Circulation: Cardiovascular Imaging*, 12(2). <https://doi.org/10.1161/CIRCIMAGING.118.008504>

Figure 1: Snapshot: Myocarditis (COVID -19)


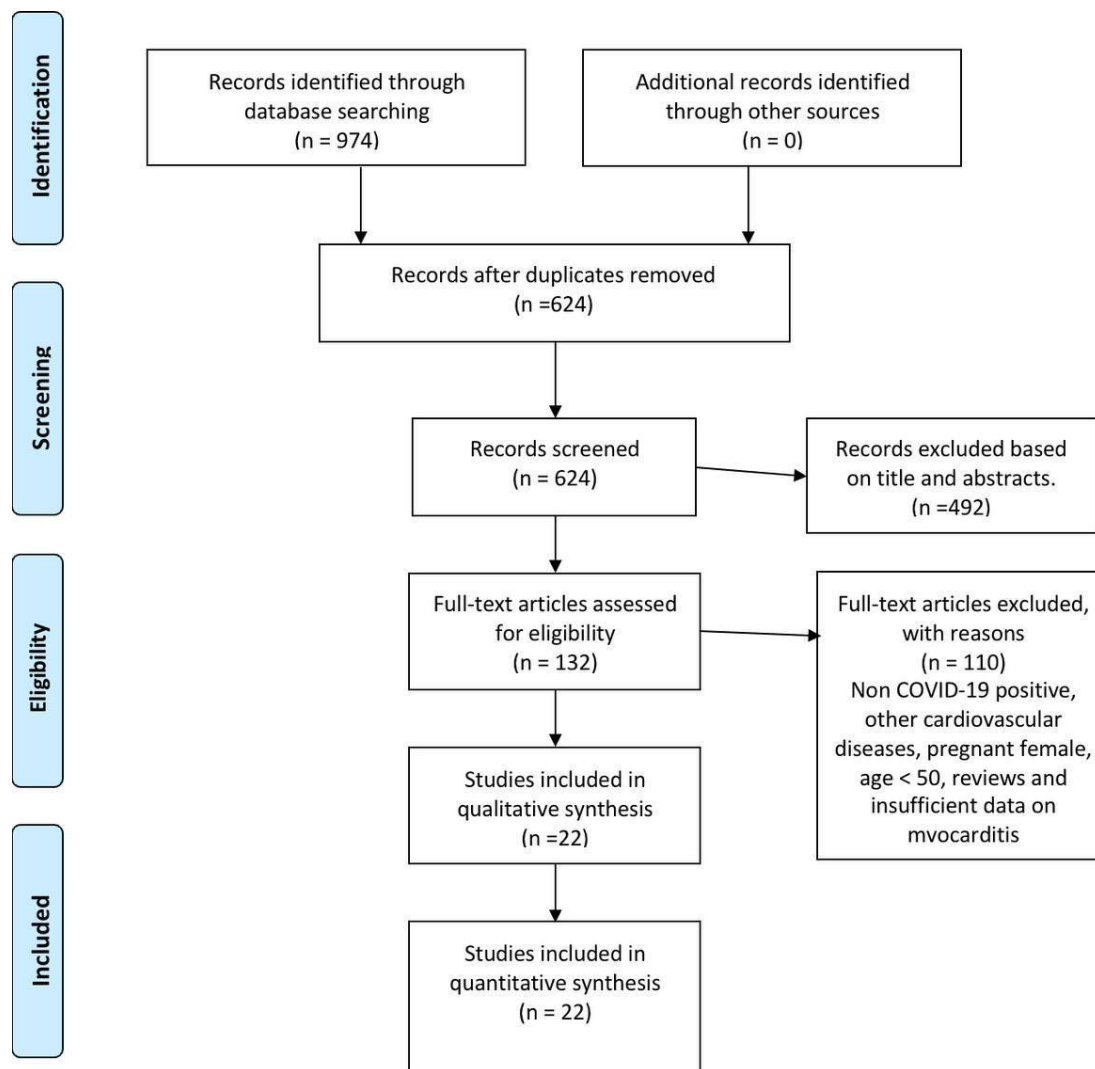


Figure 2: Flowchart on study selection and screening using PRISMA Guidelines.





## Table

**Table 1: Characteristics of the Included Studies**

Author	Study Design	Number of patients	Year of Publication	Country	Setting	Age in Years	Gender	Comorbidities
Cizgici AY et al	Case report	1	2020	Turkey	ICU	78	Male	HTN
Yokoo P et al	Case report	1	2020	Brazil	Not specified	81	Male	HTN, ischemic stroke
Pietsch H et al	Case report	1	2020	Germany	ICU	59	Female	None
Pavon AG et al	Case report	1	2020	Switzerland	ICU	64	Male	Isolated pulmonary sarcoidosis and epilepsy
Khatiri A et al	Case report	1	2020	USA	ICU	50	Male	HTN, ischemic stroke
Hussain H et al	Case report	1	2020	USA	Isolation unit	51	Male	HTN
Dalen H et al	Case report	1	2020	Norway	ICU	55	Female	None
Zengh JH	Case report	1	2020	China	ICU	63	Male	None
Doyen D et al	Case report	1	2020	France	ICU	69	Male	HTN
Faircloth E et al	Case report	1	2020	USA	Not specified	60	Male	Multiple sclerosis
Coyle J	Case report	1	2020	USA	ED	57	Male	HTN
Luetkens JA et al, 2020	Case report	1	2020	Germany	ICU	79	Male	Asthma
Jain A et al	Case report	1	2020	India	ED	60	Male	HTN, DM II
Mustafa S et al.	Case report	1	2020	USA	ED	56	Male	None
Mansoor A et al.	Case report	1	2020	USA	ED	72	Female	HTN
Al-assaf O et al.	Case report	1	2020	UAE	ED	58	Male	HTN
Khalid Y et al	Case report	1	2020	USA	Not specified	76	Female	HTN, hyperlipidemia, hypothyroidism
Ng My et al	Retrospective study	16	2020	China	ED	53 to 69	7 Females and 9 Males	None
Inciardi et al	Case report	1	2020	Italy	ED	53	Female	None
Fried et al	Case report	1	2020	USA	Not specified	64	Female	HTN, hyperlipidemia
Wehit et al	Case report	1	2020	Argentina	ICU	68	Male	HTN, obesity, DM II, chronic smoking
Radbel et al	Case report	1	2020	USA	Not specified	69	female	DM II, RA, aplastic anemia

Note: HTN – hypertension, DM II – type II diabetes mellitus, RA – rheumatoid *arthritis*

The reports included a total sample of 37 patients with COVID-19-related myocarditis. Cases were reported by patients aged between 50 to 81 years with male predominance (62%). The patients were primarily seen in the intensive care unit (41%) and emergency department (32%). In six studies (27%), the participants had no existing illness. In contrast, among those with existing morbidities, the most common diseases were hypertension (55%) and ischemic stroke (9%)

**Table number a2: Signs and symptoms of COVID-19-related myocarditis**

Author	Systemic	Cardiovascular	Respiratory	Neurology	Gastrointestinal	Mortality
Cizgici AY et al	N/A	Chest pain	Shortness of breath, ARDS	N/A	N/A	N/A
Yokoo P et al	Fever	N/A	Shortness of breath, No hypoxia (91% SpO2)	N/A	N/A	Recovered
Pietsch H et al	N/A	N/A	ARDS	N/A	N/A	N/A
Pavon AG et al	Fever (39.3)	Chest pain	Shortness of breath, Cough	N/A	N/A	Recovered
Khatiri A et al	Fever, Chills, Malaise	N/A	Shortness of Breath, Cough	Syncope	N/A	Yes
Hussain H et al	Fatigue, Fever	N/A	Cough, Shortness of breath	N/A	N/A	Recovered
Dalen H et al	Fatigue, Myalgia	Chest pain	Not mentioned	Syncope	N/A	Recovered
Zengh JH	Fever	N/A	Cough, Shortness of breath, Chest Pain	N/A	N/A	Yes
Doyen D et al	Fever	N/A	Cough, Shortness of breath	N/A	Vomiting, Diarrhea	Recovered
Faircloth E et al	Fever	Tachycardia, Hypotension	Shortness of breath, Tachypnea, Hypoxia	N/A	N/A	Recovered
Coyle J	Fever, Myalgia	N/A	Cough, Shortness of breath	N/A	Decrease appetite, Nausea, Diarrhea	Recovered
Luetkens JA et al, 2020	Fatigue	N/A	Shortness of breath, No hypoxia (94% SpO2), Wheeze	Syncope	N/A	N/A
Jain A et al	N/A	N/A	Cough, Shortness of breath, hypoxia (75% SpO2)	N/A	N/A	Recovered
Mustafa S et al.	Fatigue, Myalgia	Chest pain	Cough, Shortness of breath	N/A	N/A	Recovered
Mansoor A et al.	Myalgia, Fever	Tachycardia	Cough, Colds, Tachypnea, Hypoxia (60% SpO2)	N/A	N/A	Yes
Al-assaf O et al.	N/A	Bradycardia	No hypoxia (98% SpO2)	N/A	N/A	Recovered
Khalid Y et al	Fever	Tachycardia	Cough, Shortness of breath, ARDS, Tachypnea, Hypoxia (79%SpO2)	N/A	N/A	N/A
Ng My et al	N/A	Chest pain	Cough, Shortness of breath,	N/A	N/A	N/A
Inciardi et al	Fatigue, Fever	Hypotension	Cough	N/A	N/A	Recovered
Fried et al	No fever	No chest pain	No shortness of breath	N/A	N/A	Recovered
Wehit et al	Fever, Fatigue	N/A	ARDS	N/A	N/A	N/A
Radbel et al	Fever, fatigue, Septic shock	Chest pain	Cough, ARDS	N/A	Abdominal pain	Yes

Out of 22 studies, 17 articles reported the typical systemic symptoms of COVID-19 myocarditis, which included fever (77%), fatigue (41%), and myalgia (18%). Only 12 studies noted the cardiovascular complaints of the patients, such as chest pain (50%), tachycardia (25%), and hypotension (17%). Meanwhile, 21 studies discussed respiratory signs and symptoms, including shortness of breath (67%), cough (62%), acute respiratory distress syndrome (24%), hypoxia (19%), and tachypnea (14%). Out of 22 studies, only three reports examined the neurological presentation of COVID-19 myocarditis. All studies noted syncope (100%). Then, three studies documented the gastrointestinal complaints of the patients, wherein diarrhea (67%) was the most common presentation

### **Prognosis**

Out of 22 studies, only 16 articles (73%) reported mortality, while six studies (27%) did not mention any consequent prognosis. Variable outcomes were reported on COVID-19-related myocarditis with a mortality of 25% ( $n = 4$ ). Out of 16 patients, 12 of them

(75%) recovered (Table 2).

**Table 3: Laboratory findings of COVID-19-related myocarditis**

Author	Troponin Level	CRP Level	CK Level	CK-MB	NT-pro BNP	Creatinine	Ferritin	ESR	Procalcitonin	WBC count	D-Dimer
Clagici AY et al	998.1 ng/L (elevated)	9.46 mg/dl (elevated)	NA	NA	NA	NA	NA	NA	NA	NA	NA
Yokoo P et al	33ng/L (elevated)	NA	NA	NA	NA	NA	NA	NA	NA	NA	NA
Pietsch H et al	83.6 ng/L (elevated)	NA	125 U/l (elevated)	7.14ng/ml (elevated)	NA	NA	NA	NA	NA	NA	NA
Pavon AG et al	263 ng/L (elevated)	NA	NA	NA	NA	NA	NA	NA	NA	NA	1210 ng/mL (elevated)
Khatri A et al	544 ng/L (elevated)	NA	2135 U/L (elevated)	54.3 ng/mL (elevated)	NA	NA	NA	NA	NA	NA	1068 ng/mL (elevated)
Hussain H et al	290 ng/L (normal)	NA	NA	20.1 ng/mL (elevated)	1,287 pg/mL (elevated)	NA	NA	NA	NA	NA	NA
Dalen H et al	108 ng/L (elevated)	NA	NA	NA	1025 pg/ml (elevated)	NA	NA	NA	NA	NA	NA
Zengh JH	1.137 ng/L(elevated)	NA	NA	NA	22,600 pg/ml (elevated)	1.78 mg/dl (elevated)	NA	NA	NA	NA	NA
Doyen D et al	9002 ng/L (elevated)	NA	NA	NA	NA	NA	NA	NA	NA	NA	NA
Faircloth E et al	2500ng/L (elevated)	20.02 mg/dl (elevated)	NA	NA	969 pg/ml (elevated)	NA	757 ng/ml (elevated)	78 mm/hr (elevated)	NA	NA	NA
Coyle J	3576 ng/L (elevated)	8.1 mg/dl (elevated)	NA	NA	859 pg/ml (elevated)	NA	2,106 ng/ml (elevated)	NA	0.18 ng/ml (elevated)	NA	NA
Luetkens JA et al, 2020	18.8 ng/L (elevated)	1380 mg/dl (elevated)	NA	NA	Normal	NA	NA	NA	NA	Normal	NA
Jain A et al	Elevated, no values mentioned	NA	NA	NA	NA	NA	NA	NA	NA	NA	NA
Mustafa S et al.	8600 ng/L (elevated)	16 mg/dl (elevated)	NA	NA	NA	NA	NA	NA	NA	NA	NA
Mansoor A et al.	NA	27 mg/dl (elevated)	NA	NA	4639 pg/mL (elevated)	NA	928 ng/mL (elevated)	82 mm/hr (elevated)	NA	24,000/ $\mu$ L (elevated)	3455 ng/mL (elevated)
Al-assaif O et al.	NA	NA	NA	NA	NA	NA	NA	NA	NA	Not done	NA
Khalid Y et al	503 ng/L (elevated)	23.10 mg/dl (elevated)	NA	NA	35,000 pg/mL (elevated)	1.79 mg/dl (elevated)	457 ng/ml (elevated)	NA	15.20 ng/mL (elevated)	16,100/ $\mu$ L (elevated)	NA
Ng My et al	Elevated, no values mentioned	NA	NA	NA	NA	NA	NA	NA	NA	NA	NA
Ricardo M et al	240 ng/L (elevated)	1.3 mg/dl (elevated)	NA	20.3 ng/mL (elevated)	5647 pg/mL (elevated)	0.75 mg/dl (normal)	NA	NA	NA	8,900/ $\mu$ L (normal)	NA
Justin A et al	7900ng/L (elevated)	0.0054 mg/dl (elevated)	NA	NA	NA	NA	967ng/ml	NA	NA	NA	166 ng/mL (normal)
Jeanette et al	16 ng/L (elevated)	NA	NA	NA	370 pg/ml (elevated)	NA	723ng/ml	NA	NA	NA	300 ng/ml (normal)
Jared et al	10ng/L	20.08mg/dl	NA	NA	NA	0.9mg/dl (normal)	NA	NA	NA	21000/ $\mu$ L (elevated)	830 ng/ml (elevated)

Most of the studies noted an increase in troponin (86%), NT-pro BNP (91%), ferritin (80%), WBC (80%), and D-dimer (67%) levels. The median troponin level was 290 (IQR = 3,543) ng/L, median NT-pro BNP was 4,639 (IQR = 4,678) pg/mL, median ferritin level was 948 (IQR = 244) ng/ml, mean WBC count was 17,500 ( $SD = 5,710.08$ ) per  $\mu$ L, and median D-dimer level was 949 (IQR = 742) ng/mL. Meanwhile, in the studies that examined creatine, 50% noted risen levels with a mean creatinine level of 1.31 ( $SD = 0.48$ ) mg/dL. On the other hand, all studies that evaluated CRP, CK level, CK-MB, ESR and procalcitonin noted elevated laboratory findings. The median CRP level was 18.01 (IQR = 14.09) mg/dL, median CK level was 1130 (IQR = 1005) U/L, median CK-MB level was 20.1 (IQR = 11.94) ng/ml, mean ESR was 80 ( $SD = 2.83$ ) mm/hr, and median procalcitonin level was 7.69 (IQR = 7.51) ng/ml.

**Table 4: ECG findings of COVID-19 related myocarditis**

Author	Rate	Rhythm	Hypertrophy	Ischemia and Infarction	Miscellaneous
Cizgici AY et al	Tachycardia	fibrillation	NA	Concave ST elevation except for aVR lead	NA
Yokoo P et al	Normal	Normal	Normal	Normal	Normal
Pietsch H et al	NA	NA	NA	NA	NA
Pavon AG et al	NA	NA	NA	NA	NA
Khatri A et al	Tachycardia	Sinus Rhythm	NA	ST-elevation in leads II, III, aVF and ST-depression in I, aVL	NA
Hussain H et al	NA	NA	NA	Extensive and diffuse ST-segment elevation	NA
Dalen H et al	Tachycardia	Sinus Rhythm	NA	Insignificant ST-elevation in inferior leads, T-wave inversion in precordial leads.	Low-voltage ECG with peak-to-peak QRS amplitude less than 5 mm in the standard leads and 10 mm in the precordial leads (V5 and V6)
Zengh JH	Tachycardia	Sinus Rhythm	NA	No ST-segment elevation	NA
Doyen D et al	NA	NA	Left ventricular hypertrophy (LVH)	Diffuse inverted T waves in anterior leads	NA
Faircloth E et al	NA	NA	NA	Non-specific ST-changes in the anterior leads not consistent with STEMI	NA
Coyle J	Tachycardia	Sinus Rhythm	NA	No ST-T wave changes	NA
Luetkens JA et al, 2020	Normal	Normal	Normal	Normal	Normal
Jain A et al	NA	NA	NA	Inferior infarct versus left anterior fascicular block;	Myocardial infarction findings were no longer present.
Mustafa S et al.	NA	NA	NA	ST elevations in the antero-lateral distribution	NA
Mansoor A et al.	Tachycardia	Sinus Rhythm	NA	Ischemic ST changes and fusion beats	PR elevation present in aVR and PR depression in leads II and aVF consistent with myocarditis
Al-assaf O et al.	Bradycardia	Sinus Rhythm	NA	None	Repeat ECG 1 hour later showed 2:1 second-degree AV block
Khalid Y et al	Normal Rate	Sinus Rhythm	Left ventricular hypertrophy (LVH)	Normal	Short PR interval of 72 ms., and a QTc interval of 680 ms
Ng My et al	NA	NA	NA	NA	NA
Inciardi et al	Normal	Sinus Rhythm	NA	Minimal diffuse ST-segment elevation and an ST-segment depression with T-wave inversion in lead V1 and aVR	Low voltage in the limb leads
Fried et al	Tachycardia	Sinus Rhythm	NA	ST segment elevations in leads I, II, aVL, V2-V6, and PR elevation and ST depressions in aVR	Low voltage QRS complexes in the limb leads
Wehit et al	Normal	NA	NA	NA	NA
Radbel et al	Tachycardia	NA	NA	NA	NA

Tachycardia was noted in eight studies (47%). In terms of rhythm, normal sinus rhythm was noted in nine studies (75%) and atrial fibrillation in one study (8%). The ECG reports also revealed left ventricular hypertrophy (50%). The findings also noted alterations in the ST segments (41%) and T wave inversion (18%) (Figure 6). All in all, these electrocardiogram findings vary pretty broadly.

**Table 5:** *Echocardiogram findings of COVID-19 related myocarditis*

Author	Ejection Fraction	Structure	Pericardial Effusion
Cizgici AY et al	NA	NA	NA
Yokoo P et al	45% to 35% (reduced)	Normal	NA
Pietsch H et al	Normal	Severe diastolic dysfunction III with an increased wall thickness (interventricular septum, 14 mm)	Positive
Pavon AG et al	47% (reduced)	Normal	NA
Khatri A et al	NA	Severe global LV systolic dysfunction, RV enlargement, RV systolic dysfunction. Tamponade	Positive
Hussain H et al	20% (reduced)	Enlarged heart with a marked decrease in ventricular systolic function.	NA
Dalen H et al	NA	LV hypertrophy, hyperechogenic pattern of the endocardium and epicardium, tamponade	Positive
Zengh JH	32% (reduced)	Enlarged heart with a marked decrease in ventricular systolic function.	Negative
Doyen D et al	Normal	Wall motion was within normal limits. Mild LVH	NA
Faircloth E et al	35% to 40% (reduced)	Moderate diffuse hypokinesis with relative apical sparing.	Negative
Coyle J	25% (reduced)	Global hypokinesis with regional variation	NA
Luetkens JA et al, 2020	Normal	Normal	NA
Jain A et al	<30% (reduced)	Akinesis of the mid to apical myocardial segments, Normal ventricular function on day 10.	NA
Mustafa S et al.	NA	NA	NA
Mansoor A et al.	NA	Mildly reduced left ventricular dysfunction	NA
Al-assaf O et al.	NA	Mildly dilated ascending aorta	NA
Khalid Y et al	25-30% (reduced)	Severely decreased LV systolic function with segmental wall motion abnormalities, akinesis of the distal segments of the left ventricle and mid and distal portions of the right ventricle	NA
Ng My et al	NA	NA	NA
Inciardi et al	40% (reduced)	Normal left ventricular (LV) dimensions with an increased wall thickness and a diffuse echo-bright appearance of the myocardium	Positive
Fried et al	30% (reduced)	Severe concentric left ventricular hypertrophy, and a dilated, severely hypokinetic right ventricle	Positive
Wehit et al	NA	NA	NA
Radbel et al	NA	NA	NA

The majority of studies (77%) observed a reduced left ventricular ejection fraction (LVEF). The mean LVEF was 33% ( $SD = 8.35$ ). Out of the 17 studies, there were also significant abnormalities in the left ventricle in six studies (34%) and right ventricle in two studies (12%). Pericardial effusion was noted in 5 studies, but most studies had no mention of this.

**Table 6:** *Imaging findings of COVID-19 related myocarditis*



Author	Coronary Angiography	Chest CT	Chest x-ray
Cizgici AY et al	Negative for CAD	Ground glass changes	N/A
Yokoo P et al	N/A	Ground glass changes	N/A
Pietsch H et al	N/A	N/A	N/A
Pavon AG et al	N/A	N/A	N/A
Khatri A et al	Negative for CAD	Ground glass changes	N/A
Hussain H et al	Negative for CAD	Ground glass changes	Bilateral interstitial opacities
Dalen H et al	Negative for CAD	Ground glass changes	Bilateral pleural effusion
Zengh JH	N/A	N/A	Bilateral pleural effusion
Doyen D et al	N/A	Ground glass changes	Ground glass changes
Faircloth E et al	Negative CAD	Ground glass changes	N/A
Coyle J	N/A	N/A	Bilateral interstitial opacities
Luetkens JA et al, 2020	N/A	Bilateral interstitial opacities	Bilateral interstitial opacities
Jain A et al	N/A	Ground glass changes	Normal
Mustafa S et al.	N/A	N/A	Bilateral interstitial opacities
Mansoor A et al.	N/A	N/A	Bilateral interstitial opacities
Al-assaf O et al.	Positive for CAD	N/A	Normal
Khalid Y et al	N/A	N/A	Bilateral interstitial opacities
Ng My et al	N/A	N/A	N/A
Inciardi et al	Negative for CAD	N/A	Normal
Fried et al	Negative for CAD	N/A	Normal
Wehit et al	N/A	N/A	Right basal opacities
Radbel et al	N/A	Bilateral nodular opacities	N/A

In terms of the coronary angiography results, only 1 study found a significant coronary artery disease, while of the ten studies, 8 (80%) had a chest CT noted with ground-glass changes, and 2 (20%) was noted with bilateral opacities. Similarly, in 14 studies with chest x-ray findings, 6 (43%) were noted with bilateral interstitial opacities, 2 (14%) with bilateral basal opacities, and 2 (14%) with bilateral pleural effusion.

**Table 7:** *CMR and myocardial biopsy findings*

Author	CMR	Myocardial biopsy	Possible or Confirmed Case
Cizgici AY et al	NA	NA	suspected
Yokoo P et al	Late enhancement areas with an ischemic pattern on the left ventricle base septum wall, with diffuse hypokinesia, and global systolic function	NA	Confirmed
Pietsch H et al	NA	EMB: Intramyocardial inflammation with absence of signs of necrosis. Increased no. of CD45RO+ T memory cells (96.15 cells/mm <sup>2</sup> ), CD3+ cells (20.54 cells/mm <sup>2</sup> ), CD11a+ cells (24.36 cells/mm <sup>2</sup> ), CD11b+ cells (91.56 cells/mm <sup>2</sup> ), and CD54+ cells (area fraction 1.91%), histology: hypertrophied myocytes (diameter 31 μm)	Confirmed
Pavon AG et al	Reduced left-ventricular (LV) systolic function ( 42%), mild hypokinesia of the lateral wall. T2-mapping sequences showed myocardial edema (segmental T2 = 55-57 ms)	NA	Confirmed
Khatiri A et al	NA	NA	suspected
Hussain H et al	NA	NA	suspected
Dalen H et al	Acute perimyocarditis, moderate enhancement in the anterolateral wall	NA	Confirmed
Zeng JH	NA	NA	suspected
Doyen D et al	Subepicardial late gadolinium enhancement of the apex and inferolateral wall	No significant findings	Confirmed
Faircloth E et al	NA	NA	suspected
Coyle J	NA	NA	suspected
Luetkens JA et al, 2020	Normal LV size, mild systolic dysfunction (LV EF: 49%) with discrete hypokinesia, and pericardial effusion around the LV wall (+ 10 mm), diffuse interstitial myocardial edema with increased T2 signal, diffuse myocardial inflammation.	NA	Confirmed
Jain A et al	NA	NA	suspected
Mustafa S et al.	NA	NA	suspected
Mansoor A et al.	NA	NA	suspected
Al-assaf O et al.	Edema of the interventricular septum indicative of myocarditis	NA	Confirmed
Khalid Y et al	NA	NA	suspected
Ng My et al	Non-ischemic LGE with elevated global T2-mapping values (57-62 ms)	NA	suspected
Inciardi et al	Increased wall thickness with diffuse biventricular apical hypokinesia, severe LV dysfunction (LVEF of 35%) , Short tau inversion recovery and T2-mapping sequences showed marked biventricular myocardial interstitial edema.	NA	Confirmed
Fried et al	NA	NA	suspected
Wehit et al	NA	NA	suspected
Radbel et al	NA	NA	suspected

The CMR and myocardial biopsy results were used to identify possible and confirmed cases of COVID-19-related myocarditis. Out of 22 studies, eight studies performed CMR, and only two were able to provide histopathological findings through EMB. Eight were confirmed cases (36%), and the rest were suspected cases.

