

1 Title: Neuromotor Prosthetic to Treat Stroke-Related Paresis

2
3 Authors: Mijail D. Serruya^{1*}, Alessandro Napoli¹, Nicholas Satterthwaite¹, Joseph Kardine, Jr², Joseph McCoy²,
4 Namrata Grampurohit³, Kiran Talekar⁴, Devon Middleton⁴, Feroze Mohamed⁴, Michael Kogan⁵, Ashwini Sharan⁵,
5 Chengyuan Wu⁵, Robert Rosenwasser⁵

6
7 ¹ Department of Neurology, Thomas Jefferson University, Philadelphia, PA 19107

8 * Corresponding author: Mijail.Serruya@jefferson.edu

9 ² Jefferson Rehabilitation (Outpatient), Thomas Jefferson University Hospital, Philadelphia, PA 19107

10 ³ College of Rehabilitation Science, Thomas Jefferson University, Philadelphia, PA 19107

11 ⁴ Department of Radiology, Thomas Jefferson University, Philadelphia, PA 19107

12 ⁵ Department of Neurosurgery, Thomas Jefferson University, Philadelphia, PA 19107

13
14 ABSTRACT

15
16 Background

17 Functional recovery of independent arm movement typically plateaus within six months following a stroke, leaving
18 chronic motor deficits. This feasibility study tested whether a wearable, powered exoskeletal orthosis, driven by a
19 percutaneous, implanted brain-computer interface (BCI), using the ensemble activity of individual neurons in the
20 precentral gyrus in the affected cortical hemisphere, could restore voluntary upper extremity function in a person
21 with chronic hemiparetic subsequent to a cerebral hemispheric stroke involving subcortical gray and white matter
22 and cortical gray matter .

23
24 Methods

25 One chronic hemiparetic stroke survivor with moderate-to-severe upper-limb motor impairment used a powered
26 wearable elbow-wrist-hand orthosis that opened and closed the affected hand using cortical activity, recorded from
27 four 64-channel microelectrode arrays implanted in the ipsilesional precentral gyrus, based on decoding of neural
28 spiking (discriminated single- and multi-unit) patterns and high frequency local field potentials generated by
29 imagined hand movements using technology and decoding methods used for people with other causes of paralysis.
30 The system was evaluated in a home setting daily for 12 weeks. Motor function was evaluated before, during, and
31 after the treatment.

32
33 Results

34 Robust single unit activity, modulating with attempted or imagined movement, was present throughout the
35 precentral gyrus areas implanted for the duration of the study. Although abnormal neural oscillations, that appeared
36 to correlate with contralateral spasticity, were present, the participant was able to acquire voluntary control over a
37 hand-orthosis BCI based upon ensemble single unit activity and high frequency local field potential power. The
38 study participant (C2) was able to achieve a maximum score of 10 points on the Action Research Arm Test (ARAT)
39 while using the BCI system as compared to 0 without any device, and 5 using only myoelectric control (where 0
40 indicates no functional abilities an upper extremity and 53 indicates full, normal healthy function). Orthosis-
41 powered hand-opening was faster with BCI-based control as compared to myoelectric control, on a standardized
42 object-movement task, possibly due to the fact that BCI-control could be deployed without triggering abnormal
43 spasticity inevitably reinforced by myoelectric control.

44
45 Conclusions

46 The findings demonstrate the therapeutic potential to use an implantable BCI system coupled to a limb exoskeleton
47 to be used to promote and assess neurally driven rehabilitation of limb function. This targeting the affected
48 hemisphere, to “electrically bypass” the stroke, in this n-of-1 pilot study. The participant’s ability to rapidly acquire
49 voluntary control over otherwise paralyzed hand opening, more than 18 months after a subcortical stroke, lays the
50 foundation for a fully implanted movement restoration system that could restore independent arm function to stroke
51 survivors.

52
53 INTRODUCTION

54
55 Stroke is a leading cause of disability ¹ with a global prevalence of over 42 million people in 2015 ², affecting over
56 four million adults in the United States alone with 800,000 new cases per year ³. Stroke leads to permanent motor

57 disabilities in 80% of cases ⁴, and half of stroke survivors require long term care. Brain computer interface (BCI)
58 technologies offer a potential solution to restore functional independence and improve health in people living with
59 its effects. In the past decade, intracortical BCI technology has continued to advance, with multiple groups
60 demonstrating the safety and efficacy of this approach to derive control signals ⁵⁻⁷ to restore communication and
61 control. In parallel, wearable robotic orthosis technology has evolved into FDA-cleared devices bringing concrete
62 benefits to patients with weakened limbs ^{8,9}, as a therapeutic intervention, to promote recovery. This single-patient
63 pilot clinical trial sought to provide proof of concept that a commercially available powered arm orthosis could be
64 linked to the cerebral cortex in an adult with the most common form of chronic stroke. A direct path from the brain's
65 motor centers to the orthotic could both reanimate a paralyzed limb to enable useful hand and arm function and
66 potentially provide a new, neurally driven rehabilitation tool.

67
68 Several signal sources have been coopted to provide commands to move paralyzed limbs. Electromyographic
69 (EMG) control of a powered orthosis or functional electrical stimulation (FES) of muscles, has proven problematic
70 either because users could not generate sufficient or reliable activity to provide a good control signal, or because
71 voluntary activation of those recorded muscles (that were intended to generate the command) was opposed by the
72 stimulator's effects ¹⁰. Contralaterally controlled electrical stimulation- where activity from the unaffected arm
73 triggers stimulation on the paretic arm- is a useful therapeutic intervention to improve function in the weaker limb¹¹
74 but it is not clear how this unnatural command source could be generalized to continuously-worn devices that enable
75 independent arm movements. Several groups have explored scalp EEG, which is closer to the command's origins, to
76 derive control signals to drive robotic braces, and in one case, FES ^{8,12-14}. While using EEG-derived signals may be
77 promising for rehabilitation therapy, it would not be feasible for daily independent function. Scalp EEG requires
78 careful electrode positioning by a trained technician, while skin sweat and hair can cause impedances to fluctuate,
79 thus compromising signal quality. Daily application of even a subset of contacts to the same skin sites can lead to
80 skin breakdown and clinically worrisome cellulitis. Further, EEG signals are limited in the richness of commands
81 that can be easily and reliably derived from the available signal. By contrast, intracortical interfaces offer a rich
82 sources of high resolution, multidimensional control signals, since it is the origin of such signals in healthy adults,
83 in non-human primates and in people with spinal or brainstem disorders ^{7,15,16}.

84
85 While the vast majority of strokes involve cerebral white matter and even direct parenchymal damage. Notably,
86 intracortical neuromotor prosthetics have not been tested in people with strokes above the mesencephalon. It is not
87 known whether motor cortex remains a reliable signal source in this large population. If you used siA proof-of-
88 concept that a brain-computer interface, based on microelectrode arrays (MEAs) implanted in intact cortex above a
89 subcortical stroke, could restore behaviorally useful independent, voluntary movement, could lead to the development
90 of a fully implantable medical device that, in principle, could reverse the motor deficits caused by stroke, and
91 ultimately other lesional diseases such as tumors, multiple sclerosis, and arteriovenous malformations near or in the
92 cortex. This approach of using adjacent healthy cortex could also be expanded to restore non-motor functions,
93 including language, memory, perception and executive function.

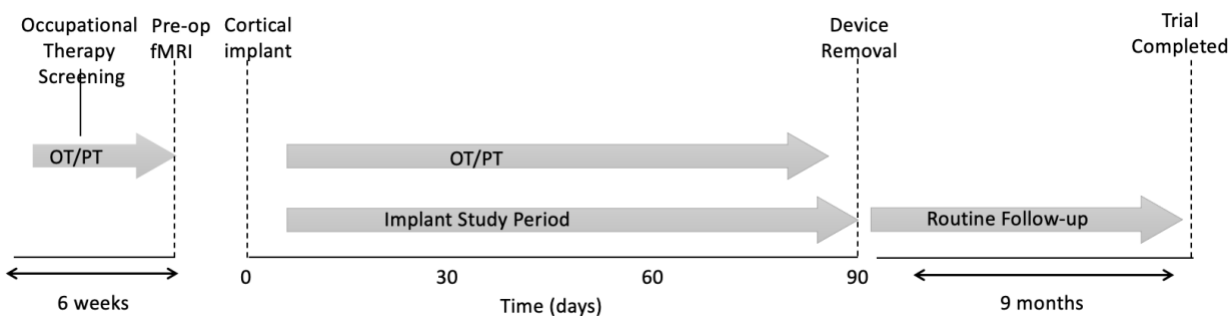
94

95 METHODS

96

97 Approval for this study was granted by the US Food and Drug Administration (Investigational Device Exemption)
98 and the Thomas Jefferson University Institutional Review Board. The participant described in this report has provided
99 permission for photographs, videos and portions of his protected health information to be published for scientific and
100 educational purposes. After completion of informed consent, medical and surgical screening procedures, two
101 MultiPorts (Blackrock Microsystems, UT), each comprising two 8x8 platinum tipped microelectrode arrays tethered
102 to a titanium pedestal connector, were implanted into the cortex of the precentral gyrus using a pneumatic insertion
103 technique^{17,18}. Details of the human surgical procedure are in preparation for publication, but it followed procedures
104 used in other studies of similar technology (REFS?). Trial selection criteria are available online for this trial (see
105 Clinicaltrials.gov, number NCT03913286). The trial was designed with the implantation phase to last a maximum of
106 three months (Fig. 1). Approval for this study was granted by the US Food and Drug Administration (Investigational
107 Device Exemption) and the Thomas Jefferson University Institutional Review Board. The participant described in this
108 report has provided permission for photographs, videos and portions of his protected health information to be
109 published for scientific and educational purposes. After completion of informed consent, medical and surgical
110 screening procedures, two MultiPorts (Blackrock Microsystems, UT), each comprising two 8x8 microelectrode arrays
111 tethered to a titanium pedestal connector, were implanted into the cortex of the precentral gyrus using a pneumatic

112 insertion technique¹⁷¹⁸. Details of the human surgical procedure are in preparation for publication. Selection criteria
113 are available online (see [Clinicaltrials.gov](https://clinicaltrials.gov), number NCT03913286). The trial was designed with the implantation
114 phase to last a maximum of three months (Fig. 1).
115



116
117 **Figure 1. The clinical trial timeline.**
118

119 *Participant.* The participant (ID number C2) was a right-handed male who experienced right hemispheric stroke,
120 manifest as acute onset dense left hemiparesis and expressive aphasia, at which time he was age between ages 35 to
121 40. Due to unknown time of onset and hypertension at presentation, the participant was not a candidate for
122 thrombolysis. CT angiogram showed occlusion of the right posterior cerebral artery and high-grade stenosis of the
123 left posterior cerebral artery in the proximal P2 segment. MRI of the brain showed acute infarcts in the right basal
124 ganglia/corona radiata and right occipital lobe. He was started on dual antiplatelet therapy for 3 weeks and then was
125 transitioned to aspirin 81 mg once daily, along with atorvastatin and anti-hypertensives. He had left-sided
126 hemiparesis, dysphagia, left homonymous hemianopsia and dense left visual neglect and was transferred to rehab
127 hospital for supervised therapies. He subsequently underwent two months of intensive inpatient rehabilitation and
128 aphasia and dysphagia resolved; over a period of three months, he acquired the ability to ambulate independently,
129 albeit with a persistent left foot drop. Neuroimaging showed evidence of multi-focal strokes, and prior silent strokes.
130 The participant had previously been in good health and did not have any known stroke risk factors such as diabetes
131 or smoking. There was a history of loud snoring and the participant had not been evaluated for obstructive sleep
132 apnea. Transthoracic and transesophageal echocardiography were normal as were serial hypercoagulability panels;
133 the participant was adopted and the biological family history unknown. The participant was deemed to have had
134 embolic strokes of unknown source (ESUS). Although serial electrocardiography since the stroke was normal, the
135 participant is being scheduled for a loop recorder to survey for possible paroxysmal atrial fibrillation. The
136 participant had learning disabilities and was presumed to have had mild cognitive impairment prior to the stroke.
137 Screening formal neuropsychological testing identified significant neurocognitive problems (full scale IQ 59) and
138 also concluded that the participant remained fully capable to provide proper informed consent and to participate in
139 this trial, meeting its demands and requirements. The participant provided both verbal and written informed consent,
140 both to participate in the trial and to share his identifying information with the public. He had been working full time
141 at the time of the stroke and has been unable to return to work since the stroke.
142

143 *Pre-operative fMRI.* The participant underwent MRI on a 3T Philips Ingenia MRI scanner (Amsterdam, The
144 Netherlands). A 1mm isotropic 3-D T2 FLAIR was obtained for structural localization. A single-shot echoplanar
145 gradient echo imaging (EPI) sequence with 80 volumes, repetition time (TR) = 2 s, echo time (TE) = 25 msec, voxel
146 size = 3 x 3 mm², slice thickness = 3mm, axial slices = 37. *Motor Task:* The participant was asked to visualize
147 movements of his paretic left hand during the MRI. Each motor trial consisted of a block design featuring a 20 s rest
148 block and a 20 s active block repeated. This block design was repeated between 4-6 times for a total of 160-240 s
149 scans. Visual stimulus comprised a 20 s video depicting two 3D modeled limbs at rest, followed by a 20 s video of
150 the limb(s) performing the desired motor task. Motor tasks were designated “hand” (repeated hand open/clench) and
151 “arm” (repeated arm extension elbow), and classified as “active” (participant performed or attempted to perform the
152 motion) or “passive” (physician manually moved participant’s hand/arm). Hand motor was performed as bilateral-
153 active, paretic-active, and paretic-passive. Arm motor was performed as paretic-active and paretic-passive. In active
154 tasks, the participant was instructed to follow the movements in the video or concentrate on following in the case of
155 the paretic limb. Task choice and prioritization was based on pre-exam training and examination of participant’s
156 capabilities and examination of BOLD activation observed during the scan. For example, a breath-hold challenge was

157 employed after the first couple of tasks failed to show desired activation with an attempt to improve cerebrovascular
158 reactivity. BOLD activation subsequently became apparent. Post processing of the BOLD data including motion
159 correction, smoothing, and general linear model (GLM) estimation was performed using SPM software
160 (www.fil.ion.ucl.ac.uk/spm) as well as Nordic brain EX software (NordicNeuroLab, Bergen, Norway). After BOLD
161 post-processing, generated statistical maps were overlaid on the 3D T2 FLAIR image for visualization of activation.

162
163

164 *Cortimo system.* ‘Cortimo’ is the designation
165 provided to the FDA to represent the overall
166 system (Fig. 2) that comprised two percutaneous
167 Multiports (Blackrock Microsystems, Inc), each
168 in turn having two multi-electrode array sensors,
169 the cabling, amplifiers, software and the powered
170 MyoPro orthosis (described subsequently). Each
171 sensor is an 8x8 array of silicon microelectrodes
172 that protrude 1.5 mm from a 3.3 x 3.3-mm
173 platform. At manufacture, electrodes had an
174 impedance ranging between 70 KOhm and 340
175 KOhm. The array was implanted onto the surface
176 of the MI arm/hand region guided by the pre-
177 operative fMRI; with electrodes penetrating into
178 the cortex to attempt to record neurons in layer V.
179 Recorded electrical signals pass externally
180 through a Ti percutaneous connector, which was
181 secured to the skull. Cabling attached to the
182 connector during recording sessions routes

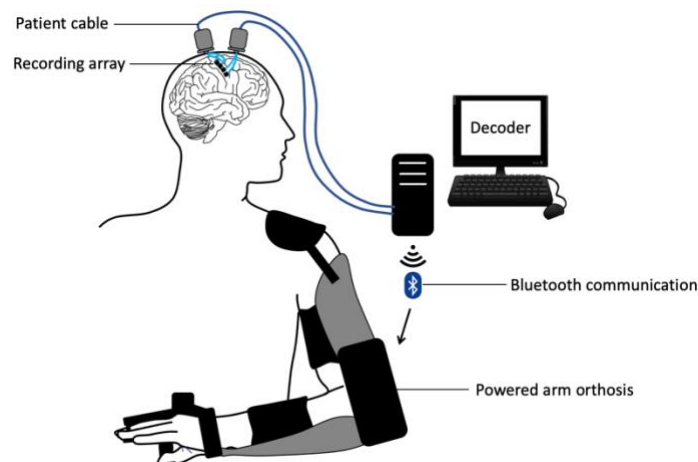


Figure 2. The Cortimo system. The overall device comprises two Multiports, each with two 8x8 microelectrode arrays, patient cables linked to external amplifiers, a decoding computer and a wearable, powered arm orthosis.

183 signals to external amplifiers and then to a series of computers in a cart that process the signals and convert them into
184 different outputs, such as servo motor position of the MyoPro brace or screen position of a neural cursor that can be
185 viewed by the participant on a computer monitor. Currently, this system must be set up and managed by an experienced
186 technician.

187

188 *MyoPro brace.* The MyoPro (Myomo, Inc, Cambridge, MA) is an FDA-cleared myoelectric powered arm orthosis
189 designed to support a paretic arm ⁹. The rigid brace incorporates metal contacts attached to soft straps that can be
190 adjusted such that contacts rest on the biceps and triceps proximally, and on wrist flexors and extensors distally, on
191 the paretic upper extremity. The sensors continuously record the root mean square of underlying muscle activity.
192 Thresholds are manually set using software such that signals exceeding them will trigger one of the MyoPro motors.
193 Because the participant retained residual elbow flexion and extension strength, the motor at the elbow was set up such
194 that biceps activation triggered elbow flexion and triceps activation triggered elbow extension. For hand opening, the
195 MyoPro was set up to either use myoelectric control, or to use BCI-based control. Since the participant was unable to
196 voluntarily extend the wrist or open the fingers, the myoelectric mode was set up such that the default state was with
197 the hand open, and it would only be closed by activating enough wrist flexor activity.

198

199 *Recording sessions.* Research sessions were scheduled five days per week at a temporary residence, adjacent to the
200 hospital, provided to the participant. Sessions could be cancelled (for example, due to participant request or schedule
201 conflict) or ended early at the participant's request. Sessions would commence with neural recording and spike
202 discrimination. While initial sessions included filter building and structured clinical end-point (cursor control) trials,
203 in the final month of the trial, “training-less” algorithms were used with the participant proceeding directly to BCI-
204 controlled hand action as soon as the patient cables were connected. Performance of computer tasks, orthosis control
205 and occupational therapy exercises followed. The electrodes and neural signals selected immediately before filter
206 building remained constant for any given session's orthosis control trials.

207 *Spike discrimination.* Units were extracted using an automatic thresholding approach based for each electrode channel,
208 based on Root Mean Squared multipliers¹⁶. We did not perform any type of spike sorting and applied no objective
209 criteria to determine whether any particular unit recorded on one day was the same as that recorded on a subsequent
210 day.

211 *Spike discrimination.* Units were extracted using an automatic thresholding approach based on Root Mean Squared
212 multipliers¹⁶. We did not perform any type of spike sorting and applied no objective criteria to determine whether any
213 particular unit (or admixture of units) recorded on one day was the same as that recorded on a subsequent day. Smaller
214 amplitude signals likely comprised a combination of spikes from multiple neurons.

215 *Decoder Filter Building.* For each session, single and multiunit data or high frequency (100-1000 Hz) local field
216 potentials derived from multiple channels (20-30) were used to create a linear filter to convert these real-time
217 multidimensional neural features into either a one or a two-dimensional (position or velocity) output signal. During
218 the course of the trial, a variety of motor activity and motor imagery approaches were tested for filter building,
219 including imagining opening and closing the paretic hand, passively flexing and extending the elbow, passively
220 opening and closing the hand, and simply observing a computer cursor displayed on a monitor moving up and down
221 without any specific instruction. Training data for building the linear filter were collected with the participant gazing
222 at a screen where a target cursor was moved slowly up and down for one minute (5 seconds to go from the top to the
223 bottom of the screen or vice versa, at 20° visual angle). After this preliminary filter was built, a new 1-minute re-
224 training session was performed, this time the manually controlled target cursor was accompanied by a prediction
225 cursor that was neurally controlled by the participant. Using this additional training set, a second filter was built and
226 then tested on a simple target acquisition game in which the y-position of the predicted output was discretized into
227 zones such that positions on the upper part of the screen would cause an animation sprite to move up by a fixed
228 distance (1 cm), and positions on the lower part of the screen would cause the sprite to move down by the same fixed
229 distance.

230 BCI MyoPro use. This discrete output was then used to control the aperture of the hand via the MyoPro's hand brace
231 motor. The up-down mapping on the screen was translated into closed-open positions of the hand. The participant
232 then performed a series of functional tasks including grasping and then dropping an object, the Action Research Arm
233 Test¹⁹, and a variation on Jebsen Taylor item moving test²⁰. These were tested with both the participant seated and
234 standing.

235 *BCI Orthosis use.* The discrete output was then used to control the aperture of the hand via the MyoPro's hand brace
236 motor. The up-down mapping on the screen was translated into closed-open positions of the hand. The participant
237 then performed a series of functional tasks including grasping and then dropping an object, the Action Research Arm
238 Test¹⁹, and a variation on Jebsen Taylor item moving test²⁰. These were tested with both the participant seated and
239 standing.

240 *"Training-less" Mapping.* During certain sessions, the participant was able to effortlessly adapt the continuous cursor
241 control on to hand open-close control. During other sessions, however, the participant could not achieve this 'efferent
242 remapping,' and would attempt to overpower the orthosis motors with residual finger flexion strength. A novel
243 'training-less' approach was deployed in which a rolling 1-second baseline of the LFPs signals from the most
244 neuromodulated 20 channels was used to calculate spectral power in the high gamma band (100-500 Hz). Namely, 1-
245 second long LFP continuous voltages were used for computing the average spectral density estimation in the frequency
246 band 100-500 Hz, using non-overlapping frequency bins with a 50Hz width. Spectral density was computed using the
247 Matlab built-in periodogram method. Spectral values were updated every 500 ms, using 1-second-long rolling
248 windows with 50% overlap. Finally, these real-time spectral features derived from the 20 most neuromodulated
249 channels were averaged across channels to produce a single high gamma band value for each 500 ms software update.
250 Orthosis hand-closure would be triggered by an increase in this mean spectral power from the resting baseline ranging
251 between 0.5 and 3 V²/Hz to values greater than 10 V²/Hz, where real-time values above this threshold would make
252 the hand motor close.

253 *Concomitant Occupational and Physical Therapy.* Since being discharged from acute rehabilitation 60 days after the
254 initial stroke, the participant enrolled in outpatient physical and occupational therapy. Prior to the device implantation,
255 the participant completed a six-week course of occupational therapy (two to three sessions per week) intended to be a
256 screening phase to assess the participant's ability to wear and use the MyoPro device with myoelectric control and
257 follow complex instructions. Following device implantation, the participant continued occupational therapy, twice per
258 week, and physical therapy, once per week. Occupational therapy focused on postural training while seated and
259 walking, donning and doffing the MyoPro, and using the MyoPro for functional activities. Timed functional electrical
260 stimulation (e.g., pincer grasp programs; XCite, from Restorative Therapies, Inc, Baltimore, MD) and vibration
261 therapy were used for spasticity management both pre- and post-operatively. Physical therapy exercises included
262 scapular mobilization, progressive range of motion, weight bearing, forced use with game-related activities to
263 encourage left UE volitional control, aerobic endurance exercise. Broadly, the therapeutic goal was to encourage
264 volitional control outside of the abnormal synergistic patterns while varying postural stability.
265

266 RESULTS

267

268 The participant underwent intracortical implantation in autumn of 2020 and explantation three months later on January
269 2021, in accordance with the intended 3-month duration of the trial. Over the course of the study, the participant had
270 three minor, and one serious, device-related adverse events, all of which were treated, resolved, and reported to the
271 governing regulatory bodies. The serious adverse event was the development of a scalp infection at the left pedestal
272 site one week prior to the device removal date, despite a regimen of topical antibiotics and regular cleaning. This
273 infection was anticipated and was described as a potential risk in the informed consent form and consent interview.
274 The left pedestal site had posed a challenge since the time of the initial surgery as it was not possible to exactly re-
275 approximate the skin flap leaving the base of the pedestal exposed. This area was protected and eventually granulated
276 and grew new skin. The participant was afebrile and asymptomatic, and the infection was detected only by close visual
277 inspection. The participant was treated with twice daily amoxicillin/clavulanic acid for the 7 days prior to the device
278 removal. Pedestal site skin cultures taken at device removal revealed pansensitive *staphylococcus lugdunensis* and
279 *staphylococcus capitis*, and yeast, and appropriate antimicrobial treatment was provided. No organisms grew from
280 cultures taken of the bone adjacent to the pedestals. The only macroscopic evidence of infection at device removal
281 was a small area (~ 2 cm³) of erythema and friable tissue at the skin adjacent to the right pedestal. The participant was
282 discharged home. The participant remains in the Cortimo trial both for ongoing neurosurgical follow-up and
283 surveillance, and to track any further performance improvements in myoelectric MyoPro use with ongoing outpatient
284 occupational therapy.

285

286 *Preoperative anatomic and functional neuroimaging.* Preoperative imaging revealed
287 the old infarct in right lentiform nucleus and adjacent white matter including corona radiata
288 and adjacent white matter including corona radiata and a portion of the posterior limb of the
289 internal capsule, along with a large old right PCA infarct, progressed since the acute stroke
290 imaging MRI from 2019 (Fig. 3). In addition,
291 a small region of bandlike signal abnormality
292 involving subcortical white matter and medial
293 aspect of hand knob region of right precentral
294 gyrus was identified, likely reflecting
295 retrograde neuronal degeneration, (which
296 influenced the clinical decision for the implant
297 placement). On DTI, there was extensive loss
298 of fractional anisotropy in the region of right
299 corticospinal tract from old infarct. The

300 "imagined" left hand motor paradigm and
301 passive elbow/forearm motor paradigm were
302 diagnostic with good concordance.
303 Subsequent to hypercapnia challenge, a
304 marked BOLD signal was evident at the
305 precentral gyrus. The brief breath-holding
306 presumably allowed relatively increased
307 carbon dioxide retention (relative respiratory
308 acidosis) that in turn induced mild cerebral
309 vasodilatation facilitating BOLD signal
310 acquisition (in this subject with underlying
311 vascular abnormality as a cause of his multiple
312 strokes). On the "imagined" left hand motor paradigm, activation was noted in the expected location along central
313 sulcus involving lateral aspect of the hand knob region of the precentral gyrus and the adjacent portion of postcentral
314 gyrus (Fig. 3c). On the passive left elbow/forearm motor paradigm, activation was seen along central sulcus which
315 shows good concordance with the "imagined" motor task as discussed with a slightly more posterior and superior
316 extension of activation reflecting the prominent sensory component of this passive motor paradigm. A 3D brain model
317
318
319

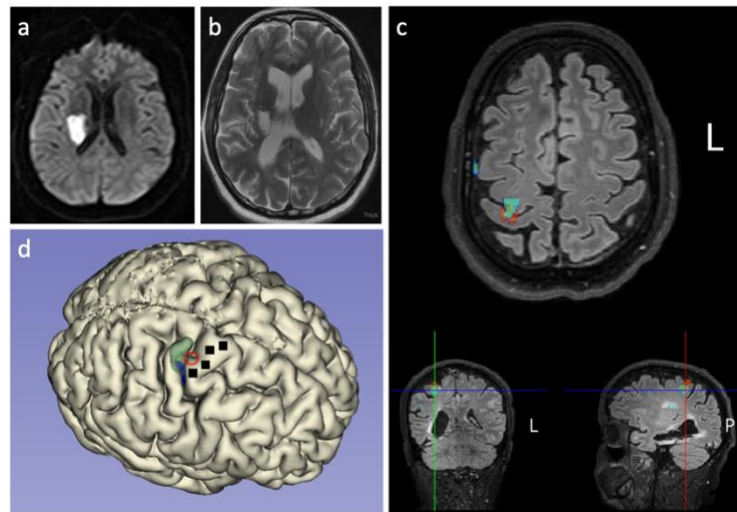


Figure 3. Neuroimaging results. Diffusion sequence from MRI scan on January 19, 2019 when the acute stroke occurred; diffusion restriction is evident in the right lentiform nucleus and adjacent white matter (a). T2-weighted MRI from January 22, 2021, shows areas of encephalomalacia and relative ventriculomegaly that have developed since the stroke (b). Functional neuroimaging revealed a hot spot of activation, indicated by a red circle, in the depth of the central sulcus along the 'hand knob' area of the precentral gyrus (c). A three-dimensional reconstruction of the participant's cortical surface derived from the MRI with the imagined left hand movement centroid of activity indicated by the red circle (d). The green shading indicates an area responsive to sensory stimulation of the left hand. The black squares indicate the location of the four microelectrode arrays.

320 was printed using the 3D FLAIR sequence to allow for 3D visualization of the surgical field for more accurate pre-
321 operative planning (Fig. 3d).

322

323 *Neural recordings.* Well-delineated single units were recorded from 87 of the 256
324 channels (Fig. 4). Neural activity correlated with actual and attempted movements
325 in both the paretic left arm in addition to the intact right arm. The multi-electrode
326 arrays that were recorded via the right pedestal connector were more lateral and
327 posterior along the precentral gyrus and were closer to the centroid of fMRI
328 imagined movement activation (Fig. 3c) and closer in absolute terms to the
329 subcortical stroke. Although all four arrays were closely spaced along the
330 precentral gyrus, cross-array discharge properties appeared to vary amongst them
331 (Fig. 5). The discharge rate of various units appeared to correlate with specific
332 residual actions, including the wrist extension that gradually developed in the
333 course of the three-month duration (Fig. 6). By taking the spike counts recorded
334 at each channel every 200 milliseconds and running them through a leaky
335 integrator²¹, and then summing these leaky integrator outputs across all channels,
336 we were able to visualize the cumulative cross-array firing rate activity in
337 comparison to forearm electromyographic activity (Fig. 7). Of the 256 electrodes,
338 in each session, we identified 20 to 40 channels that were eventually used for neural decoding. These channels were
339 used for extraction of neural features (whether threshold crossing or spectral high-frequency power) that coded for
340 hand and elbow flexion and extension. Two main decoding approaches were used: 1) A discrete two-class (hand
341 opening/closing) classifier based on a 1-dimensional linear filter continuous output; 2) a “training-less” threshold
342 crossing approach with a rolling baseline normalization, used to control hand closing or opening.

343

344 *Orthosis control.* The left upper extremity score on the
345 Action Research Arm Test (ARAT)¹⁹¹⁹ was 0 without the
346 orthosis on, 5 using the orthosis under myoelectric control,
347 and 10 using the orthosis under direct brain-control. In one
348 component of the Jebsen-Taylor standardized test of hand
349 function²²²², the goal is to pick up and move 5 cans, one at
350 a time, a few inches away forward on the table (normal
351 times are 3.23 seconds for empty soup cans in substest 6,
352 and 3.30 seconds for full cans in substest 7). Because the
353 design of the hand orthosis precluded the ability to grasp a
354 soup can (i.e., the brace only supports the thumb and next
355 two digits such that not all digits can be used for grasp and
356 the fourth and fifth digit, since they remain tightly flexed,
357 in fact physically block the can), the participant performed
358 variations on the test. It took the participant 146 seconds to
359 pick up, move and release 5 pill bottles using myoelectric
360 control, and 95 seconds to perform the identical task under
361 BCI control. Another task was to hold an object in the right
362 hand (e.g., a stress ball or a whiteboard eraser) and place it
363 into the paretic left hand, and then extend the left arm down
364 towards the floor and drop the object into a bin; this
365 process was then repeated 5 times in a row. Both these
366 tasks were performed with the participant seated. On two
367 trials of this pick-up-and-drop-5 in myoelectric mode, the
368 participant’s completion times were 128 and 222 sec/trial?;
369 seconds; on five trials of the same task in BCI mode, times
370 were 81, 106, 137, 214 seconds. In addition to measuring
371 the total time to perform these grasp-move-release tasks,
372 we also quantified the time it took to release an object once the hand was in the target position. Hand release times
373 were faster under BCI control than myoelectric control ($p=0.04$, two-sample t-test).

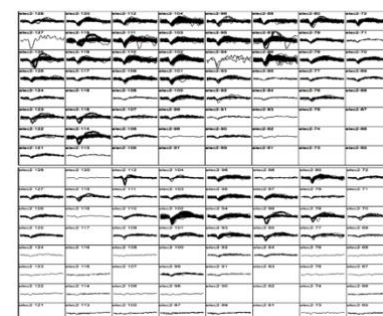


Figure 4. Action potential waveforms. Snapshot of action potential waveforms recorded from two of the arrays.

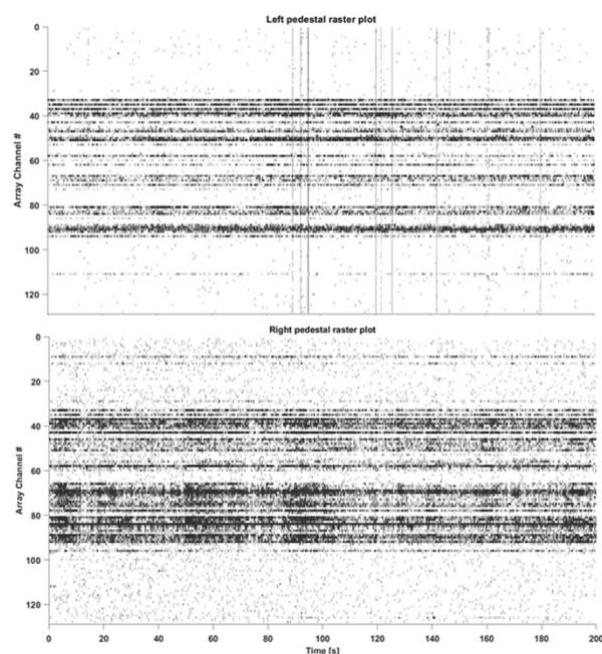


Figure 5. Spike rasters derived from both pedestals (four arrays) in a 200-second example clip. Recordings from the left pedestal (top panel) reflect activity recorded by the two arrays located more medially and dorsally along the precentral gyrus. Recordings from the right pedestal (bottom panel), reflect activity by the two arrays located more laterally along the precentral gyrus and closer to the stroke.

374
375
376
377
378
379
380
381
382
383
384
385
386
387
388
389
390
391
392
393
394
395
396
397
398
399
400
401
402
403
404
405
406
407
408
409
410
411
412
413
414
415
416
417
418
419
420
421
422
423
424
425
426
427
428

Motor outcomes. Motor measures, performed when the participant was not connected to the BCI or wearing the MyoPro orthosis, were tracked over time and demonstrated that the implantation procedure did not decrease residual strength in the paretic left arm and left leg. In fact, muscle strength increased in the left arm. Whereas serial neurological exams since the time of the stroke demonstrated an absence of voluntary wrist extension or finger extension (0/5 on manual muscle testing, starting two months into the trial, the participant began to consistently exhibit voluntary wrist extension against gravity (3/5), and on a few occasions was able to voluntarily extend the fingers slightly (2/5)^{23,23}. One month prior to the device implantation, the Fugl-Meyer upper extremity score was 30 (out of a maximum of 66) for the left upper extremity; this increased to a score of 36 four weeks after the two Multiports were implanted, and a score of 38 seven weeks post-implantation^{24,24}. Although the participant did not receive botulinum toxin injections, or receive any type of anti-spasticity medication, during the clinical trial, spasticity gradually decreased with time as reflected in gradually decreasing numbers on serial measurements of the modified Ashworth scale for spasticity for passive flexion and extension movements of the fingers, wrist, and elbow, along with internal and external rotation of the shoulder^{25,25}.

DISCUSSION

This pilot trial demonstrated that ensemble single unit activity remains active in ipsilesional cerebral cortex overlying chronic subcortical stroke. To our knowledge, this is the first report of intracortical recordings in ipsilesional cerebral cortex for a stroke above the mesencephalon. The trial established that single neuron, movement related activity can be decoded used to control a powered orthosis that restored functionally useful voluntary upper extremity movement. Importantly, this brain-computer interface system can be used simultaneously with residual

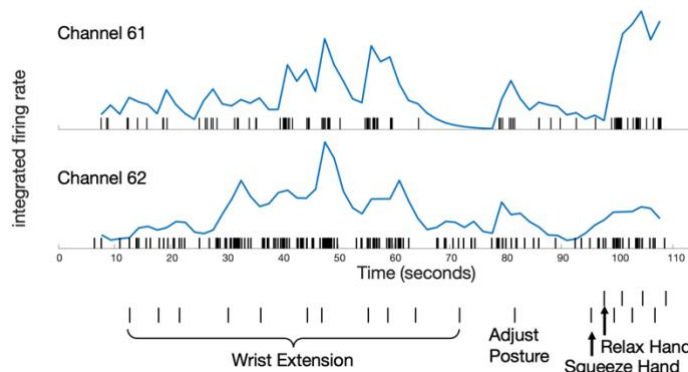


Figure 6. Neuronal activity correlated with performed movements in the paretic limb. Over a 110-s period, the participant was asked to perform a series of left limb movements (which are described on the abscissa). Movement instruction times, delivered as a verbal command, is indicated by a small vertical hash mark. Spiking activity of two simultaneously recorded units is displayed. Rasters indicate the time of each action potential. Normalized, integrated firing rates appear beneath each raster, as derived by the ‘leaky integrator’ equation described in²¹; normalization is achieved by dividing by the maximum integrated firing rate from each unit’s spike train over the time period displayed. Although both units tend to discharge with wrist extension and hand squeezing, the top unit (channel 61) is relatively more active for hand squeezing than wrist extension, relative to the bottom, simultaneously recorded unit (channel 62). The participant performed all movements; however, such motions required effort and he was unable to engage a consistent level of activity for each cue, and also exhibited a variable reaction time to a given cue. The participant was easily fatigued, requiring him to take a break and then adjust his posture.

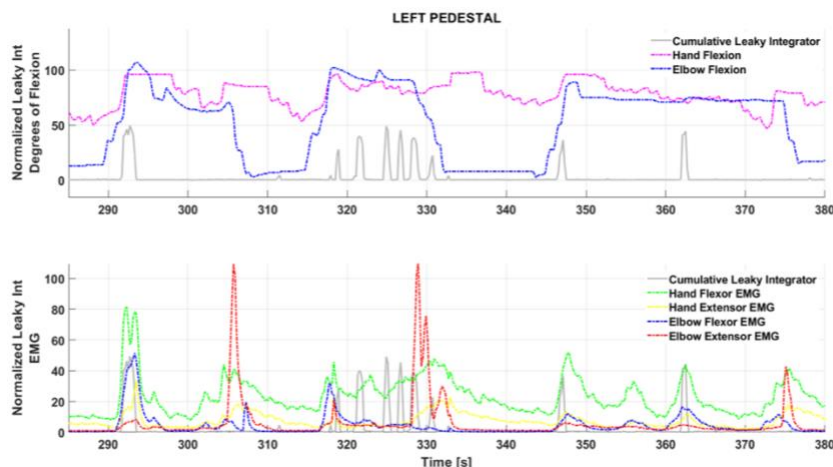


Figure 7. Cumulative, integrated spike activity across channels fluctuating with joint position (top) and residual left forearm electromyographic activity (bottom). The summed spike activity across channels and run through a leaky integrator²¹ appeared to fluctuate with specific residual actions in the left upper extremity. More proximal residual activity in the biceps and triceps generated a more normal-appearing pattern: as seen between 290 and 310 seconds in the bottom panel, biceps (blue trace) and triceps (red trace) activity alternate. In the distal upper extremity, however, wrist flexor (green) and wrist extensor (yellow) trace, tend to occur together in an abnormal synergy; it is also evident that wrist flexor activity is likewise abnormally synergistic with biceps activity (an abnormal flexor synergy). The summed, integrated spiking activity across channels appears to fluctuate most consistently with wrist flexor activity.

429 intact movement, in particular in a limb with a gradient of intact to absent voluntary movement, as is common
430 following cerebral strokes. While myoelectric approaches based upon wrist flexion did enable voluntary hand opening,
431 this approach triggered increased muscle tone that subsequently slowed orthosis use (as the motors were opposing the
432 abnormal tone): the BCI control mode essentially bypassed this issue and allowed motors to operate more smoothly
433 and quickly. Electromyographic recordings demonstrated that while the participant did continue to engage wrist
434 flexors during BCI control, the amplitude was decreased from abnormally elevated levels to more normal amplitudes.
435

436 This trial was not intended to restore voluntary motor control in the hemiparetic upper extremity in the absence of any
437 device use, but even so, we found that strength improved, and spasticity decreased. At the very least, this suggests that
438 the implantation of four microelectrode arrays into ipsilesional precentral gyrus cortex did not exacerbate pre-existing
439 hemiparesis (i.e., it did not worsen hand or arm weakness); indeed, after the intervention hand functions improved.
440 One potential explanation for the participant's unexpected improvements in voluntary wrist and finger extension
441 include mass practice (from regular physical and occupational therapy, with daily practice reinforced by clinical trial
442 assistants), Although the use of an extension arm splint 8 hours each night, and the frequent use of an electric blanket
443 to warm the paretic forearm, undoubtedly helped reduce spasticity and stretch flexor tendons, these interventions
444 cannot account for the benefits as they had also been in use for months prior to enrollment when serial measurements
445 showed no improvements in manual muscle testing. Another, more speculative, explanation for the participant's
446 improved forearm function is that the daily exercise of ipsilesional cortical activity for BCI-orthosis control, promoted
447 a plasticity driven response to either normalize or compensate for abnormal motor synergies.
448

449 Although the limited number of trials on various tasks reduced statistical power to compare myoelectric to BCI control,
450 qualitatively there appeared to be a trend of faster control in the BCI mode. We speculate that this may be due to the
451 fact that triggering orthosis action from direct cortical recordings does not activate abnormal forearm synergies in the
452 same manner that myoelectric control appears to. Post-stroke spasticity is thought to represent a form of abnormal
453 plasticity and loss of corticoreticular facilitation of the medullary inhibition center in turn leading to decreased
454 inhibition from the dorsal reticulospinal tract on the spinal stretch reflex: the medial reticulospinal and vestibulospinal
455 tracts are unopposed leading to stretch reflex hyperexcitability^{26,26}. In the myoelectric mode, where hand closing is
456 triggered by activation of residual wrist flexors, this hyperexcitability is inevitably triggered such that the orthosis
457 motors have to 'fight harder' to open the hand, slowing that process. In the BCI mode, even if residual wrist flexor
458 and extensor activity are engaged, it is to lesser degree such that abnormal tone is not elevated, and the orthosis motors
459 can more easily and rapidly achieve hand actions.
460

461 This pilot study implies that usable control signals are present in ipsilesional cerebral cortical activity. To be clinically
462 scalable, future devices must be fully implantable to minimize infection risk and allow mobility. With the advent of
463 fully implantable BCI (i.e., no percutaneous connectors,^{27,28,29}), a wider range of stroke survivors could benefit.
464 Although a fully implantable BCI could be coupled to an external wearable orthosis, an option that may gain even
465 wider clinical adoption would be to couple direct cortical control to implantable functional electrical stimulation in
466 the paretic arm, as has been demonstrated in at least one stroke survivor¹⁰. The combination of a fully implantable
467 brain sensor with a fully implantable peripheral neuromuscular stimulation hence could be a potential solution to
468 "unparalyze" the arm. Direct cortically driven peripheral muscular stimulation may have both rehabilitative³⁰ benefits
469 when used intermittently and direct functional (hand use) benefits if deployed continuously in daily life. Fully
470 implantable brain-computer interfaces may represent a new combined medical device opportunity to help stroke
471 survivors break through their plateau in recovery and to achieve greater functional independence.
472

473 This pilot study implies that usable control signals are present in ipsilesional cerebral cortical activity. To be clinically
474 scalable, future devices must be fully implantable to minimize infection risk. With the advent of fully implantable BCI
475 (i.e., no percutaneous connectors,^{27,28,29}), a wider range of stroke survivors could benefit. Although a fully implantable
476 BCI could be coupled to an external wearable orthosis, an option that may gain even wider clinical adoption would be
477 to couple direct cortical control to implantable functional electrical stimulation in the paretic arm, as has been
478 demonstrated in at least one stroke survivor [17]. The combination of a fully implantable brain sensor with a fully
479 implantable peripheral neuromuscular stimulation hence could be a potential solution to "unparalyze" the arm. Direct
480 cortically driven peripheral muscular stimulation may have both rehabilitative³⁰ benefits when used intermittently
481 and direct functional benefits if deployed continuously in daily life. Fully implantable brain-computer interfaces may

482 represent a medical device opportunity to help stroke survivors break through their plateau in recovery and keep going
483 to achieve greater functional independence.

484

485 FUNDING

486

487 This research was supported by philanthropy to the Farber Institute of Neuroscience at Thomas Jefferson University.

488

489 ETHICS COMMITTEE APPROVAL

490

491 This research was approved, and remains in approved status, by the Institutional Review Board of Thomas Jefferson
492 University, protocol number 17D.459.

493

494 CONFLICT OF INTEREST STATEMENT

495

496 Drs. Serruya and Napoli are inventors on a US provisional patent application that has been filed by Thomas Jefferson
497 University on the methods described in this paper. All authors report that they do not have any conflicts of interest
498 with the research described.

499

500 ACKNOWLEDGEMENTS

501

502 The authors would like to thank the following people for their assistance and input: Erica Jones, Shivayogi Hiremath,
503 Christopher Thompson, Carlos Vargas-Irwin, John Donoghue, Nicholas Hatsopoulos, David Weisman, Kristofer
504 Feeko, M.J. Mulcahey, Joseph Tracy, Diana Tzeng, Daniel Graves, Ashly Parekh, Joely Mass, Thomas J. Kelly, IV,
505 Stephen Valverde, Allison Weiss, Shaista Alam, Robin Dharia, Elan Miller, Lisa Bowman, Rodney Bell, Michael
506 Sperling, and the participant and his mother.

507

508 REFERENCES

509

- 510 1. Katan, M. & Luft, A. Global Burden of Stroke. *Semin. Neurol.* (2018). doi:10.1055/s-0038-1649503
- 511 2. Vos, T. *et al.* Global, regional, and national incidence, prevalence, and years lived with disability for 310
512 diseases and injuries, 1990–2015: a systematic analysis for the Global Burden of Disease Study 2015.
513 *Lancet* (2016). doi:10.1016/S0140-6736(16)31678-6
- 514 3. Centers for Disease Control. *Prevalence of stroke--United States, 2006-2010. MMWR. Morbidity and*
515 *mortality weekly report* **61**, (2012).
- 516 4. Kwakkel, G., Kollen, B. J., Van der Grond, J. V. & Prevo, A. J. H. Probability of regaining dexterity in the
517 flaccid upper limb: Impact of severity of paresis and time since onset in acute stroke. *Stroke* (2003).
518 doi:10.1161/01.STR.0000087172.16305.CD
- 519 5. Milekovic T, Sarma AA, Bacher D, Simeral JD, Saab J, Pandarinath C, S. B., Blabe C, Oakley EM, Tringale
520 KR, Eskandar E, Cash SS, Henderson JM, S. K. & Donoghue JP, H. L. Stable long-term BCI-enabled
521 communication in ALS and locked-in syndrome using LFP signals. *J Neurophysiol* (2018).
522 doi:10.1152/jn.00493.2017
- 523 6. Klaes, C. *et al.* A cognitive neuroprosthetic that uses cortical stimulation for somatosensory feedback. *J.*
524 *Neural Eng.* **11**, 056024 (2014).
- 525 7. Collinger, J. L. *et al.* High-performance neuroprosthetic control by an individual with tetraplegia. *Lancet*
526 **381**, 557–564 (2013).
- 527 8. Bhagat, N. A. *et al.* Design and optimization of an EEG-based brain machine interface (BMI) to an upper-
528 limb exoskeleton for stroke survivors. *Front. Neurosci.* **10**, (2016).
- 529 9. Page, S. J., Hill, V. & White, S. Portable upper extremity robotics is as efficacious as upper extremity
530 rehabilitative therapy: a randomized controlled pilot trial. *Clin. Rehabil.* **27**, 494–503 (2013).
- 531 10. Knutson, J. S. *et al.* Implanted neuroprosthesis for assisting arm and hand function after stroke: A case
532 study. *J. Rehabil. Res. Dev.* **49**, 1505 (2012).
- 533 11. Knutson, J. S. *et al.* Adding contralaterally controlled electrical stimulation of the triceps to contralaterally

- 534 controlled functional electrical stimulation of the finger extensors reduces upper limb impairment and
535 improves reachable workspace but not dexterity: A randomized . *Am. J. Phys. Med. Rehabil.* (2020).
536 doi:10.1097/PHM.0000000000001363
- 537 12. Wisneski, K. J. *et al.* Unique cortical physiology associated with ipsilateral hand movements and
538 neuroprosthetic implications. *Stroke* **39**, 3351–3359 (2008).
- 539 13. Knutson, J. S. *et al.* Implanted neuroprosthesis for assisting arm and hand function after stroke: a case study.
540 *J. Rehabil. Res. Dev.* **49**, 1505–16 (2012).
- 541 14. Bundy, D. T. *et al.* Using ipsilateral motor signals in the unaffected cerebral hemisphere as a signal platform
542 for brain-computer interfaces in hemiplegic stroke survivors. *J. Neural Eng.* **9**, 036011 (2012).
- 543 15. Vargas-Irwin, C. E. *et al.* Watch, imagine, attempt: Motor cortex single-unit activity reveals context-
544 dependent movement encoding in humans with tetraplegia. *Front. Hum. Neurosci.* (2018).
545 doi:10.3389/fnhum.2018.00450
- 546 16. Hochberg, L. R. *et al.* Reach and grasp by people with tetraplegia using a neurally controlled robotic arm.
547 *Nature* **485**, 372–375 (2012).
- 548 17. Suner, S., Fellows, M. R., Vargas-Irwin, C., Nakata, G. K. & Donoghue, J. P. Reliability of signals from a
549 chronically implanted, silicon-based electrode array in non-human primate primary motor cortex. *IEEE*
550 *Trans. Neural Syst. Rehabil. Eng.* **13**, 524–541 (2005).
- 551 18. Rousche, P. J. & Normann, R. A. A method for pneumatically inserting an array of penetrating electrodes
552 into cortical tissue. *Ann. Biomed. Eng.* (1992). doi:10.1007/BF02368133
- 553 19. Yozbatiran, N., Der-Yeghiaian, L. & Cramer, S. C. A standardized approach to performing the action
554 research arm test. *Neurorehabil. Neural Repair* (2008). doi:10.1177/1545968307305353
- 555 20. Taylor, N., Sand, P. L. & Jebsen, R. H. Evaluation of hand function in children. *Arch. Phys. Med. Rehabil.*
556 (1973).
- 557 21. Fetz, E. E. & Baker, M. A. Operantly conditioned patterns on precentral unit activity and correlated
558 responses in adjacent cells and contralateral muscles. *J. Neurophysiol.* (1973). doi:10.1152/jn.1973.36.2.179
- 559 22. Jebsen, R. H., Taylor, N., Trieschmann, R. B., Trotter, M. J. & Howard, L. A. An objective and standardized
560 test of hand function. *Arch. Phys. Med. Rehabil.* (1969).
- 561 23. Martin, E. G. & Lovett, R. W. A Method of Testing Muscular Strength in Infantile Paralysis. *J. Am. Med.*
562 *Assoc.* (1915). doi:10.1001/jama.1915.02580180016006
- 563 24. Fugl-Meyer, A. R., Jääskö, L., Leyman, I., Olsson, S. & Steglind, S. The post-stroke hemiplegic patient. 1. a
564 method for evaluation of physical performance. *Scand. J. Rehabil. Med.* (1975). doi:10.1038/35081184
- 565 25. Ashworth, B. Preliminary trial of carisoprodol in multiple sclerosis. *Practitioner* (1964).
- 566 26. Li, S. Spasticity, motor recovery, and neural plasticity after stroke. *Frontiers in Neurology* (2017).
567 doi:10.3389/fneur.2017.00120
- 568 27. Yin, M. *et al.* Wireless neurosensor for full-spectrum electrophysiology recordings during free behavior.
569 *Neuron* (2014). doi:10.1016/j.neuron.2014.11.010
- 570 28. Musk, E. An Integrated Brain-Machine Interface Platform With Thousands of Channels. *J. Med. Internet*
571 *Res.* (2019). doi:10.2196/16194
- 572 29. Kohler, F. *et al.* Closed-loop interaction with the cerebral cortex: a review of wireless implant technology\$.
573 *Brain-Computer Interfaces* (2017). doi:10.1080/2326263X.2017.1338011
- 574 30. Olsen, S. *et al.* Peripheral Electrical Stimulation Paired With Movement-Related Cortical Potentials
575 Improves Isometric Muscle Strength and Voluntary Activation Following Stroke. *Front. Hum. Neurosci.*
576 (2020). doi:10.3389/fnhum.2020.00156
577