Supplementary Material

Vascular Thrombosis in COVID-19: A Potential Association with Antiphospholipid Antibodies

Aneesh S Kallapur[1], Eric Y Yen[1], Ram Raj Singh[1,2,3,4]

[1]Department of Medicine, University of California at Los Angeles (UCLA) David Geffen School of Medicine, Los Angeles, CA, [2]Jonsson Comprehensive Cancer Center, UCLA, Los Angeles, CA, [3]Molecular Toxicology Interdepartmental Program, UCLA, Los Angeles, CA, [4]Department of Pathology and Laboratory Medicine, UCLA, Los Angeles, CA.

Corresponding author: Ram Raj Singh, MD, Autoimmunity and Tolerance Laboratory, Division of Rheumatology, UCLA, 1000 Veteran Avenue, Room 32-59, Los Angeles, CA 90095-1670 (rrsingh@mednet.ucla.edu).

CONTENTS

1. Appendix Figure 1. Search results in our systematic review.
2. Appendix Table 1. Quality of evidence.
3. Appendix Table 2. Case Reports of patients with COVID-19 and thrombosis who had antiphospholipid assays. This Table includes reports of single and two cases with thrombosis and antiphospholipid testing.
4. Appendix Table 3. Comorbidities in patients with COVID-19 and thrombosis who had antiphospholipid testing.
5. Supplementary References

Appendix Figure 1. **Search results in our systematic review.**

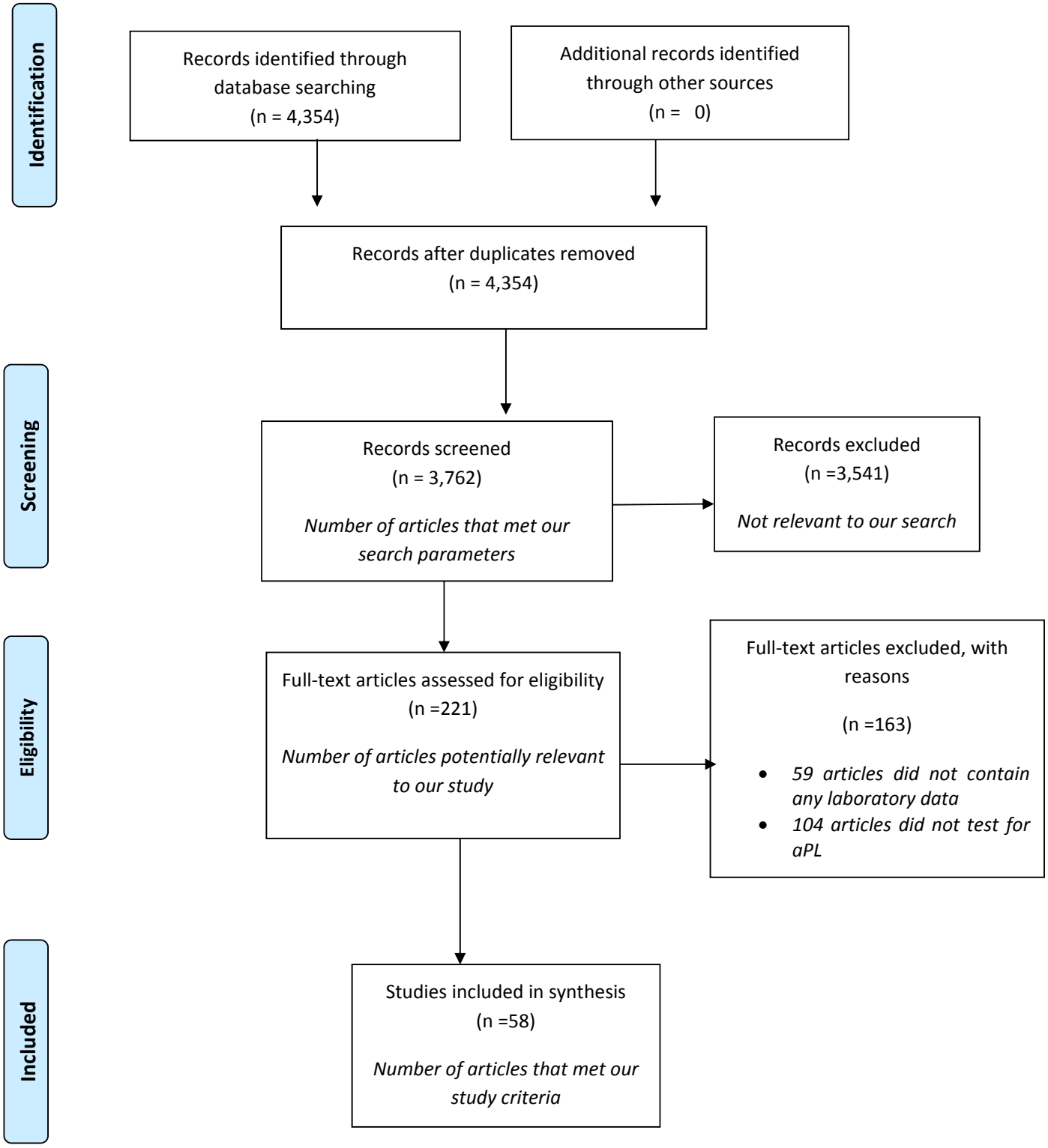

Appendix Table 1. Quality of Evidence

Study	Type of evidence	Quality of evidence
Al-Ani, et al.	Systematic review with meta-analysis	1
Helms, et al.	Prospective cohort study	3
Wichmann, et al.	Prospective cohort study	3
Zhang, et al.	Case series without intervention	4
Bowles, et al.	Retrospective cohort study	3
Reyes Gil, et al.	Retrospective cohort study	3
Gatto, et al.	Cross-sectional study	4
Xiao, et.al	Cross-sectional study	4
Zhang et al.	Cross-sectional study	4
Siguret, et al.	Cross sectional study	4
Borghi, et al.	Cross-sectional study (Not peer-reviewed)	4
Zuo, et al.	Cross-sectional study (Not peer-reviewed)	4
Pineton De Chambrun, et al.	Cross sectional study	4
Galeano-Valle, et al.	Cross sectional study	4
Devreese, et al.	Cross-sectional study	4
Beyrouti, et al.	Case series without intervention	4
Etkin, et al.	Cross sectional study	4
Kashi, et al.	Case series without intervention	4
Delahoy, et al.	Cross sectional study	4
Wong, et al.	Case series without intervention	4
Freeman, et al.	Case series without intervention	4
Elsoukkary, et al.	Case series without intervention	4
Harzallah, et al.	Cross sectional study	4
Khan, et al.	Case series without intervention	4
Vechi, et al.	Case series without intervention	4
Mao, et al.	Case series without intervention	4
Fan, et al.	Case series without intervention	4
Xiong, et al.	Retrospective cohort study	3
Barrios-López*, et al.*	Case series without intervention	4
Basi, et al.	Case report	5
Bigliardi, et al.	Case report	5
Bonardel, et al.	Case report	5
D'Anna, et al.	Case series without intervention	4
Diaz-Perez, et al.	Case series without intervention	4
Duroi, et al.	Case report	5
Fara, et al.	Case report	5
Gemcioglu, et al.	Case report	5
González-Pinto*, et al.*	Case report	5
Helms, et al.	Case series without intervention	4
Immovilli, et al.	Case series without intervention	4
Klok, et al.	Cross sectional study	4
Lapergue, et al.	Case series without intervention	4
Lodigiani, et al.	Retrospective cohort study	3
Mohamed, et al.	Case report	5
Morassi, et al.	Case series without intervention	4
Roy, et al.	Case series without intervention	4
TunÇ*, et al.*	Case series without intervention	4
Zayet, et al.	Case series without intervention	4
Avula, et al.	Case series without intervention	4
Deliwala, et al.	Case report	5
Elshereye, et al.	Case report	5
Esenwa, et al.	Case series without intervention	4
Garg, et al.	Case report	5
Goldberg, et al.	Case report	5

Gunasekaran, et al.	Case report	5
Jillella, et al.	Case series without intervention	4
Kariyanna, et al.	Case report	5
Katz, et al.	Case series without intervention	4
Kihira, et al.	Case-control study	3
Kvernland, et al.	Retrospective cohort study	3
Xia, et al.	Retrospective cohort study	3
Mahboob, et al.	Case report	5
Majidi, et al.	Case series without intervention	4
Oxley, et al.	Case series without intervention	4
Reddy, et al.	Case series without intervention	4
Rothstein, et al.	Case series without intervention	4
Valderrama, et al.	Case report	5
Yaghi, et al.	Retrospective cohort study	3
Zahid, et al.	Case report	5

Supplementary Table

Author and Citation Number	Type of Evidence	Quality of Evidence
Hossri, et.al.	Case series without intervention	4
Dumitrascu, et.al.	Case report	5
Shams, et.al.	Case report	5
Zendjebil, et.al.	Case report	5
Soltani, et.al.	Case report	5
Gomez-Arbelaez, et.al.	Case series without intervention	4
Woehl, et.al.	Case series without intervention	4
Nassabein, et.al.	Case report	5
Mosbahi, et.al.	Case report	5
Veyre, et.al.	Case report	5
Singh, et.al.	Case series without intervention	4
Warrior, et.al.	Case report	5
Renaud-Picard, et.al.	Case report	5
Garaci, et.al.	Case report	5
Klein, et.al.	Case report	5
Roy-Gash, et.al.	Case report	5
Bolaji, et.al.	Case report	5
Hemasian, et.al.	Case report	5
Alharthy, et.al.	Case series without intervention	4
Marsico, et.al.	Case series without intervention	4
Akiyama, et.al.	Case report	5
Ofosu, et.al.	Case report	5
Franco-Moreno, et.al.	Case report	5
Del Hoyo, et.al.	Case report	5
Pang, et.al.	Case report	5
Fan, et.al.	Case report	5
Veyseh, et.al.	Case report	5
Sung, et.al.	Case report	5
Davoodi, et.al.	Case report	5
Nauka, et.al.	Case report	5

Appendix Table 2. **Case Reports of patients with COVID-19 and thrombosis who had antiphospholipid assays.**

This Table includes reports of single and two cases with thrombosis and aPL testing.

Location (Ref)	Patient cohort	Thrombotic manifestations	aPL test
Arterial thrombotic events			
USA (1)	2 critically ill patients	Multiple cerebral infarction and splenic infarct (patient 1), Acute limb ischemia (patient 2)	IgM and IgG aCL + in both
USA (2)	1 patient (48/M)	Ophthalmic artery occlusion	–
Qatar (3)	1 patient (28/M)	Coronary thrombosis	aCL –
France (4)	1 patient (42/M)	Myocardial infarction	–
Canada (5)	1 patient (63/F)	Myocardial infarction	–
Spain (6)	4 patients (50-76 years)	Aortic thrombosis	2/4 patients were tested; both –
France (7)	4 patients (64-78 years)	Aortic thrombosis	2/4 patients tested; both –
Canada (8)	1 patient (66/F)	Aortic thrombosis	–
Switzerland (9)	1 patient (58/M)	Aortic thrombosis	Thrombophilia workup –, exact aPL status unclear
France (10)	1 patient (24/M)	Femoral artery thrombosis	Negative
USA (11)	3 patients (71/F, 70/M, 70/F)	Acute limb ischemia	Only 2 were tested, both trace + for IgM aCL
USA (12)	1 patient (59/F)	Acute limb ischemia	**IgM aCL +**
France (13)	1 patient (31/M)	Acute limb ischemia	**LA +**
Venous thrombotic events			
Italy (14)	1 patient (44/F)	Cerebral venous thrombosis	–
USA (15)	1 patient (29/F)	Cerebral venous thrombosis	**aCL +**
France (16)	1 patient (63/F)	Cerebral venous thrombosis	–
UK(17)	1 patient (63/M)	Cerebral venous thrombosis	**LA low titer +**
Iran (18)	1 patient (65/M)	Cerebral venous thrombosis	Thrombophilia workup –, aPL status unclear.
Saudi Arabia (19)	2 patients- 50/F, 56/F	Acute pulmonary embolism	Thrombophilia workup –, aPL status unclear
Spain (20)	2 patients- 32/M, 59/F	Pulmonary embolism	**LA +,** not specified for patient 2
Japan(21)	1 patient (56/M)	Pulmonary embolism	–
USA (22)	1 patient (55/M)	Portal vein thrombosis	LA –
Spain (23)	1 patient (27/M)	Portal vein thrombosis	–
Spain (24)	1 patient (61/F)	Splanchnic vein thrombosis	**Low titer LA +**
Singapore (25)	1 patient (30/M)	Superior mesenteric vein thrombosis	**LA +**
Singapore (26)	1 patient (30/M)	Superior mesenteric vein thrombosis	**LA +**
USA(27)	1 patient (52/F)	Gonadal vein thrombosis	LA –
USA (28)	1 patient	Four extremity DVT	LA and IgM/IgG aCL +
Iran(29)	1 patient (57/F)	DVT	aCL –
USA (30)	1 patient (48/M)	DVT	–

–, negative; +, positive; aCL, anti-cardiolipin antibody; aPL, antiphospholipid; CAD, coronary artery disease; DM, diabetes mellitus; DVT, deep vein thrombosis; F, female; HTN, hypertension; LA, lupus anticoagulant; M, male.

Overall, we found reports of positive aPL antibodies in all 8 patients with acute limb ischemia, 1 of 4 patients with myocardial infarction, none of 6 with aortic thrombosis, 2 of 5

patients with cerebral venous thrombosis, and all 3 patients with splanchnic/superior mesenteric venous thrombosis.

Appendix Table 3. **Comorbidities in patients with COVID-19 and thrombosis who had antiphospholipid testing**.

Location [Ref.]	Patient cohort	Comorbidites
Wuhan, China (31)	3 critically ill patients with COVID-19	HTN (3/3), DM (2/3), stroke (2/3)
Wuhan, China (32)	66 critically ill patients with COVID-19	HTN (≈ 50%), DM (≈ 20%)
Wuhan, China (33)	19 ICU patients with COVID-19; all on anticoagulation	63% with comorbidities
Italy (34)	53 hospitalized patients and 69 in home quarantine; 89% on anticoagulation	Not mentioned
Italy (35)	122 severe or critical patients; 98% anticoagulated	6 patients with thrombotic event in the past
France (36)	74 mechanically ventilated patients on anticoagulation	DM and HTN in 43% of those with thrombosis and 39%-46% of those without it.
France (37)	25 critically ill patients	Not mentioned
Spain (38)	24 of 785 COVID-19 patients who had VTE (3%)	Not mentioned
Belgium (39)	31 ICU patients with COVID-19	45% CVD, 25.8% DM, 12.9% obesity
UK (40)	4 COVID-19 with stroke	HTN (3/4), DM (2/4)
Mexico (41)	21 severe or critical patients; 18 anticoagulated	HTN 12 (57%), DM 8 (39%), obesity 7 (33%)
Michigan, USA (42)	172 hospitalized patients; most on anticoagulation.	HTN (68%), DM (41%), obesity (51%), smoking (26%)
New York, USA (43)	68 patients who had LA test orders and PCR+ for SARS-n-COV-2 at a tertiary hospital	Ventilation, mortality, and anticoagulation similar in LA+ vs. LA– patients
UAE (44)	22 patients with ischemic stroke and COVID-19	36% DM, 32% HTN, 9% CVD, 9% dyslipidemia
Brazil (45)	5 patients with mild infection	1 DM, 1 obesity and HTN
USA (1)	Two critically ill patients with COVID-19	Sickle cell trait (patient 1) Dyslipidemia (patient 2)
USA (2)	1 patient (48/M)	Obesity
Qatar (3)	1 patient (28/M)	None
France (4)	1 patient (42/M)	None
Canada (5)	1 patient (63/F)	COPD
Spain (6)	4 patients (50-76 years)	1 each with HTN, and HTN+ dyslipidemia
France (7)	4 patients (64-78 years)	2 with HTN+ dyslipidemia, 1 with HTN
Canada (8)	1 patient (66/F)	HTN, malignancy
Switzerland (9)	1 patient (58/M)	Not mentioned
France (10)	1 patient (24/M)	None
USA (11)	3 patients (71/F, 70/M, 70/F)	1 with dementia, Parkinson's, 1 HTN, 1 DM + HTN
USA (12)	1 patient (59/F)	HTN, hyperlipidemia
France (13)	1 patient (31/M)	Cystic fibrosis, bilateral lung transplantation
Italy (14)	1 patient (44/F)	None
USA (15)	1 patient (29/F)	None
France (16)	1 patient (63/F)	Not mentioned

UK(17)	1 patient (63/M)	DM
Iran (18)	1 patient (65/M)	None
Saudi Arabia (19)	2 patients- 50/F, 56/F	None
Spain (20)	2 patients- 32/M, 59/F	None, HTN
Japan(21)	1 patient (56/M)	None
USA (22)	1 patient (55/M)	Hyperlipidemia
Spain (23)	1 patient (27/M)	None
Spain (24)	1 patient (61/F)	DM
Singapore (25)	1 patient (30/M)	None
Singapore (26)	1 patient (30/M)	None
USA(27)	1 patient (52/F)	None
USA (28)	One patient	None
Iran(29)	1 patient (57/F)	None
USA (30)	1 patient (48/M)	CAD, renal donation

+, positive; –, negative; aβ2GP1, anti-ß2 glycoprotein 1 antibody; aCL, anti-cardiolipin antibody; aPL, antiphospholipid antibody; CVC, central venous catheter; CVD, cardiovascular disease; DM, diabetes mellitus; dRVVT, diluted Russell viper venom test; DVT, deep vein thrombosis; HTN, hypertension; incl., including; ICU, intensive care unit; LA, lupus anticoagulant; OR, odds ratio; PE, pulmonary embolism; VTE, venous thromboembolism

Supplementary References

1. Hossri S, Shadi M, Hamarsha Z, Schneider R, El-Sayegh D. Clinically significant anticardiolipin antibodies associated with COVID-19. J Crit Care. 2020;59:32-4.
2. Dumitrascu OM, Volod O, Bose S, Wang Y, Biousse V, Lyden PD. Acute ophthalmic artery occlusion in a COVID-19 patient on apixaban. J Stroke Cerebrovasc Dis. 2020;29(8):104982.
3. Shams A, Ata F, Mushtaq K, Munir W, Yousaf Z. Coronary thrombosis in a young male with COVID-19. IDCases. 2020;21:e00923.
4. Zendjebil S, Zeitouni M, Batonga M, El Bèze N, Guedeney P, Collet JP, et al. Acute Multivessel Coronary Occlusion Revealing COVID-19 in a Young Adult. JACC Case Rep. 2020;2(9):1297-301.
5. Soltani M, Mansour S. Biventricular Thrombi Associated With Myocardial Infarction in a Patient With COVID-19. Can J Cardiol. 2020;36(8):1326.e9-.e11.
6. Gomez-Arbelaez D, Ibarra-Sanchez G, Garcia-Gutierrez A, Comanges-Yeboles A, Ansuategui-Vicente M, Gonzalez-Fajardo JA. COVID-19-Related Aortic Thrombosis: A Report of Four Cases. Ann Vasc Surg. 2020;67:10-3.
7. Woehl B, Lawson B, Jambert L, Tousch J, Ghassani A, Hamade A. 4 Cases of Aortic Thrombosis in Patients With COVID-19. JACC Case Rep. 2020;2(9):1397-401.
8. Nassabein R, Routy B, Blais N, Ayoub JP, Tehfé M. Arterial thrombosis and coronavirus disease 2019 in a patient with cancer. Eur J Cancer. 2020;134:1-2.
9. Mosbahi S, Heinisch PP, Schoenhoff FS, Berger DC. COVID-19-associated aortic arch thrombus. Eur J Cardiothorac Surg. 2020;58(4):870.
10. Veyre F, Poulain-Veyre C, Esparcieux A, Monsarrat N, Aouifi A, Lapeze J, et al. Femoral Arterial Thrombosis in a Young Adult after Nonsevere COVID-19. Ann Vasc Surg. 2020.
11. Singh B, Aly R, Kaur P, Gupta S, Vasudev R, Virk HS, et al. COVID-19 Infection and Arterial Thrombosis: Report of Three Cases. Ann Vasc Surg. 2020.
12. Warrior K, Chung PA, Ahmed N, Soult MC, Simpson KP. Acute Limb Ischemia Due to Arterial Thrombosis Associated With Coronavirus Disease 2019. Crit Care Explor. 2020;2(6):e0140.
13. Renaud-Picard B, Gallais F, Ohana M, Zeyons F, Kretz B, Andre J, et al. Bilateral Acute Cardioembolic Limb Ischemia After Coronavirus Disease 2019 Pneumonia in a Lung Transplant Recipient: A Case Report. Transplant Proc. 2020.
14. Garaci F, Di Giuliano F, Picchi E, Da Ros V, Floris R. Venous cerebral thrombosis in COVID-19 patient. J Neurol Sci. 2020;414:116871.
15. Klein DE, Libman R, Kirsch C, Arora R. Cerebral venous thrombosis: A typical presentation of COVID-19 in the young. J Stroke Cerebrovasc Dis. 2020;29(8):104989.
16. Roy-Gash F, De Mesmay M, Devys JM, Vespignani H, Blanc R, Engrand N. COVID-19-associated acute cerebral venous thrombosis: clinical, CT, MRI and EEG features. Crit Care. 2020;24(1):419.
17. Bolaji P, Kukoyi B, Ahmad N, Wharton C. Extensive cerebral venous sinus thrombosis: a potential complication in a patient with COVID-19 disease. BMJ Case Rep. 2020;13(8).
18. Hemasian H, Ansari B. First case of Covid-19 presented with cerebral venous thrombosis: A rare and dreaded case. Rev Neurol (Paris). 2020;176(6):521-3.
19. Alharthy A, Balhamar A, Faqihi F, Alshaya R, Noor A, Alaklobi F, et al. Insidious development of pulmonary embolism in asymptomatic patients with COVID-19: Two rare case-reports. Respir Med Case Rep. 2020;31:101186.
20. Marsico S, Espallargas Giménez I, Carbullanca Toledo SJ, Del Carpio Bellido LA, Maiques Llácer JM, Zuccarino F. Pulmonary infarction secondary to pulmonary thromboembolism in COVID-19 diagnosed with dual-energy CT pulmonary angiography. Rev Esp Cardiol (Engl Ed). 2020;73(8):672-4.
21. Akiyama Y, Horiuchi K, Kondo Y, Kabata H, Ishii M, Fukunaga K. A case of non-severe COVID-19 complicated by pulmonary embolism. Respirol Case Rep. 2020;8(7):e00622.

22. Ofosu A, Ramai D, Novikov A, Sushma V. Portal Vein Thrombosis in a Patient With COVID-19. Am J Gastroenterol. 2020;115(9):1545-6.
23. Franco-Moreno A, Piniella-Ruiz E, Montoya-Adarraga J, Ballano-Franco C, Alvarez-Miguel F, Peinado-Martinez C, et al. Portal vein thrombosis in a patient with COVID-19. Thromb Res. 2020;194:150-2.
24. Del Hoyo J, López-Muñoz P, Fernández-de la Varga M, Garrido-Marín A, Valero-Pérez E, Prieto M, et al. Hepatobiliary and Pancreatic: A fatal case of extensive splanchnic vein thrombosis in a patient with Covid-19. J Gastroenterol Hepatol. 2020.
25. Pang JHQ, Tang JH, Eugene-Fan B, Lee CL, Low JK. A Peculiar Case of Small Bowel Stricture in a Coronavirus Disease 2019 Patient with Congenital Adhesion Band and Superior Mesenteric Vein Thrombosis. Ann Vasc Surg. 2020.
26. Fan BE, Chang CCR, Teo CHY, Yap ES. COVID-19 Coagulopathy with Superior Mesenteric Vein Thrombosis Complicated by an Ischaemic Bowel. Hamostaseologie. 2020.
27. Veyseh M, Pophali P, Jayarangaiah A, Kumar A. Left gonadal vein thrombosis in a patient with COVID-19-associated coagulopathy. BMJ Case Rep. 2020;13(9).
28. Sung J, Anjum S. Coronavirus Disease 2019 (COVID-19) Infection Associated With Antiphospholipid Antibodies and Four-Extremity Deep Vein thrombosis in a Previously Healthy Female. Cureus. 2020;12(6):e8408.
29. Davoodi L, Jafarpour H, Taghavi M, Razavi A. COVID-19 Presented With Deep Vein Thrombosis: An Unusual Presenting. J Investig Med High Impact Case Rep. 2020;8:2324709620931239.
30. Nauka PC, Oran E, Chekuri S. Deep venous thrombosis in a non-critically ill patient with novel COVID-19 infection. Thromb Res. 2020;192:27-8.
31. Zhang Y, Xiao M, Zhang S, Xia P, Cao W, Jiang W, et al. Coagulopathy and Antiphospholipid Antibodies in Patients with Covid-19. N Engl J Med. 2020;382(17):e38.
32. Xiao M, Zhang Y, Zhang S, Qin X, Xia P, Cao W, et al. Brief Report: Anti-phospholipid antibodies in critically ill patients with Coronavirus Disease 2019 (COVID-19). Arthritis Rheumatol. 2020.
33. Zhang Y, Cao W, Jiang W, Xiao M, Li Y, Tang N, et al. Profile of natural anticoagulant, coagulant factor and anti-phospholipid antibody in critically ill COVID-19 patients. J Thromb Thrombolysis. 2020:1-7.
34. Gatto M, Perricone C, Tonello M, Bistoni O, Cattelan AM, Bursi R, et al. Frequency and clinical correlates of antiphospholipid antibodies arising in patients with SARS-CoV-2 infection: findings from a multicentre study on 122 cases. Clin Exp Rheumatol. 2020;38(4):754-9.
35. Borghi MO, Beltagy A, Garrafa E, Curreli D, Cecchini G, Bodio C, et al. Prevalence, specificity, and clinical association of anti-phospholipid antibodies in COVID-19 patients: are the antibodies really guilty? medRxiv. 2020.
36. Siguret V, Voicu S, Neuwirth M, Delrue M, Gayat E, Stépanian A, et al. Are antiphospholipid antibodies associated with thrombotic complications in critically ill COVID-19 patients? Thromb Res. 2020;195:74-6.
37. Pineton de Chambrun M, Frere C, Miyara M, Amoura Z, Martin-Toutain I, Mathian A, et al. High frequency of antiphospholipid antibodies in critically ill COVID-19 patients: a link with hypercoagulability? J Intern Med. 2020.
38. Galeano-Valle F, Oblitas CM, Ferreiro-Mazón MM, Alonso-Muñoz J, Del Toro-Cervera J, di Natale M, et al. Antiphospholipid antibodies are not elevated in patients with severe COVID-19 pneumonia and venous thromboembolism. Thromb Res. 2020;192:113-5.
39. Devreese KMJ, Linskens EA, Benoit D, Peperstraete H. Antiphospholipid antibodies in patients with COVID-19: A relevant observation? J Thromb Haemost. 2020.

40. Beyrouti R, Adams ME, Benjamin L, Cohen H, Farmer SF, Goh YY, et al. Characteristics of ischaemic stroke associated with COVID-19. J Neurol Neurosurg Psychiatry. 2020;91(8):889-91.
41. Amezcua-Guerra LM, Rojas-Velasco G, Brianza-Padilla M, Vázquez-Rangel A, Márquez-Velasco R, Baranda-Tovar F, et al. Presence of antiphospholipid antibodies in COVID-19: case series study. Ann Rheum Dis. 2020.
42. Zuo Y, Estes SK, Gandhi AA, Yalavarthi S, Ali RA, Shi H, et al. Prothrombotic antiphospholipid antibodies in COVID-19. medRxiv. 2020.
43. Reyes Gil M, Barouqa M, Szymanski J, Gonzalez-Lugo JD, Rahman S, Billett HH**.** Assessment of Lupus Anticoagulant Positivity in Patients With Coronavirus Disease 2019 (COVID-19). JAMA Netw Open. 2020;3(8):e2017539.
44. Khan M, Ibrahim RH, Siddiqi SA, Kerolos Y, Al-Kaylani MM, AlRukn SA, et al. COVID-19 and acute ischemic stroke - A case series from Dubai, UAE. Int J Stroke. 2020;15(6):699-700.
45. Vechi HT, Maia LR, Alves MDM**.** Late acute pulmonary embolism after mild Coronavirus Disease 2019 (COVID-19): a case series. Rev Inst Med Trop Sao Paulo. 2020;62:e63.