

## 1 **Duration of viral detection in throat and rectum of a patient with COVID-19**

2 Le Van Tan<sup>1</sup>, Nghiem My Ngoc<sup>1,2</sup>, Bui Thi Ton That<sup>2</sup>, Le Thi Tam Uyen<sup>2</sup>, Nguyen Thi Thu  
3 Hong<sup>1</sup>, Nguyen Thi Phuong Dung<sup>1</sup>, Le Nguyen Truc Nhu<sup>1</sup>, Tran Tan Thanh<sup>1</sup>, Dinh Nguyen Huy  
4 Man<sup>2</sup>, Nguyen Thanh Phong<sup>2</sup>, Tran Tinh Hien<sup>1,3</sup>, Nguyen Thanh Truong<sup>2</sup>, Guy Thwaites<sup>1,3</sup>,  
5 Nguyen Van Vinh Chau<sup>2</sup>

6 <sup>1</sup>Oxford University Clinical Research Unit, Ho Chi Minh City, Vietnam

7 <sup>2</sup>Hospital for Tropical Diseases, Ho Chi Minh City, Vietnam

8 <sup>3</sup>Centre for Tropical Medicine and Global Health, Nuffield Department of Medicine, University  
9 of Oxford, Oxford, UK

### 10 **Correspondence**

11 Le Van Tan, Oxford University Clinical Research Unit, Ho Chi Minh City, Vietnam; Tel: (+84  
12 28) 8384009; Fax: (+84 8) 9238904; E-mail: [tanlv@oucru.org](mailto:tanlv@oucru.org)

13 Nguyen Van Vinh Chau, Hospital for Tropical Diseases, Ho Chi Minh City, Vietnam; Tel:  
14 (+8428) 39238704, Fax: (+8428) 39236943, E-mail: [chaunvv@oucru.org](mailto:chaunvv@oucru.org)

15 **Abstract**

16 The rapid spread of coronavirus disease 2019 (COVID-19) raises concern about a global  
17 pandemic. Knowledge about the duration of viral shedding remains important for patient  
18 management and infection control. We report the duration of viral detection in throat and rectum  
19 of a COVID-19 patient treated at the Hospital for Tropical Diseases in Ho Chi Minh City,  
20 Vietnam. Despite clinical recovery, SARS-CoV-2 RNA remained detectable by real time RT-  
21 PCR in throat and rectal swabs until day 11 and 18 of hospitalization, respectively. Because live  
22 SARS-CoV-2 has been successfully isolated from a stool sample from a COVID-19 patient in  
23 China, the results demonstrate that COVID-19 patients may remain infectious for long periods,  
24 and fecal-oral transmission may be possible. Therefore, our finding has important implications  
25 for infection control.

26 The emergence of severe acute respiratory syndrome coronavirus 2 (SARS-CoV-2) and its  
27 current global spread have prompted the World Health Organization to declare a Public Health  
28 Emergency of International Concern. We report the duration of viral detection in throat and  
29 rectal swabs taken from a patient treated at the Hospital for Tropical Diseases (HTD) in Ho Chi  
30 Minh City, Vietnam. HTD is a referral hospital responsible for receiving and treating patients  
31 with coronavirus disease 2019 (COVID-19) from southern Vietnam with a population of >40  
32 million.

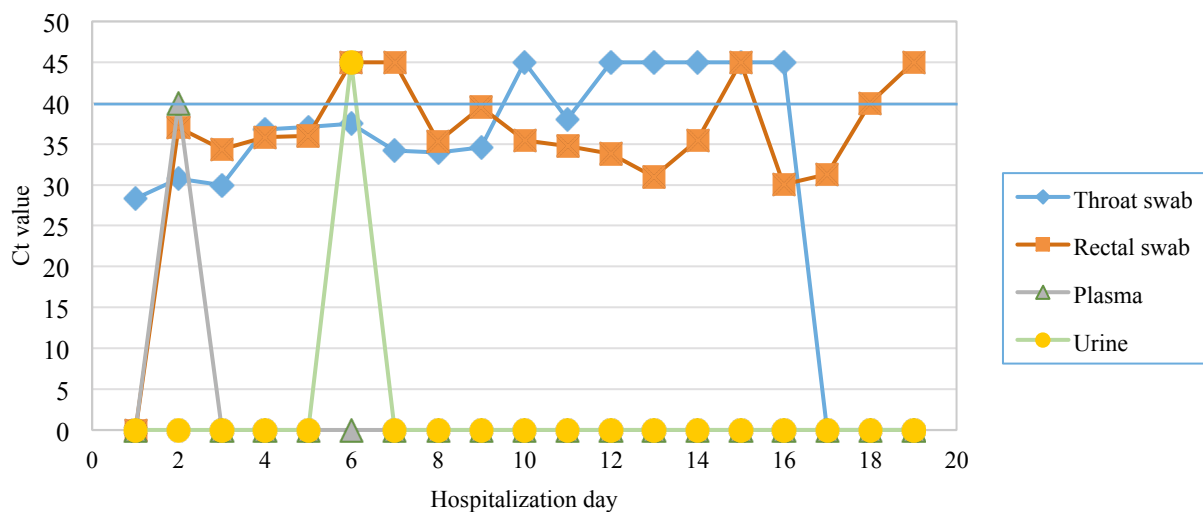
33 On January 31, 2020, a 73-year-old man with a history of benign prostatic hyperplasia was  
34 admitted to HTD with dry cough and breathing difficulties, but without fever. He had become ill  
35 with respiratory symptoms on January 26, 2020, ten days after arrival in Vietnam from the  
36 United States. Whilst travelling to Vietnam, he had two hours of transit at an airport in Wuhan,  
37 China.

38 Blood tests on hospital admission showed an elevation of white cells ( $22,9 \times 10^3$  cells per cubic  
39 millimeter), but others parameters (platelet and hematocrit) were in normal ranges (data not  
40 shown). His chest radiographs obtained on admission showed bilateral infiltrates (Supplementary  
41 Figure 1). The patient was empirically treated with a combination of antivirals and antibiotics,  
42 and received supplemental oxygen through an oxygen mask.

43 On February 1, 2020, a throat swab collected on admission from the patient was positive for  
44 SARS-CoV-2 by reverse-transcription polymerase chain reaction (RT-PCR) (Supplementary  
45 Table 1), followed by sequencing of the amplified product to confirm the result. Testing for other  
46 pathogens (routine bacterial culture and influenza A/B viruses) were negative.

47 His clinical condition improved, and from February 9<sup>th</sup> he no longer required supplementary  
48 oxygen. However, follow-up throat swabs remained positive for SARS-CoV-2 by real-time RT-

49 PCR (1), until day 11 of hospitalization (i.e. day 16 of illness) (Figure 1). Rectal swabs were RT-  
50 PCR positive until day 18 of hospitalization (day 23 of illness). Additionally, a plasma sample  
51 collected on day 2 of admission was weakly positive; urine samples were negative (Figure 1).  
52 The patient was discharged with full recovery on February 21, 2020 after 21 days of  
53 hospitalization.  
54 Since his arrival in Vietnam, the patient had stayed in a hotel in Ho Chi Minh City, and had  
55 sought for medical treatments at private clinics before hospital admission. A total of 14 close  
56 contacts were identified and followed for 14 days, but none had signs of respiratory infections,  
57 and their throat swabs collected on day 14 of quarantine were RT-PCR negative for SARS-CoV-  
58 2.  
59 Long duration of viral detection in throat swabs by RT-PCR has been reported in a case series  
60 from China (2) and a patient in the US (3). Together with the recent success of SARS-CoV-2  
61 isolation in cell culture in a stool sample of a COVID-19 patient in China (4), our finding on the  
62 persistent PCR positivity in rectal swabs raise concerns about the possibility of fecal-oral  
63 transmission of SARS-CoV-2.  
64 Collectively, our report shows the persistence of PCR positivity in throat and rectum of a patient  
65 with COVID-19, which may potentially indicate persistent viral shedding. As such COVID-19  
66 patients may remain infectious for long periods, and fecal-oral transmission may be possible.  
67 Therefore, our finding has important implications for infection control.



**Figure 1:** Results of real-time RT-PCR analysis of serial samples

**Note to figure 1:** a Ct value of 0 indicates no samples available for RT-PCR analysis. Ct value of 40 is the cut-off of assay detection limit (blue line). A Ct value of 45 represents for a negative real-time RT-PCR result.

## **Acknowledgements**

This study was funded by the Wellcome Trust of Great Britain (106680/B/14/Z and 204904/Z/16/Z).

We thank Pham Thi Ngoc Thoa, Tran Nguyen Phuong Thao, Tran Thi Lan Phuong, Tran Thi Thanh Tam, Huynh Thi Kim Nhung, Ngo Tan Tai, Vo Trong Vuong, Le Kim Thanh, Le Nguyen Truc Nhu, Nguyen Thi Han Ny, Motiur Rahman and Evelyne Kestelyn for their laboratory/logistic support.

Ware indebted to the patient for his participations in this study, and all the nursing and medical staff at Ward D of the Hospital for Tropical Diseases who provided care for the patient and helped collect clinical data.

## References:

1. Corman VM, Landt O, Kaiser M, Molenkamp R, Meijer A, Chu DK, et al. Detection of 2019 novel coronavirus (2019-nCoV) by real-time RT-PCR. *Euro Surveill.* 2020;25(3).
2. Zou L, Ruan F, Huang M, Liang L, Huang H, Hong Z, et al. SARS-CoV-2 Viral Load in Upper Respiratory Specimens of Infected Patients. *N Engl J Med.* 2020.
3. Holshue ML, DeBolt C, Lindquist S, Lofy KH, Wiesman J, Bruce H, et al. First Case of 2019 Novel Coronavirus in the United States. *N Engl J Med.* 2020.
4. Zhang Y, Chen C, Zhu S, Shu C, Wang D, Song J, et al. Isolation of 2019-nCoV from a Stool Specimen of a Laboratory-Confirmed Case of the Coronavirus Disease 2019 (COVID-19). *China CDC Weeklu.* 2020;2(8):2.

## Supplementary Materials:

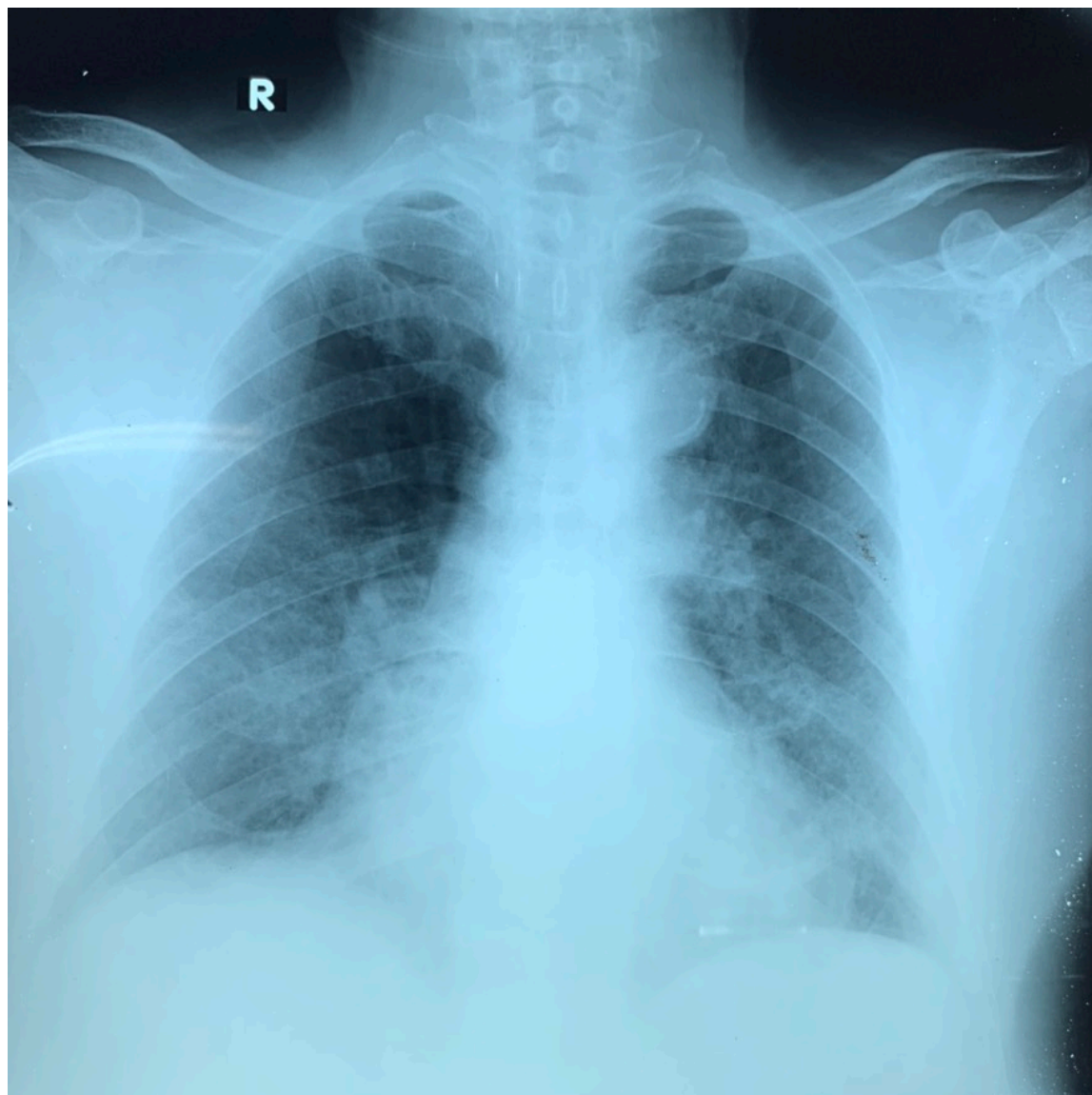**Supplementary Table 1:** List of oligo sequences used for initial detection of SARS-CoV-2 in admission throat swab of the patient

Oligonucleotide ID*	Sequence (5'–3')	Gene target	Expected product
CoV_F_M	GGTTGGGATTATCCTAAATGT	ORF1	440bp
CoV_R_M	GCATCGTCAGAGAGTATCATC	ORF1	

**Note:**

\*Modified based on pan-coronavirus primers described elsewhere (Methods in Molecular Biology, vol. 454: SARS- and Other Coronaviruses, 2008). Sequencing of amplified product was carried using the PCR primers.





**Supplementary Figure 1:** Chest radiograph taken on admission (January 31<sup>st</sup>, 2020) showing bilateral infiltrates