Rapid and Sustained Resolution of Scrotal Content Pain Through Multimodal Integrative Neuromuscular Interventions

Christopher L Mendias, PhD, ATC[1,*], Tariq M Awan, DO[1]

[1]Performance Medicine Institute, Phoenix, AZ, 85012, USA

**Corresponding Author*
Christopher Mendias, PhD, ATC
Performance Medicine Institute
3330 N 2nd St Ste 401
Phoenix, AZ 85012
602-606-8949
cmendias@performancemedinst.com

Keywords
Orchialgia, Scrotal Pain, Scrotal Content Pain, Pain Management, Pelvic Floor Therapy, Exercise Therapy, Neuromuscular Re-Education

Acknowledgments
None

Funding Statement
None

Conflicts of Interest
None

Author Contributions
CLM: Conceptualization, Formal analysis, Investigation, Visualization, Writing - original draft, Writing - review & editing
TMA: Conceptualization, Formal analysis, Investigation, Visualization, Writing - review & editing

Abstract

Scrotal content pain (SCP) is a common and often refractory condition that significantly affects quality of life. This study evaluates outcomes of an integrative physiotherapy protocol targeting neuromuscular contributors to idiopathic SCP. A total of 28 men (mean age 42.1 years) referred to a single outpatient clinic who had SCP symptoms for a mean duration of 3.5 months. Patients with infection, tumors, or varicocele were excluded from analysis. All had persistent SCP unresponsive to oral analgesics or antibiotics. Patients underwent four weekly sessions consisting of: (1) class IV laser therapy from the distal scrotum to the inguinal canal; (2) dry needling along the inguinal tunnel; (3) pulsed electromagnetic field (PEMF) therapy over the lower abdominal and pelvic floor muscles; (4) manual therapy; (5) progressive therapeutic exercise; (6) daily oral tadalafil 5mg. Pain and quality of life were assessed using the Visual Analog Scale (VAS) and PROMIS Global 10 scores. Minimal clinically important differences (MCID) were defined as ≥2.0 for VAS and ≥3.0 for PROMIS domains. Mean VAS pain decreased from 8.0 cm to 3.0 cm after the first session, and to 0.8 cm at four weeks ($P<0.05$), exceeding the MCID threshold. PROMIS Physical Health scores improved from 40.6 to 51.7 and Mental Health from 46.7 to 51.1 ($P<0.05$). At 3 to 6 months after discharge, all patients who responded reported durable pain relief without recurrence. This study identified that an integrated multimodal treatment protocol combining laser therapy, dry needling, PEMF, manual therapy, and rehabilitative exercise produced rapid and sustained improvement in pain and functional outcomes for SCP. These findings support a neuromuscular etiology for many cases of orchialgia and SCP, and highlight the therapeutic potential of addressing pain and muscle dysfunction concurrently. Prospective controlled studies are warranted to confirm these results.

Study

Scrotal content pain (SCP) represents a significant clinical challenge that substantially impairs quality of life. SCP accounts for 2.5-5% of outpatient urology consultations and many times an underlying etiology cannot be identified [1] . Patients often present after failing to respond to conservative management, leaving them with limited options [2]. The scrotum and its contents receive sensory innervation from the genital branch of the genitofemoral nerve and the ilioinguinal nerve, which travel within or adjacent to the spermatic cord and inguinal canal. The spermatic cord is ensheathed within three fascial layers derived from the abdominal wall – this intimate anatomical relationship means that mechanical dysfunction of the lower abdominal wall, inguinal canal, or pelvic floor can directly lead to nerve irritation or compression and referred pain in the scrotum.

Idiopathic SCP is increasingly thought to be neuromuscular in nature. Hypertonicity of the cremaster muscle can cause SCP by compressing the spermatic cord. Pathological analyses of spermatic cords from men with SCP identified a high prevalence of Wallerian degeneration in small nerve fibers of the cremaster muscle and fascia, indicating a state of chronic nerve injury [3]. Myofascial restriction and hypertonicity within the inguinal canal can therefore create a compressive neuropathy of the ilioinguinal and genitofemoral nerves, leading to SCP. Activation of nociceptive neurons of the scrotum can lead to reciprocal activation of the motor neurons of the cremaster through interneuron intermediates in the spinal cord, resulting in a persistent pain-spasm cycle. Many previous interventional studies for SCP have focused either on treating pain or muscle dysfunction, without taking an integrative approach to address both aspects.

Class IV lasers are used extensively to treat acute and chronic pain in various musculoskeletal conditions by inhibiting TRPV channels present in Aδ and C nociceptive

neurons [4]. This impairs the ability of nociceptive neurons to depolarize and propagate signals, with no impact on the function of motor neurons [4]. Lasers therefore have advantages over local anesthetic medications used in inguinal canal blocks which broadly target both sensory and motor neurons. By acutely reducing pain while preserving motor function, laser therapy creates an ideal therapeutic window to selectively block nociceptive pain and spasms, allowing patients to perform exercises needed to restore normal neuromuscular control and achieve a lasting resolution. This retrospective case series reports the outcomes of a novel, integrated therapeutic protocol which used existing therapeutic techniques consisting of laser therapy, dry needling, pulsed electromagnetic field (PEMF) therapy, manual therapy, and therapeutic exercise to provide lasting symptom relief for men with SCP.

This study includes 28 male patients (mean age 42.1±14.9 years) who were treated at a single outpatient clinic (Table 1). Patients were evaluated by a urologist prior to treatment, including imaging to rule out pathologies such as hernia, tumor, or varicocele. Mean SCP symptom duration was 3.5±1.4 months. Laboratory tests confirmed the absence of active infection, with negative urine leukocyte esterase and bacterial cultures, and C-reactive protein levels within normal limits (Table 1). Prostatitis was considered unlikely, with PSA levels <4 ng/mL and no pain on digital rectal examination (Table 1). All patients previously trialed and failed oral anti-inflammatory medications or acetaminophen for pain relief. Nearly one-third (29%) had a previous vasectomy, but this was performed >3 years before SCP symptoms developed. Almost half (46%) had been treated with antibiotics without benefit, even though there were no laboratory signs of infection.

Patients underwent four weekly treatment sessions (Table 2). The intervention combined five synergistic modalities: class IV laser therapy applied topically from the origin of the

inguinal canal to the distal scrotum; dry needling with needles placed intradermally or subcutaneously over the inguinal canal; PEMF focused on the pelvic floor and abdominal muscles; manual therapy consisting of myofascial release and proprioceptive neuromuscular facilitative stretching of the abdominal, lumbar, and hip musculature; and therapeutic exercises during each session. Therapeutic exercises were selected based on the mobility and fitness level of the patient, starting with foundational exercises (isometric adduction, supine march, pelvic tilts, cat-cow, quadruped rocking, glute bridge), progressing to intermediate (single leg bridge, double leg raise, step-downs, swiss ball rollouts, side-lying abduction, dead bugs, squats, Pallof press, body blade rotations) and then advanced (Copenhagen plank, reverse lunges, reverse deadlifts, Bulgarian split-squats, Russian twists, bicycle crunches) exercises. Patients were provided with instructions to perform exercises and stretching at home 2-3 times weekly, along with diaphragmatic breathing. Patients were also prescribed oral tadalafil 5 mg daily to promote pelvic blood flow. To quantify the impact of treatment on pain and quality of life, visual analog scale (VAS, 10 cm) pain was measured before and after each session, and the NIH PROMIS Global 10 health outcome assessment was measured prior to starting treatment and at the end of the final session.

Pain and quality-of-life outcomes improved dramatically over the 4-week program (Figure 1A). Mean VAS pain score decreased from 8.0±0.6 cm prior to starting treatment to 3.0±1.1 cm at the end of the first treatment session ($P<0.05$). Pain continued to progressively decrease over 4 weeks of treatment, with a mean VAS of 0.8±0.8 cm ($P<0.05$) after the final session. This >7-point reduction exceeded the minimal clinically important difference (MCID) of 2.0 for pain. Patient-reported physical and mental health also improved. The PROMIS Global-10 Physical Health score increased from 40.6±5.8 pre-treatment to 51.7±4.0 by Week 4, and the

Mental Health score rose from 46.7±5.3 to 51.1±6.5 (Figure 1B–C). These improvements exceeded the MCID of 3.0 that is commonly reported for this instrument. Follow-up at 3-6 months after therapy indicated that therapeutic gains were well maintained. Of the 25 (89%) who were successfully contacted, all reported treatment outcome satisfaction and denied any recurrence of significant pain. No patients returned to the clinic for SCP-related issues during this follow-up period.

These findings demonstrate that a multimodal protocol (Supplemental Figure S2) can provide rapid and sustained pain relief and quality of life improvements for men with SCP. While limited by sample size and a lack of a control group, our results align with growing evidence supporting a neuromuscular etiology for many cases of SCP. This study also supports the need for improved collaboration between urologists and musculoskeletal clinicians in the treatment of pelvic pain. Future prospective, randomized controlled trials are warranted to validate these findings and further establish the role of neuromuscular interventions in the treatment of SCP.

References

[1] Sigalos JT, Pastuszak AW. Chronic orchialgia: epidemiology, diagnosis and evaluation. Transl Androl Urol 2017;6:S37–43. https://doi.org/10.21037/tau.2017.05.23.

[2] Levine LA, Abdelsayed GA. Chronic Scrotal Content Pain: A Diagnostic and Treatment Dilemma. J Sex Med 2018;15:1212–5. https://doi.org/10.1016/j.jsxm.2018.07.008.

[3] Parekattil SJ, Gudeloglu A, Brahmbhatt JV, Priola KB, Vieweg J, Allan RW. Trifecta Nerve Complex: Potential Anatomical Basis for Microsurgical Denervation of the Spermatic Cord for Chronic Orchialgia. J Urol 2013;190:265–70. https://doi.org/10.1016/j.juro.2013.01.045.

[4] Wang L, Zhang D, Schwarz W. TRPV Channels in Mast Cells as a Target for Low-Level-Laser Therapy. Cells 2014;3:662–73. https://doi.org/10.3390/cells3030662.

Table 1. Subject demographics. Values are mean±SD. N=28 male subjects.

Demographic	Value
Age (years)	42.1±14.9
BMI (kg/m^2)	29.2±4.9
Symptom Duration (months)	3.5±1.4
Symptom Laterality	Left: 64% Right: 25% Bilateral: 11%
Men With Vasectomy	29%
Prophylactic Antibiotics	46%
High sensitivity C-reactive protein (mg/L)	1.7±0.9
Prostate specific antigen (ng/mL)	1.0±0.9

Table 2. Overview of study time points, treatment interventions, and measurements.

VAS, Visual Analog Scale; PEMF, Pulsed Electromagnetic Field.

Time Point	Treatment Interventions and Measurements
Week 1	NIH PROMIS Global 10, VAS pain pre-treatment, class IV laser, dry needling, PEMF, manual therapy, therapeutic exercises, VAS pain post-treatment
Week 2	VAS pain pre-treatment, class IV laser, dry needling, PEMF, manual therapy, therapeutic exercises, VAS pain post-treatment
Week 3	VAS pain pre-treatment, class IV laser, dry needling, PEMF, manual therapy, therapeutic exercises, VAS pain post-treatment
Week 4	VAS pain pre-treatment, class IV laser, dry needling, PEMF, manual therapy, therapeutic exercises, VAS pain post-treatment, NIH PROMIS Global 10

Figure 1. Changes in VAS Pain and PROMIS Global 10 scores over time. (A) VAS scores, differences were tested with a two-way ANOVA followed by Tukey's multiple comparisons test. Post-hoc sorting: a, significantly different ($P<0.05$) from Week 1 Pre-Treatment; b, significantly different ($P<0.05$) from Week 1 Post-Treatment; c, significantly different ($P<0.05$) from Week 2 Pre-Treatment; d, significantly different ($P<0.05$) from Week 2 Post-Treatment; e, significantly different ($P<0.05$) from Week 3 Pre-Treatment; f, significantly different ($P<0.05$) from Week 3 Post-Treatment; g, significantly different ($P<0.05$) from Week 4 Pre-Treatment. PROMIS Global 10 (B) Physical Health and (C) Mental Health scores. Differences between Week 1 and Week 4 were tested with paired t-tests: a, significantly different ($P<0.05$) from Week 1. N=28 male subjects.

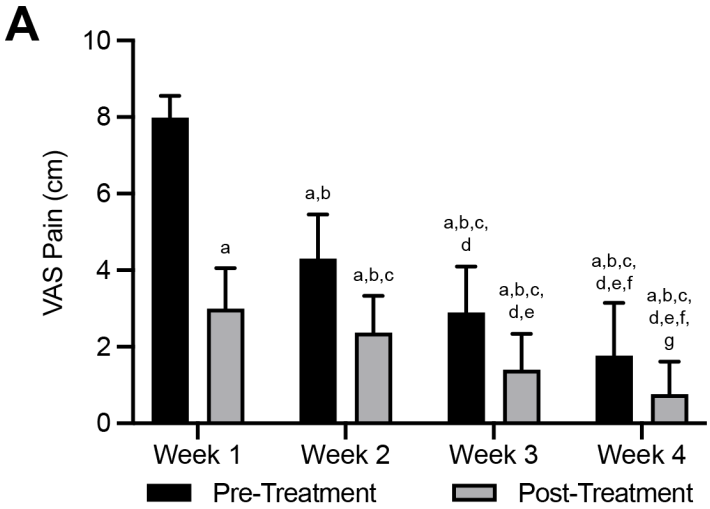

a, different (P<0.05) from Week 1 Pre-Treatment
b, different (P<0.05) from Week 1 Post-Treatment
c, different (P<0.05) from Week 2 Pre-Treatment
d, different (P<0.05) from Week 2 Post-Treatment
e, different (P<0.05) from Week 3 Pre-Treatment
f, different (P<0.05) from Week 3 Post-Treatment
g, different (P<0.05) from Week 4 Pre-Treatment

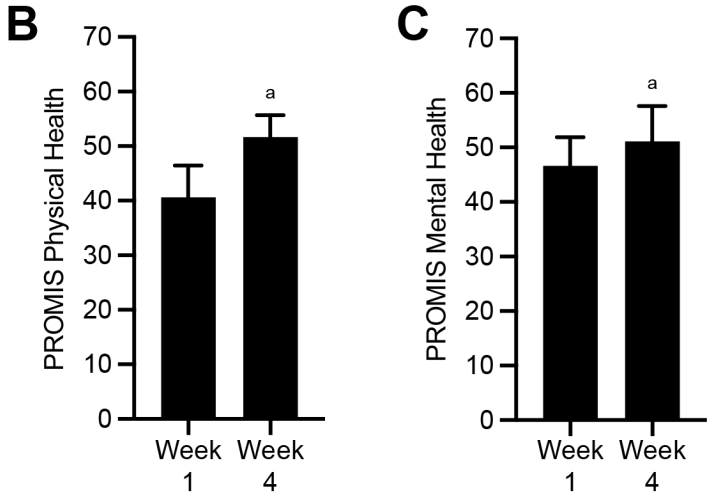

a, different (P<0.05) from Week 1
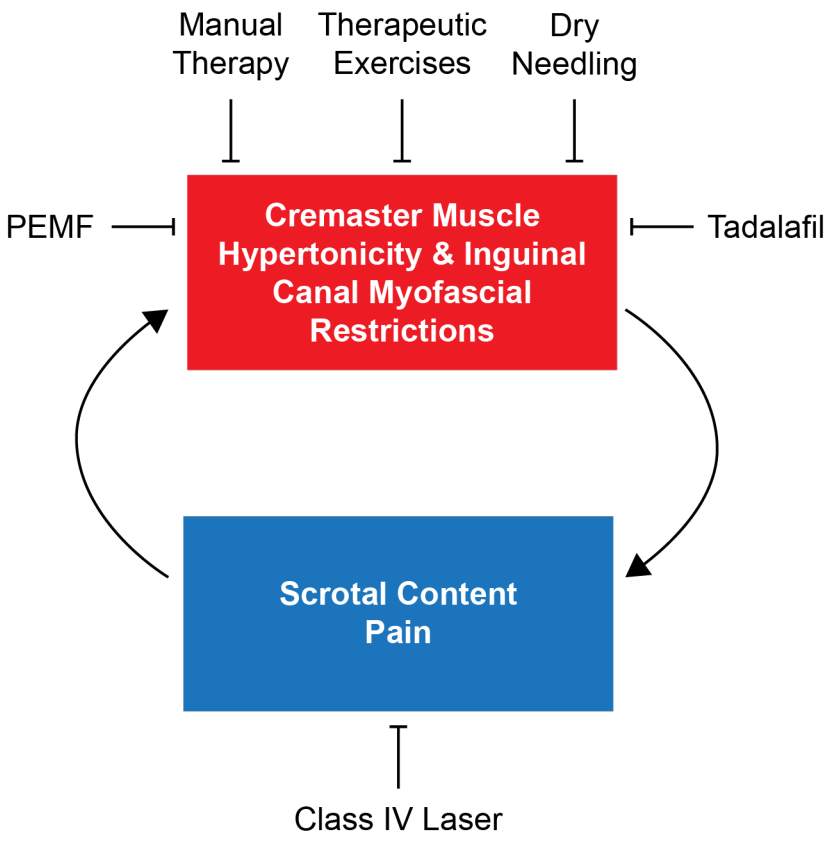
Figure 2. Proposed integrative model of treating scrotal content pain. PEMF, Pulsed electromagnetic field therapy.