Key Histologic Features Distinguish Cytomegalovirus Hepatitis from Acute T-cell Mediated Rejection in Liver Allografts

Shunsuke Koga, MD, PhD, [1] Yusuf Ozcelik, MD, [1] Liping Wang, MD, PhD, [1] Sujani Madabhushi, MD, [1] Kristen M. Stashek, MD, [1] Emma E. Furth, MD, [1] and Rashmi Tondon, MD [1]

1) Department of Pathology and Laboratory Medicine, Hospital of the University of Pennsylvania, Philadelphia, Pennsylvania, USA

Corresponding author:

Shunsuke Koga, MD, PhD

Department of Pathology and Laboratory Medicine

Hospital of the University of Pennsylvania

3400 Spruce Street, Philadelphia,

Pennsylvania, 19104, USA

Email: Shunsuke.koga@pennmedicine.upenn.edu

ORCID: Shunsuke Koga 0000-0001-8868-9700

Manuscript word count: 1275 words

Abstract: None

References: 7

Figure: 1

Table: 1

Keywords: Cytomegalovirus hepatitis; acute cellular rejection, T-cell mediated rejection; liver biopsy; bile duct injury; diagnostic pitfalls; histology.

Abstract

Cytomegalovirus (CMV) is a major opportunistic infection after liver transplantation and often mimics acute T cell-mediated rejection (TCMR), creating management uncertainty. We performed a retrospective study to identify practical histologic features that separate CMV hepatitis from TCMR in routine sign-out. We included 10 recipients with CMV hepatitis and 5 with moderate to severe TCMR. A board-certified pathologist with liver expertise rereviewed available slides and recorded portal inflammation, bile duct injury, venous endotheliitis, lobular microgranulomas, neutrophilic microabscesses, and CMV inclusions; clinical data were abstracted from the record.

CMV hepatitis was diagnosed earlier after transplant than TCMR (272 ± 211 vs 549 ± 522 days). Slides were available for 7 CMV and all 5 TCMR biopsies. In CMV hepatitis, inclusions were present in all reviewed patients; semi-quantitatively, a single inclusion was seen in 3/7 (43%) and >3 inclusions in 4/7 (57%). Venous endotheliitis was present in all cases (7/7, 100%). Portal infiltrates were lymphohistiocytic with rare to occasional eosinophils (7/7, 100%). Lobular microgranulomas were universal (7/7, 100%), with one patient showing well-defined portal and lobular non-necrotizing granulomas. Bile duct injury was none or minimal in 6/7 (86%), and neutrophilic microabscesses were present in 3/7 (43%). In contrast, TCMR biopsies lacked inclusions, microgranulomas, and microabscesses (0/5 each) and showed predominantly lymphocytic portal inflammation with prominent bile duct injury and venous endotheliitis (5/5, 100%). Antiviral therapy was given in 9/10 CMV patients; four were indeterminate for TCMR and one had concomitant TCMR. During follow-up, recurrent CMV occurred in 4/10 and late chronic rejection in 2; no incident CMV viremia occurred in the TCMR group.

A pattern of portal-predominant, histiocyte-rich inflammation with lobular microgranulomas and occasional neutrophilic microabscesses, in the setting of little or no bile duct injury, supports CMV hepatitis over TCMR and can guide targeted inclusion searches and ancillary testing.

Introduction

Cytomegalovirus (CMV) is one of the most significant opportunistic infections after liver transplantation, with the highest risk in donor positive and recipient negative serostatus pairings, and its clinical presentations often overlap with those of acute T-cell mediated rejection.[1] Accurate distinction is critical because initial therapy differs: antiviral treatment for CMV versus increasing immunosuppression for acute T-cell mediated rejection. Misclassification can adversely affect graft outcomes.[2] Histologically, the Banff Working Group schema defines acute T-cell mediated rejection by a triad of portal inflammation, bile duct injury, and venous endotheliitis.[3] Prior studies have described histologic features that raise suspicion for CMV, including lobular microgranulomas and histiocyte-rich inflammation. Presence of classic viral cytopathic inclusions on hematoxylin and eosin (H&E) sections is diagnostic but these inclusions may be sparse, sometimes limited to a single cell.[4] Recent series emphasize that CMV can mimic acute T-cell mediated rejection at low power; therefore a targeted search for inclusions is required to reach the correct diagnosis.[5] To identify practical histologic features that separate CMV hepatitis from acute T-cell mediated rejection during routine sign-out, we conducted a retrospective, single-center study.

Materials and Methods

Study design

We conducted a retrospective, single-center study at the Hospital of the University of Pennsylvania (Philadelphia, Pennsylvania) over a 15-year period. All biopsies had been diagnosed in routine clinical practice by experienced, American Board of Pathology certified anatomic pathologists with expertise in medical liver pathology.

Case selection

We searched the surgical pathology archives and electronic medical record to identify liver allograft biopsies diagnosed as CMV hepatitis and a comparison group with acute T-cell mediated rejection from the same period. CMV hepatitis required CMV cytopathic inclusions on H&E sections; plasma CMV polymerase chain reaction (PCR) results were recorded when available. Acute T-cell mediated rejection controls were randomly selected biopsies reported as moderate to severe per Banff Working Group criteria and had no detectable plasma CMV by PCR at biopsy.

Pathology review and data collection

For all patients with available slides, a single pathologist (RT), board-certified in anatomic pathology and specializing in medical liver pathology, rereviewed H&E sections and recorded histologic features. The variables included portal inflammation, bile duct injury, venous endotheliitis in both portal and central veins, lobular microgranulomas, neutrophilic microabscesses, and CMV inclusions. Clinical information was abstracted from the medical record. Clinical variables included age, sex, indication for transplantation, donor/recipient CMV serostatus, time from transplant to biopsy, CMV prophylaxis, prior or subsequent episodes of CMV or T-cell–mediated rejection, treatments at the index biopsy (antiviral and/or antirejection), and follow-up outcomes (incident or recurrent CMV and chronic rejection).

Results

Cohort characteristics

We analyzed 10 recipients with CMV hepatitis and 5 with acute T-cell mediated rejection. Baseline demographics, serostatus, CMV prophylaxis, and key histologic features are summarized in **Table 1**. In the CMV group, primary sclerosing cholangitis was the most

frequent indication for transplantation (4/10 patients), followed by non-alcoholic steatohepatitis, autoimmune hepatitis, alcoholic cirrhosis, primary biliary cholangitis, and hepatitis C (1 patient each), with 1 patient classified as unknown. In the acute T-cell mediated rejection group, alcoholic cirrhosis was the most common indication (3/5 patients), followed by autoimmune hepatitis and hepatitis C (1 patient each). Overall, CMV hepatitis was diagnosed earlier after transplantation than acute T-cell mediated rejection (272 ± 211 vs. 549 ± 522 days), and plasma CMV was detectable only in the CMV group.

Histopathology

Slides were available for 7 CMV and all 5 T-cell mediated rejection biopsies. In CMV hepatitis, all reviewed patients showed CMV inclusions on H&E; semi-quantitatively, a single inclusion was present in 3 of 7 patients (43%) and more than three inclusions in 4 of 7 (57%). Endotheliitis was present in all 7 patients. The portal infiltrate was lymphohistiocytic with rare to occasional eosinophils (7/7, 100%), and lobular microgranulomas were identified in every patient (7/7, 100%); one patient shows well-defined portal and lobular non-necrotizing granulomas (14%). Bile duct injury was none or minimal in 6 of 7 patients (86%). Neutrophilic microabscesses were present in 3 of 7 (43%). In contrast, acute T-cell mediated rejection biopsies showed no CMV inclusions, microgranulomas, or neutrophilic microabscesses, and instead demonstrated predominantly lymphocytic portal inflammation with prominent bile duct injury (5/5, 100%), and venous endotheliitis (5/5, 100%).

Management and follow-up

Antiviral therapy was given in 9 of 10 CMV patients. In the CMV group, due to overlapping histological features, four patients were diagnosed as indeterminate for acute T-cell

mediated rejection, and one with concomitant acute T-cell mediated rejection. Antirejection therapy was administered in 3 patients with indeterminate category, whereas the single patient with a diagnosis of concomitant T-cell mediated on histology did not receive such therapy. All acute T-cell mediated rejection controls received antirejection therapy. During follow-up, recurrent CMV was documented in four patients in the CMV group; among these, two patients subsequently developed late chronic rejection. No CMV viremia was observed in the acute T-cell mediated rejection group.

Representative Case

Among the CMV group, one illustrative example was a man in his 60s transplanted for autoimmune hepatitis and metabolic-associated steatohepatitis. Within the first year after transplantation, he presented with malaise and elevated liver enzymes. Liver biopsy revealed moderate inflammatory infiltrates composed of lymphocytes, eosinophils, neutrophils, and macrophages with bile duct injury and interface activity (**Figure 1A**), initially suggestive of acute T-cell–mediated rejection. Lobular activity with poorly formed non-necrotizing granulomas was also present. On careful examination, a single epithelial cell with intranuclear and intracytoplasmic inclusions characteristic of CMV infection was identified (**Figures 1B-C**), establishing the diagnosis of CMV hepatitis. Plasma CMV PCR was positive, and combined antiviral and steroid therapy led to clearance of viremia and normalization of liver enzymes, with stable graft function thereafter.

Discussion

These findings support a practical combination of histologic features that should raise suspicion for CMV during histological assessment: portal-predominant inflammation with a histiocyte-rich component, lobular microgranulomas, and neutrophilic microabscesses in the

setting of little or no bile duct injury. Because venous endotheliitis occurred in both groups, it was not discriminatory in our material and should be interpreted with bile duct changes and the lobular context.[6] We found presence or absence of bile duct injury as the most helpful clue in differentiating the two entities. In practice, when this pattern is present, deeper levels and a careful search for inclusions are warranted, with a low threshold for CMV immunohistochemistry or plasma PCR when morphology is equivocal.[4, 5, 7] We also observed discordance between pathology reports and therapy. Some patients without definite acute T-cell mediated rejection received antirejection treatment, while one diagnosed with acute T-cell mediated rejection did not. Together with recurrent CMV viremia and subsequent chronic rejection in a minority of patients, these patterns highlight the need to integrate pathology with contemporaneous virology when treatment decisions are made.[2]

The strengths of this study include consistent biopsy handling at a single institution, review by a board-certified pathologist with expertise in medical liver pathology, and the use of predefined histologic variables from Banff schema, which improves reproducibility. Linking histology to treatment and short-term outcomes further highlights the clinical impact of initial classification. Limitations include the retrospective design, single-observer non-blinded rereview, small cohort, incomplete slide availability in some CMV patients, and descriptive analysis. Sampling variability is a concern because inclusions may be very focal, and CMV immunohistochemistry was not consistently performed throughout the study period. The control group included only patients with moderate to severe acute T-cell mediated rejection who were CMV PCR negative, which clarified the contrast with CMV hepatitis but excluded the rare situation of concurrent CMV infection and clinically significant rejection. Larger, prospective studies are warranted.

In summary, our findings support a pattern-based framework that emphasizes bile duct injury, portal infiltrate composition, and lobular clues. This approach may reduce

unnecessary immunosuppression and enable timely antiviral therapy, improving graft outcomes.

Acknowledgments

We acknowledge the contributions of the pathology assistants and residents in the Department of Pathology and Laboratory Medicine at the Hospital of the University of Pennsylvania for their efforts in specimen preparation.

Author Contributions

Shunsuke Koga interpreted the data and drafted the manuscript. Yusuf Ozcelik, Lipin Wang, and Sujani Madabhushi collected and curated the clinical and pathological data. Kristen M. Stashek reviewed and verified the histologic assessments. Emma E. Furth reviewed and verified the histologic assessments and provided critical review and revisions. Rashmi Tondon conceptualized the project, evaluated the pathological findings, and provided critical review and revisions. All authors approved the final version of the manuscript.

Ethical Approval

This study was approved by the Institutional Review Board at the Hospital of the University of Pennsylvania, meeting exemption criteria (category 4) with a HIPAA waiver. This study was conducted in accordance with the Declaration of Helsinki 1975.

Informed Consent

In accordance with institutional policy, the hospital obtains general consent at the time of care that permits secondary research use of de-identified clinical data and archived

pathology material; therefore, the Institutional Review Board waived the requirement for study-specific informed consent.

Declaration of Conflicting Interests

None declared.

Funding

This study did not receive any funding.

Data Availability Statement

All data produced in the present study are available upon reasonable request to the authors.

References

1. Lizaola-Mayo, BC, Rodriguez, EA. Cytomegalovirus infection after liver transplantation. *World J Transplant*. Jul 29 2020;10(7):183-190. doi:10.5500/wjt.v10.i7.183

2. Razonable, RR, Humar, A. Cytomegalovirus in solid organ transplant recipients-Guidelines of the American Society of Transplantation Infectious Diseases Community of Practice. *Clin Transplant*. Sep 2019;33(9):e13512. doi:10.1111/ctr.13512

3. Demetris, AJ, Bellamy, C, Hubscher, SG, et al. 2016 Comprehensive Update of the Banff Working Group on Liver Allograft Pathology: Introduction of Antibody-Mediated Rejection. *Am J Transplant*. Oct 2016;16(10):2816-2835. doi:10.1111/ajt.13909

4. Colina, F, Juca, NT, Moreno, E, et al. Histological diagnosis of cytomegalovirus hepatitis in liver allografts. *J Clin Pathol*. Apr 1995;48(4):351-7. doi:10.1136/jcp.48.4.351

5. Shih, AR, Naini, BV, Westerhoff, M, Alpert, L, Masia, R, Misdraji, J. Cytomegalovirus Hepatitis in Allograft Livers May Show Histologic Features of Acute Cellular Rejection. *Arch Pathol Lab Med*. Jun 1 2023;147(6):655-664. doi:10.5858/arpa.2021-0551-OA

6. Shi, Y, Dong, K, Zhang, YG, et al. Sinusoidal endotheliitis as a histological parameter for diagnosing acute liver allograft rejection. *World J Gastroenterol*. Feb 7 2017;23(5):792-799. doi:10.3748/wjg.v23.i5.792

7. Lamps, LW, Pinson, CW, Raiford, DS, Shyr, Y, Scott, MA, Washington, MK. The significance of microabscesses in liver transplant biopsies: a clinicopathological study. *Hepatology*. Dec 1998;28(6):1532-7. doi:10.1002/hep.510280613

Table 1. Clinicopathologic features of cytomegalovirus hepatitis versus acute T-cell mediated rejection in liver allograft biopsies

Variable	CMV hepatitis (n=10)	Acute TCMR (n=5)
Age, mean (SD), years	56 (9)	50 (10)
Male sex, n (%)	7 (70%)	4 (80%)
Time from transplant to biopsy, mean (SD), days	272 (211)	549 (522)
Donor/recipient serostatus	D+/R-: 5; others: 5	D+/R-: 2; others: 3
CMV prophylaxis	9/10 (90%)	5/5 (100%)
CMV PCR positive at biopsy	7/7 (100%)	0/5 (0%)
Histology (slides reviewed)	7/10 (70%)	5/5 (100%)
Bile duct injury	Minimal to none in 6/7 (86%)	Prominent in all
Portal infiltrate	Lymphohistiocytic	Lymphocytic
Endotheliitis	7/7 (100%)	5/5 (100%)
Microgranulomas	7/7 (100%)	0/5 (0%)
Neutrophilic microabscesses	3/7 (43%)	0/5 (0%)
CMV inclusions	7/7 (100%)	0/5 (0%)
Diagnosis of TCMR	Present: 1; indeterminate: 4; none: 5	Present: 5
Treatment	Antiviral: 9/10; TCMR therapy also in 3 patients without definite TCMR	TCMR therapy in all
Follow-up	Recurrent CMV: 4/10 (1 indeterminate, 2 late chronic rejection)	No CMV viremia

Abbreviations: CMV, cytomegalovirus; TCMR, T-cell mediated rejection; D+/R−, donor-positive/recipient-negative for CMV IgG serostatus; PCR, polymerase chain reaction; H&E, hematoxylin and eosin.

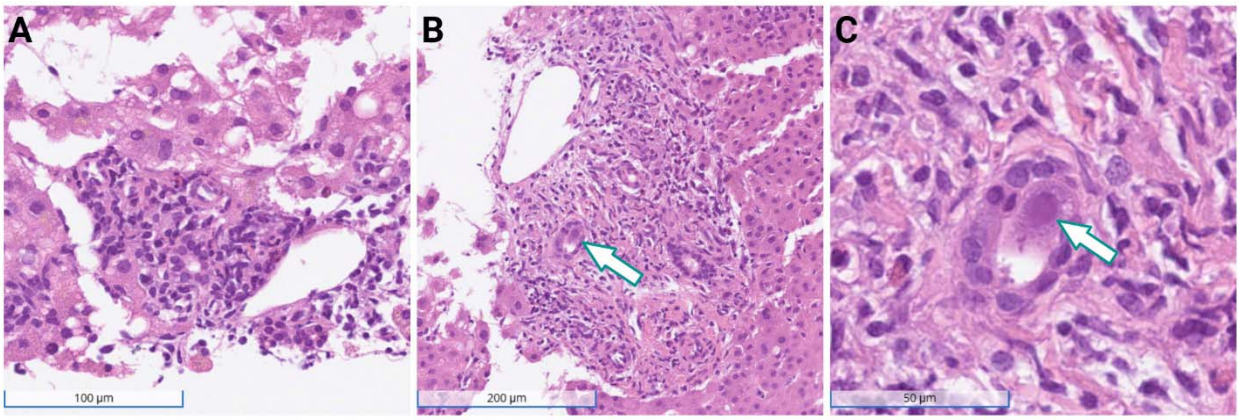

Figure 1. Cytomegalovirus hepatitis in a liver allograft biopsy

H&E shows (A) portal mixed inflammation with bile duct injury and interface activity, mimicking T-cell–mediated rejection. (B-C) A single epithelial cell with intranuclear and intracytoplasmic CMV inclusions (arrow), shown at lower (B) and higher (C) magnification.

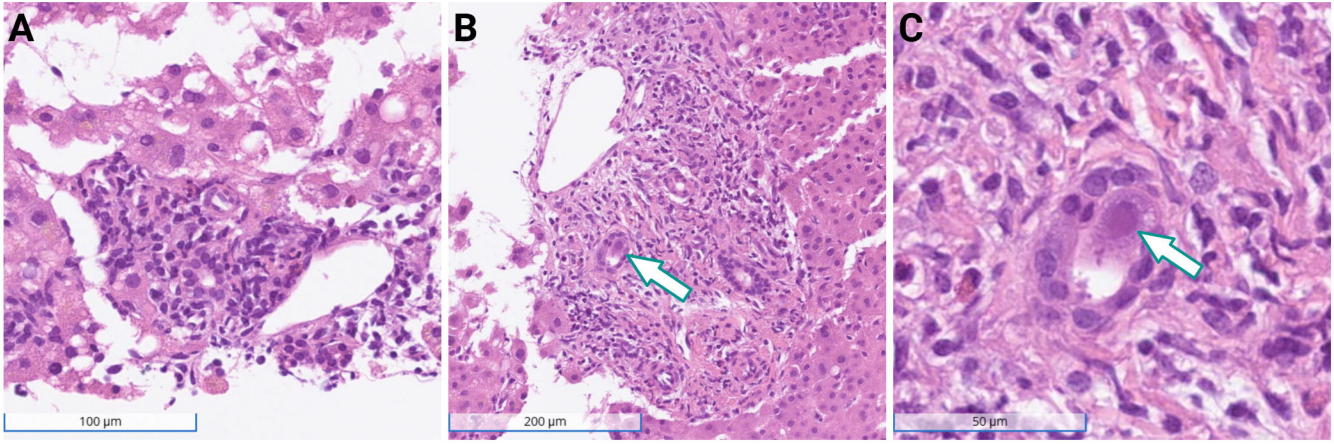
A
100 µm
B
200 µm
C
50 µm