Dolichocolon as a Potential Modifier of Pediatric Ulcerative Colitis Phenotype

Richard Kellermayer, MD, PhD[1,2]*, Donovan Berens, MD[1], Réka G. Szigeti, MD, PhD[3]

[1] Division of Pediatric Gastroenterology, Texas Children's Hospital, Baylor College of Medicine, Houston, TX, USA
[2] USDA/ARS Children's Nutrition Research Center, Houston, TX, USA
[3] Department of Pathology & Genomic Medicine, Houston Methodist Hospital, Houston, TX, USA

Conflict of interest: None to declare
Sources of funding: No direct funding was received for this work
Graphic abstract: Created with BioRender by D. Berens
Acknowledgements: R.K. was supported by the Gutsy Kids Fund, graciously maintained by Brock Wagner, the Klaasmeyers, the Frugonis, and other generous donor families.
Declaration of generative AI and AI-assisted technologies in the writing process: ChatGPT was used to decrease word count and enhance readability; content was reviewed and edited by the author(s), who take full responsibility.

Address correspondence to: Richard Kellermayer; Section of Pediatric Gastroenterology, Hepatology & Nutrition, Baylor College of Medicine; 6621 Fannin St., CC1010.00; Houston, TX 77030-2399; Voice: 713-798-0319; Fax: 832-825-3633; Email: kellerma@bcm.edu

Keywords: children, redundant colon, phenotype modifier, constipation, inflammatory bowel disease

Abstract

Dolichocolon (DC), an underrecognized anatomic variant characterized by colonic redundancy, is strongly linked to constipation. Its potential role in modifying inflammatory bowel disease phenotype has not been examined. We retrospectively evaluated pediatric patients with ulcerative colitis (UC) who underwent magnetic resonance enterography. DC was significantly more common in UC compared with Crohn's disease and non-IBD controls, even in the absence of constipation. Subtype distribution differed by disease extent: Type 1 DC predominated in proctitis/left-sided UC (E1/E2), whereas Type 2 DC was enriched in extensive/pancolitis (E3/E4). Complex DC (Types 1+2) was uniquely observed in UC. These findings suggest that DC may influence the anatomic localization and persistence of UC by altering colonic architecture, epithelial surface exposure, and host–microbe interactions. DC may thus represent a congenital or developmental modifier of UC phenotype in children, warranting further investigation.

Dolichocolon (DC), an underrecognized anatomical variant characterized by redundancy of the large intestine, is strongly associated with functional constipation in both pediatric[1] and adult[2] populations. In adults, DC has been subclassified into three types: cranial displacement of the sigmoid loop relative to the iliac crests (Type 1), caudal displacement of the transverse colon below the iliac crests (Type 2), and redundant loops at the hepatic or splenic flexures (Type 3)[2]. Due to ambiguity in defining Type 3 DC, we have historically limited diagnostic consideration in pediatric cases to Types 1 and 2. Our recent findings (under review in JPGN) support previous observations suggesting DC is typically congenital in children, whereas it may also develop secondarily in older adults with increasing colonic stiffness and longstanding constipation.

A recent study found that pediatric patients with ulcerative colitis (UC), particularly those with proctitis (E1) or left-sided colitis (E2), had a higher prevalence of constipation compared to those with extensive (E3) or pancolitis (E4)[3] (Fisher's exact test [FE] $p = 0.0116$), or Crohn's disease (CD) (FE $p = 0.0272$), aligning with our own clinical observations.

Given the association between DC and pediatric constipation, we examined whether DC may contribute to the pathogenesis or localization of UC in children. We identified 39 pediatric patients with E1/E2 UC (Paris classification[4]) who had undergone diagnostic magnetic resonance enterography (MRE) and exhibited no disease progression towards extensive UC for at least six months. Of these, 22 (56 %) had a documented history of constipation, compared to 7 of 27 (26 %) in the E3/E4 UC group (FE $p = 0.0226$). However, the prevalence of DC on MRE did not

differ significantly between E1/E2 (69 %) and E3/E4 (52 %) groups (FE p = 0.1993), nor between constipated and non-constipated E1/E2 patients (73 % vs. 65 %, p = 0.7302).

To further assess the potential association of DC with UC, we compared DC prevalence (including subtype distribution) across non-constipated patients with E1/E2 UC, E3/E4 UC, L3 Crohn's disease, and non-IBD (without inflammatory bowel disease [IBD] or other documented chronic disorder) trauma controls with normal intestinal anatomy on CT by report (Supplemental Table 1). DC was significantly more common in both E1/E2 and E3/E4 UC groups compared to L3 CD and non-IBD controls (Figure 1A). Notably, combinations of Type 1 and Type 2 DC (Figure 1B) were observed exclusively in UC patients, with none identified in CD or control cohorts. The increased prevalence of DC in E1/E2 UC was primarily attributable to Type 1 DC, whereas Type 2 DC was more prominent in the E3/E4 UC group (Figure 1C). The frequency of isolated Type 3 DC, which we excluded from primary analysis due to definitional ambiguity, was similar across all groups (Supplemental Table 1). The study was performed under institutional IRB-approved protocols (H-43969, H-50062).

These findings suggest that DC, even in the absence of clinically significant constipation, may influence the anatomic distribution of UC. Our findings indicate that Type 1 DC may promote left-sided disease, while Type 2 DC may predispose to extensive or pancolitis, possibly by directing inflammatory processes to specific colonic regions (Figure 1C). As DC results in increased colonic length without corresponding increases in volume[2], it may expand epithelial surface area and

augment host-microbiome interactions[5], which may induce autoimmunity in susceptible segments[6]. Segmental redundancy may lead to intermittent mechanical kinking and fluctuating epithelial oxygenation in the colon, potentially amplifying localized inflammation[7] and favoring a UC phenotype over CD in genetically and environmentally predisposed individuals.

While UC and CD share many genetic and environmental risk factors[8], our observations are, to our knowledge, the first to implicate DC as a potential developmental modifier of UC phenotype in over 50 % of the cases. These findings may help explain not only the development of UC in the context of IBD susceptibility but also the persistence of segment-specific disease. Further investigation is warranted to elucidate the mechanistic and clinical implications of DC in IBD pathogenesis.

Our discovery findings, however, set the nidus for potential interventions that may prevent the development of UC in those children at increased risk for the disease, such as those with first-degree relatives suffering from IBD[9]. Early recognition of DC in such children may improve adherence to dietary, lifestyle, and bowel-management interventions—strategies that can optimize colonic function and potentially reduce UC risk.

Figure legends

Figure 1. Dolichocolon (DC) may modify pediatric ulcerative colitis phenotype. A. DC was significantly more commonly present in E1/2 UC (n=17), and E3/4 UC (n=20), than in patients with ileocolonic (L3, n=20) Crohn's disease (CD), or otherwise healthy patients with blunt force abdominal trauma (control: Ctrl; n=25). B. Complex DC (Type 1 and Type 2 simultaneously, as demonstrated in a case on the MRI enterography image) was uniquely present only in patients with UC in this cohort. C. The prevalence of Type 1 vs. Type 2 DC (alone or in combination) significantly separated E1/2 UC from E3/4 UC, respectively. P values demonstrated on the figures were calculated in GraphPad Prism (Dotmatics, 225 Franklin Street, Floor 26 Boston, MA 02110, USA) by Fischer's exact testing.

References

1. Vattimo A, Burroni L, Bertelli P, et al. Total and segmental colon transit time in constipated children assessed by scintigraphy with 111In-DTPA given orally. J Nucl Biol Med. 1993 Dec;37(4):218-22. PMID: 8172963.
2. Dilmaghani S, Lupianez-Merly C, Fetzer J, et al. Colon volume by computed tomography and scintigraphic colonic transit in constipated patients with or without redundant colon. Clin Gastroenterol Hepatol. 2024 Nov;22(11):2327-2329.e2. doi:10.1016/j.cgh.2024.04.009. PMID: 38697236.
3. Cenni S, Colucci A, Salomone S, et al. The prevalence of constipation in children with new diagnosis of inflammatory bowel disease: a retrospective study. J Pediatr Gastroenterol Nutr. 2025 May;80(5):799-806. doi:10.1002/jpn3.70005. PMID: 39935294.
4. Levine A, Griffiths A, Markowitz J, et al. Pediatric modification of the Montreal classification for inflammatory bowel disease: the Paris classification. Inflamm Bowel Dis. 2011 Jun;17(6):1314-21. doi:10.1002/ibd.21493. PMID: 21560194.
5. Kellermayer R, Zilbauer M. The gut microbiome and the triple environmental hit concept of inflammatory bowel disease pathogenesis. J Pediatr Gastroenterol Nutr. 2020 Nov;71(5):589-95. doi:10.1097/MPG.0000000000002908. PMID: 33093364.
6. Nagy-Szakal D, Hollister EB, Luna RA, et al. Cellulose supplementation early in life ameliorates colitis in adult mice. PLoS One. 2013;8(2):e56685. doi:10.1371/journal.pone.0056685. PMID: 23437211.
7. Campbell EL, Colgan SP. Oxygen metabolism and innate immune responses in the gut. J Appl Physiol (1985). 2018 Feb 1;124(2):353-60. doi:10.1152/japplphysiol.01075.2017. PMID: 28705991.
8. Kellermayer R. Challenges for epigenetic research in inflammatory bowel diseases. Epigenomics. 2017 Apr;9(4):527-38. doi:10.2217/epi-2016-0155. PMID: 28343422.

9. Kim HJ, Hann HJ, Hong SN, et al. Familial Risk of Inflammatory Bowel Disease, Based on a Population Cohort Study in South Korea. Clin Gastroenterol Hepatol. 2021;19(5):983–991.e4. doi:10.1016/j.cgh.2020.09.036. PMID 33010407.

A.

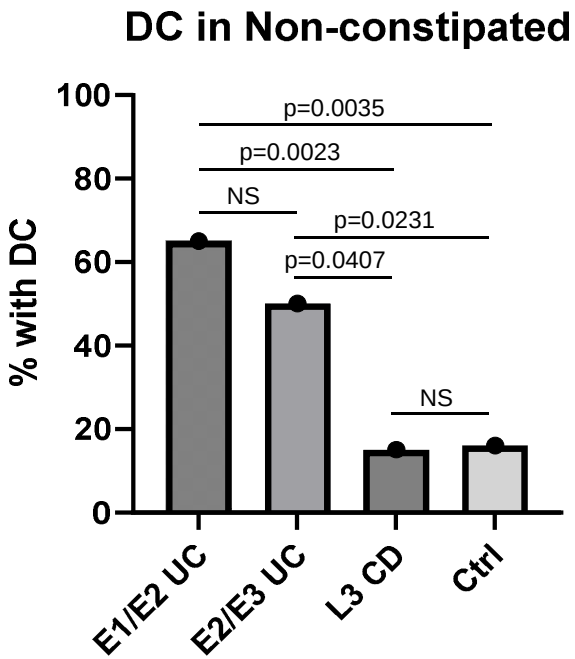

B.

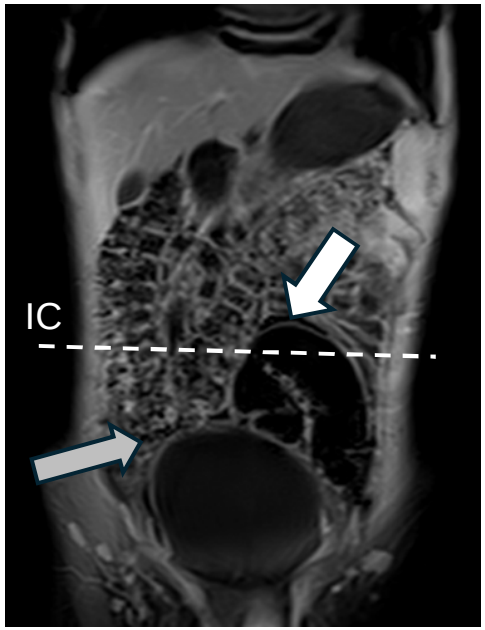

Type 1 DC

Type 2 DC

IC Iliac crests line
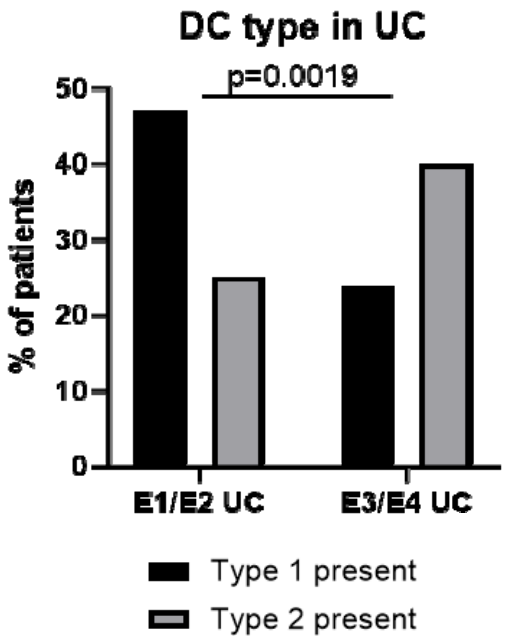
C.