Multi-omic profiling of atherosclerosis: protocol and pilot data for the AtherOMICS biobank

Luka Živković[1], Roya Batool[1], Julian Louma[1], Paulo Vinicius Gil Alabarse[1], Yingle Li[1], Lanyue Zhang[1], Stefan Mayrhofer[1], Anushree Ray[1], Mohamad Ali Antabi[1], Panagiotis Zangas[1], Jana Mattar[1], Anna Kopczak[1], Andreas Schindler[2], Paul Reidler[3], Yaw Asare[1], Steffen Tiedt[1,4,5], Lars Kellert[4], Barbara Rantner[6], Martin Dichgans[1,5,7], Nikolaos Tsilimiparis[6], Marios K. Georgakis[1,4,8]

[1] Institute for Stroke and Dementia Research (ISD), University Hospital, LMU Munich, Munich, Germany

[2] Institute of Neuroradiology, University Hospital, LMU Munich, Munich, Germany

[3] Department of Radiology, University Hospital, LMU Munich, Munich, Germany

[4] Department of Neurology, University Hospital, LMU Munich, Munich, Germany

[5] Munich Cluster for Systems Neurology (SyNergy), Munich, Germany

[6] Department of Vascular Surgery, University Hospital, LMU Munich, Munich, Germany

[7] German Centre for Neurodegenerative Diseases (DZNE), Munich, Germany

[8] Program in Medical and Population Genetics and Cardiovascular Disease Initiative, Broad Institute of MIT and Harvard, Cambridge, MA, USA

Correspondence to:

Marios K. Georgakis, MD, PhD
Institute for Stroke and Dementia Research, University Hospital LMU
Ludwig-Maximilians-University (LMU), Munich, Germany
Feodor-Lynen-Str. 17, 81377 Munich, Germany
Telephone: +49-89-4400-46154; Fax: +49-89-4400-46148
e-mail: marios.georgakis@med.uni-muenchen.de

Abstract

Omics technologies enable deep profiling of human atherosclerosis, but have mostly been applied in small studies lacking integration with other data modalities. AtherOMICS is a biobanking project linking multi-omic atherosclerotic plaque phenotyping with blood biobanking, in vivo imaging, and clinical data. Since August 2022, 212 patients scheduled to undergo carotid or femoral endarterectomy at LMU Klinikum (Munich, Germany), have been enrolled (median age 73 years, 30.5% female). Plaques undergo systematic histological characterization of lipid core, calcification, intraplaque hemorrhage, fibrous cap, macrophages, and smooth muscle cells. Single-nuclei RNAseq (n=17) has highlighted macrophages as the dominant intraplaque cell type, whereas paired plaque and plasma affinity-based proteomics (n=88) quantified 2,841 shared proteins showing low plaque-plasma correlation (median ρ=0.10). Cross-modality image integration (histology, *ex vivo* MRI, *in vivo* MRI, CTA) proved feasible. Taken together, AtherOMICS enables multimodal characterization of human atherosclerosis aiming for the discovery of athero-specific drug targets, molecular signatures of atheroprogression, and non-invasive biomarkers of plaque vulnerability.

Introduction

Atherosclerotic cardiovascular disease remains the leading cause of mortality and adult disability worldwide.[1] Despite the widespread adoption of prevention strategies targeting systemic vascular risk factors, the incidence of atherosclerotic cardiovascular disease is rising. The destabilization of atherosclerotic plaques is the main mechanism underlying myocardial infarction, ischemic stroke, and cardiovascular death. Decades of research have identified cellular phenotypes and molecular effectors in the plaque microenvironment associated with atheroprogression and plaque destabilization.[2, 3] A deeper understanding of these mechanisms could reveal novel therapeutic targets, as has been demonstrated by the development of anti-inflammatory atheroprotective strategies that were largely informed by studies on plaque biology.[4-6]

However, the mechanisms driving atheroprogression in humans remain underexplored.[7, 8] Most mechanistic studies leverage animal models of atherosclerosis, which often fail to translate to humans.[9] For instance, different genetic underpinnings in murine and human atheroprogression, result in differential plaque compositions and an absence of plaque rupture in mice, highlighting the need to prioritize the use of human biomaterials in atherosclerosis research.[10, 11] Also, current concepts of human atheroprogression are largely informed by histopathological studies conducted in the 1960s and 70s[12, 13]. Since then, significant advances in biotechnology have enabled high-resolution investigations at the cellular and subcellular levels, uncovering previously unknown molecular regulators of atheroprogression.[14-17] Deep, multi-omic phenotyping could offer a powerful approach to dissect these mechanisms and thus inform future therapeutic approaches.[18, 19]

Advancing therapies that target plaque biology requires diagnostic and risk stratification tools capable of capturing local plaque progression.[20] While best practices emphasize the need for personalized risk assessment, existing risk stratification tools build on systemic cardiovascular risk factors rather than changes within the plaque microenvironment.[21, 22] Readily available, noninvasive imaging modalities, such as ultrasonography, CT angiography (CTA) and magnetic resonance imaging (MRI) can reliably identify atherosclerotic plaques and assess basic composition features.[23, 24] Similarly, omics technologies could help detect circulating signatures of plaque destabilization.[17] Developing imaging and circulating biomarkers of plaque stability could refine patient selection for targeted therapies and treatment response monitoring.[25] However, efforts to link *in vivo* imaging and circulating molecular signatures with extensive phenotyping of the plaque microenvironment remain limited.[26]

To address these gaps, we have launched AtherOMICS, a biobanking study that integrates deep phenotyping of human atherosclerotic plaques with peripheral blood biobanking, multimodal *in vivo* non-invasive imaging, and clinical data collection. We perform extensive

histopathological and omics analyses in plaque samples from patients undergoing carotid or femoral endarterectomy and integrate the derived data with matched preoperative blood samples and *in vivo* plaque imaging. The objectives of AtherOMICS are: To (1) identify druggable molecular mechanisms driving plaque progression; (2) detect molecular signatures of plaque destabilization; and (3) develop circulating and imaging biomarkers of plaque vulnerability.

Methods

Study overview

A detailed version of the study protocol and procedures of the AtherOMICS study is available in the **Supplementary Methods**. AtherOMICS has been approved by the Ethics Committee of the Faculty of Medicine of the Ludwig-Maximilians-Universität (LMU) in Munich, Germany (protocol numbers: 121-09, 22-0135, 23-0772). All participants have provided written informed consent and the study conforms to the ethical guidelines of the 2008 Declaration of Helsinki. Data storage is conducted exclusively on servers under EU jurisdiction and in compliance with data protection regulations.

Recruitment for AtherOMICS began in August 2022 and includes (**Fig. 1**):

- Plaque biobanking: Plaque material removed during carotid or femoral endarterectomy is collected and processed for histology, *ex vivo* MRI, and omics analyses.
- Blood biobanking: Peripheral blood is collected from eligible participants before undergoing endarterectomy.
- Clinical data collection: Demographic, anthropometric, medical and medication history, and laboratory data are collected from eligible participants and their medical files.
- *In vivo* imaging: CTAs and brain MRIs are obtained from clinical routine diagnostics. Additionally, consenting participants undergo high-resolution study-specific carotid MRI prior to surgery.

Study participants

The target population of AtherOMICS includes adults scheduled to undergo carotid or femoral endarterectomy due to atherosclerotic disease. Participants are consecutively recruited from the Vascular Surgery and Neurology Departments at the LMU University Hospital in Munich, Germany. Reasons for referral are symptomatic or asymptomatic internal carotid artery stenosis and symptomatic peripheral artery disease due to stenotic lesions in the femoral artery. Study team members identify potentially eligible participants by daily screening of hospital admission records and surgery plans. The inclusion criteria for the biobank are:

1. Adults (age ≥ 18 years)

2. Scheduled for carotid or femoral endarterectomy in the next 7 days
3. Provision of written informed consent for the study prior to participation

The exclusion criteria are:

1. Inability or unwillingness to provide written informed consent
2. Presence of restenosis after previous endarterectomy or stenting
3. Carotid or femoral stenosis following local radiation therapy

Participants scheduled for carotid endarterectomy providing consent for inclusion in the biobank are additionally invited to participate in *in vivo* imaging assessment with carotid MRI prior to surgery. Team members performing eligibility screening are bound to uphold data protection requirements. A physician trained in Good Clinical Practice oversees screening activity and ultimately determines eligibility.

Plaque biobanking

Plaque material is collected directly from the operational room during endarterectomy with the goal of minimizing time from excision to collection. Details on sample handling and processing are provided in the **Supplementary Methods**. Each sample is dissected into 5 mm-long segments centered around the segment exhibiting the highest degree of atherosclerotic burden, as represented by plaque thickness (**Suppl. Fig. I**). The central segments undergo *ex vivo* MRI scanning and histological processing for morphological plaque characterization, while the surrounding sections are flash-frozen and transferred to long-term storage (-80°C) for omics analyses. Within one to four days post-excision, the central segments are scanned with a 3T small animal scanner (nanoScan PET/MRI, Mediso, Münster, Germany) for deeper plaque characterization. Following a previously described protocol, quantitative T1/T2/T2* mapping sequences (qT1, qT2, qT2*) and multi-contrast fast-spin echo (FSE) sequences including T1, T2, T2*, and proton-density (PD) weighted images are acquired in axial orientation (**Suppl. Table I**).[27] The central segments are subsequently decalcified and embedded in paraffin for histological processing at the Core Facility Pathology & Tissue Analytics, Helmholtz Munich, Germany. In serial sections of 5µm thickness in 1mm intervals, stainings are performed with H&E, Picrosirius Red (for collagen), and immunohistochemistry using anti-alpha-smooth-muscle-actin (αSMA; smooth muscle cells) and anti-CD68 antibodies (macrophages). The slides are scanned at high resolution with a microscope (Carl Zeiss NTS Ltd., Oberkochen, Germany). Plaque features are annotated and quantified following a standard protocol (**Supplementary Methods**). The extracted features include total plaque area, lipid core area, calcification area, presence and extent of neovascularization, presence and size of intraplaque hemorrhage, fibrous cap thickness, collagen, macrophage and smooth muscle cell (SMC) content.

Blood biobanking

Peripheral blood is collected from study participants prior to surgery. Serum and plasma aliquots are kept in long-term storage (-80°C) for further analyses, while whole blood is used for DNA extraction. The detailed protocols are available in the **Supplementary Methods**.

Demographic and clinical data collection

Study participants undergo a structured interview (**Suppl. Table II**) followed by inspection of their electronic health record files. We record detailed information on sociodemographic data, cardiovascular risk factors, biosampling, indication for surgery, medical history, current medications, and the most recent laboratory assessments from clinical routine (**Suppl. Table III**).

In vivo imaging

We collect vascular and brain imaging studies from the electronic records of the study participants. Specifically, we export pseudonymized imaging stacks in DICOM format from the most recent carotid CTA and brain MRI performed before the endarterectomy. The scans are acquired pre-surgery during routine clinical assessment and scanner brand and parameter settings vary across patients.

Eligible participants are additionally invited to a pre-surgery high-resolution MRI of the carotid arteries and brain in the context of an imaging study nested within AtherOMICS (**Supplementary Methods**). The imaging protocol is based on a previous study[28] and includes time-of-flight MR angiography (TOF-MRA), pre- and post-contrast black-blood T1-, PD- and T2-weighted sequences with fat suppression. Scans are performed on a 3T device (Magnetom Prisma, Siemens Healthineers, Erlangen, Germany) using a routine 32-channel head coil and two 4-channel, special-purpose carotid coils. A physician assesses whether contraindications for MRI are present and obtains separate written, informed consent from the participant. Participants unwilling or unable to undergo MRI can still participate in the biobank through collection of plaque material, blood samples, and clinical data.

Omics profiling

Fresh frozen plaque samples, as well as serum and plasma samples are stored for further omics analyses. To date we have pursued single-nuclei RNA sequencing (snRNAseq) and affinity-based proteomics and plan to expand to genotyping, bulk RNA sequencing, and spatial transcriptomics (**Supplementary Methods**). For snRNAseq, frozen plaque samples were lysed and mechanically dissociated to extract nuclei. Then, nuclei were captured using barcoded gel beads prior to reverse transcription and cDNA amplification. Proteomic profiling was performed using Olink's Explore 3072 © proximity extension assay. Briefly, stabilized lysates from frozen

plaque sections were incubated with DNA barcodes tagging specific proteins from predetermined panels prior to PCR barcode amplification.

Results

Patient cohort

As of May 31, 2025, 212 patients have been recruited to the AtherOMICS biobank. Recruitment started in August 2022 with patients undergoing carotid endarterectomy and was expanded in March 2024 to include patients undergoing femoral endarterectomy (**Suppl. Fig. IIA**). Of the participants, 189 underwent carotid endarterectomy for either asymptomatic (37.0%) or symptomatic (63.0%) carotid stenosis, while 23 patients underwent femoral endarterectomy for advanced peripheral artery disease. Among patients with symptomatic carotid stenosis, the most common qualifying event was ischemic stroke (48.7%), followed by transient ischemic attack (24.3%), amaurosis fugax (12.6%), and central retinal artery occlusion (7.6%) (**Suppl. Fig. IIB**).

Baseline characteristics of carotid endarterectomy patients are summarized in **Table 1**. As expected, there was a high prevalence of vascular risk factors with 75%, 66%, and 25% reporting a history of hypertension, hypercholesterolemia, or diabetes, respectively. Furthermore, 37%, 25%, and 16% of the patients undergoing carotid endarterectomy had a history of coronary artery disease, prior stroke, or peripheral artery disease, respectively (**Table 1**). Baseline characteristics of the recruited femoral endarterectomy patients are presented in **Suppl. Table IV**.

Histopathological plaque characterization

Collected plaques undergo initial processing until flash-freezing within a median of 40 [IQR 33 to 50] minutes after removal (**Suppl. Fig. IIC**). All excised plaques undergo *ex vivo* MRI and histological assessment for morphological characterization (**Fig. 2A**). Macrophage and SMC contents are quantified via automated segmentation of CD68 and αSMA-positive areas in immunohistochemical stainings (**Fig. 2B-C**). Morphological features, including lipid core size, intraplaque hemorrhage, calcification, neovessel density, and fibrous cap thickness, are manually segmented and annotated across histological and *ex vivo* MRI images (**Fig. 2D-I**). **Fig. 2** summarizes these quantitative features in subsets of up to 68 carotid plaques, comparing symptomatic and asymptomatic individuals. Across all assessed features, intraplaque hemorrhage area was significantly larger in plaques from symptomatic patients (asymptomatic 3.72 ± 6.14% vs. symptomatic 7.08 ± 7.82%, n = 17 vs. 28, p = 0.017; **Fig. 2H**).

Proteomics and transcriptomics

Plaque segments and peripheral blood samples (serum and plasma) are stored for omics analyses. To date we have performed snRNA-seq on 17 carotid plaque samples, as well as

proximity extension assay proteomics (Olink Explore 3072) for 88 paired carotid plaque and plasma samples. snRNAseq revealed a total of 19,091 nuclei across the 17 samples, of which 35% were identified as nuclei of macrophages, 33% SMCs, 13% endothelial cells, 11% T cells, and 7% neutrophils (**Fig. 3A**). Our snRNAseq data points towards macrophages as the predominant immune cell type. While in line with findings from a recent study,[29] prior data from single-cell RNAseq analyses had suggested T cells as the predominant leukocyte subset.[16, 30-33] These diverging results might be related to differences in the viability of immune cell subsets across different protocols.[34]

Proteomic analysis of 88 matched plaque and plasma samples demonstrated the utility of proximity-extension proteomic assays in plaque tissue, revealing the presence of 2,841 distinct proteins. The median Spearman correlation between plaque and serum protein levels for these 2,841 proteins was $\rho = 0.10$ (IQR 0.02 – 0.20), although 214 proteins showed a correlation of $\rho > 0.4$ (**Fig. 3B**). These data offer a unique resource for exploring circulating biomarkers of atherosclerotic plaque stability. For example, plasma levels of IL-6, a commonly used surrogate of vascular inflammation, were significantly upregulated in patients with symptomatic compared to asymptomatic plaques ($p < 0.001$; **Fig. 3C**). Yet, there was no significant correlation between plaque and plasma levels (Spearman's $\rho = 0.13$, $p = 0.23$, **Fig. 3D**).

Imaging

We have collected pre-surgery head and neck CTA stacks from 102 patients and performed 9 carotid and brain MRI scans as part of the imaging sub-study within AtherOMICS (**Fig. 4**), which began imaging participants in August 2024. We noted that plaque features observed in CTA imaging, such as calcification, were also detectable in *ex vivo* imaging techniques, such as MRI and histology (**Fig. 4A-B**). Similarly, *in vivo* MRI augmented the characterization of non-calcified, soft plaque tissue in CTA (**Fig. 4C-D**). *In vivo* MRI of five symptomatic and four asymptomatic patients detected intraplaque hemorrhage in four out of nine carotid arteries (**Fig. 4D**). The quantification of previously described, CTA-derived plaque features revealed no significant differences in total plaque thickness and soft plaque thickness at the level of the index lesion, remodeling index, calcification location, and total calcification volume between asymptomatic and symptomatic patients. There was a statistically significant difference in mean calcification density (asymptomatic 780 ± 322 HU vs. symptomatic 1009 ± 405 HU, $n = 32$ vs. 71, $p = 0.002$) (**Fig. 4E**).

Discussion

Here, we present the study protocol and pilot data from AtherOMICS, a biobanking study of patients undergoing endarterectomy surgery that bridges deep plaque phenotyping with blood biobanking, *in vivo* non-invasive imaging and clinical data collection. By integrating these data types, we aim to identify key mechanisms driving plaque progression, understand molecular phenotypes associated with destabilization, and propose non-invasive biomarkers for the detection of vulnerable plaques.

AtherOMICS is uniquely positioned to address these goals. To elucidate the mechanisms underlying plaque biology, we first aim to map molecular quantitative trait loci (molQTLs) active within atherosclerotic lesions and link them to genetic loci associated with atherosclerotic cardiovascular outcomes. While hundreds of genomic signals have been detected for cardiovascular disease outcomes in genome-wide association studies,[35, 36] the mechanisms driving these associations remain unknown.[37, 38] Most lead variants are located in non-coding genomic regions and are assumed to influence gene or protein expression, but we lack functional genomic studies from relevant tissues to study such variant effects.[39] To this end, we will genotype samples from the AtherOMICS cohort and perform molecular profiling of plaques to identify variants associated with features of the local plaque microenvironment. By integrating these data with existing genomic resources for atherosclerotic traits and endpoints,[40] we aim to deepen our understanding of the genetic drivers of atherosclerosis and pinpoint candidate genes involved in plaque progression and destabilization. Second, we aim to identify molecular signatures associated with plaque vulnerability—such as symptomatic versus asymptomatic disease status. Histological analysis has been essential for characterizing the pathophysiology of atherosclerosis, enabling detailed phenotyping across stages of lesion development and identifying substructures linked to plaque instability.[41-43] However, the molecular features that correspond to unstable plaques remain poorly defined. By linking clinical data and histology with plaque omics profiles, AtherOMICS provides a unique opportunity to investigate these associations. Third, to discover novel biomarkers of symptomatic atherosclerotic disease, we will examine how plaque histological and molecular features relate to *in vivo* imaging phenotypes and to omics profiles in peripheral blood. By aligning imaging and histology data, we aim to characterize how vulnerable plaque substructures appear in noninvasive diagnostics (**Fig. 4**). In parallel, correlating blood-based omics profiles with plaque features will enable the identification of circulating biomarkers predictive of clinical events such as stroke or myocardial infarction.[44] Together, these efforts can support the development of noninvasive tools for assessing plaque stability and forecasting adverse cardiovascular outcomes.

AtherOMICS has specific limitations. First, endarterectomy patients typically exhibit advanced stages of atherosclerotic disease, which is reflected in a low number of less advanced plaques

in the study and thus limits the interpretability of findings for less advanced atherosclerosis stages. Second, it does not follow up on patients after endarterectomy surgery, meaning that recurrent cardiovascular and cerebrovascular events are not captured and circulating biomarkers cannot be studied across different timepoints like in prospective studies. Third, despite ongoing recruitment, several omics analyses, typically requiring very large sample sizes, are still underpowered. Fourth, compared to the biobanking and clinical data components of the study, fewer patients agree to participate in the *in vivo* MRI substudy, thus limiting the pace of inclusion. Fifth, the monocentric study design results in an overrepresentation of urban-dwelling individuals of European ancestry, which may require additional validation of findings in other populations.

In conclusion, AtherOMICS integrates deep multi-omic profiling of human atherosclerotic plaques with conventional histopathology, clinical phenotyping, blood biobanking, and *in vivo* plaque imaging. This biobanking effort has the potential to contribute novel insights into mechanisms underlying human atheroprogression, reveal the molecular signatures of plaque vulnerability, and develop non-invasive biomarkers of plaque instability.

Disclosures

ST received consulting fees from Quanterix unrelated to this work. MKG received consulting fees from Tourmaline Bio, Inc., Pheiron GmbH, and Gerson Lehrman Group, Inc. unrelated to this work.

Financial Support

The AtherOMICS study is funded by the German Research Foundation's Emmy Noether Programme (GZ: GE3461/2-1, ID 512461526 to M.K.G.) the Munich Cluster for Systems Neurology (SyNergy; EXC 2145, ID 390857198 to M.K.G.), the Fritz Thyssen Foundation (Ref. 10.22.2.024 MN to M.K.G.), the Hertie Foundation (Hertie Network of Excellence in Clinical Neuroscience, ID P1230035 to M.K.G.), and the Vascular Dementia Research Foundation.

Acknowledgements

We thank Fanni Magdane Boldoczki (Institute for Stroke and Dementia Research, ISD) for her assistance in developing the *ex vivo* MRI protocol, Nadja Sachs (Department for Vascular and Endovascular Surgery, TUM Klinikum, Technical University of Munich) for sharing expertise in plaque processing and biobanking, Andrea Stadie and Tanja Beer (both ISD) for conducting *in*

vivo MRI scans, as well as Philip Melton and Karin Waegemann (both ISD) for their assistance in the implementation of the blood biobanking protocol.

References

[1] Feigin, VL, Abate, MD, Abate, YH, et al., Global, regional, and national burden of stroke and its risk factors, 1990–2021: a systematic analysis for the Global Burden of Disease Study 2021, The Lancet Neurology, 2024/10/01;23.

[2] Gleissner, CA, Translational atherosclerosis research: From experimental models to coronary artery disease in humans, Atherosclerosis, 2016;248:110-116.

[3] Libby, P, The changing landscape of atherosclerosis, Nature, 2021;592:524-533.

[4] Ridker, PM, MacFadyen, JG, Everett, BM, et al., Relationship of C-reactive protein reduction to cardiovascular event reduction following treatment with canakinumab: a secondary analysis from the CANTOS randomised controlled trial, Lancet, 2018;391:319-328.

[5] Tardif, J-C, Kouz, S, Waters, DD, et al., Efficacy and Safety of Low-Dose Colchicine after Myocardial Infarction, New England Journal of Medicine, 2019;381:2497-2505.

[6] Nidorf, SM, Fiolet, ATL, Mosterd, A, et al., Colchicine in Patients with Chronic Coronary Disease, N Engl J Med, 2020;383:1838-1847.

[7] Fan, J and Watanabe, T, Atherosclerosis: Known and unknown, Pathol Int, 2022;72:151-160.

[8] Libby, P, Buring, JE, Badimon, L, et al., Atherosclerosis, Nature Reviews Disease Primers 2019 5:1, 2019-08-16;5.

[9] May, Lauren T, Bartolo, Belinda A, Harrison, David G, et al., Translating atherosclerosis research from bench to bedside: navigating the barriers for effective preclinical drug discovery, Clinical Science, 2022;136:1731-1758.

[10] Pasterkamp, G, Ruijter, HMd and Giannarelli, C, False Utopia of One Unifying Description of the Vulnerable Atherosclerotic Plaque: A Call for Recalibration That Appreciates the Diversity of Mechanisms Leading to Atherosclerotic Disease, Arteriosclerosis, thrombosis, and vascular biology, 2022;42.

[11] van Dijk, RA, Kleemann, R, Schaapherder, AF, et al., Validating human and mouse tissues commonly used in atherosclerosis research with coronary and aortic reference tissue: similarities but profound differences in disease initiation and plaque stability, JVS Vasc Sci, 2023;4:100118.

[12] Ross, R, Glomset, J and Harker, L, Response to injury and atherogenesis, Am J Pathol, 1977;86:675-684.

[13] Furie, MB and Mitchell, RN, Plaque Attack: One Hundred Years of Atherosclerosis in The American Journal of Pathology, The American Journal of Pathology, 2012;180:2184-2187.

[14] Tan, J, Liang, Y, Yang, Z, et al., Single-Cell Transcriptomics Reveals Crucial Cell Subsets and Functional Heterogeneity Associated With Carotid Atherosclerosis and Cerebrovascular Events, Arteriosclerosis, thrombosis, and vascular biology, 2023-12;43.

[15] Mokry, M, Boltjes, A, Slenders, L, et al., Transcriptomic-based clustering of human atherosclerotic plaques identifies subgroups with different underlying biology and clinical presentation, Nature Cardiovascular Research, 2022;1:1140-1155.

[16] Depuydt, MAC, Prange, KHM, Slenders, L, et al., Microanatomy of the Human Atherosclerotic Plaque by Single-Cell Transcriptomics, Circ Res, 2020;127:1437-1455.

[17] Palm, K, Theofilatos, K, Laan, SVD, et al., Proteomic profiling reveals higher presence of glycolytic enzymes in vulnerable atherosclerotic lesions, Atherosclerosis, 2024/08/01;395.

[18] Wu, X and Zhang, H, Omics Approaches Unveiling the Biology of Human Atherosclerotic Plaques, The American Journal of Pathology, 2024/04/01;194.

[19] Nurmohamed, NS, Kraaijenhof, JM, Mayr, M, et al., Proteomics and lipidomics in atherosclerotic cardiovascular disease risk prediction, Eur Heart J, 2023;44:1594-1607.

[20] Barkas, F, Sener, YZ, Golforoush, PA, et al., Advancements in risk stratification and management strategies in primary cardiovascular prevention, Atherosclerosis, 2024;395.

[21] 2024 Guideline for the Primary Prevention of Stroke: A Guideline From the American Heart Association/American Stroke Association, Stroke, 2024;55.

[22] Brindle, P, Beswick, A, Fahey, T, et al., Accuracy and impact of risk assessment in the primary prevention of cardiovascular disease: a systematic review, Heart, 2006-12-01;92.

[23] Obaid, DR, Calvert, PA, Brown, A, et al., Coronary CT angiography features of ruptured and high-risk atherosclerotic plaques: Correlation with intra-vascular ultrasound, Journal of Cardiovascular Computed Tomography, 2017/11/01;11.

[24] Saba, L, Anzidei, M, Marincola, BC, et al., Imaging of the Carotid Artery Vulnerable Plaque, CardioVascular and Interventional Radiology 2013 37:3, 2013-08-03;37.

[25] Mei, Z, Xu, L, Huang, Q, et al., Metabonomic Biomarkers of Plaque Burden and Instability in Patients With Coronary Atherosclerotic Disease After Moderate Lipid-Lowering Therapy, Journal of the American Heart Association, 2024;13:e036906.

[26] Koenig, W, High-sensitivity C-reactive protein and atherosclerotic disease: from improved risk prediction to risk-guided therapy, Int J Cardiol, 2013;168:5126-5134.

[27] Jiang, Y, Zhu, C, Peng, W, et al., Ex-vivo imaging and plaque type classification of intracranial atherosclerotic plaque using high resolution MRI, Atherosclerosis, 2016;249:10-16.

[28] Bayer-Karpinska, A, Schwarz, F, Wollenweber, FA, et al., The carotid plaque imaging in acute stroke (CAPIAS) study: protocol and initial baseline data, BMC Neurology, 2013;13:201.

[29] Bashore, AC, Yan, H, Xue, C, et al., High-Dimensional Single-Cell Multimodal Landscape of Human Carotid Atherosclerosis, Arteriosclerosis, thrombosis, and vascular biology, 2024;44:930-945.

[30] Horstmann, H, Lindau, A, Hansen, S, et al., Atlas of the immune cell repertoire in human atherosclerotic plaques characterized by single cell RNA-sequencing and multi-color flow cytometry, European Heart Journal, 2020;41.

[31] Slysz, J, Sinha, A, DeBerge, M, et al., Single-cell profiling reveals inflammatory polarization of human carotid versus femoral plaque leukocytes, JCI Insight, 2023;8.

[32] Dib, L, Koneva, LA, Edsfeldt, A, et al., Lipid-associated macrophages transition to an inflammatory state in human atherosclerosis, increasing the risk of cerebrovascular complications, Nature Cardiovascular Research, 2023;2:656-672.

[33] Fernandez, DM, Rahman, AH, Fernandez, NF, et al., Single-cell immune landscape of human atherosclerotic plaques, Nature Medicine 2019 25:10, 2019-10-07;25.

[34] Williams, JW, Winkels, H, Durant, CP, et al., Single Cell RNA Sequencing in Atherosclerosis Research, Circulation Research, 2020;126:1112-1126.

[35] Aragam, KG, Jiang, T, Goel, A, et al., Discovery and systematic characterization of risk variants and genes for coronary artery disease in over a million participants, Nature Genetics, 2022;54:1803-1815.

[36] Mishra, A, Malik, R, Hachiya, T, et al., Stroke genetics informs drug discovery and risk prediction across ancestries, Nature, 2022;611:115-123.

[37] Mountjoy, E, Schmidt, EM, Carmona, M, et al., An open approach to systematically prioritize causal variants and genes at all published human GWAS trait-associated loci, Nature Genetics 2021 53:11, 2021-10-28;53.

[38] Koyama, S, Liu, X, Koike, Y, et al., Population-specific putative causal variants shape quantitative traits, Nature Genetics, 2024;56:2027-2035.

[39] Cano-Gamez, E and Trynka, G, From GWAS to Function: Using Functional Genomics to Identify the Mechanisms Underlying Complex Diseases, Frontiers in Genetics, 2020;Volume 11 - 2020.

[40] Ray, A, Alabarse, P, Malik, R, et al., Single-cell transcriptome-wide Mendelian randomization and colocalization analyses uncover cell-specific mechanisms in atherosclerotic cardiovascular disease, medRxiv, 2024:2024.2012.2019.24319316.

[41] Stary, HC, Chandler, AB, Dinsmore, RE, et al., A Definition of Advanced Types of Atherosclerotic Lesions and a Histological Classification of Atherosclerosis, Circulation, 1995;92:1355-1374.

[42] Michel, J-B, Martin-Ventura, JL, Nicoletti, A, et al., Pathology of human plaque vulnerability: Mechanisms and consequences of intraplaque haemorrhages, Atherosclerosis, 2014;234:311-319.

[43] Sakamoto, A, Suwa, K, Kawakami, R, et al., Significance of Intra-plaque Hemorrhage for the Development of High-Risk Vulnerable Plaque: Current Understanding from Basic to Clinical Points of View, International Journal of Molecular Sciences, 2023;24:13298.

[44] Montaner, J, Ramiro, L, Simats, A, et al., Multilevel omics for the discovery of biomarkers and therapeutic targets for stroke, Nature Reviews Neurology, 2020;16:247-264.

Table 1. Baseline characteristics of recruited carotid endarterectomy patients in the AtherOMICS study.

	Overall N = 189	**Asymptomatic** N = 70	**Symptomatic** N = 119	**p-value**
Age (years), median (Q1, Q3)	73 (66, 79)	71 (65, 78)	74 (67, 81)	0.040
Females, n (%)	56 (31%)	18 (27%)	38 (33%)	0.384
BMI, mean ± SD	26.4 ± 4.4	27.1 ± 4.2	26.0 ± 4.5	0.100
Family history of MI or stroke, n (%)	94 (50%)	37 (53%)	57 (48%)	0.510
History of hypertension, n (%)	141 (75%)	57 (81%)	84 (71%)	0.098
History of diabetes, n (%)	48 (25%)	19 (27%)	29 (24%)	0.672
Current smoker, n (%)	45 (24%)	10 (14%)	35 (29%)	0.018
History of hypercholesterolemia, n (%)	125 (66%)	56 (80%)	69 (58%)	0.002
History of coronary artery disease, n (%)	70 (37%)	33 (47%)	37 (31%)	0.027
History of stroke, n (%)	47 (25%)	11 (16%)	36 (30%)	0.026
History of peripheral artery disease, n (%)	30 (16%)	9 (13%)	21 (18%)	0.384
Antihypertensive medication use, n (%)	144 (76%)	58 (83%)	86 (72%)	0.099
Statin use, n (%)	137 (72%)	58 (83%)	79 (66%)	0.014
Antidiabetic medication use, n (%)	46 (24%)	20 (29%)	26 (22%)	0.298
Antiplatelet medication use, n (%)	158 (84%)	67 (96%)	91 (76%)	<0.001
Total cholesterol (mg/dL), mean ± SD	158 ± 40	143 ± 34	167 ± 41	<0.001
HDL-C (mg/dL), mean ± SD	51 ± 16	55 ± 17	49 ± 15	0.033
LDL-C (mg/dL), mean ± SD	91 ± 40	73 ± 35	101 ± 39	<0.001
HbA1c (%), mean ± SD	6.07 ± 0.82	6.18 ± 1.00	6.00 ± 0.69	0.512
CRP (mg/dL), median (Q1, Q3)	0.20 (0.10, 0.50)	0.10 (0.10, 0.35)	0.30 (0.10, 0.60)	0.011

P-values are calculated using the Wilcoxon rank sum test, Pearson's Chi-squared test, or Fisher's exact test, as appropriate.

MI = myocardial infarction, HDL-C = high-density lipoprotein, LDL-C = low-density lipoprotein, CRP = C-reactive protein, HbA1c = glycated hemoglobin.

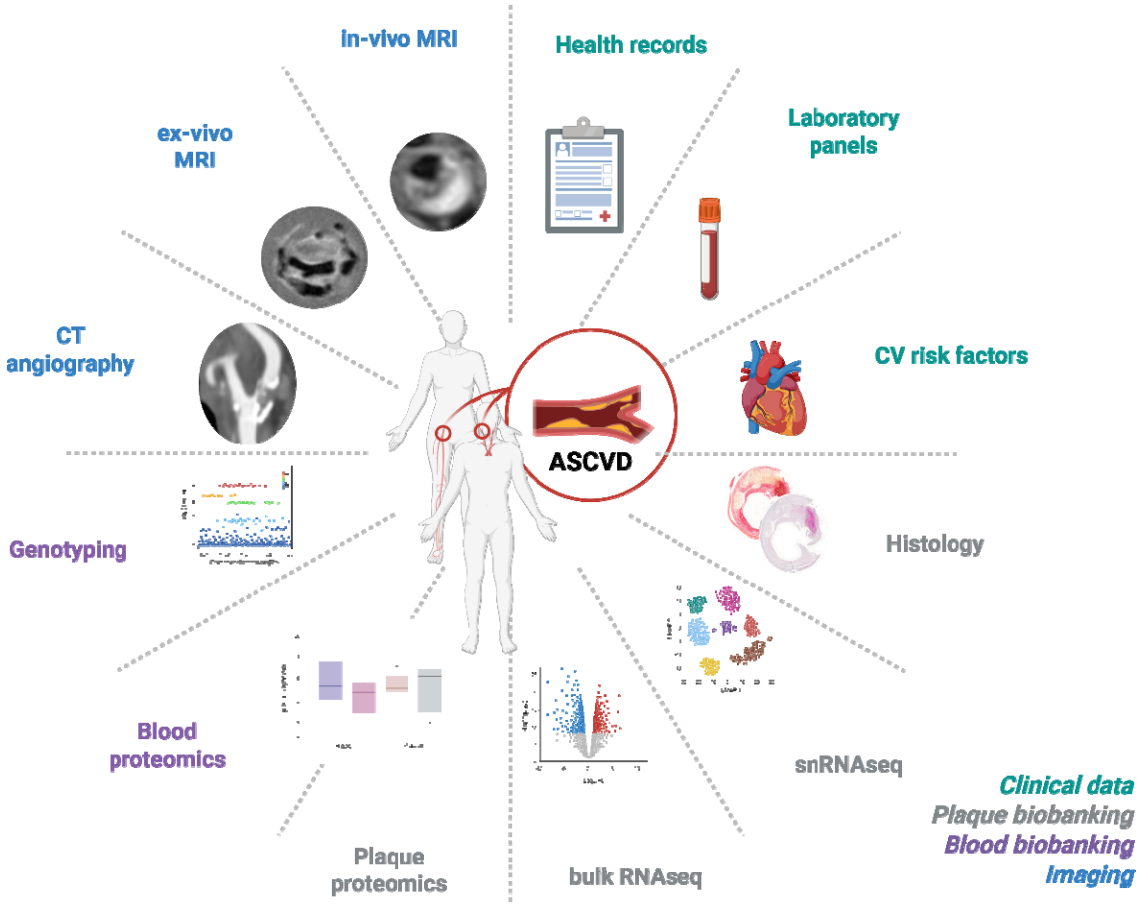

Figure 1. Schematic overview of AtherOMICS data types.

CV = cardiovascular, snRNAseq = single-nuclei RNA sequencing, CT = computed tomography, MRI = magnetic resonance imaging. Created with biorender.com

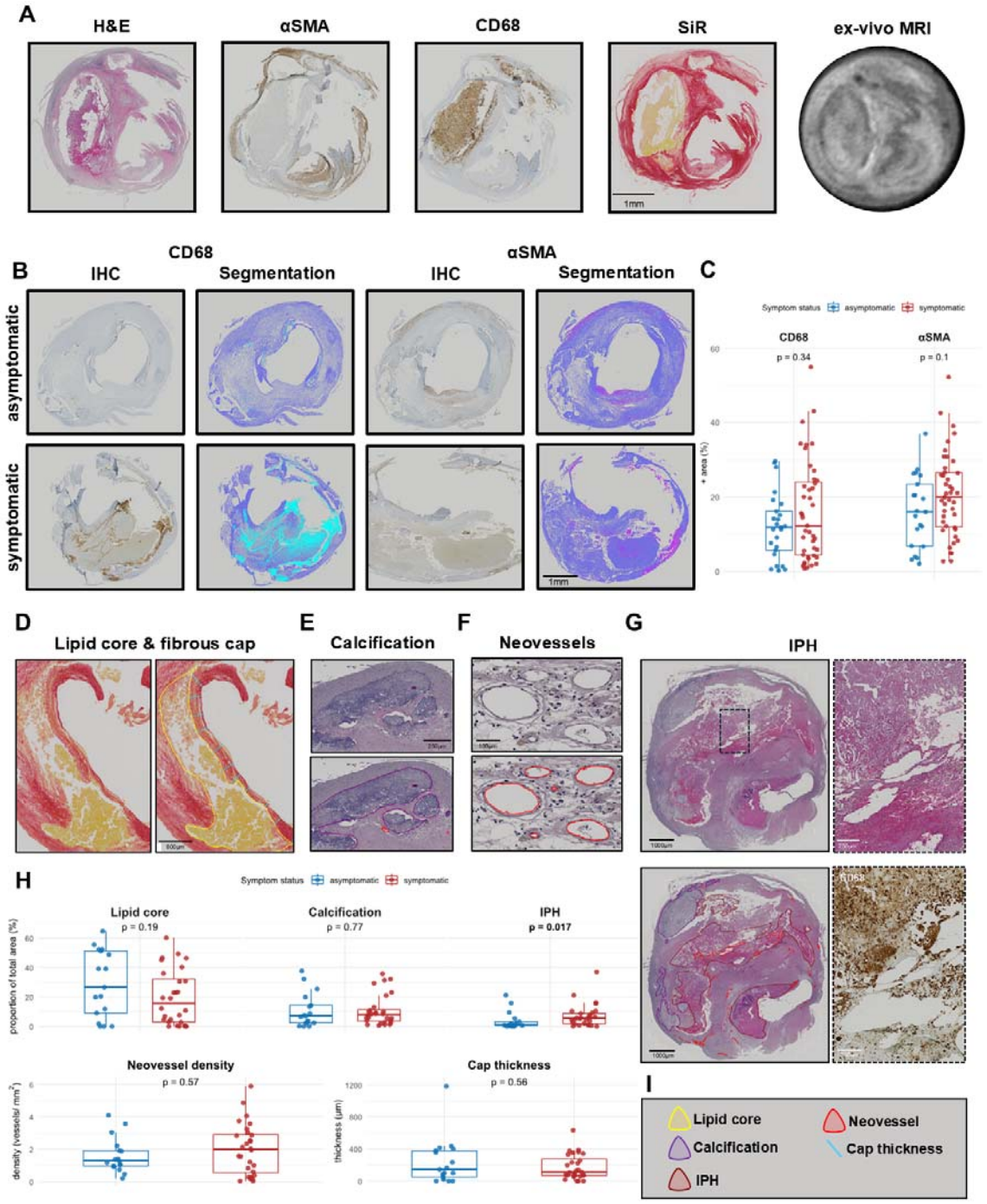

Figure 2. Histological assessment of carotid atherosclerosis in AtherOMICS. A. Plaque cross-section across multiple *ex vivo* imaging modalities. From left to right: Hematoxylin & eosin (H&E) for general histology, anti-α-smooth-muscle actin (αSMA) for SMCs, anti-CD68 for macrophages, Sirius Red (SiR) for collagen content and lipid cores, T2*-weighted ex-vivo MRI for morphology. Scale bar represents 1mm. **B.** Quantification of immunohistochemical stainings through automated feature segmentation. Original whole-slide image (IHC) is displayed next to the result of the segmentation algorithm ("Segmentation" panels). In CD68

segmentation, light blue indicates positive signal. In αSMA, purple indicates positive signal. Dark blue indicates negative signal in both stainings. Scale bar represents 1mm. **C.** Box-and-whiskers-plot of CD68 & αSMA-positive areas relative to total plaque area in asymptomatic (CD68: n = 25; αSMA: n = 21) vs. symptomatic (CD68: n = 43; αSMA: n = 43) participants. Blue color represents asymptomatic, red color symptomatic participants. Data points indicate individual values and the upper and lower boundaries of the boxes indicate Q3 and Q1, respectively. The median is represented through a bold line. Whiskers extend to 1.5 x IQR above/below their respective quartiles. p-values are provided above. Mann-Whitney U (CD68) and unpaired, two-sided Student's t-test (αSMA). **D-G.** Representative images depicting plaque substructures. Bottom panels (D: right panel) display examples of manual plaque feature annotation in whole-slide scans prior to quantification. Scale bars represent 800µm (D), 250µm (E), 100µm (F), 1000µm (G, left-hand panels) and 250µm (G, right-hand insets). **H.** Box-and-whiskers plots comparing plaque vulnerability features in plaques from asymptomatic (n = 17) and symptomatic (n = 28) participants. p-values considered statistically significant at $\alpha < 0.05$ are provided in bold. Mann-Whitney U test. **I.** Graphical legend for the annotation line colors used in **D-G**.

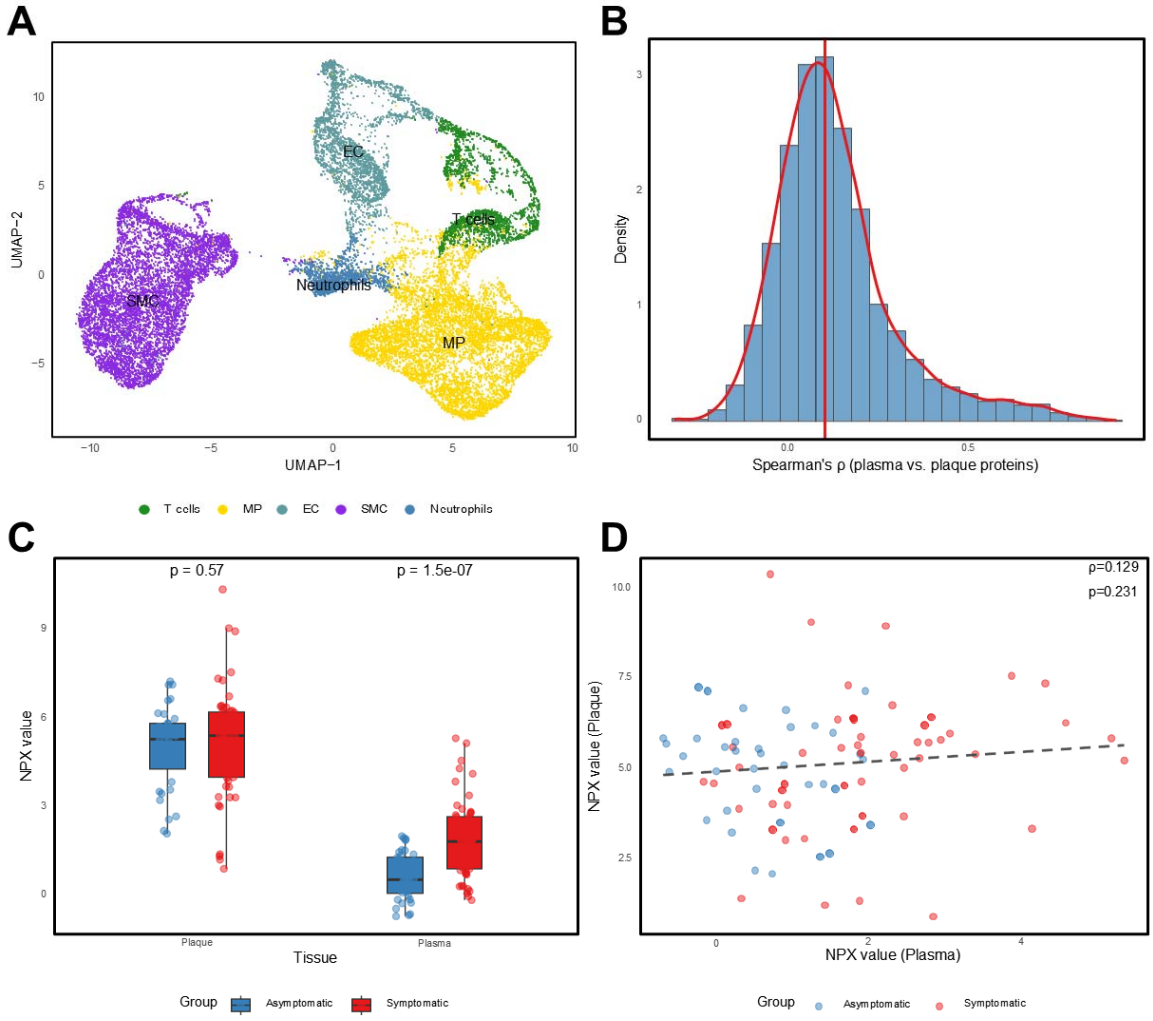

Figure 3. **Single-nuclei transcriptomic and proteomic profiling of plaque and plasma samples from carotid endarterectomy patients. A.** UMAP plot of plaque tissue single-nuclei RNA sequencing data from 17 participants (8 asymptomatic, 9 symptomatic). MP = macrophages, EC = endothelial cells, SMC = Smooth muscle cells. **B.** Histogram and density curve of Spearman correlation coefficients (ρ) between paired plasma and plaque samples computed across 2,810 proteins for 88 carotid endarterectomy patients, overlaid with a density curve. The dashed red line indicates the median correlation coefficient (ρ = 0.10). **C**. Box plots for plaque and plasma interleukin-6 (IL6) normalized protein expression (NPX) values in asymptomatic (blue) and symptomatic (red) patients. P-values are provided above the boxes. Student's t-test. **D.** Scatterplot of the plasma and plaque NPX values across the 88 sample pairs

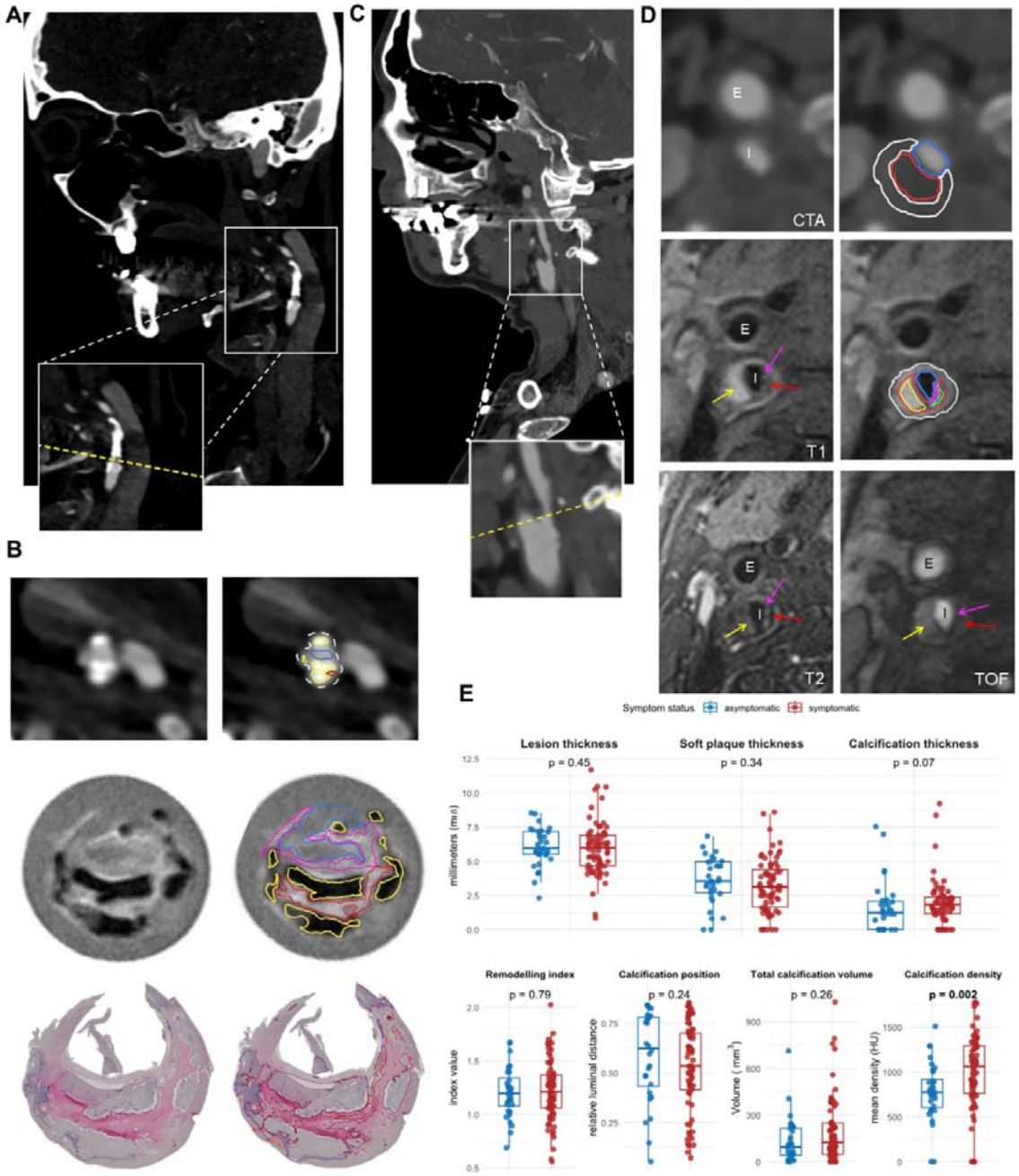

Figure 4. Multi-modal *in vivo* and *ex vivo* carotid plaque imaging in AtherOMICS. A. Computed tomography angiography (CTA) in sagittal plane showing the right carotid artery of an 81-year-old woman presenting with sudden-onset left upper limb motor deficit prior to inclusion into the AtherOMICS study. The yellow dashed line within the inset indicates the location of the axial plane in subpanel B. **B.** Presentation of calcified plaque substructures across multiple imaging modalities. Left column displays the original image, right column annotated structures. From top to bottom: Axial-plane CTA, T2-weighted ex-vivo MRI, H&E histology. Annotations: White dashed line denotes outer vessel wall, blue line the lumen, yellow (H&E: purple) line calcification, purple line (H&E: not represented) fibrous cap, red line

soft plaque (H&E: intraplaque hemorrhage). **C.** CTA in sagittal plane showing the right carotid artery of a 73-year-old man presenting with sudden-onset left upper limb sensorimotor deficit prior to inclusion. The yellow dashed line within the inset indicates the location of the axial plane in subpanel D. **D.** Side-by-side comparison of axial CTA and in-vivo MRI imaging. “E” indicates the external, “I” the internal carotid artery. The outer vessel wall is delineated in white, lumen in blue, soft plaque in red, intraplaque hemorrhage and fibrous cap (MRI sequences) in yellow and purple, respectively. In T1, T2 and time-of-flight angiography (TOF), the purple arrow points to the fibrous cap, the green arrow to a lipid core, and the yellow arrow to intraplaque hemorrhage on the dorsolateral side of the artery. **E.** Box-and-whiskers plots comparing CTA-derived plaque features in asymptomatic (n = 28 for calcification location, n = 32 for all others) and symptomatic (n = 69 for calcification location, n = 71 for all others) participants. Blue color represents asymptomatic, red color symptomatic patients. Data points indicate individual values and the upper and lower boundaries of the boxes indicate Q3 and Q1, respectively. The median is represented through a bold line. Whiskers extend to 1.5 x IQR above/below their respective quartiles. Student’s t-test (Soft plaque thickness, remodeling index) and Mann Whitney U test (all other comparisons).