Automated diagnosis of usual interstitial pneumonia on chest CT via the mean curvature of isophotes

Peter Savadjiev [1,2.], Morteza Rezanejad [3], Sahir Bhatnagar [4,5], David Camirand [6,7], Claude Kauffmann [8], Kaleem Siddiqi [1,2], Ronald J Dandurand [9-12], Patrick Bourgouin [6,7], Carl Chartrand-Lefebvre [6,7], Alexandre Semionov [13]

1. School of Computer Science, McGill University, Montreal, QC, Canada
2. Centre for Intelligent Machines, McGill University, Montreal, QC, Canada
3. Rosalind & Morris Goodman Cancer Institute, McGill University, Montreal, QC, Canada
4. Department of Epidemiology, Biostatistics and Occupational Health, McGill University, Montreal, QC, Canada
5. 5 Prime Sciences, Montreal, QC, Canada
6. Department of Radiology, Radiation Oncology and Nuclear Medicine, Université de Montréal, Montreal, QC, Canada
7. Department of Radiology, Centre Hospitalier de l'Université de Montréal (CHUM), Montreal, QC, Canada
8. Centre d'intégration et d'analyse des données médicales (CITADEL), Centre Hospitalier de l'Université de Montréal (CHUM), Montreal, QC, Canada
9. Department of Medicine, McGill University, Montreal, QC, Canada
10. Research Institute, McGill University Health Center, Montreal, QC, Canada
11. Montreal Chest Institute, McGill University Health Center, Montreal, QC, Canada
12. Lakeshore General Hospital, Pointe-Claire, QC, Canada
13. Department of Diagnostic Radiology, McGill University, Montreal, QC, Canada

This work has been submitted to *Radiology: Artificial Intelligence* for possible publication. Copyright may be transferred without notice, after which this version may no longer be accessible.

Abstract

Purpose: To test whether the mean curvature of isophotes (MCI), a geometric image transformation, can be used to improve automatic detection on chest CT of Usual Interstitial Pneumonia (UIP), a determining radiological pattern in the diagnosis of Interstitial Lung Diseases (ILD).

Materials and methods: This retrospective study included chest CT scans from 234 patients (123 female,111 male; mean age: 61.6 years; age range: 18-90 years) obtained at two independent institutions between 2007 and 2024.

Three different classification models were trained on the original CT images and separately on MCI-transformed CT images: (1) a previously published deep learning model for classifying fibrotic lung disease on chest CT, (2) a simplified version of the same, and (3) a non-deep-learning model based on the functional principal component analysis (FPCA) of density functions of voxel intensity.

All models were trained on data from the first institution and evaluated on data from the second institution with the recall-macro, precision-macro and F1-macro scores. Performance difference between classifier pairs was tested with the Stuart-Maxwell marginal homogeneity test.

Results: For a fixed model architecture and training algorithm, MCI-transformed images yield comparable or better classification performance than the original CT images. The best performance improvement achieved with MCI compared to CT was: recall-macro 0.83 vs 0.57, precision-macro 0.81 vs 0.50, F1-macro 0.80 vs 0.49, p=4.2e-5.

Conclusion: MCI may be a valuable addition to existing AI systems for screening for UIP on chest CT.

Summary statement

Machine learning methods for identifying usual interstitial pneumonia on chest CT perform better when the input CT images are transformed via the mean curvature of isophotes (MCI), a geometric transformation method known from classical computer vision.

Key Points

- Three machine learning models were trained on a dataset of 158 patients from one institution and tested on another dataset of 76 patients from an independent institution to discriminate for usual interstitial pneumonia (UIP) on chest CT in a 3-group classification task.
- When keeping the network architecture and parameters fixed, changing the input image domain from the original CT to MCI-transformed images improved classification performance (Stuart-Maxwell test, $p < .001$)
- MCI may be a valuable addition to existing machine learning systems for screening for UIP on chest CT, whether based on deep learning or on simpler shallow classifiers.

Introduction

Interstitial lung disease (ILD) is a heterogeneous group of disorders characterized by architectural changes of the lung parenchyma, resulting from progressive pulmonary inflammation and/or fibrosis. These changes lead to deterioration of lung function, disability, and premature death [1].

The standard diagnostic test for ILD is a high-resolution computed tomography (CT) scan of the chest [2]. Unfortunately, CT interpretative guidelines for ILD are largely subjective, and radiological diagnosis of ILD suffers from important inter-reader variability [2]. As a result, much effort has gone into developing quantitative CT analysis algorithms usually based on a deep-learning strategy [2]. Due to their success in a wide range of applications, it is commonly believed that deep learning algorithms such as convolutional neural networks (CNNs) extract the most effective image features for a given task, whereas human-engineered methods derived from domain knowledge are assumed to be sub-optimal.

However, a growing body of literature shows that in fact, CNN performance can be significantly improved if combined with explicit domain knowledge [3-6]. In particular, the mean curvature of isophotes (MCI) is a geometric image transformation that has recently been shown to improve CNN performance in detecting chronic obstructive pulmonary disease (COPD) on chest CT [7,8].

In the present work, we take the MCI framework to the domain of ILD. At the heart of our comparison lies the SOFIA method, a well-known CNN-based approach to classifying fibrotic lung disease on chest CT [9,10]. Our main hypothesis is that changing the input image domain from the original CT to MCI-transformed images, while keeping the network architecture and parameters fixed, can improve performance in a 3-group classification task.

These 3 groups consist of control CT scans without pulmonary disease; CT scans with ILD featuring a particular radiological pattern known as usual interstitial pneumonia (UIP) [11,12] ; and CT scans with other types of lung disease including types of ILD other than UIP. We stratify the ILD cases on a UIP vs. non-UIP basis because the UIP pattern has been associated with a faster progression and worse clinical prognosis. In this manner we emulate a recent clinical trial on progressive fibrosing ILD, where randomization was stratified according to the presence of UIP vs other ILD patterns [1]. As a result of this trial and others, anti-fibrotic therapy is now available following an UIP diagnosis.

Our secondary hypothesis is that the mathematical properties of the MCI transformation will make it possible for a simpler computational alternative based on functional principal components analysis (FPCA) [13,14] to yield a classification performance comparable to that of deep learning.

We worked with imaging data from two independent institutions, with data from one institution used to train classification models and data from the second institution used for independent testing.

Materials and Methods

Patient populations

This retrospective study was conducted with data acquired between 2007 and 2021 at McGill University and its affiliated hospitals, Montréal, QC, Canada (Institution 1), and between 2015 and 2024 at the Centre Hospitalier de l'Université de Montréal (CHUM), Montréal, QC, Canada

(Institution 2). The study received ethics approval at each participating institution, and patient informed consent was waived.

In both institutions, ILD cases are initially diagnosed during multidisciplinary meetings between pulmonologists, rheumatologists, pathologists and radiologists. Cases included in this study were randomly selected from such interdisciplinary discussions. Scans with non-ILD pulmonary diseases were randomly selected from participating thoracic radiologists' daily worklist using search keywords: sarcoidosis, Kaposi sarcoma, bronchioloalveolar carcinoma, pneumonia, lymphangitic carcinomatosis, pulmonary edema, pulmonary alveolar proteinosis, atelectasis, PCP, and COVID19. The final diagnosis based on chest CT and available clinical history for each case was done by thoracic radiologists: AS (14y experience) at Institution 1; PB (5y experience), and CCL (26y experience) at Institution 2. Cases with avert pulmonary parenchymal and pleural disease which had no inkling of possible ILD were excluded; for example, cases with large pleural effusions, extensive atelectasis, multilobar pneumonia, lobectomy/pneumonectomy, or diffuse nodular metastases.

Scans of patients without radiological evidence of pulmonary disease other than occasional micronodules were selected as normal controls. Nine such scans were initially retrieved in Institution 1. To increase the number of controls in the training dataset, 27 additional control scans were selected from the clinical practice of a participating respirologist (RJD, 44y experience) affiliated with Institution 1. These 27 patients are a subset of the control patient cohort previously reported in [7].

DICOM images were extracted from the radiology databases (PACS) of the two institutions. All CT images were anonymized prior to further analysis.

Diagnostic groups

The official 2018 clinical practice guideline for radiological diagnosis of ILD [11] advocates the use of four diagnostic categories: UIP, Probable UIP, Indeterminate for UIP, Alternative Diagnosis. In an update from 2022 [12], the guideline committee discusses the option of merging the 'UIP' and 'Probable UIP' categories, and provides several reasons for doing so. In our experiments, we merged the 'UIP' and 'probable UIP' groups into one. We also merged the 'Indeterminate for UIP' group, the 'Alternative Diagnosis' group as well as the non-ILD chronic pulmonary disease patients into another group. In this manner, a final set of three diagnostic groups was obtained: (1) patients with UIP or probable UIP, (2) patients with chronic pulmonary disease without evidence for UIP (may or may not be part of the ILD spectrum), and (3) the control patients without pulmonary disease.

CT Imaging characteristics

Each of the two institutions represents a large academic network of participating hospitals, thus patient scans were acquired at different sites with different scanner models and parameters, as detailed in Table 1.

SOFIA

The Systematic Objective Fibrotic Imaging Analysis (SOFIA) algorithm was introduced in [9] as a chest CT classification method based on the Inception-ResNet-v2 CNN architecture. A particular characteristic of SOFIA is their data augmentation technique, which consists in dividing the craniocaudal lung length into 4 equal blocks of segmented axial images, then selecting at random one slice from each block and joining each selected slice into a 2x2 slice montage, as shown in Fig. 2 in [9]. This process is repeated 500 times for each 3D scan, to

create 500 unique random montages per scan. Each montage was downsized to 350x350 pixels. The Inception-ResNet-v2 architecture was then trained on the resulting montages. See [9] for details.

Three image contrasts

To assess the benefit of the MCI transformation, we compared the diagnostic performance of the SOFIA approach trained on CT images to its performance when trained separately on MCI images.

To create the SOFIA montages, we first selected random slices from the CT images. Then, the same slice selections were used to create montages from the corresponding MCI images. In this manner, the set of montages differed only in image contrast (CT vs MCI), not in slice selection.

While working with the SOFIA method, we hypothesized that when 4 slices are downsized and combined together into a single 350x350 montage, the main discriminative signal carried by each montage would reflect mostly the overall shape of the slices, as opposed to smaller scale textural features. This hypothesis was also motivated by theoretical considerations and previous findings reviewed in the Discussion section.

To test this hypothesis, we created a third set of montages by binarizing the CT montages, so that all voxels within the lung mask were set to 1 (in all three montage sets, voxels in the background were set to 0).

Fig 1. shows an example montage for each of the three types of images.

Simplified SOFIA

As the choice and design of a 2x2 montage appears somewhat arbitrary, we also created a simplified set of inputs to the same CNN architecture, by taking all individual axial slices of a scan except the top and bottom 10%, and used them as input on their own, without creating multiple slice montages. Fig. 2 shows examples of such single slice inputs.

More details on the implementation of the SOFIA and Simplified SOFIA pipelines are provided in the Supplementary Material.

Alternative classification based on FPCA of voxel distributions

We also compared the performance of SOFIA to that of a simpler method based on the FPCA of voxel intensity distributions. Details are provided in the Supplementary Material.

Model evaluation

We report the classification performance of all our models in terms of three standard machine learning metrics: precision, recall and F1-score. Since there are more than 2 classes, we report the per-class macro average of these metrics. Of note, the per-class macro average of recall is equivalent to balanced accuracy.

Statistics

To compare classifier pairs, we apply the Stuart-Maxwell marginal homogeneity test [15,16]. It is a generalization of the McNemar test to the case of more than two categories (three in our

case). We performed 5 comparisons, which implies that following a Bonferroni correction for multiple comparisons, the p-value threshold for significance is 0.05/5=0.01.

Software

The computation of MCI was done in Matlab with code provided publicly by [7]. While code for the Inception-ResNet-v2 model itself is publicly available, the overall SOFIA pipeline is not, so we reimplemented SOFIA based on details available in [9]. CNN training and evaluation was done in Python 3.10.12 with PyTorch. FPCA modeling was done with a combination of R,Python and Matlab programming languages, based on code provided at [https://github.com/czhang-pstat/Density-Review]. The Stuart-Maxwell test was computed with the homogeneity() function from the statsmodels python package v.0.14.4. Our code is provided at the following link: https://github.com/petersv2/MCI_UIP/

Results

The final training dataset (institution 1) consisted of 158 patients, and the final testing dataset (institution 2) comprised 76 patients.

Table 2 presents the patient population within each dataset. The two datasets are age-matched (p=0.19, Mann-Whitney U test).

Table 3 presents the diagnostic performance of the classification models on the testing dataset from Institution 2.

Table 4 shows the p-value of the Stuart-Maxwell test comparing MCI vs CT classifiers in the three settings under investigation, as well as the improvement in MCI classification performance going from the original SOFIA to the simplified SOFIA and then to the FPCA framework.

Discussion

MCI is an image transformation which reflects the geometric structure of the imaged scene. It has long been studied in the field of computer vision and other fields such as astronomy due to its ability to extract the intrinsic structure of images in an invariant manner [7,8,17].

It is widely assumed that CNNs automatically discover the optimal features for a task. However, in chest CT analysis, it was shown that a CNN performs better at detecting early COPD when presented with MCI-transformed images, as opposed to the original CT images [7]. This is not because MCI images contain more information - since they are derived from CT images, all information in MCI is necessarily present also in the CT contrast. However, the invariance properties of MCI reduce unwanted variability while at the same time reveal geometric information that appears helpful in detecting/characterizing lung disease, information which the CNN did not seem to recover on its own from the original CT [7].

In this study, we took this line of work to the field of ILD, with the task of differentiating three classes of images: (1) controls without pulmonary disease , (2) patients with probable or definite UIP, and (3) patients with other pulmonary disease, including (but not limited to) patients with non-UIP ILD. In this manner, we address a challenging classification problem of pulmonary diseases not limited to the ILD spectrum. This is in contrast to a number of studies which focus only on binary UIP vs non-UIP classification [18-21]. While some train their models

on populations that include non-ILD pulmonary disease and healthy controls [20,21], testing is usually done on ILD-only cohorts.

In addition to diagnostic heterogeneity, our data is also highly heterogeneous in terms of imaging characteristics. As seen in Table 1, the training data contains images acquired at 13 scanning sites, with 8 different scanner models and a large variability of scanning parameters, including 23% of scans (36/158) with intravenous contrast. The testing data was acquired at 13 sites different from those of the training data, on 12 scanner models, with 5% of scans (4/76) having intravenous contrast. In this manner, we attempted to create minimally-curated datasets representative of everyday clinical practice.

In the context of such data heterogeneity, the objective was to showcase the relative improvement in performance for the same model architecture and training algorithm when provided MCI-transformed images as input, as opposed to original CT images. Model training and testing was done on independent datasets from two institutions.

Our first comparison between MCI and CT was done through SOFIA [9,10], a method using the CNN architecture Inception-ResNet-v2. While Inception-ResNet-v2 is an older architecture, we chose to work with SOFIA as it is a well-known approach to CT image analysis in the ILD literature. We next tested a simplified SOFIA pipeline with the same Inception-ResNet-v2 architecture but with a simplified preparation of input images. Finally, we tested a non-deep-learning classifier based on the FPCA of density functions of voxel intensity.

Our results show that for a fixed CNN architecture, MCI gives comparable or better results than CT. With the original SOFIA approach, MCI performance is comparable to that of CT (balanced accuracy of 0.72 vs 0.65, precision-macro of 0.62 vs 0.62, p=0.072). With the simplified processing pipeline, MCI performance improves but the CT performance does not (balanced accuracy of 0.72 vs 0.60, precision-macro of 0.86 vs 0.57, p=6.9e-5). In fact, the best performance is obtained with MCI using the simpler FPCA technique (balanced accuracy of 0.83 vs 0.57, precision-macro of 0.81 vs 0.50, p=4.2e-5).

A recent deep-learning study for detecting UIP on chest CT claimed that the low prevalence of UIP will always result in a low positive predictive value (PPV) for any tool developed to screen for or classify ILD in a healthcare-based cohort [21]. In that binary classification study, their deep learning model resulted in a PPV of 68% and negative predictive value (NPV) of 87% [21]. In our study, MCI achieved a precision-macro value of 86% with Simplified SOFIA and 81% with FPCA. As a reminder, the precision-macro value is the multiclass equivalent of the average of the PPV and NPV of a binary classifier. In [21], the average of PPV and NPV was 78%.

Our results also link to an ongoing debate on whether CNNs focus preferentially on texture or on shape [22]. In our study the CNN has a clear preference for shape. In a 3-class task, a random classifier is expected to result in a balanced accuracy of 0.33 purely by chance. Here, we observed that the binary (textureless) shape images achieve a much higher value, between 0.52 and 0.56, which is only 10% (or less) below the performance achieved with the CT contrast. One implication is that lung shape alone plays a role in distinguishing between the 3 groups of patients. Another implication is that clearly, the CNN over-relies on shape and under-exploits CT texture. It appears that due to shortcut learning [23,24], the CNN learns the simplest possible signal that leads to discrimination (also known as simplicity bias), which is this case is carried mostly by the shape of the segmented lung slices over a uniform background. Again, this runs contrary to the commonly held expectation that CNNs find on their own the best features for a given task, as overall lung shape is clearly not the best way to detect UIP. Our work shows that the same CNN can achieve better results if explicitly provided with precomputed MCI information. Interestingly, even better performance is achieved by the simpler FPCA method which by design does not use shape information.

It may be argued that the CNN could have achieved better performance with CT images, without requiring explicit MCI information, by optimizing the training procedure and hyperparameter choices, with better data-augmentation, or by choosing a more contemporary CNN architecture. This may well be the case; however, the objective of this study was not to determine the most optimal CNN model for this specific clinical problem. Rather, it was to showcase the relative performance improvement for the same CNN method when provided MCI images as input, as opposed to original CT images.

The main limitation of our study is the small sized datasets. As this is an exploratory study, we strived to present a proof-of-concept of the applicability of MCI in ILD in the presence of data heterogeneity and with testing on an independent external dataset. In future work, we will expand testing with much larger datasets such as those collected by the Open Source Imaging Consortium [25][https://www.osicild.org/]. Another limitation is that we did not examine associations between classification results and clinical outcomes. As a proof-of-concept, our study focused on radiological data only. In future work will also focus on clinical outcomes with larger datasets as described above. Finally, one technical limitation is that we only worked with MCI at a single spatial scale of 2mm. As discussed in [7], MCI is derived from classical scale-space literature in computer vision, where scale is modeled as a continuously varying parameter. In future work, we will extend our approach to a range of spatial scales with an optimal scale being determined automatically akin to classical scale-space methods in computer vision. [26,27]

Whereas this study showcased the utility of MCI for discrimination, an important next step is understanding the association between the MCI signal and underlying biological tissue characteristics. A recent histology study on explanted lungs with radiologically documented interstitial lung abnormalities found varying degrees of fibrosis in areas that appeared normal on CT scans [28]. An interesting topic of future investigation is whether MCI can reveal abnormal structure in such normal-appearing areas on CT. Future work will also focus on the role MCI might play in prediction of disease progression and response to treatment [2,25], as well as in the building of foundation models for lung imaging [29].

In conclusion, our results suggest MCI may be a valuable addition to existing machine learning systems for screening for UIP on chest CT, whether based on deep learning or on simpler shallow classifiers. In this work, we transform the input image space with MCI, but it is worthwhile exploring whether a MCI computation layer can be incorporated directly within a deep learning architecture.

Acknowledgements: PS acknowledges funding from NSERC Discovery Grant RGPIN-2018-05636. SB acknowledges funding from NSERC Discovery Grant RGPIN-2020-05133. PS is currently employed at the Department of Radiology, University of Vermont, Burlington VT USA.

References

[1] Flaherty KR, Wells AU, Cottin V, Devaraj A, Walsh SLF, Inoue Y, et al. Nintedanib in Progressive Fibrosing Interstitial Lung Diseases. N Engl J Med. 2019; 381(18):1718-1727. doi: 10.1056/NEJMoa1908681.

[2] Barnes H, Humphries SM, George PM, Assayag D, Glaspole I, Mackintosh JA, et al. Machine learning in radiology: the new frontier in interstitial lung diseases. Lancet Digit Health. 2023;5(1):e41-e50. doi: 10.1016/S2589-7500(22)00230-8.

[3] Clough JR, Byrne N, Oksuz I, Zimmer VA, Schnabel JA, King AP. A Topological Loss Function for Deep-Learning Based Image Segmentation Using Persistent Homology. IEEE Transactions on Pattern Analysis and Machine Intelligence 2022; 44(12):8766-8778. doi: 10.1109/TPAMI.2020.3013679.

[4] Smets BMN, Portegies J, Bekkers EJ, Duits R. PDE-Based Group Equivariant Convolutional Neural Networks. J Math Imaging Vis 2023; 65:209–239. doi: 10.1007/s10851-022-01114-x

[5] Masquelin AH, Cheney N, Kinsey CM, Bates JHT. Wavelet decomposition facilitates training on small datasets for medical image classification by deep learning. Histochem Cell Biol. 2021; 155(2):309-317. doi: 10.1007/s00418-020-01961-y.

[6] Rezanejad M, Downs G, Wilder J, et al. Scene Categorization from Contours: Medial Axis Based Salience Measures. In: 2019 IEEE/CVF Conference on Computer Vision and Pattern Recognition (CVPR), Long Beach, CA, June 15–20, 2019. Piscataway, NJ: IEEE, 2019; 4111–4119. doi: 10.1109/CVPR.2019.00424

[7] Savadjiev P, Gallix B, Rezanejad M, Bhatnagar S, Semionov A, Siddiqi K, et al. Improved Detection of Chronic Obstructive Pulmonary Disease at Chest CT Using the Mean Curvature of Isophotes. Radiol Artif Intell. 2022; 4(1):e210105. doi: 10.1148/ryai.210105.

[8] Vannier MW. Isophotes, Scale Space, and Invariants in Lung CT for COPD Diagnosis. Radiol Artif Intell. 2022; 4(1):e210301. doi: 10.1148/ryai.210301.

[9] Walsh SLF, Calandriello L, Silva M, Sverzellati N. Deep learning for classifying fibrotic lung disease on high-resolution computed tomography: a case-cohort study. Lancet Respir Med. 2018;6(11):837-845. doi: 10.1016/S2213-2600(18)30286-8.

[10] Walsh SLF, Mackintosh JA, Calandriello L, Silva M, Sverzellati N, Larici AR, et al. Deep Learning-based Outcome Prediction in Progressive Fibrotic Lung Disease Using High-Resolution Computed Tomography. Am J Respir Crit Care Med. 2022;206(7):883-891. doi: 10.1164/rccm.202112-2684OC.

[11] Raghu G, Remy-Jardin M, Myers JL, Richeldi L, Ryerson CJ, Lederer DJ, et al. Diagnosis of Idiopathic Pulmonary Fibrosis. An Official ATS/ERS/JRS/ALAT Clinical Practice Guideline. Am J Respir Crit Care Med. 2018; 198(5):e44-e68. doi: 10.1164/rccm.201807-1255ST.

[12] Raghu G, Remy-Jardin M, Richeldi L, Thomson CC, Inoue Y, Johkoh T, et al. Idiopathic Pulmonary Fibrosis (an Update) and Progressive Pulmonary Fibrosis in Adults: An Official ATS/ERS/JRS/ALAT Clinical Practice Guideline. Am J Respir Crit Care Med. 2022; 205(9):e18-e47. doi: 10.1164/rccm.202202-0399ST.

[13] Petersen A, Müller HG. Functional data analysis for density functions by transformation to a Hilbert space. Ann. Statist. 2016; 44(1):183-218. doi: 10.1214/15-AOS1363

[14] Petersen A, Zhang C, Kokoszka P. Modeling probability density functions as data objects. Econometrics and Statistics 2022; 21:159-178. doi: 10.1016/j.ecosta.2021.04.004

[15] Stuart A. A test for homogeneity of the marginal distributions in a two-way classification. Biometrika 1955; 42:412-416. doi: 10.1093/biomet/42.3-4.412

[16] Maxwell AE. Comparing the classification of subjects by two independent judges. British Journal of Psychiatry 1970; 116:651-655. doi: 10.1192/bjp.116.535.651

[17] Florack LM, Ter Haar Romeny BM, Koenderink JJ, Viergever MA. General intensity transformations and differential invariants. J Math Imaging Vis 1994;4(2):171–187. doi: 10.1007/BF01249895

[18] Bratt A, Williams JM, Liu G, Panda A, Patel PP, Walkoff L, et al. Predicting Usual Interstitial Pneumonia Histopathology From Chest CT Imaging With Deep Learning. Chest. 2022; 162(4):815-823. doi: 10.1016/j.chest.2022.03.044.

[19] Shaish H, Ahmed FS, Lederer D, D'Souza B, Armenta P, Salvatore M, et al. Deep Learning of Computed Tomography Virtual Wedge Resection for Prediction of Histologic Usual Interstitial Pneumonitis. Ann Am Thorac Soc. 2021;18(1):51-59. doi: 10.1513/AnnalsATS.202001-068OC.

[20] Humphries SM, Thieke D, Baraghoshi D, Strand MJ, Swigris JJ, Chae KJ, et al. Deep Learning Classification of Usual Interstitial Pneumonia Predicts Outcomes. Am J Respir Crit Care Med. 2024;209(9):1121-1131. doi: 10.1164/rccm.202307-1191OC.

[21] Chung JH, Chelala L, Pugashetti JV, Wang JM, Adegunsoye A, Matyga AW, et al. A Deep Learning-Based Radiomic Classifier for Usual Interstitial Pneumonia. Chest. 2024;165(2):371-380. doi: 10.1016/j.chest.2023.10.012.

[22] Tartaglini AR, Vong W, Lake B. A Developmentally-Inspired Examination of Shape versus Texture Bias in Machines. In J. Culbertson, A. Perfors, H. Rabagliati & V. Ramenzoni (Eds.), Proceedings of the 44th Annual Conference of the Cognitive Science Society, 2022. Retrieved from https://escholarship.org/uc/item/6hj739kb

[23] Ong Ly C, Unnikrishnan B, Tadic T. et al. Shortcut learning in medical AI hinders generalization: method for estimating AI model generalization without external data. NPJ Digit. Med. 2024; 7:124. doi: 10.1038/s41746-024-01118-4

[24] Hermann K, Mobahi H, Fel T, Mozer MC. On the Foundations of Shortcut Learning. In Proceedings of the ICLR 2024 conference, https://openreview.net/forum?id=Tj3xLVuE9f

[25] Walsh SLF, De Backer J, Prosch H, Langs G, Calandriello L, Cottin V, et al. Towards the adoption of quantitative computed tomography in the management of interstitial lung disease. Eur Respir Rev. 2024;33(171):230055. doi: 10.1183/16000617.0055-2023.

[26] Lindeberg T. Scale-Space Theory in Computer Vision: Volume 256 of Kluwer International Series in Engineering and Computer Science. Boston, Mass: Kluwer Academic, 1994.

[27] Lindeberg, T. Feature Detection with Automatic Scale Selection. International Journal of Computer Vision 1998; 30:79–116. doi: 10.1023/A:1008045108935

[28] Verleden SE, Vanstapel A, Jacob J, Goos T, Hendriks J, Ceulemans LJ, et al. Radiologic and Histologic Correlates of Early Interstitial Lung Changes in Explanted Lungs. Radiology. 2023; 307(1):e221145. doi: 10.1148/radiol.221145.

[29] Pai, S., Bontempi, D., Hadzic, I. et al. Foundation model for cancer imaging biomarkers. Nat Mach Intell 2024; 6:354–367. doi: 10.1038/s42256-024-00807-9

Training Dataset (Institution 1)

Model	Revolution EVO	LightSpeed VCT	Ingenuity CT	Aquilion Prime	Discovery CT750 HD	Aquilion	SOMATOM Definition Edge	SOMATOM Definition AS+
Manufacturer	GE MEDICAL SYSTEMS	GE MEDICAL SYSTEMS	PHILIPS	TOSHIBA	GE MEDICAL SYSTEMS	TOSHIBA	SIEMENS	SIEMENS
Sites	b, f	a, e, h, l, b, m	a, g	a	c, b	d, l	c	j, k
Number of patients	45	42	32	25	7	3	2	2
IVContrast	15 (33.33%)	2 (4.76%)	6 (18.75%)	9 (36.00%)	3 (42.86%)	1 (33.33%)	0 (0%)	0 (0%)
Convolution kernel	'STANDARD': 45	'STANDARD': 36, 'LUNG': 1, N/A: 5	'C': 14, 'B': 17, 'YA': 1	'FC08': 22, 'FC52': 1, 'FC51': 1, 'FC19': 1	'STANDARD': 4, 'LUNG': 1, N/A: 2	'FC14': 2, 'FC08': 1	'I40f\\2': 2	'I70f\\3': 1, 'B35': 1
Pixel spacing (mm)	0.768 (0.688, 0.805)	0.703 (0.678, 0.756)	0.684 (0.629, 0.721)	0.674 (0.613, 0.705)	0.826 (0.791, 0.882)	0.647 (0.637, 0.699)	0.812 (0.808, 0.817)	0.857 (0.842, 0.873)
Slice thickness (mm)	1.25	1.25	1.5	1.5	2.5 (1.9, 2.5)	1.0	3.0	2.2 (1.9, 2.6)
Field of view (mm)	389.0 (352.0, 412.0)	360.0 (347.0, 387.0)	350.0 (322.0, 362.0)	345.0 (324.0, 355.0)	423.0 (405.0, 451.5)	331.0 (326.5, 357.5)	416.0 (413.5, 418.5)	439.0 (431.0, 447.0)
Voltage (kV)	120	120	120	120	120	120	120	120
Tube current (mA)	134.0 (108.0, 224.0)	350.5 (202.2, 446.0)	328.0 (294.0, 485.8)	366.0 (258.0, 375.0)	N/A	N/A	99.5 (99.2, 99.8)	536.0 (476.0, 596.0)

A

Testing Dataset (Institution 2)

Model	SOMATOM Definition Flash	Aquilion ONE	Brilliance 64	SOMATOM Definition Edge	Aquilion PRIME	iCT 256	Sensation 64	Revolution Frontier	SOMATOM Drive	Optima CT660	SOMATOM Definition AS+	BrightSpeed
Manufacturer	SIEMENS	TOSHIBA	PHILIPS	SIEMENS	TOSHIBA	PHILIPS	SIEMENS	GE MEDICAL SYSTEMS	SIEMENS	GE MEDICAL SYSTEMS	SIEMENS	GE MEDICAL SYSTEMS
Sites	A	A, F	A	B, E, G, J	C	K	M	D	A	H	I	L
Number of patients	38	11	10	5	3	2	2	1	1	1	1	1
IVContrast	2 (5.26%)	1 (9.09%)	0 (0%)	0 (0%)	1 (33.33%)	0 (0%)	0 (0%)	0 (0%)	0 (0%)	0 (0%)	0 (0%)	0 (0%)
Convolution kernel	'B70f': 29, 'I40f_1': 5, 'I40f_2': 4	'FC52': 9', 'LUNG': 2	'L': 10	'B59f': 3, 'B57f_1': 1, 'B57f': 1	'FC52': 3	'A': 2	'B40f': 1, 'B60f': 1	'LUNG': 1	'B40f_1': 1	'LUNG: 1'	'B60f': 1	STANDARD': 1
Pixel spacing	0.747 (0.679, 0.801)	0.705 (0.654, 0.818)	0.793 (0.671, 0.901)	0.869 (0.678, 0.875)	0.625 (0.605, 0.669)	0.671 (0.656, 0.686)	0.653 (0.652, 0.655)	0.674	0.859	0.783	0.686	0.666
Slice thickness	2.0	2.0 (1.5, 2.0)	2.0	2.0	1.0	2.0	2.0	1.25	2.0	1.25	1.0	2.5
Field of view (mm)	382.5 (347.5, 410.0)	361.0 (334.8, 418.8)	406.0 (343.5, 461.2)	445.0 (347.0, 448.0)	320.0 (310.0, 342.8)	343.5 (335.8, 351.2)	334.5 (333.8, 335.2)	345.0	440.0	401.0	351.0	341.0
Voltage (kV)	120.0 (105.0, 120.0)	120	120	120.0 (120.0, 140.0)	120.0 (120.0, 127.5)	120	120	120	120	120	120	120
Tube current (mA)	583.0 (363.8, 1029.2)	271.0 (197.5, 320.5)	207.0 (136.5, 299.0)	541.0 (314.0, 552.0)	144.0 (144.0, 196.5)	167.0 (164.5, 169.5)	330.5 (219.2, 441.8)	150	314	148	420	50

B

Table 1.
Scan parameters for the training (A) and testing (B) datasets. For each scanner model used, the sites at which this model was used are identified with lower-case letters for the training dataset (A) and capital letters for the testing dataset (B). The table also shows the number of patients scanned with this scanner model, the number among them that was scanned with intravenous contrast (IVContrast, data shown as a number and also as a percentage of the total number of patients for that scanner), the convolution kernel used and the number of scans corresponding to that kernel, as well as several quantitative parameters. If a given quantitative parameter has a single value for all patients for that scanner model, that value is given. If more than one value is present within that patient group, the median (interquartile range) is provided. N/A: data not available

	Institution 1 (training)	Institution 2 (testing)
Age at scan in years, mean [range]	62.1 [19.0, 86.0]	60.5 [18.0, 90.0]
Age at scan in years, median [interquartile range]	65.0 [53.0, 72.8]	62.0 [54.0, 68.0]
Total number of patients (number of females)	158 (81)	76 (42)
Group 1 (controls)	36	16
Group 2 (non-UIP lung disease)	74	48
Group 3 (probable or definite UIP)	48	12

Table 2. Mean age [range], Median age [interquartile range], total number of patients (number of female patients), and number of patients in each diagnostic group for each dataset.

Method	Image Contrast	Classifier Performance metrics		
		Recall-macro (balanced accuracy)	Precision-macro	F1-macro
SOFIA	MCI	0.72	0.62	0.65
	CT	0.65	0.62	0.63
	Binary/Shape	0.56	0.53	0.54
Simplified SOFIA	MCI	0.72	0.86	0.73
	CT	0.60	0.57	0.54
	Binary/Shape	0.52	0.57	0.54
FPCA	MCI	0.83	0.81	0.80
	CT	0.57	0.50	0.49

Table 3. Diagnostic performance of classification models

Method	Image Contrast	Stuart-Maxwell test p-value
SOFIA	**MCI**	0.072
	CT	
Simplified SOFIA	**MCI**	6.9E-05
	CT	
FPCA	**MCI**	4.2E-05
	CT	
SOFIA	**MCI**	7.7E-05
Simplified SOFIA		
Simplified SOFIA	**MCI**	2.9E-05
FPCA		

Table 4. P-values of the Stuart-Maxwell marginal homogeneity test, for selected pairs of classifiers.

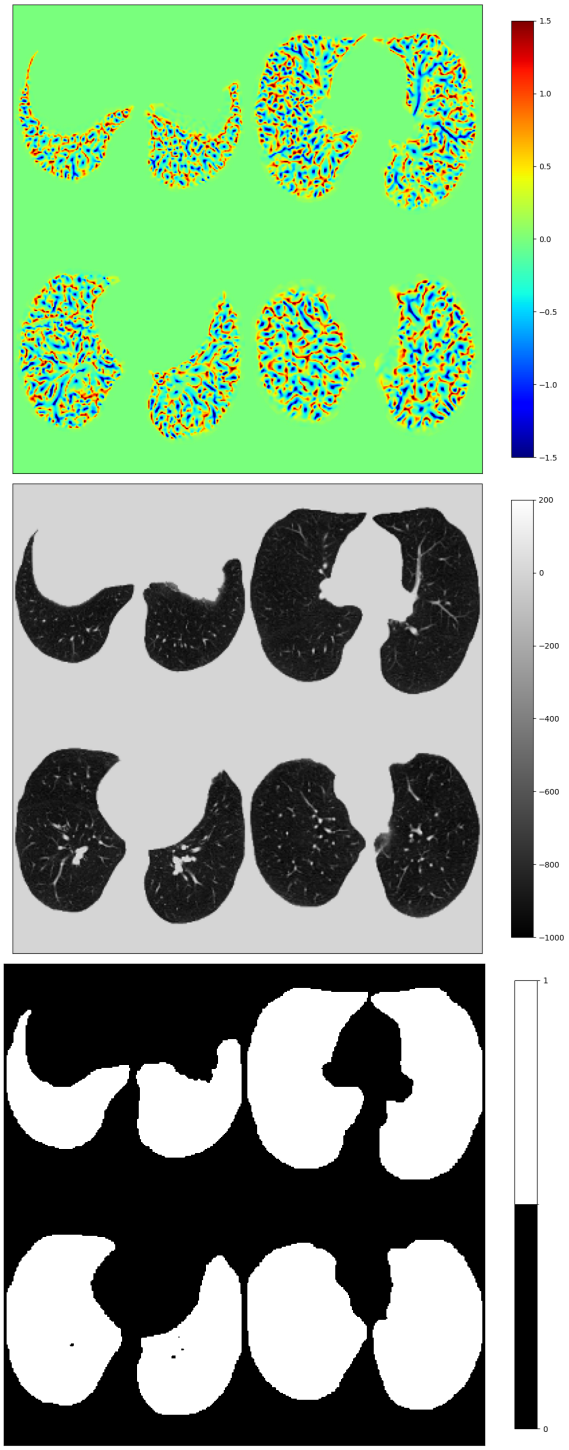

Figure. 1 Examples of MCI (top), CT (middle) and binary shape (bottom) 2x2 montages used as input to the SOFIA method.

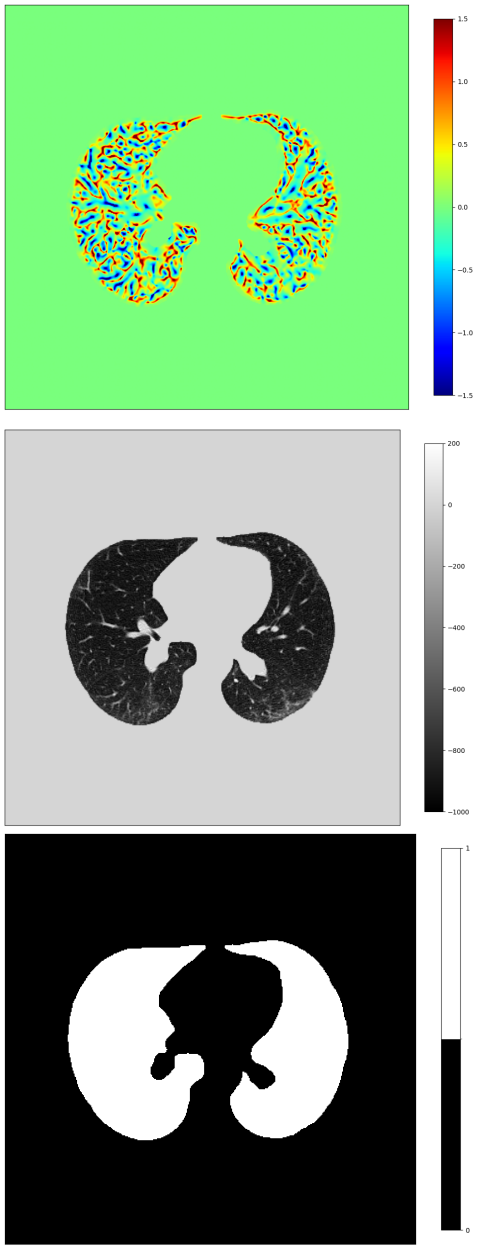

Figure. 2 Examples of MCI (top), CT (middle) and binary shape (bottom) single slice inputs used as input to our Simplified SOFIA method.

SUPPLEMENTARY MATERIAL

Note: a list of references specific to the supplementary material appears at the end of this document

Supplementary methods

Image preprocessing and MCI computation

Following the methodology of Savadjiev et al. [1], we first resampled all original CT images to an isotropic voxel grid of 0.9×0.9×0.9 mm. The MCI transformation of these resampled images was then computed, with a scale value of σ=2mm [1]. A lung mask was computed on the resampled CT images using the Chest Imaging Platform (http://chestimagingplatform.org/), an open-source software. This mask was then applied to both the CT and the MCI-transformed images to set voxels outside the lungs to 0.

Montage creation in the original SOFIA pipeline

We followed all the details provided by the original SOFIA publication [2] to reimplement their algorithmic pipeline. Sufficient detail is given with respect to the training of the Inception-ResNet-v2 CNN architecture. However, some detail with regards to the construction of the 2x2 slice montages is not provided explicitly in their methods and had to be inferred from the montage provided as an example in Fig 2 in [2].

Normally, when four different axial slices are extracted from a chest CT image of the lung at four different heights, they would have a different surface area. More specifically, a tight-fitting square bounding box around each segmented axial slice would have varying size based on the location of the slice. For instance, slices that are more apical would tend to have smaller bounding boxes than slices that are more basal. However, when looking at Fig. 2 in [2], it is clear that these four slices have had their size changed, so that their tight-fitting bounding box matches a fixed and predetermined quadrant size in the final 2x2 montage. This is necessary for creating tight-fitting 2x2 montages, and while it is not explicitly stated in [2], it must have been done in order to create a montage as the one shown in Fig. 2 in [2].

As a result of this observation, our code creates slice montages by first finding the tight-fitting square bounding box around each selected axial slice, cropping the slice around this bounding box and then interpolating each slice down to a fixed quadrant size in a 2x2 montage of 350x350 pixels. In particular, since the four slices are to be tightly fitting in four quadrants of the same size, each slice has a somewhat different downsampling factor. As a result, the physical size in mm that each pixel represents in the final montage is not necessarily the same across the four quadrants of the same montage.

Implementation of the Simplified SOFIA pipeline

The fact that physical pixel size in the original SOFIA montages may not be the same across the different quadrants of the same 2x2 montage could potentially be disadvantageous and is not really necessary, it is just an artefact of the design of the SOFIA methodology. In our proposed Simplified SOFIA pipeline, by removing the creation of 2x2 slice montages, we also remove this artifact. In our Simplified SOFIA implementation, physical pixel size is kept constant. We simply crop the segmented axial slice around its tight-fitting bounding box and then add the necessary padding of 0-valued pixels around it to obtain a final image with size 400x400 pixels, without additional interpolation/resizing.

Per-patient classification

The CNN classification approach for SOFIA (or simplified SOFIA) was applied separately on the 3 sets of montages (or individual slices, respectively) described in the main manuscript. In other words, the three different image contrasts were not used as three channels in the same model. Rather, three different models were trained for each individual image contrast.

At inference time, each of these trained models assigns a classification label to each montage (or individual slice, respectively). To obtain a per-patient label, we used majority voting, i.e., the final predicted label assigned to each patient was the label associated with the largest number of montages (slices, respectively) pertaining to that patient.

Alternative classification based on FPCA of voxel distributions

Inspired by the LAA950 metric commonly used in lung quantitative CT analyses [3], the work by Savadjiev et al. [1] introduced a metric called "hmci1" defined as the fraction of lung voxels with an MCI value larger than a certain threshold. Equivalently, this can be seen as the area under the probability density function of MCI values above a given threshold. In [1] an MCI threshold value of $1mm^{-1}$ was chosen somewhat arbitrarily.

Recognizing the limitations of fixing a specific threshold value, here we work with the entire MCI probability density function as a data object itself, obviating the need for choosing a threshold. This is done within a functional principal components analysis (FPCA) framework, where low-dimensional embeddings of the density functions are obtained by computing the principal components (modes of variation) of the MCI density functions [4,5]. These embeddings are then used for classification.

Probability densities (PD) are nonnegative functions with an integral that sums to 1. These constraints imply that the functional space of PDs is convex but not linear. As a result, standard FPCA methods are not directly applicable. To address this, Petersen et al. [4] have proposed a transformation approach where PDs are mapped to a Hilbert space of functions through a continuous and invertible map. The resulting representations of PDs in this Hilbert space are then amenable to the construction of functional modes of variation and FPCA. Results are mapped back to the density space using the inverse transformation map.

In this work, we used the implementation of this method available at [https://github.com/czhang-pstat/Density-Review] to build a simple classification model based on the modes of variation of the MCI densities. We computed the PDs of MCI values over the extent of the segmented lungs, using kernel density estimation (function ksdensity() in Matlab). We then applied the method of [4] with their log quantile density (LQD) transformation to compute FPCA embeddings of all the MCI PDs from the training dataset. The MCI PDs from the testing dataset were transformed in the same fashion and projected into the FPCA space computed from the training PDs. This was achieved with the MdVar() function in [https://github.com/czhang-pstat/Density-Review]. Classification of the FPCA embeddings of the testing PDs was achieved using a k-nearest-neighbor classifier (k=5). For comparison, the same process was repeated with the HU values of CT images over the same lung segmentations.

References cited in the Supplementary Material

[1] Savadjiev P, Gallix B, Rezanejad M, Bhatnagar S, Semionov A, Siddiqi K, et al. Improved Detection of Chronic Obstructive Pulmonary Disease at Chest CT Using the Mean Curvature of Isophotes. Radiol Artif Intell. 2021; 4(1):e210105. doi: 10.1148/ryai.210105.

[2] Walsh SLF, Calandriello L, Silva M, Sverzellati N. Deep learning for classifying fibrotic lung disease on high-resolution computed tomography: a case-cohort study. Lancet Respir Med. 2018;6(11):837-845. doi: 10.1016/S2213-2600(18)30286-8.

[3] Gevenois PA, De Vuyst P, de Maertelaer V, Zanen J, Jacobovitz D, Cosio MG, Yernault JC. Comparison of computed density and microscopic morphometry in pulmonary emphysema. Am J Respir Crit Care Med. 1996;154(1):187-92. doi: 10.1164/ajrccm.154.1.8680679.

[4] Petersen A, Müller HG. Functional data analysis for density functions by transformation to a Hilbert space. Ann. Statist. 2016; 44(1):183-218. doi: 10.1214/15-AOS1363

[5] Petersen A, Zhang C, Kokoszka P. Modeling probability density functions as data objects. Econometrics and Statistics 2022; 21:159-178. doi: 10.1016/j.ecosta.2021.04.004