First Use of Phage Therapy in Canada for the Treatment of a Life-Threatening, Multidrug-Resistant *Staphylococcus epidermidis* Periprosthetic Joint Infection: An N-of-1 Trial

Melissa T. Cammuso, PharmD[1], Bradley W. M. Cook, PhD [2*], D. William Cameron, MD[3,4], Stephen Ryan, MD, PhD[5], Gina A. Suh, MD[6] and Marisa A. Azad, MD, PhD[3,4*]

[1]Department of Pharmacy, The Ottawa Hospital, Ottawa, Canada

[2]Cytophage Technologies, Ltd., Oak Bluff, Manitoba, Canada

[3]Division of Infectious Diseases, Department of Medicine, University of Ottawa at The Ottawa Hospital, Ottawa, Canada

[4]Ottawa Hospital Research Institute, Ottawa, Ontario, Canada

[5]Department of Medical Imaging, The Ottawa Hospital, Ottawa, Canada

[6]Division of Infectious Diseases, Department of Medicine, Mayo Clinic, Rochester, USA

*Corresponding Authors:
Marisa Ann Azad, MD, PhD
Division of Infectious Diseases
Department of Medicine
The Ottawa Hospital
Ottawa, K1H 8L6, Canada
Phone: 613-737-8899 x78856
Email: maazad@toh.ca

Bradley Cook, PhD, MSc
Cytophage Technologies, Ltd.
Oak Bluff, R4G 0B1, Canada
Phone: 204-296-7231
Email: bcook@cytophage.com

ABSTRACT

We describe the first use of phage therapy in Canada for the treatment of a life-threatening periprosthetic joint infection (PJI), with successful outcome. PJI is a devastating complication of joint replacement surgery, with high morbidity and mortality. Our patient presented with early sepsis from a chronic recalcitrant multidrug-resistant *Staphylococcus epidermidis* hip PJI which had repeatedly failed standard therapy. She had previously undergone 10 operations of the right hip, and only three weeks after completing a prolonged course of daptomycin following her most recent hip revision, she developed a draining sinus tract. Given the high burden of disease, inability to achieve surgical source control, and lack of antibiotic treatment options for long-term suppressive therapy, bacteriophage (phage) therapy was pursued. The patient underwent irrigation and debridement with complex flap reconstruction: intraoperative tissue cultures again yielded MDR *S. epidermidis*. We developed a novel phage protocol for this patient, with twice daily, intra-articular and intravenous (7×10^9 PFU/dose) phage delivery over a planned 14-day course. Complete healing of the wound with cessation of drainage occurred within one month after treatment. A marked improvement in right hip pain and mobility occurred within three months after treatment. Ten months following phage treatment, there is normalization of serum inflammatory markers with diminished pain, increased mobility, and no recurrent surgery. Our patient continues to improve and is currently living independently at home, with sustained clinical control of infection.

INTRODUCTION

A female patient in their 70s presented to our periprosthetic joint infection (PJI) clinic with a one-week history of subjective fever and a draining abscess overlying the right hip (**Figure 1**). Her past medical history was significant for drug reaction with eosinophilia and systemic symptoms (DRESS; β-lactam and glycopeptide antibiotic classes were to be avoided). Her orthopedic surgery history was extensive, including 10 operations of the right hip, with development of a recalcitrant multidrug resistant (MDR) *Staphylococcus epidermidis* right hip PJI (antibiotic susceptibilities shown in **Table 1**). She had failed treatment with multiple courses of antibiotics, including chronic suppression with doxycycline, and – just prior to presentation – a 12-week course of daptomycin with concurrent revision of the right total hip arthroplasty and acetabular reconstruction. While on daptomycin, she developed peripheral neuropathy and myalgias.

Only three weeks after completion of daptomycin, she developed increasing fatigue, right hip pain, subjective fever, rigors, and a draining sinus tract overlying the right hip posterior incision site. C-reactive protein (CRP) and erythrocyte sedimentation rate (ESR) were 85 mg/L and 67 mm/h, respectively. Creatinine kinase was within normal limits. The patient was afebrile but appeared unwell and lethargic. Copious purulent fluid was draining from the right hip sinus tract. A pelvic X-ray and computed tomography (CT) of the right hip are shown in **Figures 2** and **3**, respectively. She was promptly readmitted. A goals of care discussion was held: given that surgical source control with complete implant removal (i.e., a right hemipelvectomy) could not be safely achieved, and viable antibiotic treatment options for long-term suppressive therapy were not available, bacteriophage (phage) therapy was pursued. The patient underwent irrigation and debridement with complex flap reconstruction and was restarted on daptomycin with the addition of oral ciprofloxacin empirically, pending microbiology. All four intraoperative tissue cultures yielded MDR *S. epidermidis*. Antimicrobial therapy was transitioned to daptomycin and oral

rifampin. She re-developed myalgias and peripheral neuropathy on daptomycin, even at reduced dosing.

Phage Therapy: In collaboration with Cytophage Technologies, Ltd., (Winnipeg, Canada), we developed a novel phage protocol for this patient. Regulatory, research ethics board, and institutional approvals from Health Canada and the Ottawa Hospital Research Institute (OHRI) were obtained (OHRI Protocol#: 20240008-01H). Preclinical *in vitro* testing against the *S. epidermidis* isolate led to the identification and characterization of the therapeutic potential of a single, lytic phage. The phage was not cultivated using the clinical isolate, as whole-genome sequencing identified two intact prophages which could contaminate final phage preparations. The phage was propagated within an avirulent *Staphylococcus succinus* host. Resultant phage lysates were concentrated and purified. The therapeutic quality monophage preparation was profiled using rigorous testing by Cytophage and a third-party, thus ensuring final product potency (7×10^9 PFU/mL), purity, fidelity, and safety. These tests included United States Pharmacopeia (USP) standards (sterility, endotoxin and physical chemistry) and final product identity measures (electron microscopy, PCR, and sequencing), in adherence to compassionate-use recommendations (1).

RESULTS & DISCUSSION

Results: The patient was admitted, underwent ultrasound-guided percutaneous drainage catheter insertion into a right hip fluid collection, and was administered phage therapy, twice daily, both intra-articularly and intravenously (7×10^9 PFU/dose). She received concomitant daptomycin and oral rifampin. The catheter became malpositioned on day seven of treatment which was then removed to prevent the introduction of additional microorganisms into the joint space (intra-articular phage administration was discontinued). Intravenous phage therapy was continued for an additional seven days, completing the planned 14-day treatment course. After phage administration, the patient developed initial and immediate mild hypotension, followed by

hypertension, low-grade fever, chest pain, rigors, and wheezing, lasting approximately 30 minutes from treatment on days one to five. These reactions were more marked following intra-articular phage delivery which followed intravenous administration, peaking after the second dose on day one, then subsiding with each subsequent dose, with resolution by day five. Liver enzymes (alanine transaminase [ALT], aspartate aminotransferase [AST], alkaline phosphatase [ALP], and gamma-glutamyl transpeptidase [GGT]) increased and peaked in the first week of treatment (baseline and peak values: AST 30 to 99 U/L; ALT 29 to 108 U/L; ALP 124 to 223 U/L; GGT 61 to 105 U/L). Liver enzymes began to fall at week two of treatment and returned to baseline by one month after treatment. Baseline inflammatory biomarkers, ESR and CRP, were 51 mm/hr and 28 mg/L, respectively. CRP peaked on day 3 of treatment (93 mg/L) and decreased to 43 mg/L at one-month follow up. ESR remained overall unchanged throughout treatment.

The patient was monitored in PJI clinic. Complete healing of the wound with cessation of drainage occurred within one month after treatment. A marked improvement in right hip pain and mobility occurred within three months after treatment. Daptomycin was transitioned to oral linezolid three months after treatment and rifampin was discontinued after seven months. An overall decrease in serum CRP and ESR occurred with normalization 10 months after treatment. **Table 2** shows an overall trend in inflammatory markers. There is sustained improvement in right hip pain and mobility, and the patient has moved from family-assisted living to independent living in her own home. Given how high risk this patient is for relapse of infection (with significant associated mortality and morbidity), a decision was made to continue linezolid, with close monitoring for toxicity. Should this occur, three-times weekly linezolid will be considered, with eventual cessation of therapy, assuming ongoing clinical improvement and/or stability, near the one-year mark. A repeat hip aspirate will be considered then.

Discussion: PJI is a catastrophic disease which complicates 1-2% of primary joint replacements (2). In Canada, PJI is one of the leading causes of revision operations in hip and knee replacements and poses a large burden of disease (3). Early recognition, accurate

133 microbiologic diagnosis, and prompt surgical and medical treatment of PJI are critical to
134 preventing recalcitrant infection, which is not only incurable, but associated with significant
135 morbidity and mortality (4). Frequently, chronic PJI requires long-term antibiotic therapy and
136 multiple surgical interventions. In severe cases, resection arthroplasty or amputation may be
137 needed. There is an unmet need for novel therapeutic approaches.

138 Phage therapy is underexplored for PJI. Phage are viruses which are ubiquitous in nature
139 and specifically infect bacteria. In specific cases, phage is an attractive adjunctive therapeutic
140 option for targeted antimicrobial therapy, and for combating antimicrobial drug resistance. Overall,
141 promising outcomes with phage therapy as a treatment for PJI have been summarized in recent
142 reviews (5, 6). In all cases, phage therapy was delivered to patients that repeatedly failed standard
143 treatment options. Phage treatment protocols were variable with respect to preparations
144 (monophage or cocktails), dosing (single or sequential; concentration), frequency and duration,
145 method of delivery (e.g., intra-articular, topical, and/or intravenous), concurrent surgical
146 intervention, co-administration of antibiotic(s), and follow-up. In a systematic review by Yang et
147 al., 16 clinical studies were screened (one prospective controlled clinical trial and 15 case reports),
148 in total including 42 patients with hip and/or knee PJI who received phage therapy. Following
149 phage therapy, two cases demonstrated relapse of infection, while others demonstrated improved
150 outcomes (5). In a systematic review by Suh et al., the outcomes of 33 bone and joint infection
151 cases treated with phage therapy since 2010 were highlighted. Of these cases, 87% achieved
152 favorable outcomes (microbiologic or clinical success), with only rare mild adverse events (6).
153 Overall, despite having non-standardized protocols, phage therapy appears to be a potential
154 adjunctive modality to treat orthopedic infections, including PJI.

155 Phage therapy is generally considered safe, although rare and minor adverse events have
156 been reported such as local reactions at the treatment site (erythema, pain), transient pruritis,
157 shortness of breath and wheezing, fevers and chills, flushing, and hypotension (7, 8, 9). Our
158 patient demonstrated an interesting tempo of reactions during phage treatment which have not,

159 to our knowledge, been reported, including initial and transient hypotension, followed by
160 hypertension, low-grade fever, chest pain, rigors, and wheezing during early treatment. These
161 were worse following initial intra-articular phage delivery (which followed intravenous injections)
162 and resolved by day five of treatment. Little is known about the immunobiology of these reactions,
163 although data may point towards the release of endotoxins (in cases of Gram-negative bacterial
164 infection) or other bacterial components (e.g., DNA, lipoteichoic acid, membrane-embedded
165 proteins, and secreted exotoxins) as stimulators of inflammatory cytokine responses (10).

166 We report the first use of phage therapy in Canada for the treatment of a life-threatening
167 hip PJI, with successful outcome of wound healing, diminished pain, increased mobility, and
168 normalization of inflammatory biomarkers, without recurrent surgery. Our patient continues to
169 improve and is currently living independently at home, with sustained clinical control of infection.
170 Several barriers to the wide-spread use of phage therapy exist, including regulatory hurdles and
171 a lack of standardization and high-quality evidence to better understand which PJI patients would
172 benefit most from this therapy. Despite these challenges, phage therapy appears to be a
173 promising potential adjunct for recalcitrant PJI where standard medical and surgical management
174 has repeatedly failed.

175
176
177
178
179
180
181
182
183
184

REFERENCES

1. Pirnay JP, Blasdel BG, Bretaudeau L, Buckling A, Chanishvili N, Clark JR, et al. Quality and safety requirements for sustainable phage therapy products. Pharm Res. 2015;32(7):2173-9.
2. Kurtz SM, Lau E, Watson H, Schmier JK, Parvizi J. Economic burden of periprosthetic joint infection in the United States. J Arthroplasty. 2012;27(8 Suppl):61-5.e1.
3. Canadian Institute for Health Information. CJRR annual report: Hip and knee replacements in Canada, 2019–2020. Accessed December 16, 2024.
4. Azad MA, Patel R. Practical Guidance for Clinical Microbiology Laboratories: Microbiologic diagnosis of implant-associated infections. Clin Microbiol Rev. 2024:e0010423.
5. Yang S, Mukh AA, Abdelatif E, Schmidt A, Batailler C, Ferry T, et al. Bacteriophage therapy as an innovative strategy for the treatment of periprosthetic joint infection: a systematic review. Int Orthop. 2024;48(11):2809-25.
6. Suh GA, Ferry T, Abdel MP. Phage therapy as a novel therapeutic for the treatment of bone and joint infections. Clin Infect Dis. 2023;77(Suppl 5):S407-s15.
7. Clarke AL, De Soir S, Jones JD. The safety and efficacy of phage therapy for bone and joint infections: a systematic review. Antibiotics (Basel). 2020;9(11).
8. Genevière J, McCallin S, Huttner A, Pham TT, Suva D. A systematic review of phage therapy applied to bone and joint infections: an analysis of success rates, treatment modalities and safety. EFORT Open Rev. 2021;6(12):1148-56.
9. Suh GA, Lodise TP, Tamma PD, Knisely JM, Alexander J, Aslam S, et al. Considerations for the use of phage therapy in clinical practice. Antimicrob Agents Chemother. 2022;66(3):e0207121.
10. Liu D, Van Belleghem JD, de Vries CR, Burgener E, Chen Q, Manasherob R, et al. The safety and toxicity of phage therapy: a review of animal and clinical studies. Viruses. 2021;13(7).

ACKNOWLEDGEMENTS

The authors thank the Cytophage Technologies Inc. laboratory team whose efforts were critical for the experimental treatment (Marielou Tamayo, Melissa Plett, Stephanie Lau, Tia Arnaud, Dr. Henrik Almblad, Nicolas Fournier, Karen LoVetri, Dr. Tasia Lightly, Dr. Yuen Ming Chung, Riya Roy, Natasha Theriault, and Dr. Steven Theriault). The authors also thank Dr. Jessica Sacher for fruitful discussion. We also wish to thank Dr. John Bell, Dr. Jennifer Quizi, Dr. Mathieu J.F. Crupi and the Biotherapeutics Manufacturing Centre (Jessica Hentschel), as well as our microbiology colleagues at Eastern Ontario Regional Laboratory Association.

FUNDING

This study received no funding.

DECLARATION OF COMPETING INTEREST

M.A.A. is a consultant for BioFire USA and bioMérieux Canada. D.W.C. receives a salary award from the Faculty and Department of Medicine, University of Ottawa. G.A.S. is an unpaid advisor for Phiogen and has intellectual property licensed to Adaptive Phage Therapeutics and Precisio Biotix and contractual rights to receive royalties. B.W.M.C. is an employee of and lead scientist at Cytophage Technologies Ltd.

Figure 1. Development of a *S. epidermidis* abscess with a draining sinus tract overlying the right hip three weeks after cessation of a 12-week course of daptomycin.

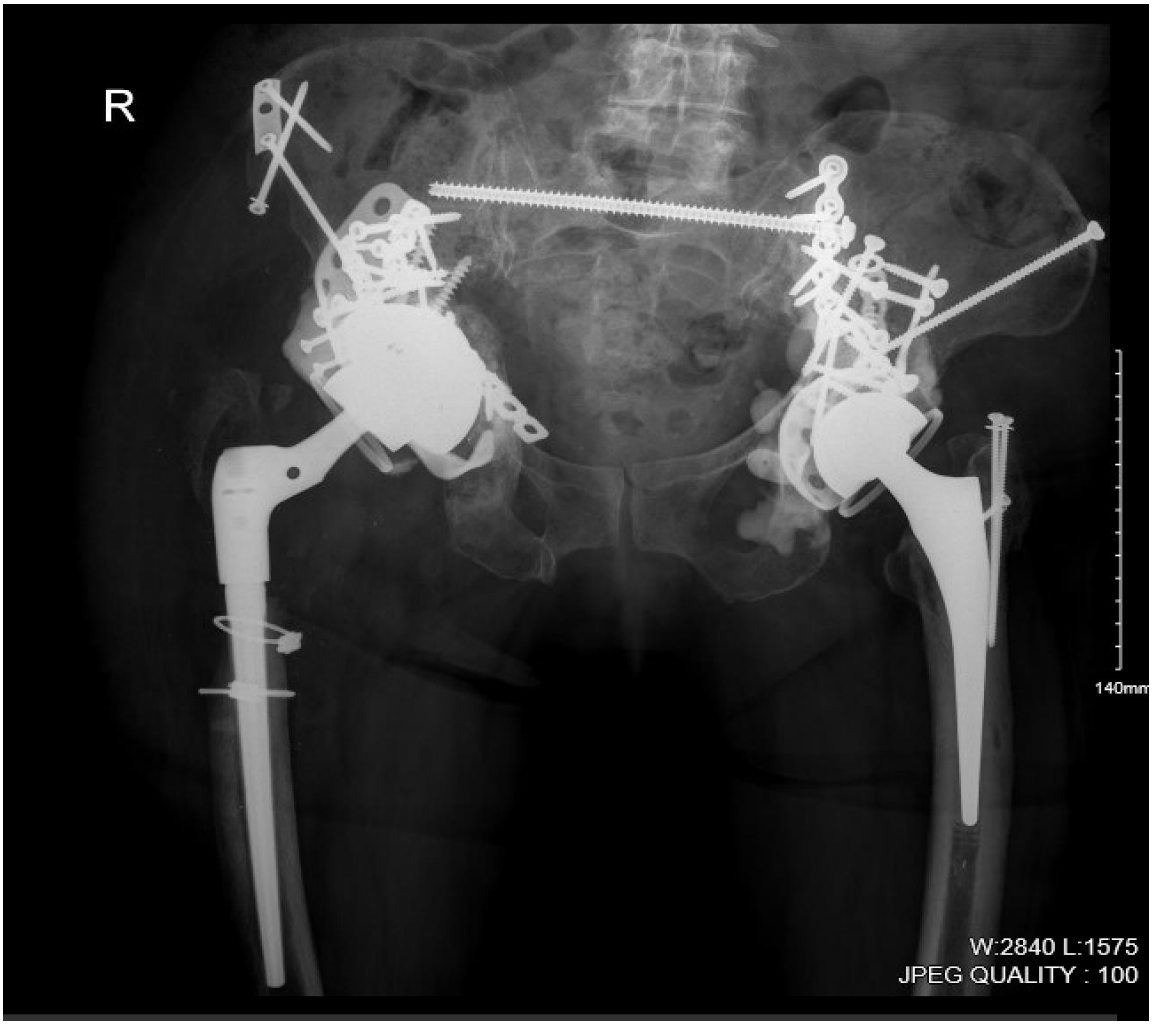

Figure 2. Pelvic X-ray highlighting the burden of *S. epidermidis* infected hardware involvement of the right hip and hemipelvis.

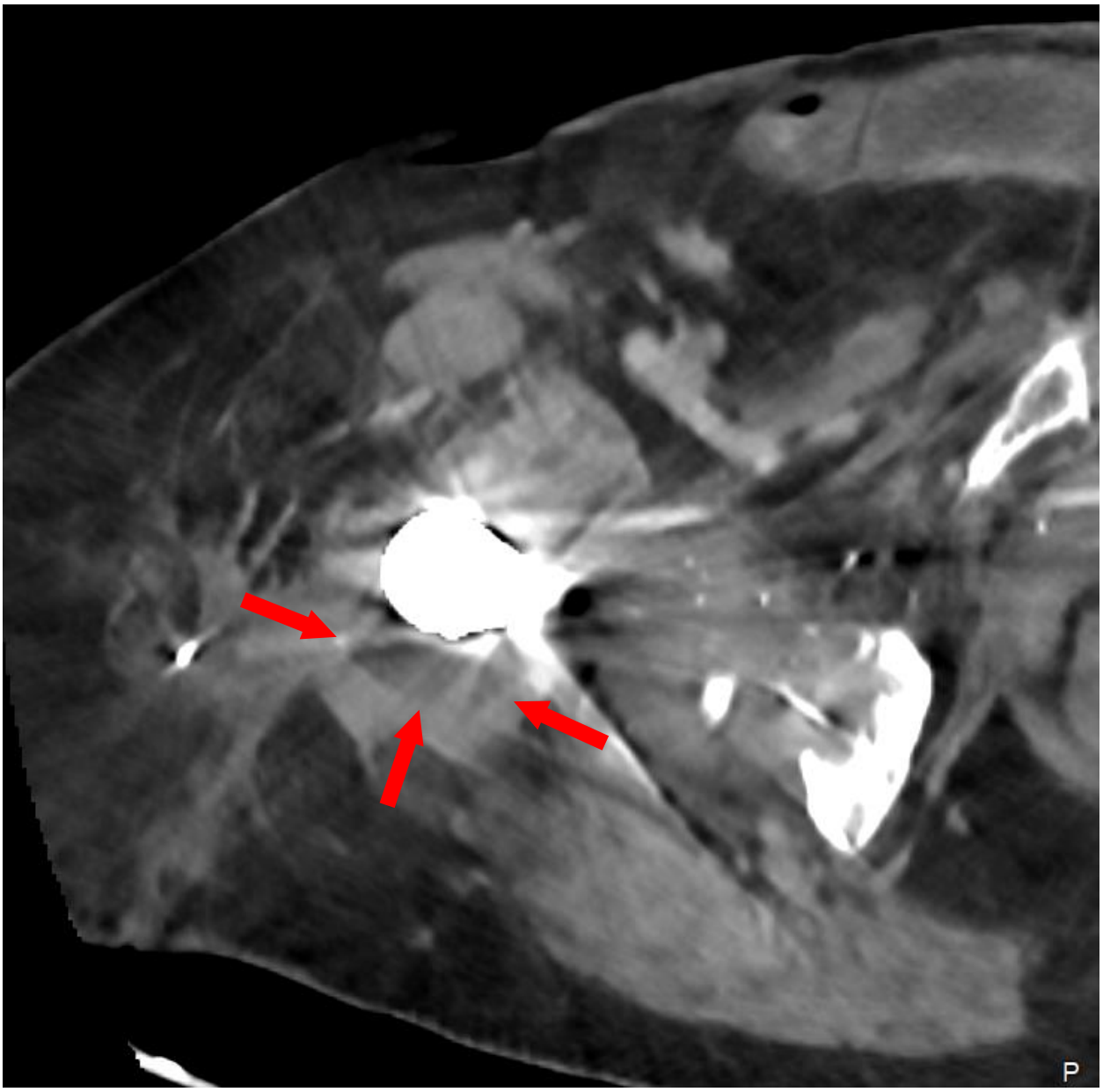

Figure 3. Axial CT image of the right hip demonstrating a stable periprosthetic fluid collection (red arrows) post percutaneous drainage catheter insertion (catheter not imaged).

259 **Table 1.** *Staphylococcus epidermidis* isolate extended antibiotic susceptibility profile.

Antibiotic	***Staphylococcus epidermidis* Minimum Inhibitory Concentration (MIC) or Zone of Inhibition**	**Interpretation**
Oxacillin	2 mg/L	Resistant
Clindamycin	>4 mg/L	Resistant
Ciprofloxacin	7 mm	Resistant
Rifampin	≤0.25 mg/L	Susceptible
Tetracycline	6 mm	Resistant
Trimethoprim/Sulfamethoxazole	4 mg/L	Resistant
Vancomycin	1 mg/L	Susceptible
Daptomycin	≤0.5 mg/L	Susceptible
Linezolid	≤2 mg/L	Susceptible
Ceftaroline	0.38 mg/L	Unknown*
Ceftobiprole	0.75 mg/L	Unknown*
Fosfomycin	16 mg/L	Unknown*

*Note that no Clinical and Laboratory Standards Institute (CLSI) minimum inhibitory concentration (MIC) breakpoints currently exist.

260

261 **Table 2**. Overall trend of inflammatory markers during and after phage treatment.

	Baseline	Week 1 of Treatment	Week 2 of Treatment	Month 6 Follow-up	Month 10 Follow-up
CRP (mg/L)	28	64	34	23	5
ESR (mm/hr)	51	55	46	43	11

262