Major keywords: Dermatofibroma, Dermatofibrosarcoma protuberans, Immunohistochemistry, Diagnostic markers

Title: Immunohistochemical profiles of dermatofibroma and dermatofibrosarcoma protuberans: A scoping review

Authors: Céline S. C. Hardy[1,2#], Ali Razavi[1], Natalie Nunez[1], William Fitzmaurice[1], Loma Dave[1], Amy R. Slutzky[3], Kaitlin Vanderbeck[4], Ramsay Farah[5].

Affiliations: [1] College of Medicine, Upstate Medical University, Syracuse, New York. [2]Department of Microbiology and Immunology, Upstate Medical University, Syracuse, New York, USA. [3] Health Sciences Library, Upstate Medical University, Syracuse, New York. [4]Department of Laboratory Medicine and Pathobiology, University of Toronto, Toronto, Ontario**.** [5] Division of Dermatology, Upstate Medical University, Syracuse, New York

#Adress correspondence to hardyce@upstate.edu

Conflicts of interest: the authors have no conflicts to declare.
Acknowledgements: the authors have no acknowledgements to report.

Author contributions: Céline S. C. Hardy, Conceptualization, Data curation, Formal analysis, Investigation, Methodology, Visualization, Writing – original draft, Writing – review and editing | Ali S. Razavi, Conceptualization, Data curation, Investigation, Methodology, Writing – review and editing | Natalie Nunez, Data curation, Investigation, Writing – review and editing | William Fitzmaurice, Data curation, Investigation, Writing – review and editing | Loma Dave, Data curation, Investigation, Writing – review and editing | Amy R. Slutzky, Data curation, Methodology, Supervision, Writing – review and editing | Kaitlin Vanderbeck, Conceptualization, Data curation, Investigation, Methodology, Supervision, Writing – review and editing | Ramsay Farah, Conceptualization, Investigation, Methodology, Supervision, Writing – review and editing

Immunohistochemical profiles of dermatofibroma and dermatofibrosarcoma protuberans: A scoping review

Keywords: Dermatofibroma, Dermatofibrosarcoma protuberans, Immunohistochemistry, Diagnostic markers

ABSTRACT

This review summarizes the immunohistochemical profiles of dermatofibroma (DF) and dermatofibrosarcoma protuberans (DFSP) as reported by primary literature in the past 10 years. 63 studies were included in the review, with staining information for a total of 99 unique IHC markers reported. The most commonly reported stains were CD34, SMA, S100, and FXIIIa. Most studies applied IHC either to explore descriptive features of DF or DFSP or to determine their utility in diagnostic identification of the lesions. A number of studies applied novel biomarkers which may hold promise for distinguishing DF and DFSP, namely WT1, Cx43, LSP-1, and PHH3, which demonstrated considerable expression differences between the two lesions. This review highlights the need for validation of existing and emerging IHC markers for the diagnosis of DF and DFSP.

1.INTRODUCTION

Dermatofibroma (DF) and dermatofibrosarcoma protuberans (DFSP) are spindle cell lesions with overlapping clinical and histologic features. DF, also known as benign fibrous histiocytoma (BFH), are benign soft tissue tumors with good prognosis. Contrastingly, DFSP are locally aggressive tumors which frequently recur. Additionally, DFSPs may undergo fibrosarcomatous transformation, which portends a higher rate recurrence and increased risk of metastasis[1,2]. Appropriate identification of DFs and DFSPs from each other and their histologic mimics is of critical importance to ensure proper clinical management. Despite their clinical divergence, these two lesions share many histologic and morphologic features. Morphologically, both are spindled lesions which may show increased cellularity and mixed fascicular, whorled or storiform growth patterns. Given their clinical and histologic similarities, it may be challenging to differentiate these two entities on histologic grounds alone, particularly in limited biopsies. Therefore, immunohistochemistry (IHC) is often used to differentiate DF from DFSP and is a mainstay in

their diagnosis. Key immunohistochemical markers classically include cluster of differentiation 34 (CD34) and Factor XIIIa (FXIIIa), where CD34 is known to be strongly positive in over 90% of DFSP[3,4], while DFs are known to be negative for CD34 but positive for factor XIIIa [5,6]. Additional markers used to distinguish between these lesions from each other and their mimics include smooth muscle actin (SMA), S-100, and Desmin. Within both DF and DFSP, IHC can also inform or validate the presence of histologic subtypes, pathogenic/driving gene fusions, and specific pathogenic mechanisms within these lesions.

However, despite the elaborate use of IHC in classifying and studying DF and DFSP, the diagnostic specificity of the currently employed markers is imperfect. Although a number of novel markers have been suggested, constantly emerging literature coupled with a lack of validated data can lead to confusion about which markers are the most effective. For this reason, we conducted a scoping review of the literature in order to systematically report IHC staining data on these lesions, summarize the utility of existing markers, and highlight emerging markers specifically useful for distinguishing DF and DFSP. An effective summary of the current literature on the IHC staining profiles of these lesions is useful for consolidating information and providing insight into prospective biomarkers which require additional validation.

2.METHODS

2.1 Study design

This review was conducted and reported in accordance with the Preferred Reporting Items for Systematic Reviews and Meta-Analyses Extension for Scoping Reviews (PRISMA-ScR) guidelines[7]. An a priori study protocol was registered in the Open Science Framework (https://doi.org/10.17605/OSF.IO/92EWY).

2.2 Information sources and search strategy

Four databases – PubMed, Embase (Elsevier), Scopus (Elsevier), and the Cochrane Library – were searched for relevant articles. For each database, key concepts were defined using combinations of controlled vocabulary (where available) and keywords, to maximize search sensitivity. The PubMed search strategy is given below; full search strategies are given in Appendix X.

PubMed search strategy:

("Histiocytoma, Benign Fibrous"[Mesh] OR "Dermatofibrosarcoma"[Mesh] OR “histiocytoma*”[tiab] OR dermatofibro*[tiab] OR DFSP[tiab] OR “nodular subepidermal fibrosis”[tiab])

AND

("Immunohistochemistry"[Mesh] OR immunohistochem*[tiab] OR IHC[tiab] OR immunostain*[tiab])

Database search strategies limited search results to publication dates over the past 20 years (2003-present). Final searches for all databases were run on June 24, 2024.

2.3 Eligibility criteria

Studies were selected for inclusion in the review if they:

- evaluated protein expression by immunohistochemistry (IHC), specifically immunoperoxidase staining, of tissue specimens from human subjects of histologically confirmed cases of cutaneous DF (including benign fibrous histiocytoma, cutaneous fibrous histiocytoma, and epithelioid fibrous histiocytoma) or DFSP;
- reported the number of lesions evaluated and the fraction of lesions positive or negative for a given marker for greater than 5 lesions;
- focused on evaluating the tumor cell compartment (as opposed to stromal or immune cell profiling); and
- were published in English, French, or Spanish.

The following types of studies were excluded from the review: review articles, case reports, conference abstracts, in vitro studies, and animal studies.

2.4 Article screening

Results from all database searches were uploaded to Covidence (Veritas Health Innovation, Melbourne, Australia). Duplicate records were identified and removed automatically by Covidence, with all duplicate pairs manually confirmed (AS). Then two reviewers (AR, WF, NN, and/or LD) independently screened each title/abstract for inclusion in the review, with any conflicts resolved via discussion with content experts (RF and/or KV). After title/abstract screening was complete, a decision was made to limit the review to studies published over the

past 10 years (2013-present), and to exclude case studies and case series evaluating fewer than five lesions. These decisions were made both due to practical/time constraints and in consideration of the relevance of IHC markers evaluated, pertinence and consistency of antibody clones and staining protocols used. Full-text articles were then screened independently by two reviewers (AR, WF, NN, and/or CH), with any conflicts resolved as described above.

2.5 Data abstraction

Data collection was performed first by one of two independent reviewers (CH, AR) and then independently verified by the second reviewer. The following data were collected and charted using Microsoft Excel:

- Study characteristics (article title, publication date, study aim, study geographic location)
- Lesion information (type and number of lesions studied, sample/specimen type, histologic information if available)
- IHC characteristics (IHC stains performed, method of IHC evaluation, specific antibodies used, staining expression results for lesions of interest)

3.RESULTS

3.1 Selection and characteristics of sources of evidence

Database searches identified 2506 distinct articles. Following title/abstract and full text screening, 63 articles were selected for inclusion in the review[8–70] (**Fig. 1**). Of those 63 studies, 15 contained IHC data for DF only, 28 for DFSP only, and 20 studies contained data for both DF and DFSP. Complete characteristics of data extracted from all articles -- including geographic location, date of sample collection, and study aim -- are summarized in supplemental **Table S1.**

3.2 Immunohistochemical markers applied in DF and DFSP

Across all studies, a total of 99 IHC markers were evaluated, of which the most discussed markers included CD34, SMA, S100, FXIIIa, Desmin, and Ki-67 (**Fig. 2**). Cluster of differentiation 68 (CD68), anaplastic lymphoma kinase (ALK), epithelial membrane antigen (EMA), and pan-cytokeratin (PanCK) were also frequently discussed (**Fig. 2**). The purpose of IHC application in these studies could be broadly categorized as descriptive, diagnostic, or prognostic. Summary tables of IHC biomarkers applied and their indication or purpose of

application in DF and DFSP are summarized in **Table 1** and **Table 2**, respectively. The majority of IHC markers were applied for descriptive or diagnostic purposes. Descriptive studies focused primarily on characterizing expression of a given marker in specific entities, determining associations of expression with variant histology, or evaluating the role of expression in disease pathogenesis. Of the studies evaluating IHC staining with respect to its diagnostic utility, 37 studies assessed a role for IHC in distinguishing histologic mimics from either DF or DFSP, while 15 studies contained data focused specifically on distinguishing DF and DFSP from each other.

3.3 Immunohistochemical markers for distinguishing DF and DFSP

When focusing on studies aiming to characterize differences in immunohistochemical expression between DF and DFSP (n=13), a total of 30 IHC markers were evaluated. CD34 and Factor XIIIa were the most frequently employed markers for distinguishing DF and DFSP in the reviewed studies (**Fig. S1**). Summary statistics of the staining expression of classical markers in DF compared to DFSP across all studies are provided in **Table 3**. CD34 was frequently strongly positive in DFSPs (95.8%), while negative in DF (15.5%), and contrastingly Factor XIIIa was positive in DF (86.2%) but more frequently negative in DFSP (24.9%) (**Table 3**). SMA, ALK, CD99, and CD68 were more frequently positive in DF than DFSP, while S100 and Desmin tended to be negative in both (**Table 3**). Many studies also provided data regarding more novel markers evaluated for distinguishing between the two lesions, these included: Wilm's tumor 1 (WT1), ETS transcription factor (ERG), podoplanin (D2-40), phosphohistone H3 (PHH3), p75, connexin 43 (Cx43), fibroblast growth factor 2 (FGF2), fibroblast growth factor receptor 4 (FGFR4), lymphocyte specific protein 1 (LSP-1), p16, and Ki-67 (**Table 4).** Of these, studies evaluating WT1, Cx43 and LSP-1 demonstrated the greatest difference in expression between DF and DFSP. Complete expression data for all markers across all studies are available in supplemental **Table S2.**

4.DISCUSSION

In this study, we summarize the applications of IHC markers in DF and DFSP and their utility for distinguishing these lesions as reported in the literature over the past 10 years. In this review a total of 99 unique IHC markers were reported in the 63 studies evaluated. Interpretation of the

156 expression data of these markers and the utility of key markers for distinguishing DF and DFSP
157 will be elaborated upon in the following sections.
158
159 **4.1 Accuracy of classical markers for distinguishing DF and DFSP**
160 Classical markers for diagnosis of DF and DFSP such as CD34, FXIIIa, S-100, and Desmin all
161 demonstrated expression in expected proportions and patterns according to the literature[71].
162 However, it is important to note that despite these overall trends there was marked intra-study
163 variability for most markers. For example, even CD34, one of the most specific markers positive
164 in DFSP, was weakly or focally positive in ~15% of DFs[42,53,64]. Most commonly, conventional
165 DFs did show negativity for CD34, however many DFs which contained variant histology were
166 specifically noted to have focal CD34 expression. This highlights previous observations that
167 application of CD34 alone is insufficient, and the need for additional markers to clarify the
168 identity of lesions where CD34 expression is ambiguous or present focally. Interestingly,
169 expression of classical markers CD99 and CD68 were reported of variable diagnostic utility to
170 distinguish DF and DFSP. While one study showed that DFs have higher frequency of CD99
171 positivity compared to DFSPs[37] and additional data supports there being evidently low
172 expression of CD99 in DFSPs (0% positivity)[23,69], data from Song et al. shows 50% positivity in
173 both lesions[23,37,60,69]. Altogether, there remains work to be done to determine the expression in
174 DF compared to DFSP of classical markers using additional sample sets. Beyond these
175 diagnostic applications, there is a need to better understand the expression of classical markers
176 within these lesion types in regions with variant histology.
177
178 **4.2 Emerging markers for distinguishing DF and DFSP**
179 Given the imperfect specificity of classical markers, there is an inherent need to identify and
180 validate the utility of more novel markers for diagnostic dilemmas. A number of the reviewed
181 studies assessed a role for novel markers in distinguishing DF and DFSP from each other or their
182 mimics. Promising emerging IHC markers included WT1, LSP-1, Cx43, and a combined Ki67
183 and PHH3 score, which warrant further investigation[12,26,34,50].Piombino et al. assessed the
184 expression of WT1, a master transcriptional/translational regulator in cell differentiation in a
185 series of soft tissue neoplasms of mesenchymal origin. They found that cytoplasmic WT1
186 expression was absent in all evaluated DFs, but positive in 94.7% of DFSPs[50]. Similar to WT1,

connexin 43 (Cx43) was evaluated by Fernandez-Flores et al. because of its suspected role in pathogenesis. Specifically, with respect to propensity for invasion given that connexins are involved in mediating cell-cell adhesion. Cx43 demonstrated excellent specificity for the lesions, with 100% positivity in DF and 0% positivity in DFSP[26]. Another promising marker studied was Leukocyte specific protein 1 (LSP-1) which was also highly positive in DF, while negative in DFSP[34].

Although Ki-67 is traditionally thought of as a prognostic, rather than diagnostic biomarker, Agarwal et al. identify potential utility of Ki-67 for distinguishing DF and DFSP in a combined scoring system with PHH3[12]. PHH3 is expressed in M phase and is therefore useful in determining mitotic counts. The goal of this study was to assess the utility of a combined scoring system incorporating both the Ki67 index and PHH3 mitotic count, where they found that the mean Ki67 proliferation index and mitotic count were significantly higher in DF compared to DFSP[12]. Interestingly, this study may highlight that the integration of multiple features or biomarkers can provide more comprehensive information than looking for one "silver bullet" IHC marker to clarify the diagnosis.

D2-40 is another emerging marker for which a number of studies suggested utility, however these data were contradictory and require additional validation. A number of studies suggest D2-40 for aiding in the differential diagnosis of DF and DFSP, where D2-40 is positive in DF and negative in DFSP[14,53]. However, data from Song et al. demonstrated only 33% positivity in DF[60]. Like D2-20, markers such as ERG, CD10, and p75 have some data to indicate utility, but require further investigation due to conflicting data, or low sample numbers. Across all markers, it should be noted that small sample size, differences in antibody clones, staining protocols, and staining evaluation methodology remain a challenge that likely contribute greatly to the observed variability across studies evaluating a given marker.

5. Conclusions

In this review, we report the IHC expression in DF and DFSP of traditional diagnostic markers as well as novel markers which may hold diagnostic utility according to the literature from the past 10 years. Of the markers discussed with diagnostic relevance, traditional markers such as CD34, SMA, and FXIIIa were the most common and demonstrated expected expression patterns in DF and DFSP. Additionally, studies investigated novel markers for distinguishing DF and

DFSP such as WT1, Cx43, LSP-1, and PHH3/Ki-67. Future studies should seek to continue investigating the expression of these markers and their potential utility for diagnostic application.

Data availability

Data supporting the findings of this study are available within the article and/or its supplementary material.

REFERENCES

1. Abbott JJ, Oliveira AM, Nascimento AG. The Prognostic Significance of Fibrosarcomatous Transformation in Dermatofibrosarcoma Protuberans. *Am J Surg Pathol*. 2006;30(4). https://journals.lww.com/ajsp/fulltext/2006/04000/the_prognostic_significance_of_fibrosarcomatous.2.aspx

2. Reifs CMA, Salido-Vallejo R. Dermatofibrosarcoma protuberans with fibrosarcomatous transformation. *An Bras Dermatol*. 2016;91(5):700-701. doi:10.1590/abd1806-4841.20164886

3. Abenoza P, Lillemoe T. CD34 and Factor XIII a in the Differential Diagnosis of Dermatofibroma and Dermatofibrosarcoma Protuberans: *Am J Dermatopathol*. 1993;15(5):429-434. doi:10.1097/00000372-199310000-00003

4. Llombart B, Sanmartín O, López-Guerrero JA, et al. Dermatofibrosarcoma protuberans: clinical, pathological, and genetic (*COL1A1-PDGFB*) study with therapeutic implications. *Histopathology*. 2009;54(7):860-872. doi:10.1111/j.1365-2559.2009.03310.x

5. CERIO R, SPAULL J, JONES EW. Histiocytoma cutis: a tumour of dermal dendrocytes (dermal dendrocytoma). *Br J Dermatol*. 1989;120(2):197-206. doi:10.1111/j.1365-2133.1989.tb07783.x

6. RAMANI P, BRADLEY NJ, FLETCHER CDM. QBEND/10, a new monoclonal antibody to endothelium: assessment of its diagnostic utility in paraffin sections. *Histopathology*. 1990;17(3):237-242. doi:10.1111/j.1365-2559.1990.tb00713.x

7. Tricco AC, Lillie E, Zarin W, et al. PRISMA Extension for Scoping Reviews (PRISMA-ScR): Checklist and Explanation. *Ann Intern Med*. 2018;169(7):467-473. doi:10.7326/M18-0850

8. Abdaljaleel MYO, North JP. Sclerosing Dermatofibrosarcoma Protuberans Shows Significant Overlap With Sclerotic Fibroma in Both Routine and Immunohistochemical Analysis: A Potential Diagnostic Pitfall. *Am J Dermatopathol*. 2017;39(2):83-88. doi:10.1097/DAD.0000000000000584

9. Abdaljaleel M, North JP. Positive MITF and NKI/C3 Expression in Cellular Neurothekeoma and Dermatofibroma. *Appl Immunohistochem Mol Morphol*. 2021;29(6):440-445. doi:10.1097/PAI.0000000000000889

10. Adem D, Yazici S, Ozsen M, et al. The Ki-67 proliferation index predicts recurrence-free survival in patients with dermatofibrosarcoma protuberans. *Bosn J Basic Med Sci*. Published online October 20, 2020. doi:10.17305/bjbms.2020.5088

11. Afifi MM, Elnouaem MI, Omar EM, El-Komary I. Oral and Extraoral Intermediate Tumors: Are MMP-9 and Ki-67 Biomarkers Correlated to Their High Recurrence Rates? *Appl Immunohistochem Mol Morphol*. 2020;28(3):229-236. doi:10.1097/PAI.0000000000000703

12. Agarwal A, Gopinath A, Tetzlaff MT, Prieto VG. Phosphohistone-H3 and Ki67: Useful Markers in Differentiating Dermatofibroma From Dermatofibrosarcoma Protuberans and Atypical Fibrohistiocytic Lesions. *Am J Dermatopathol*. 2017;39(7):504-507. doi:10.1097/DAD.0000000000000690

13. AlOtaibi MN, Basfar AS, Jawhari AM, et al. The Burden of Skin Cancers in Saudi Arabia Through 2011-2022. *Cureus*. Published online September 11, 2023. doi:10.7759/cureus.45052

14. Aslam M, Khan FW, Chughtai AS, Naeem A, Bashir A, Khan A. Frequency of Expression of D240 in Dermatofibroma – A diagnostic study. *Pak J Med Health Sci*. 2022;16(1):37-39. doi:10.53350/pjmhs2216137

15. Berklite L, Ranganathan S, John I, Picarsic J, Santoro L, Alaggio R. Fibrous histiocytoma/dermatofibroma in children: the same as adults? *Hum Pathol*. 2020;99:107-115. doi:10.1016/j.humpath.2020.03.012

16. Berklite L, John I, Ranganathan S, Parafioriti A, Alaggio R. SOX9 Immunohistochemistry in the Distinction of Angiomatoid Fibrous Histiocytoma From Histologic Mimics: Diagnostic Utility and Pitfalls. *Appl Immunohistochem Mol Morphol*. 2020;28(8):635-640. doi:10.1097/PAI.0000000000000809

17. Brčić I, Godschachner TM, Bergovec M, et al. Broadening the spectrum of NTRK rearranged mesenchymal tumors and usefulness of pan-TRK immunohistochemistry for identification of NTRK fusions. *Mod Pathol*. 2021;34(2):396-407. doi:10.1038/s41379-020-00657-x

18. Cammareri C, Beltzung F, Michal M, et al. PRAME immunohistochemistry in soft tissue tumors and mimics: a study of 350 cases highlighting its imperfect specificity but potentially useful diagnostic applications. *Virchows Arch*. 2023;483(2):145-156. doi:10.1007/s00428-023-03606-6

19. Campione E, Di Prete M, Costanza G, et al. Increased Occurrence of Cutaneous Leiomyomas and Dermatofibromas in Patients with Uterine Leiomyomas without Fumarate Hydratase

286 Gene Mutations. *Dermatopathology*. 2023;10(3):231-243.
287 doi:10.3390/dermatopathology10030032

288 20. Cheah AL, Billings SD, Goldblum JR, Carver P, Tanas MZ, Rubin BP. STAT6 rabbit monoclonal
289 antibody is a robust diagnostic tool for the distinction of solitary fibrous tumour from its
290 mimics. *Pathology (Phila)*. 2014;46(5):389-395. doi:10.1097/PAT.0000000000000122

291 21. Cleven AHG, Sannaa GAA, Briaire-de Bruijn I, et al. Loss of H3K27 tri-methylation is a
292 diagnostic marker for malignant peripheral nerve sheath tumors and an indicator for an
293 inferior survival. *Mod Pathol*. 2016;29(6):582-590. doi:10.1038/modpathol.2016.45

294 22. Dahiya S, Tomar R, Ahuja M, et al. Dermatofibrosarcoma protuberans: Clinicopathological
295 spectrum with emphasis on lymph node metastasis and fibrosarcomatous transformation. *J*
296 *Cancer Res Ther*. 2022;18(9):439. doi:10.4103/jcrt.JCRT_370_20

297 23. Dai Z, He Y, Zhang X, et al. Head-and-neck dermatofibrosarcoma protuberans: Survival
298 analysis and Clinically relevant immunohistochemical indicators. *Oral Dis*. 2024;30(3):1040-
299 1051. doi:10.1111/odi.14495

300 24. Doyle LA, Mariño-Enriquez A, Fletcher CD, Hornick JL. ALK rearrangement and
301 overexpression in epithelioid fibrous histiocytoma. *Mod Pathol*. 2015;28(7):904-912.
302 doi:10.1038/modpathol.2015.49

303 25. Effiom OA, Olurotimi Olojede AC, Akinde OR, Olawuyi AB, Amoo AT, Arotiba GT.
304 Dermatofibrosarcoma protuberans: clinicopathologic presentation in Nigerians. *Pan Afr*
305 *Med J*. 2018;31. doi:10.11604/pamj.2018.31.25.13665

306 26. Fernandez-Flores A, Varela-Vazquez A, Mayan MD, Fonseca E. Connexin 43 in
307 Dermatofibroma and Dermatofibrosarcoma Protuberans: Diagnostic, Pathogenic, and
308 Therapeutic Implications. *Am J Dermatopathol*. 2023;45(12):812-815.
309 doi:10.1097/DAD.0000000000002562

310 27. Ha SY, Lee SE, Kwon MJ, et al. PDGFB rearrangement in dermatofibrosarcoma protuberans:
311 correlation with clinicopathologic characteristics and clinical implications. *Hum Pathol*.
312 2013;44(7):1300-1309. doi:10.1016/j.humpath.2012.09.021

313 28. Han Q, Chen M, Yang J, Du T, Peng H. Dermatofibrosarcoma protuberans of the face: A
314 clinicopathologic and molecular study of 34 cases. *JDDG J Dtsch Dermatol Ges*.
315 2022;20(11):1463-1473. doi:10.1111/ddg.14882

316 29. Hengy M, Veenstra J, Perry K, Ozog DM, Friedman BJ. ETS-related Gene (ERG) is
317 Differentially Expressed in Dermatofibroma (Fibrous Histiocytoma) as Compared With
318 Dermatofibrosarcoma Protuberans and Hypertrophic Scars: A Pilot Immunohistochemical
319 Study. *Appl Immunohistochem Mol Morphol*. 2022;30(6):453-458.
320 doi:10.1097/PAI.0000000000001030

321 30. Hiraki-Hotokebuchi Y, Yamada Y, Kohashi K, et al. Alteration of PDGFRβ-Akt-mTOR pathway
322 signaling in fibrosarcomatous transformation of dermatofibrosarcoma protuberans. *Hum*
323 *Pathol*. 2017;67:60-68. doi:10.1016/j.humpath.2017.07.001

324 31. Hung YP, Fletcher CDM, Hornick JL. FOSB is a Useful Diagnostic Marker for Pseudomyogenic
325 Hemangioendothelioma. *Am J Surg Pathol*. 2017;41(5):596-606.
326 doi:10.1097/PAS.0000000000000795

327 32. Ishigami T, Hida Y, Matsudate Y, Murao K, Kubo Y. The involvement of fibroblast growth
328 factor receptor signaling pathways in dermatofibroma and dermatofibrosarcoma
329 protuberans. *J Med Invest*. 2013;60(1.2):106-113. doi:10.2152/jmi.60.106

330 33. Jahanseir K, Xing D, Greipp PT, et al. PDGFB Rearrangements in Dermatofibrosarcoma
331 Protuberans of the Vulva: A Study of 11 Cases Including Myxoid and Fibrosarcomatous
332 Variants. *Int J Gynecol Pathol*. 2018;37(6):537-546. doi:10.1097/PGP.0000000000000472

333 34. Jin SY, Choi JS, Choi YL, Choi YL, Kim DH, Lee SH. Identification of Leukocyte-Specific Protein
334 1-Positive Cells: A Clue to the Cell of Origin and a Marker for the Diagnosis of
335 Dermatofibroma. *Ann Dermatol*. 2015;27(2):157. doi:10.5021/ad.2015.27.2.157

336 35. Karanian M, Pérot G, Coindre JM, Chibon F, Pedeutour F, Neuville A. Fluorescence in situ
337 hybridization analysis is a helpful test for the diagnosis of dermatofibrosarcoma
338 protuberans. *Mod Pathol*. 2015;28(2):230-237. doi:10.1038/modpathol.2014.97

339 36. Kazakov DV, Kyrpychova L, Martinek P, et al. ALK Gene Fusions in Epithelioid Fibrous
340 Histiocytoma: A Study of 14 Cases, With New Histopathological Findings. *Am J*
341 *Dermatopathol*. 2018;40(11):805-814. doi:10.1097/DAD.0000000000001085

342 37. Kazlouskaya V, Malhotra S, Kabigting FD, Lal K, Elston DM. CD99 Expression in
343 Dermatofibrosarcoma Protuberans and Dermatofibroma. *Am J Dermatopathol*.
344 2014;36(5):392-396. doi:10.1097/DAD.0b013e3182a15f3e

345 38. Kim JE, Lee JH, Jeong KH, Kim GM, Kang H. Notch Intracellular Domain Expression in Various
346 Skin Fibroproliferative Diseases. *Ann Dermatol*. 2014;26(3):332.
347 doi:10.5021/ad.2014.26.3.332

348 39. Kouki N, Ben Rejeb S, Cherif I, et al. Comparative expression profile of CD10 and cyclin D1 in
349 cutaneous histiocytofibroma and dermatofibrosarcoma. *J Immunoassay Immunochem*.
350 2021;42(4):347-358. doi:10.1080/15321819.2020.1868000

351 40. Kreicher KL, Honda KS, Kurlander DE, Bordeaux JS. Hormone receptor expression in patients
352 with dermatofibrosarcoma protuberans. *J Am Acad Dermatol*. 2016;75(6):1205-1209.
353 doi:10.1016/j.jaad.2016.07.011

354 41. Li FZ, Ye Q, Ran LW, Fang S. Adipophilin expression in skin lesions with clear cell histology. *J*
355 *Clin Pathol*. 2022;75(9):627-631. doi:10.1136/jclinpath-2021-207443

356 42. Liu F, Wang H, Wu G, Li C. Clinical and pathological studies of eight cases of lipidized fibrous
357 histiocytoma. *Exp Ther Med*. 2023;25(2):93. doi:10.3892/etm.2023.11792

358 43. Lo C hai, Tsang P man, Cheng S ying, Ling C nam, Ho C lam. Myoid differentiation in
359 dermatofibrosarcoma protuberans and its fibrosarcomatous variant: 10 years experience in
360 a tertiary hospital. *Autopsy Case Rep*. 2022;12:e2021368. doi:10.4322/acr.2021.368

361 44. Meng T, Shi X, Wu S, Luo Y, Wang X, Long X. Hormone receptors analysis in Chinese patients
362 with dermatofibrosarcoma protuberans. *J Surg Oncol*. 2018;118(1):157-166.
363 doi:10.1002/jso.25117

364 45. Moayed-Alaei L, Vargas AC, Adybeik D, Maclean F, Moir D. Analyzing the morphological
365 spectrum of epithelioid fibrous histiocytoma and the immunohistochemical performance of
366 the ALK D5F3 and ALK1 clones. *Hum Pathol*. 2022;120:46-56.
367 doi:10.1016/j.humpath.2021.12.004

368 46. Nakamura I, Kariya Y, Okada E, et al. A Novel Chromosomal Translocation Associated With
369 *COL1A2* - *PDGFB* Gene Fusion in Dermatofibrosarcoma Protuberans: PDGF Expression as a
370 New Diagnostic Tool. *JAMA Dermatol*. 2015;151(12):1330.
371 doi:10.1001/jamadermatol.2015.2389

372 47. Nam KH, Park SW, Yun SK. A clinicohistopathological analysis of cutaneous fibrous
373 histiocytomas of the finger. *Indian J Dermatol*. 2020;65(5):401. doi:10.4103/ijd.IJD_366_18

374 48. Pan H, Byers J, Yin H, et al. The utility of TLE1 and BCOR as immunohistochemical.

375 49. Park S, Cho S, Kim M, et al. Dermatofibrosarcoma protuberans: A retrospective study of
376 clinicopathologic features and related Akt/mTOR, STAT3, ERK, cyclin D1, and PD-L1
377 expression. *J Am Acad Dermatol*. 2018;79(5):843-852. doi:10.1016/j.jaad.2018.05.016

378 50. Piombino E, Broggi G, Barbareschi M, et al. Wilms' Tumor 1 (WT1): A Novel Immunomarker
379 of Dermatofibrosarcoma Protuberans—An Immunohistochemical Study on a Series of 114
380 Cases of Bland-Looking Mesenchymal Spindle Cell Lesions of the Dermis/Subcutaneous
381 Tissues. *Cancers*. 2021;13(2):252. doi:10.3390/cancers13020252

382 51. Pukhalskaya T, Smoller BR. TLE1 expression fails to distinguish between synovial sarcoma,
383 atypical fibroxanthoma, and dermatofibrosarcoma protuberans. *J Cutan Pathol*.
384 2020;47(2):135-138. doi:10.1111/cup.13596

385 52. Russell-Goldman E, Dong F, Laga A, Hanna J. A Novel Fusion Partner, SP100, Drives Nuclear
386 Dot Localization of ALK in Epithelioid Fibrous Histiocytoma. *Am J Dermatopathol*.
387 2023;45(8):539-543. doi:10.1097/DAD.0000000000002475

388 53. Sadullahoglu C, Dere Y, Atasever TR, Oztop MT, Karaaslan O. The role of cd34 and d2-40 in
389 the differentiation of dermatofibroma and dermatofibrosarcoma protuberans. *Turk J*
390 *Pathol*. Published online 2017. doi:10.5146/tjpath.2017.01402

391 54. Saeed O, Zhang S, Cheng L, Lin J, Alruwaii F, Chen S. STAT6 Expression in Solitary Fibrous
392 Tumor and Histologic Mimics: a Single Institution Experience. *Appl Immunohistochem Mol*
393 *Morphol*. 2020;28(4):311-315. doi:10.1097/PAI.0000000000000745

394 55. Sandell RF, Carter JM, Folpe AL. Solitary (juvenile) xanthogranuloma: a comprehensive
395 immunohistochemical study emphasizing recently developed markers of histiocytic lineage.
396 *Hum Pathol*. 2015;46(9):1390-1397. doi:10.1016/j.humpath.2015.05.025

397 56. Schechter SA, Bresler SC, Patel RM. Fat necrosis with an associated lymphocytic infiltrate
398 represents a histopathologic clue that distinguishes cellular dermatofibroma from
399 dermatofibrosarcoma protuberans. *J Cutan Pathol*. 2020;47(10):913-916.
400 doi:10.1111/cup.13744

401 57. Serra-Guillén C, Llombart B, Nagore E, et al. High immunohistochemical nestin expression is
402 associated with greater depth of infiltration in dermatofibrosarcoma protuberans: a study
403 of 71 cases. *J Cutan Pathol*. 2013;40(10):871-878. doi:10.1111/cup.12203

404 58. Shah KK, McHugh JB, Folpe AL, Patel RM. Dermatofibrosarcoma Protuberans of Distal
405 Extremities and Acral Sites: A Clinicopathologic Analysis of 27 Cases. *Am J Surg Pathol*.
406 2018;42(3):413-419. doi:10.1097/PAS.0000000000000998

407 59. Smith EH, Lowe L, Harms PW, Fullen DR, Chan MP. Immunohistochemical evaluation of P16
408 expression in cutaneous histiocytic, fibrohistiocytic and undifferentiated lesions. *J Cutan*
409 *Pathol*. 2016;43(8):671-678. doi:10.1111/cup.12730

410 60. Song JS, Kim EJ, Park CS, Cho KJ. Dermatofibrosarcoma Protuberans: An Immunomarker
411 Study of 57 Cases That Included Putative Mesenchymal Stem Cell Markers. *Appl*
412 *Immunohistochem Mol Morphol*. 2017;25(8):586-591. doi:10.1097/PAI.0000000000000348

413 61. Thangaiah JJ, Westling BE, Roden AC, et al. Loss of dimethylated H3K27 (H3K27me2)
414 expression is not a specific marker of malignant peripheral nerve sheath tumor (MPNST):
415 An immunohistochemical study of 137 cases, with emphasis on MPNST and melanocytic
416 tumors. *Ann Diagn Pathol*. 2022;59:151967. doi:10.1016/j.anndiagpath.2022.151967

417 62. Üyetürk Ü. Dermatofibrosarcoma Protuberans: A Rare Malignancy. *Turk J Oncol*. Published
418 online 2017. doi:10.5505/tjo.2017.1635

419 63. Vivero M, Doyle LA, Fletcher CDM, Mertens F, Hornick JL. GRIA 2 is a novel diagnostic
420 marker for solitary fibrous tumour identified through gene expression profiling.
421 *Histopathology*. 2014;65(1):71-80. doi:10.1111/his.12377

422 64. West KL, Cardona DM, Su Z, Puri PK. Immunohistochemical Markers in Fibrohistiocytic
423 Lesions: Factor XIIIa, CD34, S-100 and p75. *Am J Dermatopathol*. 2014;36(5).

65. Xiong JX, Cai T, Hu L, et al. Risk factors related to postoperative recurrence of dermatofibrosarcoma protuberans: A retrospective study and literature review. *World J Clin Cases*. 2021;9(20):5442-5452. doi:10.12998/wjcc.v9.i20.5442

66. Xu S, Zhao L, Wang J. Atrophic dermatofibrosarcoma protuberans: a clinicopathological study of 16 cases. *Pathology (Phila)*. 2019;51(6):615-620. doi:10.1016/j.pathol.2019.06.002

67. Yamada Y, Ichiki T, Susuki Y, et al. Diagnostic utility of ERG immunostaining in dermatofibroma. *J Clin Pathol*. 2023;76(8):536-540. doi:10.1136/jclinpath-2022-208158

68. Zhang X, Sun D, Zheng H, et al. Comprehensive analysis of transcriptome characteristics and identification of TLK2 as a potential biomarker in dermatofibrosarcoma protuberans. *Front Genet*. 2022;13:926282. doi:10.3389/fgene.2022.926282

69. Zhang Z, Lu Y, Shi C, Chen M, He X, Zhang H. Pediatric dermatofibrosarcoma protuberans: A clinicopathologic and genetic analysis of 66 cases in the largest institution in Southwest China. *Front Oncol*. 2023;13:1017154. doi:10.3389/fonc.2023.1017154

70. Zhou L, Xu H, Zhou J, et al. Nuclear TFE3 expression is a diagnostic marker for Desmoid-type fibromatosis. *Diagn Pathol*. 2019;14(1):34. doi:10.1186/s13000-019-0814-4

71. Haycox CL, Odland PB, Olbricht SM, Piepkorn M. dermatofibrosarcoma protuberans with practical applications for diagnosis and treatment.

TABLES

Table 1. Immunohistochemical biomarkers applied in DF and their primary indication as evaluated in the studies reviewed.

Indication	Markers	Utility/Findings
Diagnostic	CD34, FXIIIa, S100, SMA, Desmin, Vimentin	Classical diagnostic markers
	FOSB	Distinguish from pseudomyogenic hemagioendothelioma[31]
	SOX9	Distinguish from AFH[16]
	TLE1, BCOR	Distinguish from AFH[48]
	STAT6	Distinguish from SFT[20]
	MITF, NKI/C3	Compare to expression in cellular neurothekoma[9]
	TFE3	Compare expression to desmoid type fibromatosis[70] and evaluate histopathologic features[36,45]
	ERG[29,67], WT1[50], p75[64], D2-40[14,53]	Distinguish from DFSP and its mimics
	CD10[39,60], CCND1[39], LSP1[34], CD68[34,42,45,47]	Distinguish from DFSP
	CD99	Distinguish from DFSP and describe expression[37,60]
Descriptive	MUC4	Describe features of lipidized fibrous histiocytoma[42]
	FGFR1-4, FGF2	Understand expression patterns and role in pathogenesis[32]

	Akt, mTOR, STAT3, ERK, CCND1	Understand expression pattern and assess role in recurrence[49]
	CD163[45,55], CD11c,CD31,CD45, lysozyme, and CD4[55]	Characterize the immunophenotype of solitary xanthogranuloma in comparison to its differential diagnoses (including BFH)
	NCID[38], PRAME[18]	Describe expression in various fibroproliferative diseases
	TGFb, TGFRb-1/2, SMAD3, VDR	Describe expression in DF, cutaneous leiomyomas, and uterine leiomyomas[19]
	PanCK[42,45], SOX10, p63, and EMA[45], P16[59,69], P53[33,41], CD105, CD133, Oct3/4, CD117, and ALK[60], PDGFRα/β, PDGFα/β[46,60], Nestin[46]	Describe expression
Prognostic	Ki-67, MMP9	Association with high recurrence rate[11]

Abbreviations: AFH, angiomatoid fibrous histiocytoma; Akt, protein kinase B; ALK, anaplastic lymphoma kinase; BCOR, BCL6 corepressor; BHF, benign fibrous histiocytoma; CCND1, cyclin D1; CD, cluster of differentiation (CD34, CD10, CD68, CD99, CD163, CD11c, CD31, CD45, CD4, CD105, CD133, CD117); D2-40, podoplanin; DF, dermatofibroma; DFSP, dermatofibrosarcoma protuberans; EMA, Epithelial membrane antigen; ERG, erythroblast transformation specific related gene; ERK, extracellular signal-regulated kinase; FXIIIa, factor XIIIa; FGF2, fibroblast growth factor 2; FGFR1-4, fibroblast growth factor receptors 1-4; FOSB, FBJ murine osteosarcoma viral oncogene homolog B; Ki-67, Antigen Kiel 67; LSP1, lymphocyte-specific protein 1; MITF, microphthalmia-associated transcription factor; MMP, matrix metalloproteinase; mTOR, mammalian target of rapamycin;MUC4, mucin 4;NICD, notch intracellular domain; NKI/C3, also known as cluster of differentiation 68 (CD68); Oct3/4, octamer-binding transcription factor 3/4; P, protein (p75, p63, p16, p53); PanCK, pan-cytokeratin; PDGFα/β, platelet derived growth factor alpha and beta; PDGFRα/β, platelet derived growth factor receptor alpha and beta; PRAME, Preferentially expressed Antigen in Melanoma; SFT, solitary fibrous tumor; SMA, smooth muscle actin; SMAD3, suppressor of mothers against decapentaplegic homolog 3; SOX, SRY-related HMG box gene (SOX9, SOX10); STAT3, signal transducer and activator of transcription 3; STAT6, signal transducer and activator of transcription 6; TFE3, transcription factor binding to IGHM enhancer 3; TGFb, transforming growth factor beta; TGFRb-1/2, transforming growth factor beta receptor 1 and 2; TLE1, transducin-like enhancer of split 1; VDR, vitamin D receptor; WT1, Wilms tumor gene 1

Table 2. Immunohistochemical markers applied in DFSP and their primary indication as evaluated in the studies reviewed.

Indication	Markers	Utility/Findings
Diagnostic	CD34, FXIIIa, SMA, S100, Desmin, Vimentin	Classical diagnostic markers
	GRIA2[63], STAT6[20,54,66]	Distinguish from SFT[20] and describe expression
	H3K27me3, H3K27me2	Distinguish PNST from its mimics[21,61]
	TLE1	Distinguish AFX and synovial sarcoma[51]
	EVG	Compare to expression in sclerotic fibroma and perineuroma[8]
	ERG	Distinguish from its mimics[29,67]
	WT1	Distinguish from DFSP and its mimics[50]
	LSP1[34], CD68[37,66], p75[64], D2-40[53,60], CD10[39,41,60], CCND1[39,49]	Distinguish from DF
Descriptive	Melan-A[37,66], PanCK and HMB45[66]	Study features of atrophic DFSP
	ER, PR	Describe role in pathogenesis/tumor growth[40,44]
	FGFR1-4, FGF2	Understand expression patterns and role in pathogenesis[32]
	Akt[30,49], mTOR, STAT3, and ERK [49], p-4EBP1, p-S6RP, p-and mTOR[30]	Understand expression patterns and role in pathogenesis
	NTRK[17]	Describe expression in soft tissue sarcomas
	P16[59,69]	Describe expression patterns

	BCL-2[23,65,69], CD99[23,37,60,69], p63, Myogenin[69], MSA[23]	Describe expression patterns/understand clinicopathologic features
	EMA	Describe expression[8,28,69] and assess relevance to fibrosarcomatous transformation[41]
	CD105, CD133, ALK, Oct3/4, and CD117[60], PDGFRα/β[23,30,60], PDGFα/β[23,60], FAM118B and TLK2[68], PRAME[18]	Describe expression
Prognostic	Ki-67	Independent predictor of RFS[10]
	EZH2, EGFR, PD-L1, VEGF	Investigation as therapeutic targets [23]
	Nestin[46,57]	Association of expression with degree of invasion[57]

Abbreviations: AFX, atypical fibroxanthoma; Akt, protein kinase B; ALK, anaplastic lymphoma kinase; BCL-2, b-cell leukemia/lymphoma 2 protein;CCND1, cyclin D1; CD, cluster of differentiation (CD34, CD68, CD10, CD99, CD105, CD133, CD177); D2-40, podoplanin; DF, dermatofibroma; DFSP, dermatofibrosarcoma protuberans; EGFR, epidermal growth factor receptor;EMA, epithelial membrane antigen; ER, estrogen receptor; ERG, erythroblast transformation specific related gene; ERK, extracellular signal-regulated kinase; EVG, elastin Van Gieson; EZH2, enhancer of zeste homolog 2;FAM118B, family with sequence similarity 118 member B;FGF2, fibroblast growth factor 2; FGFR1-4, fibroblast growth factor receptors 1-4; FXIIIa, factor XIIIa; GRIA2, glutamate ionotropic receptor AMPA type subunit 2; H3K27me2, epigenetic modification to the DNA packaging protein Histone H2; H3K27me3, epigenetic modification to the DNA packaging protein Histone H3; HMB45, human melanoma black 45; Ki-67, Antigen Kiel 67; LSP1, lymphocyte-specific protein 1;Melan-A, melanoma antigen recognized by T cells; MSA, muscle specific actin; mTOR, mammalian target of rapamycin; NTRK, neurotrophic tyrosine receptor kinase; Oct3/4, octamer-binding transcription factor 3/4;P, protein; (p75, p16, p63); p-4EBP1, eukaryotic translation initiation factor 4E-binding protein 1; p-mTOR, phosphorylated mammalian target of rapamycin; p-S6RP, S6 ribosomal protein; PanCK, pan-cytokeratin; PDGFα/β, platelet derived growth factor alpha and beta; PDGFRα/β, platelet derived growth factor receptor alpha and beta; PD-L1, programmed death-ligand 1; PNST, peripheral nerve sheath tumor; PR, progesterone receptor; PRAME, Preferentially expressed Antigen in Melanoma; RFS, recurrence-free survival; SFT, solitary fibrous tumor; SMA, smooth muscle actin; STAT, signal transducer and activator of transcriptionSTAT6, signal transducer and activator of transcription 6;TLE1, transducin-like enhancer of split 1; TLK2, tousled-like kinase 2;VEGF, vascular endothelial growth factor; WT1, Wilms tumor gene 1.

Table 3. General trends of immunohistochemical expression for classical/well described markers for distinguishing DF and DFSP.

Listed markers	**DF**		**DFSP**	
	General expression (+/-)	In evaluated studies n/total, (%)	General expression (+/-)	In evaluated studies n/total, (%)
CD34	-	35/226 (15.5)	+	980/1023 (95.8)
FXIIIa	+	163/189 (86.2)	-	28/108 (25.9)
SMA	+	63/183 (34.4)	-	26/370 (7)
S100	-	15/114 (13.1)	-	12/432 (2.8)
ALK	+	71/154 (46.1)	-	0/57 (0)
CD99	+	30/36 (83.3)	-	56/176 (31.8)
CD68	+	25/59 (42.4)	-	5/27 (18.5)
Desmin	-	0/41(0)	-	0/332 (0)
Vimentin	N/A	N/A	+	123/126 (97.6)

n/total where n=number of positive samples. Abbreviations: (+), positive for expression; (-), negative for expression; ALK, anaplastic lymphoma kinase; CD, cluster of differentiation

493 (CD34, CD99, CD68); DF, dermatofibroma; DFSP, dermatofibrosarcoma protuberans; FXIIIa,
494 factor XIIIa; N/A, not available; SMA, smooth muscle actin.
495
496 **Table 4**. General trends of immunohistochemical expression for novel/emerging markers
497 evaluated in distinguishing DF and DFSP.

Marker	**Evidence** (n positive/total)	**Study**
WT1	Negative in DF (0/15), positive in DFSP (54/57)	Piombino et al. (2021)[50]
Cx43	Positive in DF (16/16), Negative in DFSP (0/13 positive)	Fernandez-flores et al. (2023)[26]
LSP-1	Positive in DF (18/20), negative in DFSP (2/20)	Jin et al. (2015)[34]
ERG	87/97 DF positive with variable (50-89% cells) positive, 0/64 DFSP positive	Yamada et al. (2023)[67]
	15/15 DF positive, 6/9 DFSP positive	Hengy et al. (2022)[29]
PHH3	DF mean mitotic count 1.8 mm^2, DFSP mean mitotic count 0.5/mm^2	Agarwal et al. (2017)[12]
Ki-67	Mean proliferative index in DF: 39.2mm^2, DFSP: 12.6 mm^2	Agarwal et al. (2017)[12]
P75	0/30 DF positive, 17/32 DFSP positive	West et al. (2014)[64]
D2-40	Positive in DF (49/70)	Aslam et al. (2021)[14]
	Positive in DF (23/30) and negative in DFSP (2/15 positive)	Sadullahoglu 2017[53]
	DF 4/12 positive, DFSP 2/57 positive	Song et al. (2017)[60]
Oct3/4	0/12 DF, 0/57 DFSP	Song et al. (2017)[60]
CD10	12/12 DF, 23/57 DFSP	Song et al. (2017)[60]
	13/15 DF, 15/15 DFSP	Kouki et al. (2021)[39]
	12/15 DF, 15/15 DFSP	Kouki et al. (2021)[30]
FGF2 and FGFR4	Positive in DF (20/20), variable expressivity in DFSP (4/6 positive)	Ishigami et al. (2013)[32]
FGFR1-3	All cases negative in both DF (0/20) and DFSP (0/6)	Ishigami et al. (2013)[32]
P16	Positive in both DF (18/19) and DFSP (4/5)	Smith et al. (2016)[59]

498 Abbreviations: CD, cluster of differentiation (CD10); Cx43, connexin 43; D2-40, podoplanin;
499 DF, dermatofibroma; DFSP, dermatofibrosarcoma protuberans; ERG, erythroblast
500 transformation specific related gene; FGF2, fibroblast growth factor 2; FGFR1-3, fibroblast
501 growth factor receptors 1-3; FGFR4, fibroblast growth factor receptor 4; Ki-67, Antigen Kiel 67;
502 LSP1, lymphocyte-specific protein 1; Oct3/4, octamer-binding transcription factor 3/4; P, protein
503 (p75, p16);PHH3, phosphohistone H3; WT1, Wilms tumor gene 1.
504
505
506

507 **FIGURE LEGENDS**

508 **Figure 1. PRISMA flow diagram indicating the article selection process.**

509 **Figure 2. Frequency of IHC biomarker use across all studies (n=63).** Bar plot indicating the
510 frequency of IHC biomarkers assessed across all studies. Bars indicate the number of studies
511 which evaluated a given marker.

512

513 **SUPPLEMENTAL MATERIAL**

514 **Table S1.** Study characteristics data extracted from the included studies (n=63).

515 **Table S2.** IHC expression data extracted from the included studies (n=63).

516 **Figure S1. Frequency of IHC biomarker use in studies distinguishing between DF and**
517 **DFSP (n=15).** Bar plot indicating the frequency of IHC biomarkers assessed across studies
518 which aimed to differentiate DF and DFSP. Bars indicate the number of studies which evaluated
519 a given marker.

520

521

522

Figure 1.

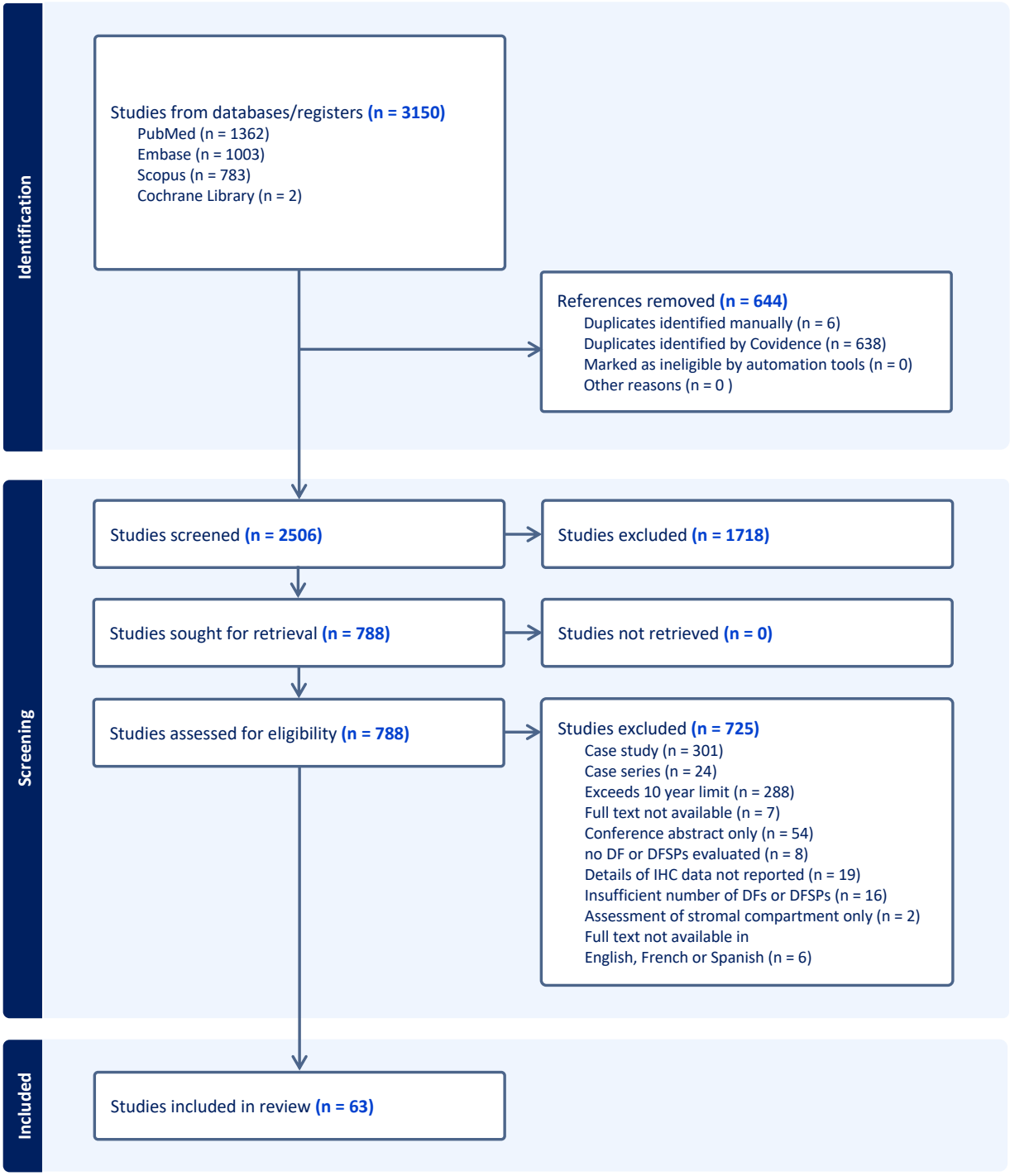
Identification
Studies from databases/registers (n = 3150)
PubMed (n = 1362)
Embase (n = 1003)
Scopus (n = 783)
Cochrane Library (n = 2)
References removed (n = 644)
Duplicates identified manually (n = 6)
Duplicates identified by Covidence (n = 638)
Marked as ineligible by automation tools (n = 0)
Other reasons (n = 0)
Screening
Studies screened (n = 2506)
Studies excluded (n = 1718)
Studies sought for retrieval (n = 788)
Studies not retrieved (n = 0)
Studies assessed for eligibility (n = 788)
Studies excluded (n = 725)
Case study (n = 301)
Case series (n = 24)
Exceeds 10 year limit (n = 288)
Full text not available (n = 7)
Conference abstract only (n = 54)
no DF or DFSPs evaluated (n = 8)
Details of IHC data not reported (n = 19)
Insufficient number of DFs or DFSPs (n = 16)
Assessment of stromal compartment only (n = 2)
Full text not available in
English, French or Spanish (n = 6)
Included
Studies included in review (n = 63)

Figure 2.

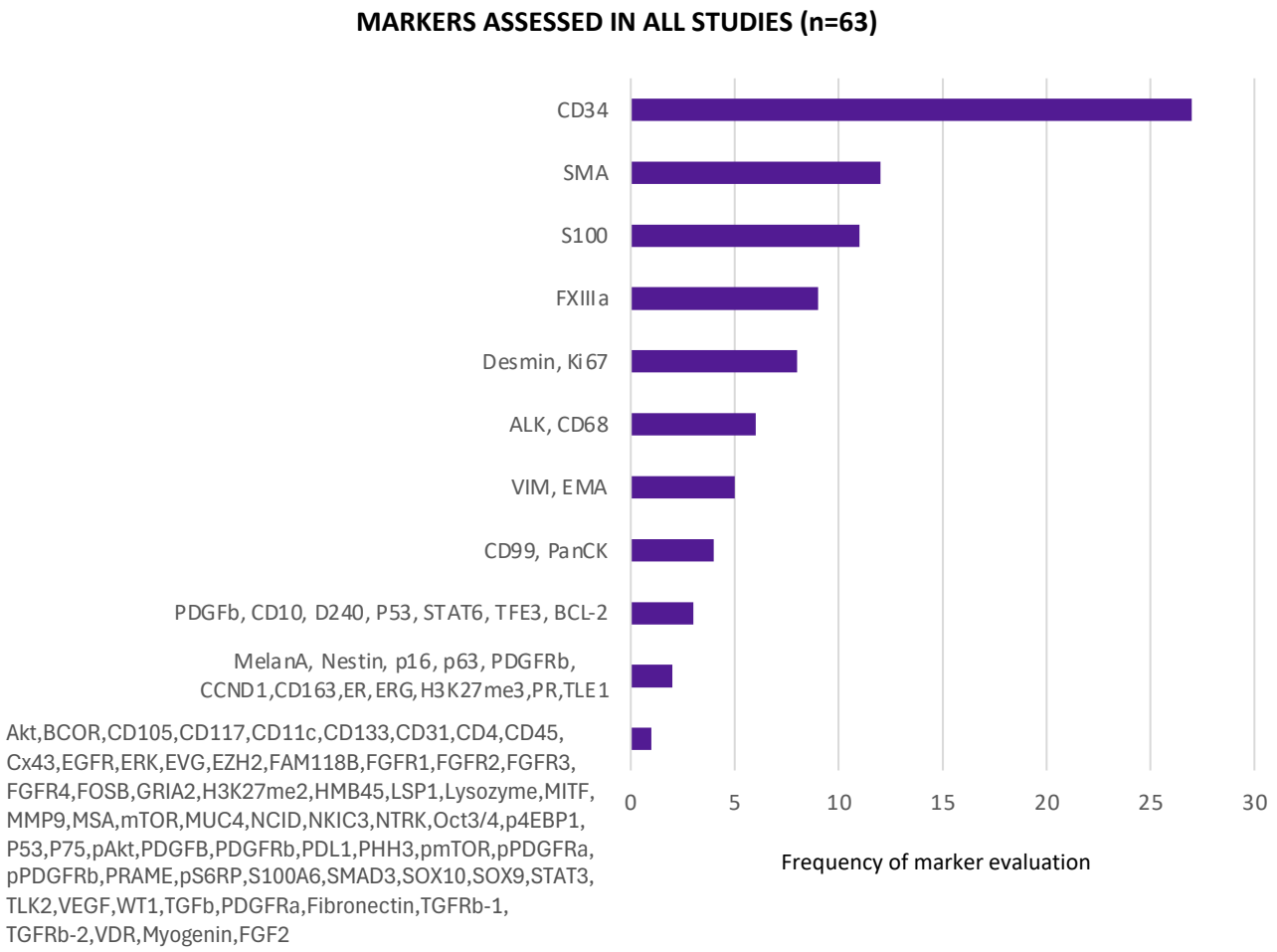
MARKERS ASSESSED IN ALL STUDIES (n=63)
CD34
SMA
S100
FXIIIa
Desmin, Ki67
ALK, CD68
VIM, EMA
CD99, PanCK
PDGFb, CD10, D240, P53, STAT6, TFE3, BCL-2
MelanA, Nestin, p16, p63, PDGFRb, CCND1,CD163,ER, ERG, H3K27me3,PR,TLE1
Akt,BCOR,CD105,CD117,CD11c,CD133,CD31,CD4,CD45, Cx43,EGFR,ERK,EVG,EZH2,FAM118B,FGFR1,FGFR2,FGFR3, FGFR4,FOSB,GRIA2,H3K27me2,HMB45,LSP1,Lysozyme,MITF, MMP9,MSA,mTOR,MUC4,NCID,NKIC3,NTRK,Oct3/4,p4EBP1, P53,P75,pAkt,PDGFB,PDGFRb,PDL1,PHH3,pmTOR,pPDGFRa, pPDGFRb,PRAME,pS6RP,S100A6,SMAD3,SOX10,SOX9,STAT3, TLK2,VEGF,WT1,TGFb,PDGFRa,Fibronectin,TGFRb-1, TGFRb-2,VDR,Myogenin,FGF2
0
5
10
15
20
25
30
Frequency of marker evaluation