medRxiv preprint doi: https://doi.org/10.1101/2024.09.30.24314649; this version posted October 2, 2024. The copyright holder for this preprint (which was not certified by peer review) is the author/funder, who has granted medRxiv a license to display the preprint in perpetuity. It is made available under a CC-BY-NC-ND 4.0 International license .

A Method For Mimicking Tumour Tissue In Brain Ex-Vivo Ultrasound For Research Application And Clinical Training

Alistair Weld[a], Luke Dixon[b], Giulio Anichini[c], Giovanni Faoro[d], Arianna Menciassi[d], Sophie Camp[c], Stamatia Giannarou[a]

[a] *Hamlyn Centre, Imperial College London, UK*
[b] *Department of Imaging, Charing Cross Hospital, UK*
[c] *Department of Neurosurgery, Charing Cross Hospital, UK*
[d] *BioRobotics Institute, Scuola Superiore Sant'Anna, IT*

Abstract

Introduction: Intraoperative ultrasound is becoming a common tool in neurosurgery. However, effective simulation methods are limited. Current, commercial, and homemade phantoms lack replication of anatomical correctness and texture complexity of brain and tumour tissue in ultrasound images. Materials and Methods: We utilise ex-vivo brain tissue, as opposed to synthetic materials, to achieve realistic echogenic complexity and anatomical correctness. Agar, at 10-20% concentrate, is injected into the brain tissue to simulate the tumour mass. A commercially available phantom was purchased for benchmarking. Results: Qualitative analysis is performed by experienced professionals, measuring the impact of the addition of agar and comparing it to the commercial phantom. Overall, the use of ex vivo tissue was deemed more accurate and representative, compared to the synthetic materials-based phantom, as it provided good visualisation of real brain anatomy and good contrast within tissue. The agar tumour correctly produced a region of higher echogenicity with slight diffusion along the margin and expected interaction with the neighbouring anatomy. Discussion: Using human samples for training is limited due to high logistical and ethical challenges. Sparsity of online neurosurgical US data further compounds this. The proposed method successfully produced a better simulation of tumours in brain tissue than the phantom which suffers from surface texture dissimilarity, ultrasound echogenic homogeneity, and lack of anatomical correctness. Conclusion: The proposed method for creating tumour-mimicking tissue in brain tissue is in-

NOTE: This preprint reports new research that has not been certified by peer review and should not be used to guide clinical practice.

medRxiv preprint doi: https://doi.org/10.1101/2024.09.30.24314649; this version posted October 2, 2024. The copyright holder for this preprint (which was not certified by peer review) is the author/funder, who has granted medRxiv a license to display the preprint in perpetuity. It is made available under a CC-BY-NC-ND 4.0 International license .

expensive, accurate, and simple. Beneficial for both the trainee clinician and the researcher. A total of 576 annotated images are made publicly available upon request. Word count ≈ 3400.

Keywords: Ultrasound, Homemade Brain Tumour, Medical Education, Inexpensive Data Simulation

---

1. Introduction

Intraoperative ultrasound (IOUS) is an increasingly popular tool, as it is a viable alternative to more complex, time consuming and expensive solutions such as intraoperative magnetic resonance imaging [1] [2]. However, this imaging technology and the relevant expertise required to master it reside in a state of "terra incognita"; who performs this task is not well defined, whether it should be the surgeon, radiologist, sonographer, or a combination of these professionals. The background commensurate training, in turn, remains highly variable and not standardised. In radiology, radiologists and sonographers undergo formal training and routinely perform hundreds of supervised US scans on real patients over a condensed period to reach competency with accepted forms of assessment and accreditation. In contrast, in surgery, US training is highly variable depending on local practice and expertise and typically lacks the same structure. This is compounded by the much lower frequency of cases and greater risks that are inherent to intraoperative US which greatly limits access and slows experience in contrast to routine nonoperative diagnostic US which is high volume, low risk, and ubiquitous across most hospitals. Taking into account these challenges but also the many strengths of IOUS, such as real-time imaging and ease of integration into the surgical workflow, it is clear that methods to improve surgical training in IOUS are needed.

A particularly noteworthy application of IOUS is in oncological brain surgery, where the goal is maximal safe resection (removing the most tumour while preserving function and avoiding disability). This is due to the reduced reliability of preoperative imaging due to factors such as brain shift and deformation and the specific challenges with delineating pathological from functional tissue in the brain[3]. Precision and safety are of the utmost importance during brain IOUS, as the probe interacts with highly sensitive, fragile, and functionally crucial cortical surfaces. During tumour resection, a craniotomy is performed to expose a localised section of the brain surface

medRxiv preprint doi: https://doi.org/10.1101/2024.09.30.24314649; this version posted October 2, 2024. The copyright holder for this preprint (which was not certified by peer review) is the author/funder, who has granted medRxiv a license to display the preprint in perpetuity. It is made available under a CC-BY-NC-ND 4.0 International license .

directly above the tumour. IOUS can then be used to visualise the brain and locate pathological tissue. This cavity is typically small, with a limited field of view, and will often contain blood products, gas, and other sources of artefacts that can complicate scanning [4]. The aforementioned difficulty with gaining necessary IOUS experience is also particularly daunting in neurosurgery, where it is uniquely not possible to perform practice US scanning of the brain on people outside of the operating theatre as a window through the skull is needed. This is in contrast to IOUS in liver surgery, where diagnostic liver US can be performed to gain experience. In neurosurgery, this further steepens the learning curve impacting adoption and performance.

Currently, the availability of accurate simulations of this surgical procedure and brain anatomy is limited, which is a factor that has contributed to the lack of standardised training [3], experimental research and technical innovation. This, therefore, compels the development of preclinical resources that approximate real-world practice.

In this article, a simple method is proposed for the modification of the inexpensive, commercially available brain ex vivo to mimic the appearance of pathological tissue in US. This methodology creates a resource that can be used for both technical innovation and clinical training.

2. Literature Review

Traditionally, medical phantoms are used to simulate anatomy and medical procedures. Due to the absence of standardised training and the relatively small pool of clinicians with significant experience with this imaging technique, there is limited access to purchasable educational tools and known homemade methods for creating phantoms for this IOUS application. Most commercially available brain phantoms are primarily designed for cutting, suturing, incision, and general surgical training and tend to be expensive. For example, the Blue Phantom range by Elevate Healthcare, who are a large provider of simulation technology for training, has products ranging from a £612 Branched 2 Vessel Training Block Model, a £1830 Thyroid Biopsy Training Model, a £7314 Scrotal Training Model, to a £40,932 FAST Exam Training Model (as listed on Sim & Skills). As ultrasound is only one facet of the surgical process, the anatomical correctness of the tissue is usually simplistic, lacking real structural and textural details. This, in the case of the brain, is a significant issue due to the inherent complexity of the anatomy.

medRxiv preprint doi: https://doi.org/10.1101/2024.09.30.24314649; this version posted October 2, 2024. The copyright holder for this preprint (which was not certified by peer review) is the author/funder, who has granted medRxiv a license to display the preprint in perpetuity. It is made available under a CC-BY-NC-ND 4.0 International license .

Homemade phantoms can be a more affordable and customisable solution. These phantoms can be made using food products [5] such as spam [6] or solutions such as ballistic gelatin [7] [8], bovine gelatin [9], sodium alginate [10], polyvinyl alcohol (PVA) [11] or agar [12][13]. In particular, agar has been shown to successfully replicate the mechanical properties of human tumour tissue [14]. Although these methods are inexpensive, the core structure of the phantom will be simplistic, with significant homogeneity present in the ultrasound texture, characterised by a single echogenic level. Foreign bodies can be embedded in the medium to create diversity in echogenic features [15]. However, because of the simplicity of the medium, the insertion of these objects tends to serve only the purpose of creating a region of interest for detection or tracking. They do not help to mimic real anatomy and therefore these phantoms have a narrow benefit with regards to simulation; real tissue is complex and the interpretation of the ultrasound perspective and visible anatomy is one of the fundamental challenges in IOUS. Experimentation, data collection, and training can also be performed during surgery. However, this is the least accessible of the mentioned methods due to ethical and resource constraints.

The requirement of accurate simulation resources for educational purposes is self-explanatory. However, the benefit for research and technological development is less understood. One particularly promising example in which significant efforts and progress have been made is in the field of robotic ultrasound [16]. As with most robotic applications for surgery, ultrasound guidance is still in an early preclinical, experimental research-focused phase. As such, this has allowed for temporary circumvention of the simulation of more challenging surgical procedures which may utilise ultrasound, and the expected intricacies of the anatomical features that would be present. In a large number of these works, the application is non-invasive, on-the-skin procedures [17] [18], or are works that can be evaluated on simple synthetic medical phantoms, to explore technical novelty in the design and control of the robotic system [19] [20] [21] [22]. However, some research has been performed using ex vivo tissue. In [23], human cadavers were used for on the skin servoing over the spine. [24] used porcine tissue as the medium for a needle tracking task. Kidney and heart ex vivo were used in [25] to provide more challenging and realistic evaluation extensions of their proposed learning-from-demonstration method. Germane to this article, [26] uses an unmodified chicken breast for the evaluation of focused US ablation. The study pertained to the feasibility of real-time detection of the ablation area

medRxiv preprint doi: https://doi.org/10.1101/2024.09.30.24314649; this version posted October 2, 2024. The copyright holder for this preprint (which was not certified by peer review) is the author/funder, who has granted medRxiv a license to display the preprint in perpetuity. It is made available under a CC-BY-NC-ND 4.0 International license .

and, as such, the task did not require the ablated tissue to be pathological. However, the clinical motivation for this research and many others within the field of robotic ultrasound is therapeutic surgery.

Returning to the primary concern of this article, which is IOUS in brain surgery, from the above literature review it can be stated that from an educational and technical perspective, there is a lack of simulation resources of accurate brain phantoms containing pathological tissue. Where, commercially available phantoms lack anatomical correctness, and there are no proposed methods for modifying brain ex vivo.

This article highlights the importance of creating anatomical accuracy in phantoms. A method is proposed to create a phantom to mimic tumours in inexpensive brain ex vivo using agar. A data set is created and made publicly available upon request that contains bounding-box annotations of multiple ex vivo ovine brains containing tumour-mimicking agar. The data set contains 576 annotated images and 388 images without tumours, where the frames were extracted from US videos at 1Hz. The images are stored as MAT-files with the annotations in CSV files with the structure [top left corner, width, height].

3. Materials and Methods

A summary of the cost and difficulty of creating the phantom is provided in Tab. 1. As a benchmark for commercially available phantoms, the 'Tumour box' and 5 'Glioma Cartridge' from UpSurgeOn [27], were purchased at the cost of 654.92 € and 855.00 € with a shipping fee of 50.00 €. This phantom is designed primarily for resection practice, with ultrasound property being only a secondary feature. However, this was the reason for the preference of this phantom, as with most other medical training phantoms, the phantom will be interacted with in such a way that there will be destruction of the material. For example, phantoms are commonly used for vascular access, epidurals, joint injections, or aspiration. Therefore, having multiple cartridges is a significant benefit of this phantom, unlike alternatives such as the Adult Brain phantoms by True Phantom Solutions. Although the latter may have better imaging feedback, it costs more ($1,738 Basic, $3,090 Standard and $4,250 Complex model), it is non-replaceable and can only be used in such a way as to preserve the integrity of the material. No cutting, modification, or rough handling.

medRxiv preprint doi: https://doi.org/10.1101/2024.09.30.24314649; this version posted October 2, 2024. The copyright holder for this preprint (which was not certified by peer review) is the author/funder, who has granted medRxiv a license to display the preprint in perpetuity. It is made available under a CC-BY-NC-ND 4.0 International license .

Multiple ovine and bovine ex vivo samples (Figure. 1) were purchased at the cost of £5 each. All data were captured using an Ultrasonix Sonix CEP ultrasound system and a L14-5 linear probe. This was chosen as it is a previous generation machine, therefore producing lower quality images than can be expected with the modern state-of-the-art systems and mimicking a real-life scenario where clinicians rarely have access to the latest technological developments. Among the different materials used in the literature, to simulate brain tumours, agar was chosen due to its low cost and matching mechanical properties [14]. Agar is also easy to manipulate, since there is no need for freeze-thawing cycles (as needed with PVA [11]), and it can be injected during its liquid stage and allowed to solidify after injection in minimal time.

Tumour simulation was achieved using 2ml of 10-20% concentrate agar, heated using a Fisherbrand™ Hotplate Stirrer set to 150° and 1500 rpm, injected into the depth of the subcortical white matter/centrum semiovale - the agar was cooled before injection. Where both these areas are approximately equivalent to the human counterpart in terms of anatomical features such as texture, locations, colour, and physiological role. Depending on the concentration, temperature, volume, and area injected, from our observations, the time it took to harden could vary anywhere from a few minutes up to half an hour. To simulate the necrotic core of a tumour, water was injected into the hardened agar. Ultrasound feedback was used to guide the needle into the agar solution.

Two experienced IOUS operators individually assessed the phantoms in relation to the acquired images. Evaluation categories were defined for qualitative assessment, using the five-point Liekert scale. Five categories were chosen, which were considered comprehensive for the evaluation of medical phantoms and their similarity to real brain tissue. The categories are Reusability, Echotexture, Cerebral structure, Tactile feedback, and Tumour mimic semblance.

4. Results

The results of the qualitative ratings are shown in Table. 2. Overall, the quality of the phantoms made using real brain tissue produced far superior imaging, anatomical accuracy, and tumour accuracy, in comparison to the phantom. However, the animal phantom was not reusable and had to be disposed of on the day of use to prevent decay and necrosis.

medRxiv preprint doi: https://doi.org/10.1101/2024.09.30.24314649; this version posted October 2, 2024. The copyright holder for this preprint (which was not certified by peer review) is the author/funder, who has granted medRxiv a license to display the preprint in perpetuity. It is made available under a CC-BY-NC-ND 4.0 International license .

4.1. Phantom analysis

Figure. 2 shows an image of the phantom captured by our device and an official UpSurgeOn image. The most prominent and noticeable features in both cases are the linear, horizontal hyperechogenic lines. Although useful in defining the echogenic nature of the tissue analysed, their clinical correlation is debatable. The tumour itself appears as a circular hyperechoic ring with a hypoechoid core, causing significant acoustic shadowing. In the clinical setting, such shadowing is generally indicative of a tumour with a calcified component. In general, although there is echogenic diversity, these features are incoherent and do not resemble real anatomy.

4.2. Ex-Vivo and agar

The unmodified bovine brain sample is shown on the left side of Figure. 3 and the ovine sample in section A and B of Figure. 4. The good contrast within the tissue is the first noticeable property. The samples provided a good visualisation of the cortical sulci and gyri, with evident arachnoidal hyperechogenity and differentiation of grey-white matter. There were no shadows, artefacts, or elements of degradation. The images obtained through these specimens closely resembled a mammalian brain anatomy and therefore were considered more reliable to reproduce a clinical neurosurgical scenario.

In the same figures, the same tissues are also shown, but with the addition of injected 10-20% concentrate agar. In the context of the bovine brain, the addition of agar is shown in the right image of Figure. 3. With the ovine tissue, sections C and D in Figure. 4 show the agar solution. The agar solution was injected into the depth of the inferior frontal sulcus. As expected, the tumour appeared embedded in the subcortical white matter creating an echogenic sphere, with a narrow tract following the entry point.

Unlike phantoms, agar injection into a real brain not only showed a well-defined and clearly identifiable anomaly but also provided a mass and an infiltrative effect to the surrounding areas. This interaction with brain tissue appears to be more reliable and useful for educational purposes and research applications.

For reference of a normal IOUS view of brain tumour tissue, Figure. 5 shows images of glioblastomas - highlighted with yellow dotted lines - taken intraoperatively and right before resection, at Charing Cross Hospital, using a state-of-the-art system Canon i900 ultrasound machine [28]. Noticeable are the layered tissue, which produces structured echogenic diversity. Similar to what is seen in the ovine and bovine tissue and dissimilar to what is seen in

medRxiv preprint doi: https://doi.org/10.1101/2024.09.30.24314649; this version posted October 2, 2024. The copyright holder for this preprint (which was not certified by peer review) is the author/funder, who has granted medRxiv a license to display the preprint in perpetuity. It is made available under a CC-BY-NC-ND 4.0 International license .

the phantom. The tumours share similar resemblance to that produced using agar, creating a region of concentrated, higher echogenicity with diffusion along the margins.

A cross section of the agar in one of the ovine ex vivo samples is shown in Figure. 7. The agar was mixed before injection with acriflavine to dye the tissue. As shown in the figure, it is possible to embed the agar solution in an area of normal tissue.

4.3. Necrosis Simulaiton

Figure. 6 shows an example of the outcome of injecting water directly into the agar solution. In this example, the water successfully displaces the agar, creating a nested spherical area of lower echogenicity within the higher echogenic agar solution. This can be seen as an area of slightly higher echogenicity than the background levels. The figure also shows an image of a human brain tumour with a necrotic core to highlight the impact on the echogenic profile.

5. Discussion

The creation of resources for surgical simulation, particularly the simulation of anatomy, is ever in demand and requires ongoing commitments to overcome a series of technical, logistical, and regulatory challenges. Regarding the specific problems related to the application of IOUS during brain tumour surgery, the current article addresses one of the critical issues related to this imaging technology, the lack of simulation resources to support preclinical / cadaveric training and technical innovation.

Through our experiments with agar injection into animal ex vivo brain tissue, we show that it is possible to mimic tumours in inexpensive real tissue, replicating an anatomy that is as similar to human as possible and providing the expected ultrasound feedback. The simulation of necrosis, by injecting water into the hardened agar, created an acceptable resemblance to a high-grade real-life tumour scenario. This solution removed a few of the issues related to the artificial phantom, namely the lack of resemblance to the surrounding gyri and sulci, the acoustic shadow underlying the tumour model (absent in most cases) and overall, the signal obtained in terms of both resolution and reliability.

The creation of medical simulation resources such as this is important, as it provides a method of improving practical skills and reducing the de-

medRxiv preprint doi: https://doi.org/10.1101/2024.09.30.24314649; this version posted October 2, 2024. The copyright holder for this preprint (which was not certified by peer review) is the author/funder, who has granted medRxiv a license to display the preprint in perpetuity. It is made available under a CC-BY-NC-ND 4.0 International license .

pendency on learning from experience during real surgeries. Extending from this, it would also facilitate learning new US-guided techniques such as US-guided core biopsies which are presently, due to lack of access, under applied in neurosurgery but readily used in other medical fields. For example, in this case the operators found that the task of using US to guide the agar injections was qualitatively associated with an improvement in US coordination and US localisation of the needle.

In addition, accurate simulation of brain anatomy and pathology encourages technical innovation, for example, training and validation of data-driven algorithms or evaluation of robotic systems. For example, by having an inexpensive method for creating accurate brain phantoms with pathology, data can be collected more easily and used to supplement the more difficult-to-acquire in vivo data. This may aid in deep learning training, which usually requires large volumes of data to prevent overfitting. This level of data collection has been achieved for some applications, such as chest X-rays for COVID-19 and brain magnetic resonance imaging, but these cases tend to involve data that are less logistically demanding to collect and annotate or are critical topics such as COVID. Furthermore, the inexpensiveness and anatomical and textural accuracy of the phantom can provide an object that can be used to conduct robotic experiments.

Our solution is not without limitations. First, prion disease represents a serious biohazard and needs to be addressed properly when manipulating the brains of dead animals. We have circumvented this problem opting for young animal brains (veals and lambs) specifically harvested for human consumption and have already gone through official clearance with the relevant regulatory authorities. If an adult animal brain is preferable for whatever reason, a much stricter protocol would be required. As an additional precaution measure to manage any biosafety risk, all biological material has been discarded according to standard safety protocols. Second challenge, working with ex vivo biological tissue should ideally be done in biosafe laboratories, unlike commercial phantoms, which could be used in any setting. This set-up is per se expensive and/or not always accessible for all centres. Finally, while the tissue does show much closer resemblance with the in vivo images, the possibility of degradation-related artefacts must be considered. For these experiments, tissue samples were kept out of the refrigerator at room temperature for more than an hour, and the harvesting time presumably took place 24 to 48 hours earlier. However, no significant necrosis or tissue degradation was observed within this time period, both on macroscopic inspection

medRxiv preprint doi: https://doi.org/10.1101/2024.09.30.24314649; this version posted October 2, 2024. The copyright holder for this preprint (which was not certified by peer review) is the author/funder, who has granted medRxiv a license to display the preprint in perpetuity. It is made available under a CC-BY-NC-ND 4.0 International license .

and on imaging. Some degree of manipulation-related damage was noticed especially at the level of the basal structures, but this was negligible for the purpose of our acquisitions. Some of the tissue that was left out was later frozen and used on another day, and it was observed that the fluctuation of temperature and the freezing process minimally impacted the usability of the tissue. In general, we found that this setting and time frame is acceptable, reliable, and replicable.

6. Conclusions

Methods for mimicking tumours within ultrasound images are valuable both for clinical training and research. This is especially the case with brain tumours, which are complex, highly variable, and diffuse. IOUS is a difficult tool to become proficient with, outside of real surgeries. The lack of affordable and accurate commercially available phantoms creates the need for home-made methods to create inexpensive homemade phantoms. Our proposed method solves this by mimicking tumours within real tissue, by combining easy and cheap butchers meat with agar powder. Furthermore, this will encourage technical innovation, as the lack of simulation resources has been a significant bottleneck in technical innovation. A data set of 576 annotated images and 388 images without tumours was created from the experiments and is publicly available upon request. Sample images from the data set are shown in Figure. 8.

Future work is encouraged to improve the realism of the tumour mimicry. This could include testing different concentrations of agar solution, testing different locations, and using more than one compound to simulate tumour characteristics, creating more complex layering and diffusion effects. Further research is desirable to simulate a more infiltrative type of lesion, with reduced margin sharpness.

Acknowledgements

This project was supported by the UK Research and Innovation (UKRI) Centre for Doctoral Training in AI for Healthcare (EP/S023283/1), the Royal Society (URF\R\201014), the NIHR Imperial Biomedical Research Centre.

medRxiv preprint doi: https://doi.org/10.1101/2024.09.30.24314649; this version posted October 2, 2024. The copyright holder for this preprint (which was not certified by peer review) is the author/funder, who has granted medRxiv a license to display the preprint in perpetuity. It is made available under a CC-BY-NC-ND 4.0 International license .

References

[1] R. U. Gandhe, C. P. Bhave, Intraoperative magnetic resonance imaging for neurosurgery – an anaesthesiologist's challenge, Indian Journal of Anaesthesia 62 (2018) 411 – 417.

[2] P. L. Kubben, F. Scholtes, O. Schijns, M. P. ter Laak-Poort, O. P. Teernstra, A. G. H. Kessels, J. J. van Overbeeke, D. Martin, H. van Santbrink, Intraoperative magnetic resonance imaging versus standard neuronavigation for the neurosurgical treatment of glioblastoma: A randomized controlled trial, Surgical Neurology International 5 (2014).

[3] L. Dixon, A. Lim, M. Grech-Sollars, D. Nandi, S. J. Camp, Intraoperative ultrasound in brain tumor surgery: A review and implementation guide, Neurosurgical Review 45 (2022) 2503 – 2515.

[4] A. Steno, J. Buvala, V. P. Babkova, A. Kiss, D. Toma, A. Lysak, Current limitations of intraoperative ultrasound in brain tumor surgery, Frontiers in Oncology 11 (2021).

[5] J. Wilson, L. Ng, V. A. Browne, R. E. Lewiss, An easy-to-make, low-cost ultrasound phantom for simulation training in abscess identification and aspiration, Journal of Ultrasound in Medicine 36 (2017).

[6] L. Nolting, P. S. Hunt, T. Cook, B. Douglas, An inexpensive and easy ultrasound phantom, Journal of Ultrasound in Medicine 35 (2016).

[7] R. Amini, J. Z. Kartchner, L. A. Stolz, D. E. Biffar, A. J. Hamilton, S. Adhikari, A novel and inexpensive ballistic gel phantom for ultrasound training., World journal of emergency medicine 6 3 (2015) 225–8.

[8] D. Morrow, J. Cupp, J. S. Broder, Versatile, reusable, and inexpensive ultrasound phantom procedural trainers, Journal of Ultrasound in Medicine 35 (2016).

[9] J. M. Martínez, B. J. Jarosz, 3d perfused brain phantom for interstitial ultrasound thermal therapy and imaging: design, construction and characterization, Physics in Medicine & Biology 60 (2015) 1879 – 1900.

[10] M. Aoyagi, Sodium alginate ultrasound phantom for medical education, Ultrasonic Imaging 43 (2021) 253 – 261.

medRxiv preprint doi: https://doi.org/10.1101/2024.09.30.24314649; this version posted October 2, 2024. The copyright holder for this preprint (which was not certified by peer review) is the author/funder, who has granted medRxiv a license to display the preprint in perpetuity. It is made available under a CC-BY-NC-ND 4.0 International license .

[11] E. C. Mackle, J. Shapey, E. Maneas, S. R. Saeed, R. Bradford, S. Ourselin, T. K. M. Vercauteren, A. E. Desjardins, Patient-specific polyvinyl alcohol phantom fabrication with ultrasound and x-ray contrast for brain tumor surgery planning, Journal of visualized experiments : JoVE (2020).

[12] A. Antoniou, N. Evripidou, L. Georgiou, A. Chrysanthou, C. Ioannides, C. Damianou, Tumor phantom model for mri-guided focused ultrasound ablation studies., Medical physics (2023).

[13] G. Menikou, T. Dadakova, M. Pavlina, M. Bock, C. Damianou, Mri compatible head phantom for ultrasound surgery., Ultrasonics 57 (2015) 144–52.

[14] D. C. Stewart, A. Rubiano, K. A. Dyson, C. S. Simmons, Mechanical characterization of human brain tumors from patients and comparison to potential surgical phantoms, PLoS ONE 12 (2017).

[15] V. K. Singh, S. A. Shaikh, P. Shetty, A. V. Moiyadi, Customized low cost model for hands-on training in intraoperative ultrasound for neurosurgeons: Our experience and review of literature., World neurosurgery (2020).

[16] Z. Jiang, S. E. Salcudeanb, N. Navab, Robotic ultrasound imaging: State-of-the-art and future perspectives, Medical image analysis 89 (2023) 102878.

[17] M. Victorova, M. K.-S. Lee, D. Navarro-Alarcon, Y. P. Zheng, Follow the curve: Robotic ultrasound navigation with learning based localization of spinous processes for scoliosis assessment, IEEE Access PP (2021) 1–1.

[18] Z. Jiang, Y. Zhou, Y. Bi, M. Zhou, T. Wendler, N. Navab, Deformation-aware robotic 3d ultrasound, IEEE Robotics and Automation Letters 6 (2021) 7675–7682.

[19] M. Dyck, A. Weld, J. Klodmann, A. Kirst, L. Dixon, G. Anichini, S. Camp, A. Albu-Schaffer, S. Giannarou, Toward safe and collaborative robotic ultrasound tissue scanning in neurosurgery, IEEE Transactions on Medical Robotics and Bionics 6 (2023) 64–67.

medRxiv preprint doi: https://doi.org/10.1101/2024.09.30.24314649; this version posted October 2, 2024. The copyright holder for this preprint (which was not certified by peer review) is the author/funder, who has granted medRxiv a license to display the preprint in perpetuity. It is made available under a CC-BY-NC-ND 4.0 International license .

[20] M. Akbari, J. Carriere, R. S. Sloboda, T. Meyer, N. Usmani, S. Husain, M. Tavakoli, Robot-assisted breast ultrasound scanning using geometrical analysis of the seroma and image segmentation, 2021 IEEE/RSJ International Conference on Intelligent Robots and Systems (IROS) (2021) 3784–3791.

[21] F. Suligoj, C. M. Heunis, J. Sikorski, S. Misra, Robust–an autonomous robotic ultrasound system for medical imaging, IEEE Access 9 (2021) 67456–67465.

[22] G. Faoro, S. Maglio, S. Pane, V. Iacovacci, A. Menciassi, An artificial intelligence-aided robotic platform for ultrasound-guided transcarotid revascularization, IEEE Robotics and Automation Letters 8 (2023) 2349–2356.
URL `https://api.semanticscholar.org/CorpusID:257319469`

[23] R. Li, A. Davoodi, Y. Cai, K. Niu, G. Borghesan, N. A. Cavalcanti, A. Massalimova, F. Carrillo, C. J. Laux, M. Farshad, P. Fürnstahl, E. B. V. Poorten, Robot-assisted ultrasound reconstruction for spine surgery: from bench-top to pre-clinical study, International Journal of Computer Assisted Radiology and Surgery 18 (2023) 1613–1623.

[24] Z. Jiang, X. Li, X. Chu, A. Karlas, Y. Bi, Y. Cheng, K. W. S. Au, N. Navab, Needle segmentation using gan: Restoring thin instrument visibility in robotic ultrasound, ArXiv abs/2407.18357 (2024).

[25] Z. Jiang, Y. Bi, M. Zhou, Y. Hu, M. Burke, N. Navab, Intelligent robotic sonographer: Mutual information-based disentangled reward learning from few demonstrations, The International Journal of Robotics Research 43 (2023) 981 – 1002.

[26] M. Sadeghi-Goughari, H. Rajabzadeh, J. woo Han, H.-J. Kwon, Artificial intelligence-assisted ultrasound-guided focused ultrasound therapy: a feasibility study, International Journal of Hyperthermia 40 (2023).

[27] UpSurgeOn, braintumorbox, `https://store.upsurgeon.com/products/braintumorbox/`, accessed: 29/05/2024.

[28] A. Weld, L. Dixon, G. Anichini, N. Patel, A. Nimer, M. Dyck, K. ONeill, A. Lim, S. Giannarou, S. Camp, Challenges with segmenting intraoperative ultrasound for brain tumours, Acta Neurochirurgica 166 (2023).

medRxiv preprint doi: https://doi.org/10.1101/2024.09.30.24314649; this version posted October 2, 2024. The copyright holder for this preprint (which was not certified by peer review) is the author/funder, who has granted medRxiv a license to display the preprint in perpetuity. It is made available under a CC-BY-NC-ND 4.0 International license .

7. Tables

Table 1: Cost, acquisition and setup

	UpSurgeon	Animal Brain
Cost	High	Low
Availability	Moderate	Easy
Time to construct	5 min	10 min
Special storage	No	Yes
Special handling	No	Yes
Complexity of set up	Simple	Intermediate

Table 2: Qualitative assessment using a five-point Liekert scale (1 = poor to 5 = excellent)

	UpSurgeOn	Animal Brain
Reusability	4	2
Echotexture	3	5
Cerebral structure	1	5
Tactile feedback	2	5
Tumour mimic semblance	2	4

medRxiv preprint doi: https://doi.org/10.1101/2024.09.30.24314649; this version posted October 2, 2024. The copyright holder for this preprint (which was not certified by peer review) is the author/funder, who has granted medRxiv a license to display the preprint in perpetuity. It is made available under a CC-BY-NC-ND 4.0 International license .

8. Figures

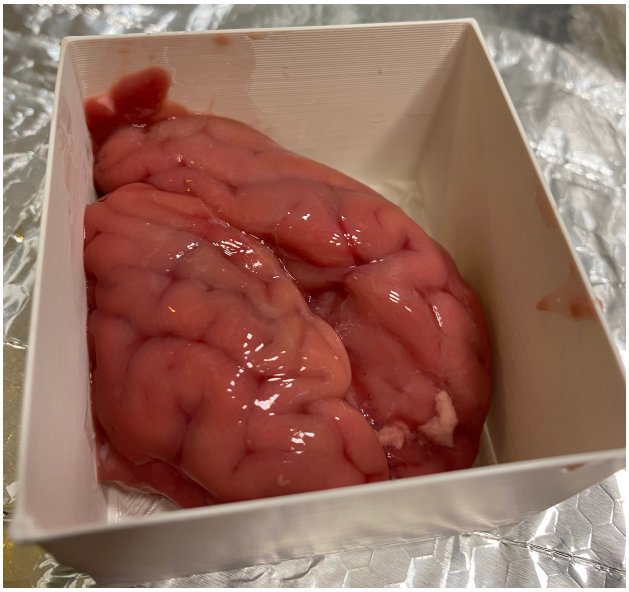

Figure 1: An ovine sample used to collect the data, before the agar solution was injected. The container has the dimensions 6.5cm×7.0cm.

medRxiv preprint doi: https://doi.org/10.1101/2024.09.30.24314649; this version posted October 2, 2024. The copyright holder for this preprint (which was not certified by peer review) is the author/funder, who has granted medRxiv a license to display the preprint in perpetuity. It is made available under a CC-BY-NC-ND 4.0 International license .

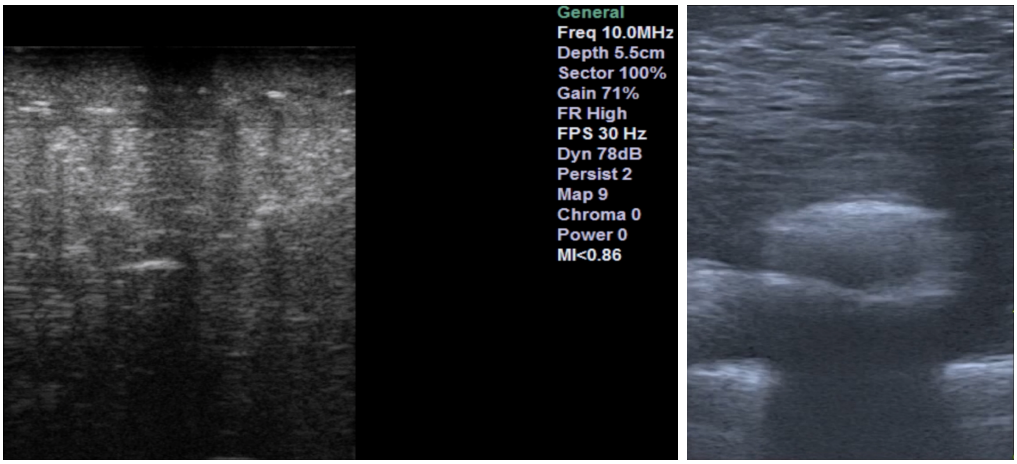

Figure 2: UpSurgeOn brain box phantom. The left figure is from our machine, the right is an image provided by UpSurgeOn.

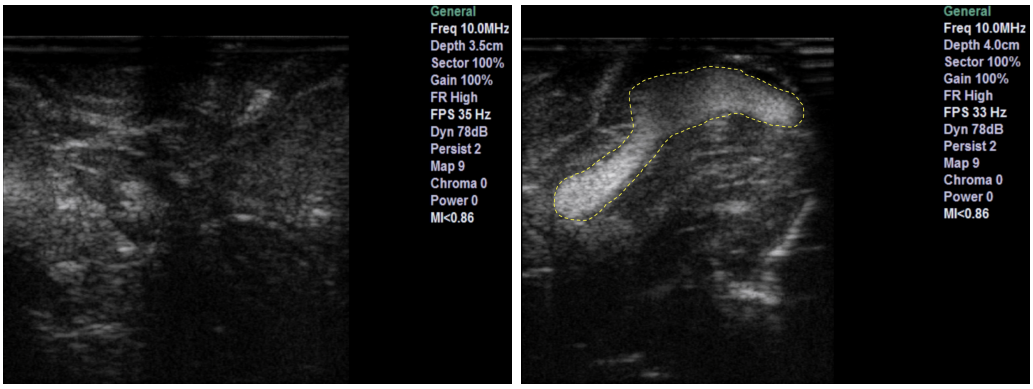

Figure 3: Bovine sample. Left shows ultrasound feedback of phantom without tumour addition. Right shows ultrasound feedback with agar injected

medRxiv preprint doi: https://doi.org/10.1101/2024.09.30.24314649; this version posted October 2, 2024. The copyright holder for this preprint (which was not certified by peer review) is the author/funder, who has granted medRxiv a license to display the preprint in perpetuity. It is made available under a CC-BY-NC-ND 4.0 International license .

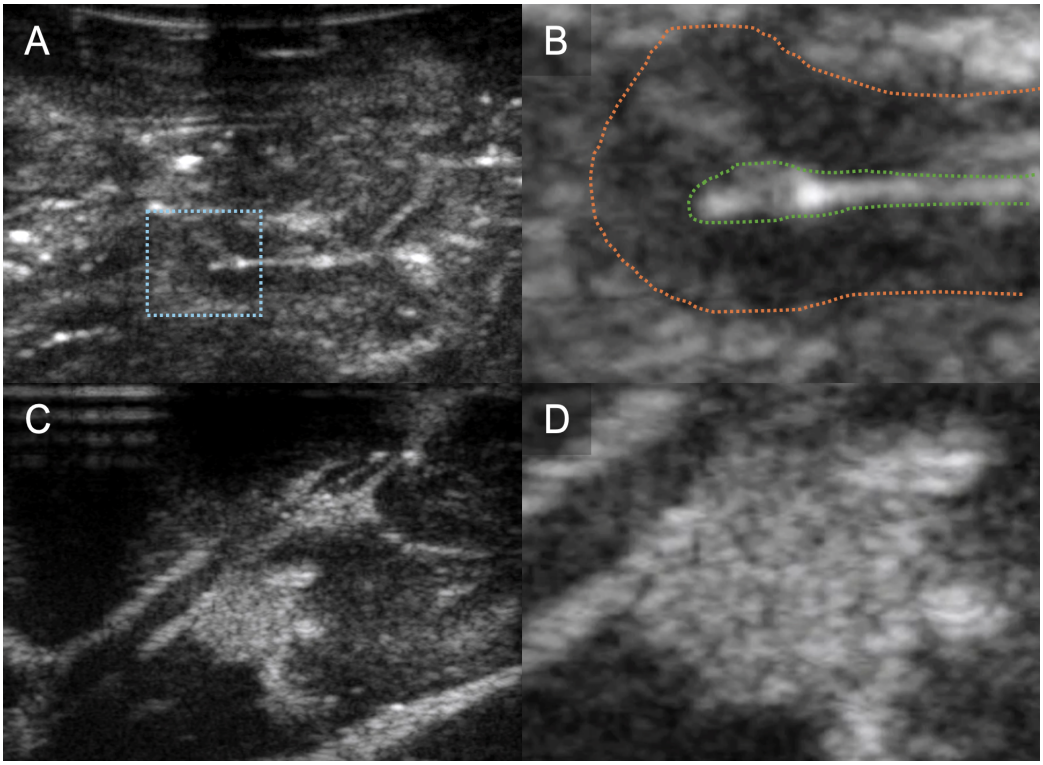

Figure 4: Ovine sample. B-mode image of sheep brain (A) with magnified image of gyrus (B) demonstrating discernible normal cerebral architecture with sulci and pia (outlined by green dotted line), cortex (outlined by orange dotted line) and surrounding white matter. B-mode image of the same sheep brain after localised infiltration of agar to mimic a hypercellular, echogenic tumour (C) with magnified image of tumour mimic demonstrating clear margins (D).

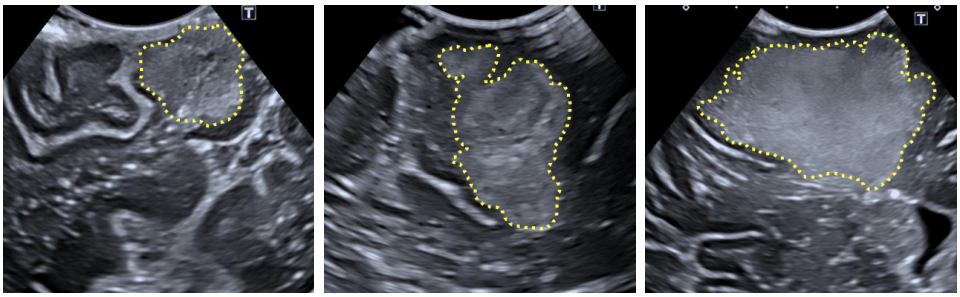

Figure 5: Human intraoperative ultrasound images of Glioblastoma. The tumours are highlighted using the yellow dotted lines. The left and right figures show a maximum depth of 5cm, while the middle figure shows a maximum depth of 4.5cm.

medRxiv preprint doi: https://doi.org/10.1101/2024.09.30.24314649; this version posted October 2, 2024. The copyright holder for this preprint (which was not certified by peer review) is the author/funder, who has granted medRxiv a license to display the preprint in perpetuity. It is made available under a CC-BY-NC-ND 4.0 International license .

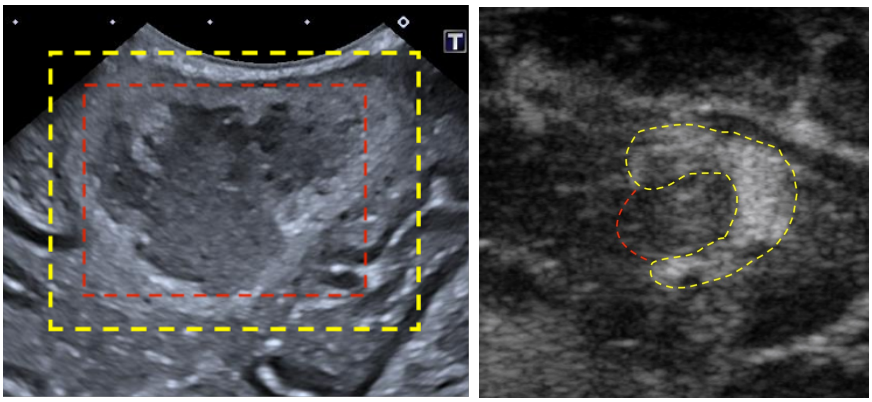

Figure 6: The right example shows a real case of a brain tumour, highlighted in yellow, with a necrotic core, highlighted in red. On the left is water added to the agar to simulate a necrotic core. Yellow line outlines the agar, red line outlines the water.

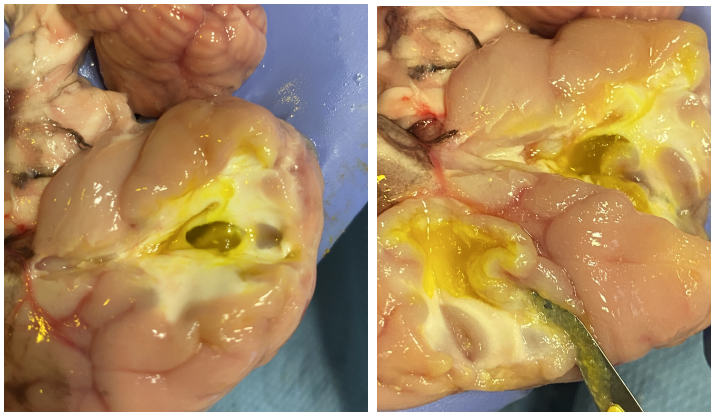

Figure 7: Cross section of one of the ovine brains. In this sample, two sites were injected with agar (dyed yellow).

medRxiv preprint doi: https://doi.org/10.1101/2024.09.30.24314649; this version posted October 2, 2024. The copyright holder for this preprint
(which was not certified by peer review) is the author/funder, who has granted medRxiv a license to display the preprint in perpetuity.
It is made available under a CC-BY-NC-ND 4.0 International license .

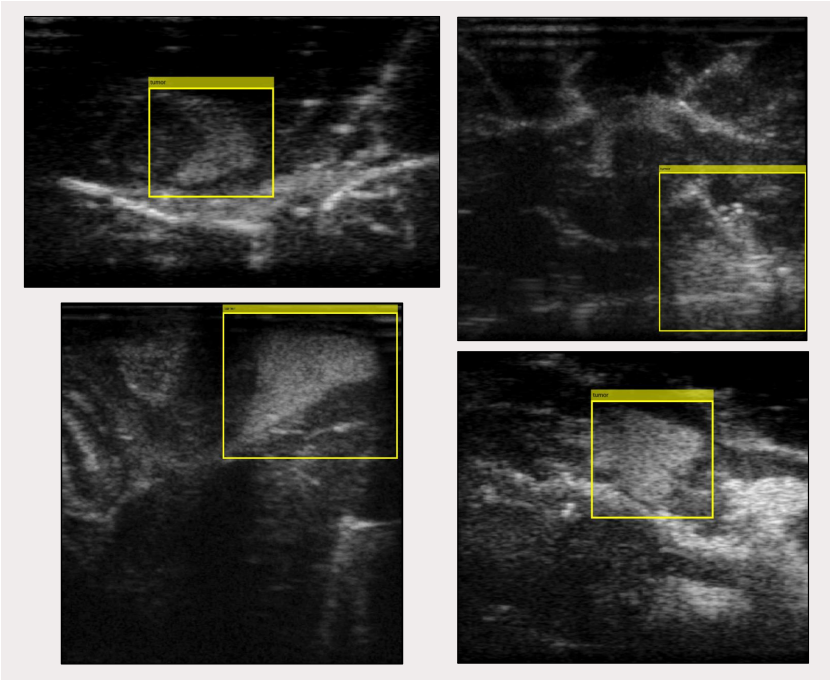

Figure 8: Samples from the data set with super imposed bounding box annotation.