medRxiv preprint doi: https://doi.org/10.1101/2024.09.18.24313868; this version posted September 19, 2024. The copyright holder for this preprint **(which was not certified by peer review)** is the author/funder, who has granted medRxiv a license to display the preprint in perpetuity.

It is made available under a CC-BY-NC 4.0 International license .

Obstetric anal sphincter injuries detection by digital rectal examination and impedance spectroscopy: post-hoc analysis of the results from a prospective, comparative, multicentre clinical study

Stefano Salvatore[1], Katarzyna Borycka[2,3], Alessandro Ruffolo[1,4], Marcel Młyńczak[2,5], Maciej Rosoł[2,5], Kacper Korzeniewski[2,5], Piotr Iwanowski[2], Antonino Spinelli[6,7], Renaud de Tayrac[8], Carlo Ratto[9], Stavros Athanasiou[10], Diaa Essameldin Ali Rizk[11], Andrea Stuart[12], Jan Baekelandt[13], Hynek Heřman[14,15], Petr Janku[16,17], Peter Rosenblat[18], Rita Franco[19], Mariusz Grzesiak[20], Adam Dziki[21], Ruwan Fernando[22]

1 Obstetrics and Gynecology Unit, Vita-Salute San Raffaele University Milan, Italy IRCCS San Raffaele Scientific Institute, Milan, Italy
2 OASIS Diagnostics, R&D of Medical Technology, Warsaw, Poland
3 Centre of Postgraduate Medical Education, Warsaw, Poland
4 Department of Gynecology, Jeanne de Flandre University Hospital, Lille, France
5 Warsaw University of Technology, Faculty of Mechatronics, Institute of Metrology and Biomedical Engineering, Warsaw, Poland
6 Department of Biomedical Sciences, Humanitas University, Via Rita Levi Montalcini 4, 20072 Pieve Emanuele, Milan, Italy
7 IRCCS Humanitas Research Hospital, via Manzoni 56, 20089 Rozzano, Milan, Italy
8 Department of Obstetrics and Gynaecology, Nimes University Hospital, Montpellier University, Nîmes, France
9 Proctology and Pelvic Floor Surgery Unit, Isola Tiberina Hospital, Gemelli Isola, Catholic University, Rome, Italy
10 Urogynecology Unit, Alexandra Hospital, Kapodistrian University of Athens, Greece
11 Clinical Research Centre, Arabian Gulf University, Bahrain
12 Department of Obstetrics and Gynecology, Helsingborg Central Hospital, Helsingborg, Sweden
13 Department of Obstetrics and Gynaecology, Imelda Hospital, Bonheiden, Belgium
14 3rd Medical Faculty, Charles University, Prague, Czech Republic
15 Institute for the Care of Mother and Child, Prague, Czech Republic
16 Department of Obstetrics and Gynaecology, University Hospital Brno and Medical Faculty, Masaryk University, Brno, Czech Republic
17 Department of Health Sciences, Medical Faculty, Masaryk University, Brno, Czech Republic
18 Division of Urogynecology and Reconstructive Pelvic Surgery, Cambridge Department of Obstetrics and Gynecology, Harvard Medical School, Boston, Massachusetts, USA
19 Division of Gynecology and Obstetrics, Isola Tiberina Hospital, Gemelli Isola, Catholic University, Rome, Italy
20 Institute of Polish Mother's Health Centre, Łódź, Poland
21 Department of General and Colorectal Surgery, Medical University of Lodz, Poland
22 Department of Urogynaecology, St Mary's Hospital, Imperial College Healthcare NHS Trust, London, UK

Short Title

NOTE: This preprint reports new research that has not been certified by peer review and should not be used to guide clinical practice.

medRxiv preprint doi: https://doi.org/10.1101/2024.09.18.24313868; this version posted September 19, 2024. The copyright holder for this preprint **(which was not certified by peer review)** is the author/funder, who has granted medRxiv a license to display the preprint in perpetuity.

It is made available under a CC-BY-NC 4.0 International license .

Finger versus impedance spectroscopy in OASI detection

medRxiv preprint doi: https://doi.org/10.1101/2024.09.18.24313868; this version posted September 19, 2024. The copyright holder for this preprint **(which was not certified by peer review)** is the author/funder, who has granted medRxiv a license to display the preprint in perpetuity.

It is made available under a CC-BY-NC 4.0 International license .

Abstract

Objective: To evaluate the clinical performance of digital rectal examination (DRE) and machine learning-assisted impedance spectroscopy (ONIRY) for detecting obstetric anal sphincter injuries (OASI) compared to three-dimensional endoanal ultrasound (EAUS).

Design: A post-hoc analysis of data from a prospective, comparative, multicentre, international study (NCT04903977).

Setting: Poland, Czech Republic, Slovakia, and Spain.

Population: 152 vaginally delivered women to 8 weeks post-partum.

Methods: Participants were divided into two groups based on EAUS results: Group I (no OASI, including 1st and 2nd degree perineal tears per OASIS classification) and Group II (OASI, including 3rd and 4th-degree tears per OASIS classification). DRE and impedance measurements using the ONIRY system were performed. The machine learning (ML) model for ONIRY was trained and validated. The diagnostic outcomes of ONIRY and DRE were compared to EAUS.

Main Outcome Measures: Accuracy, sensitivity, and specificity.

Results: DRE's performance versus EAUS was 67.8% for accuracy, 44.3% for sensitivity, and 83.5% for specificity. After completion of ML model training, impedance spectroscopy's accuracy, sensitivity, and specificity were 87.0%, 90.6%, and 84.6%, respectively, compared with EAUS.

Conclusion: DRE is insufficient for OASI detection. The ML-assisted impedance spectroscopy demonstrated higher accuracy and could facilitate rapid OASI detection post-delivery.

Funding: The study was financed by the European Union's Fast Track program through the Polish National Centre for Research and Development (POIR.01.01.01-00-0726/18)

Keywords: Obstetric anal sphincter injury (OASI), anal sphincter, perineal tear, faecal

medRxiv preprint doi: https://doi.org/10.1101/2024.09.18.24313868; this version posted September 19, 2024. The copyright holder for this preprint (which was not certified by peer review) is the author/funder, who has granted medRxiv a license to display the preprint in perpetuity.

It is made available under a CC-BY-NC 4.0 International license .

incontinence, rapid diagnostics, impedance spectroscopy, machine learning, endoanal ultrasound

Introduction

Obstetric anal sphincter injuries (OASIs) present a significant diagnostic challenge within maternal care [1-10]. The dynamic nature of childbirth, combined with the need to simultaneously care for both mother and infant and the variable experience of obstetric staff at delivery rooms, complicates the accurate diagnosis of OASIs. Reported incidences of OASIs vary, with typical clinical settings reporting rates between 0.1% and 6% [3-5], while a recent meta-analysis involving over 4,000 women in more than 30 studies suggests a higher prevalence of approximately 26% [11]. Current clinical guidelines [12-24] recommend that primary repair of these injuries should ideally be performed within 8-12 hours post-delivery to maximize therapeutic outcomes.

Although endoanal ultrasonography (EAUS) is considered the gold standard for detecting these injuries, due to its high accuracy in skilled hands, it is not widely available in all healthcare settings. In contrast, digital rectal examination (DRE) is widely used due to its immediate availability in maternity wards. However, the efficacy of DRE is compromised by its subjective nature, heavily reliant on the examiner's expertise and experience [2 8, 9, 10]. Guidelines emphasise the proper conduct of the DRE [12, 14, 16, 19, 24], instructing exactly how to perform it and strongly stressing the value of training and expertise in OASIs to mitigate variability in diagnostic accuracy [14, 20, 22, 19, 24]. The literature reports significant rates of underdiagnosis of internal anal sphincter injuries when relying solely on DRE [25] and challenges in identifying residual injuries post-repair [26]. Given that up to 80% of OASIs remain undetected [27], this underdiagnosis highlights the need for more effective diagnostic tools.

medRxiv preprint doi: https://doi.org/10.1101/2024.09.18.24313868; this version posted September 19, 2024. The copyright holder for this preprint (which was not certified by peer review) is the author/funder, who has granted medRxiv a license to display the preprint in perpetuity.

It is made available under a CC-BY-NC 4.0 International license .

To address this gap, the ONIRY system, a machine learning-assisted (ML) impedance spectroscopy tool, has been developed. This system offers a rapid and minimally invasive complement to palpation diagnosis that could potentially enhance the detection of OASIs directly within labour wards. The performance and safety of the ONIRY device have been investigated in several early studies [28-31], as well as a prospective, multicentre pivotal study using EAUS as a reference. The paper presents a post-hoc analysis of this pivotal study comparing the clinical performance of the traditional DRE and the ONIRY method in detecting OASIs, using EAUS as the reference standard. Our analysis aims to evaluate whether ONIRY can offer a significant improvement over DRE in routine obstetric practice.

Materials and Methods

Study design and population

This work analyses data from a prospective, comparative, multicentre, international study registered on ClinicalTrials.gov under NCT04903977. The study was designed to validate the clinical performance and safety of the ONIRY device, an impedance spectroscopy tool, for detecting OASIs when compared with DRE, considering EAUS as the reference diagnostic method. This study followed the clinical phase of the trial with modelling and analysis using ML techniques.

In the clinical phase, 152 women within eight weeks postpartum were enrolled in five European centres from May 2021 to December 2022. Eligible participants included both primiparous and multiparous women aged 18 to 49 who had undergone vaginal delivery (spontaneous or assisted) of a live, singleton foetus at a gestational age of 34 weeks or greater. Exclusion criteria included uncontrolled acute or chronic diseases (excluding stable hemorrhoidal disease), faecal incontinence (FI) symptoms from causes other than OASI, history of perineal or anal surgery, exacerbations of inflammatory bowel disease,

medRxiv preprint doi: https://doi.org/10.1101/2024.09.18.24313868; this version posted September 19, 2024. The copyright holder for this preprint (which was not certified by peer review) is the author/funder, who has granted medRxiv a license to display the preprint in perpetuity.

It is made available under a CC-BY-NC 4.0 International license .

and the presence of cardiac devices or arrhythmias.

In the first study visit, participants underwent an EAUS examination to classify perineal tears based on the OASIS classification [20, 21]. They were then categorized into two groups: Group I included women with either no perineal tear or first- or second-degree tears (no OASI detected), and Group II comprised those with third- or fourth-degree tears (OASI detected). Following this classification, each subject was assessed using DRE and the impedance test with the ONIRY system.

No blinding of the study was deemed feasible. However, it was not considered as required for securing objectivity of the study outcomes as the preliminary interpretation of the impedance measurement displayed by the ONIRY system immediately after the impedance measurement was independent of the test operator and thus not impacted by the EAUS result knowledge at study entry. Furthermore, to minimize any bias related to the EAUS evaluation as the primary reference method, a specific technical control measure was in place that allowed for the performance of the ONIRY examination only after the EAUS result and interpretation were fixed.

Machine learning-assisted impedance spectroscopy was evaluated using the collected impedance data with EAUS as a reference across 10 iterations of 10-fold cross-validation. In each iteration, every patient was compared with the reference only once.

ONIRY System Description

The ONIRY system consists of an impedance spectrometer and an endoanal probe, which performs measurements in the supine gynaecological patient's position in approximately one minute. It analyses the electrical impedance of perineal tissues under current excitation, using an ML model for parameters deep analysis and assessment. The system outputs a "PASS" for no OASI detection or "REFER" for suspected OASI, also indicating the probable position of the injury.

medRxiv preprint doi: https://doi.org/10.1101/2024.09.18.24313868; this version posted September 19, 2024. The copyright holder for this preprint (which was not certified by peer review) is the author/funder, who has granted medRxiv a license to display the preprint in perpetuity.

It is made available under a CC-BY-NC 4.0 International license .

Diagnostic Outcome and Statistical Analysis

The diagnostic accuracy of the ONIRY system and DRE, using the EAUS as a reference method, was evaluated for each participant. Success (True Positive or True Negative) and Failure (False Positive or False Negative) rates were analysed to assess the performance (accuracy, specificity, sensitivity) of each diagnostic approach.

The study adhered to the ISO 14155:2020 guidelines for clinical practice in medical device trials and the Declaration of Helsinki. Informed consent was obtained from each participant prior to enrolment.

Results

The key characteristics of the study population, per study group and in total, are presented in Table 1.

The performance of DRE in identifying OASIs was assessed. The findings indicated an accuracy of 67.8%, reflecting the proportion of total diagnoses (both positive and negative) that were correctly identified. Sensitivity, which measured the ability of DRE to correctly identify those with the OASI presence (true positive rate), was relatively low at 44.3%. On the other hand, specificity, measuring the ability to correctly identify those without the condition (true negative rate), was higher at 83.5%.

The machine learning-assisted impedance spectroscopy was evaluated by comparing the trained ML models' output with EAUS results. The system achieved an accuracy of 87.0% ± 0.5%, which represents a significant enhancement in the overall ability to diagnose OASIs correctly. The sensitivity of the ONIRY system was 90.6% ± 2.0%, indicating its strong capability to identify true positive cases of OASIs effectively. Specificity was robust

medRxiv preprint doi: https://doi.org/10.1101/2024.09.18.24313868; this version posted September 19, 2024. The copyright holder for this preprint (which was not certified by peer review) is the author/funder, who has granted medRxiv a license to display the preprint in perpetuity.

It is made available under a CC-BY-NC 4.0 International license .

at 84.6% ± 1.9%, suggesting that the ONIRY system maintains a high level of accuracy in confirming the absence of injuries, similar to DRE.

Table 2 gathers the ONIRY performance metrics for each iteration of 10-fold cross-validation and the overall statistics.

The accuracy of the two compared methods in detecting OASI in each OASIS classification grades 3a, 3b, 3c, and 4 is shown in Table 3.

The comparison of receiver operating characteristic (ROC) curves for ONIRY and DRE, along with their respective area under the curve (AUC) values, is presented in Figure 1.

Discussion

The findings of this study highlight the diagnostic superiority of the ONIRY method over traditional DRE in detecting OASIs. While DRE demonstrated limited sensitivity (44.3%), failing to detect a significant number of true OASI cases, the ONIRY system achieved significantly higher parameters of sensitivity (90.6%) and accuracy (87.0%).

The DRE was more effective in confirming the absence of injury than detecting its presence. It had the poorest accuracy in assessing the extent of external sphincter injury (24% and 53.8% in OASIS grades 3a and 3b, respectively). This is what is most challenging for clinicians in obstetric practice: differentiating between perineal injury grade 2, which can be addressed by a midwife, and perineal injury grade 3, when the external sphincter is injured and an obstetrician (or colorectal surgeon) with expertise in OASIs is required for repair.

medRxiv preprint doi: https://doi.org/10.1101/2024.09.18.24313868; this version posted September 19, 2024. The copyright holder for this preprint (which was not certified by peer review) is the author/funder, who has granted medRxiv a license to display the preprint in perpetuity.

It is made available under a CC-BY-NC 4.0 International license .

This superiority showed by the ONIRY method can be crucial given the potential consequences of undiagnosed or misclassified and improperly repaired OASI, which can lead to severe conditions, including anal incontinence and a significantly impaired quality of life.

Undiagnosed OASIs significantly worsen outcomes. For instance, women with symptomatic, missed OASIs exhibit worse anal and urinary incontinence symptoms and require additional colorectal consultations compared to OASIs that are timely diagnosed and repaired, as demonstrated by Taithongchai et al. ([32]). Moreover, improperly classified injuries at the time of delivery often result in inadequate repairs, leaving a persistent sphincter defect, which Roper et al. have found to be associated with higher rates of incontinence [33]. This highlights the need for accurate diagnosis and repair, particularly in cases of down-staged OASI.

Recent meta-analyses by Okeahialam et al. [34, 35] have indicated an overall incidence of anal incontinence following OASI of 18.1%, with the incidence varying by the grade of perineal tear: 15.6% for 3a, 18.3% for 3b, 20.6% for 3c, and 28.4% for 4th-degree tears. This data highlights the necessity of accurate diagnosis and appropriate repair, particularly for the most frequent OASI group, the 3a tears, which show the best clinical outcomes when adequately managed.

Furthermore, Andrews et al. [36] demonstrated that primary repair outcomes are good, with only 10% of patients showing defects on ultrasound in early postoperative observation and no significant deterioration in symptoms of faecal urgency, incontinence, or quality of life one year after delivery. These results are supported by the observation of Norderval et al. [37], who reported a low rate of faecal incontinence (7%, with an additive 24% rate of mild gas incontinence symptoms) after an anatomically correct primary repair. In contrast, as demonstrated by Ramage et al. [38], patients with missed OASI had significantly worse

medRxiv preprint doi: https://doi.org/10.1101/2024.09.18.24313868; this version posted September 19, 2024. The copyright holder for this preprint **(which was not certified by peer review)** is the author/funder, who has granted medRxiv a license to display the preprint in perpetuity.

It is made available under a CC-BY-NC 4.0 International license .

outcomes in terms of faecal incontinence, as well as poorer overall physical functioning. In such initially unrecognized OASI cases, delayed sphincteroplasty becomes necessary due to increased faecal incontinence symptoms. Unfortunately, the results of late treatment are no longer as encouraging as the ones of primary repair. After delayed sphincteroplasty, only 40% of patients retain continence [39], and the effect deteriorates with time. In the 10-year follow-up after sphincteroplasty by Zutshi et al., no patients were fully continent [40].

The economic analysis by Tan et al. provides insight into the cost-effectiveness of primary versus delayed sphincter repair. They found that primary repair not only offers a higher quality of life but also is more cost-effective over a 10-year period [41]. This is a further argument for considering the widespread implementation of effective early diagnosis to enable primary sphincter repair to be carried out within the optimal 24-hour therapeutic window. The ONIRY system's independence from the operator skill and its rapid application could improve OASI detection, particularly in labour settings where advanced imaging technologies (like EAUS) are unavailable, which would be especially appreciated in the “critical window,” where the timely and accurate diagnosis is paramount.

The early detection of OASI is critical not only for initiating appropriate repair but also for managing potential postpartum complications, including wound breakdown, infection, and more severe outcomes like necrotizing fasciitis [7]. Early diagnosis could lead to better management of these risks through targeted care and appropriate use of prophylactic antibiotics.

This study is distinctive in its use of a machine learning model within the ONIRY system, marking a significant advancement in the field of obstetric diagnostics. The ability of machine learning to accurately detect anatomical changes in impedance values shows significant promise for enhancing clinical settings, marking a major advancement in the management and treatment of OASI.

medRxiv preprint doi: https://doi.org/10.1101/2024.09.18.24313868; this version posted September 19, 2024. The copyright holder for this preprint **(which was not certified by peer review)** is the author/funder, who has granted medRxiv a license to display the preprint in perpetuity.

It is made available under a CC-BY-NC 4.0 International license .

Driven by the study findings, it seems that the decision to perform the ONIRY test should be made at the time of DRE. As DRE is an integral part of the physical examination and every postpartum woman should be examined by palpation, ONIRY testing would be particularly beneficial in cases where, after performing a DRE, the examiner cannot exclude the presence of OASI. The indication for diagnosis with ONIRY would then be all cases of 'uncertain' DRE diagnoses (when confirming the absence of injury is impossible). With this approach, ONIRY would perfectly complement the current standard of practice, bridging the gap between DRE and specialised, elective diagnostics such as enodanal ultrasound.

Limitations and Future Directions

Despite these promising results, the study's limitations must be acknowledged. The potential alteration of impedance parameters due to a prior primary repair, in a few cases, may affect the ONIRY system accuracy, a factor that necessitates further investigation. Future studies should aim to confirm these findings in broader clinical settings and evaluate the impact displayed by the ONIRY system on long-term postpartum outcomes, including the reduction of complication rates and improvement in the quality of life.

Moreover, the potential for operator bias in DRE performance, given that operators were possibly more experienced than average, was not controlled in this study. This factor could artificially enhance the perceived performance of DRE.

Conclusion

The performance of DRE in detecting OASI is insufficient. ML-assisted impedance spectroscopy appeared to be a more precise method for rapid detection of OASIs immediately post-delivery. With its higher accuracy and simple application, it holds the

medRxiv preprint doi: https://doi.org/10.1101/2024.09.18.24313868; this version posted September 19, 2024. The copyright holder for this preprint (which was not certified by peer review) is the author/funder, who has granted medRxiv a license to display the preprint in perpetuity.

It is made available under a CC-BY-NC 4.0 International license .

promise of becoming an essential tool in obstetric care, potentially reducing the incidence of long-term complications associated with OASI.

Acknowledgments

The authors would like to thank all the other investigators and co-investigators involved in the clinical trial from centres in the Czech Republic (Brno and Prague), Slovakia (Kosice), Poland (Warsaw), and Spain (Leon) for their invaluable contributions to patient recruitment, the clinical trials conduct, and the help they provided in developing the results.

Disclosure of interests

K.B. is a founder and management board member at OASIS Diagnostics, the author of the related patent and R&D strategy, an independent consultant, and a Takeda trainer.

M.M., M.R., K.K., and P.I. are staff of OASIS Diagnostics.

A.S. is an independent Ethicon, Takeda, Pfizer, and Sofar consultant.

H.H. and P.J. received remuneration as study investigators.

S.S., R.DT., A.S., H.H., C.R., S.A., DE.A.R., A.St., J.B., R.Fr., M.G., A.D., and R.F. are independent consultants and OASIS Diagnostics' Scientific Advisory Board members.

Contribution to Authorship

Conceptualization: S.S., R.F. K.B., M.M., P.I.

Data curation: S.S., M.M., M.R., K.K., P.I.

Formal analysis: M.M., M.R., K.K.

medRxiv preprint doi: https://doi.org/10.1101/2024.09.18.24313868; this version posted September 19, 2024. The copyright holder for this preprint **(which was not certified by peer review)** is the author/funder, who has granted medRxiv a license to display the preprint in perpetuity.

It is made available under a CC-BY-NC 4.0 International license .

Funding acquisition: K.B., M.M.

Investigation: H.H., P.J.

Methodology: S.S., R.DT., A.S., H.H., C.R., S.A., DE.A.R., A.St., J.B., R.Fr., M.G., A.D., and R.F.

Project administration: K.B., M.M.

Resources: H.H., P.J.

Software: M.R., K.K.

Supervision: R.DT., A.S., H.H., C.R., S.A., DE.A.R., A.St., J.B., R.Fr., M.G., A.D., and R.F.

Validation: M.M., P.I.

Visualization: M.R., K.K.

Writing - original draft: S.S., K.B., A.R., A.S. M.M., M.R., K.K.

Details of Ethics Approval

The study received approval from the ethics committees of the respective study sites on the following dates: 19 March 2021 by the Ethics Committee of the Institute for Maternal and Child Care (approval no. 1/19.03.2021), 27 April 2021 by the Ethics Committee for Research with Medicines of the Health Areas of León and Bierzo (approval no. 2186), 9 June 2021 by the Ethics Committee of the University Hospital of Brno (approval no. 47/21Zdrav.), 14 October 2021 by the Ethics Committee at the Regional Medical Chamber in Warsaw (approval no. KB/1362/21), and 25 July 2022 by the Ethics Committee at AGEL Hospital Košice-Šaca (approval no. ONIRY 3/2/2020).

Funding

The study was financed by the European Union as part of the Fast Track program,

medRxiv preprint doi: https://doi.org/10.1101/2024.09.18.24313868; this version posted September 19, 2024. The copyright holder for this preprint (which was not certified by peer review) is the author/funder, who has granted medRxiv a license to display the preprint in perpetuity.

It is made available under a CC-BY-NC 4.0 International license .

conducted in Poland by the Polish National Centre for Research and Development (POIR.01.01.01-00-0726/18).

References

1. Sultan AH, Kamm MA, Hudson CN, Thomas JM, Bartram CI. Anal sphincter disruption during vaginal delivery. N Engl J Med 1993; 329:1905-11.
2. Groom KM, Paterson-Brown S. Can we improve on the diagnosis of third degree tears? Eur J Obstet Gynecol Reprod Biol 2002;101:19 21.
3. Thiagamoorthy G, Johnson A, Thakar R, Sultan AH. A national survey of perineal trauma and its subsequent management in the United Kingdom. Int Urogynecol J 2014;25:1621–7.
4. Gurol-Urganci I, Cromwell DA, Edozien LC, et al. Third- and fourth-degree perineal tears among primiparous women in England between 2000 and 2012: time trends and risk factors. BJOG 2013;120:1516–25
5. Baghestan E, Irgens LM, Bordahl PE, Rasmussen S. Trends in risk factors for obstetric anal sphincter injuries in Norway. Obstet Gynecol 2010;116:25–34.
6. Zetterström J, López A, Anzén B, Norman M, Holmström B, Mellgren A. Anal sphincter tears at vaginal delivery: risk factors and clinical outcome of primary repair. Obstet Gynecol. 1999 Jul;94(1):21-8. PMID: 10389712.
7. Lewicky-Gaupp C, Leader-Cramer A, Johnson LL, Kenton K, Gossett DR. Wound complications after obstetric anal sphincter injuries. Obstet Gynecol. 2015 May;125(5):1088-1093. doi: 10.1097/AOG.0000000000000833. PMID: 25932836.
8. Andrews V, Sultan AH, Thakar R, Jones PW. Occult anal sphincter injuries--myth or reality? BJOG. 2006;113:195–200.
9. Serati M, Ruffolo AF, Scancarello C, Braga A, Salvatore S, Ghezzi F. When does

medRxiv preprint doi: https://doi.org/10.1101/2024.09.18.24313868; this version posted September 19, 2024. The copyright holder for this preprint **(which was not certified by peer review)** is the author/funder, who has granted medRxiv a license to display the preprint in perpetuity.

It is made available under a CC-BY-NC 4.0 International license .

oasis cause de novo pelvic floor dysfunction? role of the surgeon's skills. Int Urogynecol J. 2023 Feb;34(2):493-498. doi: 10.1007/s00192-022-05205-6. Epub 2022 Apr 25. PMID: 35467138; PMCID: PMC9036836.

10. Zimmo K, Laine K, Vikanes A, Foss E, Zimmo M, Ali H, et al. Diagnosis and repair of perineal injuries: knowledge before and after expert training multicentre observational study among Palestinian physicians and midwives. BMJ Open 2017;7(4):e014183, 2017.
11. Sideris, M., McCaughey T, Hanrahan JG, Arroyo-Manzano D, Zamora J, Jha S, Knowles CH, Thakar R, Chaliha C, Thangaratinam S. Risk of obstetric anal sphincter injuries (OASIS) and anal incontinence: a meta-analysis. (2020). European Journal of Obstetrics & Gynecology and Reproductive Biology, 252, 303-312.
12. Department for Health and Wellbeing. South Australian Perinatal Practice Guideline - Third and fourth degree tear management 2018. Available from: www.sahealth.sa.gov.au/wps/wcm/connect/1faf87004eedec4db635b76a7ac0d6e4/Third+and+Fourth+Degree+Tear+Management_PPG_v5_1.pdf?MOD=AJPERES&CACHEID=ROOTWORKSPACE-1faf87004eedec4db635b76a7ac0d6e4-oc-RC8a
13. Queensland Clinical Guidelines. Queensland clinical guidelines: Perineal Care 2023. Available from: https://www.health.qld.gov.au/__data/assets/pdf_file/0022/142384/g-pericare.pdf
14. Harvey MA, Pierce M, Alter JE, Chou Q, Diamond P, Epp A, et al. Obstetrical Anal Sphincter Injuries (OASIS): Prevention, Recognition, and Repair. J Obstet Gynaecol Can.2015;37(12):1131-48.
15. Danish Association of Obstetrics and Gynaecology. Guideline for obstetric anal sphincter injury (OASIS) 2019. Available from: https://nfog.org/wp-

medRxiv preprint doi: https://doi.org/10.1101/2024.09.18.24313868; this version posted September 19, 2024. The copyright holder for this preprint **(which was not certified by peer review)** is the author/funder, who has granted medRxiv a license to display the preprint in perpetuity.

It is made available under a CC-BY-NC 4.0 International license .

content/uploads/2019/03/190313-obstetric-anal-sphincter-injury.pdf

16. Kropshofer A, Aigmüller T, Beilecke K, et al. Management of Third and Fourth-Degree Perineal Tears After Vaginal Birth. Guideline of the DGGG, OEGGG, and SGGG (S2k-Level, AWMF Registry No. 015/079, December 2020). Geburtshilfe Frauenheilkd. 2022 Dec 7;83(2):165-183. doi: 10.1055/a-1933-2647.
17. Royal College of Physicians of Ireland. Institute of obstetricians and gynaecologists and, directorate of clinical strategy and programmes, health service executive. Management of obstetric anal sphincter injuries (2012).
18. Ministry of Health Mexico. Prevención, diagnóstico y tratamiento de episiotomía complicada. 2015. Available from: https://www.cenetec-difusion.com/CMGPC/IMSS-608-13/ER.pdf
19. Netherlands Society of Obstetrics and Gynaecology. Total rupture during childbirth 2013-2024.
20. Royal College of Obstetrics and Gynaecology. Management of third and fourth degree perineal tears. Greentop guideline number 29 2015. Available from: https://www.rcog.org.uk/media/5jeb5hzu/gtg-29.pdf
21. The American College of Obstetricians and Gynecologists. Practice bulletin no. 198 Prevention and Management of Obstetric Lacerations at vaginal delivery. Obstet Gynecol. 2018;132:e87–102 . https://pubmed.ncbi.nlm.nih.gov/30134424/
22. Ducarme G, Pizzoferrato AC, de Tayrac R, Schantz C, Thubert T, Le Ray C, Riethmuller D, Verspyck E, Gachon B, Pierre F, Artzner F, Jacquetin B, Fritel X. Perineal prevention and protection in obstetrics: CNGOF clinical practice guidelines. J Gynecol Obstet Hum Reprod. 2019 Sep;48(7):455-460. doi: 10.1016/j.jogoh.2018.12.002. Epub 2018 Dec 12.
23. Marty N, Verspyck E. Perineal tears and episiotomy: Surgical procedure - CNGOF perineal prevention and protection in obstetrics guidelines. Gynecol Obstet Fertil

medRxiv preprint doi: https://doi.org/10.1101/2024.09.18.24313868; this version posted September 19, 2024. The copyright holder for this preprint **(which was not certified by peer review)** is the author/funder, who has granted medRxiv a license to display the preprint in perpetuity.

It is made available under a CC-BY-NC 4.0 International license .

Senol. 2018

24. Flemish Society of Obstetrics and Gynecology (VVOG). CLINICAL GUIDANCE PAPER VVOG. Obstetrical Anal Sphincter Injuries – OASIS. 2024
25. O'Leary BD, Kelly L, Fitzpatrick M, Keane DP. Underdiagnosis of internal anal sphincter trauma following vaginal delivery.Ultrasound Obstet Gynecol. 2023 Feb;61(2):251-256. doi: 10.1002/uog.26049
26. Shek KL, Atan IK, Dietz HP. Can Anal Sphincter Defects Be Identified by Palpation? Female Pelvic Med Reconstr Surg. 2016 Nov/Dec;22(6):472-475
27. Guzmán Rojas RA, Salvesen KA, Volløyhaug I. Anal sphincter defects and fecal incontinence 15–24 years after first delivery: a cross-sectional study. Ultrasound Obstet Gynecol 2018;51(5): 677-683, 2018.
28. Młyńczak M, Borycka-Kiciak K, Uchman-Musielak M, Dziki A. Impedance Spectroscopy Method to Detect Pelvic Floor Muscle Damage – A Feasibility Study," In World Congress on Medical Physics and Biomedical Engineering, Springer, Singapore, pp. 875–878, 2018.
29. Borycka-Kiciak K, Młyńczak M, Kiciak A, Pietrzak P, Dziki A. Noninvasive obstetric anal sphincter injury diagnostics using impedance spectroscopy. Scientific Reports 2019;9(7097):1–9.
30. Młyńczak M, Rosoł M, Spinelli A, Dziki A, Wlazlak E, Surkont G, et al. Obstetric Anal Sphincter Injury Detection Using Impedance Spectroscopy with the ONIRY Probe. Appl Sci 2021;11:637, 2021.
31. Borycka K, Młyńczak M, Rosoł M, Iwanowski P, Uchman Musielak M, Mik M, Sudoł-Szopińska I, Herman H, Ratto C, Dziki A, Wlaźlak E, Surkont G, Krzycka M, Pająk P, Spinelli A. Impedance spectroscopy for the diagnosis of obstetric anal sphincter injuries: the pilot experience," In: 15 Congress of the European Society of Gynecology, 2023.

medRxiv preprint doi: https://doi.org/10.1101/2024.09.18.24313868; this version posted September 19, 2024. The copyright holder for this preprint **(which was not certified by peer review)** is the author/funder, who has granted medRxiv a license to display the preprint in perpetuity.

It is made available under a CC-BY-NC 4.0 International license .

32. Taithongchai A, Veiga SI, Sultan AH, Thakar R. The consequences of undiagnosed obstetric anal sphincter injuries (OASIS) following vaginal delivery. Int Urogynecol J 2020;31:635–41
33. Roper JC, Thakar R, Sultan AH. Underclassified obstetric anal sphincter injuries. Int Urogynecol J 2022;33:1473–9.
34. Okeahialam NA, Taithongchai A, Thakar R, Sultan AH. The incidence of anal incontinence following obstetric anal sphincter injury graded using the Sultan classification: a network meta-analysis. Am J Obstet Gynecol. 2023. PMID: 36379266 Review.
35. Corrigendum to 'The incidence of anal incontinence following obstetric anal sphincter injury graded using the Sultan classification: A network meta-analysis' [American Journal of Obstetrics and Gynecology 228/6 (2023) 675-688] Am J Obstet Gynecol2024
36. Andrews V, Thakar R, Sultan AH. Outcome of obstetric anal sphincter injuries (OASIS)-role of structured management", Int Urogynecol J Pelvic Floor Dysfunct 2009; 20(8):973-8.
37. Norderval S, Öian P, Revhaug A, Vonen B. Anal Incontinence After Obstetric Sphincter Tears: Outcome of Anatomic Primary Repairs. Diseases of the Colon & Rectum 2005; 48(5):p 1055-1061.
38. Ramage L, Yen C, Qiu S, Simillis C, Kontovounisios C,Tan E, Tekkis P. Does a missed obstetric anal sphincter injury at time of delivery affect short-term functional outcome? Ann R Coll Surg Engl 2008;100(1):26–32, 2008.
39. Gutierrez AB, Madoff RD, Lowry AC, Parker S, Congilosi MD, Buie DW, Baxter NN. Long-Term Results of Anterior Sphincteroplasty. Diseases of the Colon & Rectum 2004; 47(5):p 727-732.
40. Zutshi M, Hull T, Bast J, Halverson A, Na J. Ten-year outcome after anal sphincter

medRxiv preprint doi: https://doi.org/10.1101/2024.09.18.24313868; this version posted September 19, 2024. The copyright holder for this preprint **(which was not certified by peer review)** is the author/funder, who has granted medRxiv a license to display the preprint in perpetuity.

It is made available under a CC-BY-NC 4.0 International license .

repair for fecal incontinence. Dis Colon Rectum 2009 Jun;52(6):1089-94.

41. Tan EK, Jacovides M, Khullar V, Teoh TG, Fernando RJ, Tekkis PP. A cost□effectiveness analysis of delayed sphincteroplasty for anal sphincter injury. Colorectal Disease 2008; 10(7):653-662.

Table/Figure Caption List

Table 1. Characteristics of the study population.

	Group I	Group II	Total
	(N=91)	(N=61)	(N=152)
Age (years)			
Mean ± SD	31.7 ± 4.6	30.7 ± 4.6	31.3 ± 4.6
Range (Min/Max)	22 (18/40)	20 (22/42)	24 (18/42)
Age categorized (n, %)			
<26 years	9 (9.9)	7 (11.5)	16 (10.5)
26<35 years	53 (58.2)	41 (67.2)	94 (61.8)
≥35 years	29 (31.9)	13 (21.3)	42 (27.6)
Weight (kg)			
Mean ± SD	71.7 ± 11.8	68.1 ± 9.6	70.2 ± 11.0
Range (Min/Max)	56 (49/105)	60 (48/108)	60 (48/108)
BMI (kg/m^2)			
Mean ± SD	25.4 ± 3.6	24.3 ± 3.4	25.0 ± 3.6
Range (Min/Max)	18.9 (17.4/36.3)	15.6 (17.7/33.3)	18.9 (17.4/36.3)
Number of pregnancies (including the index one) (n)			
Median	2	1	1
Range (Min/Max)	5 (1/6)	3 (1/4)	5 (1/6)
Primipara/Multipara	49/42	46/15	95/57
Risk factors for Obstetric Anal Sphincter Injury from the index delivery (n, %)			

medRxiv preprint doi: https://doi.org/10.1101/2024.09.18.24313868; this version posted September 19, 2024. The copyright holder for this preprint **(which was not certified by peer review)** is the author/funder, who has granted medRxiv a license to display the preprint in perpetuity.

It is made available under a CC-BY-NC 4.0 International license .

Prolonged second phase of delivery	6 (6.6)	10 (16.4)	16 (10.5)
Fetal shoulder dystocia	1 (1.1)	0 (0.0)	1 (0.7)
Birth weight of the neonate >4kg	9 (9.9)	6 (9.8)	15 (9.9)
Induction of delivery with oxytocin	15 (16.5)	9 (14.8)	24 (15.8)
Head circumference of the neonate ≥34 cm	56 (61.53)	49 (80.3)	105 (69.1)
Time between the index delivery and ONIRY examination (days)			
Median	4	28	14
Range (Min/Max)	57 (0/57)	55 (1/56)	57 (0/57)
Time between the index delivery and EAUS examination (days)			
Median	4	28	14
Range (Min/Max)	57 (0/57)	55 (1/56)	57 (0/57)

Table 2. Performance metrics of the ONIRY device in the assessment relative to 3-D Endoanal Ultrasound and OASIS classification (each row shows the statistics for a single 10-fold cross-validation each performed with different random seed).

Seed	**Accuracy**	**Sensitivity**	**Specificity**
1	87.2%	90.9%	84.6%
2	86.6%	92.6%	82.3%
3	87.9%	86.7%	88.6%
4	86.9%	87.7%	86.4%
5	87.6%	92.7%	84.2%
6	87.6%	89.4%	86.2%
7	86.9%	91.9%	83.5%
8	86.2%	91.0%	82.9%
9	86.9%	91.9%	83.5%
10	86.6%	91.2%	83.6%
Mean ±SD	87.0% ± 0.5%	90.6% ± 2.0%	84.6% ± 1.9%

medRxiv preprint doi: https://doi.org/10.1101/2024.09.18.24313868; this version posted September 19, 2024. The copyright holder for this preprint **(which was not certified by peer review)** is the author/funder, who has granted medRxiv a license to display the preprint in perpetuity.

It is made available under a CC-BY-NC 4.0 International license .

Table 3. Performance metrics of DRE and ONIRY device in the assessment in reference to EAUS under OASIS classification.

Grade	N	Accuracy of DRE	Accuracy of ONIRY
Grade 3a	25	24.0%	81.2%
Grade 3b	26	53.8%	90.8%
Grade 3c	9	77.8%	95.6%
Grade 4	1	0.0%	60%

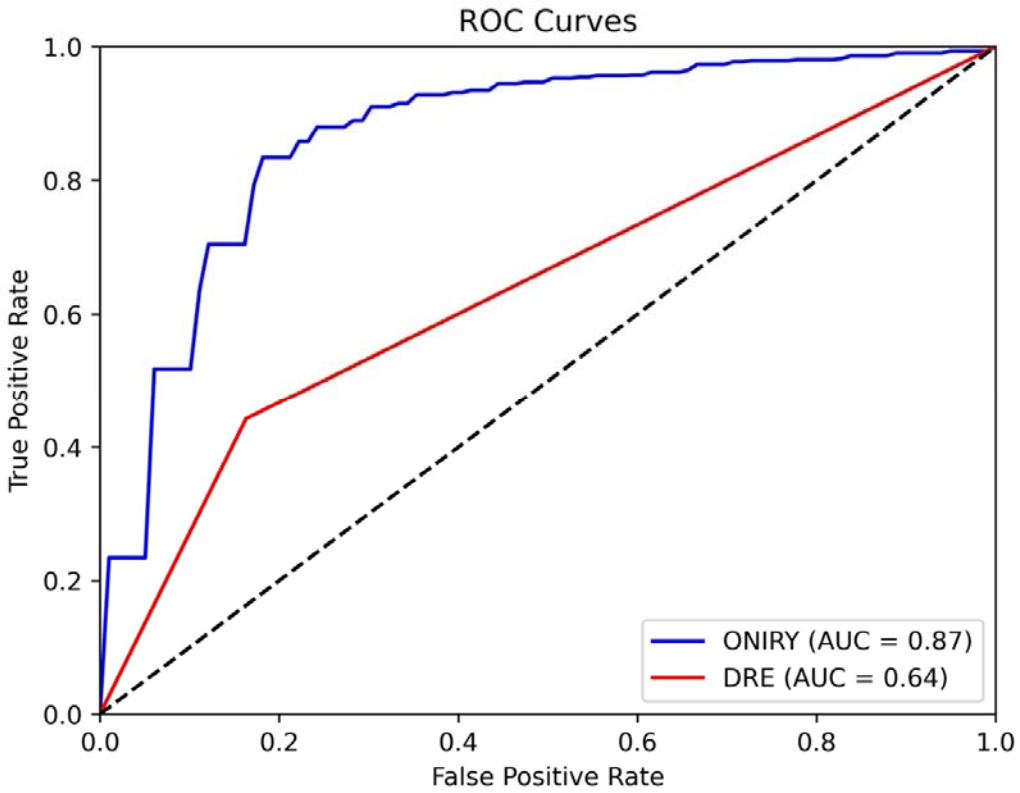

Figure 1. ROC curves for the ONIRY system and DRE are presented as blue and red lines, respectively, with the identity line depicted as a black dashed line.

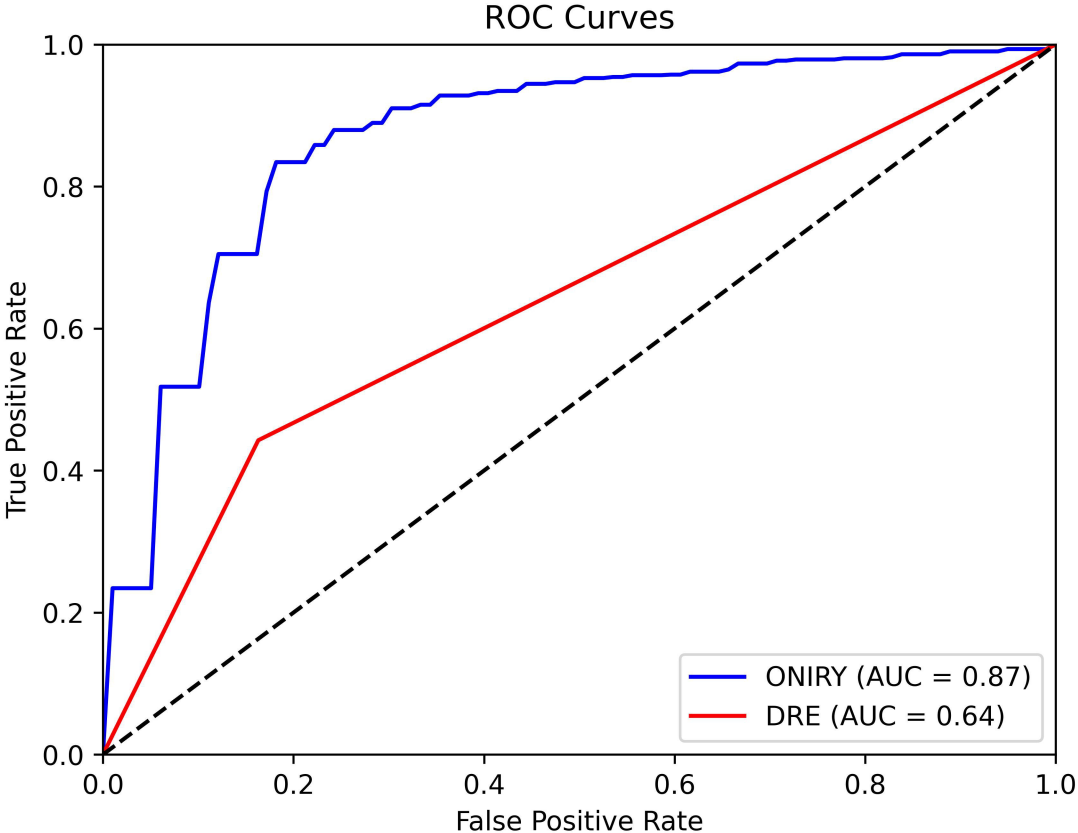
ROC Curves
True Positive Rate
False Positive Rate
0.0
0.2
0.4
0.6
0.8
1.0
ONIRY (AUC = 0.87)
DRE (AUC = 0.64)