medRxiv preprint doi: https://doi.org/10.1101/2024.08.27.24312649; this version posted August 28, 2024. The copyright holder for this preprint (which was not certified by peer review) is the author/funder, who has granted medRxiv a license to display the preprint in perpetuity.
All rights reserved. No reuse allowed without permission.



# Association between choroidal microvasculature in the eye and Alzheimer's disease risk in cognitively healthy midlife adults

Jamie Burke, [1,2,*] Samuel Gibbon,[1,3,*] Audrey Low,[4] Charlene Hamid,[5] Megan Reid-Schachter,[5] Graciela Muniz-Terrera,[6] Craig W Ritchie,[3] Baljean Dhillon,[1,3,7] John T O'Brien,[4] Stuart King,[2] Ian JC MacCormick, [1,3,8] and Thomas J MacGillivray[1,3]

[*] Authors contributed equally

[1] *Robert O Curle Ophthalmology Suite, Institute for Regeneration and Repair, University of Edinburgh, UK*

[2] *School of Mathematics, University of Edinburgh, Edinburgh, UK*

[3] *Centre for Clinical Brain Sciences, Edinburgh, UK*

[4] *Department of Psychiatry, School of Clinical Medicine, University of Cambridge, Cambridge, UK*

[5] *Edinburgh Imaging, The Queen's Medical Research Institute, University of Edinburgh, UK*

[6] *Ohio University Heritage College of Osteopathic Medicine, Athens, OH & Centre for Dementia Prevention, University of Edinburgh, Edinburgh, UK*

[7] *Princess Alexandra Eye Pavilion, Chalmers Street, Edinburgh, UK*

[8] *Institute for Adaptive and Neural Computation, University of Edinburgh, UK*

**NOTE: This preprint reports new research that has not been certified by peer review and should not be used to guide clinical practice.**

medRxiv preprint doi: https://doi.org/10.1101/2024.08.27.24312649; this version posted August 28, 2024. The copyright holder for this preprint (which was not certified by peer review) is the author/funder, who has granted medRxiv a license to display the preprint in perpetuity.
All rights reserved. No reuse allowed without permission.



**Abstract**

*Objective:* To explore associations between measurements of the ocular microvasculature in the choroid (a highly vascularised layer posterior to the retina) and genetic Alzheimer's disease risk.

*Methods:* We measured the choroidal vasculature appearing in optical coherence tomography scans of 69 healthy, mid-life individuals in the PREVENT cohort. The cohort was prospectively split into low, medium, and high-risk groups based on the presence of known risk factors (APOE4 genotype and family history of dementia). We used ordinal logistic regression to test for cross-sectional associations between choroidal measurements and pre-determined risk of future Alzheimer's disease.

*Results:* We observed progressively increased choroidal vasculature between ordinal risk groups, and all choroidal measurements were significantly associated with risk group prediction. APOE4 carriers had significantly thicker choroids and larger vascular tissue compared to non-carriers. Similar trends were observed for those with a family history of dementia. In our sample, a 0.16 $mm^2$ increase in choroidal vascular area was associated with a 2-fold increase in the likelihood of having one or more markers of Alzheimer's disease risk, compared with none.

*Conclusions:* Our results suggest a potential link between the choroidal vasculature and risk of Alzheimer's disease. However, these findings are exploratory and should be replicated in a larger, more diverse sample.

**Keywords:** optical coherence tomography; retina; choroid; dementia; APOE4

medRxiv preprint doi: https://doi.org/10.1101/2024.08.27.24312649; this version posted August 28, 2024. The copyright holder for this preprint (which was not certified by peer review) is the author/funder, who has granted medRxiv a license to display the preprint in perpetuity.
All rights reserved. No reuse allowed without permission.


## Introduction

Non-invasive examination of the back of the eye using optical coherence tomography (OCT) is increasingly used to investigate neurodegenerative diseases, including Alzheimer's disease,[1] which has a strong vascular component.[2] While the primary goal of OCT has often been to image the cross-sectional retinal layers (a *neuronal* measure and marker of neurodegeneration), recent advances in enhanced depth imaging OCT (EDI-OCT),[3] permit visualisation of the choroid, a dense *vascular* mesh posterior to the retina, which provides essential maintenance to the photoreceptors.[4] In comparison to the retinal circulation, the choroidal circulation has significantly greater blood flow and perfusion pressure,[5,6] and is innervated by the central autonomic network.[7] Autonomic dysfunction is common in adults with mild cognitive impairment,[8] and in those already living with dementia,[9] which makes the choroid a prime candidate for investigating pathophysiological response in relation to these conditions. Since the advent of EDI-OCT, there have been numerous studies linking choroidal changes to both systemic health outcomes,[10] and neurological diseases.[11–13]

However, there have been conflicting reports of choroidal changes in established Alzheimer's disease in older populations,[14–20] raising questions about the underlying mechanisms and stages of the disease that might influence choroidal vasculature. One possibility is that genetic factors, such as the apolipoprotein E ε4 (APOE4) allele, and family history of dementia, both of which have been identified as important determinants of Alzheimer's risk,[21–23] may play a role. To our knowledge, only one study,[24] directly assessed the relationship between choroidal measures and genetic risk (APOE4) in cognitively normal, old-age individuals but found no evidence of significant differences between carriers and non-carriers. Choroidal changes in the preclinical or prodromal stage of Alzheimer's remain unexplored, and could provide valuable insights into the underlying mechanisms linking vascular pathology to prospective cognitive decline.

medRxiv preprint doi: https://doi.org/10.1101/2024.08.27.24312649; this version posted August 28, 2024. The copyright holder for this preprint (which was not certified by peer review) is the author/funder, who has granted medRxiv a license to display the preprint in perpetuity.
All rights reserved. No reuse allowed without permission.


The *PREVENT Dementia* study,[25] investigates concurrent cerebral and retinal vascular changes in a cohort of mid-life individuals, half of whom are at increased risk of Alzheimer's disease. While most research on ocular microvascular changes in Alzheimer's disease focuses on older age groups,[14–19,24] the PREVENT cohort presents a unique opportunity to examine the microvasculature in individuals who may be in the very early preclinical stage of disease.[26] Accordingly, the study presented here aimed to explore the associations between four choroidal measures (area, thickness, choroidal vascular index, vessel area) and two genetic risk factors (APOE4, family history) in cognitively healthy midlife adults.

## Methods

### *Image capture*

The protocol for the *PREVENT Dementia* study has been outlined previously.[25,27] It aimed to recruit participants aged between 40 and 59 from five sites in the UK and Ireland, and to include a significant portion with a family history of dementia (approximately 50%). The Edinburgh site recruited 224 participants, of which 180 provided written informed consent to the retinal sub-study. The study adhered to the principles of the Declaration of Helsinki.

OCT was captured in both eyes using the Heidelberg spectral domain SPECTRALIS Standard Module (Heidelberg Engineering, Heidelberg, Germany). Fovea-centred OCT B-scans of the retina and choroid (Figure 2A – C) were taken using active eye tracking to prevent artefacts from eye movement, covering a 30° angle at high speed, resulting in approximately 9 mm field of view. Single, horizontal- and vertical-line scans were taken with an automatic real time (ART) value of 100 (the number of averaged B-scans taken during a single acquisition) to reduce speckle noise. Posterior pole volumetric scans were also collected, with 61 parallel horizontal line scans covering the macula and spaced

medRxiv preprint doi: https://doi.org/10.1101/2024.08.27.24312649; this version posted August 28, 2024. The copyright holder for this preprint (which was not certified by peer review) is the author/funder, who has granted medRxiv a license to display the preprint in perpetuity.
All rights reserved. No reuse allowed without permission.


approximately 125 microns apart, with an ART of 9. B-scans with a signal-to-noise quality index (provided in the HeyEx viewer software, version 1.10.4.0; Heidelberg Engineering, Heidelberg, Germany) less than 15 were excluded, according to the OSCAR-IB criteria[28] for retinal OCT quality assessment.

*Choroidal measurements*

Measurements of fovea-centred subfoveal choroid thickness, region area, vessel area and choroid vascular index (CVI) were computed using *Choroidalyzer*,[29] a fully automatic deep learning-based image analysis pipeline. Briefly, *Choroidalyzer* automatically segments the choroid region and vasculature of an OCT B-scan and detects the fovea (Figure 2D). The choroid was defined as the vascular space between the hyperreflective Bruch's membrane (anterior) and sclera (posterior). Subfoveal thickness was measured as a straight-line micron distance underneath the fovea, locally perpendicular to Bruch's complex (Figure 2E, blue). Choroid area was calculated as the number of pixels within a fovea-centred region of interest (RoI), converted into $mm^2$ (Figure 2E, red). Similarly, choroid vessel area was calculated as the number of vessel pixels within the prescribed RoI (Figure 2F, blue). CVI measures the proportion of vasculature within the choroid and is a dimensionless ratio of vessel pixels to choroid pixels (Figure 2F, blue : red), similarly, measured in a fovea centred RoI. Choroid measurements were made for three distinct RoI's defined by .5mm, 1.5mm and 3mm distance from the fovea, following the Early Treatment Diabetic Retinopathy Study (ETDRS) grid.[30] The software is implemented in Python (version 3.11.6).

*Data exploration and statistical analysis*

Participants in the PREVENT cohort,[25] were stratified into three risk groups based on APOE4 presence and family history of dementia (FH) by design: 'high' risk was defined

medRxiv preprint doi: https://doi.org/10.1101/2024.08.27.24312649; this version posted August 28, 2024. The copyright holder for this preprint (which was not certified by peer review) is the author/funder, who has granted medRxiv a license to display the preprint in perpetuity.
All rights reserved. No reuse allowed without permission.


where both APOE4 and FH were present, 'medium' risk where either APOE4 or FH were present and 'low' risk where neither were present.

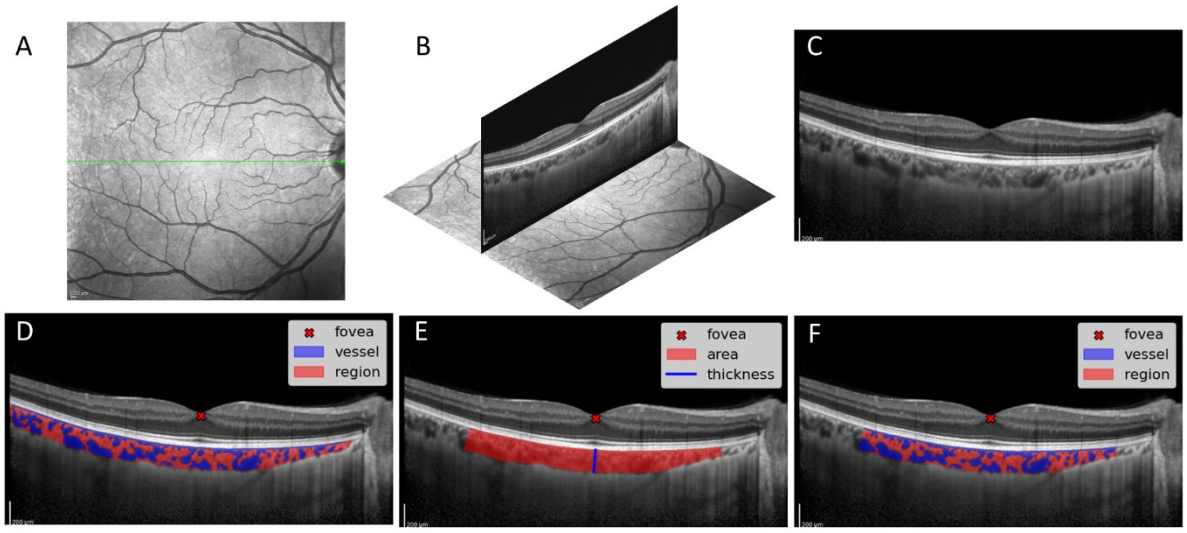


**Figure 1.** Example derivation of choroidal measurements. (A) En face image of the retina in the posterior segment of the eye with location of OCT B-scan acquisition shown in green. (B) OCT B-scan cross section overlaid onto the en face retinal image. (C) OCT B-scan. (D) Automatic segmentation of region, vasculature and detection of fovea using Choroidalyzer.[29] (E) Measurements of choroid thickness (CT) and choroid area (CA). (F) Measurements of choroid vessel area (CV) and choroid vascular index (CVI) in a fovea-centred region of interest.

As this was an exploratory study with a relatively small sample size, our primary objective was to report descriptive statistics and investigate potential trends and associations. We first graphed choroidal measurements, testing for normality using the Shapiro-Wilks test, and performed univariate hypothesis testing on the mean differences between choroidal measures stratified for each risk factor. Alongside univariate statistical tests with individual markers, we assumed a biological ordering between risk groups and used ordinal logistic regression with each choroidal measure in turn as a single covariate in an unadjusted model, as well as in adjusted models controlling for age, sex, and mean arterial blood pressure.[31–33] Unadjusted models were estimated so as to retain maximum statistical power in a relatively low sample size.

To minimise the risk of spurious associations from analyses of multiple regions of interest per eye, we only selected choroidal measurements from horizontal-line scans with a 1.5mm fovea-centred RoI with a preference for the left eye. The left eye tends to have a

medRxiv preprint doi: https://doi.org/10.1101/2024.08.27.24312649; this version posted August 28, 2024. The copyright holder for this preprint (which was not certified by peer review) is the author/funder, who has granted medRxiv a license to display the preprint in perpetuity.
All rights reserved. No reuse allowed without permission.


thinner choroid than the right,[34] helping overcome issues with image quality from optical signal degradation. Any missing values were removed at the point of analysis (see Table 1). Analyses were performed using Python's statsmodels (version 0.14.0).

**Results**

Of 180 consented to the Edinburgh site retinal sub-study, 126 participants underwent OCT capture (device error, N=3; room booking issues, N=4; opted out at the point of examination, N=48). Participants with retinal pathology (N=1, macular degeneration) were excluded from our analysis to prevent abnormal retinae from confounding our results, as well as highly myopic/hyperopic eyes (N=4, refractive error > ±6 dioptres, approximately measured using the scan focus on the OCT imaging device),[35] which have a known association with the choroid.[36] Only EDI-OCT captures with sufficient choroid visualisation were selected for analysis (N=72). After removing individuals with missing data for APOE4 and FH (N=3), the final sample contained 69 participants (66 left eyes, 3 right eyes), stratified into low (N=26), medium (N=26) and high (N=17) risk groups. A sample derivation flowchart is presented in Figure 2. While we cannot be certain of no selection bias in our final sample, upon comparing any distribution differences between the final sample (N=69) and the remaining cohort (N=155), there was no evidence of significant differences in demographic or cardiovascular variables (Supplementary Table 1).

Demographics and study variables are summarised in Table 1. The mean age was 51.6 years (SD = 5.71) with a slight female majority (N = 41, 59.4%). Mean arterial blood pressure was slightly higher in the low-risk group compared to the medium and high-risk groups (p=0.001, p=0.01). No other evidence of significant differences in demographic or cardiovascular variables were observed between risk groups.

medRxiv preprint doi: https://doi.org/10.1101/2024.08.27.24312649; this version posted August 28, 2024. The copyright holder for this preprint (which was not certified by peer review) is the author/funder, who has granted medRxiv a license to display the preprint in perpetuity.
All rights reserved. No reuse allowed without permission.



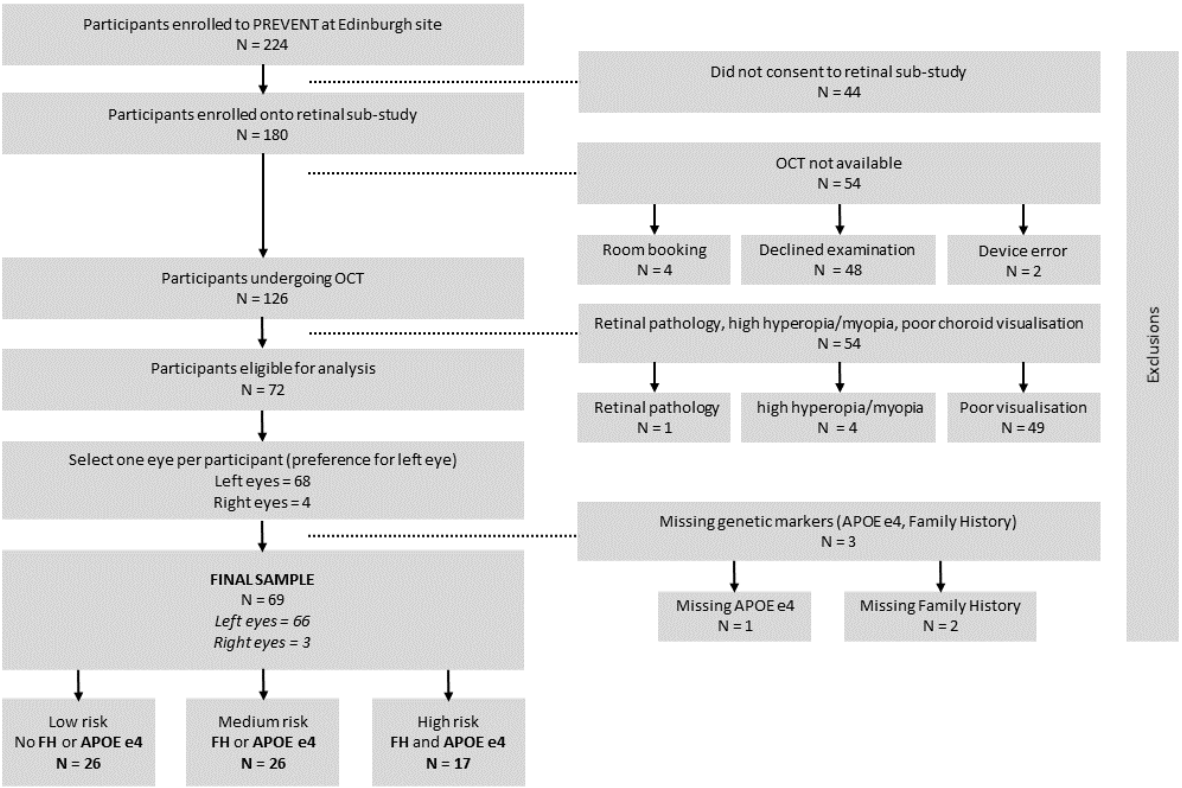


**Figure 2.** Sample derivation flowchart.

**Table 1.** Demographics and study variables, stratified by risk group.

| | Risk group | | | Overall |
|---|---|---|---|---|
| | Low | Medium | High | |
| **Participants** | 26 | 26 | 17 | 69 |
| **Age** (years) | 50.6 (6.3) | 52.4 (4.5) | 51.6 (6.4) | 51.6 (5.7) |
| **Sex** (female) | 14 (53.9%) | 17 (65.4%) | 10 (58.8%) | 41 (59.4%) |
| **Hypertension** | 4 (15.4%) | 3 (11.5%) | 1 (6.3%) | 8 (11.8%) |
| **Blood Pressure** (bpm) | 138.6 (13.0) | 124.7 (16.4) | 127.4 (13.7) | 130.6 (15.7) |
| **BMI** (kg/m$^2$) | 30.4 (6.9) | 28.1 (5.3) | 28.7 (4.2) | 29.1 (5.7) |
| **Smoking** | | | | |
| Current | 1 (3.9%) | 1 (3.8%) | 0 (0%) | 2 (2.9%) |
| Ex | 8 (30.8%) | 7 (26.9%) | 9 (52.9%) | 24 (34.8%) |
| Non | 17 (65.4%) | 18 (69.2%) | 8 (47.1%) | 43 (62.3%) |
| **Diabetes** | 1 (3.9%) | 2 (7.7%) | 0 (0%) | 3 (4.3%) |
| **Risk factors** | | | | |
| APOE4 status | 0 (0%) | 8 (30.8%) | 17 (100.0%) | 25 (36.2%) |
| Family History | 0 (0%) | 18 (69.2%) | 17 (100.0%) | 35 (50.7%) |
| **Choroidal measures** | | | | |
| Area (mm$^2$) | 0.68 (0.25) | 0.71 (0.194) | 0.87 (0.30) | 0.74 (0.26) |
| Thickness (µm) | 250.39 (84.48) | 257.00 (78.37) | 303.35 (105.56) | 265.93 (89.32) |
| Vascular index | 0.48 (0.06) | 0.53 (0.07) | 0.53 (0.08) | 0.51 (0.07) |
| Vessel area (mm$^2$) | 0.31 (0.14) | 0.36 (0.14) | 0.46 (0.18) | 0.37 (0.16) |

**Abbreviations:** BMI (body mass index); CVI (choroidal vascular index). **Notes:** All values are N (%) or Mean (standard deviation). Although modelling below only controlled for age, sex, and blood pressure, we report other cardiovascular risk factors for completeness. **Missing data (number of eyes, percentage):** Hypertension (1, 1.5%); BMI (2, 2.9%); CVI (2, 2.9%); Vessel area (2, 2.9%).

medRxiv preprint doi: https://doi.org/10.1101/2024.08.27.24312649; this version posted August 28, 2024. The copyright holder for this preprint (which was not certified by peer review) is the author/funder, who has granted medRxiv a license to display the preprint in perpetuity.
All rights reserved. No reuse allowed without permission.


Choroidal measurements were normally distributed (Supplementary Figure 1). Figure 3 presents grouped boxplots of choroidal measurements and prospectively defined Alzheimer's disease risk groups, showing a biological gradient between increasing risk and increasing choroidal measurements, particularly for choroid vessel area.

After adjusting for age, sex, and blood pressure, increased choroidal measurements were significantly associated with increased risk for Alzheimer's disease. Specifically, the presence of APOE4 and/or FH was significantly associated with increased choroidal area (OR per SD increase = 1.87 [CI: 1.12 – 3.11], p = 0.016), choroidal thickness (OR per SD increase = 1.69 [1.03 – 2.79], p = 0.039), CVI (OR per SD increase = 1.70 [1.02 – 2.82], p = 0.041), and vessel area (OR per SD increase = 2.25 [CI: 1.33 – 3.80], p = 0.003). The magnitude of effect for choroidal vessel area was the largest of all measures. Put another way, for every unit standard deviation increase in choroidal vessel area (0.16 $mm^2$), on average it is 2.25 times more likely that this individual has at least one risk marker for Alzheimer's disease (APOE4, FH) rather than none, after holding all other covariates constant. Results for both adjusted and unadjusted models are summarized in Table 2.

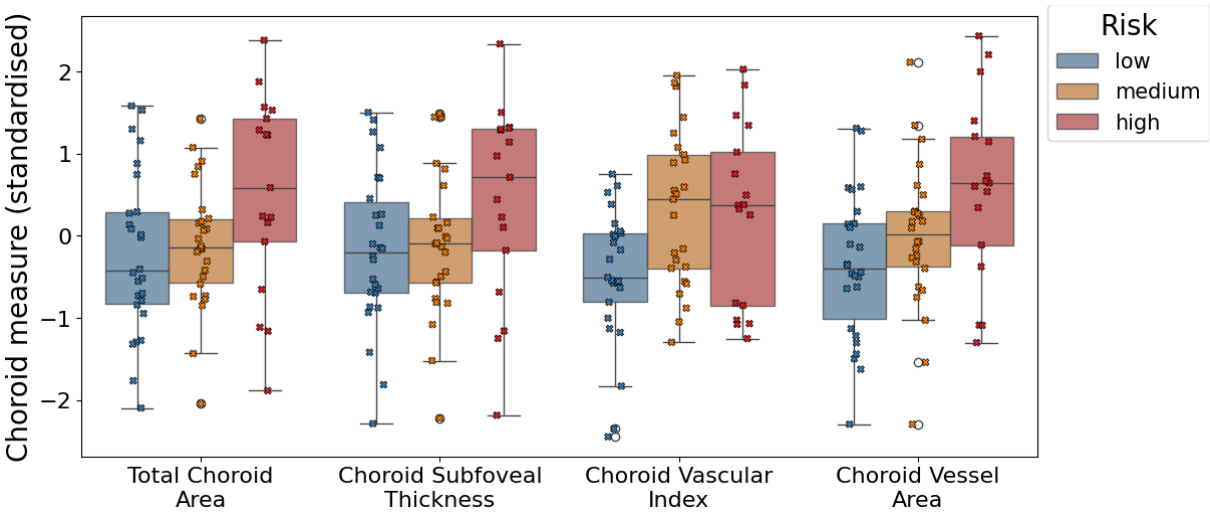


**Figure 3.** Boxplots showing the relationship between choroidal measures and risk groups, with individual datapoints overlaid in a swarm-plot.

medRxiv preprint doi: https://doi.org/10.1101/2024.08.27.24312649; this version posted August 28, 2024. The copyright holder for this preprint (which was not certified by peer review) is the author/funder, who has granted medRxiv a license to display the preprint in perpetuity.
All rights reserved. No reuse allowed without permission.


**Table 2.** Odds ratios (with 95% confidence intervals and corresponding P-values) for each ordinal logistic regression model, predicting risk group with each choroidal measure in turn.

| | **Adjusted models** | | **Unadjusted models** | |
|---|---|---|---|---|
| **Choroid measure** | *OR (CI)* | *P* | *OR (CI)* | *P* |
| Area ($mm^2$) | 1.87 (1.12 – 3.11) | **0.016** | 1.77 (1.09 – 2.88) | **0.021** |
| Thickness (μm) | 1.69 (1.03 – 2.79) | **0.039** | 1.54 (0.97 – 2.47) | 0.070 |
| Vascular index | 1.70 (1.02 – 2.82) | **0.041** | 1.87 (1.16 – 3.00) | **0.010** |
| Vessel area ($mm^2$) | 2.25 (1.33 – 3.80) | **0.003** | 2.14 (1.30 – 3.51) | **0.003** |

**Abbreviations:** OR (Odds ratio); CI (95% confidence interval). **Notes:** Adjusted models include age (standardised), blood pressure (standardised) and sex as covariates. To provide stable confidence intervals in logistic models, all choroidal measures were standardised. P-values lower than 0.05 are in bold type.

Considering individual risk, total choroidal area and vascular tissue were larger for APOE4 carriers and FH individuals, and these significant differences were supported by independent t-tests for choroid vessel area (p=0.022, p=0.009), and for choroid area (p=0.020) and vascular index (p=0.022) for APOE4 carriers and FH, respectively (Table 3). Supplementary Figure 2 illustrates these differences using boxplots and showing distributions.

**Table 3.** Distribution of choroidal measures by dementia risk with P-values for t-tests.

| | APOE4 carrier status | | |
|---|---|---|---|
| | Non-carrier | Carrier | P-Value |
| **N** | 47 | 25 | |
| Area ($mm^2$) | 0.67 (0.23) | 0.83 (0.27) | **0.02** |
| Thickness (μm) | 248.40 (85.36) | 288.64 (94.13) | 0.081 |
| Vascular index | 0.50 (0.06) | 0.53 (0.08) | 0.104 |
| Vessel area ($mm^2$) | 0.33 (0.14) | 0.43 (0.18) | **0.022** |
| | Family History of Dementia | | |
| | None | Yes | P-Value |
| **N** | 34 | 36 | |
| Area ($mm^2$) | 0.69 (0.23) | 0.79 (0.28) | 0.122 |
| Thickness (μm) | 252.03 (78.16) | 283.50 (99.83) | 0.146 |
| Vascular index | 0.49 (0.07) | 0.53 (0.07) | **0.022** |
| Vessel area ($mm^2$) | 0.32 (0.15) | 0.42 (0.16) | **0.009** |

## Discussion

We explored associations between the choroidal vasculature and two genetic risk factors for Alzheimer's disease (APOE4, FH). We observed a significant, positive association between each choroidal measure and degree of combined risk. To our best knowledge, this is

medRxiv preprint doi: https://doi.org/10.1101/2024.08.27.24312649; this version posted August 28, 2024. The copyright holder for this preprint (which was not certified by peer review) is the author/funder, who has granted medRxiv a license to display the preprint in perpetuity.
All rights reserved. No reuse allowed without permission.


the first exploration of the choroidal vasculature in cognitively healthy midlife adults at risk of Alzheimer's disease. Previous, related studies have focused only on retinal differences between genetic risk groups for Alzheimer's.[37]

The APOE4 variant is a major risk factor for Alzheimer's disease,[23] and has been associated with a wide range of negative health-related outcomes or features including cardiovascular disease,[38] blood-brain barrier dysfunction,[39] inflammation,[40] and autonomic dysfunction.[41] Lohman, et al.[41] reports that APOE4 carriers exhibit central autonomic dysfunction in early-stage Alzheimer's disease, including the parasympathetic control of cardiovascular functions.[42] Dillon et al.[8] found that mild cognitively impaired patients were on average 5.6 times more likely to have autonomic dysfunction, showing significant parasympathetic deficits, which may be involved in the pathogenesis of hypotension in dementia. Given that choroidal blood flow is regulated to some extent by autonomic input, particularly parasympathetic-mediated vasodilation, dysregulation of this autonomic supply could have played a role in the increased choroidal measurements observed in our sample. However, the choroid is a highly heterogeneous vascular compartment, and whether increased vasculature corresponds to larger calibre or simply more vessels cannot be fully understood with current imaging device resolutions.

We found just one other study that used enhanced-depth OCT choroid measures to investigate asymptomatic individuals with known APOE4 status and family history.[24] However, in contrast with our findings, Ma et al.,[24] found no evidence of significant differences in choroidal measures between carriers and non-carriers. One reason for the conflicting findings could be that the Ma study reported choroidal measurements in pixel units. By contrast, we converted choroidal measurements from pixel units into physical units (microns and $mm^2$) according to the unique pixel length-scale each B-scan corresponds to, so that measurements across the population could be compared more appropriately. Moreover,

medRxiv preprint doi: https://doi.org/10.1101/2024.08.27.24312649; this version posted August 28, 2024. The copyright holder for this preprint (which was not certified by peer review) is the author/funder, who has granted medRxiv a license to display the preprint in perpetuity.
All rights reserved. No reuse allowed without permission.


the average participant age in the Ma study was around 20 years older than ours, suggesting that age differences may also play a role in the contrasting findings.

Enhanced-depth OCT has previously been used to investigate the link between diagnosed dementia and the choroid, with mixed results. Some have found *reduced* choroidal measurements in Alzheimer's disease and MCI compared to controls.[15–17,20] Bulut et al.,[17] and Gharbiya, et al.[16] showed significant choroidal thinning in Alzheimer's disease, but selected both eyes per participant for their statistical analyses without accounting for intra-participant correlation, violating a core statistical principle. Moreover, Gharbiya et al.,[16] and Bayhan et al.,[15] analysed smaller cohorts and performed measurement of the choroid manually, which has the potential for measurement error, and may be difficult to reproduce.[43] Recently, Kwapong et al.,[20] found reduced choriocapillaris density in OCT-Angiography imaging of early-age onset Alzheimer's disease patients compared with healthy controls, and was able to discriminate between such groups. However, compared to the *PREVENT Dementia study*, the Kwapong et al,.[20] cohort was older and already presenting with symptoms sufficient for clinical diagnosis– whether the same approach can be leveraged at the preclinical stage of Alzheimer's disease still requires further validation.

Other works observed *increased* choroidal measurements in Alzheimer's disease.[18,19] Asanad et al.,[18] observed increased choroidal thickness from post mortem human tissue in eight Alzheimer's disease patients relative to eleven controls using histopathology, while Robbins et al.,[19] found increased choroidal area and vessel area in Alzheimer's disease compared with controls in enhanced-depth OCT. However, these measurements were reported in pixel space. Moreover, the authors observed significantly decreased choroidal thickness in their sample, but these distances were measured without accounting for potential choroidal curvature. Thus, where our results fit into the disease trajectory of Alzheimer's disease is yet to be determined.

medRxiv preprint doi: https://doi.org/10.1101/2024.08.27.24312649; this version posted August 28, 2024. The copyright holder for this preprint (which was not certified by peer review) is the author/funder, who has granted medRxiv a license to display the preprint in perpetuity.
All rights reserved. No reuse allowed without permission.


In this exploratory study of asymptomatic people at risk of Alzheimer's disease, we observed trends which, independent of covariates, indicate an increased retinal choroid vasculature in participants who carry the APOE4 genotype or have a family history of dementia, relative to those who do not. This reached statistical significance in choroid vessel area and choroid area. However, subfoveal thickness is less robust in characterizing the choroid than area, and the relationship between vascular index and vessel area/choroid area likely played a role in any significant, distributional differences observed between groups (Supplementary Material: *Interplay of choroidal measurements).*

Furthermore, measurement error and diurnal variation are unlikely to have had a major effect on our results. The differences in mean choroid measurements between APOE4 carriers and non-carriers (thickness, 53 microns; area, 0.19 $mm^2$; vascular index, 0.05; and vessel area, 0.15 $mm^2$), were greater than expected from approximate choroidal fluctuation due to diurnal variation, (thickness, 30 microns; area, 0.035 $mm^2$; vascular index, 0.015; vessel area, 0.02 $mm^2$),[44–48] the threshold reported on Choroidalyzer's reproducibility for choroidal analysis on single-line OCT B-scans (thickness, 11.5 microns; area, 0.05 $mm^2$; vascular index, 0.013).[49] This was also the case for individuals with and without a family history of dementia (Table 3).

The ordinal models give us an indication of the size of the observed associations found in our sample and can be easily interpreted. For example, consider two males of equal age, with the same blood pressure. If the first male's choroidal vascular tissue was greater in area by at least 0.16 $mm^2$, they are on average over two times more likely to have at least one (or both) of the risk markers, assuming the comparative individual had no genetic markers, thus placing them in a higher risk group for developing later life dementia. Whether this effect exists within the general population should be investigated in cohorts designed to test this hypothesis.

medRxiv preprint doi: https://doi.org/10.1101/2024.08.27.24312649; this version posted August 28, 2024. The copyright holder for this preprint (which was not certified by peer review) is the author/funder, who has granted medRxiv a license to display the preprint in perpetuity.
All rights reserved. No reuse allowed without permission.


Strengths of the current study include the use of novel, reproducible and fully automatic software,[29] to extract measurements from the choroidal vasculature using a standardised region of interest. Further, the software reports values in physical units rather than pixel units, aiding interpretability and helping mitigate spurious associations.[24] Another strength is the uniqueness of the PREVENT cohort, which permits characterisation of the cerebral and ocular microvasculature in asymptomatic individuals, at increased genetic risk, and around 20 years younger than most individuals in similar studies.

There were some limitations to this study. Statistical analysis was limited by low power due to small sample size and we cannot be certain that selection bias did not play a role in our results. Lower sample size also prevented the use of mixed models, which can account for the nested structure of eyes within participants. Low sample size also limited the number of covariates. Additionally, participants were primarily white in ethnicity, therefore, generalizability of our findings to other ethnic groups or the wider population may be limited. Thus, while our associations could relate to mechanistic links between the choroid microcirculation and pathogenesis of Alzheimer's disease, more research is needed. However, the PREVENT Dementia study is ongoing, collecting longitudinal data on this mid-life cohort, allowing future temporal modelling that may further validate our findings.

## Conclusion

We found that the retinal choroidal vasculature was significantly larger in individuals who were both APOE4 carriers and had a family history of dementia, compared to those with one risk factor or none.

## Acknowledgements

The PREVENT dementia Programme is funded by the Alzheimer's Society (grant numbers 178, 264 and 329), Alzheimer's Association (grant number TriBEKa-17-519007) and philanthropic donations.

medRxiv preprint doi: https://doi.org/10.1101/2024.08.27.24312649; this version posted August 28, 2024. The copyright holder for this preprint (which was not certified by peer review) is the author/funder, who has granted medRxiv a license to display the preprint in perpetuity.
All rights reserved. No reuse allowed without permission.


This work was supported by the Alzheimer's Drug Discovery Foundation (project no. GDAPB-201808-2016196, "Delivering novel neuro-retinal biomarkers for the early diagnosis of Alzheimer's disease"); NHS Lothian R&D; and British Heart Foundation Centre for Research Excellence Award III (RE/18/5/34216). The funding sources were not involved in designing, conducting, or submitting this work. We would like to acknowledge with special thanks to the PREVENT participants, the participant panel, members of the Scientific Advisory Committee, and funders for their support of the PREVENT dementia programme.

J.B. was supported by the Medical Research Council (grant MR/N013166/1) as part of the Doctoral Training Programme in Precision Medicine at the Usher Institute, University of Edinburgh. S.G. was supported by the UK Biotechnology and Biological Sciences Research Council as part of the EASTBIO Doctoral Training Programme at the University of Edinburgh [grant number: BB/M010996/1].

## Declaration

The PREVENT Dementia programme received multi-site ethical approval from the UK London-Camberwell St Giles National Health Service (NHS) Research Ethics Committee (REC reference: 12/LO/1023, IRAS project ID: 88938), which operates according to the Helsinki Declaration of 1975 (and as revised in 1983). All substantial protocol amendments have been reviewed by the same ethics committees and favourable opinion was granted before implementation at sites. The retinal sub study in Edinburgh was approved by the South East Scotland Research Ethics Committee (15/SS/0146)

## Data availability

The PREVENT dataset is available to access through a data request on the study website (www.preventdementia.co.uk); on the Alzheimer's Disease Data Initiative (ADDI) platform baseline dataset DOI: https://doi.org/10.34688/PREVENTMAIN_BASELINE_700V1; Dementia Platforms UK (DPUK); and the Global Alzheimer's Association Network (GAAIN).

## References

medRxiv preprint doi: https://doi.org/10.1101/2024.08.27.24312649; this version posted August 28, 2024. The copyright holder for this preprint (which was not certified by peer review) is the author/funder, who has granted medRxiv a license to display the preprint in perpetuity.
All rights reserved. No reuse allowed without permission.


1. Chan VTT, Sun Z, Tang S, et al. Spectral-Domain OCT Measurements in Alzheimer's Disease: A Systematic Review and Meta-analysis. *Ophthalmology*. 2019;126(4):497-510. doi:10.1016/j.ophtha.2018.08.009

2. Livingston G, Huntley J, Sommerlad A, et al. Dementia prevention, intervention, and care: 2020 report of the Lancet Commission. *The Lancet*. 2020;396(10248):413-446. doi:10.1016/S0140-6736(20)30367-6

3. Spaide RF, Koizumi H, Pozonni MC. Enhanced Depth Imaging Spectral-Domain Optical Coherence Tomography. *Am J Ophthalmol*. 2008;146(4):496-500. doi:10.1016/j.ajo.2008.05.032

4. Nickla DL, Wallman J. THE MULTIFUNCTIONAL CHOROID. *Prog Retin Eye Res*. 2010;29(2):144-168. doi:10.1016/j.preteyeres.2009.12.002

5. Villa C. Ocular Vascular Changes: Choroidal Thickness as an Early Biomarker for Alzheimer's Disease? *J Pers Med*. 2021;11(12):1365. doi:10.3390/jpm11121365

6. Martín ESG, Ramírez JM, Rojas B, et al. Glia and blood retinal barrier: effects of ocular hypertension. In: *Cardiovascular Disease II*. iConcept Press Ltd; 2014:123-162. Accessed June 19, 2024. https://produccioncientifica.ucm.es/documentos/638e0f432558037fa43f9615?lang=en

7. Reiner A, Fitzgerald MEC, Del Mar N, Li C. Neural control of choroidal blood flow. *Prog Retin Eye Res*. 2018;64:96-130. doi:10.1016/j.preteyeres.2017.12.001

8. Collins O, Dillon S, Finucane C, Lawlor B, Kenny RA. Parasympathetic autonomic dysfunction is common in mild cognitive impairment. *Neurobiol Aging*. 2012;33(10):2324-2333. doi:10.1016/j.neurobiolaging.2011.11.017

9. Beishon LC, Hosford P, Gurung D, et al. The role of the autonomic nervous system in cerebral blood flow regulation in dementia: A review. *Auton Neurosci*. 2022;240:102985. doi:10.1016/j.autneu.2022.102985

10. Steiner M, Esteban-Ortega M del M, Muñoz-Fernández S. Choroidal and retinal thickness in systemic autoimmune and inflammatory diseases: A review. *Surv Ophthalmol*. 2019;64(6):757-769. doi:10.1016/j.survophthal.2019.04.007

11. Andrade C, Beato J, Monteiro A, et al. Spectral-Domain Optical Coherence Tomography as a Potential Biomarker in Huntington's Disease. *Mov Disord*. 2016;31(3):377-383. doi:10.1002/mds.26486

12. Garcia-Martin E, Jarauta L, Pablo LE, et al. Changes in peripapillary choroidal thickness in patients with multiple sclerosis. *Acta Ophthalmol (Copenh)*. 2019;97(1):e77-e83. doi:10.1111/aos.13807

13. Robbins CB, Thompson AC, Bhullar PK, et al. Characterization of Retinal Microvascular and Choroidal Structural Changes in Parkinson Disease. *JAMA Ophthalmol*. 2021;139(2):182-188. doi:10.1001/jamaophthalmol.2020.5730

14. Cunha JP, Proença R, Dias-Santos A, et al. Choroidal thinning: Alzheimer's disease and aging. *Alzheimers Dement Diagn Assess Dis Monit*. 2017;8:11-17. doi:10.1016/j.dadm.2017.03.004

15. Bayhan HA, Aslan Bayhan S, Celikbilek A, Tanık N, Gürdal C. Evaluation of the chorioretinal thickness changes in Alzheimer's disease using spectral-domain optical coherence tomography. *Clin Experiment Ophthalmol*. 2015;43(2):145-151. doi:10.1111/ceo.12386

medRxiv preprint doi: https://doi.org/10.1101/2024.08.27.24312649; this version posted August 28, 2024. The copyright holder for this preprint (which was not certified by peer review) is the author/funder, who has granted medRxiv a license to display the preprint in perpetuity.
All rights reserved. No reuse allowed without permission.


16. Gharbiya M, Trebbastoni A, Parisi F, et al. Choroidal thinning as a new finding in Alzheimer's disease: evidence from enhanced depth imaging spectral domain optical coherence tomography. *J Alzheimers Dis JAD*. 2014;40(4):907-917. doi:10.3233/JAD-132039

17. Bulut M, Yaman A, Erol MK, et al. Choroidal Thickness in Patients with Mild Cognitive Impairment and Alzheimer's Type Dementia. *J Ophthalmol*. 2016;2016:7291257. doi:10.1155/2016/7291257

18. Asanad S, Ross-Cisneros FN, Barron E, et al. The retinal choroid as an oculovascular biomarker for Alzheimer's dementia: A histopathological study in severe disease. *Alzheimers Dement Diagn Assess Dis Monit*. 2019;11:775-783. doi:10.1016/j.dadm.2019.08.005

19. Robbins CB, Grewal DS, Thompson AC, et al. Choroidal Structural Analysis in Alzheimer Disease, Mild Cognitive Impairment, and Cognitively Healthy Controls. *Am J Ophthalmol*. 2021;223:359-367. doi:10.1016/j.ajo.2020.09.049

20. Kwapong WR, Tang F, Liu P, et al. Choriocapillaris reduction accurately discriminates against early-onset Alzheimer's disease. *Alzheimers Dement*. 2024;20(6):4185-4198. doi:10.1002/alz.13871

21. Scarabino D, Gambina G, Broggio E, Pelliccia F, Corbo RM. Influence of family history of dementia in the development and progression of late-onset Alzheimer's disease. *Am J Med Genet Part B Neuropsychiatr Genet Off Publ Int Soc Psychiatr Genet*. 2016;171B(2):250-256. doi:10.1002/ajmg.b.32399

22. Mak E, Dounavi ME, Low A, et al. Proximity to dementia onset and multi-modal neuroimaging changes: The prevent-dementia study. *NeuroImage*. 2021;229(January). doi:10.1016/j.neuroimage.2021.117749

23. Stocker H, Perna L, Weigl K, et al. Prediction of clinical diagnosis of Alzheimer's disease, vascular, mixed, and all-cause dementia by a polygenic risk score and APOE status in a community-based cohort prospectively followed over 17 years. *Mol Psychiatry*. 2021;26(10):5812-5822. doi:10.1038/s41380-020-0764-y

24. Ma JP, Robbins CB, Lee JM, et al. Longitudinal analysis of the retina and choroid in cognitively normal individuals at higher genetic risk for Alzheimer disease. *Ophthalmol Retina*. 2022;6(7):607-619. doi:10.1016/j.oret.2022.03.001

25. Ritchie CW, Ritchie K. The PREVENT study: a prospective cohort study to identify mid-life biomarkers of late-onset Alzheimer's disease. *BMJ Open*. 2012;2(6):e001893. doi:10.1136/bmjopen-2012-001893

26. Gibbon S, Low A, Hamid C, et al. Association of optic disc pallor and RNFL thickness with cerebral small vessel disease in the PREVENT-Dementia study. *Alzheimers Dement Diagn Assess Dis Monit*. 2024;16(3):e12633. doi:10.1002/dad2.12633

27. Ritchie CW, Bridgeman K, Gregory S, et al. The PREVENT dementia programme: baseline demographic, lifestyle, imaging and cognitive data from a midlife cohort study investigating risk factors for dementia. *Brain Commun*. 2024;6(3):fcae189. doi:10.1093/braincomms/fcae189

28. Tewarie P, Balk L, Costello F, et al. The OSCAR-IB consensus criteria for retinal OCT quality assessment. *PloS One*. 2012;7(4):e34823. doi:10.1371/journal.pone.0034823

medRxiv preprint doi: https://doi.org/10.1101/2024.08.27.24312649; this version posted August 28, 2024. The copyright holder for this preprint (which was not certified by peer review) is the author/funder, who has granted medRxiv a license to display the preprint in perpetuity.
All rights reserved. No reuse allowed without permission.


29. Choroidalyzer: An Open-Source, End-to-End Pipeline for Choroidal Analysis in Optical Coherence Tomography | IOVS | ARVO Journals. Accessed June 20, 2024. https://iovs.arvojournals.org/article.aspx?articleid=2793719

30. Early Treatment Diabetic Retinopathy Study Design and Baseline Patient Characteristics: ETDRS Report Number 7. *Ophthalmology*. 1991;98(5, Supplement):741-756. doi:10.1016/S0161-6420(13)38009-9

31. Polak K, Polska E, Luksch A, et al. Choroidal blood flow and arterial blood pressure. *Eye*. 2003;17(1):84-88. doi:10.1038/sj.eye.6700246

32. Sansom LT, Suter CA, McKibbin M. The association between systolic blood pressure, ocular perfusion pressure and subfoveal choroidal thickness in normal individuals. *Acta Ophthalmol (Copenh)*. 2016;94(2):e157-158. doi:10.1111/aos.12794

33. Waghamare SR, Mittal S, Pathania M, et al. Comparison of choroidal thickness in systemic hypertensive subjects with healthy individuals by spectral domain optical coherence tomography. *Indian J Ophthalmol*. 2021;69(5):1183-1188. doi:10.4103/ijo.IJO_1994_20

34. Lu J, Zhou H, Shi Y, et al. Interocular asymmetry of choroidal thickness and vascularity index measurements in normal eyes assessed by swept-source optical coherence tomography. *Quant Imaging Med Surg*. 2022;12(1):781. doi:10.21037/qims-21-813

35. Engineering H. *SPECTRALIS Product Family User Manual Sw Ver 7.0*. Version 7.; 2022.

36. Liu Y, Wang L, Xu Y, Pang Z, Mu G. The influence of the choroid on the onset and development of myopia: from perspectives of choroidal thickness and blood flow. *Acta Ophthalmol (Copenh)*. 2021;99(7):730-738. doi:10.1111/aos.14773

37. López-Cuenca I, Sánchez-Puebla L, Salobrar-García E, et al. Exploratory Longitudinal Study of Ocular Structural and Visual Functional Changes in Subjects at High Genetic Risk of Developing Alzheimer's Disease. *Biomedicines*. 2023;11(7):2024. doi:10.3390/biomedicines11072024

38. Lahoz C, Schaefer EJ, Cupples LA, et al. Apolipoprotein E genotype and cardiovascular disease in the Framingham Heart Study. *Atherosclerosis*. 2001;154(3):529-537. doi:10.1016/S0021-9150(00)00570-0

39. Montagne A, Nation DA, Sagare AP, et al. APOE4 leads to blood–brain barrier dysfunction predicting cognitive decline. *Nature*. 2020;581(7806):71-76. doi:10.1038/s41586-020-2247-3

40. Tao Q, Ang TFA, DeCarli C, et al. Association of Chronic Low-grade Inflammation With Risk of Alzheimer Disease in ApoE4 Carriers. *JAMA Netw Open*. 2018;1(6):e183597. doi:10.1001/jamanetworkopen.2018.3597

41. Lohman T, Kapoor A, Engstrom AC, et al. Central autonomic network dysfunction and plasma Alzheimer's disease biomarkers in older adults. *Alzheimers Res Ther*. 2024;16(1):124. doi:10.1186/s13195-024-01486-9

42. Lohman T, Sible I, Kapoor A, et al. Blood Pressure Variability, Central Autonomic Network Dysfunction, and Cerebral Small-Vessel Disease in APOE4 Carriers. *J Am Heart Assoc*. 2024;13(9):e034116. doi:10.1161/JAHA.123.034116

medRxiv preprint doi: https://doi.org/10.1101/2024.08.27.24312649; this version posted August 28, 2024. The copyright holder for this preprint (which was not certified by peer review) is the author/funder, who has granted medRxiv a license to display the preprint in perpetuity.
All rights reserved. No reuse allowed without permission.


43. Rahman W, Chen FK, Yeoh J, Patel P, Tufail A, Da Cruz L. Repeatability of Manual Subfoveal Choroidal Thickness Measurements in Healthy Subjects Using the Technique of Enhanced Depth Imaging Optical Coherence Tomography. *Invest Ophthalmol Vis Sci*. 2011;52(5):2267-2271. doi:10.1167/iovs.10-6024

44. Chakraborty R, Read SA, Collins MJ. Diurnal Variations in Axial Length, Choroidal Thickness, Intraocular Pressure, and Ocular Biometrics. *Invest Ophthalmol Vis Sci*. 2011;52(8):5121-5129. doi:10.1167/iovs.11-7364

45. Usui S, Ikuno Y, Akiba M, et al. Circadian changes in subfoveal choroidal thickness and the relationship with circulatory factors in healthy subjects. *Invest Ophthalmol Vis Sci*. 2012;53(4):2300-2307. doi:10.1167/iovs.11-8383

46. Tan CS, Ouyang Y, Ruiz H, Sadda SR. Diurnal Variation of Choroidal Thickness in Normal, Healthy Subjects Measured by Spectral Domain Optical Coherence Tomography. *Invest Ophthalmol Vis Sci*. 2012;53(1):261-266. doi:10.1167/iovs.11-8782

47. Kinoshita T, Mitamura Y, Shinomiya K, et al. Diurnal variations in luminal and stromal areas of choroid in normal eyes. *Br J Ophthalmol*. 2017;101(3):360-364. doi:10.1136/bjophthalmol-2016-308594

48. Ostrin LA, Harb E, Nickla DL, et al. IMI—The Dynamic Choroid: New Insights, Challenges, and Potential Significance for Human Myopia. *Invest Ophthalmol Vis Sci*. 2023;64(6):4. doi:10.1167/iovs.64.6.4

49. Burke J, Engelmann J, Gibbon S, et al. OCTolyzer: Fully automatic analysis toolkit for segmentation and feature extracting in optical coherence tomography (OCT) and scanning laser ophthalmoscopy (SLO) data. Published online July 19, 2024. doi:10.48550/arXiv.2407.14128

medRxiv preprint doi: https://doi.org/10.1101/2024.08.27.24312649; this version posted August 28, 2024. The copyright holder for this preprint (which was not certified by peer review) is the author/funder, who has granted medRxiv a license to display the preprint in perpetuity.
All rights reserved. No reuse allowed without permission.



**Supplementary material** for article "*Association between choroidal microvasculature in the eye and Alzheimer's disease risk in cognitively healthy midlife adults*"

**Supplementary Table 1.** Demographics and study variables of PREVENT Dementia retinal sub-study at the Edinburgh site, stratified by risk group.

| | Overall | Included in final sample | | |
|---|---|---|---|---|
| | | No | Yes | P-Value |
| **Participants** | 224 | 155 | 69 | |
| **Age** (years) | 51.347 (5.532) | 51.255 (5.467) | 51.551 (5.707) | 0.718* |
| **Sex** (female) | 128 (57.658) | 87 (56.863) | 41 (59.420) | 0.834† |
| **Hypertension** | 23 (10.407) | 15 (9.804) | 8 (11.765) | 0.840† |
| **Blood pressure** (bpm) | 128.205 (14.733) | 127.121 (14.204) | 130.594 (15.678) | 0.119* |
| **BMI** (kg/m$^2$) | 28.892 (6.207) | 28.782 (6.415) | 29.143 (5.741) | 0.680* |
| **Smoking** | | | | 0.704† |
| Current | 10 (4.545) | 8 (5.298) | 2 (2.899) | |
| Ex | 78 (35.455) | 54 (35.762) | 24 (34.783) | |
| None | 132 (60.000) | 89 (58.940) | 43 (62.319) | |
| **Diabetes** | 8 (3.620) | 5 (3.289) | 3 (4.348) | 0.707† |
| **Risk factors** | | | | |
| APOE4 status | 89 (40.455) | 64 (42.384) | 25 (36.232) | 0.475† |
| Family History | 104 (47.489) | 69 (46.000) | 35 (50.725) | 0.614† |

**Abbreviations:** BMI (body mass index). **Notes:** All values are N (%) or Mean (standard deviation). **Missing data (number of eyes, percentage):** Sex (2, 0.01%), Age (2, 0.01%), Hypertension (3, 0.01%); Blood Pressure (3, 0.01%), BMI (4, 0.02%); Smoker (4, 0.02%), Diabetes (3, 0.01%), APOE4 (4, 0.02%) and Family History (5, 0.02\%). *, Two-sample t-test; †, Chi-squared test.

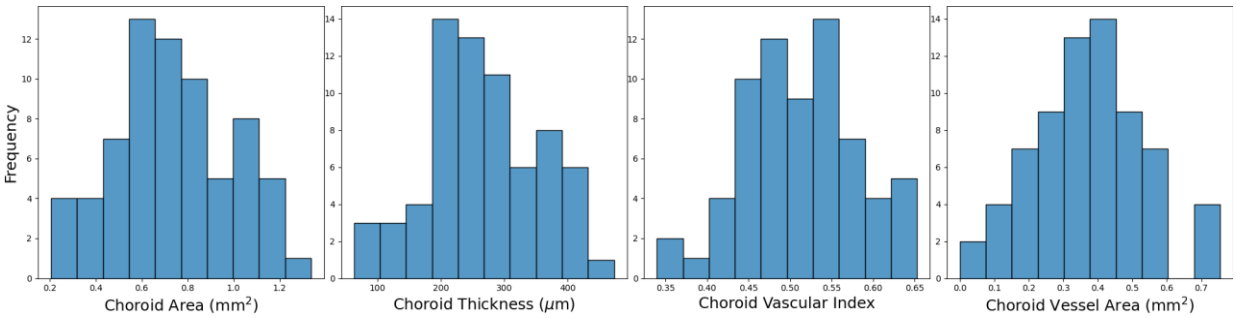


**Supplementary Figure 1.** Histogram distributions of each choroidal measure, approximately normally distributed (Shapiro-Wilks test statistic *t* (P-value) for choroid area: 0.984 (0.5); choroid thickness: 0.979 (0.309); choroid vascular index: 0.984 (0.518); choroid vessel area: 0.987 (0.721)).

medRxiv preprint doi: https://doi.org/10.1101/2024.08.27.24312649; this version posted August 28, 2024. The copyright holder for this preprint (which was not certified by peer review) is the author/funder, who has granted medRxiv a license to display the preprint in perpetuity.
All rights reserved. No reuse allowed without permission.


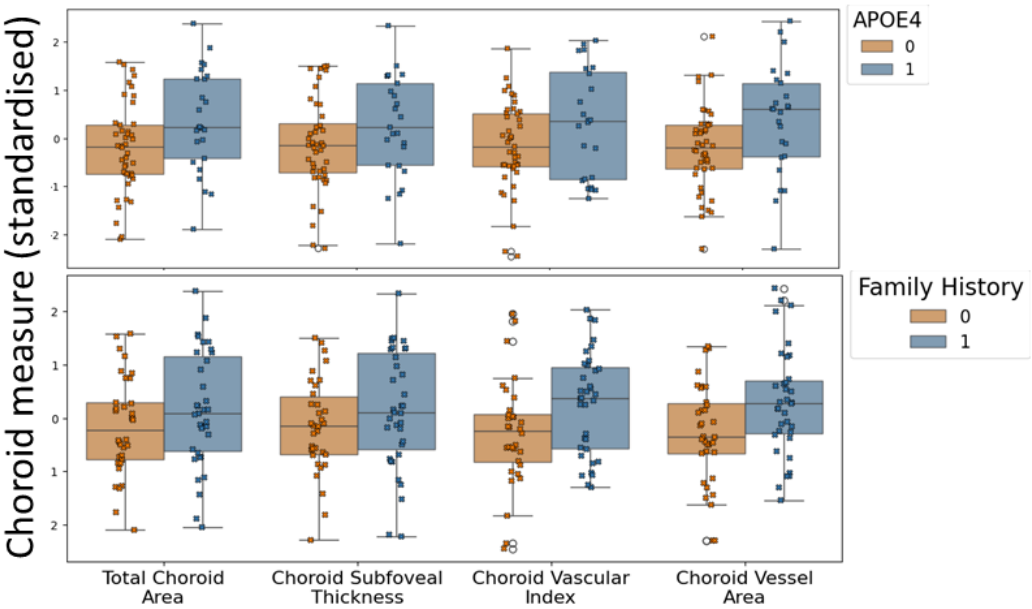


**Supplementary Figure 2.** Boxplots showing the relationship between choroidal measures and APOE e4 carrier status (A), and family history of dementia (B). Both eyes combined

*Interplay of choroidal measurements*

In this exploratory study, we observed trends which, independent of covariates, indicate an increased choroid vasculature in participants who carry the APOE4 genotype or have a family history of dementia, relative to those who do not. The trends were supported by associations which were statistically significant for all choroidal measures except for (subfoveal) choroidal thickness. Subfoveal choroid thickness is a one-dimensional point-source measurement, which we believe to be unable to characterise subtle choroidal change, particularly in the context of systemic health, relative to two-dimensional measurements such as area and vascular index.

Both choroidal area and vessel area were significantly higher in APOE4 carriers relative to non-carriers. Area and vessel area are directly and inversely proportional to choroidal vascular index (ratio of choroidal vessel area to total choroidal area), respectively,

medRxiv preprint doi: https://doi.org/10.1101/2024.08.27.24312649; this version posted August 28, 2024. The copyright holder for this preprint (which was not certified by peer review) is the author/funder, who has granted medRxiv a license to display the preprint in perpetuity.
All rights reserved. No reuse allowed without permission.


and so these two measures contribute toward estimated associations with choroidal vascular index. Thus, the increase in vascular index (mean increase of 0.03) did not reach significance likely because of the greater mean increase in region area (mean increase of 0.16 $mm^2$) relative to vessel area (mean increase of 0.1 $mm^2$).

For individuals with a family history of dementia, we observed a smaller magnitude of increase in total choroid area relative to APOE4 carriers (mean increase of 0.1 $mm^2$). Put in the context of the significant increase observed in choroidal vessel area (mean increase of 0.1 $mm^2$), this very likely contributed to the significant increase observed for vascular index (mean increase of 0.04). While these observations highlight the interplay between these representative choroidal measurements, they ultimately suggest that choroidal vessel area had the strongest signal among measurements, and that the vasculature itself was the driving factor for increased choroidal area and thickness, rather than surrounding extravascular tissue (for our sample).

*Disclosures and conflicts of interest*

Jamie Burke: None

Samuel Gibbon: None

Audrey Low: Awarded "Race Against Dementia" Fellowship in past 36 months.

Charlene Hamid: None

Megan Reid-Schachter: None

Graciela Muniz-Terrera: None

Craig W Ritchie: Founder, CEO and majority shareholder for "Scottish Brain Sciences". Received consulting fees from "Biogen", "Eisai", "mSD", "Actinogen", "Roche" and "Eli Lilly" in last 36 months. Received payment for presentation-based work by "Roche" and "Eisai" in last 36 months.

Baljean Dhillon: None

John T O'Brien: Received grant from "Avid/Lilly", "Merck" and "Alliance Medical" in last 36 months. Received consulting fees from "TauRx", "Novo Nordisk", "Biogen", "Roche", "Lilly" and "GE Healthcare" in last 36 months.

Stuart King: None

Ian J.C. MacCormick: None

Thomas J. MacGillivray: None