medRxiv preprint doi: https://doi.org/10.1101/2024.06.13.24307996; this version posted June 13, 2024. The copyright holder for this preprint (which was not certified by peer review) is the author/funder, who has granted medRxiv a license to display the preprint in perpetuity. It is made available under a CC-BY-ND 4.0 International license .

# Stage 2a IDEAL evaluation of a third-generation biocomposite suture anchor in arthroscopic rotator cuff repair: Subgroup cohort analysis of the PRULO registry with 12-month follow up

Corey Scholes[1]
Manaal Fatima[1]
Cooper Moody[2]
Kevin Eng[2,3,4]
Richard S Page[2,3,4,5]

1. EBM Analytics, Sydney, New South Wales, Australia
2. Barwon Health, Geelong, Victoria, Australia
3. Geelong Orthopaedics, Geelong, Victoria, Australia
4. Barwon Centre for Orthopaedic Research and Education (B-CORE), Deakin University, Victoria, Australia
5. St John of God Hospital, Geelong, Victoria, Australia

**Corresponding author**
Richard Page
richard.page@deakin.edu.au
Geelong Orthopaedics
Level 2/83 Myers St, Geelong VIC 3220
Australia

**NOTE: This preprint reports new research that has not been certified by peer review and should not be used to guide clinical practice.**

medRxiv preprint doi: https://doi.org/10.1101/2024.06.13.24307996; this version posted June 13, 2024. The copyright holder for this preprint (which was not certified by peer review) is the author/funder, who has granted medRxiv a license to display the preprint in perpetuity. It is made available under a CC-BY-ND 4.0 International license .


# Abstract

## Background

Poly-lactic co-glycolide with tricalcium phosphate (PLGA)/β-TCP is both bioactive and biodegradable, and is considered a third generation biomaterial for suture anchors. This study aimed to describe the incidence of adverse events and the trajectory of patient-reported outcomes up to 12 months follow up in patients undergoing rotator cuff repair with this type of anchor.

## Methods

A sub-group analysis of a prospective clinical registry embedded in an orthopaedic clinic was conducted. Patients undergoing surgery with the Healix Advance BR were identified and data on patient demographics, treatment details, complications and adverse events, as well as patient-reported outcomes (QuickDASH, WORC Index Normalised) were retrieved. Summary statistics were generated for patient characteristics and PROMs analysed using multiple imputation and a linear model to assess changes between baseline and 12 month follow up.

## Results

A consecutive cohort of 69 cases receiving the anchor of interest was included for analysis. Complications were recorded in six cases (8.7%, 95%CI 3.6 - 18.6), presenting as postoperative capsulitis/stiffness (N=3), persistent shoulder pain (N=1), a case of hemi-diaphragm palsy and a

medRxiv preprint doi: https://doi.org/10.1101/2024.06.13.24307996; this version posted June 13, 2024. The copyright holder for this preprint (which was not certified by peer review) is the author/funder, who has granted medRxiv a license to display the preprint in perpetuity. It is made available under a CC-BY-ND 4.0 International license .

case of complex regional pain syndrome in the hand. No infections or reoperations were encountered in this series. The QuickDASH scores improved significantly from 43 (IQR 34-52) preoperatively to 9 (IQR 5-23) at 12 months. WORC Index scores improved from 49 (IQR 27-61) preoperatively to 86 (IQR 57-93) at 12 months.

## Conclusion

This study found a low incidence of adverse events, no requirement for reoperation or revision and favourable recovery of patient-reported outcomes in patients treated with arthroscopic rotator cuff repair with a third-generation biocomposite suture anchor at up to 12 months follow up.

# Keywords

Rotator cuff repair; biocomposite; Poly-lactic co-glycolic acid; tricalcium phosphate; Patient-reported outcomes; IDEAL

medRxiv preprint doi: https://doi.org/10.1101/2024.06.13.24307996; this version posted June 13, 2024. The copyright holder for this preprint (which was not certified by peer review) is the author/funder, who has granted medRxiv a license to display the preprint in perpetuity. It is made available under a CC-BY-ND 4.0 International license .

# Introduction

Symptomatic tears of the rotator cuff remain a prevalent condition (Rees, 2008) and arthroscopic surgical repair is undertaken with increasing annual incidence (Colvin et al., 2012). A high risk of subsequent retear and revision arthroscopic repair persist despite advances in materials and techniques. In conventional suture anchors used for primary surgery, the incidence of revision procedures has been estimated at up to 27% (estimate 20%; 95%CI 15.3 - 26.8) (Boksh et al., 2022).

Biostable suture anchors remain popular for rotator cuff repair fixation, but have been associated with adverse events such as loosening, chondral damage, as well as interfering with revision procedures and post-operative imaging (Suroto et al., 2023). Biocomposite anchors offer advantages in rotator cuff surgery with reduced risk of suture damage in-vivo (Savage et al., 2023; Yang et al., 2023) and the replacement of bioresorbable anchors with native bone, thereby restoring anatomy (Barber et al., 2013). The absence of hardware to remove and the restoration of bone stock may reduce the complexity of subsequent revision procedures.

The concept of biodegradable anchors is well established, however there may be a role for new materials and designs to reduce cyst formation incidence (Kim et al., 2015) and improve bone integration. The results of suture anchors comprising one specific material for cuff repair is not easily discerned from the existing literature, with biodegradable materials usually combined in review papers. One systematic review (Barber et al., 2017) estimated resorption rates of at least 60% at 30 month follow up, with a low rate of imaging-detected complications. A more recent

medRxiv preprint doi: https://doi.org/10.1101/2024.06.13.24307996; this version posted June 13, 2024. The copyright holder for this preprint (which was not certified by peer review) is the author/funder, who has granted medRxiv a license to display the preprint in perpetuity. It is made available under a CC-BY-ND 4.0 International license .

systematic review (Suroto et al., 2023) reported tendon healing rates ranging from 50 - 100% in four studies of biodegradable anchors in rotator cuff repair (RCR).

Poly-lactic co-glycolic acid-coated tricalcium phosphate (PLGA)/β-TCP) is a biocomposite material explicitly developed to promote absorption at a controlled rate (Cho et al., 2021), and being both bioactive and biodegradable is considered a 3rd-generation biomaterial for suture anchors (Filip et al., 2022). A specific example is the Healix Advance BR (Mitek, Johnson and Johnson MedTech, USA; Biocryl Rapide, 30% b-tricalcium phosphate [β-TCP]/70% poly [lactide co-glycolide] [PLGA], which is a screw-in anchor with a distal bar eyelet and can be double or triple loaded with No.2 suture (Barber & Herbert, 2013). It has shown satisfactory ultimate failure load during in-vitro testing (Patzer et al., 2011), but lower failure loads during cyclic loading in both cortical and cancellous bone compared to contemporary designs comprising different materials (Barber & Herbert, 2013). Nevertheless, pain reduction and recovery of cyst formation over time has been demonstrated, with a reported retear rate of 13% at 12 month follow up (Chung et al., 2018). Equivalent patient-reported outcomes have also been reported between this suture anchor and all-suture design at up to 8 months, (Di Gennaro et al., 2022).

The information available on this anchor is encouraging but considering the IDEAL framework of surgical innovation (McCulloch et al., 2013), the evaluation of its clinical performance remains in the early stages of *idea* and *development*. Therefore, it is imperative that evidence is generated around the clinical performance of implants of this type and material. In particular, assessment in diverse populations is a priority. Institutional registries (Orthopaedics1*, 2019) offer a relatively robust framework for evaluation of innovative treatments and technologies within a variety of healthcare settings and populations (Gliklich et al., 2019). The capacity to

medRxiv preprint doi: https://doi.org/10.1101/2024.06.13.24307996; this version posted June 13, 2024. The copyright holder for this preprint (which was not certified by peer review) is the author/funder, who has granted medRxiv a license to display the preprint in perpetuity. It is made available under a CC-BY-ND 4.0 International license .

prospectively enrol patients and standardise follow up alleviates some methodological weaknesses of retrospective observational studies. Our group has emulated a quality registry in clinical practice (Scholes et al., 2023) which provides a unique platform for contributing to the evidence base of this biodegradable anchor in a diverse population.

This paper presents a Stage 2a IDEAL (McCulloch et al., 2013) evaluation of a third-generation biocomposite suture anchor in a registry sub-analysis of patients presenting with repairable rotator cuff tear for arthroscopic repair in a regional practice, describing the incidence of all-cause failures, adverse events and the trajectory of patient-reported outcomes at up to 12 months follow up.

# Methods

## Study Design

Retrospective sub-group analysis of a prospective clinical registry embedded in a regional, orthopaedic clinic.

## Setting

Data was retrieved from a multi-cohort, prospective observational, clinical quality registry. The Patient Registry of Upper Limb pathology Outcomes (PRULO) is a single-centre study involving three clinician investigators, collating clinical data and patient-reported outcomes for patients presenting to a specialist orthopaedic clinic with upper limb pathology (Scholes et al., 2023).

medRxiv preprint doi: https://doi.org/10.1101/2024.06.13.24307996; this version posted June 13, 2024. The copyright holder for this preprint (which was not certified by peer review) is the author/funder, who has granted medRxiv a license to display the preprint in perpetuity. It is made available under a CC-BY-ND 4.0 International license .

## Registration and Ethics

Ethical approval for PRULO was obtained from the Barwon Health Research Ethics Committee (Project ID 49184, Reference 19/70), and the registry is listed on the Australian New Zealand Clinical Trials Registry (ACTRN12619000770167).

## Patient Selection

Patients were included in the PRULO registry as per the registry inclusion and exclusion criteria (Scholes et al., 2023). A cohort of patients undergoing rotator cuff repair surgery with the anchor material of interest were identified by cross-matching product stock keeping units (SKU), with packaging information retained in surgery (Supplementary 1). Patients were included in the analysis irrespective of patient or tear characteristics.

## Surgical Technique and Perioperative Management

The present series of cases was performed by a single surgeon. All cases involved an arthroscopic rotator cuff repair (ARCR), performed with double row transosseous equivalent repairs in the beach chair position. The anchor of interest (Healix Advance BR, Depuy-Mitek) was utilised with a self-tensioning suture (Dynacord, Depuy-Mitek) and free suture was used when margin convergence was performed. Adjunct procedures included tenodesis or tenotomy of the long head biceps proximal tendon, limited subacromial decompression and lateral clavicle resection in some cases. Postoperative recovery involved shoulder immobilisation for four weeks and elbow and hand physiotherapy from day one. Shoulder motion was restricted to passive assisted for the next four weeks, and increased to active assisted range of motion from

medRxiv preprint doi: https://doi.org/10.1101/2024.06.13.24307996; this version posted June 13, 2024. The copyright holder for this preprint (which was not certified by peer review) is the author/funder, who has granted medRxiv a license to display the preprint in perpetuity. It is made available under a CC-BY-ND 4.0 International license .

8-12 weeks, with isometric exercises at 8 weeks and strengthening exercises added at 12 weeks.

## Outcomes

Variables collected in the PRULO registry span patient data, clinical and treatment data, and outcomes data including patient-reported outcome measures (Scholes et al., 2023). Variables retrieved to address the study aims (see Supplementary 1) included:

- Patient demographics (age, sex, body mass index (BMI), hand dominance)
- Treatment details (bilateral procedures, tear characteristics)
- Complications and adverse events. The IDEAL framework identifies scope and severity of complications as common items for which agreed standard definitions are required across the international surgical community (McCulloch et al., 2013). Since then, substantial work has been conducted to standardise complication reporting after ARCR (Audigé et al., 2016) and a modification of the Sink severity grading (Sink et al., 2012) specific for rotator cuff surgery (Felsch et al., 2021) was used to grade each instance of complication.
- Procedure survival, with treatment failure classified as a revision of the original procedure
- Patient-reported outcomes (Quick Disabilities of the Arm, Shoulder and Hand (QuickDASH) questionnaire and the Western Ontario Rotator Cuff (WORC) Index)
    - The QuickDASH was calculated according to the developer's user manual (Institute for Work & Health, n.d.)
    - The WORC Index (Normalised) was calculated according to (Kirkley et al., 2003).

medRxiv preprint doi: https://doi.org/10.1101/2024.06.13.24307996; this version posted June 13, 2024. The copyright holder for this preprint (which was not certified by peer review) is the author/funder, who has granted medRxiv a license to display the preprint in perpetuity. It is made available under a CC-BY-ND 4.0 International license .

- One question response (Physical Q3 - *How much weakness do you experience in your shoulder?*) was analysed in isolation.

## Statistical Analysis

Descriptives for continuous variables of patient characteristics were reported using medians and interquartile ranges, counts and proportions were reported categorical variables. If multiple complications were retrieved for each treatment, they were recorded when they presented and descriptive statistics generated for all complications observed. For procedure survival, duration (surgery date to *enddate*) was summarised with mean and standard deviation and visualised with ridge plots using a distribution plotting package *ggdist* (Kay, 2023). A Kaplan-Meier survival curve (with 95% confidence intervals) with procedure *failure* as the event of interest was created with the *survival* package and plotted using *ggsurvfit*. A linear model was applied to each imputed dataset for QuickDASH and WORC Index, with *Timepoint* as the primary predictor and *Age at surgery* and *Sex* included as covariates. The results from each model were pooled in the *gtsummary* package for presentation including coefficients, 95% confidence intervals and p-values. P-values for Sex and Timepoint were reported for comparisons against a reference level. The *marginaleffects* package was used to calculate pooled predictions for the PROMs based on the linear models across the multiple-imputed datasets (Arel-Bundock, 2023) and plotted across *Timepoint*. Further details can be found in Supplementary 1.

medRxiv preprint doi: https://doi.org/10.1101/2024.06.13.24307996; this version posted June 13, 2024. The copyright holder for this preprint (which was not certified by peer review) is the author/funder, who has granted medRxiv a license to display the preprint in perpetuity. It is made available under a CC-BY-ND 4.0 International license .

# Results

## Patient characteristics

A sample of 916 cases electing to undergo surgery within the registry were assessed for eligibility, with 69 receiving surgery with the anchor of interest included in the final analysis. There were no withdrawals of consent from the registry, one case was excluded from PROMs followup due to enrollment in an externally conducted randomised trial. Compliance with PROMs was 51.7% at 12 months for QDASH and 43.1% for WORC (Supplementary 1). The analysis cohort comprised 25% females, had a mean age of 60 years (IQR 51-65) and a mean body mass index (BMI) of 26 (IQR 25-30). Surgery was performed on the dominant side for 58% of patients, and 10% of the cohort underwent sequential bilateral procedures. The majority of patients (98%) presented with a full tear (Table 2).

Table 1: Summary of pre-operative patient characteristics for the cohort

| Characteristic | N | Summary | 95% CI[1] |
|---|---|---|---|
| Age at Surgery, Mean (SD) | 69 | 61 (9) | 59 - 63 |
| Female, % (n) | 69 | 32% (22) | 21 - 44 |
| Non-dominant, % (n) | 66 | 39% (26) | 28 - 52 |
| Surgeon, % (n) | 69 | | |
| A | | 1.4% (1) | 0.08 - 8.9 |
| B | | 99% (68) | 91 - 100 |
| Body Mass Index, Mean (SD) | 26 | 23 (14) | 18 - 29 |
| Bilateral, % (n) | 69 | 16% (11) | 8.6 - 27 |

medRxiv preprint doi: https://doi.org/10.1101/2024.06.13.24307996; this version posted June 13, 2024. The copyright holder for this preprint (which was not certified by peer review) is the author/funder, who has granted medRxiv a license to display the preprint in perpetuity. It is made available under a CC-BY-ND 4.0 International license .

| | | | |
|---|---|---|---|
| Exam to surgery delay (weeks), Mean (SD) | 69 | 10 (10) | 7.7 - 13 |
| Insurance Type, % (n) | 34 | | |
| DVA[2] | | 2.9% (1) | 0.15 - 17 |
| Private | | 88% (30) | 72 - 96 |
| TAC[3] | | 2.9% (1) | 0.15 - 17 |
| Uninsured | | 5.9% (2) | 1.0 - 21 |

[1]CI = Confidence Interval; [2]DVA = Department of Veterans Affairs; [3]TAC = Transport Accident Commission

Table 2: Summary of pathology characteristics for the cohort

| **Characteristic** | **Available Sample** | **Summary Statistic** | **95% CI[1]** |
|---|---|---|---|
| Primary Presentation, % (n) | 69 | 100% (69) | 93 - 100 |
| Full Tear, % (n) | 64 | 98% (63) | 90 - 100 |
| Fatty Infiltration, % (n) | 64 | | |
| 0 | | 11% (7) | 4.9 - 22 |
| 1 | | 52% (33) | 39 - 64 |
| 2 | | 33% (21) | 22 - 46 |
| 3 | | 4.7% (3) | 1.2 - 14 |
| Tendon Retraction[2], % (n) | 64 | | |
| I | | 33% (21) | 22 - 46 |
| II | | 44% (28) | 32 - 57 |
| III | | 20% (13) | 12 - 33 |
| IV | | 3.1% (2) | 0.54 - 12 |
| Tendon Delamination, % (n) | 64 | 72% (46) | 59 - 82 |
| Tendons Involved (+Supraspinatus), % (n) | 64 | | |
| Infraspinatus | | 22% (14) | 13 - 34 |

medRxiv preprint doi: https://doi.org/10.1101/2024.06.13.24307996; this version posted June 13, 2024. The copyright holder for this preprint (which was not certified by peer review) is the author/funder, who has granted medRxiv a license to display the preprint in perpetuity. It is made available under a CC-BY-ND 4.0 International license .

| | | | |
|---|---|---|---|
| Infraspinatus; Subscapularis | | 11% (7) | 4.9 - 22 |
| Infraspinatus; Teres Minor; Subscapularis | | 1.6% (1) | 0.08 - 9.5 |
| Subscapularis | | 13% (8) | 5.9 - 24 |
| Subscapularis (isolated) | | 16% (10) | 8.1 - 27 |
| Supraspinatus (isolated) | | 38% (24) | 26 - 51 |
| Tear Size AP (mm), Mean (SD) | 63 | 24 (11) | 21 - 27 |
| Tear Size ML (mm), Mean (SD) | 64 | 20 (9) | 17 - 22 |
| Tear Area (mm^2), Mean (SD) | 63 | 548 (584) | 401 - 695 |
| Tear Classification[3], % (n) | 63 | | |
| Large | | 16% (10) | 8.3 - 28 |
| Massive | | 3.2% (2) | 0.55 - 12 |
| Medium | | 76% (48) | 64 - 86 |
| Partial | | 1.6% (1) | 0.08 - 9.7 |
| Small | | 3.2% (2) | 0.55 - 12 |
| Tear Pattern, % (n) | 64 | | |
| Crescent | | 48% (31) | 36 - 61 |
| L | | 17% (11) | 9.3 - 29 |
| Reverse L | | 14% (9) | 7.0 - 26 |
| U | | 17% (11) | 9.3 - 29 |
| V | | 3.1% (2) | 0.54 - 12 |
| Other Pathology, % (n) | 47 | 43% (20) | 29 - 58 |

[1] CI = Confidence Interval

[2] Modified Patte Grading (Lädermann et al., 2016)

[3] Tear classification (Rashid et al., 2017)

medRxiv preprint doi: https://doi.org/10.1101/2024.06.13.24307996; this version posted June 13, 2024. The copyright holder for this preprint (which was not certified by peer review) is the author/funder, who has granted medRxiv a license to display the preprint in perpetuity. It is made available under a CC-BY-ND 4.0 International license .

# Complications and Treatment Survival

There were no intraoperative adverse events, or any instances of explantation of the anchor. Postoperative complications were reported in six cases (overall incidence of 9.8%, 95%CI 4.1 - 20.9). Three cases presented with capsulitis - progressive pain and stiffness at 8 or 21 weeks after surgery (Sink grade I) and one receiving a corticosteroid injection (Sink grade II). One of these cases displayed signs of adhesive capsulitis at the time of surgery. One case suffered from transient phrenic nerve palsy suspected to be due to a local anaesthetic interscalene block prior to the repair procedure (Sink grade II). One case re-presented with complex regional pain syndrome in the ipsilateral limb at 16 weeks follow-up, while one case presented with persistent post-surgical pain at 16 weeks follow-up (Sink grade I). No infections or inflammatory reactions were observed in this series. No reoperation procedures were performed during the duration of follow-up, and no treatment failures were observed.

# Patient-reported outcomes

## Quick Disabilities of the Arm, Shoulder and Hand questionnaire

The model-predicted QuickDASH improved significantly from baseline to 12 month follow up (Table 3). QuickDASH scores for the cohort were 43 (IQR 34-52) preoperatively, 32 (IQR 14-45) at three months, 18 (IQR 5-30) at six months and 9 (IQR 5-23) at 12 months. Average scores improved over the 12 months following surgery, and the distribution of scores revealed different trajectories of recovery for the patients, with the majority responding well to treatment (Figure 2).

medRxiv preprint doi: https://doi.org/10.1101/2024.06.13.24307996; this version posted June 13, 2024. The copyright holder for this preprint (which was not certified by peer review) is the author/funder, who has granted medRxiv a license to display the preprint in perpetuity. It is made available under a CC-BY-ND 4.0 International license .

Table 3: Summary of model of QuickDASH after multiple imputation

| Characteristic | Beta | 95% CI[1] | p-value |
|---|---|---|---|
| TimePoint | | | |
| Preop | — | — | |
| 3months | -12.19 | -18.23, -6.15 | <0.001 |
| 6months | -25.57 | -32.24, -18.89 | <0.001 |
| 12months | -32.32 | -38.65, -25.98 | <0.001 |
| Age at Surgery | -0.02 | -0.42, 0.38 | 0.915 |
| Male vs Female | -9.07 | -17.07, -1.08 | 0.027 |

[1] CI = Confidence Interval

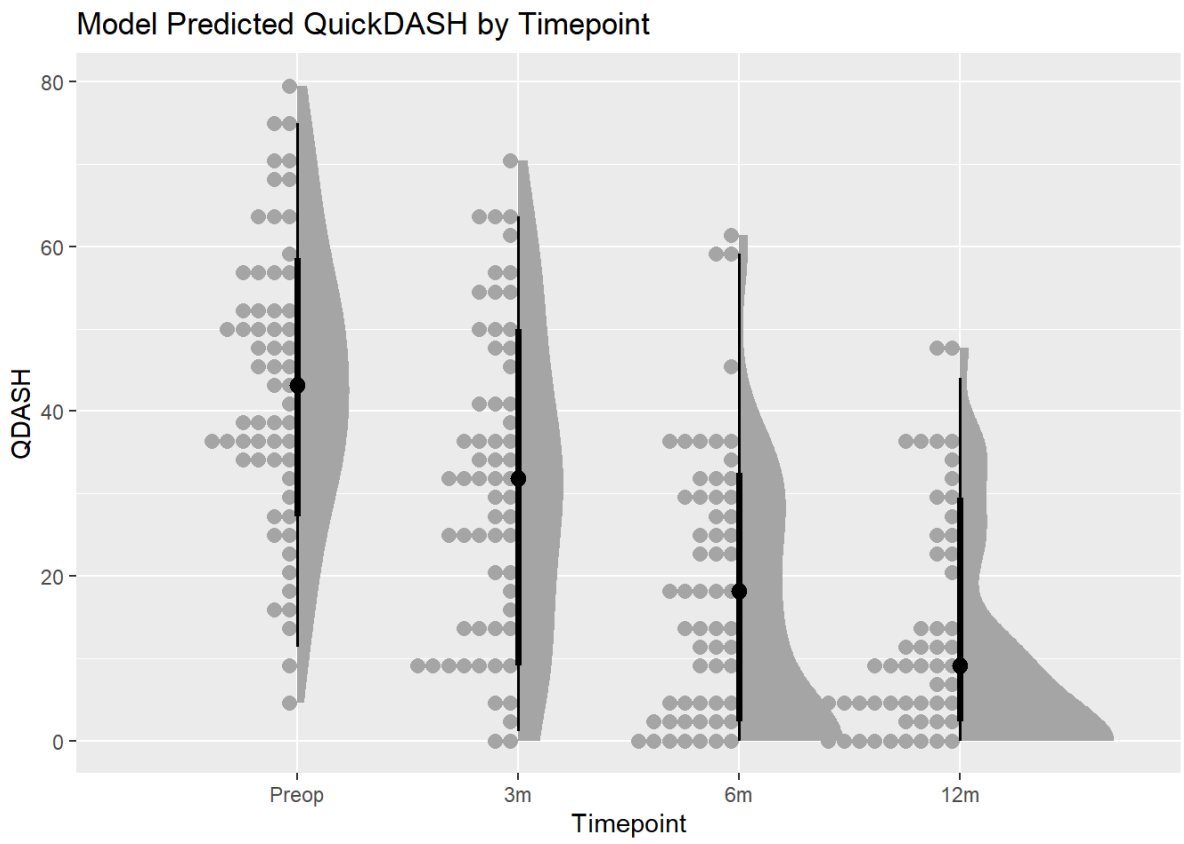


Figure 2: Change in distribution over time for imputed QuickDASH (age and sex adjusted) with median and interquartile ranges (black dot and solid line)

medRxiv preprint doi: https://doi.org/10.1101/2024.06.13.24307996; this version posted June 13, 2024. The copyright holder for this preprint (which was not certified by peer review) is the author/funder, who has granted medRxiv a license to display the preprint in perpetuity. It is made available under a CC-BY-ND 4.0 International license .

## Western Ontario Rotator Cuff Index

Timepoint was associated with significant improvements in the WORC Index from baseline when adjusted for age and sex (Table 3). WORC Index scores for the cohort were 49 (IQR 27-61) preoperatively, 76 (IQR 46-87) at six months and 86 (IQR 57-93) at 12 months. As with the QuickDASH, scores improved over the 12 months following surgery, and the distribution of scores revealed different trajectories of recovery for the patients (Figure 3). The individual question (Physical Q3) demonstrated improvements in the sample average over time, but a proportion reported persistent weakness in the shoulder at the 12 months after surgery (Figure 3).

Table 3: Summary of models of WORC Index and Physical Q3 after multiple imputation

| | Normalised Index | | | Physical Q3 | | |
|---|---|---|---|---|---|---|
| **Characteristic** | **Beta** | **95% CI**[1] | **p-value** | **Beta** | **95% CI**[1] | **p-value** |
| TimePoint | | | | | | |
| Preop | — | — | | — | — | |
| 6months | 33.18 | 24.21, 42.15 | <0.001 | -32.13 | -42.87, -21.40 | <0.001 |
| 12months | 38.56 | 30.07, 47.05 | <0.001 | -43.35 | -53.97, -32.73 | <0.001 |
| Age at Surgery | 0.34 | -0.10, 0.77 | 0.123 | -0.47 | -1.16, 0.23 | 0.177 |
| Male vs Female | 10.24 | 0.08, 20.40 | 0.048 | -7.92 | -20.40, 4.56 | 0.203 |

[1] CI = Confidence Interval

medRxiv preprint doi: https://doi.org/10.1101/2024.06.13.24307996; this version posted June 13, 2024. The copyright holder for this preprint (which was not certified by peer review) is the author/funder, who has granted medRxiv a license to display the preprint in perpetuity. It is made available under a CC-BY-ND 4.0 International license .

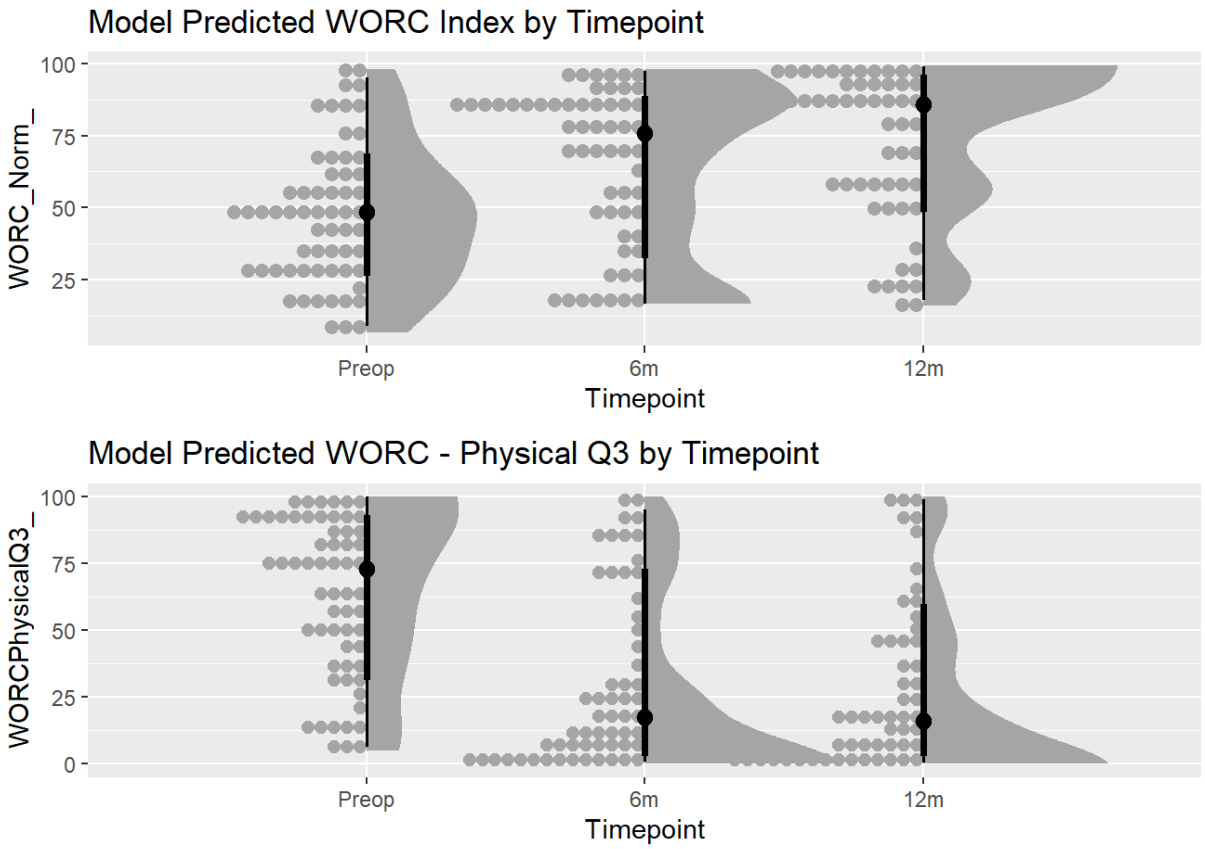


Figure 3: Change in distribution over time for adjusted and imputed WORC Index (top) and Q3 of the Physical subscale (bottom) with median and interquartile ranges (black dot and solid line)

# Discussion

The aim of this paper was to present a stage 2a IDEAL evaluation of a bioabsorbable anchor (Healix Advance BR, Depuy-Mitek, USA) with respect to clinical (adverse events, failures) and patient-reported outcomes in patients presenting with rotator cuff pathology treated with ARCR at up to 12 months follow up. The key findings were a low incidence of postoperative complications and no anchor-related intraoperative events, with no requirement for reoperation

medRxiv preprint doi: https://doi.org/10.1101/2024.06.13.24307996; this version posted June 13, 2024. The copyright holder for this preprint (which was not certified by peer review) is the author/funder, who has granted medRxiv a license to display the preprint in perpetuity. It is made available under a CC-BY-ND 4.0 International license .

or revision, as well as improvement in patient-reported outcomes aligned with expectations derived from the relevant literature

The reported benefits of PLGA/β-TCP implants is improved absorption and increased osteoconductivity, with low rates of imaging-observed adverse events (Barber et al., 2017)(Suroto et al., 2023). We report low-grade postoperative complications after ARCR using a PLGA/β-TCP anchor (Healix Advance BR). A registry-based analysis of ARCR (N = 1891) (Felsch et al., 2021) reported an overall incidence of all complication types of 18.5% (95%CI 16.6 - 20.4) at 6 months follow-up. The upper confidence limit of the present complication incidence (18.6%) aligns well to this estimate and may be improved with a larger sample. Overall, the use of the anchor of interest was not associated with a higher than expected rate of postoperative complications in this sample, with just one case of persistent post-surgical pain observed.

The clinical outcomes reported here cannot be readily compared with other studies reporting on the use of the anchor of interest (Chung et al., 2018; Di Gennaro et al., 2022) as they rely on postoperative MRI to assess imaging-based complications and did not report clinical presentations of known complications or adverse events. The presence of cysts is frequently reported, and varies widely at 12 month follow up, ranging from 10.8% (Ro et al., 2019) to 60% (Chung et al., 2018, 2019), but may not be clinically significant in the majority of cases (Chung et al., 2019). Further, one comparative study observed no relationship between perianchor fluid and the integrity of cuff repair, while the persistence of perianchor cysts postoperatively may be associated with a larger tear size and greater tendon retraction (Chung et al., 2019). Perianchor osteolysis (Pawaskar et al., 2015) and foreign body reactions (Nusselt et al., 2010) have been

medRxiv preprint doi: https://doi.org/10.1101/2024.06.13.24307996; this version posted June 13, 2024. The copyright holder for this preprint (which was not certified by peer review) is the author/funder, who has granted medRxiv a license to display the preprint in perpetuity. It is made available under a CC-BY-ND 4.0 International license .

reported for biodegradable anchors (Park et al., 2017), but the presence of radiolucent rings around these anchors (indicating osteolysis) have not been correlated with healing/retear or clinical outcomes in rotator cuff repair (Park et al., 2017).

To the best of our knowledge, there is one other study that has assessed patient-reported outcomes with the use of PLGA implants, specifically the anchor of interest in our study (Di Gennaro et al., 2022). The questionnaires utilised are slightly different (QuickDASH vs DASH) although well correlated with each other, there are subtle differences in scores that can accumulate error to the point of a minimal clinically important difference (Gummesson et al., 2006). Also the baseline DASH reported in their study is higher, with the reported mean for the sample one point below the maximum score for the questionnaire and the between-patient standard deviation exceeding the maximum score. The demographics of the studies also differ, with Di Gennaro et al reporting half the proportion of males compared to the present cohort. The baseline QuickDASH in this study is more typical of what has been observed for patients undergoing rotator cuff repair (Macdermid et al., 2015; Shibahashi et al., 2024), with the minimally clinical important difference of 15.9 - 20 points observed by six months in this study (Macdermid et al., 2015). Average WORC Index scores for the present cohort were also comparable at baseline (albeit higher) and at 12 months follow up in a meta-analysis of rotator cuff repair comprising 15 studies (N = 1371) (Sahoo et al., 2021). Of note however, the results of the individual question asking about shoulder weakness revealed a proportion of patients experiencing weakness at 12 month follow up. Considering the lack of imaging-confirmed failures in this series, these results may relate to a subset of patients at risk of displaying signs of failure below the clinical threshold for seeking additional care. Worse PROMs and reduced

medRxiv preprint doi: https://doi.org/10.1101/2024.06.13.24307996; this version posted June 13, 2024. The copyright holder for this preprint (which was not certified by peer review) is the author/funder, who has granted medRxiv a license to display the preprint in perpetuity. It is made available under a CC-BY-ND 4.0 International license .

strength are associated with retears in this population (Jancuska et al., 2018). Future work should target this subset of patients for imaging follow up to confirm cuff status.

## Limitations

The study is embedded within a clinical registry that is vulnerable to specific biases that should not be ignored (Scholes et al., 2023). Of particular relevance is selection bias, as the capacity for patients to engage in the process may be limited by language, technological and competency barriers. Thus the present cohort is not presented as representative of the entire cuff repair population, as evidenced by the majority male sample, above-average baseline scores, and private funded patient status. Future evaluations may include postoperative imaging to assess imaging-based complications that are particularly relevant for this type of anchor (Barber et al., 2017) and longer follow up. However, the outcome measures of this study are well validated and representative of the clinically relevant functional outcome status of the cohort. Further, judgements made about success or failure at this stage (2a) may not reflect the full spectrum of clinically relevant effects that could be observed with longer term follow-up (McCulloch et al., 2013). The alternative however, would be to wait for years for the result of definitive trials, which may not be possible without short-term observational studies as presented here.

medRxiv preprint doi: https://doi.org/10.1101/2024.06.13.24307996; this version posted June 13, 2024. The copyright holder for this preprint (which was not certified by peer review) is the author/funder, who has granted medRxiv a license to display the preprint in perpetuity. It is made available under a CC-BY-ND 4.0 International license .

## Conclusion

The findings of this IDEAL stage 2a evaluation at up to 12 months follow up reveal an acceptable incidence of adverse events, no requirement for reoperation and improvement of patient-reported outcomes in those treated for rotator cuff tear with ARCR with a third-generation biocomposite suture anchor by an experienced surgeon. These results should provide sufficient motivation for a larger evaluation or randomised trial to further evaluate efficacy in a bigger and more diverse population.

# Acknowledgements

The authors would like to acknowledge the participation of the patients in the PRULO registry and contributions of the staff at Geelong Orthopaedics for the conduct of the study. The authors would also like to thank Milad Ebrahimi (EBM Analytics) and other team members for assistance with data collection and extraction for this study.

## Funding Statement

Part funding for this analysis was provided by DePuy-Mitek (Johnson & Johnson Medical Pty Ltd). Funding arrangements for the PRULO registry are detailed in the protocol (Scholes et al., 2023).

medRxiv preprint doi: https://doi.org/10.1101/2024.06.13.24307996; this version posted June 13, 2024. The copyright holder for this preprint (which was not certified by peer review) is the author/funder, who has granted medRxiv a license to display the preprint in perpetuity. It is made available under a CC-BY-ND 4.0 International license .

# References

Arel-Bundock, V. (2023). *_marginaleffects: Predictions, Comparisons, Slopes, Marginal Means, and Hypothesis Tests_* (Version 0.15.0) [R package]. https://marginaleffects.com/

Audigé, L., Flury, M., Müller, A. M., ARCR CES Consensus Panel, & Durchholz, H. (2016). Complications associated with arthroscopic rotator cuff tear repair: definition of a core event set by Delphi consensus process. *Journal of Shoulder and Elbow Surgery / American Shoulder and Elbow Surgeons ... [et Al.]*, *25*(12), 1907–1917.

Barber, F. A., Dockery, W. D., & Cowden, C. H., 3rd. (2013). The degradation outcome of biocomposite suture anchors made from poly L-lactide-co-glycolide and β-tricalcium phosphate. *Arthroscopy: The Journal of Arthroscopic & Related Surgery: Official Publication of the Arthroscopy Association of North America and the International Arthroscopy Association*, *29*(11), 1834–1839.

Barber, F. A., & Herbert, M. A. (2013). Cyclic loading biomechanical analysis of the pullout strengths of rotator cuff and glenoid anchors: 2013 update. *Arthroscopy: The Journal of Arthroscopic & Related Surgery: Official Publication of the Arthroscopy Association of North America and the International Arthroscopy Association*, *29*(5), 832–844.

Barber, F. A., Spenciner, D. B., Bhattacharyya, S., & Miller, L. E. (2017). Biocomposite Implants Composed of Poly(Lactide-co-Glycolide)/β-Tricalcium Phosphate: Systematic Review of Imaging, Complication, and Performance Outcomes. *Arthroscopy: The Journal of Arthroscopic & Related Surgery: Official Publication of the Arthroscopy Association of North America and the International Arthroscopy Association*, *33*(3), 683–689.

Boksh, K., Haque, A., Sharma, A., Divall, P., & Singh, H. (2022). Use of Suture Tapes Versus

medRxiv preprint doi: https://doi.org/10.1101/2024.06.13.24307996; this version posted June 13, 2024. The copyright holder for this preprint (which was not certified by peer review) is the author/funder, who has granted medRxiv a license to display the preprint in perpetuity. It is made available under a CC-BY-ND 4.0 International license .

Conventional Sutures for Arthroscopic Rotator Cuff Repairs: A Systematic Review and Meta-analysis. *The American Journal of Sports Medicine*, *50*(1), 264–272.

Cho, C.-H., Bae, K.-C., & Kim, D.-H. (2021). Biomaterials Used for Suture Anchors in Orthopedic Surgery. *Clinics in Orthopedic Surgery*, *13*(3), 287–292.

Chung, S. W., Lee, Y.-S., Kim, J.-Y., Lee, J.-H., Ki, S.-Y., Oh, K.-S., Yoon, J. P., & Kim, J. Y. (2019). Changes in Perianchor Cyst Formation Over Time After Rotator Cuff Repair: Influential Factors and Outcomes. *The American Journal of Sports Medicine*, *47*(1), 165–172.

Chung, S. W., Oh, K.-S., Kang, S. J., Yoon, J. P., & Kim, J. Y. (2018). Clinical Outcomes of Arthroscopic Rotator Cuff Repair Using Poly Lactic-co-glycolic Acid Plus β-tricalcium Phosphate Biocomposite Suture Anchors. *Clinics in Shoulder and Elbow*, *21*(1), 22–29.

Colvin, A. C., Egorova, N., Harrison, A. K., Moskowitz, A., & Flatow, E. L. (2012). National trends in rotator cuff repair. *The Journal of Bone and Joint Surgery. American Volume*, *94*(3), 227–233.

Di Gennaro, S., Lecce, D., Tarantino, A., De Cupis, M., Bassetti, E., Scarnera, P., Ciminello, E., & Calvisi, V. (2022). Arthroscopic repair of rotator cuff injury with bioabsorbable suture anchor vs. all-suture anchor: a non-inferiority study. *BMC Musculoskeletal Disorders*, *23*(1), 1098.

Felsch, Q., Mai, V., Durchholz, H., Flury, M., Lenz, M., Capellen, C., & Audigé, L. (2021). Complications Within 6 Months After Arthroscopic Rotator Cuff Repair: Registry-Based Evaluation According to a Core Event Set and Severity Grading. *Arthroscopy: The Journal of Arthroscopic & Related Surgery: Official Publication of the Arthroscopy Association of North America and the International Arthroscopy Association*, *37*(1), 50–58.

Filip, N., Radu, I., Veliceasa, B., Filip, C., Pertea, M., Clim, A., Pinzariu, A. C., Drochioi, I. C.,

medRxiv preprint doi: https://doi.org/10.1101/2024.06.13.24307996; this version posted June 13, 2024. The copyright holder for this preprint (which was not certified by peer review) is the author/funder, who has granted medRxiv a license to display the preprint in perpetuity. It is made available under a CC-BY-ND 4.0 International license .

Hilitanu, R. L., & Serban, I. L. (2022). Biomaterials in Orthopedic Devices: Current Issues and Future Perspectives. *Coatings World*, *12*(10), 1544.

Gliklich, R. E., Leavy, M. B., & Dreyer, N. A. (2019). *Registries for Evaluating Patient Outcomes: A User's Guide*. Agency for Healthcare Research and Quality (US).

Gummesson, C., Ward, M. M., & Atroshi, I. (2006). The shortened disabilities of the arm, shoulder and hand questionnaire (QuickDASH): validity and reliability based on responses within the full-length DASH. *BMC Musculoskeletal Disorders*, *7*(1), 44.

Institute for Work & Health. (n.d.). *The DASH Outcome Measure - Disabilities of the Arm, Shoulder and Hand*. Scoring Instructions. Retrieved 20-Feb-2024, from https://dash.iwh.on.ca/scoring

Jancuska, J., Matthews, J., Miller, T., Kluczynski, M. A., & Bisson, L. J. (2018). A Systematic Summary of Systematic Reviews on the Topic of the Rotator Cuff. *Orthopaedic Journal of Sports Medicine*, *6*(9), 2325967118797891.

Kay, M. (2023). *ggdist: Visualizations of Distributions and Uncertainty in the Grammar of Graphics*. https://doi.org/10.31219/osf.io/2gsz6

Kim, S. H., Kim, D. Y., Kwon, J. E., Park, J. S., & Oh, J. H. (2015). Perianchor Cyst Formation Around Biocomposite Biodegradable Suture Anchors After Rotator Cuff Repair. *The American Journal of Sports Medicine*, *43*(12), 2907–2912.

Kirkley, A., Alvarez, C., & Griffin, S. (2003). The development and evaluation of a disease-specific quality-of-life questionnaire for disorders of the rotator cuff: The Western Ontario Rotator Cuff Index. *Clinical Journal of Sport Medicine: Official Journal of the Canadian Academy of Sport Medicine*, *13*(2), 84–92.

Lädermann, A., Burkhart, S. S., Hoffmeyer, P., Neyton, L., Collin, P., Yates, E., & Denard, P. J. (2016). Classification of full-thickness rotator cuff lesions: a review. *EFORT Open Reviews*,

medRxiv preprint doi: https://doi.org/10.1101/2024.06.13.24307996; this version posted June 13, 2024. The copyright holder for this preprint (which was not certified by peer review) is the author/funder, who has granted medRxiv a license to display the preprint in perpetuity. It is made available under a CC-BY-ND 4.0 International license .

*1*(12), 420–430.

Macdermid, J. C., Khadilkar, L., Birmingham, T. B., & Athwal, G. S. (2015). Validity of the QuickDASH in patients with shoulder-related disorders undergoing surgery. *The Journal of Orthopaedic and Sports Physical Therapy*, *45*(1), 25–36.

McCulloch, P., Cook, J. A., Altman, D. G., Heneghan, C., Diener, M. K., & IDEAL Group. (2013). IDEAL framework for surgical innovation 1: the idea and development stages. *BMJ* , *346*, f3012.

Nusselt, T., Freche, S., Klinger, H.-M., & Baums, M. H. (2010). Intraosseous foreign body granuloma in rotator cuff repair with bioabsorbable suture anchor. *Archives of Orthopaedic and Traumatic Surgery. Archiv Fur Orthopadische Und Unfall-Chirurgie*, *130*(8), 1037–1040.

Orthopaedics1*, O. C. C. (2019). Implementing a Scientifically Valid, Cost-Effective, and Scalable Data Collection System at Point of Care: The Cleveland Clinic OME Cohort. *JBJS*, *101*(5), 458.

Park, J.-Y., Jang, S.-H., Oh, K.-S., & Li, Y. J. (2017). Radiolucent rings around bioabsorbable anchors after rotator cuff repair are not associated with clinical outcomes. *Archives of Orthopaedic and Traumatic Surgery. Archiv Fur Orthopadische Und Unfall-Chirurgie*, *137*(11), 1539–1546.

Patzer, T., Rundic, J. M., Bobrowitsch, E., Olender, G. D., Hurschler, C., & Schofer, M. D. (2011). Biomechanical comparison of arthroscopically performable techniques for suprapectoral biceps tenodesis. *Arthroscopy: The Journal of Arthroscopic & Related Surgery: Official Publication of the Arthroscopy Association of North America and the International Arthroscopy Association*, *27*(8), 1036–1047.

Pawaskar, A. C., Kekatpure, A., Cho, N.-S., Rhee, Y.-G., & Jeon, I.-H. (2015). Magnetic resonance appearance of bioabsorbable anchor screws for double row arthroscopic rotator

medRxiv preprint doi: https://doi.org/10.1101/2024.06.13.24307996; this version posted June 13, 2024. The copyright holder for this preprint (which was not certified by peer review) is the author/funder, who has granted medRxiv a license to display the preprint in perpetuity. It is made available under a CC-BY-ND 4.0 International license .

cuff repairs. *Indian Journal of Orthopaedics*, *49*(2), 164–170.

Rashid, M. S., Cooper, C., Cook, J., Cooper, D., Dakin, S. G., Snelling, S., & Carr, A. J. (2017). Increasing age and tear size reduce rotator cuff repair healing rate at 1 year. *Acta Orthopaedica*, *88*(6), 606–611.

Rees, J. L. (2008). The pathogenesis and surgical treatment of tears of the rotator cuff. *The Journal of Bone and Joint Surgery. British Volume*, *90*(7), 827–832.

Ro, K., Pancholi, S., Son, H. S., & Rhee, Y. G. (2019). Perianchor Cyst Formation After Arthroscopic Rotator Cuff Repair Using All-Suture-Type, Bioabsorbable-Type, and PEEK-Type Anchors. *Arthroscopy: The Journal of Arthroscopic & Related Surgery: Official Publication of the Arthroscopy Association of North America and the International Arthroscopy Association*, *35*(8), 2284–2292.

Sahoo, S., Stojanovska, M., Imrey, P. B., Jin, Y., Bowles, R. J., Ho, J. C., Iannotti, J. P., Ricchetti, E. T., Spindler, K. P., Derwin, K. A., & Entezari, V. (2021). Changes From Baseline in Patient- Reported Outcomes at 1 Year Versus 2 Years After Rotator Cuff Repair: A Systematic Review and Meta-analysis. *The American Journal of Sports Medicine*, 3635465211023967.

Savage, E., Hurren, C. J., Rajmohan, G. D., Thomas, W., & Page, R. S. (2023). Arthroscopic knots: Suture and knot characterisation of modern polyblend suture materials. *Heliyon*, *9*(9), e19391.

Scholes, C., Eng, K., Harrison-Brown, M., Ebrahimi, M., Brown, G., Gill, S., & Page, R. (2023). Patient Registry of Upper Limb Outcomes (PRULO): a protocol for an orthopaedic clinical quality registry to monitor treatment outcomes. *Journal of Surgical Protocols and Research Methodologies*, *2023*(4), snad014.

Shibahashi, H., Murakawa, M., Yuki, I., Uno, T., Takakubo, Y., & Takagi, M. (2024). Patient Sex

medRxiv preprint doi: https://doi.org/10.1101/2024.06.13.24307996; this version posted June 13, 2024. The copyright holder for this preprint (which was not certified by peer review) is the author/funder, who has granted medRxiv a license to display the preprint in perpetuity. It is made available under a CC-BY-ND 4.0 International license .

Is a Significant Factor in Arm Function Recovery After Arthroscopic Rotator Cuff Repair. *Sports Medicine, Arthroscopy, Rehabilitation, Therapy & Technology: SMARTT*, *6*(1), 100834.

Sink, E. L., Leunig, M., Zaltz, I., Gilbert, J. C., Clohisy, J., & Academic Network for Conservational Hip Outcomes Research Group. (2012). Reliability of a complication classification system for orthopaedic surgery. *Clinical Orthopaedics and Related Research*, *470*(8), 2220–2226.

Suroto, H., Anindita Satmoko, B., Prajasari, T., De Vega, B., Wardhana, T. H., & Samijo, S. K. (2023). Biodegradable vs nonbiodegradable suture anchors for rotator cuff repair: a systematic review and meta-analysis. *EFORT Open Reviews*, *8*(10), 731–747.

Yang, Y.-S., Shih, C.-A., Fang, C.-J., Huang, T.-T., Hsu, K.-L., Kuan, F.-C., Su, W.-R., & Hong, C.-K. (2023). Biomechanical comparison of different suture anchors used in rotator cuff repair surgery-all-suture anchors are equivalent to other suture anchors: a systematic review and network meta-analysis. *Journal of Experimental Orthopaedics*, *10*(1), 45.