Immersive 3D Visualisations (3D Printing, Virtual Reality) enhance spatial understanding of complex cardiac dysmorphology imaging

Mahesh Kappanayil (FNB)[1,2,*], Aishwarya Gurav (DM)[1*], Sarin Xavier (M.Tech)[2], Harikrishnan Anil Maya (MSc)[2], Balaji Srimurugan (MCh)[3], Abish Sudhakar (MA)[1], Raman Krishna Kumar (DM)[1].

[1]Department of Pediatric Cardiology, Amrita Institute of Medical Sciences, Kochi, Kerala, India.
[2]Cardiovascular 3D Printing and Extended Reality Laboratory, Amrita Institute of Medical Sciences, Kochi, Kerala, India.
[3]Department of Pediatric Cardiovascular and Thoracic Surgery, Amrita Institute of Medical Sciences, Kochi, Kerala, India.
***Equal contribution first authors.**

Running Title : Immersive 3D tools enhance spatial understanding.

Word Count : 5534.

Financial Disclosures : None.

Address for correspondence :
Dr.Mahesh Kappanayil
Professor, Department of Pediatric Cardiology,
Amrita Institute of Medical Sciences
Kochi, Kerala'INDIA
Web: www.aimshospital.org.
Phone : +91-484-2801234 Extn: 3570
Mobile: +91-9846190020
FAX : +91-484-
Email : maheshpes@yahoo.co.in
X : @kappanayil

Abstract

Background:

Diagnosing, managing complex CHD demands excellent morphological understanding. Individual differences in visuospatial skills, training and experience can impact spatial interpretation of volumetric cardiac imaging. Immersive 3D visualisation may help overcome these challenges, but evidence of clinical benefit is lacking.

This study explores variability in visuospatial abilities and interpretation of conventionally viewed volumetric cardiac imaging data among members of a pediatric cardiac unit, and impact of using immersive 3D formats (3D-prints, Virtual Reality) on spatial understanding of complex CHD morphology.

Methods:

Prospective cohort study involving 9 heterogenous members of an advanced pediatric cardiac program [3 consultant cardiologists, 2 cardiothoracic surgeons, 1 cardiac radiologist, 3 cardiology trainees]. Participants' visuospatial abilities were quantified using a validated test (Revised PSVT:R). Understanding of spatial relationships between anatomical structures was assessed using structured questionnaires for 17 unique anonymised volumetric cardiac scans (15 CT, 2 MRI) of complex CHD visualised in three formats 1). conventional DICOM (CDICOM); 2). 3D prints (3DP); 3). Virtual Reality (VR). Accuracy, time taken, perceived level of difficulty, and confidence in interpretation were assessed and compared.

Results :

Spatial abilities varied widely (median 8, IQR 6-30), independent of expertise/experience. Limitations in conventional reading were significantly overcome with immersive 3D. Mean accuracy score of 60.48% ±17.13% with CDICOM increased to 83.93% ± 7.84% with 3DP, and 90.81% ± 5.03% with VR ($p<0.001$). 3DP and VR permitted significantly faster interpretation ($p<0.001$), with significantly better ease and confidence. While immersive 3D visualisation led to significantly improved spatial understanding for all, it also minimised differences between participants with widely variable skill and experience levels.

Conclusion:

This study provides evidence that immersive 3D visualisation can enhance spatial understanding of complex CHD morphology, overcoming challenges in spatial ability, experience, expertise. These technologies may be suitably leveraged as effective clinical and teaching tools in congenital cardiology.

Keywords : Cardiovascular imaging, Spatial Intelligence, congenital heart disease, 3D imaging, digital twin, extended reality.

Abbreviations :

CHD : Congenital heart disease

CT : computed tomography

DICOM : Digital Imaging and Communication in Medicine

MRI : magnetic resonance imaging

PSVT:R : Perdue Spatial Visualisation Test - Test of Rotations

Introduction

Novel applications of immersive three-dimensional (3D) technologies like 3D Printing (3DP), Extended Reality (XR) have been capturing popular imagination. They offer powerful new ways to engage with digital data by converting digital 3D files into physical prototypes (3D prints) or computer-generated virtual 3D objects or environments (XR). Healthcare, especially pediatric cardiac care, may present some of the most impactful use-cases - spanning diagnosis, procedural planning, communication, teaching, research, simulation and collaboration [1-7]. These technologies are still nascent; wider acceptance and adoption awaits convincing scientific proof [4-7].

Pediatric cardiac professionals are constantly challenged by need to identify, understand, communicate and treat wide range of complex anatomical abnormalities - spatiotemporal understanding is key. Much of diagnostic cardiovascular imaging is either inherently 2-dimensional (2D), or viewed in 2D formats. Even 'volumetric' imaging like CT and MR angiography are conventionally viewed as 2D stacks, or volume-rendered images on flat screens. Mentally reconstructing complex 3D anatomies from 2D images requires combination of visuospatial abilities, training and experience. While skill and experience can be acquired, spatial intelligence, composed of various elements like abstract thinking, imagination, mental strategising, rotational understanding and other cognitive aspects, may be a unique and variable trait [8]. Variability in visuospatial abilities among pediatric cardiac professionals, and its implications, have not been studied. Advanced, immersive 3D technologies have potential to simplify visualisation and understanding of complex CHD morphologies, compensating for individual differences in spatial cognition and experience.

This study explores variability in spatial intelligence, and impact of using immersive 3D technologies (3D printing and Virtual Reality) on cognitive understanding, interpretation of tomographic cardiovascular images of complex CHD, among diverse members of a high-competency pediatric cardiac unit.

MATERIALS AND METHODS

i). Setting and Participants

Prospective observational study conducted over 20 months (November 2021-June 2023) at a high volume pediatric cardiac unit that regularly performs wide range of cardiac surgical procedures in-

cluding neonatal surgeries, complex biventricular repairs and univentricular palliations with excellent outcomes [9-11]. Tomographic cardiac imaging is supported by dedicated cardiac radiology service. Cardiologists, surgeons and trainees regularly view, interpret tomographic images in day-to-day clinical workflow. Major management decisions, particularly regarding complex cases are taken in joint multidisciplinary meetings. Unit has point-of-care (POC) Cardiovascular 3D Printing and XR Laboratory [3].

Nine team members volunteered to participate - six faculty (10-30 years of individual domain experience) including three pediatric cardiology consultants (PCC), two pediatric cardiac surgeons (PCS) and one cardiac radiologist (CR) - and three pediatric cardiology fellows (PCF) (1 month to 2 years into training).

ii). Test of Spatial Abilities

All participants underwent validated test of spatial abilities - Revised Purdue Spatial Visualization test - Test of Rotations [Revised PSVT:R] (with permission from author) [12]. Administered in standardised manner, test required subjects to answer thirty questions within twenty minutes, assessing ability to interpret change in visual perspective upon rotation of 2-dimensional diagrams of 3-dimensional shapes. Responses were tallied against correct answers provided in answer-key - assigned score of 1 for correct and nil for incorrect responses - scores were totalled (n/30).

iii). Selection and Preparation of Test-case Tomographic Imaging Datasets

17 tomographic imaging datasets (CT, MRA) of complex CHD cases were selected from departmental imaging archives (preceding ten years) after screening for data quality (resolution, slice thickness, readability, suitability for conversion to 3D formats). Clinical data, echocardiography, operation notes and other relevant information were reviewed. Cases included a mix of spatially complex cardiovascular anomalies ; situs and cardiac position variations were also represented. (Table 1).

Case-specific questionnaires were prepared with 5 to 7 multiple-choice questions assessing ability to identify spatial relationships between different ‘segments’ of cardiovascular anatomy - e.g., atrioventricular relationships, spatial positioning of cardiac chambers and great arteries, locations of ventricular septal defect etc; no descriptive responses, specific diagnosis or nomenclatures were sought. Responses were tallied against case-specific answer keys prepared by research team after thorough review of data.

iv). *Visualisation Formats*

All 17 selected datasets were anonymised and prepared for three visualisation formats : i.conventional DICOM (CDICOM); ii.3D printed (3DP) models; iii.Virtual Reality (VR).

Conventional visualisation was using standard workstation-based DICOM viewing/analysis platform (Horos, Horos Project, Brooklyn, New York, USA) which all participants were already conversant with, and included in-built tools like multi-planar viewing, windowing, thresholding, sizing, measuring etc. No special training was required.

Conversion to Immersive 3D Formats : DICOM data was imported into proprietary software (Materialise Innovation Suite MIS V26.0, Materialise NV, Belgium). Standard workflow was followed for segmentation of region-of-interest and conversion to digital 3D file format (standard triangulation language/.stl) [4,13]. 'Hollow' models with appropriately designed cut-planes were created for intracardiac visualisation and 'solid' models for predominantly extracardiac study questions. Markers of orthogonal planes were incorporated. 3D conversions were done by expert (KM) at in-house 3D Labs. STL files were digitally optimised (Preform, Formlabs, USA) and 3D printed in 1:1 scale on Form2 3D printer (Formlabs, USA), using clear photopolymer resin. Models were post-processed, and optimised for administering.

Virtual Reality visualisations were done using XR computer applications - FDA-approved 3D medical modelling software Elucis (Realize Medical, Canada), 3D volume-rendering software Vea (Vea Simulations, Poland) and homegrown VR visualisation platform (based on Unity Game Engine, Unity Technologies). VR tools included interactions like grabbing, scaling, cutting, labelling, dissecting, annotating (using handheld 'game-controllers'). Conversions to VR were done by expert (KM). Hardware included Meta Quest2 (Meta, USA) and HTC Vive-Pro (HTC, Taiwan) VR headsets tethered to GPU workstation. Participants were trained for VR using dummy datasets, until adequately proficient.

v). Tests

Test-cases were administered to all participants in all three formats in random, shuffled manner. Participants were required to answer case-specific questionnaires (identical across all three visualisation formats), blinded to clinical and other imaging information. Sessions were timed with a stopwatch.

Participants were scored for accuracy (correct=1, incorrect=0) and time taken (seconds). 10-point Likert's scale was used to assess subjective elements - i). perceived level of difficulty (1 - 'very easy' and 10 - 'very difficult'). ii). level of confidence in interpretation (1 - 'not confident', 10 - 'very confident') [13].

Mean values were calculated for individual participants for each visualisation mode across the 17 test datasets. Subgroup comparisons were made between cardiologists, surgeons, fellows and cardiac radiologist. Comparisons were also made between experienced pediatric cardiac specialists (PCC plus PCS) and fellows-in-training.

v). Statistical Analysis

Pearson Chi-Square test was used to compare categorical variables. Spearman's correlation was used to find the correlation between spatial orientation score and accuracy scores and time across the three visualisation modalities. Paired t- test was used to compare the continuous variables among participants across modalities. A repeated measures ANOVA with Post hoc Bonferroni correction was used to compare accuracy score and time in different modalities for participants. Statistical analyses were conducted using SPSS Version 20.0 for Windows (IBM Corporation ARMONK, NY, USA).

RESULTS

All 9 participants completed baseline spatial ability test and analysis of 17 imaging datasets across all three visualisation formats. 459 test-case questionnaires were analysed. Tables 2 and 3 summarise accuracy scores and time-performance.

Spatial Abilities

Revised PSVT:R showed wide variability in spatial rotational abilities, independent of clinical seniority, experience or expertise. Scores ranged from 0-15/30, median score 8 (IQR 6.5-30) (figure 1).

Accuracy

All participants logged lowest individual accuracy scores with conventional reading, which improved with 3DP and VR (Table 2) - statistically significant for all except cardiac radiologist. Mean accuracy score for cohort with CDICOM (60.46% ±7.13%) improved to 83.93% ± 7.84% with

3DP, and to 90.81% ± 5.03% with VR (p<0.001). Improvement in accuracy from 3DP to VR was statistically significant (p=0.002). (Table 2).

Table 3 compares accuracy scores of subgroups (CR, PCC, PCS and PCF) across formats, as well as the difference in accuracy within each format across participant groups.

i). Comparing accuracy across formats :

Change in accuracy scores is shown in figure 2A. Accuracy improved from CDICOM through 3DP to VR, with the change being statistically significant for consultant cardiologists (p<0.001), surgeons (p<0.001) and fellows (p<0.001) (table 3).

ii). Comparing accuracy across participant groups :

<u>CDICOM</u> : Cardiac radiologist performed best at conventional visualisation with mean accuracy score of 84.62% ± 17.65%, followed by cardiology consultants (70.7% ± 11.2%), surgeons (66.8% ± 13.21%) and fellows (37.95% ± 7.08%). Difference in accuracy scores was statistically significant (p<0.001).

Mean accuracy score for 'pediatric cardiac team' (PCC + PCS + PCF) was 57.43% ± 7.15 %. Gap between pediatric cardiology fellows (PCF) and consultants (PCC + PCS) was wide (37.95% ± 7.08% vs 69.12± 9.14 %, p<0.001).

<u>3DP</u> : Mean accuracy scores significantly improved for all with use of 3D printed models (Tables 2,3; Figure 2A), resulting in statistically insignificant difference between them (p=0.06) (Table 3). Pediatric cardiac team mean score improved to 83.41% ± 7.29 %. Difference between fellows and the consultants became narrow (79.2% ± 8.96 % vs 85.92% ± 9.12 %), though a statistically significant difference between the two persisted (p=0.02).

<u>VR</u> : Best accuracy was with VR (Tables 2,3; Figure 2A). Mean accuracy of composite pediatric cardiac team was 90.72% ± 5.04 %. Though there was statistically significant difference between accuracy scores of fellows (85.55± 6.71 %) and consultants (93.82 ± 5.25 %) with VR (p<0.001), there was marked improvement from conventional viewing, and narrowing of the gap.

Figure 2B summarises the change among members of Pediatric Cardiac Team (consultants and fellows).

Elements of Spatial Anatomy

Table 4 compares pediatric cardiac consultants and fellows while analysing specific elements of spatial anatomy. Conventional visualisation was associated with lower accuracy, and wide gap between them, both of which significantly improved with immersive 3D visualisations.

2. Time Taken

CDICOM interpretation took longer than 3DP and VR - statistically significant for individual participants as well as for mean values for whole cohort (Table 2).

Figure 2C compares time taken by participant subgroups - significantly lesser time required with 3DP and VR ($p<0.001$) (Table 3). Consultant cardiologists and surgeons took lesser time with 3DP than with VR ($p=0.034$ and $p=0.033$ respectively). Fellows also took lesser time with 3DP than with VR , but difference was not statistically significant ($p=0.089$). Radiologist took longer to interpret 3DP than VR; difference was not statistically significant ($p=0.973$).

Difference in time taken by four subgroups was statistically significant while interpreting CDICOM ($p=0.002$) and with VR ($p=0.028$), but not for 3DP ($p=0.080$) (Table 3). There was wide, statistically significant difference between pediatric cardiac consultants (326.48± 69.94 seconds) and fellows (447 ± 94 seconds), $p<0.001$ with CDICOM; gap narrowed with immersive 3D (Figure 2D). There was no significant difference between them while interpreting VR (227.51± 53.37 vs 238.27± 58.18 seconds, $p=0.375$); borderline significance remained with 3DP (179.35± 60.94 vs 208.88± 36.98 seconds, $p=0.047$).

3. Subjective Parameters - Likert's Scale

Table 5 compares subjective perceptions of 'level of difficulty' and 'level of confidence' in interpretation among participant groups.

L***evel of difficulty*** *:* CDICOM was rated most difficult and VR simplest to interpret($p<0.001$). There was statistically significant difference between four subgroups for CDICOM ($p<0.001$) and for 3DP ($p=0.011$), but not for VR ($p=0.319$). Reduction in difficulty ratings from CDICOM to 3DP to VR was statistically significant for all subgroups. The changes is shown in figure 3A.

Level of confidence : While there was no significant change in level of confidence for cardiac radiologist, there was significant improvement for other three groups with immersive 3D (Table 4). Surgeons had higher confidence with 3DP over VR ($p=0.048$) while cardiology fellows were more

confident with VR than with 3DP ($p<0.006$). There was no statistically significant difference between VR and 3DP for consultant cardiologists. The changes are depicted in figure 3B.

Correlation of Spatial abilities with accuracy and speed of interpretation.

Spatial ability score had weak positive correlation with accuracy, weak negative correlation with speed of interpretation of CDICOM - statistically insignificant. Similarly, statistically insignificant weak positive correlations were noted between spatial ability score and accuracy at interpreting 3DP and VR. Spatial ability score had a strong negative correlation with time taken for interpreting 3DP ($p=0.002$); correlation was weak and statistically insignificant for VR ($p=0.317$).

DISCUSSION

Immersive 3D technologies can transform how we visualise and interact with medical imaging data. This study, for first time, explores differences in visuospatial abilities among members of a busy pediatric cardiac unit, and impact of immersive 3D visualisation on their interpretation of volumetric imaging.

Pediatric cardiac professionals have been among earliest healthcare adopters of 3D technologies. 3D printed heart models have been increasingly used in procedural planning in recent years [1-4,7,14-16]. More recently, XR is being explored for digital immersion capabilities [5-7]. Prime driver for adoption has been need for better morphological understanding in diagnosing, treating complex CHD given the wide gamut of possible anatomical variations. Successful management, particularly in complex cases, depends not just upon operative skills but on host of factors including anatomical understanding, team-based approach, effective communication and careful procedural planning. Conventional imaging and training do not adequately foster spatial understanding. Even '3D volume-rendered' images viewed on 2D workstation screens do not adequately convey depth and scale. Access to morphological specimens is rare, increasingly inaccessible for most during training or early career. Learning occurs mostly though textual descriptions, diagrams, photographs and accumulated experience. Nomenclatures and classifications have been developed to aid identification, categorisation and communication [17]. However, no two patients are exactly alike; anatomical uniqueness of each case can be critical to management. Cardiologists are often straitjacketed into interpreting predefined 'views' and cross-sectional slices of imaging data, without conscious effort, opportunity and sometimes innate ability to adequately understand spatial anatomy. Complex vari-

ants of double outlet right ventricle (DORV), anatomically corrected malposition of great arteries (ACMGA), criss-cross hearts, 'topsy-turvy hearts', heterotaxy syndromes are just some examples of morphologies that can be challenging to mentally reconstruct from conventional image visualisations, diagrams or wordy descriptions. Despite long learning curves typically running into years, it is not uncommon to be repeatedly surprised by morphological complexities one has not encountered prior. Errors in understanding can translate to judgement errors, operative surprises and impact on outcomes.

'Spatial intelligence' is mental computational capacity to solve spatial problems, and determines one's ability to mentally retrieve, process, retain and transform visual information [8,12]. Its importance has been recognised, acknowledged in numerous fields including art, creativity and STEM (Science Technology Engineering Mathematics) disciplines [18]. Multi-dimensional in construct, spatial intelligence has at least two core aspects - spatial visualisation (SV) and spatial relation/orientation (SR). *'Mental rotational ability'* is the component that enables one to visualise a 3D object from different perspectives/viewpoints by mentally rotating it. Several specialised tests and instruments have been developed for objective assessment [12,19-21]. Purdue Spatial Visualisation Test (PSVT), with three subtests ('Developments', 'Rotations', 'Views'), was originally developed by Guay in 1976; 'Rotations' subtest was subsequently extended to PSVT:R (Visualisation of Rotations) to test mental rotational ability, further modified by Yoon (2011) into Revised PSVT:R used for this study [21].

Limited studies have explored importance of visuospatial abilities among medical professionals [22-25]. 3D understanding has been shown to be associated with achievements in anatomy learning among medical students [22-24].Variability has also been shown to impact surgical skill learning acquisition and performance - especially in early stages of learning [25]. While accumulation of experience and practice may obviate the impact to some extent, lower spatial abilities may translate into longer learning curves, and need for better training techniques. Differences in spatial abilities among pediatric cardiac professionals has not been studied adequately previously.

Immersive 3D technologies have potential to change the paradigm by presenting volumetric imaging data in spatial, interactive formats. 3D printing involves creation of three-dimensional physical prototypes by adding material layer-by-layer based on a digital design derived from patient-specific volumetric scans using computer-aided design (CAD) software [2-4,7,15]. These 1:1 scale physical replicas derived from their 'digital twins' provide uniquely immersive and tactile interaction, in sharp contrast to conventional viewing on flat workstation screens [1-4, 7, 14-16]. Printed in suitable materials, they can be used to simulate surgical/interventional procedures, and also for communication,

teaching, and even educating patients and families about upcoming procedures [4,7,15]. Owing to infrastructural needs like physical space, 3D printers, printing materials, dedicated software, and expertise, adoption has been restricted to select centres [7].

Extended Reality is an umbrella term encompassing VR, augmented reality (AR), and mixed reality (MR). While VR immerses users in a completely computer-generated environment, AR overlays digital information, images, or objects onto the real world. MR merges elements of both AR and VR, allowing digital and physical objects to interact in real-time. These 'simulated realities' are typically experienced using specialised headsets or eyewear, software applications and handheld controllers (or gesture controls). Exponential growth in digital technology has made XR increasingly affordable, available and adaptable for diverse applications across disciplines. In healthcare, it's role is being explored for myriad use-cases that include surgical simulations, medical training, patient education, therapy, and collaboration. XR offers powerful new means for immersive visualisation of digital 3D versions of volumetric cardiovascular imaging data [5-7]. Transcending visualisation, incorporation of digital tools like virtual dissection, measurement, annotation, scaling, remote collaboration, and procedural simulation can further enhance the interaction; 3D printed models while providing unmatched haptic experience, are limited in versatility and range of interactions. Infrastructural needs and turnaround times are less for XR than for 3D printing. While offering unique form of gamification and engagement - XR may be associated with cybersickness, vertigo and headache in some users [5].

While centres globally are beginning to explore point-of-care 3D printing and XR visualisation, there still is considerable hesitancy in adopting these novel technologies in clinical arena. Published literature being predominantly case reports and case series, robust clinical validation and unequivocal evidence of outcome benefit are still lacking - particularly in context of multitude of variables impacting CHD outcomes [4-7, 15,16].

This study was intended to validate a more fundamental study question - whether immersive 3D technologies can improve morphological understanding of complex CHD - as a precursor and foundation for better clinical care and outcomes. We also tried to understand existing gaps in spatial understanding between individuals with diverse skill-levels and experience in a real-world clinical setting, and whether these can be overcome by using immersive 3D technologies.

Test of Spatial Ability

Wide variability and overall low scores on Revised PSVT:R (median 8, IQR 6.5-30), irrespective of clinical experience, expertise or sub-speciality, highlight heterogeneity of spatial abilities among

physicians comprising a typical pediatric cardiac team - pointer towards need to develop better training and visualisation tools to compensate for these differences. Assessing true impact of such variability, as well as potential determinants like gender, race, environment would require larger, systematic studies.

Accuracy of interpretation.

Salient observations included significant limitations as well as variability in accuracy of interpretation with conventional visualisation (mean accuracy 60.46% ± 7.13%). Those with specialised training (cardiac radiologist - mean score 84.62% ± 17.65%) and/or with more experience (pediatric cardiac consultants - mean score 69.12± 9.14 %) fared significantly better than trainees (mean score 37.95% ± 7.08%). Expectedly, cardiac radiologist with combination of training and experience fared best. Gap between fellows and consultants was strikingly wide ($p<0.001$).

Use of 3DP and VR led to significant change with mean scores improving to 83.93% ± 7.84% with 3DP , and 90.81% ± 5.03% with VR, and dramatic shrinking of gap between subgroups . Most impressive change was for the trainees, bringing them almost at par with their vastly more experienced senior consultants. With 3D printed models, there was no statistically significant difference between accuracy scores of consultants and trainees. With VR, even though there was statistically significant difference ($p=0.006$), the gap was markedly narrowed (table 3, figure 3).

Time Taken

Immersive 3D visualisation permitted faster interpretation. Significant differences between subgroups (especially consultants and fellows) with conventional format, were markedly reduced with 3DP and VR ($p<0.001$). Time difference between groups was insignificant with 3DP ($p=0.080$). 3D printed models allowed quickest interpretation for all except cardiac radiologist (VR fastest). Interestingly, though VR interpretation had best accuracy, it required more time than 3DP for most. This may partly be due to immersive, 'gamified' engagement in VR as also need to adapt to hardware (headsets, controllers).

Subjective parameters

Immersive 3D formats resulted in simplification of spatial understanding for all participants, reflecting in significantly lower scores for 'level of difficulty' and higher scores for 'level of confidence'.

Gains were again most notable for trainees, reducing gap between them and the more experienced consultants.

Conclusions

Study offers novel insights into variability in spatial abilities, and interpretation of volumetric imaging of complex CHD among members of a real-world pediatric cardiac team. It provides objective evidence that immersive 3D visualisation can help overcome multi-dimensional individual variabilities, improving understanding and minimising gaps - equipping physicians for better, safer and more precise patient care. Immersive learning tools and collaborations based on these novel technologies may shorten learning curves and elevate quality of pediatric cardiac care.

Limitations

Single center study with limited number of participants, test cases. Imaging data was archival, and clinical decisions, outcomes were not analysed. 3D formats were created at in-house 3D Printing, XR Lab - capabilities unavailable at majority of centres.

Ethics : Study was approved by Institutional Ethics Committee.

Source of funding : Study was funded by institutional research grant. No funding from external agencies or industry.

Disclosures : None

REFERENCES

1. Farooqi KM, Nielsen JC, Uppu SC et al. Use of 3-dimensional printing to demonstrate complex intracardiac relationships in double-outlet right ventricle for surgical planning. *Circulation: Cardiovascular Imaging.* 2015;8(5):e003043.
2. Anwar S, Singh GK, Varughese J et al. 3D printing in complex congenital heart disease: across a spectrum of age, pathology, and imaging techniques. *JACC: Cardiovascular Imaging*. 2017;10(8):953-6.
3. Kappanayil M, Koneti NR, Kannan RR, Kottayil BP, Kumar K. Three-dimensional-printed cardiac prototypes aid surgical decision-making and preoperative planning in selected cases of complex congenital heart diseases: Early experience and proof of concept in a resource-limited environment. *Ann Pediatric Cardiol*. 2017;10(2):117.
4. Giannopoulos AA, Mitsouras D, Yoo SJ, Liu PP, Chatzizisis YS, Rybicki FJ. Applications of 3D printing in cardiovascular diseases. *Nat Rev Cardio*l. 2016 Dec;13(12):701-718.
5. Jung C, Wolff G, Wernly B et al. Virtual and Augmented Reality in Cardiovascular Care: State-of-the-Art and Future Perspectives. J*ACC Cardiovasc Imaging*. 2022 Mar;15(3):519-532.
6. Sacks LD, Axelrod DM. Virtual reality in pediatric cardiology: hype or hope for the future? Curr Opin Cardiol. 2020 Jan;35(1):37-41.
7. Sachdeva R, Armstrong AK, Arnaout R et al. Novel Techniques in Imaging Congenital Heart Disease: JACC Scientific Statement. J *Am Coll Cardiol*. 2024 Jan 2;83(1):63-81.
8. Maeda Y, Yoon SY. A meta-analysis on gender differences in mental rotation ability measured by the Purdue spatial visualization tests: Visualization of rotations (PSVT: R). *Educational Psychology Review*. 2013;25:69-94.
9. Sen AS, Morrow DF, Balachandran R et al. Postoperative Infection in Developing World Congenital Heart Surgery Programs: Data From the International Quality Improvement Collaborative. *Circ Cardiovasc Qual Outcomes*. 2017;10:e002935.

10. Kottayil BP, Sunil GS, Kappanayil M et al. Two-ventricle repair for complex congenital heart defects palliated towards single-ventricle repair. *Interact Cardiovasc Thorac Surg*. 2014;18:266-7.
11. Wei ZA, Johnson C, Trusty P, Stephens M et al. Comparison of Fontan Surgical Options for Patients with Apicocaval Juxtaposition. *Pediatr Cardiol.* 2020;10.1007/s00246-020-02353-8.
12. Yoon, S. Y. (2011). Revised Purdue Spatial Visualization Test: Visualization of Rotations (Revised PSVT:R) [Psychometric Instrument].
13. Likert, Rensis (1932). "A Technique for the Measurement of Attitudes". *Archives of Psychology.* 1932:140: 1–55.
14. Vukicevic M, Mosadegh B, Min JK, Little SH. Cardiac 3D Printing and its Future Directions. *JACC Cardiovasc Imaging*. 2017 Feb;10(2):171-184.
15. Lau I, Sun Z. Three-dimensional printing in congenital heart disease: A systematic review. *J Med Radiat Sci*. 2018;65(3):226-36.
16. Biglino G, Milano EG. Applications of 3D printing in paediatric cardiology: its potential and the need for gathering evidence. *Translational Pediatrics*. 2018;7(3):219.
17. Franklin RCG, Béland MJ, Colan SD et al. Nomenclature for congenital and paediatric cardiac disease: the International Paediatric and Congenital Cardiac Code (IPCCC) and the Eleventh Iteration of the International Classification of Diseases (ICD-11). *Cardiol Young.* 2017 Dec; 27(10):1872-1938.
18. Yoon, S. Y., & Mann, E. L. Exploring spatial ability of undergraduate students: Association with gender, STEM majors, and gifted program experiences. *Gifted Child Quarterly*. 2017; 61(4), 313-327.
19. Bodner GM, Guay RB. The Purdue Visualization of Rotations Test. *The Chemical Educator.* 1997;2(4):1-17.

20. Peters M. Sex differences and the factor of time in solving Vandenberg and Kuse mental rotation problems. *Brain and cognition*. 2005;57(2):176-84.

21. Yoon, S. Y. (2011). Psychometric properties of the Revised Purdue Spatial Visualization Tests: Visualization of Rotations (The Revised PSVT:R) (Doctoral Dissertation). Purdue University, West Lafayette, IN, USA. Retrieved from ProQuest Dissertations and Theses. (Order Number: 3480934).

22. Fernandez R, Dror IE, Smith C. Spatial abilities of expert clinical anatomists: comparison of abilities between novices, intermediates, and experts in anatomy. *Anat Sci Educ.* 2011 Jan-Feb; 4(1):1-8.

23. Roach VA, Mi M, Mussell J et al. Correlating Spatial Ability With Anatomy Assessment Performance: A Meta-Analysis. *Anat Sci Educ.* 2021 May;14(3):317-329.

24. Zhao J, Xu X, Jiang H, Ding Y. The effectiveness of virtual reality-based technology on anatomy teaching: a meta-analysis of randomized controlled studies. *BMC Med Educ.* 2020 Apr 25;20(1):127.

25. Wanzel KR, Hamstra SJ, Caminiti MF, Anastakis DJ, Grober ED, Reznick RK. Visual-spatial ability correlates with efficiency of hand motion and successful surgical performance. *Surgery.* 2003;134(5):750–757.

FIGURE LEGENDS

FIGURE 1 : *Spatial Intelligence.*

Scatter diagram showing spatial ability scores of individual participants on Revised Perdue Spatial Visualisation Test - Test of Rotations (PSVT:R).

FIGURE 2 : *Accuracy and TimeTaken.*

2A : Mean accuracy scores (%) of participant subgroups in interpreting 17 test-cases using three visualisation formats. Accuracy improved for all subgroups with immersive visualisation - VR enabled best accuracy.

2B : Comparison of mean accuracy scores of pediatric cardiac fellows (dotted line) with consultants (dashed line) - wide gap with conventional visualisation significantly narrowed with 3D print and VR. Solid line represents mean scores for composite pediatric cardiac team.

2C : Mean time taken (seconds) for interpretation - significant reduction with immersive 3D formats. 3D prints required least time except for cardiac radiologist (VR fastest).

2D : Comparison of time taken by fellows (dotted line) and consultants (dashed line) - wide gap with conventional, narrowed with 3D print and VR. Solid line represents mean combined scores. CDICOM - conventional DICOM. CR - cardiac radiologist. 3DP - 3D print. PCC - pediatric cardiology consultants. PCS - pediatric cardiac surgeons. PCF - pediatric cardiology fellows. VR - virtual reality.

FIGURE 3 : *Subjective parameters [10-point Likert Scale].*

3A : 'Level of difficulty' in interpretation perceived by participant subgroups using test formats - significant reduction with immersive 3D formats, VR perceived simplest. Change was most notable for fellows.

3B : 'Level of confidence' in interpretation - improved with 3D prints and VR - most notable for the fellows.

CDICOM - conventional DICOM. CR - cardiac radiologist. 3DP - 3D print. PCC - pediatric cardiology consultants. PCS - pediatric cardiac surgeons. PCF - pediatric cardiology fellows. VR - virtual reality.

FIGURE 4 : *Visualisation modes*

4 A,B,C : Computed tomography scan data of case of situs ambiguous, dextrocardia, common atrioventricular canal defect, double outlet right ventricle, pulmonic stenosis as visualised in conventional format (4A), 3D printed model (4B) and VR (4C).

4D, E : case of double outlet right ventricle, dextro-malposed Aorta, large inlet VSD with conoventricular extension. **4D** - 3D printed model with anterior walls subtracted to show intracardiac anatomy. **4E** - intracardiac anatomy with VR virtual dissection, coronal plane.

4F : intracardiac anatomy of case of double-outlet right ventricle in VR, virtual annotation of LV-to-Aorta pathway (white arrow).

4G : VR session using digital 'dissection plane', operator's position represented by 'avatar'.

VR software : 4C,E [Vea Simulations, Poland]. 4F,G [Elucis, Realize Medical, Canada]

Ao - aorta. Controllers - handheld controls. MPA main pulmonary artery. IVS - interventricular septum. LV - left ventricle. RA - right atrium. RV - right ventricle.

FIGURE 5 : Central Illustration

Interpreting cardiovascular cross-sectional imaging using conventional viewing formats requires training, experience and spatial abilities. Use of immersive 3D visualisation formats (3D prints, Extended Reality) can help overcome challenges, allowing more accurate, faster and easier interpretation, shortening learning curves and reducing differences among diverse members of cardiac team.

Figure 1

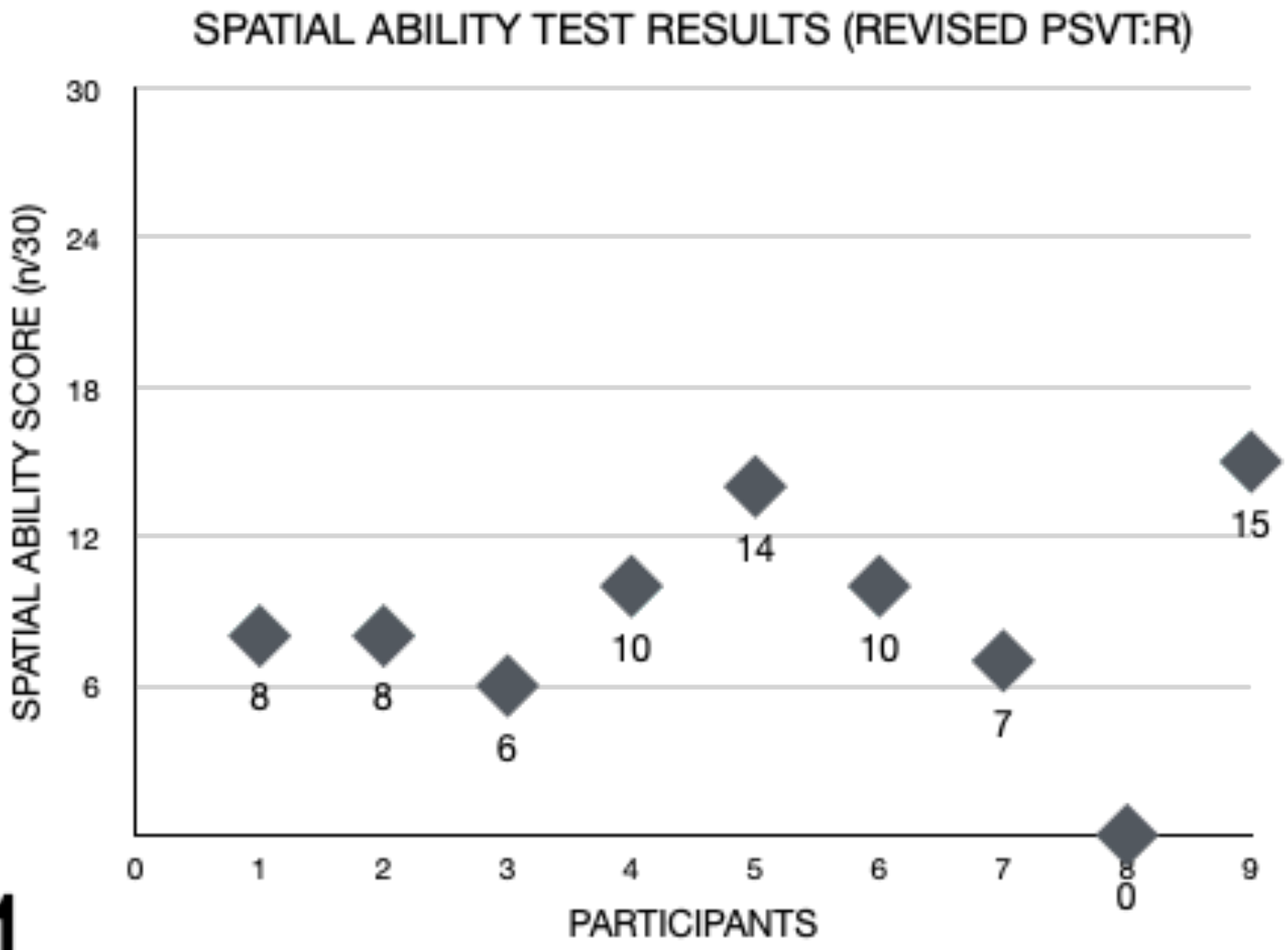
SPATIAL ABILITY TEST RESULTS (REVISED PSVT:R)
SPATIAL ABILITY SCORE (n/30)
30
24
18
12
6
0
1
2
3
4
5
6
7
8
9
8
8
6
10
14
10
7
0
15
PARTICIPANTS

1

Figure 2

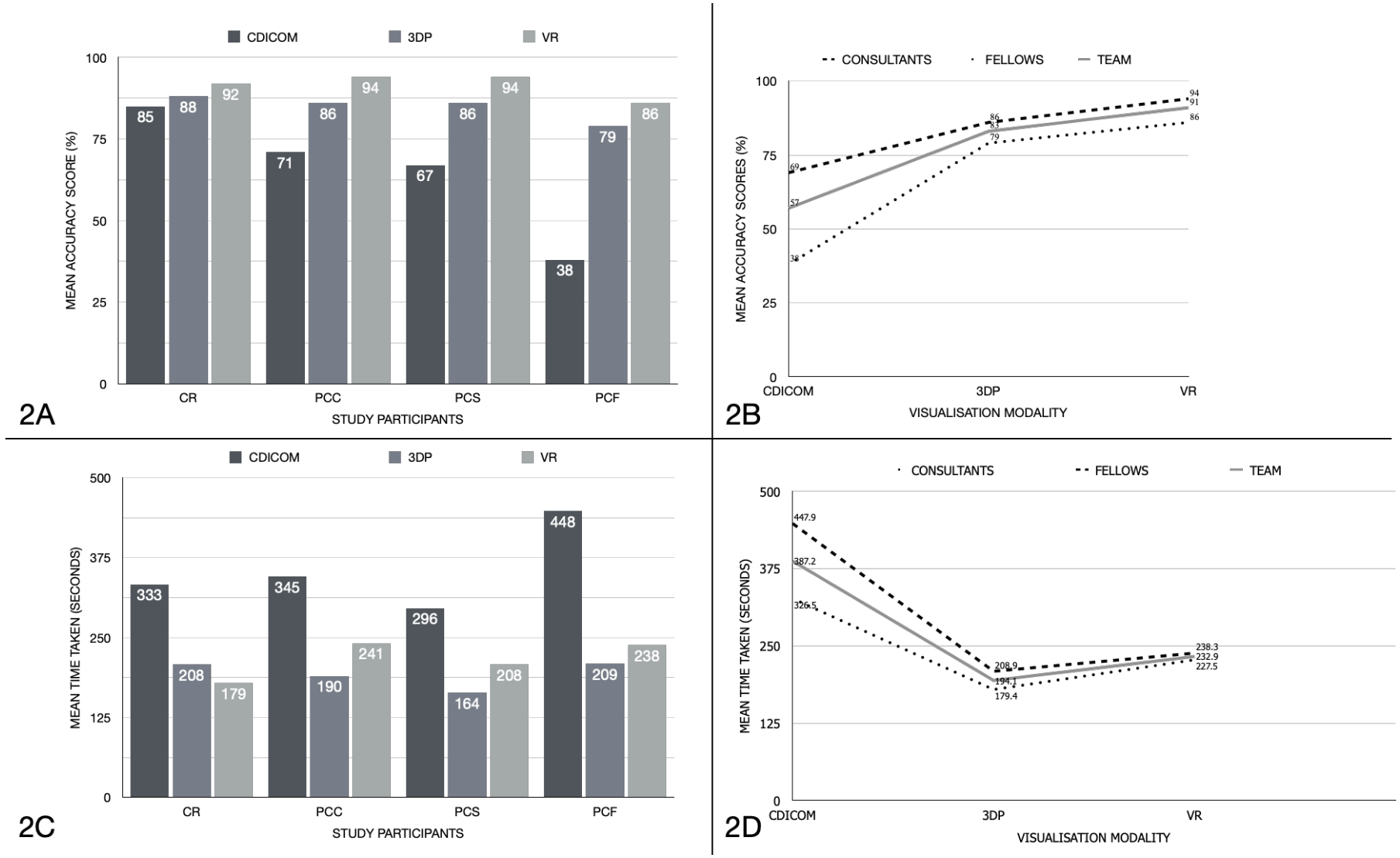
CDICOM
3DP
VR
MEAN ACCURACY SCORE (%)
100
75
50
25
0
85
88
92
71
86
94
67
86
94
38
79
86
CR
PCC
PCS
PCF
STUDY PARTICIPANTS
2A
CONSULTANTS
FELLOWS
TEAM
MEAN ACCURACY SCORES (%)
100
75
50
25
0
CDICOM
3DP
VR
VISUALISATION MODALITY
2B
CDICOM
3DP
VR
MEAN TIME TAKEN (SECONDS)
500
375
250
125
0
333
208
179
345
190
241
296
164
208
448
209
238
CR
PCC
PCS
PCF
STUDY PARTICIPANTS
2C
CONSULTANTS
FELLOWS
TEAM
MEAN TIME TAKEN (SECONDS)
500
375
250
125
0
447.9
387.2
326.5
208.9
194.1
179.4
238.3
232.9
227.5
CDICOM
3DP
VR
VISUALISATION MODALITY
2D

Figure 3

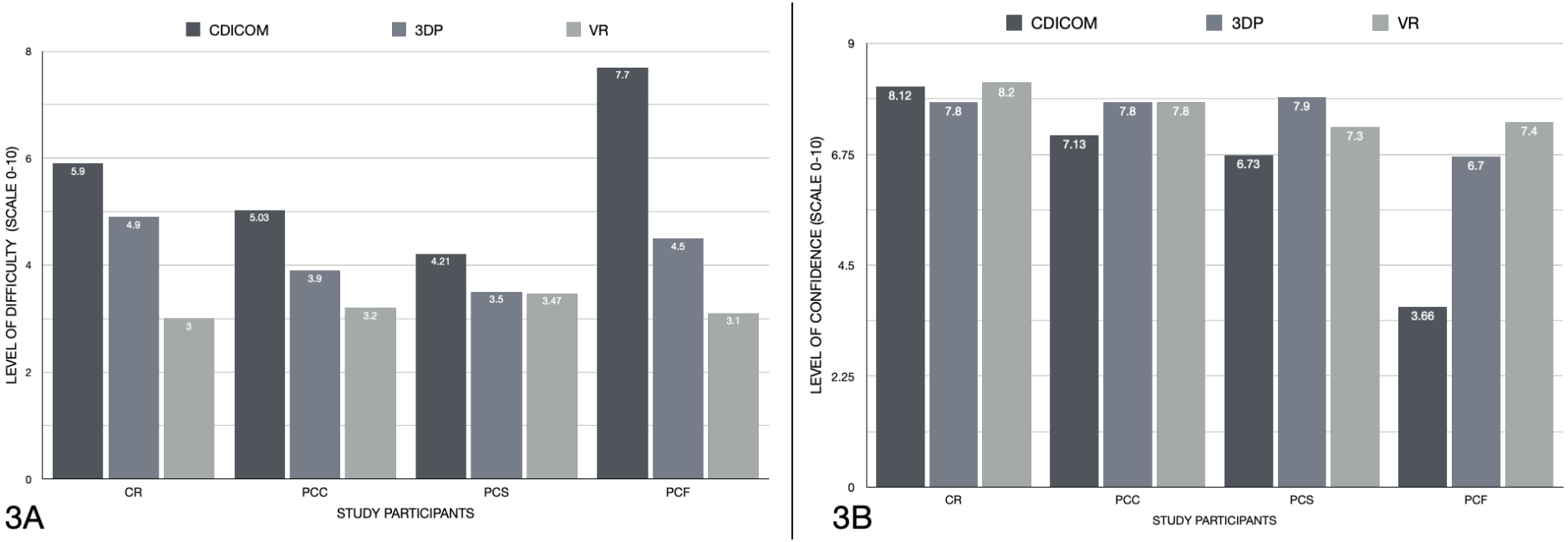
CDICOM
3DP
VR
LEVEL OF DIFFICULTY (SCALE 0-10)
8
6
4
2
0
5.9
4.9
3
5.03
3.9
3.2
4.21
3.5
3.47
7.7
4.5
3.1
CR
PCC
PCS
PCF
STUDY PARTICIPANTS
3A
CDICOM
3DP
VR
LEVEL OF CONFIDENCE (SCALE 0-10)
9
6.75
4.5
2.25
0
8.12
7.8
8.2
7.13
7.8
7.8
6.73
7.9
7.3
3.66
6.7
7.4
CR
PCC
PCS
PCF
STUDY PARTICIPANTS
3B

Figure 4

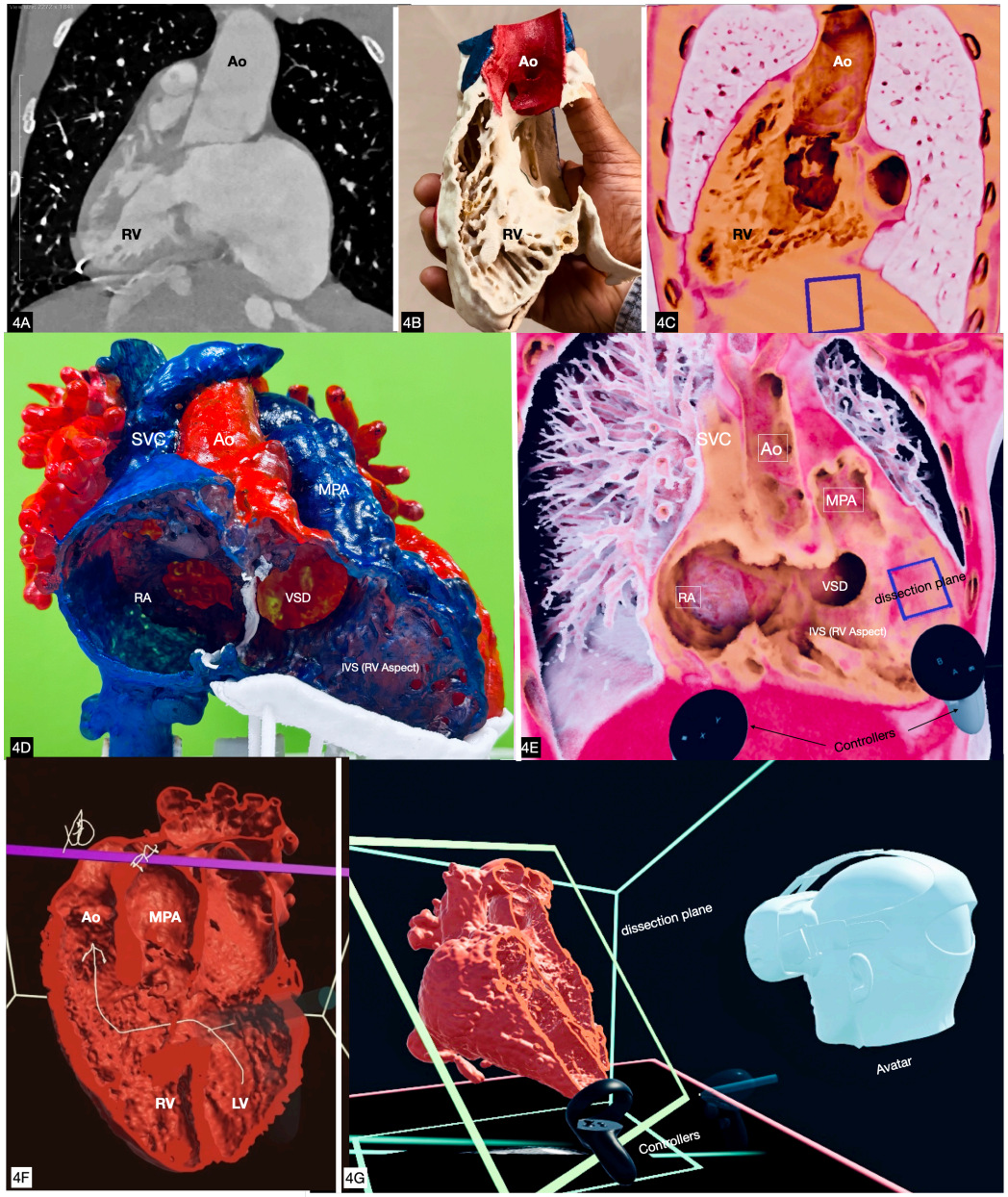
Ao
RV
4A
Ao
RV
4B
Ao
RV
4C
SVC
Ao
MPA
RA
VSD
IVS (RV Aspect)
4D
SVC
Ao
MPA
RA
VSD
dissection plane
IVS (RV Aspect)
Controllers
4E
Ao
MPA
RV
LV
4F
dissection plane
Avatar
Controllers
4G

CENTRAL ILLUSTRATION

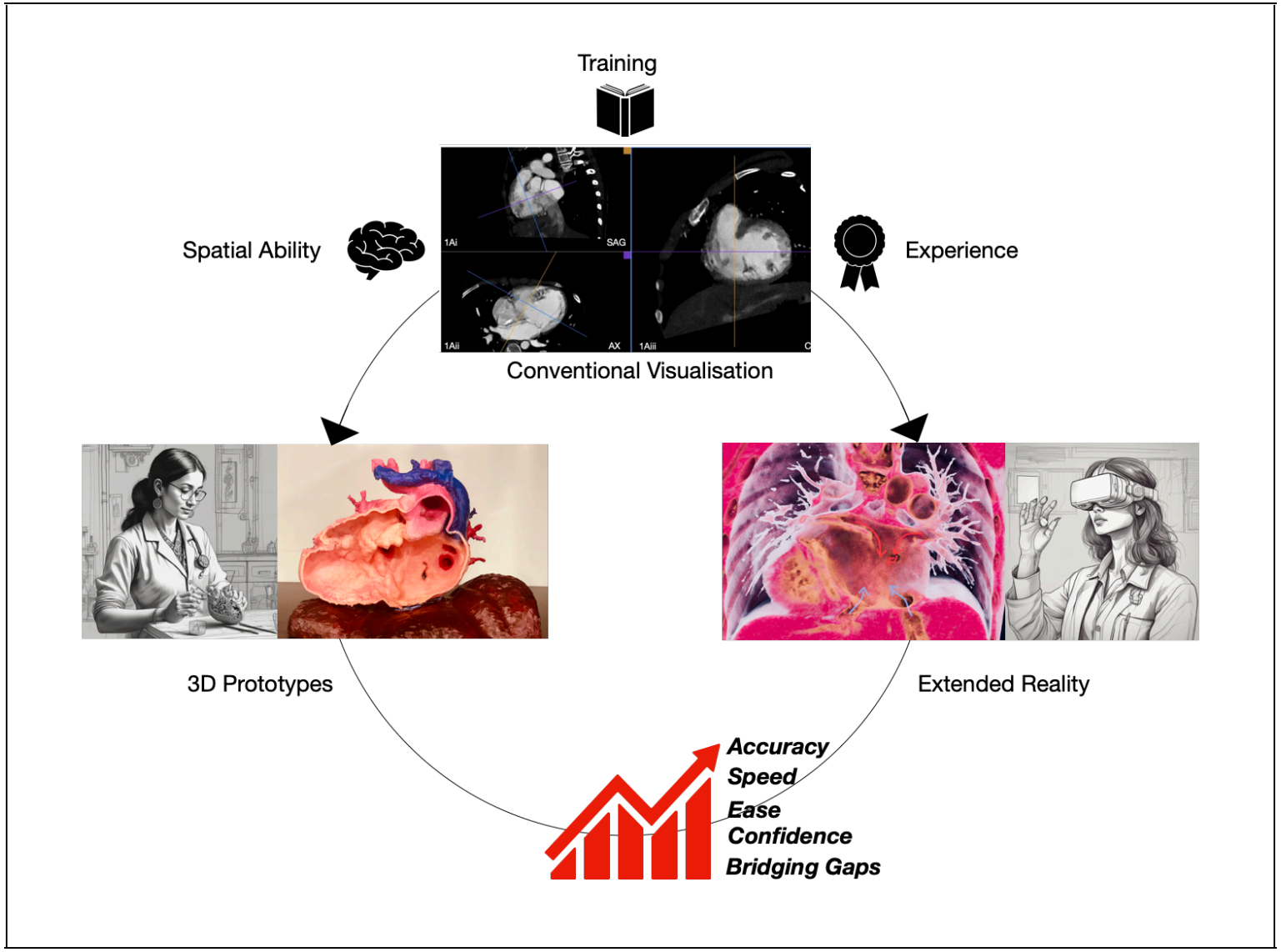

Table 1: Test-cases - basic morphological diagnosis and imaging modality

S.No	Patient Diagnosis	Modality
1	Situs ambiguous, Dextrocardia, common atrioventricular canal defect, DORV, l-malposed great arteries, post bidirectional Glenn shunt.	CT Angiogram
2	Situs solitus, levocardia, DORV, d-malposed great arteries, subpulmonic VSD, post PA Banding	CT Angiogram
3	Situs inversus, dextrocardia, DORV, l-malposed great arteries.	CT Angiogram
4	Situs solitus, Levocardia, TGA-like DORV, conoventricular VSD,post bidirectional Glenn shunt.	MR Angiogram
5	Situs solitus, Dextrocardia, atrioventricular discordance, DORV,VSD , l-malposed great arteries, post bidirectional Glenn shunt.	CT Angiogram
6	Situs solitus, Levocardia, Criss cross atrioventricular connections, DORV, d-malposed great arteries, inlet VSD	CT Angiogram
7	Situs solitus, Levocardia, DORV, d-malposed great arteries, large Inlet VSD , post PA banding	CT Angiogram
8	Situs solitus, Levocardia, TGA-like DORV, d-malposed great arteries. Conoventricular VSD, Severe PS	CT Angiogram
9	Situs solitus, Levocardia, DORV, d-malposed great arteries, conoventricular VSD, PS	CT Angiogram
10	Situs solitus, Levocardia, Large inlet VSD	CT Angiogram
11	Situs solitus,Levocardia, DORV, normally related great arteries, conoventricular VSD,Valvar PS	CT Angiogram
12	Situs inversus, Dextrocardia, DORV, l-malposed great arteries, conoventricular VSD	MR Angiogram
13	Situs inversus, Dextrocardia, DORV, l-malposed great arteries, conoventricular VSD,PS	CT Angiogram
14	Situs solitus,Levocardia, d-TGA , Restrictive VSD, PS, post Fontan	CT Angiogram
15	Situs solitus, Levocardia, normal segmental anatomy, Double Aortic arch	CT Angiogram
16	Situs solitus, Levocardia, atrioventricular discordance, DORV, normally related great arteries	CT Angiogram
17	Situs solitus, Levocardia, normal segmental anatomy, LPA sling with tracheal & left bronchial compression	CT Angiogram

DORV - Double outlet right ventricle , PA banding - Pulmonary artery banding , PS - Pulmonary Stenosis ,TGA - Transposition of great arteries ,VSD - Ventricular Septal Defect.

Table 2: Mean Accuracy (%) scores and time taken (seconds) for interpretation using the three test modalities for individual participants .

	MEAN ACCURACY (%)				TIME TAKEN			
	CDICOM (a)	**3DP (b)**	**VR (c)**	**p-value**	**CDICOM (a)**	**3DP (b)**	**VR (c)**	**p-value**
CR	84.62 ±17.65	88.12 ±15.42	91.48 ±11.02	0.151	332.88 ± 169.82	207.65 ±101.65	179.23± 73.26	<0.001
PCC1	77.79 ±17.98	90.55 ±10.14	96.49 ±6.54	<0.001	255.18 ±132.20	157.6 ±85.51	226.29 ±108.77	0.040
PCC2	70.13 ±21.87	81.75 ±15.54	93.35±8.29	<0.001	289.29±64.59	206.88 ±58.52	220.53 ±54.53	0.001
PCC3	64.18 ±15.47	85.73 ±14.850	91.81 ±8.08	<0.001	496.18 ±158.86	204.76 ±81.24	275.71 ±103.88	<0.001
PCS1	73.70 ±20.61	87.60 ±14.70	94.81 ±7.26	0.004	304.59 ±165.06	154.06 ±73.30	161.41±90.08	<0.001
PCS2	59.80 ±16.62	83.95 ±24.63	92.20 ±8.18	<0.001	287.24 ±67.02	173.53 ±110.87	253.31 ±84.05	<0.001
PCF1	34.91 ± 10.06	78.53 ±12.26	84.81 ±13.81	<0.001	569 ±135.95	237.88 ±44.72	252.35±99.22	<0.001
PCF2	32.16 ±11.15	81.18 ±14.85	85.03294 ±11.35	<0.001	422.12 ±184.87	240.47 ±90.16	204.71 ±81.97	0.001
PCF3	46.84 ±14.92	77.95 ±20.43	86.82 ±14.29	<0.001	352.71 ±117.19	148.29 ±73.29	242.24 ±88.11	<0.001
MEAN	60.46 ±7.13	83.93 ± 7.84	90.81 ± 5.03	<0.001 Sub group difference a<b,c p<0.001 b<c p=0.002	367.67 ±75.9	192.34 ±48.92	225.73 ± 47.48	<0.001 Sub group difference a>b,c p<0.001 b<c p=0.018

Table shows mean accuracy (%) and time taken (seconds) in interpreting 17 test datasets for each participant across 3 visualisation formats with p-values for the change. Mean scores for accuracy and time taken (whole cohort) for each format are shown.

CDICOM - conventional DICOM viewing. CR - Cardiac Radiologist. PCC - Pediatric Cardiology Consultant. PCS - Pediatric Cardiac Surgeon. PCF - Pediatric Cardiology Fellow-in-training. 3DP - 3D Print. VR - Virtual Reality.

Table 3 Mean Accuracy (%) scores and time taken (seconds) for interpretation using the three test modalities across participant groups .

	Category	CDICOM (a)	3DP (b)	VR (c)	P Value	Difference
ACCURACY SCORE (%)	CR	84.62 % ± 17.65	88.11%± 15.4	91.48% ± 11.02	0.151	NA
	PCC	70.7 % ± 11.2	86.02 %± 9.14	93.9% ± 5.5	<0.001	a<b, c p<0.001 b<c p=0.010
	PCS	66.8 % ± 13.21	85.77 %± 14.1	93.7% ± 6.6	<0.001	a<b, c p<0.001 b<c p=0.078
	PCF	37.95 % ± 7.08	79.2 % ± 8.96	85.8% ± 6.7	<0.001	a<b, c p<0.001 b<c p=0.017
	p-value	<0.001	0.06	0.006		
TIME TAKEN (SECONDS)	CR	332.88 ± 169.82	207.647 ±101.65	179.23 ± 73.26	<0.001	a>b p=0.006 a>c p=0.011 b>c p=0.973
	PCC	346.86± 74.89	189.72± 59.4	240.84± 60.0	<0.001	a>b,c p<0.001 b<c p=0.034
	PCS	295.92± 96.8	163.79± 76.01	207.50± 69 .15	<0.001	a>b,c p<0.001 b<c p=0.033
	PCF	447.94 ± 112.25	208.8 ± 36.98	238.27 ± 58.18	<0.001	a>b,c p<0.001 b<c p=0.089
	p-value	0.002	0.080	0 .028		

Table shows mean accuracy (%) and time taken (seconds) in interpreting test datasets for participant subgroups across 3 visualisation formats, with respective p-values for the change.

CDICOM - conventional DICOM viewing. CR - Cardiac Radiologist. PCC - Pediatric Cardiology Consultants. PCS - Pediatric Cardiac Surgeons. PCF - Pediatric Cardiology Fellows-in-training. 3DP - 3D Print. VR - Virtual Reality.

Table 4 : Distribution of Proportion of correct responses using CDICOM ,3DP, VR for individual questions in consultant and fellows group and overall scores.

SPATIAL UNDERSTANDING		CDICOM	3DP	VR	p-Value
Ventricular relationship	**Consultants**	78.40%	95.10%	99%	<0.001
	Fellows	44.2%	90.1%	94.11%	<0.001
	Overall	68.6%	94.11%	97.3%	<0.001
Atrioventricular relationship	**Consultants**	77.40%	96.40%	93.90%	<0.001
	Fellows	58.03%	93.05%	85.7%	<0.001
	Overall	61.1%	95.2%	89.68%	<0.001
Ventriculo-Arterial relationship	**Consultants**	83.30%	97.10%	100%	<0.001
	Fellows	66.6%	94.11%	94.1%	<0.001
	Overall	77.1%	96.04%	98.03%	<0.001
Great Artery arrangement	**Consultants**	84.30%	92.20%	100%	<0.001
	Fellows	72.5%	70.5%	92.1%	0.014
	Overall	81.04%	84.9%		<0.001
Type/Location of Ventricular Septal Defect	**Consultants**	62.20%	67.80%	92%	<0.001
	Fellows	20%	71.1%	80%	<0.001
	Overall	48.14%	68.8%	87.4%	<0.001
Routability of Ventricular Septal Defect to Great Artery	**Consultants**	62.70%	84%	95%	<0.001
	Fellows	10.3%	79.3%	100%	<0.001
	Overall	45.5%	81.3%	96.6%	<0.001

Great Artery override	**Consultants**	36%	58%	42%	0.302
	Fellows	8.3%	33.31%	33.31%	0.264
	Overall	25%	47.2%	36.11%	0.142

Table compares the accuracy scores of pediatric cardiac consultants (cardiologists and surgeons) with pediatric cardiology fellows-in-training while interpreting specific elements of spatial anatomy from the test datasets.

Table 5 : Subjective scores of 'level of difficulty' and 'level of confidence' while interpreting the three test modalities across participant groups.

		CDICOM (a)	3DP (b)	VR (c)	P Value	Difference
PERCEIVED LEVEL OF DIFFICULTY (LIKERT'S SCALE OF 0-10)	CR	5.94 ± 2.36	4.94 ± 2.01	3.00 ± 1.27	<0.001	a>b p=0.209 a>c p=0.001 b>c p=0.002
	PCC	5.03 ±1.00	3.94 ± 1.088	3.2± 0.97	<0.001	a>b p=0.005 a>c p<0.001 b>c p=0.095
	PCS	4.21 ± 0.81	3.47 ± 0.67	3.47± 1.15	0.004	a>b p=0.008 a>c p<0.027 b=c p=1.000
	PCF	7.7 ± 0.904	4.47 ± 0.858	3.1 ± 0.567	<0.001	a>b,c p<0.001 b>c p<0.001
	p-value	<0.001	0.011	0.319		
PERCEIVED LEVEL OF CONFIDENCE (LIKERT'S SCALE OF 0-10)	CR	8.12 ± 1.00	7.76 ± 1.64	8.17 ± 0.88	0.405	NA
	PCC	7.13 ± 0.67	7.80 ± 0.745	7.84± 0.81	0.001	a<b p=0.005 a<c p=0.006 b<c p=1.000
	PCS	6.73 ± 0.73	7.91 ± 0.51	7.29 ± 1.03	<0.001	a<b p<0.001 a<c p=0.051 b>c p=0.048
	PCF	3.66 ± 0.62	6.67 ± 0.858	7.43 ± 0.60	<0.001	a<b p<0.001 a<c p<0.001 b<c p=0.006

		CDICOM (a)	3DP (b)	VR (c)	P Value	Difference
	p-value	<0.001	0.007	<0.001		

Table shows mean ratings on 10-point Likert scale for perceived level of difficulty and level of confidence of participant subgroups while interpreting the test imaging datasets across the three visualisation formats, with respective p-values for significance.