

1 **Macular Structure Characteristics in Unilateral Idiopathic Full-Thickness Macular**

2 **Hole and the Healthy Fellow Eyes**

3 **Running title:** Macular structure characteristics in macular hole

4 Yi-Ting Hou, MD<sup>1</sup>, Chung-May Yang, MD<sup>1,2</sup>, Yi-Ting Hsieh, MD PhD<sup>1,2</sup>

5 <sup>1</sup>Department of Ophthalmology, National Taiwan University Hospital, Taipei, Taiwan

6 <sup>2</sup>College of Medicine, National Taiwan University, Taipei, Taiwan

7 **Meeting presentation:** APAO 2023, Kuala Lumpur, Malaysia.

8 **\*Corresponding Author:**

9 Yi-Ting Hsieh, MD, PhD

10 Department of Ophthalmology, National Taiwan University Hospital, Taipei, Taiwan. No. 7,

11 Chun-Shan S. Rd., Taipei, 100, Taiwan.

12 Office voice: 886-2-23123456

13 E-mail: ythyth@gmail.com

14 **Financial Support:** None

15 **Conflict of Interest:** No conflicting relationship exists for any author

16 **Keywords:** macular hole, fovea, foveal base width, retinal artery trajectory, vitreomacular

17 traction

18

19 **ABSTRACT**

20 **Aims:** To investigate the characteristics of the macular structure and foveal pit in eyes with  
21 lesions and healthy fellow eyes of patients with unilateral full-thickness macular holes  
22 (FTMH).

23 **Methods:** Patients with unilateral FTMH were retrospectively enrolled as the study group,  
24 and their age- and sex-matched individuals with no vitreomacular diseases as the control  
25 group in a medical center. FTMHs were classified as FTMH with lamellar hole-associated  
26 epiretinal proliferation (LHEP), FTMH without LHEP or FTMH without vitreomacular  
27 separation. Macular structure parameters, including foveal base width (FBW), central  
28 foveolar thickness (CFT), central subfield thickness (CST), central subfield volume (CSV),  
29 and retinal artery trajectory (RAT), were measured using optical coherence tomography and  
30 fundus photography. These parameters were compared among different FTMH groups.

31 **Results:** A total of 68 patients (39 women) with unilateral FTMH and 68 healthy controls  
32 were enrolled. The RAT of the lesioned eyes ( $0.19\pm 0.06$ ) and the healthy fellow eyes  
33 ( $0.14\pm 0.04$ ) were both smaller than those of the normal controls ( $0.37\pm 0.14$ ) ( $P<0.001$  for  
34 both). The FBW of the healthy fellow eyes ( $446.8\pm 98.2\ \mu\text{m}$ ) were significantly larger than  
35 those in the control group ( $338.4\pm 80.6\ \mu\text{m}$ ,  $P<0.001$ ). No significant differences in any  
36 macular parameters were noted among the three different types of FTMH.

37 **Conclusions:** Patients with unilateral FTMH had a wider RAT in both the lesioned and

38 healthy eyes, and a wider foveal base in their healthy fellow eyes than in normal controls.

39 Such macular structure characteristics may be prone to macular hole formation.

40

41

42

## 43 INTRODUCTION

44 Full-thickness macular hole (FTMH) predominantly affects the aging population without  
45 significant underlying disease or etiologies.<sup>1,2</sup> The prevalence is higher in females than  
46 males.<sup>3</sup> Patients with a full-thickness macular hole would suffer from visual acuity  
47 deterioration if remained untreated.<sup>4-6</sup> Although the exact pathogenesis of FTMH remains  
48 unclear, the most commonly accepted mechanism is the traction force at the vitreoretinal  
49 interface, which would induce foveal deformity and tissue disruption.<sup>2</sup> Traditionally, FTMH  
50 was thought to be caused mainly by the anteroposterior vitreomacular traction from the  
51 partially detached posterior hyaloid, and Gass proposed the classic 4-stage concept of FTMH  
52 formation.<sup>7,8</sup> With the recent advances in optical coherence tomography (OCT), the macular  
53 structure and its relationship with posterior hyaloid in FTMH can be identified and quantified  
54 more precisely.<sup>9,10</sup> Recent studies have found that traction from epiretinal membrane (ERM)  
55 may also give rise to the development of FTMH in eyes with posterior vitreous detachment  
56 (PVD).<sup>6,11,12</sup> Furthermore, our study team also found that FTMH could develop in eyes  
57 without vitreomacular separation (VMS); some of them had ERM, while some did not.<sup>13</sup> This  
58 suggests that the force underlying FTMH may also come from the centrifugal tangential  
59 traction of the posterior hyaloid or ERM.

60 In our previous study, we identified a wide-based foveal pit as a specific foveal pattern that  
61 was associated with higher incidences of vitreomacular abnormalities, including ERM and

62 FTMH.<sup>14</sup> We proposed that the widening of the foveal pit may be related to tangential  
63 centrifugal traction at the macula, which may keep dragging the macula centrifugally, leading  
64 to some vitreomacular interface change including internal limiting membrane (ILM) cleft  
65 formation, glial cell proliferation, and eventually ERM formation; on the other hand, such  
66 traction force may lead to foveal thinning, lamellar macular hole formation, and FMTH  
67 formation in the long term. Sometimes ERM and MH may exist simultaneously. Another  
68 study from our team has demonstrated that fellow eyes with unilateral ERM had a larger  
69 foveal base width (FBW) and a wider retinal artery trajectory (RAT) than the normal  
70 population;<sup>14,15</sup> These findings support our hypothesis that some tangential centrifugal  
71 traction may cause the development of ERM due to glial cell proliferation after the formation  
72 of the ILM cleft. We aimed to elucidate whether tangential centrifugal traction is also a  
73 possible cause for the development of FTMH. It is well known that patients with unilateral  
74 FTMH also have an increased risk of developing FTMH in their fellow eyes.<sup>16-18</sup> Previous  
75 studies also demonstrated that symmetric foveal configuration exists in both eyes.<sup>19,20</sup> Since  
76 the macular structure changes after the formation of FTMH, the macular structure of the  
77 fellow eyes of patients with unilateral FTMH should also provide some information regarding  
78 the vitreoretinal interface and macular structure, that may result in the formation of FTMH. In  
79 this study, we investigated the macular structure parameters in the lesioned eyes as well as the  
80 asymptomatic fellow eyes of patients with unilateral FTMH and compared them with normal

81 controls as well as among different types of FTMH.

82

## 83 **METHODS**

### 84 **Study subjects**

85 This retrospective observational study adhered to the tenets of the Declaration of Helsinki  
86 and was approved by the Research Ethics Committee of National Taiwan University Hospital  
87 (No.202111031RINA). The requirement for informed consent was waived owing to the  
88 retrospective nature of the study. Patients who presented with unilateral idiopathic FTMH and  
89 had undergone macular OCT examinations under Dr. YT Hsieh or Dr. CM Yang at the  
90 National Taiwan University Hospital from January 2018 to December 2021 were  
91 retrospectively enrolled as the study group. Exclusion criteria included the presence of high  
92 myopia (spherical equivalent of  $-6.0$  diopters or less or an axial length greater than 26 mm),  
93 posterior staphyloma, history of retinal detachment, diabetic retinopathy, retinopathy of  
94 prematurity, retinal vascular diseases, retinal dystrophy, choroidal neovascularization,  
95 posterior uveitis, previous intraocular surgeries except for cataract surgery, and any condition  
96 that may cause secondary FTMH formation. Because one specific type of FTMH, macular  
97 hole without VMS, was less prevalent, we also recruited cases of this type that had been  
98 enrolled in our previous study<sup>13</sup> for analysis in the present study. During the same period,  
99 healthy normal controls were recruited from patients who visited our hospital for routine

100 examinations, including macular OCT for cataract surgery or refractive surgery, and had no  
101 apparent vitreoretinal diseases in either eye. Those who were sex- and age-matched (same sex,  
102 age difference  $\leq 5$  years) to the cases in the study group were chosen as the control group.

103 Only one eye was randomly selected from each participant in the control group for analysis.

104 For each patient, comprehensive history taking (including age, sex, and past systemic and  
105 ocular history) and ocular examination (including best-corrected visual acuity, slit-lamp  
106 evaluation, and fundoscopy) were performed. The axial length was measured using laser  
107 interferometric biometry (Lenstar LS900; HAAG-STREIT AG, Bern, Switzerland). All  
108 patients underwent macular B-scan OCT and en face OCT angiography using the Optovue  
109 Avanti RTVue XR OCT (Optovue, Inc., Fremont, CA, USA). Fundus images were obtained  
110 using color fundus photography, fundus autofluorescence, or infrared imaging. Patients with  
111 incomplete data were excluded from this study.

#### 112 **Macular structure parameters**

113 The macular structural parameters measured in this study included FBW, central foveolar  
114 thickness (CFT), central subfield thickness (CST), central subfield volume (CSV), and RAT.

115 The measurement of these parameters has been described previously,<sup>15</sup> and will be mentioned  
116 briefly here. FBW was defined as the distance between two intersections of the ILM and a  
117 line parallel to the underlying retinal pigment epithelium layer 10  $\mu\text{m}$  above the lowest point  
118 of the foveal pit in the B-scan OCT image. We calculated the vertical and horizontal sections

119 of the B-scan OCT image and recorded the mean value as the FBW. In the study group, only  
120 fellow eyes with normal macular structures and foveal contours were evaluated for FBW.  
121 CFT was measured as the distance between the lowest point of the pit and the base of the  
122 retinal pigment epithelium layer. CST and CSV were measured at the central 1 mm-diameter  
123 area around the foveal pit, and both data were retrieved automatically using the software  
124 Optovue Avanti RTVue after the centration was checked manually for precision. CST is the  
125 average retinal thickness over this area, and CSV is the total volume of the retina in this area.  
126 The technique for calculating RAT was modified according to the method proposed by  
127 Yoshihara et al,<sup>21</sup> and has been described in our previous study. We first rotated the fundus  
128 images either clockwise by 90 degrees in the right eye or counterclockwise by 90 degrees in  
129 the left eye using ImageJ (ImageJ version 1.47; National Institutes of Health, Bethesda, MD).  
130 Second, we manually dotted the arcade arteries originating from the optic disc, and 24 dots  
131 were labeled in each fundus photograph. The X-Y coordination was calculated using ImageJ  
132 software, and the coordinated data were fitted to the best curve with a second-degree  
133 polynomial equation  $ax^2/100 + bx + c$ . Constant “a” represents the slope of the main arcade  
134 morphology, where the smaller “a” makes the artery curve far from the macula, and the larger  
135 “a” means the curve is closer to the macula.

136

137 **Statistical analysis**



138 The macular structure parameters were compared between eyes with FTMH lesions and  
139 normal controls, as well as between fellow eyes with FTMH and normal controls. Continuous  
140 variables were analyzed using Student's *t*-tests, and categorical variables were examined  
141 using the chi-square test or Fisher's exact test. We also further divided FTMH into three  
142 different types: (1) Gass' stage 2 to 4 FTMH without lamellar hole-associated epiretinal  
143 proliferation (LHEP), (2) Gass' stage 2 to 4 FTMH with LHEP, and (3) FTMH without VMS,  
144 and compared the macular structure parameters among them. Univariate and multivariate  
145 logistic regression analyses were performed to investigate predisposing factors for FTMH  
146 development. Receiver operating characteristic (ROC) curves were plotted using FBW and  
147 RAT to predict whether the fellow eye had FTMH, and the areas under the curve (AUCs)  
148 were calculated. Statistical significance was set at  $P < 0.05$ . Statistical analyses were  
149 performed using IBM SPSS Statistics for Windows version 25 (IBM Corp., Armonk, NY,  
150 USA).

151

## 152 **RESULTS**

### 153 **Demographic data**

154 This study recruited 68 patients in each of the unilateral FTMH study groups and the age-  
155 and sex-matched control group. Both groups comprised 29 males and 39 females. The  
156 average age was  $60.7 \pm 8.7$  years in the study group and  $62.0 \pm 13.5$  years in the control

157 group ( $P = 0.83$ ). The average axial length was  $23.75 \pm 1.25$  mm in the unilateral FTMH

158 group and  $23.73 \pm 0.94$  mm in the age and sex-matched control group ( $P = 0.82$ ).

159

### 160 **Macular structure parameters in unilateral FTMH and normal controls**

161 Table 1 compares macular structure parameters among the lesioned eyes of patients with

162 unilateral FTMH, fellow eyes of patients with unilateral FTMH, and normal control eyes. The

163 mean FBW was  $446.8 \pm 98.2$   $\mu\text{m}$  in the fellow eye of patients with unilateral FTMH, which

164 was much higher than that in the control group ( $338.4 \pm 80.6$   $\mu\text{m}$ ,  $P < 0.001$ ). The mean RAT

165 was  $0.19 \pm 0.06$  in the lesioned eye and  $0.16 \pm 0.04$  in the fellow eye of the patients with

166 unilateral FTMH, both smaller than the mean RAT in the control group ( $0.37 \pm 0.14$ ,  $P <$

167  $0.001$  for both). This suggests that the RAT was wider in the lesioned eyes as well as in the

168 fellow eyes of patients with unilateral FTMH than in normal controls. No significant

169 differences in RAT were present between the lesioned eyes and fellow eyes of patients with

170 unilateral FTMH ( $P = 0.248$ ). As for CFT, CST, and CSV, no significant differences existed

171 between the fellow eyes with unilateral FTMH and the normal control eyes ( $P > 0.05$ ).

Table 1. Macular structure parameters in the lesioned eyes of unilateral full-thickness macular hole, contralateral unaffected eyes, and matched disease-free control eyes.

	FTMH		Fellow		Control		P value		
	N=68		N=68		N=68		FTMH vs. Fellow	FTMH vs. Control	Fellow vs. Control
	Mean	SD	Mean	SD	Mean	SD			
AXL (mm)	23.75	1.25	23.71	1.02	23.73	0.94	0.82	0.38	0.24
FBW (μm)	-	-	446.8	98.2	338.4	80.6	-	-	<0.001
CFT (μm)	-	-	201.7	32.7	203.2	25.0	-	-	0.16
CST (μm)	-	-	245.5	35.3	248.2	17.2	-	-	0.61
CSV (μm <sup>3</sup> )	-	-	0.19	0.03	0.19	0.02	-	-	0.43
RAT	0.19	0.06	0.16	0.04	0.37	0.14	0.25	<0.001	<0.001

A value of  $P < 0.05$  was taken as statistically significant.

FTMH= Full-thickness macular hole, AXL=Axial length, FBW=Foveal base width, CFT=Central foveal thickness, CST=Central subfield thickness,

CSV=Central subfield volume, RAT=Retinal artery trajectory, SD=Standard deviation

172 *Comparison of Macular anatomical structures among different types of FTMH*

173 We divided FTMH into three groups based on different characteristics and vitreomacular  
174 association: FTMH without LHEP. FTMH with LHEP and FTMH without VMS. The FTMH  
175 size of the affected eye and the macular structure characteristics, including FBW, CFT, CST,  
176 CSV, and RAT of the fellow eye, were compared among the three groups. As shown in Table  
177 2, there were no significant differences among the three groups in any macular parameter.

Table 2. Macular structure parameters in fellow eyes of the unilateral full-thickness macular hole with different patterns.

	MH without LHEP		FTMH with LHEP		FTMH without VMS		<i>P</i> value
	N=37		N=11		N=20		
	M	SD	M	SD	M	SD	
FTMH size ( $\mu\text{m}$ )	439.7	233.8	444.4	195.0	392.6	324.8	0.80
FBW ( $\mu\text{m}$ )	450.3	105.6	446.5	114.6	432.9	65.0	0.85
CFT ( $\mu\text{m}$ )	203.4	29.1	219.7	31.7	221.5	39.2	0.15
CST ( $\mu\text{m}$ )	238.9	37.7	260.7	24.5	248.9	35.3	0.18
CSV ( $\mu\text{m}^3$ )	0.19	0.03	0.20	0.17	0.19	0.03	0.40
RAT	0.16	0.04	0.16	0.28	0.17	0.07	0.82

A value of  $P < 0.05$  was taken as statistically significant.

FTMH=Full-thickness macular Hole, LHEP=Lamellar hole-associated epiretinal proliferation, VMS=Vitreomacular separation, AXL=Axial length, FBW=Foveal base width, CFT=Central foveal thickness, CST=Central subfield thickness, CSV=Central subfield volume, RAT=Retinal artery trajectory, M=Mean, SD=Standard deviation

179 **Sexual differences in Macular structure characteristics**

180 Table 3 shows the differences in macular structure parameters between males and females  
181 in the age-matched control and study groups. In the age-matched control group, the female  
182 had larger FBW ( $370.1 \pm 88.5$  vs.  $294.1 \pm 37.1$   $\mu\text{m}$ ,  $P < 0.001$ ), thinner CFT ( $198.3 \pm 18.7$  vs.  
183  $213.4 \pm 34.3$   $\mu\text{m}$ ,  $P = 0.023$ ), thinner CST ( $244.6 \pm 17.8$  vs.  $253.5 \pm 14.1$   $\mu\text{m}$ ,  $P=0.016$ ),  
184 smaller CSV ( $0.19 \pm 0.01$  vs.  $0.21 \pm 0.02$   $\mu\text{m}$ ,  $P = 0.004$ ) and wider RAT ( $0.35 \pm 0.14$  vs.  
185  $0.41 \pm 0.13$   $\mu\text{m}$ ,  $P = 0.030$ ) than males. In the study group, females also had larger FBW and  
186 thinner CFT than males. There were no statistically significant differences in CST, CSV, or  
187 RAT scores between males and females in the study group. Interestingly, we found that RAT  
188 was larger in females than males in the normal population, but RAT in males in the study  
189 group was wider than in males in the normal group and females in the study group; however,  
190 the difference was not statistically significant ( $P = 0.275$ ).

Table 3. Comparison of macular structure parameters between males and females in normal subjects and in the fellow eyes of unilateral full-thickness macular hole

	Normal controls			Fellow eyes of unilateral FTMH		
	Male (n=29)	Female (n=39)	P value	Male (n=29)	Female (n=39)	P value
Age (years)	60.4±16.3	62.1±9.56	0.15	61.69±9.18	60.00±8.22	0.428
FBW (μm)	294.1±37.1	370.1±88.5	<b>&lt;0.001</b>	417.1±87.5	465±90.3	<b>0.032</b>
CFT (μm)	213.4±34.3	198.3±18.7	<b>0.023</b>	219.60±34.5	204.63±30.5	<b>0.045</b>
CST (μm)	253.5±14.1	244.6±17.8	<b>0.016</b>	250.51±34.4	241.5±35.9	0.325
CSV (μm <sup>3</sup> )	0.21±0.02	0.19±0.01	<b>0.004</b>	0.2±0.03	0.19±0.03	0.191
RAT	0.41±0.13	0.35±0.14	<b>0.030</b>	0.15±0.04	0.17±0.06	0.275

A value of  $P < 0.05$  was taken as statistically significant.

FTMH=Full-thickness macular Hole, AXL=Axial length, FBW=Foveal base width, CFT=Central foveal thickness, CST=Central subfield thickness, CSV=Central subfield volume, RAT=Retinal artery trajectory

## 192 **Predicting FTMH with OCT parameters of the Fellow Eyes**

193 We used a logistic regression model to investigate predisposing factors for FTMH. In the  
194 univariate analysis, a wider FBW (odds ratio [OR] = 1.014, 95% confidence interval [CI] =  
195 1.008–1.020,  $P < 0.001$ ) and wider RAT (OR = 0.793, per 0.01, 95% CI = 0.735–0.862,  $P <$   
196 0.001) were associated with FTMH in fellow eyes. After adjustment for age, sex, and axial  
197 length in multivariate analysis, FBW (OR = 1.021, 95% CI = 1.010–1.033,  $P < 0.001$ ) and  
198 RAT (OR = 0.749, per 0.01, 95% CI = 0.655–0.853,  $P < 0.001$ ) remained significantly  
199 associated with the diagnosis of FTMH (Table 4).



Table 4. Logistic regression analysis for the predisposing factors associated with full-thickness macular hole

	Simple regression			Multiple regression		
	Odds ratio	95% CI	<i>P</i> value	Odds ratio	95% CI	<i>P</i> value
Age (year)	0.997	0.964–1.031	0.86	0.971	0.888–1.062	0.53
Sex						
Female	1 (Reference)			1 (Reference)		
Male	0.856	0.438–1.673	0.65	0.275	0.049–1.528	0.14
AxL (mm)	1.237	0.832–1.839	0.24	1.073	0.539–2.138	0.84
FBW (μm)	1.014	1.008–1.020	<b>&lt;0.001</b>	1.021	1.010–1.033	<b>&lt;0.001</b>
CFT (μm)	1.009	0.996–1.022	0.16			
CST (μm)	0.997	0.984–1.010	0.62			
CSV (μm <sup>3</sup> )	0.002	0.001–6554.66	0.42			
RAT (per 0.01)	0.793	0.735–0.862	<b>&lt;0.001</b>	0.749	0.655–0.853	<b>&lt;0.001</b>

Data presented as mean ± standard deviation. A value of *P* < 0.05 was taken as statistically significant.

AxL=Axial length, FBW=Foveal base width, CFT=Central foveal thickness, CST=Central subfield thickness, CSV=Central subfield volume, RAT=Retinal artery trajectory

200 We subsequently plotted ROC curves using FBW and RAT to predict whether the  
201 fellow eye had FTMH, and the AUCs were 0.874 and 0.903 for FBW and RAT,  
202 respectively. The best threshold for FBW was 381  $\mu\text{m}$ , with a sensitivity of 82.1% and  
203 specificity of 89.8%. The best threshold for RAT was 0.215, with a sensitivity of  
204 92.1% and a specificity of 79.6%. (Figure 1)

205

## 206 **DISCUSSION**

207 It is well known that patients with unilateral MH would have a higher risk of  
208 developing FTMH in their fellow eye.<sup>4,16,18</sup> This raised our interest in studying  
209 whether predisposing factors for FTMH are also present in the fellow eyes of patients  
210 with unilateral FTMH. Through OCT, early changes in foveal configuration and  
211 visualization of the vitreomacular relationship could provide more information about  
212 the pathogenesis of FTMH formation. Two major mechanisms, anteroposterior  
213 vitreous traction and tangential vitreous traction (tangential traction), over the foveal  
214 area, are generally accepted as the main contributors to FTMH formation.<sup>6,8</sup> However,  
215 the exact pathogenesis remains unclear. In the current study, we found that the  
216 lesioned eyes and fellow eyes of patients with unilateral MH had a wider foveal base  
217 and a wider RAT than age-matched healthy controls. This implies that increasing  
218 centrifugal traction parallel to the retina may exist in these patients, which results in  
219 the widening of the RAT and foveal base and the subsequent formation of MH in one

220 eye. Yoshihara et al.<sup>21</sup> found that in patients with unilateral FTMH, the RAT was  
221 wider in the FTMH eyes than in the healthy fellow eyes, and they also proposed that  
222 tangential traction may first widen the main arcades of retinal vessels and then induce  
223 larger traction over the central foveal area to induce the formation of FTMH.  
224 Although this result was different from what we found in the present study, they also  
225 found that the RAT of FTMH eyes was highly correlated with that of their healthy  
226 fellow eyes. Both results indicated that RAT was significantly associated with the  
227 formation of FTMH. Because the vitreous is usually attached tightly to retinal vessels,  
228 the larger distance between vessels may exacerbate the tangential force on the  
229 vitreomacular interface and the central macula, which also widens the foveal  
230 base.<sup>14,15,21,22</sup> Additionally, we also found that the CST and CFT were thinner in the  
231 fellow eye of patients with unilateral FTMH than in healthy controls, although no  
232 significant statistical differences were noted. These results were similar to those of  
233 Kumagai et al.<sup>23</sup> This is compatible with our hypothesis that tangential traction plays a  
234 vital role in FTMH formation with stretching of the central retina. Furthermore, no  
235 significant FBW and RAT differences were found in fellow eyes of unilateral FTMH  
236 eyes among all three groups, including the FTMH without LHEP, FTMH with LHEP,  
237 and FTMH without VMS groups. All three groups had wider RAT and FBW.  
238 Previously, our study group reported that the strong tangential traction thickened

239 posterior hyaloid without VMS has a different pathomechanism of FTMH formation,  
240 which had no anteroposterior traction from conventional VMT.<sup>13</sup> Our results from this  
241 study support that eyes with typical idiopathic FTMH may share similar macular  
242 structure characteristics with eyes with FTMH without VMS. We propose that  
243 continuous tangential traction from the posterior hyaloid or ILM may disrupt the ILM,  
244 make the retina at the central fovea more fragile, develop cystic changes in the foveal  
245 wall, induce lamellar macular hole and LHEP formation, and finally cause  
246 FTMH.<sup>6,13,15</sup>

247 Many studies have reported that macular parameters are influenced by multiple  
248 variables,<sup>24</sup> such as age,<sup>25</sup> axial length,<sup>26</sup> and sex.<sup>27</sup> Therefore, we included these  
249 factors in the univariate and multiple regression models. Only FBW and RAT were  
250 found to be associated with the development of FTMH. Additionally, no significant  
251 differences existed in the RAT between the affected and fellow eyes in patients with  
252 unilateral MH. Both ROC curves using the FBW and RAT of the fellow eyes showed  
253 good predictions in the presence of idiopathic FTMH. Therefore, we believe that both  
254 a wider FBW and RAT are anatomic predisposing factors for FTMH rather than a  
255 post-MH change.

256 To better understand the macular structural differences between males and females,  
257 we compared macular parameters in terms of sexual differences. Our previous studies

258 have reported that females have a wider FBW and a wider RAT than males in healthy  
259 eyes.<sup>15</sup> In the current study, we found that females had wider FBW, thinner CFT, CST,  
260 CSV, and wider RAT compared to the male in normal controls. These results are  
261 consistent with those of several previous studies,<sup>14,15,21</sup> which indicated that females  
262 might have a firmer centrifugal tangential force over the foveola area, making the  
263 central retina more fragile and thinner.<sup>15</sup> CFT is the thickness at the center of the  
264 foveola; widening the foveal area would contribute to a thinner umbo of foveola and  
265 the tendency for MH formation. This phenomenon can also explain the higher  
266 incidence of MH and ERM in females than in men. In some population-based studies,  
267 females were 2.2–3.3 times more likely to be affected than males by the development  
268 of FTMH.<sup>3,28</sup> In the unilateral FTMH study group, however, we found that the RAT  
269 showed not only no statistical differences between male and female, but also that the  
270 males had even wider RAT than female population. The results indicated that stronger  
271 tangential traction might be needed for males for the development of FTMH.

272 Our study had several limitations. First, this study was designed as a cross-sectional  
273 and retrospective data collection study. Second, it is not certain whether FTMH will  
274 develop in the fellow eyes that we studied. However, we sought to reduce the bias and  
275 statistical errors by matching age and sex to those in the study group. Thus, our  
276 findings are accurate, valuable, and clinically applicable.

277

278 In conclusion, we found that eyes with FTMH had a wider RAT than age- and  
279 sex-matched normal controls. As for the healthy fellow eyes with unilateral FTMH,  
280 the FBW was wider, and the RAT was wider than that of normal controls. A wider  
281 FBW and a wider RAT in healthy eyes were predictive of the presence of FTMH in  
282 the contralateral eyes. This suggests that strong tangential traction may contribute to  
283 FTMH development by dragging the foveal pit and thinning the central foveola.  
284 Females had wider FBW, wider RAT, thinner CST, CFT, and CSV than males, which  
285 can explain the higher prevalence of MH in females.

286

## 287 **References**

- 288 1. Yeh P-T, Chen T-C, Yang C-H, Ho T-C, Chen M-S, Huang J-S, Yang C-M.  
289 Formation of idiopathic macular hole—reappraisal. *Graefe's Archive for Clinical and*  
290 *Experimental Ophthalmology*. 2010/06/01 2010;248(6):793-798.  
291 doi:10.1007/s00417-009-1297-x
- 292 2. Steel DHW, Lotery AJ. Idiopathic vitreomacular traction and macular hole: a  
293 comprehensive review of pathophysiology, diagnosis, and treatment. *Eye*. 2013/10/01  
294 2013;27(1):S1-S21. doi:10.1038/eye.2013.212
- 295 3. McCannel CA, Ensminger JL, Diehl NN, Hodge DN. Population-based

- 296 incidence of macular holes. *Ophthalmology*. Jul 2009;116(7):1366-9.  
297 doi:10.1016/j.ophtha.2009.01.052
- 298 4. Lewis ML, Cohen SM, Smiddy WE, Gass JD. Bilaterality of idiopathic macular  
299 holes. *Graefes Arch Clin Exp Ophthalmol*. Apr 1996;234(4):241-5.  
300 doi:10.1007/bf00430416
- 301 5. Berton M, Robins J, Frigo AC, Wong R. Rate of progression of idiopathic  
302 full-thickness macular holes before surgery. *Eye (Lond)*. Aug 2020;34(8):1386-1391.  
303 doi:10.1038/s41433-019-0654-1
- 304 6. Bringmann A, Unterlauff JD, Barth T, Wiedemann R, Rehak M, Wiedemann P.  
305 Different modes of full-thickness macular hole formation. *Exp Eye Res*. Jan  
306 2021;202:108393. doi:10.1016/j.exer.2020.108393
- 307 7. Gass JD. Reappraisal of biomicroscopic classification of stages of development  
308 of a macular hole. *Am J Ophthalmol*. Jun 1995;119(6):752-9.  
309 doi:10.1016/s0002-9394(14)72781-3
- 310 8. Gass JD. Idiopathic senile macular hole: its early stages and pathogenesis. 1988.  
311 *Retina*. Dec 2003;23(6 Suppl):629-39.
- 312 9. Azzolini C, Patelli F, Brancato R. Correlation between optical coherence  
313 tomography data and biomicroscopic interpretation of idiopathic macular hole. *Am J*  
314 *Ophthalmol*. Sep 2001;132(3):348-55. doi:10.1016/s0002-9394(01)01005-4

- 315 10. Spaide RF, Wong D, Fisher Y, Goldbaum M. Correlation of vitreous attachment  
316 and foveal deformation in early macular hole states. *Am J Ophthalmol*. Feb  
317 2002;133(2):226-9. doi:10.1016/s0002-9394(01)01377-0
- 318 11. Tsai CY, Hsieh YT, Lai TT, Yang CM. Idiopathic macular holes and direction of  
319 vitreomacular traction: structural changes and surgical outcomes. *Eye (Lond)*. Dec  
320 2017;31(12):1689-1696. doi:10.1038/eye.2017.141
- 321 12. Tsai CY, Hsieh YT, Yang CM. EPIRETINAL MEMBRANE-INDUCED  
322 FULL-THICKNESS MACULAR HOLES: The Clinical Features and Surgical  
323 Outcomes. *Retina*. Sep 2016;36(9):1679-87. doi:10.1097/iae.0000000000000999
- 324 13. Ang AC, Hsieh YT, Tsui MC, Lai TT, Yang CM. Idiopathic Macular Hole  
325 without Vitreomacular Separation. *Ophthalmologica*. 2022;245(2):187-193.  
326 doi:10.1159/000521731
- 327 14. Ma IH, Yang CM, Hsieh YT. Wide-based foveal pit: a predisposition to  
328 idiopathic epiretinal membrane. *Graefes Arch Clin Exp Ophthalmol*. Aug  
329 2021;259(8):2095-2102. doi:10.1007/s00417-021-05092-5
- 330 15. Ma I-H, Yang C-M, Hsieh Y-T. The Correlations of Macular Structure  
331 Characteristics With Idiopathic Epiretinal Membrane and Its Sexual Preference—A  
332 Matched Comparison Study. *Invest Ophthalmol Vis Sci*. 2022;63(2):10-10.  
333 doi:10.1167/iovs.63.2.10



- 334 16. Bronstein MA, Trempe CL, Freeman HM. Fellow eyes of eyes with macular  
335 holes. *Am J Ophthalmol*. Dec 1981;92(6):757-61.  
336 doi:10.1016/s0002-9394(14)75625-9
- 337 17. Kumagai K, Ogino N, Hangai M, Larson E. Percentage of Fellow Eyes That  
338 Develop Full-Thickness Macular Hole in Patients With Unilateral Macular Hole. *Arch*  
339 *Ophthalmol*. 2012;130(3):393-394. doi:10.1001/archophthalmol.2011.1427
- 340 18. Ezra E, Wells JA, Gray RH, et al. Incidence of idiopathic full-thickness macular  
341 holes in fellow eyes. A 5-year prospective natural history study. *Ophthalmology*. Feb  
342 1998;105(2):353-9. doi:10.1016/s0161-6420(98)93562-x
- 343 19. Tick S, Rossant F, Ghorbel I, Gaudric A, Sahel J-A, Chaumet-Riffaud P, Paques  
344 M. Foveal Shape and Structure in a Normal Population. *Invest Ophthalmol Vis Sci*.  
345 2011;52(8):5105-5110. doi:10.1167/iovs.10-7005
- 346 20. Bradley A, Applegate RA, Zeffren BS, van Heuven WA. Psychophysical  
347 measurement of the size and shape of the human foveal avascular zone. *Ophthalmic*  
348 *Physiol Opt*. Jan 1992;12(1):18-23.
- 349 21. Yoshihara N, Sakamoto T, Yamashita T, Yamashita T, Yamakiri K, Sonoda S,  
350 Ishibashi T. Wider retinal artery trajectories in eyes with macular hole than in fellow  
351 eyes of patients with unilateral idiopathic macular hole. *PLoS One*.  
352 2015;10(4):e0122876. doi:10.1371/journal.pone.0122876

- 353 22. Nowroozzadeh MH, Moshksar S, Azimi A, Rasti A, Sedaghat A. Comparison of  
354 retinal vascular arcade trajectory between eyes with an idiopathic macular hole and  
355 the healthy fellow eye. *Int Ophthalmol*. 2022/01/18  
356 2022;doi:10.1007/s10792-022-02221-9
- 357 23. Kumagai K, Hangai M, Larson E, Ogino N. Foveal Thickness in Healthy Fellow  
358 Eyes of Patients With Unilateral Macular Holes. *Am J Ophthalmol*.  
359 2013;156(1):140-148. doi:10.1016/j.ajo.2012.11.029
- 360 24. Lindtjørn B, Krohn J, Forsaa VA. Optical coherence tomography features and  
361 risk of macular hole formation in the fellow eye. *BMC Ophthalmol*.  
362 2021;21(1):351-351. doi:10.1186/s12886-021-02111-1
- 363 25. Etheridge T, Liu Z, Nalbandyan M, et al. Association of Macular Thickness With  
364 Age and Age-Related Macular Degeneration in the Carotenoids in Age-Related Eye  
365 Disease Study 2 (CAREDS2), An Ancillary Study of the Women's Health Initiative.  
366 *Translational Vision Science & Technology*. 2021;10(2):39-39.  
367 doi:10.1167/tvst.10.2.39
- 368 26. Chung YW, Choi MY, Kim J-S, Kwon J-W. The Association between Macular  
369 Thickness and Axial Length in Myopic Eyes. *Biomed Res Int*.  
370 2019;2019:8913582-8913582. doi:10.1155/2019/8913582
- 371 27. Adhi M, Aziz S, Muhammad K, Adhi MI. Macular thickness by age and gender

372 in healthy eyes using spectral domain optical coherence tomography. *PLoS One*.

373 2012;7(5):e37638. doi:10.1371/journal.pone.0037638

374 28. Forsaa VA, Lindtjørn B, Kvaløy JT, Frøystein T, Krohn J. Epidemiology and

375 morphology of full-thickness macular holes. *Acta Ophthalmol*. Jun

376 2018;96(4):397-404. doi:10.1111/aos.13618

377

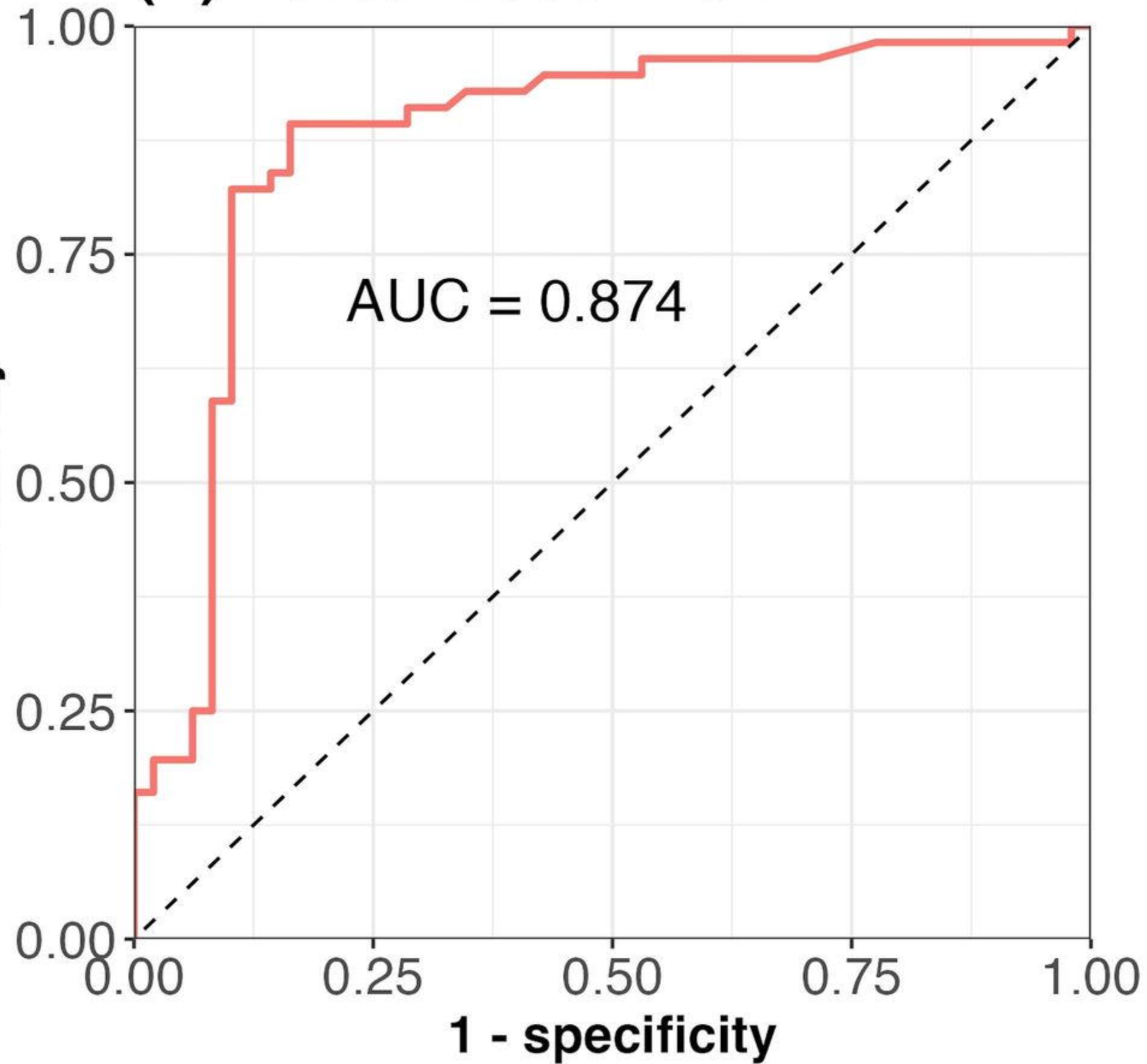
378

379 **Figure Legends**

380 Figure 1: Receiver operation characteristic curves for predicting the presence of an  
381 idiopathic macular hole using the foveal base width (FBW) or retinal artery trajectory  
382 (RAT) of the fellow eye. (A) For FBW, the area under the curve was 0.874, and the  
383 best threshold of FBW was 381.0  $\mu\text{m}$ . (B) For RAT, the area under the curve was  
384 0.903, and the best threshold of RAT was 0.215.

385

**(A) Foveal Base Width**



**(B) Retinal Artery Trajectory**

