medRxiv preprint doi: https://doi.org/10.1101/2024.02.26.24303272; this version posted February 28, 2024. The copyright holder for this preprint (which was not certified by peer review) is the author/funder, who has granted medRxiv a license to display the preprint in perpetuity. It is made available under a CC-BY-NC-ND 4.0 International license .

Clinical Diversity and Outcomes of Progressive Familial Intrahepatic Cholestasis Diagnosed by Whole Genome Sequencing in Pakistani Children

Authors:

Huma Arshad Cheema MRCP, DPGN, Professor [1, #], Aliaksandr Skrahin MD, PhD * [2, #], Anjum Saeed FCPS, MRCP Associate Professor [1], Zafar Fayyaz FCPS Associate Professor [1], Muhammad Arshad Alvi FCPS Associate Professor [1], Muhammad Nadeem Anjum FCPS Assistant Professor [1], Nadia Waheed FCPS Assistant Professor [1], Khalil Ur Rehman MD [3], Ahmad Malik MBA [2], Arndt Rolfs MD, Professor [2,4], Volha Skrahina PhD[2]

* corresponding author

# contributed equally

Affiliations:

[1] The Department of Pediatric Medicine, Division of Pediatric Gastroenterology, Hepatology and Nutrition, The Children's Hospital Lahore, University of Child Health Sciences, Lahore, Pakistan.

[2] Rare Disease Consulting RCV GmbH, Berlin, Germany.

[3] Town Women and Children Hospital, Peshawar, Pakistan

[4] University of Rostock, Medical Faculty, Rostock, Germany

Correspondence author: Dr. Aliaksandr Skrahin, Rare Disease Consulting RCV GmbH, Leibnizstrasse 58 10629, Berlin, Germany; phone: +49 15172153183, email: aliaksandr.skrahin@gmail.com,

Running title: PFIC in Pakistani Children: Genomics and Outcomes

NOTE: This preprint reports new research that has not been certified by peer review and should not be used to guide clinical practice.

medRxiv preprint doi: https://doi.org/10.1101/2024.02.26.24303272; this version posted February 28, 2024. The copyright holder for this preprint (which was not certified by peer review) is the author/funder, who has granted medRxiv a license to display the preprint in perpetuity. It is made available under a CC-BY-NC-ND 4.0 International license .

Abstract

This study analyzes 116 Pakistani children with Progressive Familial Intrahepatic Cholestasis (PFIC), diagnosed with whole genome sequencing. PFIC3 was the predominant type (44.8%), followed by PFIC2 (24.1%), PFIC1 (16.4%), PFIC4 (12.9%), and PFIC5 (1.7%). Diverging from prior studies, we found a notable absence of pruritus in a quarter of PFIC1 and PFIC3 patients, and in one-third of those with PFIC2 and PFIC4; diarrhea in 6.7% of PFIC4; hearing loss in 13.3% of PFIC4 and some PFIC3; elevated GGT levels in about half the patients with PFIC1, PFIC2, and PFIC4; anemia in 84.2%-89.3% of cases; no liver tumors observed in PFIC patients even into the second decade. Survival analysis revealed a grim 20-year cumulative survival rate of 20%. However, liver transplantation significantly improved survival to 89%, compared to 9% with standard medical treatment. PFIC3 patients showed a less aggressive disease course and better survival. This study, highlighting the genetic and phenotypic diversity within PFIC and the poor outcomes with conventional treatment, underscores the critical need for revising medical management strategies for PFIC patients.

INTRODUCTION

Bile, predominantly synthesized by hepatocytes, comprises vital components such as bilirubin, bile acids, cholesterol, lipids, and other substances essential for detoxification, maintaining cholesterol balance, nutrition, and endocrine signaling. (Bove et al. 2004) The primary bile acids, cholic acid and chenodeoxycholic acid, are liver-produced. Any disruptions in their synthesis, secretion, or modification can lead to an accumulation of bile salts, ultimately resulting in hepatic damage and cholestasis. (Heubi et al. 2007) Consequently, advanced cholestatic liver diseases form a highly varied group of conditions, with recent research identifying multiple specific proteins responsible for these diseases. (Sticova et al. 2018; Vitale et al. 2018)

medRxiv preprint doi: https://doi.org/10.1101/2024.02.26.24303272; this version posted February 28, 2024. The copyright holder for this preprint (which was not certified by peer review) is the author/funder, who has granted medRxiv a license to display the preprint in perpetuity. It is made available under a CC-BY-NC-ND 4.0 International license .

Hereditary cholestatic disorders, typically presenting in infancy and childhood, follow an autosomal recessive inheritance pattern. (Dixon et al. 2017) Their phenotypic range extends from the severe progressive familial intrahepatic cholestasis (PFIC) to the milder, intermittent, non-progressive benign recurrent intrahepatic cholestasis (BRIC). (Vitale et al. 2019) There have been limited studies detailing the genetic and clinical spectrum in larger patient groups, often lacking specific genotype/phenotype correlations. (Gupta and Karpen 2014) Genetic factors are implicated in a significant proportion of pediatric cholestatic liver diseases, with estimates suggesting that at least 45% have a genetic basis. (Gunaydin and Bozkurter Cil 2018)

This study reports on the mutation landscape in a cohort of 116 clinically diagnosed pediatric patients from Pakistan with cholestatic liver diseases. The high incidence of consanguinity in our population increases the prevalence of autosomal recessive diseases, and the larger family sizes present additional recurrence challenges for the families involved. Given the known genetic heterogeneity of cholestatic liver disease, identifying the underlying mutations in children has been challenging. To overcome this, we implemented clinical genome sequencing in routine diagnostics for patients with cholestatic liver disease. To the best of our knowledge, this cohort of PFIC patients is the most extensive reported to date. Our focus was on the diversity of clinical manifestations and the impact of different genetic variants of PFICs on clinical outcomes.

RESULTS

Patient Cohort and Clinical Findings

Our study included patients with five different types of Progressive Familial Intrahepatic Cholestasis (PFIC): PFIC1 (*ATP8B1*) - 19 cases, PFIC2 (*ABCB11*) - 28 cases, PFIC3 (*ABCB4*) - 52 cases, PFIC4 (*TJP2*) - 15 cases, and PFIC5 (*NR1H4*) - 2 cases. In each PFIC subtype, cases were marked by homozygous mutations in their respective genes (*ATP8B1, ABCB11, ABCB4, TJP2*, and *NR1H4*), all classified as either pathogenic

medRxiv preprint doi: https://doi.org/10.1101/2024.02.26.24303272; this version posted February 28, 2024. The copyright holder for this preprint (which was not certified by peer review) is the author/funder, who has granted medRxiv a license to display the preprint in perpetuity. It is made available under a CC-BY-NC-ND 4.0 International license .

or likely pathogenic (P/LP). Notably, one rare occurrence of PFIC2 involved a compound heterozygous mutation in the *ABCB11* gene. Additionally, a singular case of PFIC3, associated with the *ABCB4* gene, exhibited a variant of uncertain significance (VUS) (Supplementary Table 1). Detailed clinical and laboratory findings pertaining to these cases are outlined in Tables 1 and 2.

The distribution of PFIC patients in our cohort was as follows: PFIC1 (*ATP8B1*) - 19 (16.4%), PFIC2 (*ABCB11*) - 28 (24.1%), PFIC3 (*ABCB4*) - 52 (44.8%), PFIC4 (*TJP2*) - 15 (12.9%), PFIC5 (*NR1H4*) - 2 (1.7%). Notably, age, weight, and height were highest among PFIC3 patients and lowest in PFIC2 patients. The follow-up period ranged from 2 to 43 months, with clinical manifestations varying from mild/moderate to end-stage liver disease. Due to the small number of PFIC5 patients, comparisons were not made with other groups.

A significant proportion of patients reported a family history of liver issues: 52.6% in PFIC1 and 73.1% in PFIC3. Common clinical findings included hepatomegaly and jaundice (including scleral icterus), with increased direct and/or total bilirubin levels observed in all cohort patients. Acholic stool was more prevalent in PFIC2 patients (46.4%) and less so in PFIC3 patients (23.1%). Pruritus was less frequent in PFIC2 (60.7%) compared to other groups (66.7%-79.0%). Splenomegaly was less common in PFIC1 patients (47.4%) compared to others (75.0%-86.7%). All PFIC4 patients showed stunted growth or failure to thrive, while this was observed in 82.1% of PFIC2 patients.

Almost all patients exhibited abnormal blood coagulation tests (activated partial thromboplastin time ratio [aPTT/R]), with bleeding episodes notably more frequent in the PFIC4 group (66.7%); in contrast, only 15.8% of PFIC1 and 17.9% of PFIC2 patients reported bleeding. Diarrhea was reported in 59.4% of PFIC1 patients, with lower frequencies in other groups (3.9%-14.3%). Clinical signs of portal hypertension were observed across all groups, more commonly in PFIC4 (46.7%) and less in PFIC1 (5.3%). Sensorineural hearing loss was reported in PFIC1 (15.8%), PFIC3 (1.9%), and PFIC4 (13.3%) patients. Ultrasound investigations confirmed intrahepatic cholestasis in most cases.

medRxiv preprint doi: https://doi.org/10.1101/2024.02.26.24303272; this version posted February 28, 2024. The copyright holder for this preprint (which was not certified by peer review) is the author/funder, who has granted medRxiv a license to display the preprint in perpetuity. It is made available under a CC-BY-NC-ND 4.0 International license .

Gamma-glutamyl transferase (GGT) levels were elevated in about half of PFIC1 (68.4%), PFIC2 (42.9%), and PFIC4 (40.0%) patients, with increases typically below 2 upper limits of normal (<2 ULN). However, GGT levels were significantly elevated (>3 ULN) in 96.2% of PFIC3 patients. Nearly all patients in each group showed elevated aspartate aminotransferase (AST) and alanine aminotransferase (ALT) levels, while the prevalence of elevated alkaline phosphatase (AP) varied from 0% to 42.3%, being highest in PFIC3 and lowest in PFIC4. Alpha-fetoprotein (AFT) levels, tested in 7 patients, were within the normal range in only one PFIC3 patient. Low platelet (PLT) counts were observed in up to 20% of PFIC patients, and most exhibited low hemoglobin (Hb) levels.

Liver biopsy was conducted in 11 PFIC patients, with results aligning with expectations. Western blotting and immunofluorescence microscopy, conducted for two patients, confirmed the presence of bile salt export pump (BSEP) and absence of multidrug resistance P-glycoprotein 3 (MDR3) -specific antibodies, indicative of PFIC2 phenotypical features.

Table 1. PFIC patients' clinical data.

	PFIC1 (APT8B1)	PFIC2 (ABCB11)	PFIC3 (ABCB4)	PFIC4 (TJP2)	PFIC5 (NR1H4)
n (%)	19 (16.4%)	28 (24.1%)	52 (44.8%)	15 (12.9%)	2 (1.7%)
m/f	11/8	14/14	27/25	11/4	2/0
Age (month) median (range)	47 (20-227)	40.5 (15-107)	98 (23-160)	47 (18-203)	47.5 (44-51)
Weight (kg), median (range)	12 (8-28)	11.5 (6-22)	18.5 (9-30)	12 (6-48)	12.5 (12-13)
Height (cm), median (range)	96 (74-146)	85 (74-120)	117 (76-145)	94 (76-160)	92 (88 -96)
Follow-up time (month), median (range)	18 (3-41)	24.5 (2-43)	18 (2 - 41)	27 (3 -41)	22 (18-26)
History [1], n (%)	10 (52.6)	18 (64.3)	38 (73.1)	10 (66.7)	1 (50)
Jaundice, n (%)	19 (100)	28 (100)	52 (100)	15 (100)	2 (100)
Scleral icterus, n (%)	19 (100)	28 (100)	52 (100)	15 (100)	2 (100)
Acholic stools, n (%)	7 (36.8)	13 (46.4)	12 (23.1)	5 (33.3)	0 (0)
Pruritus, n (%)	15 (79.0)	17 (60.7)	38 (73.1)	10 (66.7)	1 (50)
Hepatomegaly, n (%)	19 (100)	28 (100)	52 (100)	15 (100)	2 (100)
Splenomegaly, n (%)	9 (47.4)	21 (75.0)	39 (75.0)	13 (86.7)	2 (100)

medRxiv preprint doi: https://doi.org/10.1101/2024.02.26.24303272; this version posted February 28, 2024. The copyright holder for this preprint (which was not certified by peer review) is the author/funder, who has granted medRxiv a license to display the preprint in perpetuity. It is made available under a CC-BY-NC-ND 4.0 International license .

Bleeding, n (%)	3 (15.8)	5 (17.9)	22 (42.3)	10 (66.7)	1 (50)
Portal hypertension [2] , n (%)	1 (5.3)	10 (35.7)	19 (36.5)	7 (46.7)	0 (0)
Diarrhea, n (%)	11 (57.9)	4 (14.3)	2 (3.9)	1 (6.7)	0 (0)
Stunted growth, n (%)	18 (94.7)	23 (82.1)	47 (90.4)	15 (100)	2 (100)
Hearing loss [3], n (%)	3 (15.8)	0 (0)	1 (1.9)	2 (13.3)	0 (0)
intrahepatic cholestasis (US [4]), n (%)	17 (89.5)	26 (92.9)	47 (90.4)	14 (93.3)	1 (50)

1 - history of liver problems in the family; 2 - esophageal varicose, gastrointestinal bleeding, ascites, "caput medusae", encephalopathy, swelling of the legs; 3 - sensorineural; 4 - ultrasound investigation.

Table 2. PFIC patients' laboratory findings.

Test	PFIC1 n=19	PFIC2 n=28	PFIC3 n=52	PFIC4 n=15	PFIC5 n=2
Bil. tot. > 1.0 mg/dL	19 (100%)	28 (100%)	51 (98.1%)	15 (100%)	2 (100%)
Bil. con. > 0.3 mg/dL	19 (100%)	28 (100%)	52 (100%)	15 (100%)	2 (100%)
GGT > 55 IU	13 (68.4%)	12 (42.9%)	50 (96.2%)	6 (40%)	0 (0%)
AP > 350 IU	2 (10.5%)	5 (17.9%)	22 (42.3%)	0 (0%)	0 (0%)
ALT > 40 IU	18 (94.7%)	27 (96.4%)	52 (100%)	15 (100%)	2 (100%)
AST > 40 IU	19 (100%)	27 (96.4%)	51 (98.1%)	15 (100%)	2 (100%)
aPTT(R) > 1.2	19 (100%)	28 (100%)	49 (94.2%)	15 (100%)	2 (100%)
INR > 1.2	18 (94.7%)	24 (85.7%)	44 (84.6%)	13 (86.75)	2 (100%)
PLT < 150*10^9 /L	1 (5,3%)	2 (7,1%)	9 (17.3%)	3 (20%)	0 (0%)
Hg < 110 g/L	16 (84.2%)	25 (89.3%)	44 (84.6%)	13 (86.7%)	2 (100%)
AFP > 25µg/L	not done	2/2	2/3 (66.7%)	1/1 (100%)	1/1 (100%)

Bil tot - bilirubin total; Bil. con. - bilirubin conjugated; GGT - Gamma-glutamyl transferase; AP - alkaline phosphatase; AST - aspartate aminotransferase; ALT - alanine aminotransferase; aPTT(R) - activated partial thromboplastin time ratio; INR - international normalized ratio; PLT - blood platelet count; Hb - hemoglobin; AFT - alpha-fetoprotein; n/a - not available.

Management and outcomes of PFICs

In our cohort, the treatment strategy for Progressive Familial Intrahepatic Cholestasis (PFIC) patients primarily included oral administration of ursodeoxycholic acid (UDCA) and fat-soluble vitamins (A, D, E, K), supplemented by nutritional interventions. For symptomatic relief of pruritus, agents such as cholestyramine and rifaximin were prescribed when necessary. Surgical interventions were also part of the treatment regimen, with nine patients undergoing Biliary Diversion (BD) and ten patients receiving liver transplants (LT).

The overall survival rate post-PFIC diagnosis was notably low at 12% (95% CI 1%-36%) (Figure 1).

medRxiv preprint doi: https://doi.org/10.1101/2024.02.26.24303272; this version posted February 28, 2024. The copyright holder for this preprint (which was not certified by peer review) is the author/funder, who has granted medRxiv a license to display the preprint in perpetuity. It is made available under a CC-BY-NC-ND 4.0 International license .

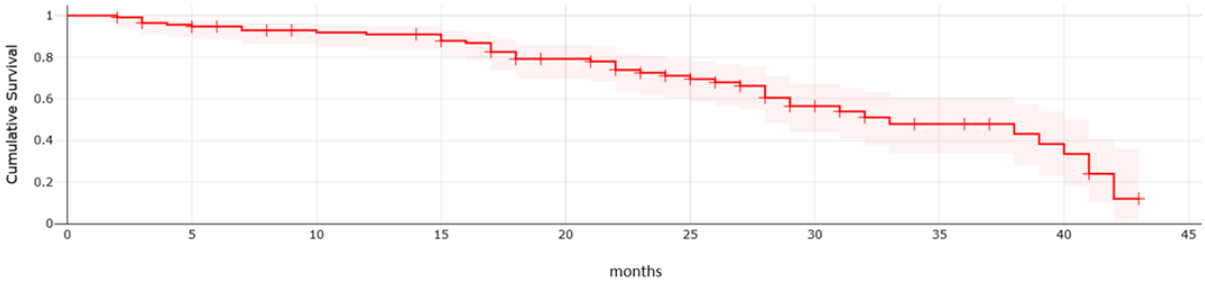

Figure 1. Cumulative survival (95% confidence interval) after PFIC diagnosis: 12% (95% CI 1%-36%).

Recognizing the hereditary nature of PFICs and the frequent delays in genetic diagnosis, we focused on assessing the cumulative survival rather than post-diagnosis survival. Over a 20-year period (240 months), the cumulative survival rate for all PFIC patients was 20% (95% CI 5%-41%) (Figure 2).

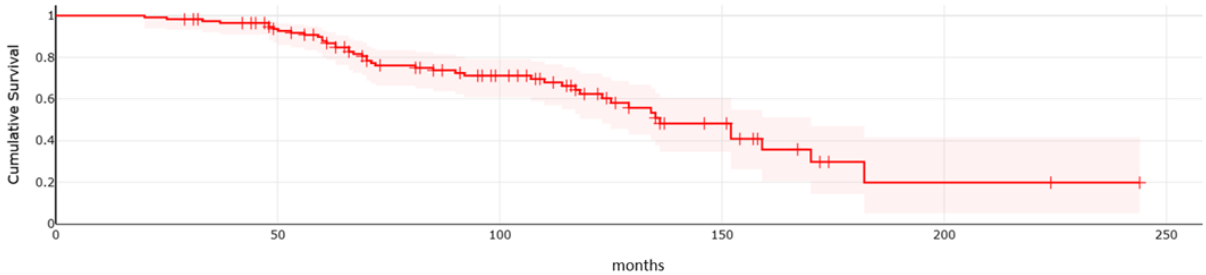

Figure 2. PFIC patients' cumulative survival (95% confidence interval) after birth: 20% (95% CI 5%-41%).

Of the 10 PFIC patients who underwent LT, only 1 patient succumbed, in contrast to 44 of the 106 patients (42%) who were treated with standard non-surgical methods. Despite LT being performed in cases with severe disease or at an advanced stage, the 20-year survival rate post-LT was significantly higher at 89% (95% CI 43%-98%), compared to a mere 9% (95% CI 1%-29%) for those not undergoing LT; p-value = 0.0161994 (Figure 3).

medRxiv preprint doi: https://doi.org/10.1101/2024.02.26.24303272; this version posted February 28, 2024. The copyright holder for this preprint (which was not certified by peer review) is the author/funder, who has granted medRxiv a license to display the preprint in perpetuity. It is made available under a CC-BY-NC-ND 4.0 International license .

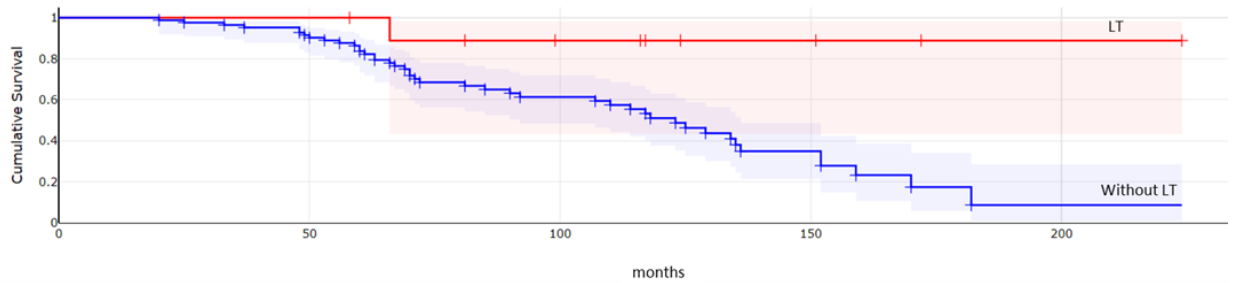

Figure 3. PFIC patients' cumulative survival (95% confidence interval) after birth without liver transplant (LT): 9% (95% CI 1%-29%) and with LT: 89% (95% CI 43%-98%), p-value = 0.0161994.

Among the four PFIC types with a sufficient patient population for analysis, PFIC3 exhibited a less aggressive course, with a better survival outcome compared to PFIC1, PFIC2, and PFIC4 (p-value = 0.0228919) (Figure 4).

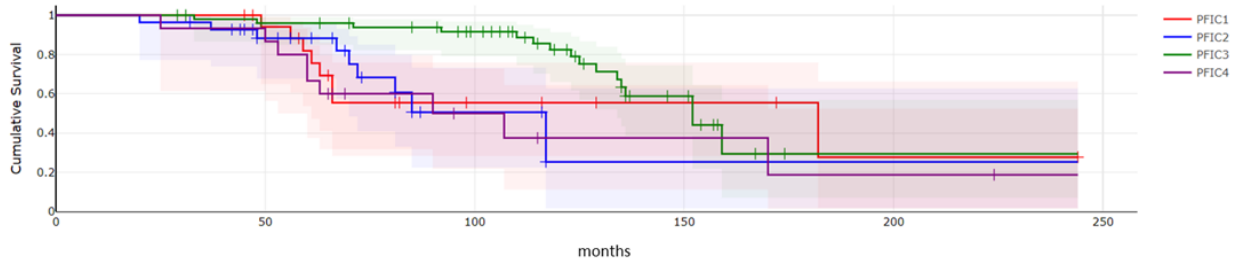

Figure 4. Cumulative survival (95% Confidence Interval) after birth: PFIC1– 27% (95% CI 2%-66%); PFIC2 – 25% (95% CI 2%-63%); PFIC3 – 29% (95% CI 7%-57%); PFIC4 – 19% (95% CI 1%-52%). PFIC3 showed better survival outcome than other PFICs, p-value = 0.0228919.

Specifically, for PFIC1 (*ATP8B1*), alongside medical treatments, 3 of 19 patients underwent BD, and 5 received LT. The 12-year survival rate was 27% (95% CI 2%-66%) (Figure 4); without LT, this rate dropped to 18% (95% CI 1%-53%), p-value = 0.194863.

In the PFIC2 (*ABCB11*) group, two patients received 4-phenylbutyrate for hyperammonemia, with five undergoing BD and one receiving LT. The 20-year survival rate was 25% (95% CI 2%-63%) (Figure. 4). Notably, none of the six patients who underwent BD or LT passed away, in contrast to 9 of 22 patients (41%) on standard medical treatment.

medRxiv preprint doi: https://doi.org/10.1101/2024.02.26.24303272; this version posted February 28, 2024. The copyright holder for this preprint (which was not certified by peer review) is the author/funder, who has granted medRxiv a license to display the preprint in perpetuity. It is made available under a CC-BY-NC-ND 4.0 International license .

For PFIC3 (*ABCB4*), three patients had LT, with a 20-year survival rate of 29% (95% CI 7%-57%) (Figure 4). None of the PFIC3 LT patients died, while 16 (31%) of the other PFIC3 patients did.

In the study of PFIC4 (*TJP2*), the cumulative survival rate was found to be 19% (95% CI 1%-52%), as shown in Figure 4. Among the subjects, one patient who underwent LT is currently alive. In contrast, 9 out of the remaining 14 patients with PFIC4, which represents 60% of that group, have succumbed to the condition.

Lastly, both patients with PFIC5 (*NR1H4*) experienced severe progressive disease and passed away having not undergone any surgical interventions.

DISCUSSION

The evolution of genomic technologies and the discovery of genes linked to Mendelian liver diseases have substantially enhanced our comprehension, detection, and detailed understanding of their pathophysiological mechanisms. In our research, we assessed the efficacy of WGS in genetically diagnosing 116 children with Progressive Familial Intrahepatic Cholestasis (PFICs). The cohort selected for our study comprised patients who had undergone extensive clinical evaluations and numerous tests, yet their conditions remained undiagnosed conclusively. In our cohort, PFIC3 emerges as the predominant subtype, representing nearly half of the cases at 44.8%. This is followed by PFIC2, PFIC1, PFIC4, and PFIC5, which comprise 24.1%, 16.4%, 12.9%, and 1.7% of the cases, respectively. Our findings are in line with those of previous research. Notably, earlier studies included diverse patient populations from France,(Davit-Spraul et al. 2010) Germany, (Müllenbach and Lammert 2011) India (Sharma et al. 2018) and the United States, encompassing Caucasian, African-American, Japanese, and Korean origins. (Lang et al. 2006) In these studies, as well, PFIC1, PFIC2, and PFIC3 were identified as the most common types of PFIC cases.

medRxiv preprint doi: https://doi.org/10.1101/2024.02.26.24303272; this version posted February 28, 2024. The copyright holder for this preprint (which was not certified by peer review) is the author/funder, who has granted medRxiv a license to display the preprint in perpetuity. It is made available under a CC-BY-NC-ND 4.0 International license .

Clinical and laboratory manifestations, as well as the disease course of various PFIC types, have been extensively documented in a multitude of studies, ranging from individual case reports to comprehensive reviews collating data from numerous publications on PFICs. The clinical presentations in our study largely align with those reported previously. However, we have identified some notable discrepancies, which we will focus on, particularly those aspects in our patient cohort that diverge from the results of previous publications. a) Pruritus and Jaundice: While jaundice and pruritus are commonly regarded as hallmark symptoms of cholestasis, (Amirneni et al. 2020; Amendola and Squires 1993; Siddiqi and Tadi 2023) our findings suggest a less consistent presentation. We observed that around a quarter of PFIC1 and PFIC3 patients, and a third of PFIC2 and PFIC4 patients, did not report pruritus. b) Diarrhea in PFIC Patients: Diarrhea is a known symptom in PFIC1, PFIC2, and PFIC3 patients, with PFIC1 often showing this as a pathognomonic feature. (Amirneni et al. 2020) Consistent with this, half of our PFIC1 patients experienced diarrhea, alongside 14.3% of PFIC2 and 3.9% of PFIC3 patients. Interestingly, a significant 6.7% of PFIC4 patients also presented with diarrhea. c) Hearing Loss: PFIC1 has been associated with hearing loss, (Amirneni et al. 2020)(Zhang et al. 2020) which our study corroborates. Additionally, we discovered that 13.3% of PFIC4 patients and one out of 52 PFIC3 patients also developed hearing loss. d) GGT Levels: Typically, an increase in Gamma-Glutamyl Transferase (GGT) is characteristic of PFIC3. (Amirneni et al. 2020; Zhang et al. 2020) with other types showing normal or low levels. However, our data slightly deviates, showing that besides the anticipated significant increase in GGT in PFIC3 patients (96.2%), about half of PFIC1, PFIC2, and PFIC4 patients also exhibited elevated GGT levels, though these increases were moderate (<2 ULN). e) AFP Levels: An elevation in Alpha-Fetoprotein (AFP) has been previously noted in PFIC5. (Amirneni et al. 2020; Amendola and Squires 1993; Gomez-Ospina et al. 2016) In our cohort, AFP was tested in seven patients across different PFIC types, with only one patient showing normal levels. The remaining six patients, including those with PFIC2 -2, PFIC3 -2, PFIC4 -1, and PFIC5 -1, had elevated AFP levels. f) Anemia in PFIC Patients: A

medRxiv preprint doi: https://doi.org/10.1101/2024.02.26.24303272; this version posted February 28, 2024. The copyright holder for this preprint (which was not certified by peer review) is the author/funder, who has granted medRxiv a license to display the preprint in perpetuity. It is made available under a CC-BY-NC-ND 4.0 International license .

significant majority of our PFIC patients (84.2%-89.3%) developed anemia, a condition not typically reported as characteristic for PFICs. (Amirneni et al. 2020; Amendola and Squires 1993; Siddiqi and Tadi 2023; Agarwal et al. 2016; Baker et al. 2019; Srivastava 2014) This finding is intriguing, considering that malabsorption and bleeding due to vitamin K deficiency, common in PFICs, could potentially lead to anemia.

The causes of mortality among PFIC patients in our study were varied, encompassing infections, bleeding (including cerebral, gastrointestinal, and splenic), liver failure, and complications stemming from cholestasis such as acute infections, dehydration, and gastrointestinal bleeding. A common feature among all PFIC types in our cohort was their poor prognosis, with a low cumulative survival rate of 20% over 20 years (95% CI 5%-41%). Consistent with previous reports, untreated PFIC1 and PFIC3 typically progress to end-stage liver disease and death within 10-20 years, with an even earlier onset in cases of PFIC2. Survival rates for those who did not undergo surgery dropped to 50% by age 10, with virtually no survivors by age 20 years. A review of 10 studies showed mortality rates ranging from 0-87%, with the median age at death being 4 years. (Baker et al. 2020) This high mortality rate underscores the frequent need for liver transplantation (LT) in PFIC1 and PFIC2 patients, with rates between 40-100%.

Literature indicates that three of the five PFIC types identified in our study (PFIC2, PFIC4, and PFIC5) are particularly aggressive, often rapidly progressing to end-stage liver disease. (Amendola and Squires 1993) This aligns with our observations: PFIC3 exhibited a less aggressive course compared to PFIC1, PFIC2, and PFIC4 in the first decade; the two patients diagnosed with PFIC5 exhibited severe progressive disease, both succumbed to their condition.

While literature suggests that PFIC2, PFIC3, and PFIC4 carry an elevated risk for the development of liver tumors, (Zhou et al. 2015) our cohort presented a different scenario. We did not observe liver tumors in any of these groups, including among patients who had entered their second decade of life.

medRxiv preprint doi: https://doi.org/10.1101/2024.02.26.24303272; this version posted February 28, 2024. The copyright holder for this preprint (which was not certified by peer review) is the author/funder, who has granted medRxiv a license to display the preprint in perpetuity. It is made available under a CC-BY-NC-ND 4.0 International license .

Our study acknowledges certain limitations. Firstly, there is a possibility that patients with a late onset of symptoms, particularly in their second decade, were not captured in our study. Additionally, this study did not include patients exhibiting mild-to-moderate forms of the disease, such as Benign Recurrent Intrahepatic Cholestasis (BRIC) and Intrahepatic Cholestasis of Pregnancy (ICP). Secondly, the clinical symptoms and laboratory findings associated with Progressive Familial Intrahepatic Cholestasis (PFIC) can evolve over the course of the disease. For example, certain markers indicative of liver injury might be less prominent in early stages, intensify as liver damage escalates, and then diminish as liver fibrosis or cirrhosis sets in. Likewise, symptoms and signs of liver failure and portal hypertension may develop and progress as the disease advances. It's important to note that our study's assessment of clinical symptoms and laboratory findings was based on a cross-sectional approach, using data from the most recent patient visits, rather than a longitudinal analysis over time.

In conclusion.

Prevalence of PFIC types in Pakistan: Our study reveals that PFIC3 is the most prevalent form among Pakistani pediatric patients, accounting for 44.8% of cases. This is followed by PFIC2 (24.1%), PFIC1 (16.4%), PFIC4 (12.9%), with PFIC5 being relatively rare (1.7%).

Unique clinical and laboratory findings: The study identifies several novel clinical and laboratory observations differing from prior studies: a) Around a quarter of PFIC1 and PFIC3 patients, and one third of PFIC2 and PFIC4 patients, did not experience pruritus. b) Diarrhea was a significant symptom in 6.7% of PFIC4 patients. c) Hearing loss was noted in 13.3% of PFIC4 patients, with possible occurrences in some PFIC3 patients. d) Gamma-glutamyl transferase (GGT) levels were moderately elevated (less than 2 times the upper limit of normal) in approximately half of the PFIC1, PFIC2, and PFIC4 patients. e) Alpha-fetoprotein (AFT) levels were elevated in patients with PFIC2, PFIC3, and PFIC4. f) A large majority (84.2%-89.3%) of PFIC patients developed anemia.

medRxiv preprint doi: https://doi.org/10.1101/2024.02.26.24303272; this version posted February 28, 2024. The copyright holder for this preprint (which was not certified by peer review) is the author/funder, who has granted medRxiv a license to display the preprint in perpetuity. It is made available under a CC-BY-NC-ND 4.0 International license .

Treatment outcomes: a) Standard medical management often fails to halt disease progression in most PFIC patients, resulting in a low 20-year cumulative survival rate of 20% (95% CI 5%-41%). b) Patients undergoing liver transplantation (LT) showed markedly improved outcomes, with a 20-year survival rate of 89% (95% CI 43%-98%), significantly higher than the 9% survival rate (95% CI 1%-29%) for those receiving only medical treatment; p-value = 0.0162. c) PFIC3 patients exhibited a less aggressive disease progression and better survival than those with PFIC1, PFIC2, and PFIC4, particularly during the first decade post-diagnosis.

Absence of Liver Tumors: Notably, we did not observe liver tumors in PFIC patients, including those who had entered their second decade of life.

METHODS

Study participants

This study enrolled patients from various Pakistani hospitals, including those in Islamabad, Karachi, Lahore, Multan, and Peshawar, each admitted for diverse reasons. All participants underwent testing as a component of their clinical assessment. We specifically included individuals exhibiting clinical indications of liver disease and possessing homozygous or compound heterozygous mutations in a set of genes: *ATP8B1, ABCB11, ABCB4, TJP2, NR1H4, SLC51A, USP53, KIF12, ZFYVE19, MYO5B, SEMA7A, and VPS33B.* Our approach integrated both retrospective and prospective analyses of demographic data, clinical observations, and laboratory results. This methodology was applied to a cohort of 116 patients diagnosed with progressive familial intrahepatic cholestasis (PFIC). In adherence to ethical guidelines, informed consent was obtained from either the participants themselves or, in the case of child participants, their guardians, through signed written consent forms. The study was approved by the Ethics Committee of Rostock University (Germany), A2022-0072, 25.04 2022.

Sequencing and data analysis

medRxiv preprint doi: https://doi.org/10.1101/2024.02.26.24303272; this version posted February 28, 2024. The copyright holder for this preprint (which was not certified by peer review) is the author/funder, who has granted medRxiv a license to display the preprint in perpetuity. It is made available under a CC-BY-NC-ND 4.0 International license .

Whole Genome Sequencing (WGS). For our study, DNA samples were prepared using the TruSeq DNA Nano Library Prep Kit from Illumina. Sequencing was performed on an Illumina platform utilizing the 150 bp paired-end protocol, achieving an average coverage depth of 30x for the nuclear genome. The alignment of raw reads to the reference genome GRCH38 and the calling of variants, including single nucleotide substitutions (SNVs), small insertions/deletions (Indels), and structural variants (SVs), were conducted using DRAGEN (version 3.10.4, Illumina). Annotation of SNVs and indels was carried out by Varvis (Limbus Medical Technologies GmbH; https://www.limbus-medtec.com/), while structural variants were annotated using ANNOTSV3.1 and our in-house structural variant database for occurrence frequencies. All genetic variants were described according to the Human Genome Variation Society (HGVS) recommendations (www.hgvs.org).

Variant evaluation and interpretation

We considered only high-quality variants with a minimum of 9 reads and an alternate allele frequency of at least 0.3%. Candidate variants underwent evaluation for their pathogenicity and causality using a 5-tier classification: pathogenic (P), likely pathogenic (LP), variants of uncertain significance (VUS), likely benign (LB), and benign (B). Our analysis was restricted to genes with clear associations with the participants' phenotypes, using Human Phenotype Ontology nomenclature (HPO) (https://hpo.jax.org/app/). Factors considered included allele frequency in control databases (gnomAD), in silico pathogenicity predictions, potential protein impacts, variant type-disease mechanisms, familial segregation, and external evidence from OMIM (https://www.omim.org/), ClinVar (https://www.ncbi.nlm.nih.gov/clinvar/), and MasterMind (https://mastermind.genomenon.com/), along with genotype-phenotype correlations.

DATA ACCESS

medRxiv preprint doi: https://doi.org/10.1101/2024.02.26.24303272; this version posted February 28, 2024. The copyright holder for this preprint (which was not certified by peer review) is the author/funder, who has granted medRxiv a license to display the preprint in perpetuity. It is made available under a CC-BY-NC-ND 4.0 International license .

The variant from this study have been submitted to the NCBI ClinVar database (http://www.clinvar.com/) under accession numbers SCV004232458 - SCV004232527.

COMPETING INTEREST STATEMENT

No financial or non-financial benefits have been received or will be received from any party related directly or indirectly to the subject of this article. AS, AR, AM and VS declared employment in a rare disease consulting company.

AUTHOR CONTRIBUTIONS

We declare that this work was done by the authors named in this article and all liabilities pertaining to claims relating to the content of this article will be borne by the authors. HAC, AS, AS, ZF and AR conceived the idea, designed the experiment and draft and revised the manuscript. MAA, MNA, NW, KR and VS performed participants' enrolment, clinical evaluation and sampling. AS, VS and AM genomic data analysis. AS, AR, VS and NW manuscript writing.

ACKNOWLEDGMENTS

We thank the contributions of the administration and staff of the Children Hospital (Lahore), Pakistan Institute of Medical Sciences (Islamabad), Children Hospital and ICH (Multan), Town Women and Children Hospital (Peshawar), and Liaquat National Hospital (Karachi).

References

Agarwal S, Lal BB, Rawat D, Rastogi A, Bharathy KGS, Alam S. 2016. Progressive Familial Intrahepatic Cholestasis (PFIC) in Indian Children: Clinical Spectrum and Outcome. *J Clin Exp Hepatol* **6**: 203–208.

Amendola M, Squires JE. 1993. Pediatric Genetic Cholestatic Liver Disease Overview. In *GeneReviews®* (eds. M.P. Adam, G.M. Mirzaa, R.A. Pagon, S.E. Wallace, L.J. Bean, K.W. Gripp, and A. Amemiya),

medRxiv preprint doi: https://doi.org/10.1101/2024.02.26.24303272; this version posted February 28, 2024. The copyright holder for this preprint (which was not certified by peer review) is the author/funder, who has granted medRxiv a license to display the preprint in perpetuity. It is made available under a CC-BY-NC-ND 4.0 International license .

University of Washington, Seattle, Seattle (WA) http://www.ncbi.nlm.nih.gov/books/NBK584020/ (Accessed May 3, 2023).

Amirneni S, Haep N, Gad MA, Soto-Gutierrez A, Squires JE, Florentino RM. 2020. Molecular overview of progressive familial intrahepatic cholestasis. *World J Gastroenterol* **26**: 7470–7484.

Baker A, Kerkar N, Todorova L, Kamath BM, Houwen RHJ. 2020. Erratum to "Systematic review of progressive familial intrahepatic cholestasis" [Clin. Res. Hepatol. Gastroenterol. 43 (2019) 20-36]. *Clin Res Hepatol Gastroenterol* **44**: 115.

Baker A, Kerkar N, Todorova L, Kamath BM, Houwen RHJ. 2019. Systematic review of progressive familial intrahepatic cholestasis. *Clin Res Hepatol Gastroenterol* **43**: 20–36.

Bove KE, Heubi JE, Balistreri WF, Setchell KDR. 2004. Bile acid synthetic defects and liver disease: a comprehensive review. *Pediatr Dev Pathol Off J Soc Pediatr Pathol Paediatr Pathol Soc* **7**: 315–334.

Davit-Spraul A, Fabre M, Branchereau S, Baussan C, Gonzales E, Stieger B, Bernard O, Jacquemin E. 2010. ATP8B1 and ABCB11 analysis in 62 children with normal gamma-glutamyl transferase progressive familial intrahepatic cholestasis (PFIC): phenotypic differences between PFIC1 and PFIC2 and natural history. *Hepatol Baltim Md* **51**: 1645–1655.

Dixon PH, Sambrotta M, Chambers J, Taylor-Harris P, Syngelaki A, Nicolaides K, Knisely AS, Thompson RJ, Williamson C. 2017. An expanded role for heterozygous mutations of ABCB4, ABCB11, ATP8B1, ABCC2 and TJP2 in intrahepatic cholestasis of pregnancy. *Sci Rep* **7**: 11823.

Gomez-Ospina N, Potter CJ, Xiao R, Manickam K, Kim M-S, Kim KH, Shneider BL, Picarsic JL, Jacobson TA, Zhang J, et al. 2016. Mutations in the nuclear bile acid receptor FXR cause progressive familial intrahepatic cholestasis. *Nat Commun* **7**: 10713.

Gunaydin M, Bozkurter Cil AT. 2018. Progressive familial intrahepatic cholestasis: diagnosis, management, and treatment. *Hepatic Med Evid Res* **10**: 95–104.

Gupta NA, Karpen SJ. 2014. Mechanisms of bile formation and cholestasis. In *Liver Disease in Children* (eds. F.J. Suchy, R.J. Sokol, and W.F. Balistreri), pp. 24–31, Cambridge University Press https://www.cambridge.org/core/product/identifier/CBO9781139012102A012/type/book_part (Accessed July 22, 2023).

Heubi JE, Setchell KDR, Bove KE. 2007. Inborn errors of bile acid metabolism. *Semin Liver Dis* **27**: 282–294.

Lang T, Haberl M, Jung D, Drescher A, Schlagenhaufer R, Keil A, Mornhinweg E, Stieger B, Kullak-Ublick GA, Kerb R. 2006. Genetic variability, haplotype structures, and ethnic diversity of hepatic transporters MDR3 (ABCB4) and bile salt export pump (ABCB11). *Drug Metab Dispos Biol Fate Chem* **34**: 1582–1599.

Müllenbach R, Lammert F. 2011. An update on genetic analysis of cholestatic liver diseases: digging deeper. *Dig Dis Basel Switz* **29**: 72–77.

medRxiv preprint doi: https://doi.org/10.1101/2024.02.26.24303272; this version posted February 28, 2024. The copyright holder for this preprint (which was not certified by peer review) is the author/funder, who has granted medRxiv a license to display the preprint in perpetuity. It is made available under a CC-BY-NC-ND 4.0 International license .

Sharma A, Poddar U, Agnihotry S, Phadke SR, Yachha SK, Aggarwal R. 2018. Spectrum of genomic variations in Indian patients with progressive familial intrahepatic cholestasis. *BMC Gastroenterol* **18**: 107.

Siddiqi I, Tadi P. 2023. Progressive Familial Intrahepatic Cholestasis. In *StatPearls*, StatPearls Publishing, Treasure Island (FL) http://www.ncbi.nlm.nih.gov/books/NBK559317/ (Accessed July 26, 2023).

Srivastava A. 2014. Progressive familial intrahepatic cholestasis. *J Clin Exp Hepatol* **4**: 25–36.

Sticova E, Jirsa M, Pawłowska J. 2018. New Insights in Genetic Cholestasis: From Molecular Mechanisms to Clinical Implications. *Can J Gastroenterol Hepatol* **2018**: 2313675.

Vitale G, Gitto S, Raimondi F, Mattiaccio A, Mantovani V, Vukotic R, D'Errico A, Seri M, Russell RB, Andreone P. 2018. Cryptogenic cholestasis in young and adults: ATP8B1, ABCB11, ABCB4, and TJP2 gene variants analysis by high-throughput sequencing. *J Gastroenterol* **53**: 945–958.

Vitale G, Gitto S, Vukotic R, Raimondi F, Andreone P. 2019. Familial intrahepatic cholestasis: New and wide perspectives. *Dig Liver Dis Off J Ital Soc Gastroenterol Ital Assoc Study Liver* **51**: 922–933.

Zhang J, Yang Y, Gong J-Y, Li L-T, Li J-Q, Zhang M-H, Lu Y, Xie X-B, Hong Y-R, Yu Z, et al. 2020. Low-GGT intrahepatic cholestasis associated with biallelic USP53 variants: Clinical, histological and ultrastructural characterization. *Liver Int Off J Int Assoc Study Liver* **40**: 1142–1150.

Zhou S, Hertel PM, Finegold MJ, Wang L, Kerkar N, Wang J, Wong L-JC, Plon SE, Sambrotta M, Foskett P, et al. 2015. Hepatocellular carcinoma associated with tight-junction protein 2 deficiency. *Hepatol Baltim Md* **62**: 1914–1916.