medRxiv preprint doi: https://doi.org/10.1101/2024.02.16.24302945; this version posted February 18, 2024. The copyright holder for this preprint (which was not certified by peer review) is the author/funder, who has granted medRxiv a license to display the preprint in perpetuity. It is made available under a CC-BY-NC-ND 4.0 International license .

Neuroradiological findings in GAA-*FGF14* ataxia (SCA27B): more than cerebellar atrophy.

Shihan Chen[1], Catherine Ashton[1,2], Rawan Sakalla[1], Guillemette Clement[3], Sophie Planel[3], Céline Bonnet[3], Phillipa Lamont[2], Karthik Kulanthaivelu[4], Atchayaram Nalini[5], Henry Houlden[6], Antoine Duquette[7], Marie-Josée Dicaire[1], Pablo Iruzubieta Agudo[8], Javier Ruiz Martinez[8], Enrique Marco de Lucas[9], Rodrigo Sutil Berjon[9], Jon Infante Ceberio[10], Elisabetta Indelicato[11], Sylvia Boesch[11], Matthis Synofzik[12,13], Benjamin Bender[14], Matt C. Danzi[15], Stephan Zuchner[15], David Pellerin[1,6], Bernard Brais[1,16] Mathilde Renaud[3], and Roberta La Piana[1,16,17]

Affiliations

[1]Department of Neurology and Neurosurgery, Montreal Neurological Institute, McGill University, Montreal, QC, Canada

[2]Department of Neurology, Royal Perth Hospital, Perth, Western Australia

[3]Service de Neurologie, CHRU de Nancy, France

[4]Department of Neuro Imaging and Interventional Radiology, National Institute of Mental Health and Neurosciences, Bengaluru, India

[5]Department of Neurology, National Institute of Mental Health and Neurosciences, Bengaluru, India

[6]Department of Neuromuscular Disease, UCL Queen Square Institute of Neurology and The National Hospital for Neurology and Neurosurgery, University College London, London, UK

[7]Department of Neurosciences, Faculty of Medicine, Université de Montréal; Centre de Recherche du Centre Hospitalier de l'Université de Montréal (CRCHUM), Montreal, QC, Canada

NOTE: This preprint reports new research that has not been certified by peer review and should not be used to guide clinical practice.

medRxiv preprint doi: https://doi.org/10.1101/2024.02.16.24302945; this version posted February 18, 2024. The copyright holder for this preprint (which was not certified by peer review) is the author/funder, who has granted medRxiv a license to display the preprint in perpetuity. It is made available under a CC-BY-NC-ND 4.0 International license .

[8]Department of Neurology, University Hospital of Donostia, Biogipuzkoa Health Research Institute, San Sebastian, Spain

[9]Department of Radiology, University of Cantabria, Spain

[10]Department of Medicine and Psychiatry, University of Cantabria, Spain

[11]Department of Neurology, Medical University of Innsbruck, Austria

[12]Division Translational Genomics of Neurodegenerative Diseases, Center for Neurology and Hertie-Institute for Clinical Brain Research, University of Tübingen, Germany

[13]German Center for Neurodegenerative Diseases (DZNE), Tübingen, Germany

[14]Department of Diagnostic and Interventional Neuroradiology, University of Tübingen, Germany

[15]Department of Human Genetics, University of Miami Miller School of Medicine, Miami, FL, USA

[16]The Neuro (Montreal Neurological Institute-Hospital), McGill University

[16]Department of Diagnostic Radiology, McGill University, Montreal, QC, Canada

Corresponding Author
Roberta La Piana

Department of Neurology & Neurosurgery and Department of Diagnostic Radiology

Montreal Neurological Institute and Hospital, McGill University

3801 rue University, Montreal, Quebec, Canada H3A 2B4

roberta.lapiana@mcgill.ca

medRxiv preprint doi: https://doi.org/10.1101/2024.02.16.24302945; this version posted February 18, 2024. The copyright holder for this preprint (which was not certified by peer review) is the author/funder, who has granted medRxiv a license to display the preprint in perpetuity. It is made available under a CC-BY-NC-ND 4.0 International license .

Abstract

Background and Objectives

GAA-*FGF14* ataxia (SCA27B) is a recently reported late-onset cerebellar ataxia (LOCA) caused by a GAA repeat expansion in intron 1 of the *FGF14* gene. Initial studies reviewing MR images of GAA-*FGF14* ataxia patients revealed variable degree of cerebellar atrophy in 74-97% of them. A more detailed brain imaging characterization of GAA-*FGF14* ataxia is now needed to provide 1) supportive diagnostic features and earlier disease recognition and 2) further information about the pathophysiology of the disease.

Methods

We reviewed the brain MRIs of 35 patients (median age at MRI 63 years; range 28-88 years; 16 females) from Quebec (n=27), Nancy (n=3), Perth (n=3) and Bengaluru (n=2) including longitudinal studies for 7 subjects. We performed qualitative analyses to assess the presence and degree of atrophy in vermis, cerebellar hemispheres, brainstem, cerebral hemispheres, and corpus callosum, as well as white matter involvement. Following the identification of the superior cerebellar peduncles involvement, we verified its presence in 54 GAA-*FGF14* ataxia patients from four independent cohorts (Tübingen n=29; Donostia n=12; Innsbruck n=7; Cantabria n=6). To assess lobular atrophy, we also performed quantitative cerebellar segmentation in 5 subjects and 5 age-matched controls.

Results

Cerebellar atrophy of variable degree was documented in 33 subjects (94.3%); limited to the vermis in 11 subjects, extended to the hemispheres in 22. We observed bilateral involvement of the superior cerebellar peduncles (SCPs) in 22 subjects (62.8%). We confirmed this finding in 30/54 (55.6%) GAA-*FGF14* positive subjects from the validation cohorts. Additional findings

medRxiv preprint doi: https://doi.org/10.1101/2024.02.16.24302945; this version posted February 18, 2024. The copyright holder for this preprint (which was not certified by peer review) is the author/funder, who has granted medRxiv a license to display the preprint in perpetuity. It is made available under a CC-BY-NC-ND 4.0 International license .

were: cerebral atrophy in 15 subjects (42.9%), ventricular enlargement in 13 (37.1%), corpus callosum thinning in 7 (20%), and brainstem atrophy in 1 (2.8%). Cerebellar segmentation showed reduced volumes of lobules X and IV in affected individuals.

Discussion

Our study confirms that cerebellar atrophy is a key feature of GAA-*FGF14* ataxia. The frequent SCP involvement observed in different cohorts may be specific to GAA-*FGF14* ataxia, and its detection can support and accelerate the diagnosis. The predominant involvement of vestibulocerebellar lobule X correlates with the finding of downbeat nystagmus frequently observed in GAA-*FGF14* ataxia patients.

medRxiv preprint doi: https://doi.org/10.1101/2024.02.16.24302945; this version posted February 18, 2024. The copyright holder for this preprint (which was not certified by peer review) is the author/funder, who has granted medRxiv a license to display the preprint in perpetuity. It is made available under a CC-BY-NC-ND 4.0 International license .

Introduction

Late-onset cerebellar ataxias (LOCA), defined by the onset of a progressive cerebellar syndrome after 30 years of age, comprise a group of heterogenous neurodegenerative disorders that have largely resisted molecular diagnosis until recently.[1, 2] GAA-*FGF14* ataxia (spinocerebellar ataxia SCA27B; OMIM 620174) is a recently described LOCA caused by a dominantly inherited GAA-TCC repeat expansion in the first intron of *FGF14*, which encodes the fibroblast growth factor-14.[3, 4] This disorder is estimated to be one of the most common forms of late onset as well as autosomal dominant ataxias, especially in the French Canadian (around 60% of previously undiagnosed patients with LOCA) and European population (around 20% of all autosomal dominant ataxias).[5] Initial review of Canadian and European brain MRI findings has revealed cerebellar atrophy in 74% of patients carrying a $(GAA)_{\geq 250}$ repeat expansion in *FGF14*, with further imaging and neuropathological examination reporting prominent vermian atrophy in the vast majority (>90%) of patients.[3, 6] It is now imperative to precisely define the specific neuroradiological features associated with GAA-*FGF14* ataxia that distinguish it from other LOCAs, to 1) provide supportive diagnostic features to ensure early diagnosis, and 2) explore its pathophysiological bases.

Methods

We performed a retrospective analysis of MRI images of patients with confirmed GAA-*FGF14* ataxia. Subjects were included if a) their phenotype was clinically compatible with GAA-*FGF14* ataxia, b) the genetic testing documented a $(GAA)_{\geq 250}$ expansion in *FGF14*, according to the testing protocol described by Bonnet et al.,[7] and c) if MRI scans including at least sagittal or 3D T1- or 3D FLAIR (Fluid-attenuated inversion recovery) T2-weighted images were available.[7, 8] Subjects were recruited in Quebec (n=27), Nancy (n=3), Perth (n=3) and Bengaluru (n=2). For all subjects, we collected demographic and clinical data.

medRxiv preprint doi: https://doi.org/10.1101/2024.02.16.24302945; this version posted February 18, 2024. The copyright holder for this preprint (which was not certified by peer review) is the author/funder, who has granted medRxiv a license to display the preprint in perpetuity. It is made available under a CC-BY-NC-ND 4.0 International license .

All images were reviewed collegially by the authors (SC, RS, CA, and RLP with 15 years of experience in imaging of neurogenetic disorders) according to the qualitative approach detailed below and blind to the clinical and genetic (i.e. size of the GAA expansion) data. Each MRI scan was evaluated twice, 3 months apart. Team disagreements were resolved by consensus. The institutional review boards of each participating institution approved the use of clinical data for the retrospective study.

Qualitative MRI analysis

We performed a qualitative analysis of the MR images to assess the degree of atrophy in the vermis, cerebellar hemispheres, and cerebral hemispheres (size of ventricular system and CSF spaces). For the vermis the atrophy was assessed on midline sagittal planes as 'present' or 'absent', with further grading as 'mild', 'moderate' or 'severe'. For the cerebellar and cerebral hemispheres, the atrophy was assessed on all planes and, when present, graded as 'mild', 'moderate' or 'severe'. The effect of the patient's age was taken into consideration by comparing the images to standard image series used in a study of a neurologically healthy population.[9]

To assess the presence of brainstem atrophy we measured the maximal anteroposterior diameter at the level of the midbrain, midpons, and medulla on sagittal images, and compared to normative values for age according to Metwally et al.[10] The corpus callosum thickness was quantified by measuring the maximum width of the body at midpoint and compared to normative values according to Gupta et al.[11]

We also reviewed and assessed the presence and characteristics of white matter abnormalities on T2- and FLAIR T2-weighted images on all planes, when available, by location (periventricular, subcortical, juxtacortical), lobar involvement (frontal, parietal, temporal, occipital, cerebellar, brainstem), and symmetry. Juxtacortical lesions were defined as lesions in direct contact with the

medRxiv preprint doi: https://doi.org/10.1101/2024.02.16.24302945; this version posted February 18, 2024. The copyright holder for this preprint (which was not certified by peer review) is the author/funder, who has granted medRxiv a license to display the preprint in perpetuity. It is made available under a CC-BY-NC-ND 4.0 International license .

cortical ribbon. Periventricular lesions included all lesions abutting any portion of lateral ventricles. Subcortical lesions were defined as supratentorial non-juxtacortical and non-periventricular. As for the assessment of atrophy described above, the effect of the patient's age was taken into consideration by comparing the images to standard images from a study of neurologically healthy population.[9]

The protocols of the reviewed MRIs were not standardized, as they were requested for clinical indication across different hospitals and scanners, thus limiting the systematic analysis of MR data.

Clinical-radiological correlations

We aimed to compare the prevalence of radiological findings (cerebral, diffuse cerebellar and vermian atrophy; superior cerebellar peduncle involvement, periventricular white matter abnormalities and multifocal white matter abnormalities; corpus callosum thinning; ventricular enlargement) between patients presenting with episodic ataxia only or permanent ataxia at the time of MRI scan. However, the two groups – 'episodic only' vs 'permanent ataxia' at the time of the first MRI - were of very different in number (2 vs 29, and missing information for 4), thus preventing this analysis. Additionally, since it is often difficult to ascertain the precise age at symptom onset and the exact moment of the transition between episodic and permanent ataxia, similar comparisons were performed between patients symptomatic for ≤ vs. > than 5 years (n=11 and n=24, respectively) at the time of initial MRI scan, since most patients becomes permanently ataxic after an average of 5 years since disease onset, and between patients aged ≤ vs > 60 years-old (n=14 and n=21 respectively) at the time of their initial MRI. We assessed differences between groups with the Fisher's exact test.

Secondary Analysis

medRxiv preprint doi: https://doi.org/10.1101/2024.02.16.24302945; this version posted February 18, 2024. The copyright holder for this preprint (which was not certified by peer review) is the author/funder, who has granted medRxiv a license to display the preprint in perpetuity. It is made available under a CC-BY-NC-ND 4.0 International license .

Following the identification of the specific involvement of the superior cerebellar peduncles (SCPs), we sought to verify its presence in four independent cohorts from Tübingen (Germany), Innsbruck (Austria), Santander (Spain), and San Sebastian (Spain). Neurologists and radiologists from each center (M.S. and B.Be., University of Tübingen; E.I., S. B. University of Innsbruck; P.I.A, A.L.M.A., University of Donostia; J.I.C., E.M.L., R.S.B. University of Cantabria) reviewed the brain MR images of their confirmed GAA-*FGF14* ataxia patients (Tübingen n=31; Donostia n=14; Innsbruck n=9; Cantabria n=6) to assess the presence or absence of the SCP involvement comparing to provided reference images (**Suppl Figure 1**). The Montreal group also independently reviewed the same MRIs, blind to the treating teams' conclusions, to assess the presence of SCP involvement. Disagreement between the two assessments were solved by consensus. As for the MR images initially included in the study, the imaging protocols from the validation cohorts were not standardized, as they were performed for clinical purposes in different hospitals and using different MR scanners.

Measurements and Quantitative MRI analysis

Quantitative analyses were performed on brain MRI studies of five individuals with confirmed GAA-*FGF14* ataxia and available 3D T1-weighted images to assess the degree of cerebellar atrophy. Segmentation of cerebellum using T1-weighted images was performed automatically using the CERES pipeline (volBrain), an automated MRI brain volumetry system.[12] CERES processed MRI images based on a training library composed of cerebellums manually segmented by experts (**Suppl Figure 2**). All anatomical structures were defined based on the MRI atlases described in Park et al., 2014.[13] We compared the following parameters between affected individuals and age-matched controls: total and lobular cerebellum volume (grey matter and

medRxiv preprint doi: https://doi.org/10.1101/2024.02.16.24302945; this version posted February 18, 2024. The copyright holder for this preprint (which was not certified by peer review) is the author/funder, who has granted medRxiv a license to display the preprint in perpetuity. It is made available under a CC-BY-NC-ND 4.0 International license .

white matter), cerebellar cortical thickness, and asymmetry index. Cerebellar volume percentage was calculated as the ratio between cerebellar volume and total intracranial volume.

Results

We included and reviewed brain MRI studies of 35 patients (14 not previously reported): 15 females, median age at MRI was 63 years (range 28-88 years); median disease duration at the time of MRI was 9 years (range 1-34 years), median age of disease onset at 52 years (range 25-75 years). The clinical features and radiological findings of the cohort of 35 subjects with confirmed GAA-*FGF14* ataxia are summarized in **Table 1**. Longitudinal studies were also available for seven subjects. Twenty-nine patients (29/31, 93.5%) presented with permanent ataxia at the time of MRI scan, while two patients (2/31, 6.5%) presented with only episodic symptoms. Information about disease status at the time of MRI (episodic vs permanent) was not available for four patients. In terms of disease duration, 24 patients (54.3%) were symptomatic for more than 5 years at the time of initial MRI.

Radiological Features

MRI patterns of atrophy

Infratentorial atrophy

Cerebellar atrophy was observed in 33 patients (33/35, 94.3%), including 22 patients (22/35, 62.8%) with involvement of both vermis and cerebellar hemispheres, and 11 (11/35, 31.4%) with isolated vermian atrophy **(Figure 1**).

For the 33 patients with vermian atrophy – either isolated or not – the degree was mild in 13 (13/35, 37.1%), moderate in 17 (17/35, 48.5%), and severe in 3 (3/35, 8.5%). The majority of patients (32/35, 91.4%) had predominant involvement of the anterior lobe and the superior

medRxiv preprint doi: https://doi.org/10.1101/2024.02.16.24302945; this version posted February 18, 2024. The copyright holder for this preprint (which was not certified by peer review) is the author/funder, who has granted medRxiv a license to display the preprint in perpetuity. It is made available under a CC-BY-NC-ND 4.0 International license .

posterior lobe of the vermis before the pre-pyramidal fissure, except for one individual with diffuse atrophy involving the vermis globally.

Among the 22 patients with both vermian and hemispheric involvement, cerebellar hemispheres were mildly atrophic in 15 subjects (15/35, 42.8%), moderately atrophic in six (6/35, 17.1%), and severely atrophic in one (1/35, 2.9%). The degree of atrophy was the same in both the vermis and cerebellar hemispheres in 11 (50%), relatively more severe in the vermis compared to the hemispheres in ten (10/22, 45.5%) and more severe in the cerebellar hemispheres in one patient (4.5%).

The measurement of the brainstem anteroposterior diameters documented values below the normal range in one subject (1/35; 2.8%) (AP diameter of the pons 1.77mm, normal range 1.9-2.5) who presented concomitant vermian and cerebellar hemispheric atrophy as well as SCP involvement.

Supratentorial atrophy

Cerebral atrophy was present in 15 subjects (15/35, 42.9%; median age 69 years, range 45-80): mild in 11 (11/35, 31.4%; median age 63 years, range 45-80), and moderate in four (4/35, 11.4%; median age 73 years, range 67-77). This was particularly evident in terms of increased CSF spaces at the level of the convexity in the frontal lobes.

Ventricular enlargement was documented in 13 subjects (13/35, 37.1%); in four (4/35, 11.4%) it was limited to the 4th ventricle secondary to the cerebellar atrophy, while the other 9 had involvement of the lateral ventricles too (9/35, 25.7%).

medRxiv preprint doi: https://doi.org/10.1101/2024.02.16.24302945; this version posted February 18, 2024. The copyright holder for this preprint (which was not certified by peer review) is the author/funder, who has granted medRxiv a license to display the preprint in perpetuity. It is made available under a CC-BY-NC-ND 4.0 International license .

The measurement of the corpus callosum body thickness documented reduced values for age in 7 subjects (7/35; 20%): (0.32, 0.35, 0.38, 0.39, 0.44, 0.48, 0.48mm; mean value ± sd 0.65 ± 0.15). All subjects with corpus callosum thinning had concomitant white matter abnormalities.

Longitudinal studies

Longitudinal MRI studies were available in seven patients. The mean interval between MRIs was 6.4 years (range 1-16 years). All seven patients had cerebellar atrophy on the initial MRI, which remained relatively stable in two patients and progressed in five (5/7, 71.4%) (**Figure 2**). Of note, we documented simultaneous progression of vermian and hemispheric atrophy in four (4/7, 57.1%) subjects. One patient developed new cerebellar hemisphere involvement on follow-up MRI. We also observed progression of cerebral atrophy in one patient, likely related to age (1/7, 14.3%; age at MRI 63 and 79 years) (**Figure 2D**) and progression of ventricular enlargement in two (2/7, 28.6%). Two patients (2/7, 28.6%) developed corpus callosum thinning on subsequent MRI (**Figure 2D**).

MRI patterns of white matter abnormality

T2 or FLAIR T2-weighted images on all three planes were available for 19 subjects, while for the remaining 16 only axial T2 or FLAIR T2 images were available for review.

White matter abnormalities (WMAs) were present in 34 subjects (34/35, 97.1%; median age 63, range 28-88). Different patterns of white matter abnormalities were observed: a characteristic superior cerebellar peduncle (SCP) involvement (**Figure 3**), as well as non-specific periventricular and multifocal (subcortical or juxtacortical) abnormalities (**Figure 4**).

Superior cerebellar peduncle involvement

medRxiv preprint doi: https://doi.org/10.1101/2024.02.16.24302945; this version posted February 18, 2024. The copyright holder for this preprint (which was not certified by peer review) is the author/funder, who has granted medRxiv a license to display the preprint in perpetuity. It is made available under a CC-BY-NC-ND 4.0 International license .

We observed involvement of the SCP and their decussation within the midbrain (**Figure 3**) in 22 subjects (22/35, 62.8%), 16 (16/22, 72.7%) of which had prominent SCP hyperintensity (**Figure 3A-D, I-L**), while six (6/22, 27.2%) presented with more faint white matter changes (**Figure 3E-H**). SCP changes were best captured by 3D FLAIR T2 images and prominent hyperintensity was visible in all three planes (coronal, sagittal, and axial), when available.

Presence of SCP involvement in validation cohorts

From the 60 subjects with confirmed GAA-*FGF14* ataxia from the four independent cohorts, we finally reviewed T2-weighted and FLAIR T2-weighted images of 54 subjects (Tübingen = 29; Donostia = 12; Innsbruck = 7; Cantabria = 6). Six subjects were excluded for poor image quality that prevented the assessment. Involvement of the SCP was identified in 30 subjects (30/54, 55.6%) from the four validation cohorts. Fifteen of them (15/30; 50%) had prominent T2 or FLAIR T2 hyperintense signal along the SCP, while 15 (15/30; 50%) had faint signal change. **Supplementary Table 1** includes the results for each independent cohort.

Non-specific periventricular and multifocal WMA

Periventricular WMAs were present in 28 (28/35, 80%; median age 64, range 28-88) cases: in six (6/35, 17.1%) they were limited to the white matter adjacent to the anterior horns of the lateral ventricles, in seven to the posterior horns only (7/35, 20%), and in 14 they extended to both anterior and posterior horns (15/35, 42.9%) (**Figure 4C, D**). A minority (6/35, 17.1%) had more diffuse involvement of the periventricular white matter with extension to the peritrigonal area (**Figure 4B**). Non-specific subcortical multifocal lesions were observed in 22 subjects (22/35, 62.8%; median age 64, range 44-88), variably located in the frontal, parietal, temporal and occipital lobes (**Figure 4A, B, C**).

medRxiv preprint doi: https://doi.org/10.1101/2024.02.16.24302945; this version posted February 18, 2024. The copyright holder for this preprint (which was not certified by peer review) is the author/funder, who has granted medRxiv a license to display the preprint in perpetuity. It is made available under a CC-BY-NC-ND 4.0 International license .

Most patients (29/35, 82.9%) had more than one type of WMA: 12 presented periventricular, multifocal, and SCP involvement (12/35, 34.3%), seven (7/35, 20%) had periventricular and multifocal lesions, six (6/35, 17.1%) presented with both SCP involvement and periventricular changes, and the remaining four (4/35, 11.4%) had simultaneous SCP involvement and multifocal abnormalities.

Vascular risk factors were documented in 19 patients (19/35, 54.3%). Among these, six (6/19, 31.5%) presented with SCP abnormal signal, ten (10/19, 52.6%) with periventricular white matter involvement, ten (10/19, 52.6%) with multifocal lesions, and seven (7/19, 36.8%) with ventricular enlargement. Approximately one third (6/19, 31.5%) presented with both non-specific white matter lesions and ventricular enlargement.

Longitudinal studies

Among the seven patients with longitudinal MRI studies, SCP involvement was observed on the initial scan in five (5/7, 71.4%), and remained relatively stable overtime. One case showed new onset mild SCP involvement 4 years after the initial MRI study. Progression of periventricular and multifocal white matter abnormalities was noted in one (1/7, 14.3%) and four (4/7, 57.1%) patients, respectively.

Clinical-radiological correlations

We did not document any statistically significant differences in the presence of neuroradiological findings between patients presenting with less vs. more than 5 years of disease duration. Cerebral atrophy and ventricular enlargement appeared to be more prevalent in older patients (>60 years-old at the time of initial MRI) compared to the rest of the cohort (p=0.046; p=0.033, respectively). Conversely, isolated vermian atrophy and involvement of the SCP were more

medRxiv preprint doi: https://doi.org/10.1101/2024.02.16.24302945; this version posted February 18, 2024. The copyright holder for this preprint (which was not certified by peer review) is the author/funder, who has granted medRxiv a license to display the preprint in perpetuity. It is made available under a CC-BY-NC-ND 4.0 International license .

prevalent in younger patients (≤60 years-old at the time of MRI) (p=0.023 and p<0.001, respectively), further suggesting that they are related to GAA-*FGF14* ataxia. All the *p* values relative to the comparison between groups are reported in **Supplementary Table 2**.

Quantitative analysis of cerebellar atrophy

Cerebellar Volume

Table 2 includes the results of the quantitative cerebellar volume analysis for the total volume percentage as well as grey matter percentage for the entire cerebellum and individual lobules in patients and controls.

We did not observe significant differences in the total cerebellar volume nor total grey matter volume between patients with GAA-*FGF14* ataxia and controls. Analyses of individual lobules revealed a decrease in the total volume percentage of lobule IV (mean 0.24±0.03% vs 0.31±0.06%, t (8) = -2.55, p=0.017, 95%CI [-0.14, -0.007]) and lobule X (mean 0.07±0.01% vs 0.1±0.02%, t (8) = 0.03, p=0.008, 95%CI [-0.056, -0.007]) in patients compared to controls. Analysis of grey matter revealed significant decrease in total volume percentage of lobule IV (mean 0.22±0.02% vs 0.27±0.06, t (8) = -1.99, p=0.04, 95%CI [-0.11, -0.009] and lobule X (mean 0.06±0.01% vs 0.09±0.01%, t (8) =-3.17, p=0.007, 95%CI [-0.046, -0.007]).

Among all lobes, we observed the greatest total volume percentage difference in lobule X (47.4%). In terms of grey matter volume, lobule X showed the greatest reduction in volume percentage (42.5%).

Our data revealed no significant difference in the asymmetry index of the whole cerebellum or cortical thickness (data not shown).

medRxiv preprint doi: https://doi.org/10.1101/2024.02.16.24302945; this version posted February 18, 2024. The copyright holder for this preprint (which was not certified by peer review) is the author/funder, who has granted medRxiv a license to display the preprint in perpetuity. It is made available under a CC-BY-NC-ND 4.0 International license .

Discussion

This study confirms that cerebellar atrophy is a common MRI finding in GAA-*FGF14* ataxia and it provides a detailed characterization of it as well as highlights additional neuroradiological features that may facilitate diagnosis.[3, 6, 14]

Cerebellar atrophy of varying severity was observed in 94% of our subjects, all with vermian involvement, and over half with atrophy extending to the cerebellar hemispheres. Vermian atrophy affected predominantly the anterior lobe and the superior part of the posterior lobe (i.e. declive, folium and tuber lobules). Despite the limited number of available longitudinal MR exams, our study documented progression of cerebellar atrophy in more than half of the subjects with available follow up over a median 6.4-year period, in line with a previous study by Wilke et al.[6]

Cerebellar atrophy is the primary radiological finding in patients with cerebellar ataxia.[1, 6, 14] In LOCA, cerebellar atrophy has been reported in the polyglutamine SCAs (Spinocerebellar Ataxia), SCA8, SCA17, *RFC1* related disorder and MSA-C (Multiple System Atrophy-Cerebellar type). [15-21] Establishing the pattern of atrophy can guide genetic testing and eventual diagnosis. For instance, atrophy associated with brainstem volume loss orients towards SCA2 and SCA3,[16, 17] while MR evidence of cerebellar atrophy mainly involving the vermis is more prevalent in SCA6,[17] and SCA7 usually is characterized by combined superior vermis and pontine atrophy.[22]

The preferential involvement of the vermis and, to a lesser degree, cerebellar hemispheres can differentiate GAA-*FGF14* ataxia from other forms of LOCA with more widespread atrophy, but the distinction from other LOCAs with more isolated involvement of the cerebellum, such as SCA6, can be more challenging.[17,16] To attempt to address this, we performed quantitative

medRxiv preprint doi: https://doi.org/10.1101/2024.02.16.24302945; this version posted February 18, 2024. The copyright holder for this preprint (which was not certified by peer review) is the author/funder, who has granted medRxiv a license to display the preprint in perpetuity. It is made available under a CC-BY-NC-ND 4.0 International license .

segmentation of the cerebellum to better characterize the specific pattern of cerebellar atrophy in GAA-*FGF14*. Little data on MRI volumetric analysis exist to assess the degree of atrophy in individual lobules in other forms of LOCA.[15, 23-26]

In the subjects with GAA-*FGF14* ataxia we assessed, lobules IV and X were preferentially affected, both in total and grey matter volume, with lobule X showing the greatest reduction. Lobule X is heavily involved in the control of the vestibular ocular reflex (VOR), gaze holding, and smooth pursuit.[27] Hypofunction of lobule X can lead to disinhibition of the superior vestibular nuclei neurons, resulting in spontaneous slow upward drift followed by corrective downward saccade (downbeat nystagmus).[28] Gaze-evoked nystagmus is another feature thought to be due to inadequate lobule X control on the brainstem ocular motor integrator.[28] These results correspond well with the frequently observed clinical feature of nystagmus, with 57% of our cohort having downbeat nystagmus, and 57% having gaze-evoked horizontal nystagmus – rates similar to other reported cohorts (range between 37 and 78%).[3, 14, 29, 30] Nystagmus was present in all the subjects included in the volumetric analysis. Interestingly, very recently, *FGF14* $(GAA)_{\geq 250}$ expansions were documented in 48% of 170 subjects with idiopathic down beat nystagmus.[31] As proposed by Pellerin et al.[31], the earliest damage in SCA27B may arise in the flocculus / paraflocculus, thus accounting for the frequently observed early downbeat nystagmus, impaired VOR, other cerebellar ocular motor signs and vertigo. Our data, although preliminary, further support that GAA-*FGF14* ataxia pathology may arise and is more severe in this region of the cerebellum.

Lobule IV is part of the anterior cerebellar sensorimotor homunculi and lesions have been shown to cause cerebellar motor syndrome and limb ataxia.[32-34] This corresponds well with the presence of gait (96-100%) and appendicular ataxia (60-80%) reported in GAA-*FGF14* ataxia.[3, 4, 6]

medRxiv preprint doi: https://doi.org/10.1101/2024.02.16.24302945; this version posted February 18, 2024. The copyright holder for this preprint (which was not certified by peer review) is the author/funder, who has granted medRxiv a license to display the preprint in perpetuity. It is made available under a CC-BY-NC-ND 4.0 International license .

Our results indicate that lobular analysis may aid in the differentiation between LOCAs with similar patterns of global atrophy and should be the focus of future targeted studies. Identification of subregions preferentially affected during the early phase of the disease may promote the development of imaging-markers for early disease detection. As previously found, there is preliminary evidence that some patients with GAA-*FGF14* disease present symptoms limited to the involvement of the cerebellar flocculus / parafloccolus region and do not develop ataxia even after several years of disease duration.[31]

Our study is the first to describe and characterize the white matter abnormalities in GAA-*FGF14* ataxia. The most striking finding was the involvement of the SCPs and their decussation within the midbrain. To date, SCP involvement has not been reported in subjects with GAA-*FGF14* ataxia, nor other forms of LOCA, except for reported decrease SCP decussation volume in patients with SCA6.[35 36] Interestingly, a similar pattern of SCP involvement has been previously documented in a minority of patients with POLR3-related disorders presenting with spastic ataxia.[37, 38] Anatomically, the SCP carries vital efferent fibers of the cerebellothalamic and cerebellorubral tracks originating from the dentate nuclei, as well as afferent fibers of mainly the ventral spinocerebellar tract.[39 40] Damage to the SCP has been associated with vestibular disturbances and gait ataxia. [41, 42] These symptoms correspond well to the clinical manifestations of GAA-*FGF14* ataxia described in other studies.[3, 6, 43] Co-existent SCP and vermian atrophy was present in 57% of our patients, and could suggest that the SCP abnormality is a reflection of reduced vermis-dentate connectivity secondary to vermian atrophy. SCP involvement was present in 62.8% of the subjects included in this study and 55.6% in subjects from the four validation cohorts, with the majority showing prominent hyperintensity in all three planes (coronal, sagittal, and axial), when available. In fact, SCP changes were best captured by 3D T2

medRxiv preprint doi: https://doi.org/10.1101/2024.02.16.24302945; this version posted February 18, 2024. The copyright holder for this preprint (which was not certified by peer review) is the author/funder, who has granted medRxiv a license to display the preprint in perpetuity. It is made available under a CC-BY-NC-ND 4.0 International license .

FLAIR images. Given the retrospective nature of our study - which limited the availability of ideal sequences - and the presence of suggestive symptoms in GAA-*FGF14* ataxia, it is reasonable to suspect that SCP involvement may be even more prevalent than what we observed.[3, 6] Hence, we recommend including 3D FLAIR T2-weighted MR sequence when assessing subjects with suspected SCA27B.

Within the limitations of this study, we did not observe any association between clinical manifestations (episodic vs. permanent ataxia at the time of MRI and disease duration of less vs. more than 5 years) and neuroradiological findings. Cerebral atrophy and ventricular enlargement were more prevalent in older patients. Since these findings can be part of normal aging process or due to other neurodegenerative processes, it will be important to verify these findings in future case-control prospective studies. More interestingly, SCP involvement and vermian atrophy were more represented in patients younger than 60. While it is expected that cerebellar atrophy may be limited to the vermis in younger patients and then extend to cerebellar hemispheres over time, the result is more surprising for the SCP involvement. Several confounding factors might have contributed to this. MRIs included in our study have been acquired over a 20-year span of time and the SCP region may not have been well visualised due to outdated MRI sequences and protocols. Additionally, factors such as family history and access to healthcare resources may affect the timing of one's initial MRI scan, thus affecting the assessment of differences between groups. Nonetheless, we cannot exclude that the signal abnormalities along the SCP might be transitory - although the fact that we documented it in longitudinal exams argues against it - and observed more frequently at a younger age. This hypothesis can be only verified with prospective dedicated neuroimaging studies, that in addition will further elucidate the diagnostic value of the SCP abnormalities and its role in the disease pathophysiology. SCP involvement

medRxiv preprint doi: https://doi.org/10.1101/2024.02.16.24302945; this version posted February 18, 2024. The copyright holder for this preprint (which was not certified by peer review) is the author/funder, who has granted medRxiv a license to display the preprint in perpetuity. It is made available under a CC-BY-NC-ND 4.0 International license .

may be a useful additional diagnostic feature, particularly in patients with an incompletely penetrant $(GAA)_{250\text{-}299}$ repeat expansion, in those presenting with episodic ataxia alone, where the clinical diagnosis may be more challenging, and as a marker distinguishing this disorder from other forms of LOCA.[44, 45]

In addition to the SCP involvement, we documented non-specific periventricular and multifocal white matter abnormalities in 80% and over 60% of individuals respectively. Most of them presented coexisting periventricular, multifocal, and/or SCP lesions. GAA-*FGF14* ataxia patients are often elderly, with published mean age of onset 55-60 years, and our cohort is consistent with this.[3, 6, 14] Cardiovascular risk factors were identified on review of available clinical records in over 50% of patients. Even though these factors and age might contribute to the observed rate of non-specific white matter changes, we observed multifocal and periventricular white matter changes even in subjects with no risk factors, as shown in Figure 4, and subjects under the age of 50.

In conclusion, we described a novel MRI finding of SCP involvement in GAA-*FGF14* ataxia patients, which may be specific to this LOCA subtype and whose detection can orient and accelerate the diagnosis, especially in the early stages of the disease. Our study confirmed that cerebellar atrophy is a key feature of GAA-*FGF14* ataxia, starting at the level of the vermis and extending to the hemispheres over time. The preferential involvement of lobule X correlates with the finding of cerebellar ocular motor signs frequently observed in GAA-*FGF14* patients. Lobular volumetric analysis of GAA-*FGF14* ataxia and further dedicated imaging studies may promote diagnostic accuracy, give insights into disease pathogenesis, and contribute to the development of early disease biomarkers.

Acknowledgements

medRxiv preprint doi: https://doi.org/10.1101/2024.02.16.24302945; this version posted February 18, 2024. The copyright holder for this preprint (which was not certified by peer review) is the author/funder, who has granted medRxiv a license to display the preprint in perpetuity. It is made available under a CC-BY-NC-ND 4.0 International license .

D. Pellerin has received a fellowship award from the Canadian Institutes of Health Research (CIHR). B. Brais has received funds from the Fondation Groupe Monaco and the Canadian Institutes of Health Research (grant 189963). M.C. Danzi and S. Zuckner were supported by the NIH National Institutes of Neurological Disorders and Stroke (grant 2R01NS072248-11A1 to S.Z.) and the NIH National Human Genome Research Institute (grant R21HG013397). M.Synofzik and B. Brais were supported by the European Joint Programme on Rare Diseases, as part of the PROSPAX consortium, under the EJP RD COFUND-EJP N° 825575 (DFG, German Research Foundation, No 441409627). R. La Piana has received a Research Scholar Junior 1 award from the Fonds de Recherche du Québec en Santé (FRQS), and research funds from the Canadian Radiological Foundation, the Spastic Paraplegia Foundation and Roche Canada. The authors thank the patients and their families for participating in this study.

Conflicts of Interests

A. Duquette has received consultancy honoraria from AavantiBio, Novartis, Pfizer Canada, PTC Therapeutics, and Reata Pharmaceuticals, all unrelated to the present manuscript. M. Synofzik has received consultancy honoraria from Ionis, UCB, Prevail, Orphazyme, Servier, Reata, GenOrph, AviadoBio, Biohaven, Zevra, Lilly, and Solaxa, all unrelated to the present manuscript. B. Bender is Co-Founder, shareholder and CTO of AIRAmed GmbH. R. La Piana has received speaking honoraria from Novartis unrelated to the present manuscript.

medRxiv preprint doi: https://doi.org/10.1101/2024.02.16.24302945; this version posted February 18, 2024. The copyright holder for this preprint (which was not certified by peer review) is the author/funder, who has granted medRxiv a license to display the preprint in perpetuity. It is made available under a CC-BY-NC-ND 4.0 International license .

Tables

Table 1. Demographic, clinical and radiological findings of 35 subjects with GAA-*FGF14* ataxia. *Legend*: SCP=superior cerebellar peduncle involvement; M = multifocal white matter abnormalities; PB = Periventricular, around anterior and posterior horns; PA = Periventricular, around anterior horns only; PP= Periventricular, around posterior horns only. *Data missing for 4 subjects.

Demographics and clinical information	**n (%) - tot 35**
Sex F;M	15; 20 (42.8; 57.2)
Median age at onset, years [range]	52 [25-75]
Median age at MRI, years [range]	63 [28-88]
Median disease duration, years [range]	9 [1-34]
Median GAA-TCC repeat expansion [range]	378 [265-508]
Permanent ataxia at time of MRI*	29 (93.5)
Episodic ataxia at time of MRI*	2 (6.5)
Down beat nystagmus	20 (57.1)
Gaze-evoked horizontal nystagmus	20 (57.1)
Vascular risk factors	19 (54.3)
MRI findings	**n (%); tot 35**
Cerebral atrophy	*15 (42.8)*
mild	11 (31.4)
moderate	4 (11.4)
Cerebellar involvement	*33 (94.3)*
Vermian atrophy	*33 (94.3)*
mild	13 (37.1)
moderate	17 (48.6)
severe	3 (8.6)
Brainstem atrophy	*1 (2.8)*
Hemispheric atrophy	*22 (62.8)*
mild	15 (42.8)
moderate	6 (17.1)
severe	1 (2.8)
White matter abnormalities	*34 (97.1)*
SCP	22 (62.8)
multifocal	22 (62.8)
periventricular	28 (80)
Corpus callosum thinning	*7 (20)*
Ventricular enlargement	*13 (37.1)*
4th ventricle	4 (11)
Extended to lateral ventricles	9 (25.7)

medRxiv preprint doi: https://doi.org/10.1101/2024.02.16.24302945; this version posted February 18, 2024. The copyright holder for this preprint (which was not certified by peer review) is the author/funder, who has granted medRxiv a license to display the preprint in perpetuity. It is made available under a CC-BY-NC-ND 4.0 International license .

Table 2. Quantitative cerebellar volume analysis. Mean values, standard deviations, and one-sided p values for the individual lobules for patients (cases) and controls. In bold the statistically significant differences (p<0.05) between groups.

Cerebellar Lobular Total Tissue %

	Mean Cases	St. Dev.	Mean Controls	St. Dev.	one-sided *p* value
Cerebellum %	7.906	0.506	8.863	1.504	0.18
I-II %	0.006	0.005	0.007	0.002	0.33
III %	0.082	0.026	0.099	0.021	0.14
IV %	**0.239**	**0.029**	**0.31**	**0.057**	**0.02**
V %	0.46	0.097	0.59	0.122	0.05
VI %	1.04	0.171	1.26	0.255	0.07
Crus I %	1.67	0.193	1.9	0.33	0.1
Crus II %	1.11	0.037	1.09	0.23	0.43
VIIB %	0.6	0.106	0.59	0.101	0.41
VIIIA %	0.733	0.087	0.737	0.099	0.47
VIIIB %	0.47	0.101	0.55	0.079	0.11
IX %	0.45	0.067	0.51	0.162	0.24
X %	**0.066**	**0.012**	**0.098**	**0.019**	**0.008**

Cerebellar Lobular Grey Matter (%)

	Mean Cases	St. Dev.	Mean Controls	St. Dev.	one-sided *p* value
Cerebellum %	6.003	0.518	6.664	1.151	0.138
I-II %	0.003	0.003	0.004	0.0005	0.29
III %	0.061	0.011	0.068	0.005	0.14
IV %	**0.22**	**0.023**	**0.27**	**0.056**	**0.04**
V %	0.4	0.093	0.5	0.099	0.06
VI %	0.93	0.157	1.14	0.227	0.07
Crus I %	1.37	0.191	1.6	0.306	0.09
Crus II %	0.93	0.024	0.931	0.207	0.49
VIIB %	0.54	0.037	0.52	0.037	0.38
VIIIA %	0.66	0.086	0.65	0.092	0.44
VIIIB %	0.42	0.095	0.46	0.044	0.39
IX %	0.38	0.042	0.41	0.127	0.33
X %	**0.06**	**0.011**	**0.09**	**0.014**	**0.007**

medRxiv preprint doi: https://doi.org/10.1101/2024.02.16.24302945; this version posted February 18, 2024. The copyright holder for this preprint (which was not certified by peer review) is the author/funder, who has granted medRxiv a license to display the preprint in perpetuity. It is made available under a CC-BY-NC-ND 4.0 International license .

Captions for Figures

Figure 1. Cerebellar atrophy. Sagittal Flair T2 (A, B) and T1-weighted images of three subjects showing different degrees of cerebellar atrophy. A, 62-year-old female subject with 9 years of disease duration with normal size of vermis (GAA-TCC expansion size 374); B, moderate cerebellar atrophy of the anterior and superior lobe of the vermis in a 64-year-old female subject with 34 years of disease duration (GAA-TCC expansion size 374); C, severe cerebellar atrophy of the anterior and superior lobe of the vermis in a 62-year-old subject with 14 years of disease duration (GAA-TCC expansion size 437).

Figure 2. Cerebellar atrophy, longitudinal data. A,B. Sagittal T1-weighted images of a male patient (GAA-TCC expansion size 424). showing stable degree of mild cerebellar atrophy localized mainly in the anterior lobe of the vermis, over the course of 10 years, from the age of 47, 17 years after disease onset (A), to the age of 57(B). C,D. Sagittal T1-weighted images of a patient showing progression of the vermian atrophy that extended from the anterior lobe of the vermis (C, age 63, 5 years after disease onset) to the posterior aspect of the vermis (D), 16 years after the first MRI. In addition, the images show that the patient developed mild corpus callosum thinning at the level of the body and midline cerebral atrophy over time.

Figure 3. Involvement of the superior cerebellar peduncles. Multiplanar Flair T2-weighted images of three subjects showing bilateral and symmetric involvement of the superior cerebellar peduncles and its decussation within the midbrain. T2-hyperintense signal is visible in the central region of the midbrain both in the axial (A, E, I) and sagittal views (D, H, L), as well as in the coronal plane (C, G, K). The SCPs are involved for their entire length, as showed in the axial views (B, F, J) and in the coronal image (C). The images are from a 76-year-old female subject with 5 history of disease duration (GAA-TCC expansion size 324) (A-D), an 80-year-old female

medRxiv preprint doi: https://doi.org/10.1101/2024.02.16.24302945; this version posted February 18, 2024. The copyright holder for this preprint (which was not certified by peer review) is the author/funder, who has granted medRxiv a license to display the preprint in perpetuity. It is made available under a CC-BY-NC-ND 4.0 International license .

subject with 10 years of disease duration (E-H) (GAA-TCC expansion size 250), a 72-year-old female subject with 21 years of disease duration (GAA-TCC expansion size 357) (I-L).

Figure 4. Non-specific white matter abnormalities. Axial FLAIR T2-weighted images showing different supratentorial white matter abnormalities. A, a focal oval-shaped lesion in the right frontal deep white matter in a 72-year-old woman (GAA-TCC expansion size 357); B, multifocal subcortical white matter abnormalities in a 72-year-old man (GAA-TCC expansion size 330); C, symmetric periventricular white matter involvement with enlargement of the lateral ventricles and multifocal subcortical white matter abnormalities in a 51-year-old man (GAA-TCC expansion size 304); D, posterior periventricular white matter involvement in a 75-year-old woman (GAA-TCC expansion size 290). None of these subjects were known for vascular risk factors.

medRxiv preprint doi: https://doi.org/10.1101/2024.02.16.24302945; this version posted February 18, 2024. The copyright holder for this preprint (which was not certified by peer review) is the author/funder, who has granted medRxiv a license to display the preprint in perpetuity. It is made available under a CC-BY-NC-ND 4.0 International license .

References

1. Krygier M, Mazurkiewicz-Beldzinska M. Milestones in genetics of cerebellar ataxias. Neurogenetics 2021;22:225-234.
2. Harding AE. "Idiopathic" late onset cerebellar ataxia. A clinical and genetic study of 36 cases. Journal of the neurological sciences 1981;51:259-271.
3. Pellerin D, Danzi MC, Wilke C, et al. Deep Intronic FGF14 GAA Repeat Expansion in Late-Onset Cerebellar Ataxia. The New England journal of medicine 2023;388:128-141.
4. Rafehi H, Read J, Szmulewicz DJ, et al. An intronic GAA repeat expansion in FGF14 causes the autosomal-dominant adult-onset ataxia SCA50/ATX-FGF14. American journal of human genetics 2023;110:105-119.
5. Hengel H, Pellerin D, Wilke C, et al. As Frequent as Polyglutamine Spinocerebellar Ataxias: SCA27B in a Large German Autosomal Dominant Ataxia Cohort. Mov Disord 2023;38:1557-1558.
6. Wilke C, Pellerin D, Mengel D, et al. GAA-FGF14 ataxia (SCA27B): phenotypic profile, natural history progression and 4-aminopyridine treatment response. Brain 2023.
7. Bonnet C, Pellerin D, Roth V, et al. Optimized testing strategy for the diagnosis of GAA-FGF14 ataxia/spinocerebellar ataxia 27B. Scientific reports 2023;13:9737.
8. Bonnet C, Pellerin D, Roth V, et al. Optimized testing strategy for the diagnosis of GAA-FGF14 ataxia. medRxiv 2023:2023.2002.2002.23285206.
9. Salonen O, Autti T, Raininko R, Ylikoski A, Erkinjuntti T. MRI of the brain in neurologically healthy middle-aged and elderly individuals. Neuroradiology 1997;39:537-545.
10. Metwally MI, Basha MAA, AbdelHamid GA, et al. Neuroanatomical MRI study: reference values for the measurements of brainstem, cerebellar vermis, and peduncles. Br J Radiol 2021;94:20201353.
11. Gupta T, Singh B, Kapoor K, Gupta M, Kochar S. Corpus callosum morphometry: comparison of fresh brain, preserved brain and magnetic resonance imaging values. Anat Sci Int 2008;83:162-168.
12. Manjon JV, Coupe P. volBrain: An Online MRI Brain Volumetry System. Front Neuroinform 2016;10:30.
13. Park MT, Pipitone J, Baer LH, et al. Derivation of high-resolution MRI atlases of the human cerebellum at 3T and segmentation using multiple automatically generated templates. Neuroimage 2014;95:217-231.
14. Iruzubieta P, Pellerin D, Bergareche A, et al. Frequency and phenotypic spectrum of spinocerebellar ataxia 27B and other genetic ataxias in a Spanish cohort of late-onset cerebellar ataxia. Eur J Neurol 2023.
15. Guerrini L, Lolli F, Ginestroni A, et al. Brainstem neurodegeneration correlates with clinical dysfunction in SCA1 but not in SCA2. A quantitative volumetric, diffusion and proton spectroscopy MR study. Brain 2004;127:1785-1795.
16. Velazquez-Perez LC, Rodriguez-Labrada R, Fernandez-Ruiz J. Spinocerebellar Ataxia Type 2: Clinicogenetic Aspects, Mechanistic Insights, and Management Approaches. Front Neurol 2017;8:472.
17. Eichler L, Bellenberg B, Hahn HK, Koster O, Schols L, Lukas C. Quantitative assessment of brain stem and cerebellar atrophy in spinocerebellar ataxia types 3 and 6: impact on clinical status. AJNR American journal of neuroradiology 2011;32:890-897.
18. Lebre AS, Brice A. Spinocerebellar ataxia 7 (SCA7). Cytogenet Genome Res 2003;100:154-163.
19. Lilja A, Hamalainen P, Kaitaranta E, Rinne R. Cognitive impairment in spinocerebellar ataxia type 8. Journal of the neurological sciences 2005;237:31-38.

medRxiv preprint doi: https://doi.org/10.1101/2024.02.16.24302945; this version posted February 18, 2024. The copyright holder for this preprint (which was not certified by peer review) is the author/funder, who has granted medRxiv a license to display the preprint in perpetuity. It is made available under a CC-BY-NC-ND 4.0 International license .

20. Loy CT, Sweeney MG, Davis MB, et al. Spinocerebellar ataxia type 17: extension of phenotype with putaminal rim hyperintensity on magnetic resonance imaging. Mov Disord 2005;20:1521-1523.
21. Vemuri P, Castillo AM, Thostenson KB, et al. Imaging biomarkers for early multiple system atrophy. Parkinsonism Relat Disord 2022;103:60-68.
22. Bang OY, Lee PH, Kim SY, Kim HJ, Huh K. Pontine atrophy precedes cerebellar degeneration in spinocerebellar ataxia 7: MRI-based volumetric analysis. J Neurol Neurosurg Psychiatry 2004;75:1452-1456.
23. Jung BC, Choi SI, Du AX, et al. MRI shows a region-specific pattern of atrophy in spinocerebellar ataxia type 2. Cerebellum 2012;11:272-279.
24. Matos P, Rezende TJR, Schmitt GS, et al. Brain Structural Signature of RFC1-Related Disorder. Mov Disord 2021;36:2634-2641.
25. Camargos ST, Marques W, Jr., Santos AC. Brain stem and cerebellum volumetric analysis of Machado Joseph disease patients. Arquivos de neuro-psiquiatria 2011;69:292-296.
26. Arruda WO, Meira AT, Ono SE, et al. Volumetric MRI Changes in Spinocerebellar Ataxia (SCA3 and SCA10) Patients. Cerebellum 2020;19:536-543.
27. Kheradmand A, Zee DS. Cerebellum and ocular motor control. Front Neurol 2011;2:53.
28. Blazquez PM, Pastor AM. Cerebellar Control of Eye Movements. In: Manto MU, Gruol DL, Schmahmann JD, Koibuchi N, Sillitoe RV, eds. Handbook of the Cerebellum and Cerebellar Disorders. Cham: Springer International Publishing, 2022: 1301-1318.
29. Wirth T, Clément G, Delvallée C, et al. Natural History and Phenotypic Spectrum of GAA-FGF14 Sporadic Late-Onset Cerebellar Ataxia (SCA27B). Mov Disord 2023.
30. Novis LE, Frezatti RS, Pellerin D, et al. Frequency of GAA-FGF14 Ataxia in a Large Cohort of Brazilian Patients With Unsolved Adult-Onset Cerebellar Ataxia. Neurol Genet 2023;9:e200094.
31. Pellerin D, Heindl F, Wilke C, et al. Intronic FGF14 GAA repeat expansions are a common cause of downbeat nystagmus syndromes: frequency, phenotypic profile, and 4-aminopyridine treatment response. medRxiv 2023.
32. Grodd W, Hulsmann E, Lotze M, Wildgruber D, Erb M. Sensorimotor mapping of the human cerebellum: fMRI evidence of somatotopic organization. Hum Brain Mapp 2001;13:55-73.
33. Schmahmann JD, Macmore J, Vangel M. Cerebellar stroke without motor deficit: clinical evidence for motor and non-motor domains within the human cerebellum. Neuroscience 2009;162:852-861.
34. Timmann D, Brandauer B, Hermsdorfer J, et al. Lesion-symptom mapping of the human cerebellum. Cerebellum 2008;7:602-606.
35. Ye C, Yang Z, Ying SH, Prince JL. Segmentation of the Cerebellar Peduncles Using a Random Forest Classifier and a Multi-object Geometric Deformable Model: Application to Spinocerebellar Ataxia Type 6. Neuroinformatics 2015;13:367-381.
36. Ochi T, Taoka T, Miyasaka T, et al. "Cerebellar peduncle quarter notes" formed by the superior and middle cerebellar peduncles: comparison with a diffusion tensor study of spinocerebellar degeneration. Jpn J Radiol 2015;33:210-215.
37. Infante J, Serrano-Cárdenas KM, Corral-Juan M, et al. POLR3A-related spastic ataxia: new mutations and a look into the phenotype. Journal of Neurology 2020;267:324-330.
38. Minnerop M, Kurzwelly D, Wagner H, et al. Hypomorphic mutations in POLR3A are a frequent cause of sporadic and recessive spastic ataxia. Brain 2017;140:1561-1578.
39. Ye C, Bogovic JA, Ying SH, Prince JL. Segmentation of the Complete Superior Cerebellar Peduncles Using a Multi-Object Geometric Deformable Model. Proc IEEE Int Symp Biomed Imaging 2013;2013:49-52.
40. Dum RP, Strick PL. An unfolded map of the cerebellar dentate nucleus and its projections to the cerebral cortex. J Neurophysiol 2003;89:634-639.

medRxiv preprint doi: https://doi.org/10.1101/2024.02.16.24302945; this version posted February 18, 2024. The copyright holder for this preprint (which was not certified by peer review) is the author/funder, who has granted medRxiv a license to display the preprint in perpetuity. It is made available under a CC-BY-NC-ND 4.0 International license .

41. Kim MS, Tak HJ, Son SM. Recovery of cerebellar peduncle injury in a patient with a cerebellar tumor: validation by diffusion tensor tractography. Neural Regen Res 2014;9:1929-1932.
42. Hong JH, Kim OL, Kim SH, Lee MY, Jang SH. Cerebellar peduncle injury in patients with ataxia following diffuse axonal injury. Brain Res Bull 2009;80:30-35.
43. Pellerin D, Wilke C, Traschütz A, et al. Intronic FGF14 GAA repeat expansions are a common cause of ataxia syndromes with neuropathy and bilateral vestibulopathy. J Neurol Neurosurg Psychiatry 2023.
44. Kim M, Ahn JH, Cho Y, Kim JS, Youn J, Cho JW. Differential value of brain magnetic resonance imaging in multiple system atrophy cerebellar phenotype and spinocerebellar ataxias. Scientific reports 2019;9:17329.
45. Burk K, Buhring U, Schulz JB, Zuhlke C, Hellenbroich Y, Dichgans J. Clinical and magnetic resonance imaging characteristics of sporadic cerebellar ataxia. Arch Neurol 2005;62:981-985.

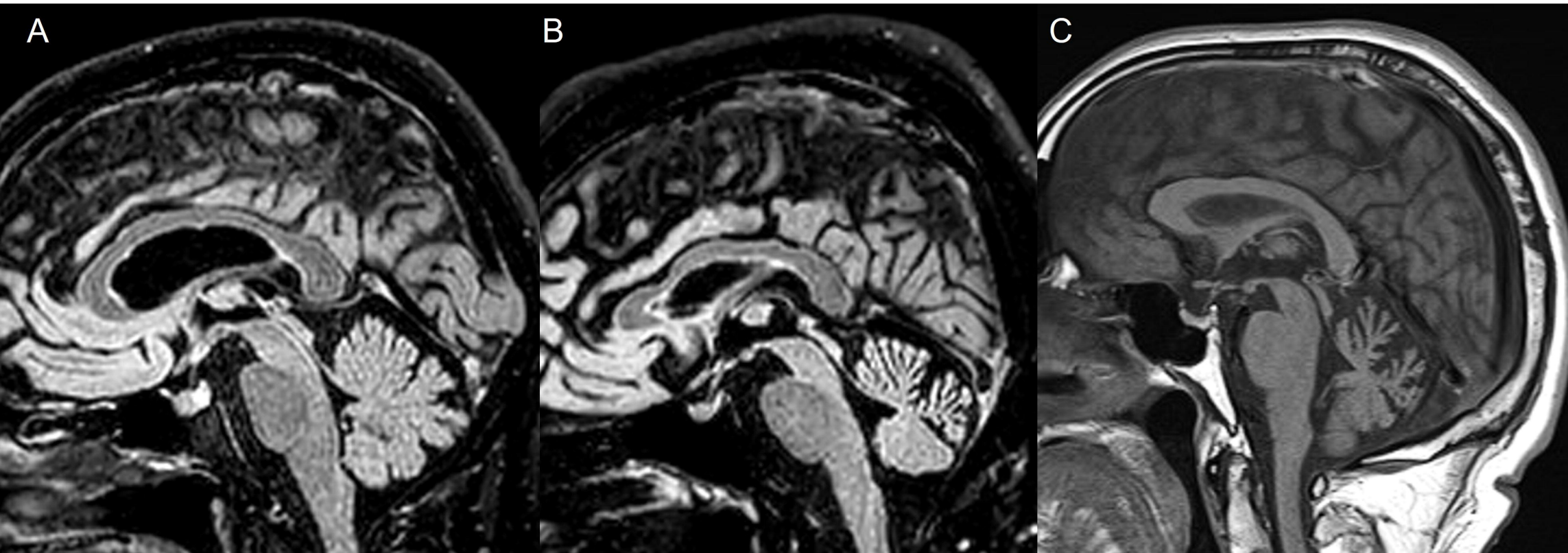
A
B
C

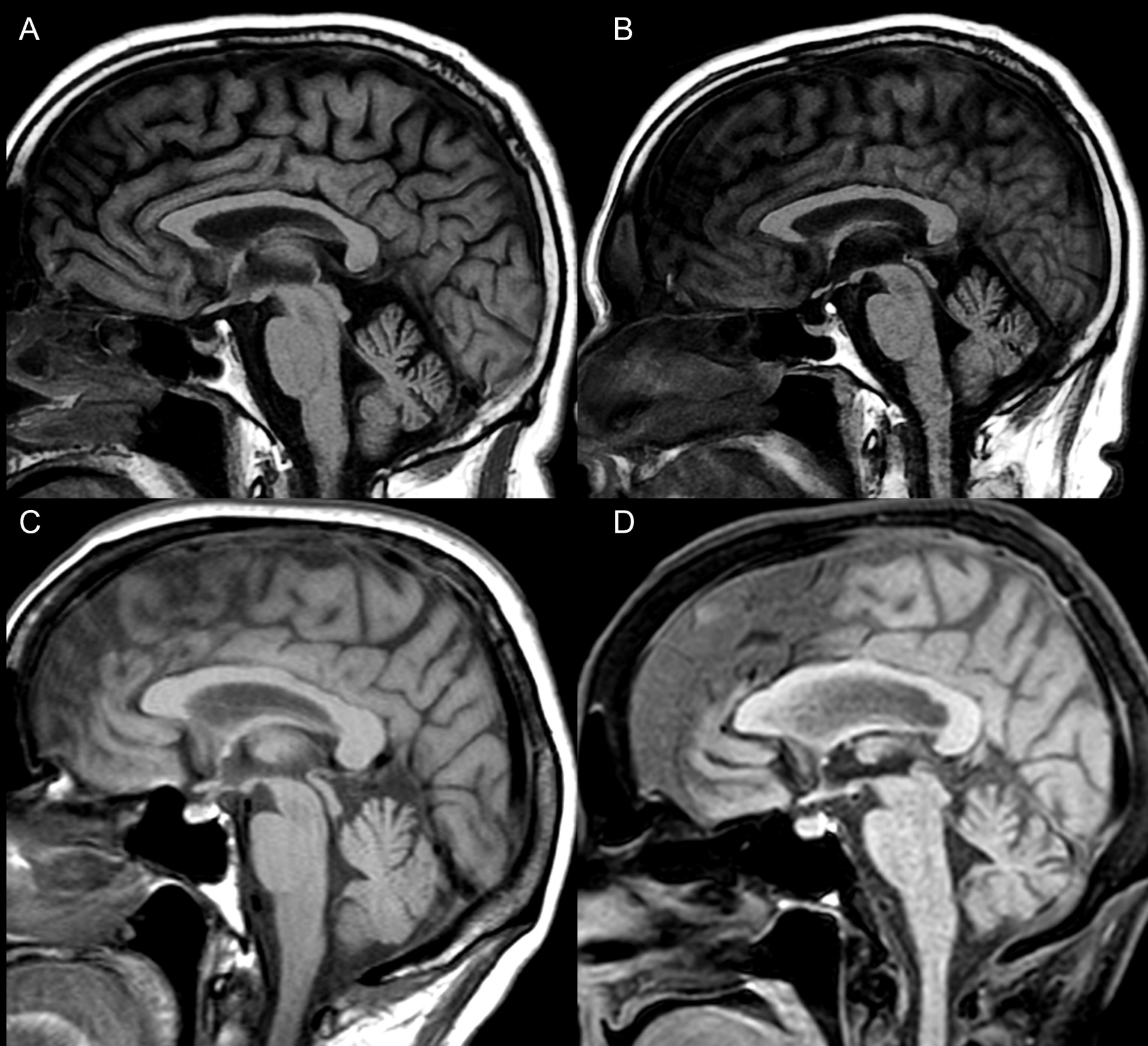
A
B
C
D

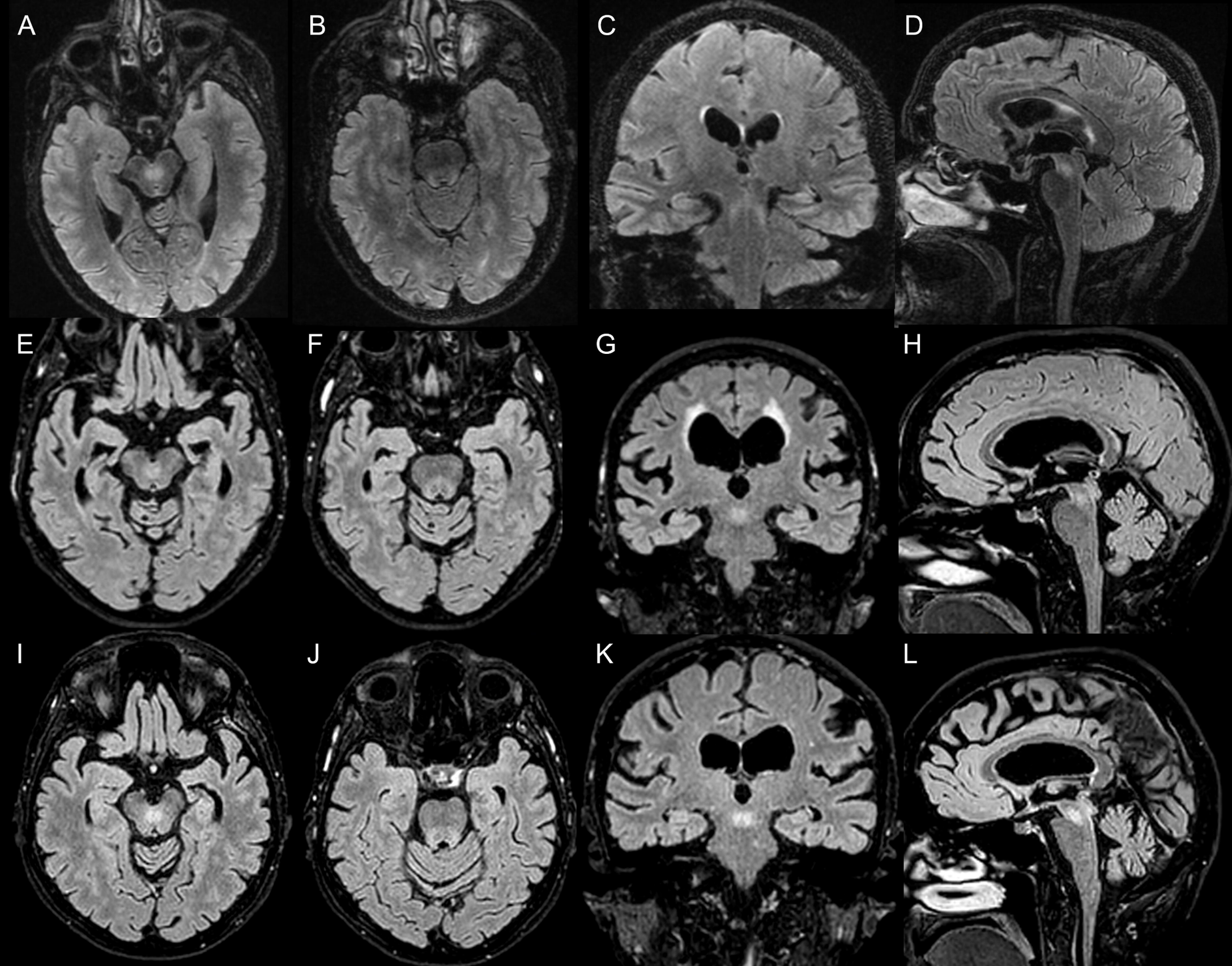
A
B
C
D
E
F
G
H
I
J
K
L

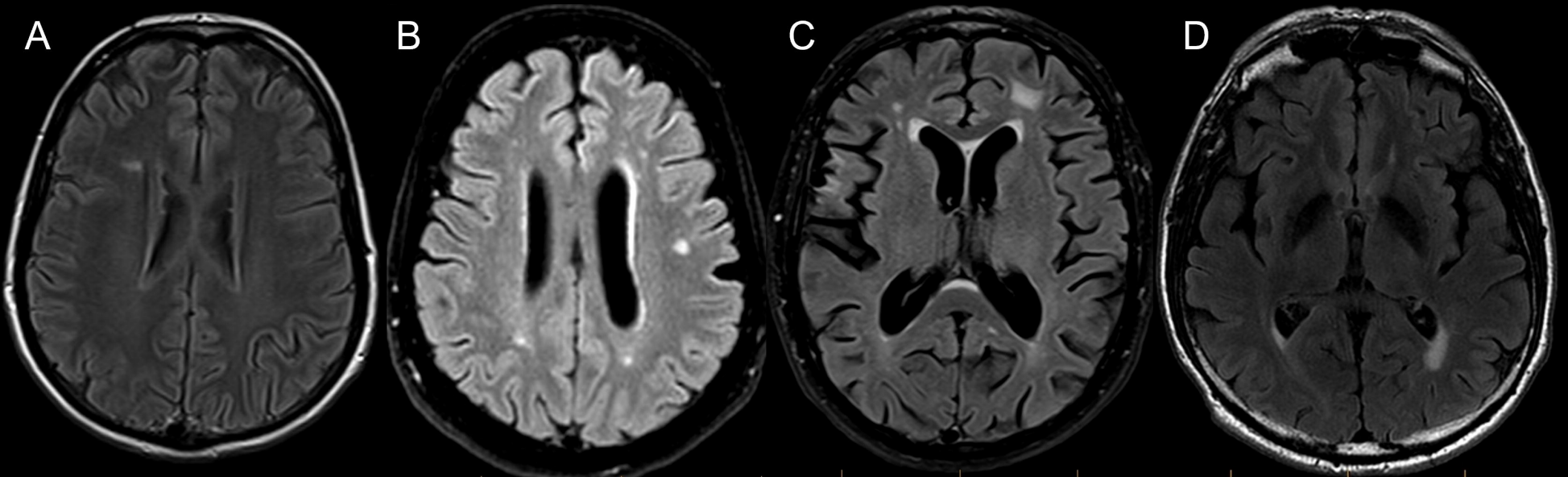
A
B
C
D