

Mucin 5AC is a sensitive surface marker for sessile serrated lesions: results from a systematic review and meta-analysis

Kevin Liu¹, Moniyka Sachar MD^{1,2}, Violeta Popov MD PhD^{1,2,3}, Ziheng Pei MD PhD^{1,2,4}, Giulio Quarta, MD^{1,2,3,*}

¹NYU Grossman School of Medicine

²Department of Medicine

³Division of Gastroenterology

⁴Department of Pathology

*To whom correspondence should be addressed: giulio.quarta@nyulangone.org

Abstract:

Sessile serrated lesions (SSLs) are a class of colon polyps which are challenging to detect through current screening methods but are highly associated with colon cancer. We reasoned that a biomarker sensitive for SSLs would be clinically useful to improve detection. Recent endoscopic and histopathologic studies suggest that SSLs are associated with alterations in intestinal mucin expression but the frequency with which this occurs is not known. We performed a meta-analysis of available pathologic studies comparing mucin expression on SSLs to normal colonic mucosa, tubular adenomas (TAs), villous adenomas (VAs), traditional serrated adenomas (TSAs), and hyperplastic polyps (HPs). We searched Medline, Pubmed, and Embase and found 440 publications in this topic, and 18 total studies met inclusion. We found that MUC5AC expression was more common in SSLs compared to normal colonic mucosa (OR=82.9, p<0.01), TAs (OR=11, p<0.01), and TSAs (OR=3.6, p=0.04). We found no difference in MUC5AC expression between SSLs versus HPs (OR=2.1, p=0.09) and no difference in MUC5AC expression between left colon and right colon HPs, with an OR=1.8, p=0.23. We found that MUC5AC expression was found commonly on VAs, SSLs, and TSAs while the frequency on colon cancers declined. MUC5AC is also upregulated in inflammatory bowel disease and in response to intestinal infections. MUC5AC expression highlights the potential of mucins as sensitive biomarkers, though not specific to SSLs. Further research into the clinical utilization of MUC5AC could enhance SSL detection.

Introduction:

In the United States and globally, populations have benefitted greatly from colon cancer screening efforts, with fecal immunochemical testing (FIT), colonoscopy, and computed tomographic colonography the most widely used tests (1). A significant improvement in morbidity and mortality comes from the ability to detect and remove colon polyps (2,3), neoplastic lesions in the colon which are precursors to high-risk dysplasia or cancer. Colon polyps are defined by histopathology as hyperplastic polyps (HPs), tubular adenomas (TAs), villous adenomas (VAs), or sessile serrated lesions (SSLs) and provide prognostic information on an individual risk of cancer (4).

Detecting colon polyps is a major goal of colonoscopy (5), however SSLs in particular have evaded currently available screening methods (6). SSLs are thought to be the most common cause of interval colon cancers; which are cancers diagnosed despite screening (7) and are thought to arise either from an unusually rapid carcinoma sequence or missed lesions not visualized during colonoscopy (7,8). SSLs are typically right-sided lesions, morphologically flat, with histological features of dilated, mucin-filled, serrated crypts (9). SSLs display reduced expression of mismatch repair proteins MLH1 and MLH2 and are associated with mutations in *BRAF* or *KRAS* (10). SSLs were differentiated pathologically from HPs in 2003, and the WHO criteria for the pathological diagnosis of SSLs was updated recently (4,11).

Previous efforts to improve the detection of SSLs in the colon have included methods to examine methylation patterns in DNA (12-15), chromoendoscopy with narrow band imaging (16), color enhancement (17,18), and novel artificial intelligence approaches (19). Despite these efforts, no single modality has gained acceptance due to cost and modest sensitivity (14). We hypothesized that a biomarker akin to the widely available fecal immunochemical testing (FIT), would be a reasonable marker for SSL development. To search for a biomarker of SSLs, we performed a meta-analysis of immunohistochemical studies and found numerous studies examining an altered pattern of mucin expression on the surface of SSLs. Our findings support that the mucin MUC5AC is a sensitive surface marker of SSLs.

Mucins are glycoproteins expressed on the surface of colon epithelium, secreted either by enterocytes or goblet cells (Figure 1) forming a dual layer of protective proteins for epithelial cells (20). The normal colon secretes mucins MUC1, MUC2, and MUC3, which can be membrane-bound or unbound (21,22). However, endoscopists (23) and pathologists (24) have noted abnormalities in the mucin expression pattern on polyps and colon cancers, and this pattern remains a criterion for detection of SSLs. While MUC5AC is typically expressed on surface and pit epithelia of gastric mucosa (25) as well as airway epithelia (26,27), aberrant mucin expression in the colon is thought to arise from the same genetic alterations which cause colon cancer (Figure 1) (23,28).

In this study, we examined the mucin expression pattern across colon polyps by histopathologic subtype. We find that MUC5AC is a surface marker highly expressed on the surface of SSLs, though it is not specific to serrated pathway lesions.

Methods

A total of three databases including Embase, Pubmed, and Medline were searched from inception to November 2023. A search strategy using the search criteria “mucin” AND “immunohistochemistry” AND “polyp” to identify studies reporting mucin expression in colonic polyps. Peer reviewed journal articles but not conference abstracts were included in the analysis. Observational retrospective studies and case series were included for full review if they were human studies that reported at least colonic sessile serrated lesion pathology subtypes and the number of colonic polyps associated with mucin positivity. For a study to be included in a MUC5AC expression comparison group, the authors must report mucin expression in polyp subtypes compared. Other reasons for exclusion were if they were written in a language other than English, were conference abstracts, or reported insufficient data to calculate odds ratios. The primary outcome assessed was the expression of mucins on the surface of SSLs compared to normal mucosa, TAs, TSAs, and HPs. Secondary outcomes included the expression of mucins in proximal HPs versus distal HPs. Studies included are listed in Supplementary Table 1 (29-47).

Full texts were reviewed by 2 study authors (KL and MS). Data was abstracted from the full text by one author (either KL or MS) and confirmed by an alternative author (either KL or MS).

Conflicts were resolved by discussion and consensus, with a senior author (GQ or VP) serving as the final arbiter if consensus was not achieved.

A random effects meta-analysis was used due to the initial assumption of heterogeneity among the individual studies. Heterogeneity was assessed using Cochran's Q and I² statistics, classified as not important (0 %–40 %), moderate (30 %–60 %), substantial (50 %–90 %), and considerable (75 %–100 %) (Higgins and Green, 2011). All analyses were done using Comprehensive Meta-Analysis Software, version 3.0 (Biostat, Engelwood, NJ, USA).

Results

Of the 440 citations identified, 18 were included in the final analysis (Fig. 2). Included studies encompassed 3,554 polyps, of which 32-75% came from female patients, with an average age ranging from 57 to 67 years old. Studies included polyp samples from the USA, Japan, Iran, Korea, France, and Turkey (Supplementary Table 1). For MUC1, MUC2, MUC5AC, and MUC6 expression there was insufficient data to perform a meta-regression by age and gender.

Of the 18 studies that were included in the final analysis, 14 reported MUC5AC expression in SSLs (Supplementary Table 2). We found that MUC5AC expression was more common in SSLs compared to normal colonic mucosa, with an OR=82.9, $p<0.01$ (4 studies, 107 SSLs polyps, 86 normal samples, $I^2=0\%$) (Figure 2). This finding is consistent with prior research as MUC5AC is not normally expressed in normal colonic mucosa (21). We found MUC5AC expression in SSLs to be higher than in TA samples, with an OR=11, $p<0.01$ (9 studies, 412 SSLs polyps, 1221 TA polyps, $I^2= 82\%$) and TSA samples, OR=3.6, $p=0.04$ (4 studies, 287 SSLs polyps, 115 TSA polyps). We found no difference in MUC5AC expression between SSLs versus HP samples, with an OR=2.1, $p=0.09$ (9 studies, 443 SSLs polyps, 681 HP polyps).

Prior research suggests that a high proportion of proximal HPs show features of SSLs (48). Because proximal HPs and SSLs share such pathologic similarities, we wanted to assess whether proximal HPs would also express increased MUC5AC in comparison to distal HPs. There was no difference in MUC5AC expression between left colon and right colon HP samples, with an OR=1.8, $p=0.23$ (3 studies, 77 right HP polyps, 151 left HP polyps).

Numerous studies have examined MUC5AC expression in the colon in various pathologic states. MUC5AC is absent from the normal intestine past 12 weeks of gestation (49). Forgue-Lafitte et al. revealed high MUC5AC expression in ulcerative colitis and to a lesser extent diverticulitis (50). Mucin-secreting cells in the colon express MUC5AC in response to bacterial and parasitic infections (51) and after perforation of the appendix associated with bacterial invasion (52). In the progression of colon polyps to cancer, Bu (45) and Kocer (42) both demonstrated that most conventional colorectal adenocarcinomas are negative for MUC5AC but most mucinous cancers are positive. MUC5AC RNA is known to be expressed to very high levels in serrated lesions of the colon (53,54), however two previous studies using differential transcriptomics did not reveal MUC5AC to have high sensitivity or specificity for SSLs (55,56). Therefore, we conclude that MUC5AC is normally expressed by mucous-secreting cells of the stomach, endocervix, gallbladder, and tracheobronchial tree but can be found in the large intestine in states of chronic inflammation, infection, and cancer in addition to pre-cancerous colon polyps.

Discussion

Here, our search of mucin biomarkers reveals that MUC5AC differentiates serrated lesions of the colon from normal tissue. Further, the odds ratios suggest the expression rate of MUC5AC is $SSL > HP > TSA > TA$. This difference suggests there is a quantitative difference of MUC5AC expression among phenotypes, which may be more specific to SSLs. For example, Mikhaleva and colleagues report that MUC5AC expression is found intensely across the entire length of the crypt, while in HPs and TSAs expression is focal (57). Differences in MUC5AC expression between SSLs and other polyp types align with previous research on this topic. MUC5AC, MUC6, and MUC17 are consistently upregulated on SSLs based on evidence from transcriptomic, proteomic, and immunohistochemical studies.

Our findings are consistent with the notion that polyp subtypes, through differing carcinogenesis pathways, lead to significant differences in MUC5AC expression. The mechanism by which MUC5AC is upregulated is postulated to be through promoter hypomethylation and overexpression (Renault). DNA methylation changes has been found to be highly associated with serrated pathway lesions (32), and is correlated with BRAF mutation, CIMP, and MSI-H chromosomal phenotypes (32,54). In addition to alterations of mucin glycoproteins normally

found in the colon, previous immunologic studies have shown that gastric antigens are expressed *de novo* in colonic polyps as well (58-60).

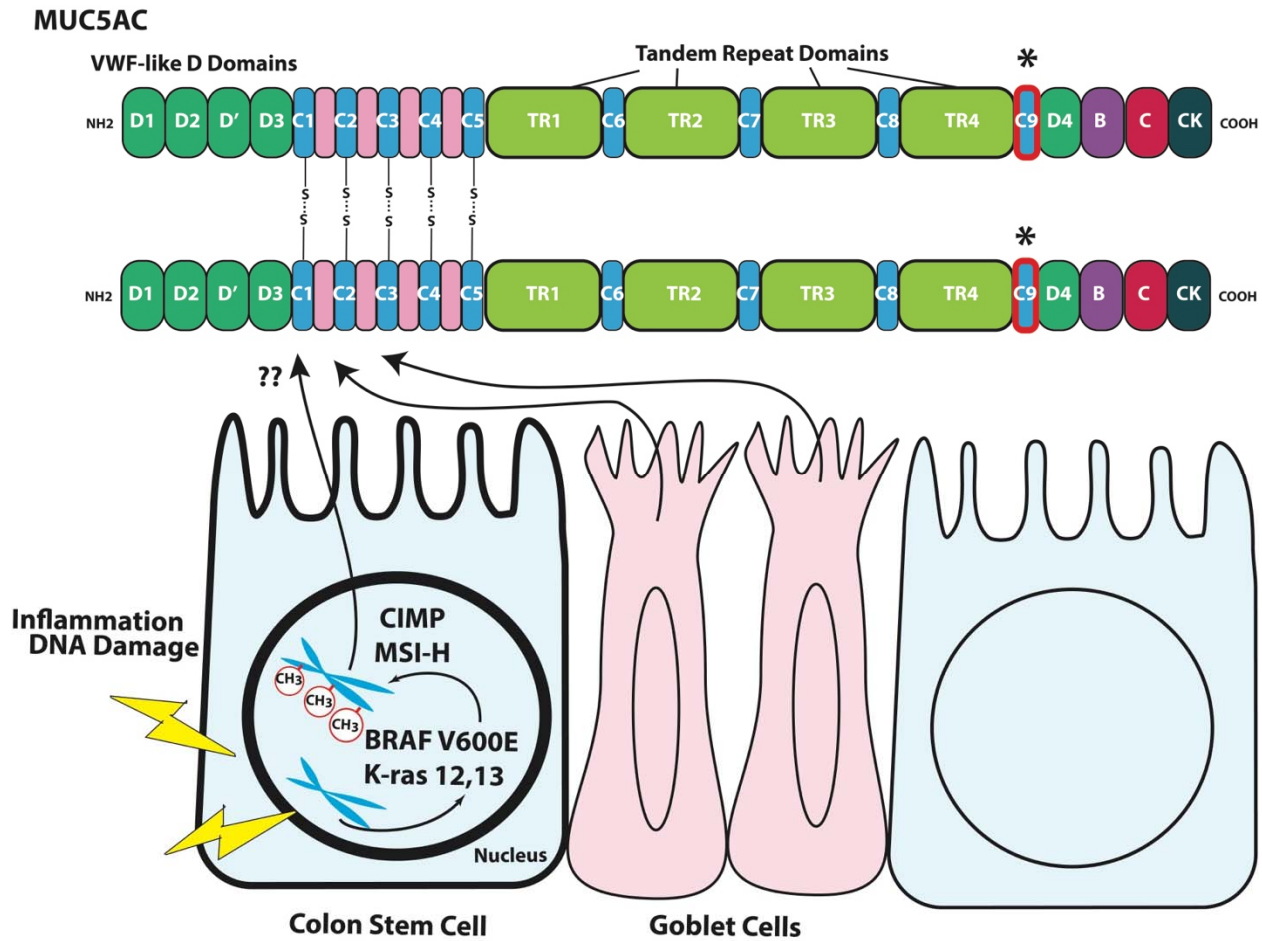
Other biomarkers for SSL development include Annexin A10 (61), Hes1 (62), Trefoil factor 1 (63), and Agrin in the muscularis layer (64), however few follow-up studies have validated these proteins. Of note, trefoil factors (TFFs) are often associated with mucins (65). Gastric-type mucin MUC6 was previously shown to be a promising biomarker for SSLs (34,38) but in a validation study did not demonstrate specificity (40), supporting the notion that HPs and SSLs lie on a continuum of carcinogenesis (54).

Although SSLs and TSAs arise from the serrated pathway, SSLs are recognized as a type of precursor lesion for colorectal cancer (CRC) with a microsatellite instability (MSI)-high phenotype, whereas TSA is likely to progress into CRC with a microsatellite stable (MSS) phenotype (66).

Given its sensitivity, we hypothesize that MUC5AC could be quantified on the surface of polyps and serve as a marker of SSL carcinogenesis. The difference in expression may distinguish HPs from SSLs for pathologists which is an evolving area of investigation. More broadly, akin to fecal immunochemical testing, the goal of a screening test is to identify as many individuals at-risk of a disease as possible. In the proper clinical context (i.e. excluding inflammatory bowel diseases and colitis patients), MUC5AC may fit this role to identify patients with SSL features. Further studies into the clinical utility of MUC5AC as a fecal biomarker or surface level expression are thus needed.

Our study has a few important limitations. Because of the difficulty in distinguishing SSLs from HPs, reported reclassification rates of HPs to SSLs in the 2007-2019 literature range from 2.6–85%, which may explain why we found no significant difference in MUC5AC expression between SSLs and HPs. Thus, there is likely pathological overlap between the defined SSLs and HPs in the studies we analyzed. Technical factors, such as staining protocols and antibodies used, different definitions of thresholds to determine positivity, as well as possible selection bias with respect to the analyzed tumors may have caused these discrepancies.

Figure 1. Domain architecture and model of MUC5AC overexpression in sessile serrated carcinogenesis.



Top panel. MUC5AC is a polymeric mucin encoded by 9 cysteine rich domains (C1-9) interspersed by nonrepetitive and tandem repeat domains. Cysteine rich domains can form multimers with other mucins (S-S bonds). The 3'-flanking region consists of the cysteine rich domains D4, B, C and cysteine knot (CK). Bottom panel. Inciting mutations in BRAF (V600E) or Kras (Codons 12 or 13) trigger a cascade of aberrant methylation in chromosomal DNA (shown as red circles on DNA) marked by CpG island methylation (CIMP) and microsatellite instability (MSI). One common methylation change is the hypomethylation of MUC5AC promoter region which leads to overexpression and secretion.

Figure 2. Flowchart of inclusion and exclusion criteria for studies.

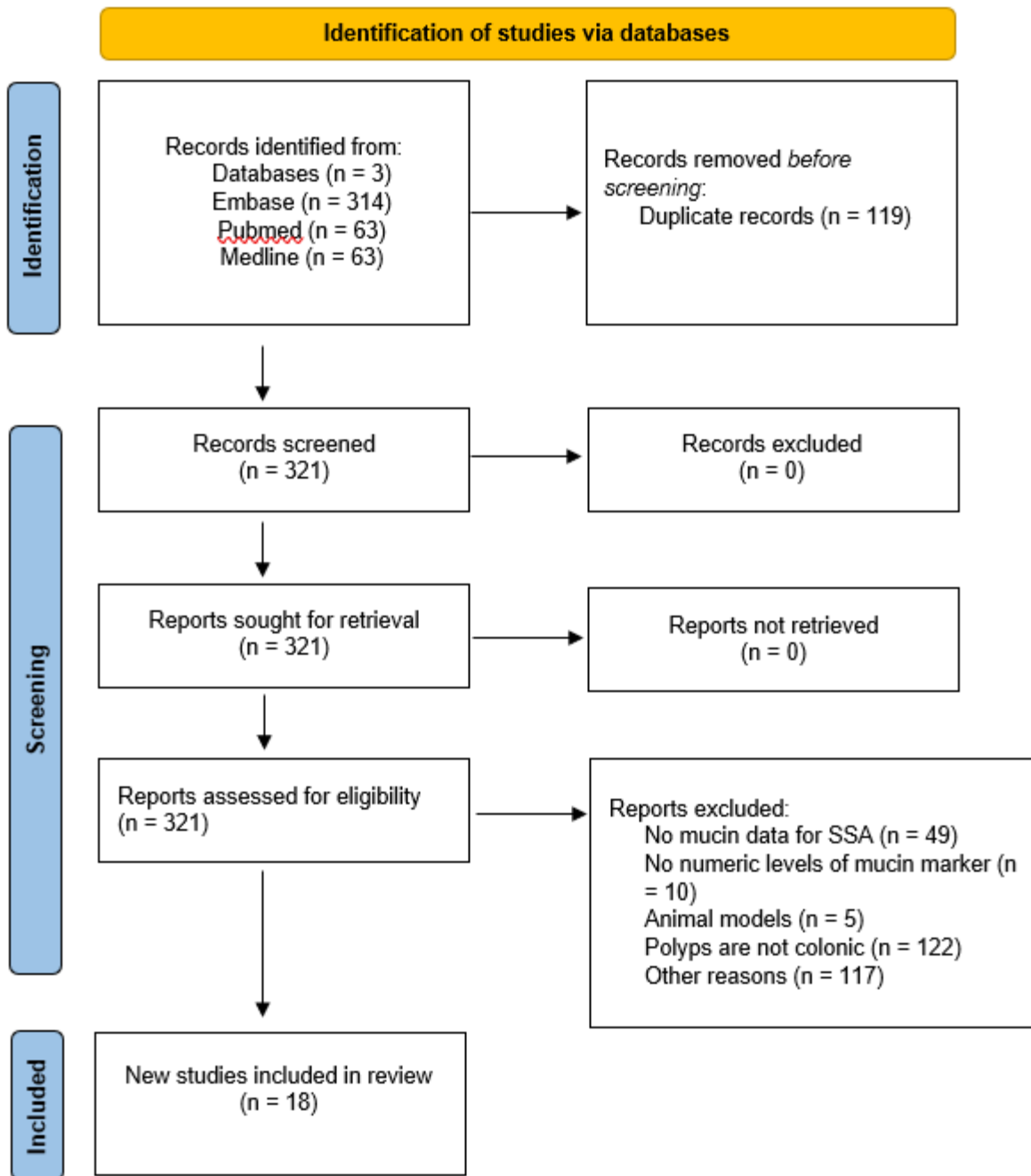
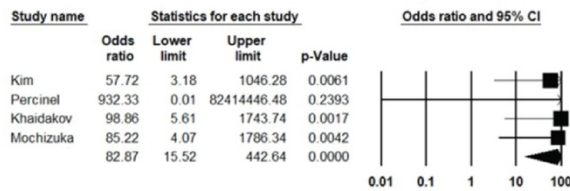
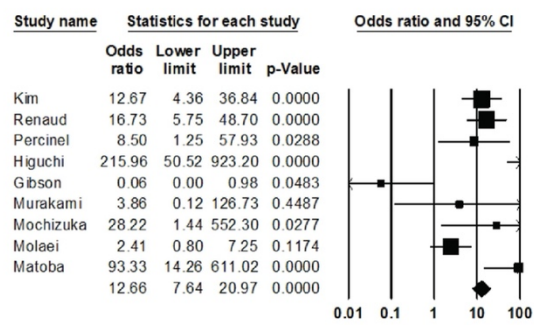


Figure 3. Forest plots of the odds ratios of MUC5AC expression in SSLs versus other histopathologic subtypes. Plots are demonstrating the odds of MUC5AC expression on the surface of SSL versus normal mucosa (A), tubular adenomas (B), hyperplastic polyps (C), and traditional serrated adenomas (D). Studies included in the meta-analysis are shown on the left panel with the cumulative odds ratio and p-values shown on the last line.

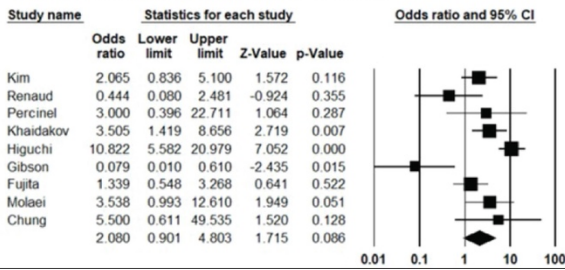
A) Odds of MUC5AC expression in SSL versus normal mucosa



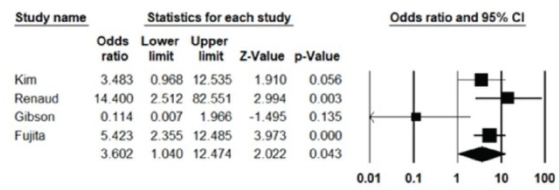
B) Odds of MUC5AC expression in SSL versus TA



C) Odds of MUC5AC expression in SSL versus HP



D) Odds of MUC5AC expression in SSL versus TSA



References

1. Lin JS, Perdue LA, Henrikson NB, Bean SI, Blasi PR. Screening for Colorectal Cancer: Updated Evidence Report and Systematic Review for the US Preventive Services Task Force. *JAMA* **2021**;325:1978-98
2. Juul FE, Cross AJ, Schoen RE, Senore C, Pinsky P, Miller E, *et al.* 15-Year Benefits of Sigmoidoscopy Screening on Colorectal Cancer Incidence and Mortality : A Pooled Analysis of Randomized Trials. *Ann Intern Med* **2022**;175:1525-33
3. Zauber AG, Winawer SJ, O'Brien MJ, Lansdorp-Vogelaar I, van Ballegooijen M, Hankey BF, *et al.* Colonoscopic polypectomy and long-term prevention of colorectal-cancer deaths. *The New England journal of medicine* **2012**;366:687-96
4. Nagtegaal ID, Odze RD, Klimstra D, Paradis V, Rugge M, Schirmacher P, *et al.* The 2019 WHO classification of tumours of the digestive system. *Histopathology* **2020**;76:182-8
5. Rex DK. Key quality indicators in colonoscopy. *Gastroenterol Rep (Oxf)* **2023**;11:goad009
6. Chang LC, Shun CT, Hsu WF, Tu CH, Tsai PY, Lin BR, *et al.* Fecal Immunochemical Test Detects Sessile Serrated Adenomas and Polyps With a Low Level of Sensitivity. *Clin Gastroenterol Hepatol* **2017**;15:872-9 e1
7. Richter JM, Pino MS, Austin TR, Campbell E, Szymonifka J, Russo AL, *et al.* Genetic mechanisms in interval colon cancers. *Dig Dis Sci* **2014**;59:2255-63
8. Arain MA, Sawhney M, Sheikh S, Anway R, Thyagarajan B, Bond JH, Shaikat A. CIMP status of interval colon cancers: another piece to the puzzle. *The American journal of gastroenterology* **2010**;105:1189-95
9. Rex DK, Ahnen DJ, Baron JA, Batts KP, Burke CA, Burt RW, *et al.* Serrated lesions of the colorectum: review and recommendations from an expert panel. *The American journal of gastroenterology* **2012**;107:1315-29; quiz 4, 30
10. Aiderus A, Barker N, Tergaonkar V. Serrated colorectal cancer: preclinical models and molecular pathways. *Trends Cancer* **2024**;10:76-91
11. Mezzapesa M, Losurdo G, Celiberto F, Rizzi S, d'Amati A, Piscitelli D, *et al.* Serrated Colorectal Lesions: An Up-to-Date Review from Histological Pattern to Molecular Pathogenesis. *Int J Mol Sci* **2022**;23
12. Anderson JC, Hisey WM, Robinson CM, Limburg PJ, Kneeder BL, Butterly LF. Serrated Polyp Yield at Colonoscopy in Patients with Positive FIT, Positive mt-sDNA, and Colonoscopy Only: Data from the New Hampshire Colonoscopy Registry. *Cancer Epidemiol Biomarkers Prev* **2023**;32:226-32
13. Gallardo-Gomez M, Costas-Rios L, Garcia-Prieto CA, Alvarez-Rodriguez L, Bujanda L, Barrero M, *et al.* Serum DNA methylome of the colorectal cancer serrated pathway enables non-invasive detection. *Mol Oncol* **2023**
14. Carethers JM. Fecal DNA Testing for Colorectal Cancer Screening. *Annu Rev Med* **2020**;71:59-69
15. Sajibu S, Sonder E, Tiwari A, Orjuela S, Parker HR, Frans OT, *et al.* Validation of hypermethylated DNA regions found in colorectal cancers as potential aging-independent biomarkers of precancerous colorectal lesions. *BMC Cancer* **2023**;23:998

16. Ferreira AO, Reves JB, Nascimento C, Frias-Gomes C, Costa-Santos MP, Ramos LR, *et al.* Narrow Band Imaging versus White Light for the Detection of Sessile Serrated Colorectal Lesions: A Randomized Clinical Trial. *GE Port J Gastroenterol* **2023**;30:368-74
17. Desai M, Viswanathan L, Gupta N, Kennedy KF, Repici A, Hassan C, Sharma P. Impact of Electronic Chromoendoscopy on Adenoma Miss Rates During Colonoscopy: A Systematic Review and Meta-analysis. *Dis Colon Rectum* **2019**;62:1124-34
18. Nishizawa T, Toyoshima O, Yoshida S, Uekura C, Kurokawa K, Munkhjargal M, *et al.* TXI (Texture and Color Enhancement Imaging) for Serrated Colorectal Lesions. *J Clin Med* **2021**;11
19. Glissen Brown JR, Mansour NM, Wang P, Chuchuca MA, Minchenberg SB, Chandnani M, *et al.* Deep Learning Computer-aided Polyp Detection Reduces Adenoma Miss Rate: A United States Multi-center Randomized Tandem Colonoscopy Study (CADeT-CS Trial). *Clin Gastroenterol Hepatol* **2022**;20:1499-507 e4
20. Cox KE, Liu S, Lwin TM, Hoffman RM, Batra SK, Bouvet M. The Mucin Family of Proteins: Candidates as Potential Biomarkers for Colon Cancer. *Cancers (Basel)* **2023**;15
21. Ho SB, Shekels LL, Toribara NW, Kim YS, Lyftogt C, Cherwitz DL, Niehans GA. Mucin gene expression in normal, preneoplastic, and neoplastic human gastric epithelium. *Cancer Res* **1995**;55:2681-90
22. Shekels LL, Hunninghake DA, Tisdale AS, Gipson IK, Kieliszewski M, Kozak CA, Ho SB. Cloning and characterization of mouse intestinal MUC3 mucin: 3' sequence contains epidermal-growth-factor-like domains. *Biochem J* **1998**;330 (Pt 3):1301-8
23. Tadepalli US, Feihel D, Miller KM, Itzkowitz SH, Freedman JS, Kornacki S, *et al.* A morphologic analysis of sessile serrated polyps observed during routine colonoscopy (with video). *Gastrointestinal endoscopy* **2011**;74:1360-8
24. Hakomori S. Aberrant glycosylation in tumors and tumor-associated carbohydrate antigens. *Adv Cancer Res* **1989**;52:257-331
25. Krishn SR, Ganguly K, Kaur S, Batra SK. Ramifications of secreted mucin MUC5AC in malignant journey: a holistic view. *Carcinogenesis* **2018**;39:633-51
26. Hovenberg HW, Davies JR, Herrmann A, Linden CJ, Carlstedt I. MUC5AC, but not MUC2, is a prominent mucin in respiratory secretions. *Glycoconj J* **1996**;13:839-47
27. Rose MC, Voynow JA. Respiratory tract mucin genes and mucin glycoproteins in health and disease. *Physiol Rev* **2006**;86:245-78
28. Pothuraju R, Rachagani S, Krishn SR, Chaudhary S, Nimmakayala RK, Siddiqui JA, *et al.* Molecular implications of MUC5AC-CD44 axis in colorectal cancer progression and chemoresistance. *Mol Cancer* **2020**;19:37
29. Bartman AE, Sanderson SJ, Ewing SL, Niehans GA, Wiehr CL, Evans MK, Ho SB. Aberrant expression of MUC5AC and MUC6 gastric mucin genes in colorectal polyps. *Int J Cancer* **1999**;80:210-8
30. Khaidakov M, Lai KK, Roudachevski D, Sargsyan J, Goyne HE, Pai RK, *et al.* Gastric Proteins MUC5AC and TFF1 as Potential Diagnostic Markers of Colonic Sessile Serrated Adenomas/Polyps. *Am J Clin Pathol* **2016**;146:530-7
31. Kim JH, Kim KJ, Rhee YY, Bae JM, Cho NY, Lee HS, Kang GH. Gastric-type expression signature in serrated pathway-associated colorectal tumors. *Hum Pathol* **2015**;46:643-56

32. Renaud F, Mariette C, Vincent A, Wacrenier A, Maunoury V, Leclerc J, *et al.* The serrated neoplasia pathway of colorectal tumors: Identification of MUC5AC hypomethylation as an early marker of polyps with malignant potential. *Int J Cancer* **2016**;138:1472-81
33. Walsh MD, Clendenning M, Williamson E, Pearson SA, Walters RJ, Nagler B, *et al.* Expression of MUC2, MUC5AC, MUC5B, and MUC6 mucins in colorectal cancers and their association with the CpG island methylator phenotype. *Mod Pathol* **2013**;26:1642-56
34. Bartley AN, Thompson PA, Buckmeier JA, Kepler CY, Hsu CH, Snyder MS, *et al.* Expression of gastric pyloric mucin, MUC6, in colorectal serrated polyps. *Mod Pathol* **2010**;23:169-76
35. Percinel S, Savas B, Ensari A, Kuzu I, Kuzu MA, Bektas M, *et al.* Mucins in the colorectal neoplastic spectrum with reference to conventional and serrated adenomas. *Turk J Gastroenterol* **2007**;18:230-8
36. Fujita K, Hirahashi M, Yamamoto H, Matsumoto T, Gushima M, Oda Y, *et al.* Mucin core protein expression in serrated polyps of the large intestine. *Virchows Arch* **2010**;457:443-9
37. Mochizuka A, Uehara T, Nakamura T, Kobayashi Y, Ota H. Hyperplastic polyps and sessile serrated 'adenomas' of the colon and rectum display gastric pyloric differentiation. *Histochem Cell Biol* **2007**;128:445-55
38. Owens SR, Chiosea SI, Kuan SF. Selective expression of gastric mucin MUC6 in colonic sessile serrated adenoma but not in hyperplastic polyp aids in morphological diagnosis of serrated polyps. *Mod Pathol* **2008**;21:660-9
39. Hirono H, Ajioka Y, Watanabe H, Baba Y, Tozawa E, Nishikura K, *et al.* Bidirectional gastric differentiation in cellular mucin phenotype (foveolar and pyloric) in serrated adenoma and hyperplastic polyp of the colorectum. *Pathol Int* **2004**;54:401-7
40. Gibson JA, Hahn HP, Shahsafaei A, Odze RD. MUC expression in hyperplastic and serrated colonic polyps: lack of specificity of MUC6. *Am J Surg Pathol* **2011**;35:742-9
41. Murakami T, Akazawa Y, Yatagai N, Hiromoto T, Sasahara N, Saito T, *et al.* Molecular characterization of sessile serrated adenoma/polyps with dysplasia/carcinoma based on immunohistochemistry, next-generation sequencing, and microsatellite instability testing: a case series study. *Diagn Pathol* **2018**;13:88
42. Kocer B, Soran A, Erdogan S, Karabeyoglu M, Yildirim O, Eroglu A, *et al.* Expression of MUC5AC in colorectal carcinoma and relationship with prognosis. *Pathol Int* **2002**;52:470-7
43. Buisine MP, Janin A, Maunoury V, Audie JP, Delescaut MP, Copin MC, *et al.* Aberrant expression of a human mucin gene (MUC5AC) in rectosigmoid villous adenoma. *Gastroenterology* **1996**;110:84-91
44. Ban S, Mitomi H, Horiguchi H, Sato H, Shimizu M. Adenocarcinoma arising in small sessile serrated adenoma/polyp (SSA/P) of the colon: clinicopathological study of eight lesions. *Pathol Int* **2014**;64:123-32
45. Bu XD, Li N, Tian XQ, Li L, Wang JS, Yu XJ, Huang PL. Altered expression of MUC2 and MUC5AC in progression of colorectal carcinoma. *World J Gastroenterol* **2010**;16:4089-94

46. Molaei M, Mansoori BK, Mashayekhi R, Vahedi M, Pourhoseingholi MA, Fatemi SR, Zali MR. Mucins in neoplastic spectrum of colorectal polyps: can they provide predictions? *BMC Cancer* **2010**;10:537
47. Biemer-Huttman AE, Walsh MD, McGuckin MA, Ajioka Y, Watanabe H, Leggett BA, Jass JR. Immunohistochemical staining patterns of MUC1, MUC2, MUC4, and MUC5AC mucins in hyperplastic polyps, serrated adenomas, and traditional adenomas of the colorectum. *J Histochem Cytochem* **1999**;47:1039-48
48. Baker K, Zhang Y, Jin C, Jass JR. Proximal versus distal hyperplastic polyps of the colorectum: different lesions or a biological spectrum? *J Clin Pathol* **2004**;57:1089-93
49. Buisine MP, Devisme L, Savidge TC, Gespach C, Gosselin B, Porchet N, Aubert JP. Mucin gene expression in human embryonic and fetal intestine. *Gut* **1998**;43:519-24
50. Forgue-Lafitte ME, Fabiani B, Levy PP, Maurin N, Flejou JF, Bara J. Abnormal expression of M1/MUC5AC mucin in distal colon of patients with diverticulitis, ulcerative colitis and cancer. *Int J Cancer* **2007**;121:1543-9
51. Hasnain SZ, Gallagher AL, Grecis RK, Thornton DJ. A new role for mucins in immunity: insights from gastrointestinal nematode infection. *Int J Biochem Cell Biol* **2013**;45:364-74
52. Semino-Mora C, Liu H, McAvoy T, Nieroda C, Studeman K, Sardi A, Dubois A. Pseudomyxoma peritonei: is disease progression related to microbial agents? A study of bacteria, MUC2 AND MUC5AC expression in disseminated peritoneal adenomucinosis and peritoneal mucinous carcinomatosis. *Ann Surg Oncol* **2008**;15:1414-23
53. Delker DA, McGettigan BM, Kanth P, Pop S, Neklason DW, Bronner MP, *et al.* RNA sequencing of sessile serrated colon polyps identifies differentially expressed genes and immunohistochemical markers. *PLoS One* **2014**;9:e88367
54. Chen B, Scurrah CR, McKinley ET, Simmons AJ, Ramirez-Solano MA, Zhu X, *et al.* Differential pre-malignant programs and microenvironment chart distinct paths to malignancy in human colorectal polyps. *Cell* **2021**;184:6262-80 e26
55. Kanth P, Bronner MP, Boucher KM, Burt RW, Neklason DW, Hagedorn CH, Delker DA. Gene Signature in Sessile Serrated Polyps Identifies Colon Cancer Subtype. *Cancer Prev Res (Phila)* **2016**;9:456-65
56. Kanth P, Boylan KE, Bronner MP, Boucher KM, Hazel MW, Yao R, *et al.* Molecular Biomarkers of Sessile Serrated Adenoma/Polyps. *Clin Transl Gastroenterol* **2019**;10:e00104
57. Mikhaleva LM, Vandysheva RA, Shakhpazyan NK, Fedorov ED, Biryukov AE, Midiber KY, Pechnikova VV. [Comparative assessment of the expression of Muc 2, Muc 5AC, and Muc 6 in serrated neoplasms of the colon]. *Arkh Patol* **2019**;81:10-7
58. Bara J, Chastre E, Mahiou J, Singh RL, Forgue-Lafitte ME, Hollande E, Godeau F. Gastric M1 mucin, an early oncofetal marker of colon carcinogenesis, is encoded by the MUC5AC gene. *Int J Cancer* **1998**;75:767-73
59. Bara J, Gautier R, Mouradian P, Decaens C, Daher N. Oncofetal mucin M1 epitope family: characterization and expression during colonic carcinogenesis. *Int J Cancer* **1991**;47:304-10

60. Higgins PJ, Friedman E, Lipkin M, Hertz R, Attiyeh F, Stonehill EH. Expression of gastric-associated antigens by human premalignant and malignant colonic epithelial cells. *Oncology* **1983**;40:26-30
61. Gonzalo DH, Lai KK, Shadrach B, Goldblum JR, Bennett AE, Downs-Kelly E, *et al.* Gene expression profiling of serrated polyps identifies annexin A10 as a marker of a sessile serrated adenoma/polyp. *J Pathol* **2013**;230:420-9
62. Cui M, Awadallah A, Liu W, Zhou L, Xin W. Loss of Hes1 Differentiates Sessile Serrated Adenoma/Polyp From Hyperplastic Polyp. *Am J Surg Pathol* **2016**;40:113-9
63. Sugai T, Osakabe M, Eizuka M, Tanaka Y, Yamada S, Yanagawa N, *et al.* Genome-wide analysis of mRNA expression identified the involvement of trefoil factor 1 in the development of sessile serrated lesions. *Pathol Res Pract* **2022**;236:153987
64. Rickelt S, Condon C, Mana M, Whittaker C, Pfirschke C, Roper J, *et al.* Agrin in the Muscularis Mucosa Serves as a Biomarker Distinguishing Hyperplastic Polyps from Sessile Serrated Lesions. *Clin Cancer Res* **2020**;26:1277-87
65. Thim L. Trefoil peptides: from structure to function. *Cell Mol Life Sci* **1997**;53:888-903
66. Tanaka Y, Eizuka M, Uesugi N, Kawasaki K, Yamano H, Suzuki H, *et al.* Traditional serrated adenoma has two distinct genetic pathways for molecular tumorigenesis with potential neoplastic progression. *J Gastroenterol* **2020**;55:846-57