

A rapid review of physical health risks associated with special procedures (tattooing, body piercing, acupuncture, electrolysis)

Authors: Meg Kiseleva¹, Judit Csontos², Deborah Edwards², Elizabeth Gillen², Mala Mann¹, Lydia Searchfield¹, Abubakar Sha'aban³, Ruth Lewis⁴, Alison Cooper³, Adrian Edwards³

1. Specialist Unit for Review Evidence, Cardiff University, United Kingdom
2. Wales Centre for Evidence Based Care, Cardiff University, United Kingdom
3. Health and Care Research Wales Evidence Centre, Cardiff University, United Kingdom
4. Health and Care Research Wales Evidence Centre, Bangor University, United Kingdom

Abstract:

Special procedures, such as tattooing (including semi-permanent make-up), body piercing, acupuncture and electrolysis involve piercing the skin and carry a potential risk of infection and other complications. This review provides an up-to-date evidence base on the main physical health risks associated with these special procedures.

Searches were conducted for research published between 2015 and 2023. Where possible, existing reviews were used. For tattooing, one systematic review including 55 studies was identified. For semi-permanent make-up, 37 cases presented in 31 case reports were identified. For body piercing, four systematic reviews were identified, which covered 174 studies. For acupuncture, one evidence map of 535 systematic reviews without age limits and one overview of 24 systematic reviews focused on children were included. For electrolysis, one case report was identified.

Complications and adverse events resulting from special procedures include fungal infections, bacterial infections, viral infections, blood-borne infections, allergic reactions, malignant growths, benign growths, sarcoidosis-related reactions, and a range of other skin and eye-related adverse reactions and dental issues.

Research Implications and Evidence Gaps: Most of the primary evidence for the physical health risks associated with the special procedures came from case reports and case series, which do not allow causal inferences or provide information on the prevalence of adverse events. Future primary research should employ more robust designs to gather evidence about the causal links between special procedures and adverse physical health events as well as about the prevalence of such events in people receiving special procedures. More evidence is needed to identify physical health risks associated with electrolysis.

Policy and Practice Implications: The evidence contained in this review will be used to inform the training of local authority enforcement officers and special procedures practitioners and to educate members of the public who seek to use these services. Due to the nature of the special procedures which involves piercing the skin and poses the risk of introducing infections to the body, high standards of hygiene may reduce the rate of infection.

Funding statement: The Wales Centre for Evidence Based Care, and the Specialist Unit for Review Evidence, were funded for this work by the Health and Care Research Wales Evidence Centre, itself funded by Health and Care Research Wales on behalf of Welsh Government.



Health and Care
Research Wales
Evidence Centre
Canolfan Dystiolaeth
Ymchwil Iechyd a
Gofal Cymru

A rapid review of physical health risks associated with special procedures (tattooing, body piercing, acupuncture, electrolysis)

December 2023



Review conducted by Cardiff Evidence Synthesis Collaborative

Report Contributors

Review Team

Meg Kiseleva, Judit Csontos, Deborah Edwards, Elizabeth Gillen, Mala Mann, Lydia Searchfield, Abubakar Sha'aban

Stakeholder

Dr Sarah Jones, Public Health Protection Directorate of Welsh Government

Methodological Advice

Ruth Lewis

Evidence Centre Team

Ruth Lewis, Adrian Edwards, Alison Cooper and Micaela Gal involved in stakeholder engagement, review of report and editing

Public Partners

Nathan Davies and Sally Anstey

Evidence need submitted to the Evidence Centre: May 2023

Initial Stakeholder Consultation Meeting: June 2023

Final report issued: December 2023

This review should be cited as: Health and Care Research Wales Evidence Centre. A rapid review of physical health risks associated with special procedures (tattooing, body piercing, acupuncture, electrolysis) (RR00018). December 2023.

A rapid review of physical health risks associated with special procedures (tattooing, body piercing, acupuncture, electrolysis)

Report number RR0018 (December, 2023)

EXECUTIVE SUMMARY

What is a Rapid Review?

Our rapid reviews use a variation of the systematic review (SR) approach, abbreviating or omitting some components to generate the evidence to inform stakeholders promptly whilst maintaining attention to bias.

Who is this Rapid Review for?

This Rapid Review was conducted on request from the Public Health Directorate of the Welsh Government in light of the implementation of Part 4: Special Procedures of the Public Health (Wales) Act 2017, which creates a mandatory licensing scheme for carrying out special procedures, such as tattooing (including semi-permanent make-up), body piercing, acupuncture and electrolysis. This review updates the evidence base for the regulations to inform how the scheme will work in practice.

Background / Aim of Rapid Review

The aforementioned special procedures involve piercing the skin and carry a potential risk of infection and other complications. The present review provides an up-to-date evidence base on the main physical health risks associated with these special procedures. Preliminary searches identified a large volume of existing systematic reviews in this field. The current review therefore utilised, where possible, existing systematic reviews or overviews/maps of existing reviews. Where there was no existing review, a review of new research (primary studies) was conducted.

Results

Extent of the evidence base

- For **tattooing**, one moderate quality systematic review including 55 studies (mainly case reports and case series) was identified. The countries where the procedures took place were not reported.
- For **semi-permanent make-up**, 37 cases presented in 31 case reports from a range of countries, including the UK, were identified.
- For **body piercing**, four systematic reviews were identified, which covered 174 studies (mainly case reports/series and cross-sectional studies) from a range of countries, including the UK. The quality of these reviews was low (n=1), moderate (n=2) and high (n=1).
- For **acupuncture**, one high quality evidence map of 535 systematic reviews without age limits and one high quality overview of 24 systematic reviews focused on children were included. The countries where the procedures took place were not reported.
- For **electrolysis**, one case report from Canada was identified.

Recency of the evidence base

Searches were conducted for research published from January 2015 to August 2023 for tattooing, body piercing, acupuncture, and electrolysis and to September 2023 for semi-permanent make-up.

- For **tattooing**: a 2021 systematic review covering primary evidence published from 1991 to 2020.
- For **semi-permanent make-up**: case reports from 2015 to 2023.
- For **body piercing**: systematic reviews published between 2016 and 2022, which included primary evidence from 1973 to 2020.

- For **acupuncture**: an evidence map and an overview of systematic reviews published in 2023 and 2015 respectively, which included systematic reviews from 1999 to 2022.
- For **electrolysis**: a case report from 2015.

Complications and adverse events

- For **tattooing**, these include bacterial infections, viral infections, blood-borne infections, allergic reactions, malignant growths, benign growths, sarcoidosis-related reactions, and a range of other skin-related adverse reactions.
 - Bacterial and viral infections reported in studies published since 2015 included non-tuberculous *Mycobacterial* skin infections, *Staphylococcal* scalded skin syndrome, and warts.
- For **semi-permanent make-up**, these include bacterial infections, viral infections, allergic reactions, sarcoidosis-related reactions and a range of other skin and eye-related adverse reactions.
 - Bacterial and viral infections reported in studies published since 2015 included necrotising fasciitis, orbital cellulitis, periorbital cellulitis, monkey pox, and *Molluscum contagiosum*.
- For **body piercing**, these include fungal, viral and bacterial infections, allergic reactions, malignant growths, benign growths, sarcoidosis-related reactions, and other skin-related adverse reactions and dental issues.
 - Bacterial and fungal infections reported in studies since 2015 included retroareolar cellulitis, unspecified infections, and *Candida dublinensis*.
- For **acupuncture**, these include infections, skin allergy reactions, and other skin-related adverse reactions.
 - Studies published since 2015 reported unspecified infections.
- For **electrolysis**, cutaneous sarcoidosis was reported.

Research Implications and Evidence Gaps

- Most of the primary evidence for the physical risks associated with the special procedures came from case reports and case series, which do not allow causal inferences or provide information on the prevalence of adverse events. Future primary research should employ more robust designs to gather evidence about the causal links between special procedures and adverse physical health events as well as about the prevalence of such events in people receiving special procedures.
- More evidence is needed to identify physical health risks associated with electrolysis.

Policy and Practice Implications

- The evidence contained in this review will be used to inform the training of local authority enforcement officers and special procedures practitioners and to educate members of the public who seek to use these services.
- Due to the nature of the special procedures which involves piercing the skin and poses the risk of introducing infections to the body, high standards of hygiene may reduce the rate of infection.

TABLE OF CONTENTS

1. BACKGROUND	9
1.1 Who is this review for?	9
1.2 Background and purpose of this review	9
2. RESULTS	10
2.1 Tattooing.....	11
2.1.1 Overview of the evidence base on tattooing	11
2.1.2 Physical health risks associated with tattooing	12
2.1.3 The quality of the SR of tattooing	13
2.1.4 Bottom line summary for tattooing.....	13
2.2 Semi-permanent make-up.....	13
2.2.1 Overview of the evidence base on semi-permanent make-up	13
2.2.2 Physical health risks associated with semi-permanent make-up	14
2.2.3 The quality of the studies on semi-permanent make-up	15
2.2.4 Bottom line summary for semi-permanent make-up	16
2.3 Body piercing.....	16
2.3.1 Overview of the evidence base on body piercing.....	16
2.3.2 Physical health risks associated with body piercing.....	17
2.3.3 The quality of the SRs of body piercing.....	19
2.3.4 Bottom line summary for body piercing	19
2.4 Acupuncture	20
2.4.1 Overview of the evidence base on acupuncture	20
2.4.2 Physical health risks associated with acupuncture	20
2.4.3 The quality of the evidence map and overview of SRs acupuncture.....	22
2.4.4 Bottom line summary for acupuncture.....	22
2.5 Electrolysis	23
2.5.1 Overview of the evidence base on electrolysis	23
2.5.2 Physical health risks associated with electrolysis	23
2.5.3 The quality of the studies on electrolysis.....	23
2.5.4 Bottom line summary for electrolysis.....	23
3. DISCUSSION.....	29
3.1 Summary of the findings.....	29
3.2 Strengths and limitations of the available evidence.....	30
3.3 Strengths and limitations of this Rapid Review	30
3.4 Implications for policy and practice.....	31
3.5 Implications for future research	31
4. REFERENCES	32
5. RAPID REVIEW METHODS.....	37
5.1 Eligibility criteria.....	37
5.2 Literature search.....	39

5.2.1	Evidence sources	39
5.2.2	Search strategy	39
5.2.3	Peer review	40
5.2.4	Reference management.....	40
5.3	Study selection process.....	40
5.4	Data extraction	40
5.5	Quality appraisal.....	40
5.5.1	Quality of the SRs and map/overview of reviews	40
5.5.2	Quality of the case reports	41
5.6	Synthesis.....	42
5.7	Assessment of body of evidence.....	44
6.	EVIDENCE.....	45
6.1	Search results and study selection.....	45
6.2	Data extraction	46
6.3	Quality appraisal.....	78
6.4	Information available on request	79
7.	ADDITIONAL INFORMATION	80
7.1	Conflicts of interest.....	80
7.2	Acknowledgements	80
8.	APPENDIX.....	81
	APPENDIX 1: Glossary.....	81
	APPENDIX 2: Search Results	85
	APPENDIX 3: Websites searched for grey literature	110
	APPENDIX 4: Excluded studies.....	112
	APPENDIX 5: Table of unique primary studies of body piercing	117

Abbreviations

Acronym	Full Description
CI	Confidence Interval
ER	Event Rate
GRADE	Grading of Recommendations, Assessment, Development and Evaluation
HIV	Human Immunodeficiency Virus
OR	Odds Ratio
RR	Relative Risk
SR	Systematic Review
UK	United Kingdom
USA	United States of America

Definitions

Acupuncture is the insertion of one or several needles into the skin at specific sites or acupuncture points for therapeutic purposes (Ernst 2010).

Acupoint catgut embedding is the implantation of absorbable catgut sutures at acupoints (Inprasit et al. 2020).

Auricular acupuncture is acupuncture of the ear (Kay Garcia & Chiang 2007).

Electroacupuncture is a type of acupuncture in which a weak electric current is passed through acupuncture needles into the skin (Cai & Yang 2019).

Dry needling therapy is the insertion of thin needles into the body (Dunning et al. 2014).

Electrolysis is a permanent method of hair removal and involves inserting a small needle or probe into the hair follicle and passing an electric current through it, aiming to destroy the follicle to prevent hair regrowth (Fernandez et al. 2013).

Microblading is a semi-permanent cosmetic procedure used to enhance the appearance of eyebrows. It is a form of eyebrow tattooing where pigment is introduced into the skin using fine needles to create hair-like strokes on the skin (Wong & Heacock 2018).

Micropigmentation is a cosmetic procedure that involves the application of pigments to the skin to create semi-permanent or permanent make-up (De Cuyper 2008). The difference between tattooing and semi-permanent skin colouring is based on the depth at which ink is placed within the skin.

1. BACKGROUND

1.1 Who is this review for?

This Rapid Review was conducted as part of the Health and Care Research Wales Evidence Centre Work Programme. The above question was suggested by the Public Health Directorate of Welsh Government in light of the implementation of Part 4: Special Procedures of the Public Health (Wales) Act 2017. The Act creates a mandatory licensing scheme for carrying out special procedures, which include tattooing, body piercing, acupuncture and electrolysis.

Given the licensing scheme is due to come into force in 2024, the requested review updates the evidence base for the regulations to provide assurance that the risks associated with these procedures remain relevant to the proposed requirements of the licensing scheme and to inform how the scheme will work in practice.

1.2 Background and purpose of this review

The prevalence of individuals in the UK receiving tattoos, including semi-permanent skin make-up such as microblading and micropigmentation, as well as cosmetic piercings, electrolysis and acupuncture, collectively known as “special procedures”, is on the rise. Each of these special procedures involves piercing the skin and as a consequence, all of these procedures carry a potential risk of infection (Royal Society for Public Health 2019).

Special procedures can lead to infection from endogenous and exogenous agents (Patel & Cobbs 2015). Endogenous agents are microorganisms that naturally reside on the skin and these do not normally cause problems. However, if the skin barrier is broken or disrupted during the procedure, they can enter the skin and cause infections at the site where the skin is pierced. Common causes of endogenous infection include streptococci, staphylococci and pseudomonas (Patel & Cobbs 2015). The second cause of infection arises from exogenous agents, which are microorganisms not naturally present on the skin. These agents are introduced during the procedure through contaminated tools or equipment, such as a dirty needle, and can lead to the transmission of blood-borne viruses, for example, viral hepatitis, tuberculosis, syphilis and HIV (Patel & Cobbs 2015, Royal Society for Public Health 2019).

Many complications related to tattooing or the application of semi-permanent make-up are caused by acute allergies and delayed hypersensitivity reactions, primarily triggered by the ingredients present in the tattoo inks or trauma during tattooing or removal procedures. These non-specific reactions, often worsened by exposure to sunlight, are unpredictable and may occasionally manifest after a long period of time (even decades), leading to chronic complications associated with underlying auto-immune conditions (Piccinini et al. 2016).

Consequently, it is crucial for practitioners to adhere to safe working practices and have good infection control measures in place so that both clients and practitioners can be safeguarded and protected (Chartered Institute of Environmental Health 2013). Additionally, the increasing prevalence of antimicrobial-resistant infections, responsible for a significant number of fatalities each year in Europe and the USA alone (estimated to be at least 50,000 lives),

underscores the critical importance of minimising infections associated with special procedures (O'Neill 2014).

The regulations and laws concerning special procedures vary across the different regions of the UK. In Wales in 2017, the Public Health (Wales) Act was enacted (Welsh Government 2017) and under Part 4 of the Act, special procedures were categorised as follows: tattooing, which includes both traditional tattooing and semi-permanent make-up such as microblading and micropigmentation; piercing, which covers various body piercing practices; electrolysis, involving the removal of hair using electric currents; and acupuncture, which includes dry needling techniques (National Assembly for Wales 2017). The legislation ensures public safety by establishing clear guidelines for practitioners, thus minimising health risks associated with the special procedures.

As part of the final phase of the changes introduced under the Public Health (Wales) Act 2017, Wales is set to become the first UK nation to introduce a mandatory national licensing scheme for the providers of special procedures (Welsh Government 2023). In preparation for this process, this Rapid Review provides an up-to-date evidence base on the main physical health risks that may be associated with tattooing, body piercing, acupuncture and electrolysis. As such, it answers the following questions:

- Q1a. What are the physical health risks associated with tattooing (including semi-permanent make-up)?
- Q1b. What are the physical health risks associated with semi-permanent make-up (i.e., microblading and micropigmentation)?
- Q2. What are the physical health risks associated with body piercing?
- Q3. What are the physical health risks associated with acupuncture?
- Q4. What are the physical health risks associated with electrolysis?

Preliminary searches identified a large volume of existing systematic reviews in this field. The current review therefore utilised, where possible, existing systematic reviews or overviews or maps of existing reviews. Where there was no existing review, a review of new research (primary studies) was conducted.

2. RESULTS

This section details the extent of the evidence base and provides an overview of the included research reporting adverse events or complications experienced by individuals who have received a tattoo, semi-permanent make-up, body piercing, acupuncture or electrolysis as identified in the literature. The research evidence is summarised separately for each of the special procedures: tattooing, semi-permanent make-up, body piercing, acupuncture and electrolysis.

The overview of the evidence base provides a description of the characteristics of the available evidence, including, where such information was available, study designs, the dates of the studies, demographic information of the participants, the puncture site, the type of practitioner undertaking the procedure, the countries where the procedures were performed, the outcomes

of interest and the time frame of when an adverse reaction or complication was experienced or reported.

Summaries of the reported clinical presentations (signs and symptoms of a medical problem), microbiological complications and non-microbiological complications are presented in Tables 1–3. A glossary of the terms associated with the adverse events is available in Appendix 1.

Microbiological complications in the context of special procedures refer to adverse reactions related to the presence of growth of microorganisms (such as bacteria, viruses or fungi) in or around the puncture site. Non-microbiological complications related to special procedures are health issues or adverse reactions that can arise from the special procedure processes themselves or the tattooing ink but that do not involve microorganisms.

At the end of each section dedicated to a particular special procedure, the quality of the included evidence based on the relevant quality appraisal checklists is summarised. Details of how quality was assessed are provided in Section 5.5. Quality appraisal tables are reported in Section 6.3, with Table 16 providing a summary of the critical appraisal scores of the included SRs, evidence map and overview of reviews and Table 17 of the case reports.

The detailed eligibility criteria for this review are presented in Tables 4–8 in Section 5.1. The results of the searches are reported in Appendix 2, and the study selection process is presented in Table 9 in Section 6.1.

2.1 Tattooing

2.1.1 Overview of the evidence base on tattooing

The searches identified one SR (Sindoni et al. 2021) that focused on tattooing, which included 55 studies (see Table 10). The study designs included 32 case reports, 13 case series, seven cross-sectional studies, two prospective cohort studies and one retrospective cohort study, which were published between 1991 and 2020. From 2015 to 2020 there were 15 case reports, eight case series and one cohort study. The locations of the tattoo on the body that were reported include the torso (seven studies), arm (nine studies), leg (six studies), face (three studies), buttock (one study), penis (one study) and multiple sites (ten studies). A further 18 studies did not report the location of the tattoo. The type of practitioner undertaking the procedures was not reported. The countries where the procedures took place were not reported. The outcomes were microbiological and non-microbiological adverse reactions as a result of tattoos in mainly adult populations (three studies included children under 18 years of age). The time frame for reporting or experiencing an adverse effect or complication, where reported, ranged from six days to two months for the studies that reported microbiological complications and from two weeks to over 10 years for the studies that reported non-microbiological complications.

The sex of participants across the case reports reporting single cases was split between males (16 studies) and females (14 studies). Two further case reports of three participants had a mix of both males and females. The sex of participants across the remaining study types (23 studies) were males (two studies), females (one study), a mix (seven studies) and 13 studies did not provide this detail.

2.1.2 Physical health risks associated with tattooing

In the one included SR by Sindoni et al. (2021), the clinical presentations commonly reported after receiving a tattoo include the following: skin irritation, swollen glands near the site, bleeding, oedema (swelling), pruritus (itching), suppuration (production of pus), blistering, scabs, pain, fever, nausea and vomiting (see Table 1).

Across 10 of the included studies (five case reports and five case series) reporting **microbiological complications** in the SR (seven good quality, two poor quality and one fair quality), the most commonly reported bacterial infections included non-tuberculous *Mycobacterial* infections (60 cases), *Mycobacterium chelonae* infections (14 cases) and cutaneous *Mycobacterial* infections (four cases). Less commonly reported bacterial infections included life-threatening cellulitis (two cases), cutaneous diphtheria (two cases) and *staphylococcal* scalded skin syndrome infection (one case). Additionally, one study (case series) described the presence of warts. The review authors concluded that it is likely that these outbreaks can be linked to poor infection control practices and contaminated or diluted inks. Additionally, one instance of the blood-borne infection Hepatitis C Virus transmitted through the use of contaminated tattoo equipment was reported.

The SR identified two case series (good quality) and one case report (fair quality) that were published from 2015 to 2020 that reported bacterial and viral infections. These were non-tuberculous *Mycobacterial* infections (two cases), *Staphylococcal* infection (one case) and warts (one case).

Thirty-seven of the included studies (23 good quality case reports, four fair quality case reports, eight good quality case series, one fair quality cross sectional and one good quality cohort study) reported a wide variety of **non-microbiological complications**. The most frequently reported were allergic reactions such as contact dermatitis to the pigments or components in tattoo ink. Other non-microbiological complications that were described include cancerous growths, benign growth conditions, sarcoidosis-related reactions (including granulomatous reactions), skin-related adverse reactions, eye-related adverse reactions and other adverse reactions.

Findings from the case reports and case series have reported a number of different types of cancers occurring in some instances up to 16 years after a person has had a tattoo and include melanoma, squamous cell carcinoma, basal cell carcinoma, dermatofibrosarcoma protuberans and leiomyosarcoma. The benign growth conditions that have been described include haemangioma, epithelioid osteoblastoma and dermatofibroma. The sarcoidosis-related reactions that were described include sarcoidosis, sarcoid uveitis, cutaneous and pulmonary sarcoidosis, granulomatous infiltrate and granulomatous dermatitis.

A wide range of other skin-related adverse reactions have been described and include dermatitis (eczema), lichenoid reactions, inflammatory reactions, keratoacanthoma, nodular dermal lymphohistiocytic infiltration, pseudoepitheliomatous hyperplasia, pyoderma gangrenosum, Koebner phenomenon, scar formation, papulo-nodular reactions and skin thickening. Additionally, a diverse range of other adverse reactions described within single cases have also been reported, such as priapism linked to a tattoo of the penis, cutaneous and pulmonary sarcoidosis, lymphopathy and photosensitivity. Eye-related adverse effects that have occurred after receiving a lid-eye tattoo include short tear film break-up time, corneal

erosion and meibomian gland loss, increased tear film instability and exacerbated signs and symptoms of ocular surface disease.

2.1.3 The quality of the SR of tattooing

The included SR of tattooing (Sindoni et al. 2021) received eight out of 11 points on the relevant critical appraisal checklist. While the SR had no critical flaws (the search strategy, the criteria for appraising studies and the methods used to combine studies were appropriate, and the sources and resources used to search for studies were adequate), it had some weaknesses deemed non-critical for the purposes of the present review, such as the lack of assessment of the likelihood of publication bias. The SR was therefore considered to be of moderate quality. Information on how quality was derived is provided in Section 5.5. More detail on the quality of the included SR can be found in Table 16 in Section 6.3.

2.1.4 Bottom line summary for tattooing

Evidence from one moderate quality SR (Sindoni et al. 2021) described a wide range of complications and adverse reactions experienced by individuals after getting a tattoo. These were classified as microbiological complications – bacterial infections, viral infections and blood-borne infections, and non-microbiological complications – allergic reactions, malignant growths, benign growths, sarcoidosis-related reactions (including granulomatous reactions), along with a wide range of other skin-related adverse reactions. The countries where the procedures took place were not reported.

Bacterial and viral infections reported in studies published since 2015 included non-tuberculous *mycobacterial* skin infections, *staphylococcal* scalded skin syndrome and warts.

2.2 Semi-permanent make-up

2.2.1 Overview of the evidence base on semi-permanent make-up

The searches identified one SR (Motoki et al. 2020), see Table 11, which sought to retrieve primary research reporting pathological scarring after eyebrow micropigmentation. However, this SR did not find any such primary research.

Due to the lack of existing secondary research, a search for primary studies was conducted as part of the present review. It identified 31 case reports (see Table 12), which were published between 2015 and 2023 that reported a variety of adverse reactions. The sample size for each case report varied from one participant to five participants, with 28 case reports (90%) involving a single participant. In total, there were 37 individual cases presented. In the majority of cases (n=26; 84%), the specific practitioner responsible for the semi-permanent make-up procedure was not explicitly specified. Among the cases (six case reports) where the practitioner information was provided, two involved non-medical professionals, one mentioned an aesthetician, one identified a medical practitioner, and for one case, it was unclear whether the practitioner was a medical or non-medical professional. Across the cases, the majority (n=33, 89.2%) of the permanent make-up procedures were applied to eyebrows, two cases (5.4%) were confined to the lips, while one case (2.7%) was limited to the eyelids and a single case (2.7%) involved both the lips and eyebrows.

The timeframe between the semi-permanent make-up procedure and a person presenting at the hospital for a microbiological reaction across five cases ranged from the same day to one month. The time frame for the non-microbiological reactions varied significantly. In two cases

(5.4%), reactions occurred within one to two days after the semi-permanent make-up procedure. In 15 cases (40.5%), reactions appeared within a range of one to 21 months. Additionally, five cases (13.5%) reported reactions occurring two to five years later, while four cases (10.8%) documented reactions emerging eight to 16 years after the procedure. In six cases (16.2%), the timeframe was not reported.

Participants across the case reports were all women, with varying ages ranging from 25 to 75 years old. Among the 31 case reports examined, only seven of them explicitly mentioned the ethnicity of the individuals, specifically Hispanic (three cases), Caucasian (one case), Chinese (one case), Japanese (one case) and Lithuanian (one case).

The majority (n=26, 84%) of the procedures occurred in what was assumed to be a commercial setting, although five case reports (16%) did not specify the setting. The case reports originated from a total of 18 countries and included Iran (n=4), the USA (n=4), two case reports each from Brazil, China, Japan, Germany, and Spain and one case report each from Canada, Colombia, Israel, Italy, Mexico, Republic of Ireland, Syria, the Netherlands, Tunisia, Turkey and the UK. The country of origin for two reports, specifically Hinojosa et al. (2017; Mexico or the USA) and Vera et al. (2018; Venezuela or Germany), was not clear.

2.2.2 Physical health risks associated with semi-permanent make-up

Across the 37 cases presented in 31 case reports, the clinical presentations commonly reported after following the application of semi-permanent make-up are reported in Table 1 and include **erythema or redness** (Akoh et al. 2021, Bashinskaya et al. 2022, Gilhooley et al. 2020, Goldberg et al. 2018, Maier et al. 2015, Mirzaei et al. 2017, Naeini et al. 2017, Sano et al. 2021, Suleman et al. 2023, Tittelbach et al. 2018, Vera et al. 2018); **oedema or swelling** (Akoh et al. 2021, Gilhooley et al. 2020, Lahouel et al. 2022, Sano et al. 2021, Soltany et al. 2023), **pain** (Motoki et al. 2020) and **pruritus** (Abtahi-Naeini et al. 2019, Ibraheim et al. 2023, Lahouel et al. 2022, Motoki et al. 2020, Tittelbach et al. 2018, Valbuena et al. 2017, Vera et al. 2018).

Five case reports (Akoh et al. 2021, Castaño-Fernández & Grau-Pérez 2023, Marcelino et al. 2021, Sano et al. 2021, Soltany et al. 2023) reported **microbiological complications** in the context of semi-permanent make-up, which included both viral and bacterial infections. The viral infections reported were **monkeypox (mpox)** (Castaño-Fernández & Grau-Pérez 2023) and *Molluscum contagiosum* (Marcelino et al. 2021) and the bacterial infections reported were **orbital cellulitis** (Soltany et al. 2023), three cases of **periorbital cellulitis** (Akoh et al. 2021, Soltany et al. 2023, Sano et al. 2021) and **necrotising fasciitis** (Soltany et al. 2023).

The **non-microbiological adverse reactions** that have been described in the context of semi-permanent make-up included 25 cases (across 19 case reports) of **sarcoidosis-related reactions** (Bashinskaya et al. 2022, Bombonato et al. 2015, Ebrahimiadib et al. 2021, Gilhooley et al. 2020, Hirai et al. 2022, Huisman et al. 2019, Ibraheim et al. 2023, Iwayama et al. 2017, Mirzaei et al. 2017, Naeini et al. 2017, Nie et al. 2022, Tukenmez Demirci et al. 2016, Valbuena et al. 2017, Vera et al. 2018, Tittelbach et al. 2018); 17 cases of **granulomatous reactions, including papules** (Bashinskaya et al. 2022, Ebrahimiadib et al. 2021, Hinojosa et al. 2017, Hirai et al. 2022, Huisman et al. 2019, Ibraheim et al. 2023, Iwayama et al. 2017, Leight-Dunn et al. 2022, Maier et al. 2015, Naeini et al. 2017, Nie et al. 2022, Suleman et al. 2023, Sun & Lao 2023, Tittelbach et al. 2018, Tukenmez Demirci et al. 2016, Valbuena et al.

2017); three cases of **allergic reactions** (Lahouel et al. 2022, Ibraheim et al. 2023, Motoki et al. 2020), 19 cases of **skin-related adverse reactions** (Abtahi-Naeini et al. 2019, Akoh et al. 2021, Bashinskaya et al. 2022, Ebrahimiadib et al. 2021, Gilhooley et al. 2020, Hinojosa et al. 2017, Goldberg et al. 2018, Hirai et al. 2022, Maier et al. 2015, Mirzaei et al. 2017, Naeini et al. 2017, Marcelino et al. 2021, Navarro-Triviño et al. 2021, Nie et al. 2022, Sano et al. 2021, Suleman et al. 2023, Tierney & Kavanagh 2021, Tittelbach et al. 2018, Vera et al. 2018) and five cases of **eye-related adverse reactions and other adverse reactions** (Sano et al. 2021, Goldberg et al. 2018, Hinojosa et al. 2017, Soltany et al. 2023, Navarro-Triviño et al. 2021).

Sarcoidosis is a multisystem inflammatory disorder characterised by the presence of granulomas in various organs and tissues throughout the body. Five cases describe **cutaneous sarcoidosis** (Bashinskaya et al. 2022, Hinojosa et al. 2017, Ibraheim et al. 2023, Naeini et al. 2017, Tukenmez Demirci et al. 2016), five cases describe **systemic sarcoidosis, i.e. affecting multiple organs systems in the body** (Bashinskaya et al. 2022, Ebrahimiadib et al. 2021, Hinojosa et al. 2017, Vera et al. 2018, Huisman et al. 2019), one case of **pulmonary sarcoidosis** (Naeini et al. 2017) and one case of **Löfgren's syndrome**, an acute form of sarcoidosis (Mirzaei et al. 2017). A range of granulomatous reactions across the 17 cases were described using a variety of terms, for example, non-caseating granulomas, granulomatous dermatitis, chronic granulomatous inflammation and sarcoidal foreign body (granulomatous) reactions.

A number of skin-related adverse effects were described and these include **crusting** (Akoh et al. 2021, Hinojosa et al. 2017, Sano et al. 2021, Suleman et al. 2023), **cutaneous lymphoid hyperplasia** (Navarro-Triviño et al. 2021); **hyperpigmentation** (Abtahi-Naeini et al. 2019, Akoh et al. 2021), **hyperplasia** (Marcelino et al. 2021), **induration** (Maier et al. 2015), **irritation** (Goldberg et al. 2018), **lichenoid tattoo reactions** (Abtahi-Naeini et al. 2019), **pustules** (Akoh et al. 2021), **rash** (Hirai et al. 2022, Nie et al. 2022, Suleman et al. 2023), **scaling** (Ebrahimiadib et al. 2021, Maier et al. 2015, Tittelbach et al. 2018), **vittiligo arising from the koebnerisation effect of microblading** (Tierney & Kavanagh 2021).

Additionally, there were eye-related adverse reactions described which included **bilateral eye swelling, redness, and pain** (Sano et al. 2021), **conjunctival injection** (Goldberg et al. 2018, Hinojosa et al. 2017), **irritation** (Goldberg et al. 2018), **right eye proptosis and painful eye movement** (Soltany et al. 2023) **uveitis** (Navarro-Triviño et al. 2021) and **pigmented stain on the eye** (Goldberg et al. 2018).

The non-microbiological **allergic reactions** were reported in relation to the pigments or components of the semi-permanent make-up inks (for example, iron oxide in Leight-Dunn et al. 2022) or to the tattoo being performed with nickel containing needles (Lahouel et al. 2022).

2.2.3 The quality of the studies on semi-permanent make-up

The quality rating for the case reports of complications associated with semi-permanent make-up ranges from four to eight points out of eight, indicating varying levels of methodological rigour and reporting quality in the included case reports.

Demographic characteristics, the clinical condition of the patient on presentation and diagnostic tests or assessment methods and their results were clearly described in all case

reports. All but one case report clearly described the patient's history and presented it as a timeline. More detail can be found in Table 17 in Section 6.3.

Seven case reports achieved the highest rating of eight out of eight on the relevant critical appraisal checklist (Akoh et al. 2021, Gilhooley et al. 2020, Goldberg et al. 2018, Hinojosa et al. 2017, Leight-Dunn et al. 2022, Mirzaei et al. 2017, Soltany et al. 2023, Sun & Lao 2023).

Seventeen case reports received a rating of seven out of eight (Abtahi-Naeini et al. 2019, Ebrahimiadib et al. 2021, Hirai et al. 2022, Huisman et al. 2019, Ibraheim et al. 2023, Iwayama et al. 2017, Lahouel et al. 2022, Maier et al. 2015, Marcelino et al. 2021, Motoki et al. 2020, Naeini et al. 2017, Navarro-Triviño et al. 2021, Nie et al. 2022).

Three case reports earned a score of six out of eight (Sano et al. 2021, Tierney & Kavanagh 2021, Valbuena et al. 2017). Three case reports were rated five out of eight (Bashinskaya et al. 2022, Castaño-Fernández & Grau-Pérez 2023, Vera et al. 2018). Finally, a single case report was rated four out of eight (Bombonato et al. 2015).

2.2.4 Bottom line summary for semi-permanent make-up

Evidence from 31 case reports reporting on 37 individual cases described a diverse spectrum of complications and adverse reactions experienced by individuals following the application of semi-permanent make-up. These can be broadly classified as microbiological complications (bacterial infections and viral infections) and non-microbiological complications (sarcoidosis-related reactions, including granulomatous reactions, allergic reactions and a range of other skin and eye-related adverse reactions).

The countries where the procedure took place were Brazil, Canada, China, Colombia, Germany, Iran, Israel, Italy, Japan, Mexico, the Republic of Ireland, Spain, Syria, the Netherlands, Tunisia, Turkey, the UK and the USA.

Bacterial and viral infections reported in studies published since 2015 included *Molluscum contagiosum*, orbital cellulitis, periorbital cellulitis, necrotising fasciitis and monkeypox.

2.3 Body piercing

2.3.1 Overview of the evidence base on body piercing

The searches identified four SRs (Acuña-Chavez et al. 2022, Hennequin-Hoenderdos et al. 2016, Passos et al. 2022, Sindoni et al. 2022) that included 174 studies published between 1973 and 2020 focusing on body piercing (see Table 13). There was a moderate overlap across the SRs, meaning that 30 primary studies were included in more than one SR. More details about overlap can be found in Section 5.6. All of the information that follows is based on the 174 studies.

Two of the SRs included adults and children and the remaining two SRs did not provide this detail. Three SRs provided details of the sex of the participants and between 61% and 85% were female. None of the SRs reported the ethnicity of the participants. Three SRs reported the country where the body piercing took place.

The study designs included before-after design (one study), case-control (23 studies), case report (62 studies), case report in a cross-sectional study (one study), case series (15 studies),

cohort (five studies), cross-sectional (65 studies, out of which 26 were prevalence studies), quasi-experimental (one study) and randomised controlled trial (one study). The SRs identified three case series, seven case reports, 11 cross-sectional studies (out of which four were prevalence studies), four case-control studies, one retrospective cohort study, and one quasi-experimental study that were published between 2015 and 2020.

The research was conducted across 31 different countries with just under a third of the studies being conducted in the USA (50 studies) and only six in the UK. Two SRs focused on oral piercing (Hennequin-Hoenderdos et al. 2016, Passos et al. 2022), one on nipple piercing (Acuña-Chavez et al. 2022) and one on piercing in general (Sindoni et al. 2022). Across all the SRs, there were 213 puncture (piercing) sites, which included the ear (22 studies), nipple (28 studies), tongue (68 studies), lip (44 studies), tongue and lip (nine studies), oral (15 studies), nose (one study), genital (one study) and navel (one study). Puncture (piercing) site was not reported in a further 24 studies. The type of practitioner undertaking the procedures was not reported.

Three of the four SRs (Sindoni et al. 2022, Acuña-Chavez et al. 2022, Passos et al. 2022) reported on the time frame for experiencing an adverse reaction or complication. Acuña-Chavez et al. (2022) and Passos et al. (2022) made no distinction when reporting microbiological and non-microbiological effects and the time frame ranged from immediate (n=11) to less than six months (n=13) and over six months (n=16), three of the 16 being over one year. The time frame wasn't reported in a further 41 studies. Sindoni et al. (2022) made a distinction when reporting microbiological and non-microbiological effects. For the studies reporting microbiological effects, the time frame ranged from within the first month (n=19), one to six months (n=13), six to 12 months (n=3) and over one year (n=8), with one study as late as eight years after the procedure. The time frame was not reported in a further ten studies. For the studies reporting non-microbiological effects, the time frame varied between less than one year (n=1) to over one year (n=5), with a further five studies not reporting. For the studies reporting both microbiological and non-microbiological effects, the time frame ranged from less than one year (n=3) to over one year (n=5), with a further 12 studies not reporting it.

The outcomes studied were most frequently isolated bacteria, microbiological complications, non-microbiological complications and the occurrence of clinical manifestations/ complications, oral lesions related to soft tissue and mucosa, periodontal and tooth damage and alterations (speech, mastication, deglutition and taste-related, saliva and galvanic current, temporomandibular disorders, soft plaque and calculus formation and microbiology).

2.3.2 Physical health risks associated with body piercing

Across the four SRs (Acuña-Chavez et al. 2022; Hennequin-Hoenderdos et al. 2016; Passos et al. 2022, Sindoni et al. 2022), the clinical presentations commonly reported after having undergone body piercing varied according to the site of the piercing. Specifically, those who had nipple piercings described breast fluid collection, breast pain or tenderness, breast swelling, deformity and discharge, as well as similar presentations to those having a piercing in other parts of the body, including erythema, fever, headache, hyperpigmentation, oedema, productive cough with bloody sputum, pruritus, swollen glands and syncope (see Table 1).

Three SRs reported **microbiological complications** in individuals who have undergone body piercing (Sindoni et al. 2022, Acuña-Chavez et al. 2022, Passos et al. 2022), which included

fungal infections (*Candida dubliniensis*), viral infections (viral hepatitis and Herpes simplex hepatitis) and bacterial infections. The bacterial infections that were described included cephalic tetanus, cerebellar brain abscess, chest wall cellulitis/retroareolar cellulitis, endocarditis, glomerulonephritis, mastitis and toxic shock syndrome and infections (unspecified). The commonly occurring organisms identified as causative agents for infections were *Staphylococcus* and non-tuberculous *Mycobacterium*. Sixteen rarer types of organisms were identified as causative agents of infections in people who received a body piercing (for details, see Table 2). Information on the prevalence of infections was not available.

The three SRs included two case series, five case reports, five cross-sectional studies (out of which two were prevalence studies) and one retrospective cohort study that were published from 2015 to 2020 that reported bacterial and fungal infections. The bacterial and fungal infections that were described included retroareolar cellulitis (one case), unspecified infections (five cross-sectional studies) and *Candida dubliniensis* (one case). The commonly occurring organisms identified as causative agents for infections included *Neisseria gonorrhoeae* (two cases), *Propionibacterium acnes* (two case series n=11) and *Staphylococcus epidermidis* (one case). Rarer types of organisms that were identified as causative agents in people who received a body piercing included *Pseudomonas aeruginosa* (one retrospective cohort study), *Mycobacterium fortuitum* (one case), *Staphylococcus epidermidis* alongside *Actinomyces turicensis* and *Peptoniphilus harei* (one case), Coagulase-negative *Staphylococci* (one case series n=4), *Corynebacterium amycolatum* (one case series n=4), *Haemophilus parainfluenzae* (one case series n=4), and a rare gram-positive cocci not otherwise specified (one case series n=4).

The **non-microbiological adverse reactions** that have been described in the context of body piercing include allergic reactions, malignant growths (basal cell carcinoma), benign growths (fibroma) and a wide range of other skin-related adverse reactions (acne, cysts, eczema (dermatitis), inflammatory reactions, scarification/keloid formation, induration and skin tearing) (Passos et al. 2022, Sindoni et al. 2022). The allergic reactions included contact dermatitis and nickel sensitisation (body piercing tattoo being performed with nickel-containing needles).

Additionally, in relation to tongue and lip piercings, a number of specific adverse reactions were described, which were oral and mucosal lesions, periodontal issues, teeth damage and alterations (changes), and these are reported in Table 3. Two SRs reported relative risks (RR), odds ratios (ORs) and event rates (ERs) to the incidence of oral and teeth injuries and the association between the presence of oral piercings and gingival recessions or dental alterations (Hennequin-Hoenderdos et al. 2016, Passos et al. 2022). Based on these SRs, the event rate within a pierced population indicated that 33% of participants with an oral piercing had gingival recession (Passos et al. 2022). Compared to the population without a piercing, the incidence of gingival recession was 2.77 times more likely in people with tongue piercing (RR = 2.77, 95% CI 1.99 to 3.85; p<0 .001) and 4.14 times more likely with a lip piercing (RR = 4.14, 95% CI 1.54 to 11.13; p=0.005; Hennequin-Hoenderdos et al. 2016). This is supported by findings from Passos et al. (2022), who found that the odds of developing gingival recession were seven times higher in people with an oral piercing than in individuals without it (OR = 7.085; 95% CI 4.252 to 11.805; p<0 .001).

The event rate of dental fracture (ER = 0.338; 95% CI 0.248 to 0.440), wear or abrasion (ER 0.344; 95% CI 0.183 to 0.553) in individuals with oral piercing was 34%, followed by 27% of

dental damage (lesion not reported in detail) (ER = 0.270; 95% CI 0.074 to 0.630), and 22% of tooth chipping or enamel infraction (Passos et al. 2022). Incidence of tooth injury (including chipped/cracked/broken teeth, tooth wear or fractures) compared to unpierced individuals was 2.44 times more likely with a tongue piercing (RR = 2.44, 95% CI 1.35 to 4.41; $p=0.003$), although it was not significantly more likely with a lip piercing (RR = 1.33, 95% CI 0.74 to 2.41; $p=0.34$; Hennequin-Hoenderdos et al. 2016). The odds of dental fracture were three times higher in people with an oral piercing compared to individuals without it (OR = 3.293; 95% CI: 1.868 to 5.807; $p < 0.001$), although no significant association was detected between tooth chipping or enamel infraction and oral piercings (OR = 2.223; 95% CI 0.737 to 6.775; $p=0.156$; Passos et al. 2022).

A diverse range of other adverse reactions were described for people undergoing body piercing and these include adornment aspiration. Adverse effects also included nipple ring ripped out, embedded earrings, lymphadenopathy, rejection and a split tongue.

2.3.3 The quality of the SRs of body piercing

The quality of the SRs of body piercing is as follows. Out of the four included SRs, one received the highest score of 11 out of 11 on the relevant critical appraisal checklist (Passos et al. 2022). It was therefore deemed to be high quality. Two scored nine out of 11 (Acuña-Chavez et al. 2022, Sindoni et al. 2022). Neither had any flaws considered critical for the purposes of the present review, but they had non-critical weaknesses, such as the lack of assessment of the likelihood of publication bias, so they were considered to be of moderate quality. Finally, one SR scored eight out of 11 (Hennequin-Hoenderdos et al. 2016). It was considered to be of low quality because one critical flaw was identified (the methods used to combine studies were not considered appropriate), as well as some non-critical weaknesses. More detail can be found in Table 16 in Section 6.3.

2.3.4 Bottom line summary for body piercing

Evidence from four SRs (Acuña-Chavez et al. 2022 – moderate quality; Hennequin-Hoenderdos et al. 2016 – low quality; Passos et al. 2022 – high quality, Sindoni et al. 2022 – moderate quality) described a wide range of complications and adverse reactions experienced by individuals who had undergone body piercing. These were classified as microbiological complications (fungal, viral and bacterial infections) and non-microbiological complications (allergic reactions, malignant growths, benign growths, and other skin adverse reactions). The countries where the procedures took place were Argentina, Austria, Australia, Belgium, Brazil, Canada, Cuba, France, Germany, Greece, Ireland, Israel, Italy, Kenya, Mexico, New Zealand, Pakistan, Poland, Saudi Arabia, Slovenia, South Africa, Spain, Sudan, Sweden, Switzerland, the Netherlands, Turkey, UK, Ukraine, USA and Venezuela.

Bacterial and fungal infections reported in studies published since 2015 included retroareolar cellulitis, unspecified infections and *Candida dublinensis*. Common causative agents for infections were identified and included *Neisseria gonorrhoeae*, *Propionibacterium acnes* and *Staphylococcus epidermidis*. Rare causative agents for infections were identified and included *Pseudomonas aeruginosa*, *Mycobacterium fortuitum*, *Staphylococcus epidermidis* alongside *Actinomyces turicensis* and *Peptoniphilus harej*, Coagulase-negative *Staphylococci*, *Corynebacterium amycolatum*, *Haemophilus parainfluenzae* and rare gram-positive cocci not otherwise specified.

Following oral piercings, including tongue and lip, a range of non-microbiological complications were reported, which included soft tissue and mucosal lesions, periodontal issues, teeth damage and alterations (changes).

2.4 Acupuncture

2.4.1 Overview of the evidence base on acupuncture

The searches identified five overviews of existing SRs (Yang et al. 2015, Chan et al. 2017, Vieira et al. 2018, Kwon et al. 2019, Xu et al. 2023) that focused on acupuncture. To avoid repetition, two overviews of SRs deemed the most exhaustive were selected for this report: one evidence map of 535 SRs with no age limit for participants (Xu et al. 2023) and one overview of 24 SRs focused on children up to 18 years old, of which six reported adverse reactions (Yang et al. 2015) – see Table 14 for detail. Among the six SRs reporting adverse reactions included in Yang et al. (2015), one was also included in Xu et al. (2023). As for the overviews of SRs identified but not reported here, Chan et al. (2017) included 17 SRs, Kwon et al. (2019) included 11 SRs, and Vieira et al. (2018) focused on auriculotherapy, including ear acupuncture, and included a total of 14 SRs. None of the three reviews were limited to children.

The evidence map of 535 SRs included both healthy people and people with 23 different disease types classified by ICD-11 (Xu et al. 2023). The included SRs were published between 1999 and 2022. It included 18 types of acupuncture, with the most popular being electroacupuncture (67 SRs), followed by manual acupuncture (47 SRs), acupoint catgut embedding (41 SRs), dry needling therapy (39 SRs), auricular acupuncture (22 SRs) and acupoint injection (14 SRs). Systematic reviews of acupuncture where there was no penetration of the skin were excluded. The age and sex of participants varied and were not reported for each included SR. The first authors of the SRs came from 18 different countries, mainly from China (336 SRs), followed by South Korea (90 SRs) and the USA (30 SRs). Twenty SRs came from the UK. The countries of origin of the primary studies included in the overview of SRs were not reported. The outcomes of interest included any adverse reactions experienced by individuals who have undergone acupuncture.

The six relevant SRs in the overview of SRs of acupuncture in children (Yang et al. 2015) included participants aged up to 18 years old with nocturnal enuresis (2 SRs), Autism (2 SRs), cerebral palsy (1 SR) and asthma (1 SR). The included SRs reported on unspecified acupuncture, needle acupuncture, tongue acupuncture, scalp acupuncture, heat-producing needling and laser acupuncture. However, one SR out of the six only reported on the adverse events experienced by individuals who have undergone with laser acupuncture and is not included here due to it being outside of the eligibility criteria. The first authors of four of the remaining SRs originated from China and one from Korea. The countries of origin of the primary studies were not reported. Any adverse reactions experienced by individuals who have undergone with acupuncture were included.

2.4.2 Physical health risks associated with acupuncture

In the evidence map of SRs (Xu et al. 2023), adverse events commonly reported by individuals who have undergone acupuncture include the following: pain (144 SRs), bleeding or bruising (120 SRs), digestive system symptoms such as nausea or vomiting, loss of appetite, dry mouth, constipation, diarrhoea, dyspepsia and heartburn (46 SRs), erythema (19 SRs), tiredness (40 SRs), discomforts (31 SRs), headache (27 SRs), pruritus (23 SRs), aggravation

of symptoms (14 SRs), numbness (13 SRs), fevers (10 SRs), palpitations (10 SRs), heat or sweating (8 SRs), menoxenia (5 SRs), mild oedema (swelling) (16 SRs) and blisters (3 SRs). Syncope was reported in 86 SRs. It was thought to be linked to stress and fear of acupuncture in patients as well as frail and seriously ill patients and those with excessive blood loss, a history of dizziness from acupuncture and an improper posture.

Microbiological complications included infections, which were reported in 19 SRs¹. Xu et al. (2023) stated that infections occurred primarily because of unsterilised needles, repeated use of needles, or contact of the needlepoint with clothing, but no further information on the cause of infections or how the causation was derived was provided. All patients recovered after receiving treatment. According to the authors of the evidence map, the rate of infections related to acupuncture has been decreasing in recent years due to the rise of health consciousness and disinfection.

Eleven SRs that reported infections in people who had received acupuncture were identified through supplementary materials to Xu et al. (2023). They were published between 2015 and 2021. These SRs included between six and 61 primary studies ($M = 24.64$), but the publication dates of the primary studies or the search dates were not reported in the evidence map. The reported infections were classified by Xu et al. (2023) as unspecified infections (4 SRs), skin infections (4 SRs, including 1 SR reporting a local skin infection), local or systemic infection (1 SR), pulmonary infection (1 SR) and urinary system infection (1 SR, in patients with urinary retention). No further information about the infections was provided.

One SR included primary studies with children six to 14 months old with cerebral palsy. Participants' age in the other included SRs was either reported as adults or not specified. Ten of the SRs came from China and one from the USA. All of the SRs included a control condition (e.g., other kinds of Chinese medicine, western medicine, rehabilitation training, unspecified usual care, unspecified other therapy, sham acupuncture, and waitlist control). The quality of these SRs was classified by Xu et al. (2023) as critically low ($n=6$), low ($n=4$) and high ($n=1$).

To gain a better understanding of what kind of infections have been reported in recent years in people who have undergone acupuncture, the SRs included in the evidence map (Xu et al. 2023) that reported infections and were published after 2015 ($n=9$) were retrieved at full-text and examined further, as a snapshot of the available evidence rather than a systematic report, which was not feasible due to the time constraints of this rapid review. Formal data extraction or quality appraisal of these SRs was not conducted. Two unique primary studies published since 2015 reporting infections (one reporting skin infection and one unspecified infection) were identified in those SRs, but neither of them specified the type of infection.

Regarding **non-microbiological complications** described in the evidence map of SRs (Xu et al. 2023), skin allergy reactions (14 SRs), haematomas (70 SRs), and induration (11 SRs) were reported. The evidence map also reported on adverse events such as neuromuscular disease (16 SRs) and motor disorders (2 SRs).

¹ There is a discrepancy relating to the number of SRs reporting infections in the text of the Xu et al. (2023) paper and in Table S1 (characteristics of the included studies) provided in supplementary materials to the paper. According to the paper, the number is 19 SRs. However, only 11 SRs reporting infections were identified in Table S1.

Other adverse events were reported in 373 SRs identified by the evidence map and included needle sticking, broken needles, and bent needles. No acupuncture-related adverse events were reported in 176 reviews and 120 reviews did not specify adverse events. In addition, 89 SRs stated that no adverse events were reported in the original studies.

Fifty-three SRs reported that acupuncture-related adverse events were associated with the practitioners, but no information on how the association was derived was provided in the evidence map. Severe needle-related adverse reactions were reported to be rare. The incidence of adverse events ranged from 6.71%–8.6% and the incidence of serious adverse events was stated to be approximately 0.001%, but information on what was considered serious adverse events was not provided (Xu et al. 2023).

As per the five relevant SRs reporting adverse events included in the overview of acupuncture in children (Yang et al. 2015), the adverse reactions that were described for children include superficial bleeding (2 SRs) and mild pain (1 SR) as well as crying (2 SRs), painful bi-auricular stimulation (1 SR), eczema (1 SR) and heat or swelling while pressing (1 SR). The frequency of these adverse events was unclear. In four SRs, the relevance between adverse events and acupuncture was unclear, and one found no relevance.

2.4.3 The quality of the evidence map and overview of SRs acupuncture

The evidence map of SRs (Xu et al. 2023) scored 11 out of 11 on the relevant critical appraisal checklist and was therefore deemed to be of high quality. The overview of SRs (Yang et al. 2015) scored 10 out of 11, and the identified weakness was not judged to be critical for the purposes of the present review, so the overall quality was considered to be high. More detail can be found in Table 16 in Section 6.3.

2.4.4 Bottom line summary for acupuncture

Evidence from one high quality evidence map of 535 SRs (Xu et al. 2023) described a wide range of complications and adverse reactions experienced by individuals (mainly adults) who had undergone acupuncture. Microbiological complications included skin infections, local or systemic infections, pulmonary infections, urinary system infections, and otherwise unspecified infections. The most commonly described non-microbiological complications were skin-related adverse effects such as skin allergy reactions, haematoma, and induration. The incidence of serious adverse events was low at 0.001%. The countries where the procedures took place were not reported.

Evidence from one high quality overview of reviews (Yang et al. 2015) described the commonly reported clinical presentations and adverse events experienced by children who have undergone acupuncture and included instances of pain and bleeding as well as eczema, heat, and swelling. The countries where the procedures took place were not reported.

Infections reported in primary studies published since 2015 included skin infection and unspecified infection. The types of infection were not stated.

2.5 Electrolysis

2.5.1 Overview of the evidence base on electrolysis

The searches did not identify any SRs that focused on electrolysis. Additional searches for primary research identified one case report (Morand et al. 2015) – see Table 15. The case was of a 35-year-old female from Canada. No further details were reported.

2.5.2 Physical health risks associated with electrolysis

A diagnosis of cutaneous sarcoidosis (non-microbiological reaction) was described in the case report by Morand et al. (2015) of a patient who had been receiving electrolysis for many years.

2.5.3 The quality of the studies on electrolysis

The single identified case report of electrolysis was rated six out of eight on the JBI critical appraisal checklist for case reports (Morand et al. 2015). It lost points because the patient's history was not clearly described and presented as a timeline and because adverse events or unanticipated events during treatment were not identified and described. More detail can be found in Table 17 in Section 6.3.

2.5.4 Bottom line summary for electrolysis

One case report described a non-microbiological complication (cutaneous sarcoidosis). The country where the procedure took place was Canada.

Table 1. Summary of clinical presentations reported in people who had undergone special procedures

Tattooing	SPMU	Body piercing	Acupuncture	Electrolysis
Bleeding Blistering Fever Headache Nausea and vomiting Oedema (swelling) Pain Pruritus Scabs Suppuration Swollen glands near the site	Oedema (swelling) Pain Pruritus	Bleeding Breast erythema Breast fluid collection Breast pain or tenderness Breast swelling Deformity Discharge Dyspnoea Fever Headache Oedema (swelling) Pain Productive cough with bloody sputum Pruritus Swollen glands Syncope	Bleeding Blisters Bruising Digestive system symptoms Discomforts Dizziness Erythema (redness) Fever Headache Menoxenia Motor disorders Numbness Oedema (swelling) Pain Palpitations Pruritus Tiredness Syncope Sweating	N/A

Key: SPMU = semi-permanent make-up.

Table 2. Summary of microbiological complications reported in people who had undergone special procedures

Tattooing	SPMU	Body piercing	Acupuncture	Electrolysis
Fungal infections identified				
N/A	N/A	<i>Candida dubliniensis</i>	N/A	N/A
Viral infections identified				
Warts	Mpox (Monkeypox) <i>Molluscum contagiosum</i>	Viral hepatitis Herpes simplex hepatitis	N/A	N/A
Bacterial infections identified				
Cutaneous diphtheria Cutaneous <i>mycobacterial</i> infections Life threatening cellulitis <i>Mycobacterium chelonae</i> infections <i>Staphylococcal scalded skin syndrome</i> Non-tuberculous <i>Mycobacterial</i> infections Tattoo-related Infections (unspecified) <i>Organisms identified as causative agents</i> Not reported	<i>Necrotising fasciitis</i> <i>Orbital cellulitis</i> <i>Periorbital cellulitis</i> <i>Organisms identified as causative agents</i> Not reported	Cephalic tetanus Cerebellar brain abscess Chest wall cellulitis / <i>Retroareolar cellulitis</i> Endocarditis Glomerulonephritis <i>Infections (unspecified)</i> Mastitis Toxic shock syndrome <i>Organisms identified as causative agents</i> Common: <i>Staphylococcus</i> <i>Non-tuberculous Mycobacterium</i> Rarer: <i>Achromobacter turicensis</i> <i>Actinomyces</i> <i>Aggregatibacter aphrophilus</i> <i>Clostridium tetani</i> <i>Corynebacterium amycolatum</i> <i>Gordonia terrae</i> <i>Haemophilus parainfluenzae</i> <i>Neisseria gonorrhoeae</i> / <i>Neisseria mucosa</i> <i>Nocardia species (Nocardia sp.)</i> <i>Prevotella</i> <i>Propionibacterium acne</i> <i>Pseudomonas aeruginosa</i> Gram-positive cocci not otherwise specified <i>Peptoniphilus harei</i> <i>Streptococcus</i>	<i>Infections (unspecified)</i> <i>Skin infections (unspecified)</i> <i>Organisms identified as causative agents</i> Not reported	N/A
Blood-borne infections				
Hepatitis C	N/A	N/A	N/A	N/A

Key: SPMU = semi-permanent make-up. The text highlighted in red indicates primary research conducted from 2015 onwards.

Table 3. Summary of non-microbiological complications reported in people who had undergone special procedures

Tattooing	SPMU	Body piercing	Acupuncture	Electrolysis
Allergic reactions				
Allergic reactions (unspecified) Contact dermatitis Dye allergy	Contact dermatitis Nickel sensitisation Reaction to iron oxide	Allergy (unspecified) Contact dermatitis Nickel sensitisation	Skin allergy reactions (unspecified)	N/A
Malignant growths				
Basal cell carcinoma Dermatofibrosarcoma protuberans Leiomyosarcoma Melanoma Squamous cell carcinoma	N/A	Basal cell carcinoma	N/A	N/A
Benign growths				
Epithelioid osteoblastoma Dermatofibroma Haemangioma	N/A	Fibroma	N/A	N/A
Sarcoidosis-related reactions (including granulomatous reactions)				
Cutaneous sarcoidosis Granulomatous dermatitis Granulomatous infiltrate Pulmonary Sarcoidosis Sarcoid uveitis Sarcoidosis	Chronic granulomatous inflammation (plaques) Cutaneous sarcoidosis Granulomatous dermatitis Löfgren's syndrome Non-caseating granulomas Pulmonary sarcoidosis Sarcoidal foreign body (granulomatous) reactions Systemic sarcoidosis	Granulomatous dermatitis Granulomatous perichondritis Granulomatous tissue	N/A	Cutaneous sarcoidosis
Skin-related adverse reactions				
Dermatitis (eczema) Inflammatory reactions Irritation Keratoacanthoma Lichenoid reaction Nodular dermal lymphohistiocytic infiltration Papulo-nodular reactions	Crusting Cutaneous lymphoid hyperplasia Erythema (Redness) Hyperpigmentation Hyperplasia Induration Irritation	Acne Breast induration Cysts Eczema/dermatitis Hyperpigmentation Inflammatory reactions Scarification/keloid formation Skin tearing	Eczema Haematoma Induration	Papules

Pseudoepitheliomatous hyperplasia Pyoderma gangrenosum Koebner phenomenon Scar formation Skin thickening	Lichenoid reaction Pustules Rash Scaling Vitiligo from koebnerisation	Papules		
Eye-related adverse reactions				
Sarcoid uveitis	Bilateral eye swelling, redness, and pain Conjunctival injection Irritation Pigmented stain on the eye Right eye proptosis and painful eye movement Uveitis	N/A	N/A	N/A
Oral and mucosal lesions				
N/A	N/A	Fibrous hyperplasia Lesions on the hard palate Lichenoid reactions Macules, ulcers, papules, nodules and bruises Mucosal atrophy Soft tissue or mucosal injury	N/A	N/A
Periodontal issues				
N/A	N/A	Bleeding on probing, clinical attachment loss, and probing depth Dental mobility Dentine hypersensitivity Erythematous palatal mucosa Gingival injury Gingival recession Gingivitis Periodontitis Tongue fissure	N/A	N/A
Teeth damage				
N/A	N/A	Demineralized enamel Dental hypersensitivity Dental injuries/ damage (non-specific) Enamel abrasion or abnormal tooth wear	N/A	N/A

		Enamel abrasions Enamel fractures Nonspecific dental injuries Tooth chipping Tooth fracture		
Alterations (changes)				
N/A	N/A	Chewing Halitosis Microbiologic alterations in the mouth Oral Galvanism Saliva Soft plaque or calculus formation Speech Swallowing Taste Temporomandibular joint dysfunction	N/A	N/A
Other adverse reactions				
Lymphadenopathy Photosensitivity Priapism resulting from a tattoo of the penis	N/A	Adornment aspiration Embedded earring Lymphadenopathy Nipple ring ripped out Rejection Split tongue	Motor disorder Neuromuscular disease	N/A

Key: SPMU = semi-permanent make-up.

3. DISCUSSION

3.1 Summary of the findings

The present rapid review summarised the available evidence on the physical health risks associated with special procedures, namely tattooing (including semi-permanent make-up), body piercing, acupuncture, and electrolysis.

All of the special procedures covered in this rapid review involve skin piercing, posing an infection risk. The skin acts as a natural defence against infections, and any breach in this defence can introduce bacteria or harmful microorganisms into the body. This rapid review has reported on a wide range of adverse events, including infections, in individuals who had undergone special procedures.

The wider literature reports that infections typically stem from two primary sources (Royal Society for Public Health 2019). The first source involves microorganisms that naturally inhabit the skin, known as “endogenous agents”, which are usually harmless but can cause infections when the skin’s protective barrier is compromised, and the second source is “exogenous agents”, which are not naturally found on the individual’s body but can be introduced, often through contaminated needles or ink, unsterilised equipment, unsanitary facilities, or practices that compromise hygiene standards (Royal Society for Public Health 2019).

This review identified a range of bacterial, viral, and fungal infections, referred to as microbiological complications, in individuals who had received special procedures. Bacterial infections that have been reported in studies published since 2015 included *Staphylococcal* scalded skin syndrome and non-tuberculous *Mycobacterial* skin infections (tattooing), necrotising fasciitis, orbital cellulitis, and periorbital cellulitis (semi-permanent make-up), retroareolar cellulitis (body piercing), as well as unspecified infections (body piercing, acupuncture). Viral infections reported in primary studies since 2015 included warts (tattooing) as well as monkeypox and *Molluscum contagiosum* (semi-permanent make-up), and fungal infections included *Candida dubliniensis* (body piercing). A wider range of infections, especially bacterial infections, was identified in the evidence published pre-2015 that was reported in the included reviews. The occurrence of infections is thought to decrease with improved disinfection practices, which highlights the importance of adhering to high standards of hygiene (Xu et al. 2023).

All special procedures carry the potential for allergic reactions, primarily due to the metals, especially nickel, used in needles (Royal Society for Public Health 2019). Tattoo ink can also trigger allergic reactions, leading to various manifestations such as allergic contact dermatitis (Royal Society for Public Health 2019). In this rapid review, such allergic reactions were experienced by individuals who had undergone special procedures with the exception of electrolysis (possibly due to the paucity of evidence).

Other non-microbiological reactions have been reported in people who had received special procedures as occurring anywhere up to 10 years later. These included malignant and benign growth (tattooing, body piercing), sarcoidosis-related reactions (tattooing, semi-permanent make-up, body piercing, electrolysis), skin-related adverse reactions (all types of special

procedures), eye-related adverse reactions (tattooing, semi-permanent make-up) as well as oral and mucosal lesions, periodontal issues, and teeth damage and alterations (body piercing).

3.2 Strengths and limitations of the available evidence

The evidence included in this review covers a wide range of physical health issues in people who have undergone special procedures. The quality of the SRs and maps/overviews of SRs that covered adverse events associated with tattooing, body piercing, and acupuncture was generally good (three high quality reviews, three moderate quality, one low quality), with a critical flaw identified in only one review. This suggests that the included review evidence was able to identify and summarise the majority of the relevant literature that existed when the searches were carried out.

However, most of the primary research, both included in the SRs of tattooing and body piercing and identified as part of this review for semi-permanent make-up and electrolysis, did not employ designs that would have enabled it to gather information on the causal links between the special procedures and adverse physical health effects and on the prevalence of complications.

The evidence identified for semi-permanent make-up and electrolysis came solely from case reports. The majority of the primary studies included in the SRs of tattooing and body piercing also employed case report or case series designs, with some cross-sectional, cohort, before-after, and case-control studies and a total of only two studies with more robust designs (randomised controlled trial and quasi-experimental, both of body piercing). Case reports are considered among the least robust forms of evidence for inferring causality (Joanna Briggs Institute 2013), however, they are valuable sources of information on potential adverse reactions and complications, especially when other forms of evidence are not available. Because of the nature of the primary studies informing the evidence base for all of the special procedures, no estimate of how many people undergo special procedures and how many experience complications was available.

As for the evidence map and the overview of SRs of acupuncture, while the vast number of included SRs (535 SRs in the evidence map and 24 SRs in the overview, of which six reported adverse events) suggests that most of the secondary evidence in the field had been captured, the overlap of the included primary studies and their robustness were unclear.

3.3 Strengths and limitations of this Rapid Review

The main strength of this rapid review is that, employing a comprehensive search of available evidence across multiple sources (seven databases and almost 50 websites as well as review unpicking where relevant and forward and backward citation tracking), it has gathered all relevant evidence for physical health risks associated with special procedures in one place: secondary evidence for tattooing, body piercing, and acupuncture and primary evidence for semi-permanent make-up and electrolysis due to the lack of existing reviews. The evidence included in the present review was selected using a robust process, with two reviewers independently screening all citations. Measures were taken to ensure the accuracy of data

extraction and quality appraisal of the available literature: these were conducted by one reviewer and checked by another.

However, it has a number of limitations. First of all, due to the volume of available literature and to avoid duplication of research effort, existing SRs were used for the evidence of physical health risks associated with tattooing and body piercing and maps/overviews of SRs for acupuncture. This meant that reporting in the present review depended on the level of detail and robustness of the evidence synthesis in the identified SRs or maps/overviews of SRs. As a result, the way that information was presented across the special procedures differed and some information that might be contained in the primary studies included in the SRs was not available. The limited time frame for this review in light of the amount of available evidence also meant that in-depth synthesis of the evidence was not possible, so high-level descriptive syntheses was carried out.

Regarding the topic of body piercing, as multiple SRs were included, overlap of their primary studies had to be considered. In this review, corrected covered area was calculated to determine overlap, which was found moderate. This means that some primary studies were included multiple times across the four SRs, so it is possible that some of the reported numbers of cases and adverse events of body piercing are overestimated in this rapid review. Determining the overlap between the primary studies included in the SRs reported in the overviews of SRs of acupuncture was not possible due to the volume of SRs and the time constraints.

3.4 Implications for policy and practice

The evidence contained in this review will not only be used to inform the training of local authority enforcement officers and special procedures practitioners, but to educate members of the public who seek to use these services.

It is important to note that the causal links between the special procedures and adverse events reported in this review could not be established due to the designs of the primary studies contributing to the evidence base. However, due to the nature of the special procedures which involves piercing the skin and poses the risk of introducing infections to the body, high standards of hygiene may reduce the rate of infection.

3.5 Implications for future research

All identified evidence for the physical health risks associated with semi-permanent make-up and electrolysis came from case reports. The majority of the primary studies included in the SRs of tattooing and body piercing were also case reports or case series. Future research may employ more robust study designs to improve the quality of available evidence and give an indication as to the causal links between these special procedures and adverse physical health events as well as to the prevalence of such events in people receiving special procedures.

The present review identified a paucity of evidence of the physical health risks associated with electrolysis. Only one case report of complications following electrolysis was found, indicating that this topic is under-researched. More evidence is needed to identify the risks associated with this procedure.

4. REFERENCES

- Abtahi-Naeini B, Shahmoradi Z, Hadian M, et al. (2019). Multiple pigmented macules as a sequel of cosmetic lip micro-pigmentation: New clinical presentation of tattoo reactions. *Nigerian Postgraduate Medical Journal*. 26(4): 244-6. doi: https://dx.doi.org/10.4103/npmj.npmj_88_19
- Acuña-Chavez LM, Alva-Alayo CA, Aguilar-Villanueva GA, et al. (2022). Bacterial infections in patients with nipple piercings: a qualitative systematic review of case reports and case series. *GMS Infectious Diseases*. 10: Doc03. doi: <https://doi.org/10.3205/id000080>
- Akoh CC, Akintilo L, Shankar S, et al. (2021). A rare case of microblading-induced preseptal cellulitis. *JAAD Case Reports*. 16: 98-100. doi: <https://dx.doi.org/10.1016/j.jdc.2021.08.014>
- Aromataris E, Fernandez R, Godfrey CM, et al. (2015). Summarizing systematic reviews: methodological development, conduct and reporting of an umbrella review approach. *International Journal of Evidence Based Healthcare*. 13(3): 132-40. doi: <https://doi.org/10.1097/XEB.0000000000000055>
- Bashinskaya A, Fernandez AD, Morgan MB. (2022). Permanent makeup procedure heralds the development of systemic sarcoidosis. *Cureus*. 14(10): e30918. doi: <https://dx.doi.org/10.7759/cureus.30918>
- Bombonato C, Argenziano G, Lallas A, et al. (2015). Orange color: a dermoscopic clue for the diagnosis of granulomatous skin diseases. *Journal of the American Academy of Dermatology*. 72(1 Suppl): S60-3. doi: <https://doi.org/10.1016/j.jaad.2014.07.059>
- Bougioukas KI, Diakonidis T, Mavromanoli AC, et al. (2023). ccaR: a package for assessing primary study overlap across systematic reviews in overviews. *Research Synthesis Methods*. 14(3): 443-54. doi: <https://doi.org/10.1002/jrsm.1610>
- Cai M, Yang EJ. (2019). Complementary and alternative medicine for treating amyotrophic lateral sclerosis: A narrative review. *Integr Med Res*. 8(4): 234-9. doi: [10.1016/j.imr.2019.08.003](https://doi.org/10.1016/j.imr.2019.08.003)
- Castaño-Fernández JL, Grau-Pérez M. (2023). Microblading-transmitted Monkeypox (mpox) infection: fomites matter. *British Journal of Dermatology*. 188(6): e40. doi: <https://dx.doi.org/10.1093/bjd/ljad063>
- Chan MWC, Wu XY, Wu JCY, et al. (2017). Safety of acupuncture: overview of systematic reviews article. *Scientific Reports*. 7(3369). doi: <https://dx.doi.org/10.1038/s41598-017-03272-0>
- Chartered Institute of Environmental Health. (2013). Tattooing and body piercing guidance. Toolkit. Chartered Institute of Environmental Health. Available at: <https://www.cieh.org/media/2004/tattooing-and-body-piercing-guidance-toolkit-july-2013.pdf> [Accessed 17th July 2023].
- De Cuyper C. (2008). Permanent makeup: indications and complications. *Clinical Dermatology*. 26(1): 30-4. doi: <https://doi.org/10.1016/j.clindermatol.2007.10.009>
- Dunning J, Butts R, Mourad F, et al. (2014). Dry needling: a literature review with implications for clinical practice guidelines. *Physical Therapy Reviews*. 19(4): 252-65. doi: [10.1179/108331913X13844245102034](https://doi.org/10.1179/108331913X13844245102034)
- Ebrahimiadib N, Adelpour F, Ghahari M, et al. (2021). Intermediate uveitis associated with tattooing of eyebrows as a manifestation of systemic sarcoidosis: report of two cases. *Ocular Immunology & Inflammation*. 29(5): 902-5. doi: <https://dx.doi.org/10.1080/09273948.2019.1699581>
- Ernst E. (2010). Acupuncture. *Lancet Oncology*. 11(1): 20. doi: [https://doi.org/10.1016/S1470-2045\(09\)70399-7](https://doi.org/10.1016/S1470-2045(09)70399-7)
- Fernandez AA, Franca K, Chacon AH, et al. (2013). From flint razors to lasers: a timeline of hair removal methods. *Journal of Cosmetic Dermatology*. 12(2): 153-62. doi: [10.1016/j.jocd.12021](https://doi.org/10.1016/j.jocd.12021)

- Gartlehner G, Nussbaumer-Streit B, Devane D, et al. (2023). Rapid reviews methods series: Guidance on assessing the certainty of evidence. *BMJ Evidence Based Medicine*. doi: <https://doi.org/10.1136/bmjebm-2022-112111>
- Gilhooley E, O'Grady C, Tobin AM, et al. (2020). Photoinduced granulomatous reaction of cosmetically tattooed lips. *Journal of Cosmetic Dermatology*. 19(12): 3423-5. doi: <https://doi.org/10.1111/jocd.13664>
- Goldberg H, Berger Y, Ben Bassat I, et al. (2018). Inadvertent corneal pigmentation following cosmetic blepharopigmentation. *American Journal of Ophthalmology Case Reports*. 12: 52-4. doi: <https://doi.org/10.1016/j.ajoc.2018.09.002>
- Guyatt G, Oxman AD, Akl EA, et al. (2011). GRADE guidelines: 1. Introduction-GRADE evidence profiles and summary of findings tables. *Journal of Clinical Epidemiology*. 64(4): 383-94. doi: <https://doi.org/10.1016/j.jclinepi.2010.04.026>
- Haddaway NR, Grainger MJ, Gray CT. (2021). citationchaser: an R package for forward and backward citations chasing in academic searching. Available at: <https://github.com/nealhaddaway/citationchaser>.
- Hennequin-Hoenderdos N, Slot N, Van der Weijden G. (2016). The incidence of complications associated with lip and/or tongue piercings: a systematic review. *International Journal of Dental Hygiene*. 14(1): 62-73. doi: <https://doi.org/10.1111/idh.12118>
- Hinojosa T, Lewis DJ, Sharghi KG, et al. (2017). Verrucous eyebrows: a cutaneous manifestation of a systemic disease. *Journal of the European Academy of Dermatology and Venereology* 31(10): e430-e2. doi: <https://doi.org/10.1111/jdv.14246>
- Hirai Y, Hamada Y, Sasaki S, et al. (2022). Sarcoidosis and sarcoidal foreign body reaction after permanent eye makeup application: Analysis by immunohistochemistry with commercially available antibodies specific to *Cutibacterium acnes* and *Mycobacteria*. *Journal of Cutaneous Pathology*. 49(7): 651-7. doi: <https://dx.doi.org/10.1111/cup.14219>
- Huisman S, van der Bent SAS, Wolkerstorfer A, et al. (2019). Granulomatous tattoo reactions in permanent makeup of the eyebrows. *Journal of Cosmetic Dermatology*. 18(1): 212-4. doi: <https://dx.doi.org/10.1111/jocd.12540>
- Ibraheim MK, Desai M, Tawfik M, et al. (2023). Microblading-induced granulomatous reaction: case report and review of the literature. *American Journal of Dermatopathology*. 45(7): 487-91. doi: <https://dx.doi.org/10.1097/DAD.0000000000002449>
- Inprasit C, Huang YC, Lin YW. (2020). Evidence for acupoint catgut embedding treatment and TRPV1 gene deletion increasing weight control in murine model. *International Journal of Molecular Medicine*. 45(3): 779-92. doi: 10.3892/ijmm.2020.4462
- Iwayama T, Fukumoto T, Horita N, et al. (2017). Granulomatous reaction to permanent eyebrow makeup successfully treated with topical steroids in combination with topical tacrolimus. *European Journal of Dermatology*. 27(6): 652-4. doi: <https://dx.doi.org/10.1684/ejd.2017.3106>
- Joanna Briggs Institute. (2013). JBI Levels of Evidence. Available at: https://jbi.global/sites/default/files/2019-05/JBI-Levels-of-evidence_2014_0.pdf.
- Kay Garcia M, Chiang JS. (2007). chapter 130 - Acupuncture. In: Waldman SD & Bloch JI (eds.) *Pain Management*. Philadelphia: W.B. Saunders.
- Kwon CY, Yoon SH, Lee B. (2019). Clinical effectiveness and safety of acupotomy: An overview of systematic reviews. *Complementary Therapies in Clinical Practice*. 36: 142-52. doi: <https://doi.org/10.1016/j.ctcp.2019.07.002>
- Lahouel I, Salah NB, Machghoul S, et al. (2022). Allergic contact dermatitis post-microblading eyebrow tattooing: A manifestation of pre-existing nickel sensitization. *Journal of Cosmetic Dermatology*. 21(10): 5270-1. doi: <https://dx.doi.org/10.1111/jocd.14920>

- Leight-Dunn H, Lemly V, Chapas A. (2022). Delayed granulomatous reaction after eyebrow microblading. *Dermatologic Surgery*. 48(1): 142-3. doi: <https://doi.org/10.1097/dss.0000000000003236>
- Lunny C, Pieper D, Thabet P, et al. (2021). Managing overlap of primary study results across systematic reviews: practical considerations for authors of overviews of reviews. *BMC Medical Research Methodology*. 21(1): 140. doi: <https://doi.org/10.1186/s12874-021-01269-y>
- Maier T, Flaig MJ, Ruzicka T, et al. (2015). High-definition optical coherence tomography and reflectance confocal microscopy in the in vivo visualization of a reaction to permanent make-up. *Journal of the European Academy of Dermatology & Venereology*. 29(3): 602-6. doi: <https://dx.doi.org/10.1111/jdv.12402>
- Marcelino FFN, de Oliveira-Filho J, Junqueira GMD, et al. (2021). Molluscum contagiosum as a tattoo complication: A case report and literature review. *Surgical and Cosmetic Dermatology*. 13(1): 1-6. doi: <https://dx.doi.org/10.5935/scd1984-8773.2021130008>
- McGowan J, Sampson M, Salzwedel DM, et al. (2016). PRESS Peer Review of Electronic Search Strategies: 2015 Guideline Statement. *Journal of Clinical Epidemiology*. 75: 40-6. doi: <https://doi.org/10.1016/j.jclinepi.2016.01.02110.1016/j.jclinepi.2016.01.021>
- Mirzaei A, Joharimoghadam MM, Zabihyeganeh M. (2017). Adalimumab-responsive refractory sarcoidosis following multiple eyebrow tattoos: a case report. *Tanaffos*. 16(1): 80-3. doi: <https://pubmed.ncbi.nlm.nih.gov/28638429/>
- Moola S, Munn Z, Tufanaru C, et al. (2020). Chapter 7: Systematic reviews of etiology and risk. In: Aromataris E & Munn Z (eds.) *JBI Manual for Evidence Synthesis*. JBI.
- Morand M, Beauregard S, Mathieu S. (2015). Systemic sarcoidosis revealed by axillary electrolysis. *Journal of Cutaneous Medicine & Surgery*. 19(4): 404-6. doi: <https://doi.org/10.1177/1203475415575016>
- Motoki THC, Isoldi FC, Ferreira LM. (2020). Pathologic scarring after eyebrow micropigmentation: a case report and systematic review. *Advances in Skin & Wound Care*. 33(10): 1-4. doi: <https://dx.doi.org/10.1097/01.ASW.0000672496.83825.75>
- Naeini FF, Pourazizi M, Abtahi-Naeini B, et al. (2017). Looking beyond the cosmetic tattoo lesion near the eyebrow: screening the lungs. *Journal of Postgraduate Medicine*. 63(2): 132-4. doi: <https://doi.org/10.4103/0022-3859.201421>
- National Assembly for Wales. (2017). Research briefing. *Public Health (Wales) Act 2017*. Act summary. Available at: [https://senedd.wales/research%20documents/public%20health%20\(wales\)%20act%202017/17-025-web-english.pdf](https://senedd.wales/research%20documents/public%20health%20(wales)%20act%202017/17-025-web-english.pdf) [Accessed 17th July 2023].
- Navarro-Triviño FJ, Naranjo-Diaz MJ, Ruiz-Villaverde R. (2021). Cutaneous lymphoid hyperplasia caused by cosmetic lip tattoo successfully treated with tacrolimus 0.1% ointment. *Contact Dermatitis*. 84(4): 270-2. doi: <https://doi.org/10.1111/cod.13726>
- Nie S, Li K, Gao C, et al. (2022). Eyebrow tattoo-associated sarcoidosis: A case report. *Frontiers in Medicine*. 9: 1009135. doi: <https://dx.doi.org/10.3389/fmed.2022.1009135>
- O'Neill J. (2014). Tackling a crisis for the health and wealth of nations. The review on antimicrobial resistance. HM Government and Wellcome Trust. Available at: https://amr-review.org/sites/default/files/AMR%20Review%20Paper%20-%20Tackling%20a%20crisis%20for%20the%20health%20and%20wealth%20of%20nations_1.pdf [Accessed 17th July 2023].
- Passos PF, Pintor AVB, Maranon-Vasquez GA, et al. (2022). Oral manifestations arising from oral piercings: a systematic review and meta-analyses. *Oral surgery, oral medicine, oral pathology and oral radiology*. 134: 327-41. doi: <https://doi.org/10.1016/j.oooo.2022.04.051>
- Patel M, Cobbs CG. (2015). Infections from body piercing and tattoos. *Microbiology Spectrum*. 3(6). doi: <https://doi.org/10.1128/microbiolspec.iol5-0016-2015>
- Piccinini P, Pakalin S, Contor L, et al. (2016). Safety of tattoos and permanent make-up: Final report. EUR 27947. Publications Office of the European Union. Available at: <https://publications.jrc.ec.europa.eu/repository/handle/JRC101601> [Accessed 17th July 2023].

- Pieper D, Antoine SL, Mathes T, et al. (2014). Systematic review finds overlapping reviews were not mentioned in every other overview. *Journal of Clinical Epidemiology*. 67(4): 368-75. doi: <https://dx.doi.org/10.1016/j.jclinepi.2013.11.007>
- Royal Society for Public Health. (2019). *Skins and Needles*. Royal Society of Public Health. Available at: <https://www.rsph.org.uk/our-work/policy/infection-control/skins-and-needles.html>.
- Sano E, Truong J, Chenevert L. (2021). Bilateral periorbital cellulitis after eyebrow microblading. *Visual Journal of Emergency Medicine*. 25(101172). doi: <https://dx.doi.org/10.1016/j.visj.2021.101172>
- Shea BJ, Reeves BC, Wells G, et al. (2017). AMSTAR 2: a critical appraisal tool for systematic reviews that include randomised or non-randomised studies of healthcare interventions, or both. *BMJ*. 358: j4008. doi: <https://doi.org/10.1136/bmj.j4008>
- Sindoni A, Valeriani F, Galle F, et al. (2021). Adverse effects related to tattoos in the community setting: a systematic review. *Journal of Epidemiology & Community Health*. 75(10): 1023-8. doi: <https://doi.org/10.1136/jech-2021-216874>
- Sindoni A, Valeriani F, Protano C, et al. (2022). Health risks for body pierced community: a systematic review. *Public Health*. 205: 202-15. doi: <https://doi.org/10.1016/j.puhe.2022.01.035>
- Soltany A, Alajieh ME, Al Aissami M. (2023). A rare case of microblading complicated by orbital exenteration and frontal defect reconstructed using crane principle. *Plastic and Reconstructive Surgery - Global Open*. 11(3): e4857. doi: <https://dx.doi.org/10.1097/GOX.0000000000004857>
- Suleman S, Villegas M, Davis T, et al. (2023). Chronic Granulomatous Reaction to Semi-permanent Eyebrow Tint. *Cureus*. 15(8): e44070. doi: <https://dx.doi.org/10.7759/cureus.44070>
- Sun YH, Lao LM. (2023). Granulomatous reaction to permanent eyebrow makeup successfully treated with oral tofacitinib. *Journal of Cosmetic Dermatology*. 22(7): 2131-2. doi: <https://dx.doi.org/10.1111/jocd.15679>
- Thomas J, O'Mara-Eves A, Harden A, et al. (2017). Chapter 8: Synthesis methods for combining and configuring textual or mixed methods data. In: Gough D, Oliver S & Thomas J (eds.) *An introduction to systematic reviews*. London: Sage Publications Limited.
- Tierney E, Kavanagh GM. (2021). Koebnerization secondary to microblading. *Journal of Cosmetic Dermatology*. 20(4): 1040-1. doi: <https://dx.doi.org/10.1111/jocd.13695>
- Tittelbach J, Peckruhn M, Schliemann S, et al. (2018). Sarcoidal foreign body reaction as a severe side-effect to permanent makeup: successful treatment with intralesional triamcinolone. *Acta Dermato-Venereologica*. 98(4): 458-9. doi: <https://dx.doi.org/10.2340/00015555-2876>
- Tukenmez Demirci G, Mansur AT, Yildiz S, et al. (2016). Is it a sarcoidal foreign-body granuloma or a cutaneous sarcoidosis on a permanent eyebrow make-up? *Journal of Cosmetic & Laser Therapy*. 18(1): 50-2. doi: <https://dx.doi.org/10.3109/14764172.2015.1052516>
- Valbuena MC, Franco VE, Sanchez L, et al. (2017). Sarcoidal granulomatous reaction due to tattoos: report of two cases. *Anais Brasileiros de Dermatologia*. 92(5 Suppl 1): 138-41. doi: <https://doi.org/10.1590/abd1806-4841.20175860>
- Vera C, Vera J, Ball E, et al. (2018). Red and itchy bilateral supraorbital swellings. *Journal of the German Society of Dermatology*. 16(12): 1503-6. doi: <https://doi.org/10.1111/ddg.13687>
- Vieira A, Reis AM, Matos LC, et al. (2018). Does auriculotherapy have therapeutic effectiveness? An overview of systematic reviews. *Complementary Therapies in Clinical Practice*. 33: 61-70. doi: <https://doi.org/10.1016/j.ctcp.2018.08.005>
- Welsh Government. (2017). *Public Health (Wales) Act 2017*. Available at: <https://www.legislation.gov.uk/anaw/2017/2/contents/enacted> [Accessed 17th July 2023].

- Welsh Government. (2023). Wales to introduce UK-first mandatory national licensing scheme for special procedures such as tattoos. Available at: <https://www.gov.wales/wales-introduce-uk-first-mandatory-national-licensing-scheme-special-procedures-such-tattoos> [Accessed 17th July 2023].
- Wong E, Heacock H. (2018). Biological hazards associated with microblading and evaluation of its infection control procedures and wound care. BCIT Environmental Public Health Journal. doi: <https://doi.org/10.47339/ephj.2018.56>
- Xu M, Yang C, Nian T, et al. (2023). Adverse effects associated with acupuncture therapies: An evidence mapping from 535 systematic reviews. Chinesische Medizin. 18(1): 38. doi: <https://doi.org/10.1186/s13020-023-00743-7>
- Yang C, Hao Z, Zhang LL, et al. (2015). Efficacy and safety of acupuncture in children: an overview of systematic reviews. Pediatric Research. 78(2): 112-9. doi: <https://doi.org/10.1038/pr.2015.91>

5. RAPID REVIEW METHODS

5.1 Eligibility criteria

Eligibility criteria for each of the sub-questions are presented in Tables 4–8.

Table 4. Eligibility criteria: Tattooing

	Inclusion criteria	Exclusion criteria
Population	People of any age receiving tattoos on any body part	
Intervention/exposure	Cosmetic skin tattooing (including semi-permanent make-up, i.e., microblading and micropigmentation)	Non-skin tattooing (e.g., corneal tattooing), medical tattooing
Control/comparison	N/A	
Outcome measures	Any physical health risks	Mental health risks
Setting/context	Commercial/business setting	Healthcare setting
Study design	Systematic Reviews Meta-analyses Rapid Reviews using systematic search methods and critical appraisal	Primary studies Narrative reviews
Countries	No geographic limits	
Language of publication	English	
Publication date	Since 2015	
Publication type	Published and grey literature	Letters, commentary, editorials, conference abstracts, protocols
Other factors Any other key points to note	Contraindications will not be purposefully searched for but will be included in the RR report if described in the identified evidence for physical health risks.	

Table 5. Eligibility criteria: Semi-permanent make-up

	Inclusion criteria	Exclusion criteria
Population	People of any age	
Intervention/exposure	Semi-permanent make-up (microblading and micropigmentation)	
Control/comparison	N/A	
Outcome measures	Any physical health risks	Mental health risks
Setting/context	Commercial/business setting	
Study design	Quantitative primary studies Case reports and case series	Secondary research
Countries	No geographic limits	
Language of publication	English	
Publication date	From 2015	
Publication type	Published and grey literature	Letters, commentary, editorials, conference abstracts, protocols
Other factors Any other key points to note	Contraindications will not be purposefully searched for but will be included in the RR report if described in the identified evidence for physical health risks.	

Table 6. Eligibility criteria: Body piercing

	Inclusion criteria	Exclusion criteria
Population	People of any age receiving body piercings on any body part	
Intervention/exposure	Cosmetic body piercing	Self-piercing
Control/comparison	N/A	
Outcome measures	Any physical health risks	Mental health risks
Setting/context	Commercial/business setting	
Study design	Systematic Reviews Meta-analyses Rapid Reviews using systematic search methods and including critical appraisal	Primary studies Narrative reviews
Countries	No geographic limits	
Language of publication	English	
Publication date	From 2015	
Publication type	Published and grey literature	Letters, commentary, editorials, conference abstracts, protocols
Other factors Any other key points to note	Contraindications will not be purposefully searched for but will be included in the RR report if described in the identified evidence for physical health risks.	

Table 7. Eligibility criteria: Acupuncture

	Inclusion criteria	Exclusion criteria
Population	General population of any age	Specific patient populations
Intervention/exposure	Needle acupuncture	Non-needle acupuncture (e.g., laser)
Control/comparison	N/A	
Outcome measures	Any physical health risks	Mental health risks
Setting/context	Any setting	
Study design	Overviews of systematic reviews and meta-analyses (umbrella reviews)	Primary studies Systematic Reviews Rapid Reviews Scoping Reviews Narrative reviews
Countries	No geographic limits	
Language of publication	English	
Publication date	From 2015	
Publication type	Published and grey literature	Letters, commentary, editorials, conference abstracts, protocols
Other factors Any other key points to note	Contraindications will not be purposefully searched for but will be included in the RR report if described in the identified evidence for physical health risks.	

Table 8. Eligibility criteria: Electrolysis

	Inclusion criteria	Exclusion criteria
Population	People of any age receiving electrolysis on any body part	
Intervention/exposure	Cosmetic electrolysis (hair removal technique)	Preoperative hair removal Laser-based or light-based hair removal (photoepilation)
Control/comparison	N/A	
Outcome measures	Any physical health risks	Mental health risks
Setting/context	Commercial/business setting	Healthcare setting
Study design	Quantitative primary studies Case reports and case series	Secondary research
Countries	No geographic limits	
Language of publication	English	
Publication date	From 2015	
Publication type	Published and grey literature	Letters, commentary, editorials, conference abstracts, protocols
Other factors Any other key points to note	Contraindications will not be purposefully searched for but will be included in the RR report if described in the identified evidence for physical health risks.	

5.2 Literature search

5.2.1 Evidence sources

Comprehensive searches were conducted across the following databases for English-language publications from 2015 to August 2023:

- On the Ovid Platform: Medline, Embase, Ovid Emcare, Allied and Complementary Medicine Database (AMED)
- On the EBSCO Platform: Cumulative Index of Nursing and Allied Health Literature (CINAHL)
- Epistemonikos (Questions 1a, 2 and 3 only)
- Cochrane Database of Systematic Reviews (Questions 1a, 2 and 3 only)

The websites of key third sector and government organisations and accreditation bodies were also searched and can be seen in Appendix 3.

5.2.2 Search strategy

An initial search of PUBMED was undertaken using the following keywords (tattoo* OR microblading* OR micropigmentation* OR makeup* OR pierc* OR electrolysis OR acupuncture) AND (adverse* or complication* or infectio* or allerg* or anaphylax* OR contra* OR sepsis OR harm OR safe*) This search was filtered by review or meta-analysis.

This initial search was followed by an analysis of the most relevant records to establish the most frequently used text words contained in the titles and abstracts and index terms used to describe articles. This informed the development of a comprehensive search strategy which was tailored for each information source. Full search strategies for all five questions are detailed in Appendix 2. Forward and backward citation tracking was completed using the citation chaser application (Haddaway et al. 2021), and relevant studies were added to the review.

5.2.3 Peer review

To ensure the robustness and validity of the searches, we implemented a rigorous peer review process:

- The review team and a wider collaboration of stakeholders, including both information and subject specialists, were involved in the development, testing and reviewing of the search strategies prior to their final run.
- Test searches were assessed using “known relevant records”, and the searches were adjusted accordingly.
- The Peer Review of Electronic Search Strategies (PRESS) checklist was used (McGowan et al. 2016) to assess all elements of the search process.

5.2.4 Reference management

All citations retrieved from the database searches were imported or entered manually into EndNote™ (Thomson Reuters, CA, USA) and duplicates were removed. Following this process, the remaining citations were exported as a TXT file and imported to Rayyan™, where any remaining duplicates were removed prior to sifting.

5.3 Study selection process

All citations were independently screened, using the information provided in the title and abstract, by two reviewers using the software package Rayyan™, with any conflicts resolved by a third reviewer. For citations that appeared to meet the inclusion criteria or in cases in which a definite decision could not be made based on the title and/or abstract alone, the full texts were retrieved. The full texts were then screened for inclusion using a customised screening tool by two reviewers, with any disagreements resolved by a third reviewer. The flow of citations through each stage of the review process for each question is displayed using a table adapted from the PRISMA flow diagram, which can be found in Section 6.1. The list of studies excluded at the full-text stage and the reasons for exclusion are reported in Table 18 in Appendix 4.

5.4 Data extraction

All relevant data were extracted directly into tables by one reviewer and checked by another. The data extracted included specific details about the populations, study methods, and outcomes of significance to the review questions and objectives and can be found in Section 6.2. Data extraction templates were piloted on manuscripts for each of the included study designs and amendments were made prior to data extraction.

5.5 Quality appraisal

5.5.1 Quality of the SRs and map/overview of reviews

Eligible SRs and maps/overviews of SRs were critically appraised using the JBI critical appraisal checklist for systematic reviews and research syntheses (Aromataris et al. 2015).. When a study or review met a criterion for inclusion, a score of one was given. Where a particular point for inclusion was regarded as not met, “unclear”, or “not applicable”, a score of zero was given. Overall critical appraisal scores were presented. The results of critical appraisal were reported in narrative form as well as in Table 16. Methodological quality assessment was conducted by one reviewer and checked by another. All SRs and maps/overviews of SRs, regardless of the results of their methodological quality, underwent data extraction and synthesis.

Alternative appraisal tools that can be used for assessing the quality of SRs, evidence maps and overviews of reviews include the AMSTAR-2 (Shea et al. 2017). While in this rapid review, the JBI critical appraisal checklist for systematic reviews and research syntheses (Aromataris et al. 2015) was selected due to its ability to be completed more swiftly than AMSTAR-2, four of the JBI quality checklist questions could be matched to the domains deemed critical in the AMSTAR-2 which were considered relevant to this review. A fifth AMSTAR-2 critical domain also assessed by the JBI checklist, the impact of publication bias, was not considered as relevant to this review because the majority of studies within the included SRs were case reports.

As a result, the JBI domains considered critical after the mapping include the following:

Q3: Was the search strategy appropriate?

Q4: Were the sources and resources used to search for studies adequate?

Q5: Were the criteria for appraising studies appropriate?

Q8: Were the methods used to combine studies appropriate?

Each review was then assessed based on the answers provided to the four critical domains as well as the remaining, non-critical, domains, and an overall rating of quality for each review was generated as detailed below.

- High [++]: No or one non-critical weakness. The systematic review provides an accurate and comprehensive summary of the results of the available studies that address the question of interest.
- Moderate [+]: More than one non-critical weakness². The systematic review has more than one weakness but no critical flaws. It may provide an accurate summary of the results of the available studies that were included in the review.
- Low [-]: One critical flaw with or without non-critical weaknesses. The review has a critical flaw and may not provide an accurate and comprehensive summary of the available studies that address the question of interest.
- Critically low [--]: More than one critical flaw with or without non-critical weaknesses. The review has more than one critical flaw and should not be relied on to provide an accurate and comprehensive summary of the available studies.

5.5.2 Quality of the case reports

Case reports were critically appraised using the JBI checklist for case reports (Moola et al. 2020). When a study or review met a criterion for inclusion, a score of one was given. Where a particular point for inclusion was regarded as not met, “unclear”, or “not applicable”, a score of zero was given. Overall critical appraisal scores were presented. The results of critical appraisal were reported in narrative form as well as in Table 17. Methodological quality assessment was conducted by one reviewer and checked by another. No formal process was used to rate the overall quality of the case reports, but where this was reported within individual reviews, it was extracted.

² Multiple non-critical weaknesses may diminish confidence in the review and it may be appropriate to move the overall appraisal down from moderate to low quality.

5.6 Synthesis

The data were reported narratively as a series of thematic summaries (Thomas et al. 2017) and was structured around the type of special procedure and adverse events.

For question 2 (body piercing), the overlap of primary research studies included in the SRs was checked and reported narratively and using tables and figures. For question 3 (acupuncture), the overlap of SRs in the maps/overviews of SRs was checked manually and reported narratively. The term overlap is used when multiple SRs on a topic include the same primary research studies (Lunny et al. 2021). Overlap can lead to issues with precision, as duplicate studies could cause an overestimation of sample sizes and number of events. Hence, it is important to determine how much overlap exists between included SRs (Lunny et al. 2021).

As a first stage for determining overlap, primary studies included in the four body piercing SRs were listed in MS Excel to see which ones were included in more than one review. Listing was assisted by the use of Web of Science, as it enabled the download of SR reference lists as an MS Excel file. To ensure the accuracy of the Web of Science generated reference lists, these were compared to data extraction and summary tables of SRs, and the included primary research studies were selected. In cases where the Web of Sciences did not identify the included primary research studies, these were manually added.

After studies were tabulated for each SR, a final overlap table was created where only unique studies were listed. Unique studies were coded depending on which review they were included in. Based on the format developed by (Bougioukas et al. 2023), the number 1 was allocated to studies when they appeared in a review, and the number 0 if they were not included. The final overlap table is presented in Appendix 5 (Table 19). Following coding, the overlap tables were imported into R Studio software to calculate the corrected covered area (CCA; Pieper et al. 2014). The corrected covered area is used to determine the degree of overlap between SRs. Using this approach, less than 5% CCA is a slight overlap, 6-10% CCA is a moderate overlap, 11-15% CCA is a high overlap and >15% CCA is a very high overlap (Pieper et al. 2014). In R Studio, the `cca` R package was used for calculation both across the four SRs and pairwise and to create a heatmap depicting pairwise CCA (Bougioukas et al. 2022).

The corrected covered area across the four SRs was 8.8%, indicating a moderate overlap. There were 136 unique primary studies out of 172 reported across the four SRs. While the narrative of the four SRs indicated 174 included primary studies, in one review (Sindoni et al. 2022), references for two studies could not be found. Therefore, these two could not be compared to studies reported in the other SRs, leading to only 172 studies used for the CCA calculation.

Regarding pairwise comparison between SRs, Acuña-Chavez et al. (2022) had no overlap with Hennequin-Hoenderdos et al. (2016) and Passos et al. (2022). This is due to Acuña-Chavez et al. (2022) focusing on nipple piercings specifically, while the other two focused on oral piercings. The highest degree of overlap (CCA=25.5%) was between Hennequin-Hoenderdos et al. (2016) and Passos et al. (2022), as apart from one study, Passos et al. (2022) contained all studies from Hennequin-Hoenderdos et al. (2022). Sindoni et al. (2022) focused on all piercing sites; hence, it overlapped with all the other three SRs. The heatmap depicting further details and comparisons is presented in Figure 1 below.

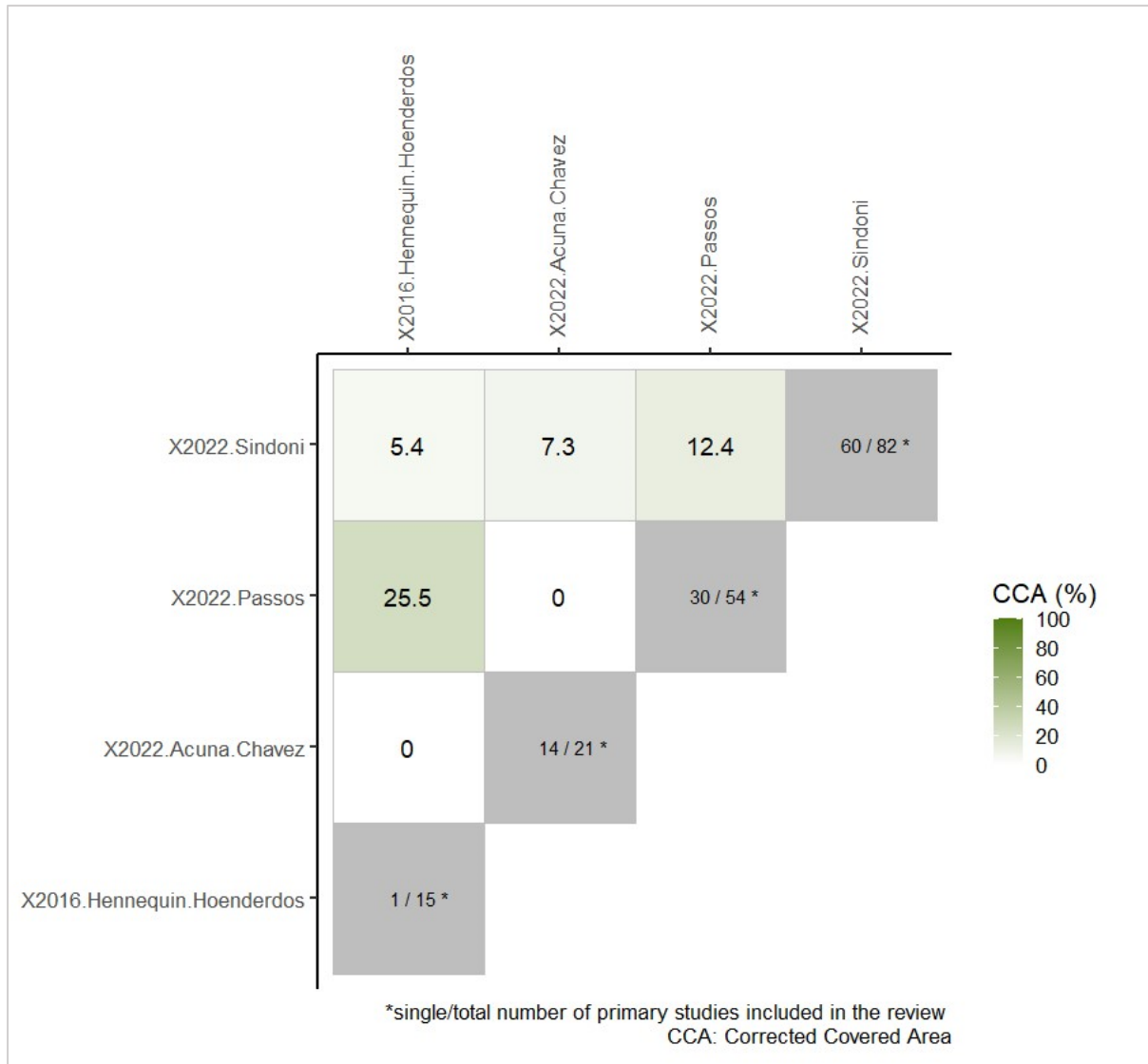


Figure 1. Heatmap depicting pairwise corrected covered area comparison of body piercing systematic reviews

As for the map and overview of SRs of acupuncture reported here (Xu et al. 2023, Yang et al. 2015), the overlap of SRs included in them was checked manually due to the fact that one of the overviews of SRs (Yang et al. 2015) only included six relevant SRs. One of these SRs was also reported in Xu et al. (2023). Determining the overlap between the primary studies included in the SRs reported in the overviews of SRs was not possible due to the volume of SRs and the time constraints of this rapid review.

5.7 Assessment of body of evidence

No formal process was used to rate the overall confidence in the evidence, but where it was reported within individual reviews, this was extracted. The GRADE (Grading of Recommendations, Assessment, Development, and Evaluation) approach assigns a certainty value to provide stakeholders with a measure of confidence in the quality of the evidence (Guyatt et al. 2011). As GRADE assessment is usually conducted using outcome effect estimates from primary studies or from a meta-analysis in rapid reviews where SRs are included, the Cochrane Rapid Review Methods Group recommends using existing GRADE from these reviews (Gartlehner et al. 2023). In this rapid review, of the five included SRs, an evidence map, and an overview of reviews, only one (Passos et al. 2022) used the GRADE approach. Due to the rapid review timeframe and the types of evidence included in the SRs with no GRADE, it was not possible for us to establish certainty of evidence based on the GRADE approach.

6. EVIDENCE

6.1 Search results and study selection

Searches for SRs of physical health risks associated with tattooing and semi-permanent make-up identified two relevant SRs, one of which focused on tattooing and the other on micropigmentation. The SR of the risks of micropigmentation had not identified any relevant literature, so separate searches for primary research into the risks of semi-permanent make-up were conducted. They resulted in 31 included studies. Searches for the other types of special procedures identified four SRs of body piercing, one evidence map, four overviews of SRs of acupuncture, and one primary study of electrolysis. Details of the methodology, including the search and selection process, are provided in Section 5 of this report. The flow of studies through the study selection process is reported in Table 9.

Table 9. Flow of studies through the study selection process

	Q1a. Tattooing ³	Q1b. SPMU	Q2. Body piercing	Q3. Acu- puncture	Q4. Electrolysis
Database searches (n)					
Medline (Ovid)	236	213	89	114	412
EMBASE (Ovid)	215	214	89	168	708
Ovid EMCARE	66	51	31	76	20
AMED (Ovid)	1	1	0	21	0
CINAHL (EBSCO)	38	46	22	86	158
Cochrane Library (Reviews)	5	N/A	5	2	N/A
Epistemonikos	86	N/A	34	86	N/A
TOTAL	647	525	270	553	1298
Screening processes (n)					
Duplicates removed in EndNote	231	251	113	301	412
Imported into Rayyan	416	274	157	252	886
Duplicates removed in Rayyan	39	3	17	28	20
Title and abstract screening	377	271	140	224	866
Full text screening	23	43	15	7	21
Excluded at full-text screening ⁴ :	21	22	11	2	20
Wrong intervention	0	4	0	0	5
Wrong publication type	0	8	2	0	1
Wrong study design	13	0	6	0	1
Wrong population	0	0	0	0	0
Wrong outcome	3	2	2	0	6
Wrong setting	0	1	0	0	2
Not English language	0	1	0	0	0
No full text available	0	0	0	0	1
Unpicked NR	N/A	5	N/A	N/A	3
Data could not be extracted	0	1	0	0	1
SR: Less than 2 databases and/or no critical appraisal	5	N/A	1	2	N/A
Studies included after full text screening	2	21	4	5	1
Studies identified through grey literature searches	0	0 ⁵	0	0	0
Studies identified by citation tracking	0	1	0	0	0
Studies identified through review unpicking	N/A	9	N/A	N/A	0
TOTAL	2	31	4	5	1

Key: SPMU = semi-permanent make-up, SR = systematic review, NR = narrative review.

³ Searched for reviews of both tattooing and semi-permanent make-up

⁴ See Table 18 in Appendix 4 for detail

⁵ 1 NR identified and unpicked

6.2 Data extraction

Separate tables are presented for the data extraction for each special procedure.

Table 10. Summary of included systematic reviews – Tattooing

Citation	Review details Participants Outcomes of interest	Characteristics of included primary studies	Details of search Quality of the primary research Quality of the review	Findings
<p>Sindoni et al. 2021</p> <p>Adverse effects related to tattoos in the community setting: a systematic review.</p> <p>https://doi.org/10.1136/jech-2021-216874</p>	<p><u>Aim</u> To assess the literature evidence about decorative tattoos complications, considering both infective and non-infective risks</p> <p><u>Special procedure/s</u> Tattoos (made by injecting one or more inks into the skin by the use of needles)</p> <p><u>Punctured site</u> Microbiological (n=10): Not reported (n=3) Multiple (n=2) Leg (n=3) Arm (n=2)</p> <p>Non-microbiological (n=37) Not reported (n=7) Multiple (n=8) Torso (n=7) Arm (n=7) Leg (n=3) Face (n=3) Buttock (n=1) Penis (n=1)</p>	<p><u>Number of included studies</u> 55</p> <p><u>Study designs</u> Case report (n=32) Case series (n=13) Cross-sectional (n=7) Cohort study (n=2) Retrospective study (n=1)</p> <p><u>Date period covered by primary studies</u> 1991-2020</p> <p><u>Time frame for reporting/experiencing adverse effects</u> Microbiological (reported in 4/10) 6 & 10 days (2 cases, 1 study) 3 weeks (n=1) 2 months (n=2)</p> <p>Non-microbiological (reported in 19/37): 2 weeks (n=2) 1-2 months (n=3) 3-6 months (n=2) 3,6 and 7 months (3 cases) 1 study) 1-2 years (n=9)</p>	<p><u>Date restrictions</u> Inception until April 2020</p> <p><u>Databases searched</u> PubMed Scopus Web of Science</p> <p><u>Language restrictions</u> English</p> <p><u>Appraisal scale</u> JBI checklist for case reports National Institute of Health Quality Assessment Tools (cohort studies, case series, cross sectional studies – Newcastle-Ottawa Quality Assessment Tool for Cohort Studies Jadad Scale (RCTs)</p> <p><u>Appraisal rating</u> Good quality (n=40) Fair quality (n=5) Poor quality (n=2) CA of another 8 studies is not reported</p>	<p><u>Microbiological adverse effects</u> 10 studies described the following</p> <ul style="list-style-type: none"> 60 cases of non-tuberculous <i>Mycobacteria</i> skin infections across 2 case series (age range 19-54) were also found from tattoos performed with diluted ink 14 cases of <i>Mycobacterium chelonae</i> from 17 tissue specimens + 4 cases of cutaneous Mycobacterial infection (<i>Mycobacterium chelonae</i> infection) among 134 tattooed people. premixed ink contaminated before distribution was hypothesised as a risk factor 2 cases of life-threatening cellulitis 1 case of cutaneous diphtheria across 2 studies 1 case of Staphylococcal scalded skin syndrome caused by tattoos or by illegally imported tattoo inks 1 case of HCV infection in a man with around 750 tattoos, some performed by himself 1 case warts (a case series found that warts were seven times more likely to be localised within black ink of tattoos when compared with coloured ink). Caused by tattoos or by illegally imported tattoo inks <p>Outbreaks were associated with poor infection control practices at tattoo studios and contamination of grey wash ink at point of manufacture</p> <p><u>Non-microbiological adverse effects</u> There were 27 case reports, 8 case series, 1 descriptive study and 1 cohort study that described non microbiological effects. Thirty-three studies had a good quality, four showed a fair quality</p> <p>From the descriptive survey</p> <ul style="list-style-type: none"> Skin problems (67.5%) Systemic reactions (6.6%) <p>From the cohort study</p>

	<p>Both microbiological and non-biological (n=8) Not reported (n=8)</p> <p><u>Practitioner</u> Not reported</p> <p><u>Participants</u> Mostly adults (up to ~80 years) 3 studies included children under 18</p> <p><u>Sex</u> Case Reports (32) Males (16) Females (14) Mix (2)</p> <p>Remaining study types (23): Males (2) Females (1) Mix (7) Not reported (13)</p> <p><u>Outcomes of interest</u> Microbiological and non-microbiological adverse effects as a result of tattoos</p>	<p>Several years (n=1) 8 years (n=1) Over 10 years (n=1)</p> <p><u>Countries</u> Not reported</p> <p><u>Settings</u> Not reported</p>	<p><u>Microbiological adverse effects</u> Good quality (n=7) Poor quality (n=2) Fair quality (n=1)</p> <p><u>Microbiological adverse effects</u> Good quality (n=33) Fair quality (n=4)</p> <p><u>Review appraisal score</u> Scored 8 out of 11 on the JBI critical appraisal checklist for systematic reviews and research syntheses.</p>	<ul style="list-style-type: none"> • Short tear film break-up time • Corneal erosion and meibomian gland loss • Increased tear film instability and exacerbated signs and symptoms of ocular surface disease <p>From the case reports</p> <ul style="list-style-type: none"> • Scar, intractable nausea and vomiting • Dermatofibrosarcoma protuberans • Cutaneous and pulmonary sarcoidosis • Extensive deposition of tattoo ink in lymph nodes • Systemic anaphylaxis • Pseudoepitheliomatous hyperplasia • Blistering of the skin over therapeutic application on tattoo site • Systemic anaphylaxis • Pyoderma gangrenosum • Allergic contact dermatitis • Hemangioma • Epithelioid osteoblastoma • Lichenoid and inflammatory reactions to chemically reactive substances of the tattoo dye • Skin graft and reconstructive surgery not possible due to multiple tattoos in donor sites • Sarcoidosis and sarcoid uveitis • Granulomatous dermatitis • Bleeding and priapism • Burning pain and skin reaction during Magnetic Resonance Imaging execution • Inflammatory reactions <p>From case series Skin capacitance higher in tattooed skin compared to non-tattooed skin.</p> <ul style="list-style-type: none"> • Allergic tattoo reactions • Melanoma • Pseudoepitheliomatous hyperplasia • Lichenoid reaction • Keratoacanthoma • Squamous cell carcinoma • Basal cell carcinoma • Systemic sarcoidosis • Uveitis • Allergic contact dermatitis to a red–brown dye
--	--	---	--	---

				<ul style="list-style-type: none"> • Dermatofibrosarcoma protuberans • Dermatofibroma • Tattoo pigment in lymph nodes mimicking nodal metastasis in melanoma • Granulomatous infiltrate • Nodular dermal lymphohistiocytic infiltration • Granulomatous dermatitis • Leiomyosarcoma, follicular, nonresponse to laser treatment due to overrepresentation of titanium <p><u>Studies evaluating both microbiological and non-microbiological (8 studies)</u></p> <ol style="list-style-type: none"> 1. Infections 2. Allergic reactions (37%), papulo-nodular reactions (13%), bacterial infections (11%), Sarcoidosis (5%) and photosensitivity, pain syndrome and lymphopathy 3. Unusual bleeding, local skin irritation, local infection, dye allergy, swollen glands near to the site 4. Oedema, pruritus, allergy, local infection and Koebner phenomenon 5. Skin irritations (short term redness, dry skin or tenderness), Hepatitis 6. Infection, pruritus and pain. 7. Pain, swelling, dermatitis, eczema, itching, skin thickening, allergic reactions and also suppuration, bleeding, dizziness, headache, scabs and fever 8. Tattoo-related infections followed by swelling, pain and other
--	--	--	--	--

Key: CA: critical appraisal; HCV: Hepatitis C Virus.

Table 11. Summary of included systematic reviews – Semi-permanent make-up

Citation	Review details Participants Outcomes of interest	Characteristics of included primary studies	Details of search Quality of the primary research Quality of the review	Findings
<p>Motoki et al. 2020</p> <p>Pathologic scarring after eyebrow micropigmentation: a case report and systematic review.</p> <p>https://doi.org/10.1097/01.asw.0000672496.83825.75</p>	<p><u>Aim</u> To carry out a systematic review of the literature on this topic and report a case of pathologic scarring on the eyebrows after micropigmentation</p> <p><u>Special procedure/s</u> Micropigmentation</p> <p><u>Outcomes of interest</u> Pathologic scarring</p>	<p><u>Number of included studies</u> None</p>	<p><u>Date restrictions</u> No date range restrictions</p> <p><u>Databases searched</u> MEDLINE SciELO Lilacs</p> <p><u>Language restrictions</u> Portuguese, English and Spanish</p> <p><u>Appraisal scale</u> Oxford Centre for Evidence-Based Medicine critical appraisal tool</p> <p><u>Review appraisal score</u> Appraisal not conducted because the review did not identify any relevant studies</p>	<p>The systematic review did not identify any relevant studies</p>

Table 12. Summary of included primary studies – Semi-permanent make-up

Citation	Study details Quality ratings	Participants Setting Time frame for experiencing/ reporting adverse effect	Findings
<p>Abtahi-Naeini 2019</p> <p>Multiple pigmented macules as a sequel of cosmetic lip micro-pigmentation new clinical presentation of tattoo reactions</p> <p>https://doi.org/10.4103/npmj.npmj_88_19</p>	<p><u>Study design</u> Case report</p> <p><u>Outcome/s of interest</u> Lichenoid tattoo reactions</p> <p><u>Comparator intervention or control</u> NA</p> <p><u>Data collection methods</u> NA</p> <p><u>Country</u> Iran</p> <p><u>Quality rating</u> Scored 7 out of 8 on the JBI critical appraisal checklist for case reports</p>	<p><u>Sample size</u> 1</p> <p><u>Participants</u> 35-year-old woman</p> <p><u>Setting</u> Commercial</p> <p><u>Practitioner</u> Nonmedical professional</p> <p><u>Puncture site</u> Lips</p> <p><u>Time frame</u> 5 weeks</p>	<p>A 35-year-old woman received permanent make-up (red-pink) of lips and lip lines by micro-pigmentation and developed hyperpigmentation, associated with mild pruritus, occurred on her upper lip line, 5 weeks after a single session of tattooing. The histopathological sections of a biopsy from pigmented lip macule were notable lichenoid lymphocytic infiltrations. Mild acanthosis, basal vacuolar degeneration and prominent band-like infiltration were notable. A diagnosis of lichenoid tattoo reactions following lip tattooing was made.</p>
<p>Akoh 2021</p> <p>A rare case of microblading-induced preseptal cellulitis</p> <p>https://doi.org/10.1016/j.jdc.2021.08.014</p>	<p><u>Study design</u> Case report</p> <p><u>Outcome/s of interest</u> Preseptal cellulitis</p> <p><u>Comparator intervention or control</u> NA</p> <p><u>Data collection methods</u> NA</p>	<p><u>Sample size</u> 1</p> <p><u>Participants</u> 39-year-old woman</p> <p><u>Setting</u> Commercial</p> <p><u>Practitioner</u> Aesthetician</p> <p><u>Puncture site</u></p>	<p>A 39-year-old woman with sickle cell disease presented with a significant periocular facial eruption (pustules in the malar area of the right cheek, which progressed to bilateral periorbital edema and pustules draining purulent exudate) after undergoing microblading 3 weeks prior. She had no history of allergies, photosensitivity, or similar skin eruptions. A few days later, she presented again with bilateral periorbital hyperpigmentation, edema, erythema, crusting, and pustules with involvement of the malar area of the cheeks and was disoriented, afebrile, and tachycardic. Preseptal cellulitis secondary to microblading was diagnosed.</p>

	<u>Country</u> USA <u>Quality rating</u> Scored 8 out of 8 on the JBI critical appraisal checklist for case reports	<u>Eyebrows</u> <u>Time frame</u> 3 weeks	
Bashinskaya 2022 Permanent make-up procedure heralds the development of systemic sarcoidosis https://doi.org/10.7759/cureus.30918	<u>Study design</u> Case report <u>Outcome/s of interest</u> Systemic sarcoidosis Cutaneous sarcoidosis, including non-caseating epithelioid granulomas <u>Comparator intervention or control</u> NA <u>Data collection methods</u> NA <u>Country</u> USA <u>Quality rating</u> Scored 5 out of 8 on the JBI critical appraisal checklist for case reports	<u>Sample size</u> 1 <u>Participants</u> 48-year-old Hispanic woman <u>Setting</u> Commercial <u>Practitioner</u> NR <u>Puncture site</u> Eyebrows <u>Time frame</u> NR	A report on a 48-year-old Hispanic female with a new onset of scar sarcoidosis that progressed to a systemic condition. Erythematous maculopapular eruptions arose on her left eyebrow area at the sites of scars from cosmetic tattooing, prior to the small airway disease exacerbation. Histopathologic examination revealed typical findings of cutaneous sarcoidosis, including non-caseating epithelioid granulomas.
Bombonato 2015 Orange color a dermoscopic clue for the diagnosis of granulomatous skin diseases https://dx.doi.org/10.1016/j.jaad.2014.07.059	<u>Study design</u> Case report <u>Outcome/s of interest</u> Chronic granulomatous inflammation <u>Comparator intervention or control</u> NA	<u>Sample size</u> 1 <u>Participants</u> 38-year-old woman <u>Setting</u> Commercial <u>Practitioner</u> NR	A report of 38-year-old woman who presented with asymptomatic coalescing hard yellowish red papules located on her eyebrows overlying a cosmetic tattoo. Histologic evaluation revealed a chronic granulomatous inflammation without necrosis in the superficial and deep dermis. In the dermis, giant cells and foreign amorphous material and black pigments were detected, which suggested the diagnosis of granulomatous reaction on the top of a cosmetic tattoo.

	<p><u>Data collection methods</u> NA</p> <p><u>Country</u> Italy</p> <p>Quality rating Scored 4 out of 8 on the JBI critical appraisal checklist for case reports</p>	<p><u>Puncture site</u> <u>Eyebrows</u></p> <p><u>Time frame</u> NR</p>	
<p>Castaño-Fernández 2023</p> <p>Microblading-transmitted Monkeypox (mpox) infection fomites matter</p> <p>https://doi.org/10.1093/bjd/ljad063</p>	<p><u>Study design</u> Case report</p> <p><u>Outcome/s of interest</u> Monkeypox (mpox) infection</p> <p><u>Comparator intervention or control</u> NA</p> <p><u>Data collection methods</u> Physical examination and Lab Test</p> <p><u>Country</u> Spain</p> <p><u>Quality rating</u> Scored 5 out of 8 on the JBI critical appraisal checklist for case reports</p>	<p><u>Sample size</u> 1</p> <p><u>Participants</u> 47-year-old woman</p> <p><u>Setting</u> Commercial</p> <p><u>Practitioner</u> NR</p> <p><u>Puncture site</u> <u>Eyebrows</u></p> <p><u>Time frame</u> 10 days</p>	<p>A 47-year-old woman with no relevant medical history presented with a 10-day facial skin eruption, after undergoing eyebrow microblading 4 days before the lesions started. Physical examination revealed a plaque with central necrotic ulceration on the medial margin of her left eyebrow. The mpox virus polymerase chain reaction test came back positive while other tests were negative. Mpox is transmitted by direct skin contact or by infected fomites.</p>
<p>Ebrahimiadib 2021</p> <p>Intermediate uveitis associated with tattooing of eyebrows as a manifestation of systemic sarcoidosis report of two cases</p> <p>https://doi.org/10.1080/09273948.2019.1699581</p>	<p><u>Study design</u> Case report</p> <p><u>Outcome/s of interest</u> Systematic sarcoidosis Non-caseating granulomas uveitis</p> <p><u>Comparator intervention or control</u></p>	<p><u>Sample size</u> 2</p> <p><u>Participants</u> 46-year-old woman 49-year-old woman</p> <p><u>Setting</u> Commercial</p>	<p>Case report describing two women presented with tattoo-associated uveitis as the first manifestations of systemic sarcoidosis. They developed intermediate uveitis shortly after skin inflammation several months after permanent make-up tattooing of eyebrows. Both had scaling and red papules on tattoo sites and one had swelling. Lung involvement, high angiotensin-converting enzyme levels, and negative PPD were present. Biopsy confirmed the presence of non-caseating granulomas consistent with systemic sarcoidosis in both. Both had non-granulomatous intermediate uveitis of moderate intensity. Skin granuloma formation was</p>

	<p>NA</p> <p><u>Data collection methods</u> NA</p> <p><u>Country</u> Iran</p> <p><u>Quality rating</u> Scored 7 out of 8 on the JBI critical appraisal checklist for case reports</p>	<p><u>Practitioner</u> NR</p> <p><u>Puncture site</u> Eyebrows</p> <p><u>Time frame</u> NR</p>	<p>diffused over the area of the tattoo in one patient and localized in the other.</p>
<p>Gilhooley 2020</p> <p>Photoinduced granulomatous reaction of cosmetically tattooed lips</p> <p>https://doi.org/10.1111/jocd.13664</p>	<p><u>Study design</u> Case report</p> <p><u>Outcome/s of interest</u> Non-caseating granulomas</p> <p><u>Comparator intervention or control</u> NA</p> <p><u>Data collection methods</u> NA</p> <p><u>Country</u> Ireland</p> <p><u>Quality rating</u> Scored 8 out of 8 on the JBI critical appraisal checklist for case reports</p>	<p><u>Sample size</u> 1</p> <p><u>Participants</u> 33-year-old woman</p> <p><u>Setting</u> Commercial</p> <p><u>Practitioner</u> NR</p> <p><u>Puncture site</u> Eyebrows and lips</p> <p><u>Time frame</u> 18 months after additional ultraviolet sunbed exposure</p>	<p>A 33-year-old woman presented with erythematous, edematous, and inflamed lips and reported an acute onset of symptoms following ultraviolet radiation exposure on a sunbed 6 months prior. She had cosmetically tattooed her lips and eyebrows 18 months prior. It was the first exposure to sunbed ultraviolet radiation after tattooing.</p> <p>Viral and bacterial swabs, serological investigations, fecal calprotectin test and chest X-ray did not identify any findings. On histopathology, aggregated epithelioid histiocytes formed discrete noncaseating granulomas within the dermis. In the superficial dermis, histiocytes displayed pigment. Under polarized light, the pigment was consistent with a foreign body. These findings were consistent with a granulomatous reaction to tattoo pigment.</p>
<p>Goldberg 2018</p> <p>Inadvertent corneal pigmentation following cosmetic blepharopigmentation</p> <p>https://doi.org/10.1016/j.ajoc.2018.09.002</p>	<p><u>Study design</u> Case report</p> <p><u>Outcome/s of interest</u> Conjunctival injection and pigmented stain on the eye</p>	<p><u>Sample size</u> 1</p> <p><u>Participants</u> 63-year-old woman</p> <p><u>Setting</u></p>	<p>A 63 year old woman presented with redness and irritation in her left eye for two days. A thick black pigmentation line of both upper and lower lash lines was evident. In the left eye there was conjunctival injection and on the nasal part of the cornea there was a large black pigmented stain. Three days prior to she had undergone permanent eyeliner tattooing on the upper and lower eyelids of both eyes and was not aware of any complications during</p>

	<p><u>Comparator intervention or control</u> NA</p> <p><u>Data collection methods</u> NA</p> <p><u>Country</u> Israel</p> <p><u>Quality rating</u> Scored 8 out of 8 on the JBI critical appraisal checklist for case reports</p>	<p>Commercial</p> <p><u>Practitioner</u> NR</p> <p><u>Puncture site</u> Eyelids</p> <p><u>Time frame</u> One day</p>	<p>the tattooing. On the following day she started feeling progressive irritation in the left eye. The pigment contained mainly carbon, oxygen and potassium, and small amounts of calcium, sulfur, chlorine and phosphorus. The presence of lead or copper was ruled out.</p>
<p>Hinojosa 2017</p> <p>Verrucous eyebrows a cutaneous manifestation of a systemic disease</p> <p>https://doi.org/10.1111/jdv.14246</p>	<p><u>Study design</u> Case report</p> <p><u>Outcome/s of interest</u> Cutaneous sarcoidosis Systematic sarcoidosis Conjunctival injection</p> <p><u>Comparator intervention or control</u> NA</p> <p><u>Data collection methods</u> NA</p> <p><u>Country</u> Unclear – Mexico or USA</p> <p><u>Quality rating</u> Scored 8 out of 8 on the JBI critical appraisal checklist for case reports</p>	<p><u>Sample size</u> 1</p> <p><u>Participants</u> 52-year-old Hispanic woman</p> <p><u>Setting</u> Commercial</p> <p><u>Practitioner</u> NA</p> <p><u>Puncture site</u> Eyebrows</p> <p><u>Time frame</u> 3 years</p>	<p>A 52-year-old Hispanic woman presented with a 5-month history of lesions on her eyebrows (brownish-pink verrucous plaques with slight crusting on both eyebrows). She also exhibited bilateral conjunctival injection without discharge. 3 years prior to presentation, she had undergone cosmetic eyebrow tattooing with an unspecified 'natural' substance in the same location. Microscopic examination revealed nodular collections of epithelioid histiocytes surrounded by a sparse infiltrate of lymphocytes throughout the dermis as well as the presence of an asteroid body. No foreign material was identified following the use of polarized light. A diagnosis of cutaneous sarcoidosis was made. Computed tomography of the chest confirmed the diagnosis of systemic sarcoidosis, with multiple subpleural nodules, multiple hilar nodules and prominent mediastinal and hilar lymph nodes.</p>
<p>Hirai 2022</p> <p>Sarcoidosis and sarcoidal foreign body reaction after permanent eye makeup application Analysis by immunohistochemistry with commercially available</p>	<p><u>Study design</u> Case report</p> <p><u>Outcome/s of interest</u> Non-caseating Granulomas</p>	<p><u>Sample size</u> 2</p> <p><u>Participants</u> 75-year-old woman</p>	<p>Two cases of granulomas that occurred at permanent makeup application sites. In both cases, noncaseating epithelioid cell granulomas developed at the permanent eye makeup injection site. A 75-year-old woman presented with a rash on both eyebrows after permanent makeup procedure 1 year and 9 months prior. A skin</p>

<p>antibodies specific to Cutibacterium acnes and Mycobacteria</p> <p>https://doi.org/10.1111/cup.14219</p>	<p>Sarcoidosis and sarcoidal foreign body reaction</p> <p><u>Comparator intervention or control</u> NA</p> <p><u>Data collection methods</u> NA</p> <p><u>Country</u> Japan</p> <p><u>Quality rating</u> Scored 7 out of 8 on the JBI critical appraisal checklist for case reports</p>	<p>46-year-old woman</p> <p><u>Setting</u> Commercial</p> <p><u>Practitioner</u> NR</p> <p><u>Puncture site</u> Eyebrows</p> <p><u>Time frame</u> 21 months 10 years</p>	<p>biopsy of the eyebrow lesion revealed granulomatous inflammation in the upper dermis and subcutaneous tissue, but no necrotic changes. Most of the black brown granules of the permanent makeup were not present in the granulomas but were localized in the upper dermis. Sarcoidosis was diagnosed based on bilateral hilar lymphadenopathy, elevated ACE, abnormal accumulation in the hilar lymph nodes on gallium scintigraphy, and histopathological evidence in the skin biopsy specimen.</p> <p>A 46-year-old woman presented with nodules on both eyebrows after a permanent makeup procedure 10 years prior. A skin biopsy of the eyebrow lesion revealed noncaseating epithelioid cell granulomas with few lymphocytes. Most of the black-brown granules of the permanent makeup were predominantly distributed outside of the granuloma, some of the black-brown granules were phagocytized in the granulomas. A diagnosis of sarcoidal foreign-body reaction was made.</p>
<p>Huisman 2019</p> <p>Granulomatous tattoo reactions in permanent makeup of the eyebrows</p> <p>https://doi.org/10.1111/jocd.12540</p>	<p><u>Study design</u> Case report</p> <p><u>Outcome/s of interest</u> Granulomatous inflammation (5 cases) Systemic sarcoidosis (1 case)</p> <p><u>Comparator intervention or control</u> NA</p> <p><u>Data collection methods</u> NA</p> <p><u>Country</u> The Netherlands</p> <p><u>Quality rating</u> Scored 7 out of 8 on the JBI critical appraisal checklist for case reports</p>	<p><u>Sample size</u> 5</p> <p><u>Participants</u> All female, aged 33-57</p> <p><u>Setting</u> Commercial</p> <p><u>Practitioner</u> NR</p> <p><u>Puncture site</u> Eyebrows (5 cases)</p> <p><u>Time frame</u> 4 to 15 years</p>	<p>The clinical presentation in the 5 patients includes elevated and frequently yellowish plaques, sharply demarcated around the tattooed skin. All patients got permanent makeup of their eyebrows several times during the last 4-15 years. The time between the last placement of the cosmetic tattoo and the onset of complaints varied between 1 and 18 months. The dyes used were in the red, brown, and black spectrum. No triggering factors could be identified, and there was no history of systemic complaints. Histopathological evaluation revealed granulomatous inflammation in all patients and additional stains were negative for fungi and acid-resistant mycobacteria. In patient 1, an elevated angiotensin-converting enzyme level of 126 (range 20-70 U/L) was found. In the same patient, high-resolution computed tomography revealed mediastinal lymphadenopathy, concluding systemic sarcoidosis. In patient 4, a chest X-ray revealed hilar adenopathy and dubious nodules. In the other patients, we did not find any signs of systemic sarcoidosis. Patients were treated with topical or intralesional corticosteroids, resulting in almost complete resolution of the skin manifestation.</p>

<p>Ibraheim 2023</p> <p>Microblading-induced granulomatous reaction case report and review of the literature</p> <p>https://doi.org/10.1097/DAD.0000000000002449</p>	<p><u>Study design</u> Case report</p> <p><u>Outcome/s of interest</u> Foreign body granulomatous reaction Cutaneous sarcoidosis Contact dermatitis Granulomatous dermatitis</p> <p><u>Comparator intervention or control</u> NA</p> <p><u>Data collection methods</u> NA</p> <p><u>Country</u> Canada</p> <p><u>Quality rating</u> Scored 7 out of 8 on the JBI critical appraisal checklist for case reports</p>	<p><u>Sample size</u> 1</p> <p><u>Participants</u> 25-year-old woman</p> <p><u>Setting</u> Commercial</p> <p><u>Practitioner</u> NR</p> <p><u>Punctures site</u> Eyebrows</p> <p><u>Time frame</u> 7 months</p>	<p>A 25-year-old woman with no medical problems presented with a 1-month history of itchy, raised plaques affecting the eyebrows. She had previously undergone 5 microblading treatments, with the final one 7 months before the plaques appeared. The differential diagnosis included foreign-body granulomatous reaction, cutaneous sarcoidosis, and contact dermatitis. Punch biopsy revealed a dense, granulomatous dermatitis with associated brisk lymphoid infiltrate and pigment deposition.</p>
<p>Iwayama 2017</p> <p>Granulomatous reaction to permanent eyebrow makeup successfully treated with topical steroids in combination with topical tacrolimus</p> <p>https://doi.org/10.1684/ejd.2017.3106</p>	<p><u>Study design</u> Case report</p> <p><u>Outcome/s of interest</u> Granulomatous reaction</p> <p><u>Comparator intervention or control</u> NA</p> <p><u>Data collection methods</u> NA</p> <p><u>Country</u> Japan</p> <p><u>Quality rating</u></p>	<p><u>Sample size</u> 1</p> <p><u>Participants</u> 32-year-old woman</p> <p><u>Setting</u> Commercial</p> <p><u>Practitioner</u> NR</p> <p><u>Puncture site</u> Eyebrows</p> <p><u>Time frame</u> 4 years</p>	<p>A 32-year-old Japanese woman presented with papules on her right eyebrow, 4 years after receiving permanent eyebrow makeup. Based on clinical and histopathological findings, the skin lesions were diagnosed as a granulomatous reaction to the colourants.</p>

	Scored 7 out of 8 on the JBI critical appraisal checklist for case reports		
<p>Lahouel 2022</p> <p>Allergic contact dermatitis post-microblading eyebrow tattooing a manifestation of pre-existing nickel sensitization</p> <p>https://doi.org/10.1111/jocd.14920</p>	<p><u>Study design</u> Case report</p> <p><u>Outcome/s of interest</u> Allergic contact dermatitis (nickel induced)</p> <p><u>Comparator intervention or control</u> NA</p> <p><u>Data collection methods</u> NA</p> <p><u>Country</u> Tunisia</p> <p><u>Quality rating</u> Scored 7 out of 8 on the JBI critical appraisal checklist for case reports</p>	<p><u>Sample size</u> 1</p> <p><u>Participants</u> 50-year-old woman</p> <p><u>Setting</u> Commercial</p> <p><u>Practitioner</u> NR</p> <p><u>Puncture site</u> Eyebrows</p> <p><u>Time frame</u> 2 days</p>	<p>A 50-year-old woman with a history of intolerance to fake jewellery presented with bilateral, symmetrical, itchy, erythematous lesions on the eyebrows, which appeared 2 days after the application of microblading to her eyebrows. The diagnosis was nickel-induced allergic contact dermatitis post-microblading eyebrow tattooing performed with nickel containing needles.</p>
<p>Leight-Dunn 2022</p> <p>Delayed granulomatous reaction after eyebrow microblading</p> <p>http://dx.doi.org/10.1097/DSS.0000000000003236</p>	<p><u>Study design</u> Case report</p> <p><u>Outcome/s of interest</u> Granulomatous reaction Granulomatous dermatitis</p> <p><u>Comparator intervention or control</u> NA</p> <p><u>Data collection methods</u> Clinical examination</p> <p><u>Country</u> NR, possible the US</p>	<p><u>Sample size</u> 1</p> <p><u>Participants</u> 29-year-old women</p> <p><u>Setting</u> NR, possibly commercial</p> <p><u>Practitioner</u> NR</p> <p><u>Puncture site</u> Eyebrows</p> <p><u>Time frame</u></p>	<p>A case of a 29-year-old woman who presented with asymptomatic, yellow–orange, flat, firm 2 to 3-mm papules and plaques confined to the eyebrow margins, and received a diagnosis of a granulomatous tattoo reaction to iron oxide. The papules appeared spontaneously, 4 months after her seventh microblading treatment which took place over a 5-year period. A shave biopsy showed granulomatous dermatitis to foreign pigment. The ink ingredients contained iron oxide, glycerine, and isopropyl alcohol. The granulomas had persisted for 1 year by the time the patient chose to suspend treatment.</p>

	<p><u>Quality rating</u> Scored 7 out of 8 on the JBI critical appraisal checklist for case reports</p>	<p>4 months after 7th microblading treatment over a 5-year period</p>	
<p>Maier 2015</p> <p>High-definition optical coherence tomography and reflectance confocal microscopy in the in vivo visualization of a reaction to permanent make-up</p> <p>https://doi.org/10.1111/jdv.12402</p>	<p><u>Study design</u> Case report</p> <p><u>Outcome/s of interest</u> Granulomatous foreign body reaction</p> <p><u>Comparator intervention or control</u> NA</p> <p><u>Data collection methods</u> NA</p> <p><u>Country</u> Germany</p> <p><u>Quality rating</u> Scored 7 out of 8 on the JBI critical appraisal checklist for case reports</p>	<p><u>Sample size</u> 1</p> <p><u>Participants</u> 40-year-old woman</p> <p><u>Setting</u> Commercial</p> <p><u>Practitioner</u> NR</p> <p><u>Punctures site</u> Lips</p> <p><u>Time frame</u> 6 months</p>	<p>A 40-year-old woman presented with erythema, swelling, nodular induration and scaling of her lips, one year ago after receiving permanent make-up. Half a year after the procedure she experienced a strong swelling, scaling, and tenderness of her lips. Both in high-definition optical coherence tomography and in reflectance confocal microscopy subepidermal pigment and granulomatous changes could be visualized and correlated with the histopathological findings. Regression of the lesions in response to topical steroids and intralesional injections of steroids and 5-fluorouracil is reported.</p>
<p>Marcelino 2021</p> <p><i>Molluscum contagiosum</i> as a tattoo complication a case report and literature review</p> <p>https://doi.org/10.5935/scd1984-8773.2021130008</p>	<p><u>Study design</u> Case report</p> <p><u>Outcome/s of interest</u> <i>Molluscum contagiosum</i></p> <p><u>Comparator intervention or control</u> NA</p> <p><u>Data collection methods</u> NA</p> <p><u>Country</u> Brazil</p>	<p><u>Sample size</u> 1</p> <p><u>Participants</u> 64-year-old woman</p> <p><u>Setting</u> Commercial (aesthetic clinic)</p> <p><u>Practitioner</u> Nonmedical professional</p> <p><u>Puncture site</u> Eyebrows</p>	<p>A 64-year-old woman presented with 1 mm to 4 mm papules, pearly and normochromic, on the tattoo area on the right eyebrow, one month after eyebrows micropigmentation. The anatomopathological examination revealed a hyperplastic region in the epidermis characterized by cell proliferation from the Malpighian body, forming piriform invaginations into the dermis. Also found progressive accumulation of amorphous and eosinophilic material, compatible with <i>Molluscum contagiosum</i>.</p>

	<u>Quality rating</u> Scored 7 out of 8 on the JBI critical appraisal checklist for case reports	<u>Time frame</u> 1 month	
Mirzaei 2017 Adalimumab-Responsive Refractory Sarcoidosis Following Multiple Eyebrow Tattoos: A Case Report https://pubmed.ncbi.nlm.nih.gov/28638429/	<u>Study design</u> Case report <u>Outcome/s of interest</u> Löfgren's syndrome, an acute form of sarcoidosis <u>Comparator intervention or control</u> NA <u>Data collection methods</u> NA <u>Country</u> Iran <u>Quality rating</u> Scored 8 out of 8 on the JBI critical appraisal checklist for case reports	<u>Sample size</u> 1 <u>Participants</u> 47- year-old woman <u>Setting</u> Commercial <u>Practitioner</u> NR <u>Puncture site</u> Eyebrows <u>Time frame</u> 4 months	A 47- year-old woman with no significant medical history presented with polyarthrits along with symptoms of erythema nodosum-like nodules and low-grade fever and distinct red papules above the eyebrows. She reported multiple tattooing over the eyebrows, with the last tattooing 4 months before symptoms manifested. Results of hematological and biochemical tests were normal and Immunologic tests were negative. CT of thorax was showed bilateral hilar adenopathy with reticulonodular lesions in lower lobes of the lung. The diagnosis of Löfgren's syndrome, an acute form of sarcoidosis was confirmed based on the presence of the triad of erythema nodosum, bilateral hilar lymphadenopathy, and polyarthrits.
Motoki 2020 Pathologic scarring after eyebrow micropigmentation a case report and systematic review https://doi.org/10.1097/01.ASW.0000672496.83825.75	<u>Study design</u> Case report <u>Outcome/s of interest</u> Dermatitis <u>Comparator intervention or control</u> NA <u>Data collection methods</u> NA <u>Country</u> Brazil	<u>Sample size</u> 1 <u>Participants</u> 50-year-old woman <u>Setting</u> Commercial <u>Practitioner</u> Medical <u>Puncture site</u> Eyebrows <u>Time frame</u>	A report on a 50-year-old female aesthetician having nodules on her eyebrows approximately 2 months after an eyebrow micropigmentation procedure. She had undergone eyebrow micropigmentation annually for the last 4 years using a medium brown coloring agent. She reported constant pruritus, mild sharp pain, local hyperemia, and peeling. Recent micropigmentation procedures occurred 10 months and 2 months prior to her current presentation. A dermatologist diagnosed her eyebrow scarring as dermatitis. At the outpatient clinic during the initial physical examination, it was noted a fibroproliferative scar with significant vertical and horizontal growth originating in the micropigmentation area suggestive of hypertrophic scarring.

	<p><u>Quality rating</u> Scored 7 out of 8 on the JBI critical appraisal checklist for case reports</p>	<p>Undergoing microblading annually for 10 years and 2 months prior to current presentation</p>	
<p>Naeini 2017</p> <p>Looking beyond the cosmetic tattoo lesion near the eyebrow Screening the lungs</p> <p>https://doi.org/10.4103/0022-3859.201421</p>	<p><u>Study design</u> Case report</p> <p><u>Outcome/s of interest</u> Pulmonary sarcoidosis Cutaneous sarcoidal granulomas</p> <p><u>Comparator intervention or control</u> NA</p> <p><u>Data collection methods</u> NA</p> <p><u>Country</u> Iran</p> <p><u>Quality rating</u> Scored 7 out of 8 on the JBI critical appraisal checklist for case reports</p>	<p><u>Sample size</u> 1</p> <p><u>Participants</u> 45-year-old woman</p> <p><u>Setting</u> Commercial</p> <p><u>Practitioner</u> NR</p> <p><u>Puncture site</u> Eyebrows</p> <p><u>Time frame</u> NR</p>	<p>A 45-year-old woman with a 15-month history of lesions on her eyebrow tattoo. Her tattoos had red, scaly patches. A skin biopsy showed non necrotising granulomas with few lymphocytes around the granuloma and negative results on acid-fast Bacillus and fungal stains. Chest imaging revealed perihilar lymphadenopathy and few small nodules in both lungs, increased Interstitial markings and peribronchial cuffing. Blood tests revealed an abnormally high level of angiotensin-converting enzyme. A diagnosis of pulmonary sarcoidosis was supported by the presence of cutaneous sarcoidal granulomas.</p>
<p>Navarro-Triviño 2021</p> <p>Cutaneous lymphoid hyperplasia caused by cosmetic lip tattoo successfully treated with tacrolimus 0.1% ointment</p> <p>https://doi.org/10.1111/cod.13726</p>	<p><u>Study design</u> Case report</p> <p><u>Outcome/s of interest</u> Cutaneous lymphoid hyperplasia</p> <p><u>Comparator intervention or control</u> NA</p> <p><u>Data collection methods</u> NA</p>	<p><u>Sample size</u> 1</p> <p><u>Participants</u> 52-year-old Caucasian woman</p> <p><u>Setting</u> Commercial</p> <p><u>Practitioner</u> NR</p> <p><u>Puncture site</u></p>	<p>A 52-year-old Caucasian woman with red papules and nodules on the lip vermilion, exclusively affecting the tattooed area after a micropigmentation tattoo lasting 1 year. She reported a tattoo micropigmentation 5 years earlier. The patient showed a positive patch test reaction to tattoo ink. A skin lip biopsy revealed cutaneous lymphoid hyperplasia. The presence of exogenous red pigment was observed. Staining demonstrated CD3 and CD4 lymphocytes. Cutaneous lymphoid hyperplasia caused by permanent makeup ink was diagnosed.</p>

	<u>Country</u> Spain <u>Quality rating</u> Scored 7 out of 8 on the JBI critical appraisal checklist for case reports	<u>Eyebrows</u> <u>Time frame</u> 5 years	
Nie 2022 Eyebrow tattoo-associated sarcoidosis a case report https://doi.org/10.3389/fmed.2022.1009135	<u>Study design</u> Case report <u>Outcome/s of interest</u> Sarcoidosis Non-caseating granulomas <u>Comparator intervention or control</u> NA <u>Data collection methods</u> NA <u>Country</u> China <u>Quality rating</u> Scored 7 out of 8 on the JBI critical appraisal checklist for case reports	<u>Sample size</u> 1 <u>Participants</u> 41-year-old woman <u>Setting</u> Unclear. The report states that the patient tattooed her eyebrows, so may be a home procedure. <u>Practitioner</u> NR <u>Puncture site</u> Eyebrows <u>Time frame</u> 3 months	A 41-year-old Chinese woman presented with a slowly enlarged rash on the bilateral eyebrows and grouped reddish and yellow–brown infiltrative papules, some of which coalesced into plaques scattered over the tattoo. She had tattooed her eyebrows 3 months before the rash appeared. CT of the chest with contrast demonstrated a few diffuse reticulonodular opacities in the bilateral lower lobe, bilateral hilar lymph nodes enlargement, and in the posterior segment of the right upper lobe are some small ground glass nodules. Tattoo-associated sarcoidosis was diagnosed based on the clinical manifestation of yellow–brown plaque and histopathological findings of non-caseating granulomas at the tattoo site.
Sano 2022 Bilateral periorbital cellulitis after eyebrow microblading https://doi.org/10.1016/j.visj.2021.101172	<u>Study design</u> Case report (Visual Case Discussion) <u>Outcome/s of interest</u> Bilateral periorbital cellulitis <u>Comparator intervention or control</u> NA <u>Data collection methods</u> NA	<u>Sample size</u> 1 <u>Participants</u> 49-year-old woman <u>Setting</u> Commercial <u>Practitioner</u> NR <u>Punctured site</u>	A 49-year-old presented with bilateral eye swelling, redness, and pain for two weeks and foul-smelling discharge from both eyes for on the day of presentation, after eyebrow microblading. Examination of the patient shows notable bilateral periorbital erythema, swelling, and crusting of the skin around her eyebrows. Given her severe penicillin allergy, she was treated with IV fluids, IV vancomycin, and 750 mg PO levofloxacin for failed outpatient therapy of periorbital cellulitis. Orbital cellulitis was ruled out with a CT Orbit with IV contrast. In the inpatient setting 100 mg PO doxycycline was added to her antibiotic regimen. Her oedema and erythema improved with treatment, and she was discharged home with close follow-up and instructed to complete a total of 7 days of levofloxacin and doxycycline.

	<u>Country</u> USA <u>Quality rating</u> Scored 6 out of 8 on the JBI critical appraisal checklist for case reports	<u>Eyebrows</u> <u>Time frame</u> Same day	
Soltany 2023 A rare case of microblading complicated by orbital exenteration and frontal defect reconstructed using crane principle https://doi.org/10.1097/GOX.0000000000004857	<u>Study design</u> Case report <u>Outcome/s of interest</u> Cellulitis Necrotising fasciitis <u>Comparator intervention or control</u> NA <u>Data collection methods</u> NA <u>Country</u> Syria <u>Quality rating</u> Scored 8 out of 8 on the JBI critical appraisal checklist for case reports	<u>Sample size</u> 1 <u>Participants</u> 43-year-old woman <u>Setting</u> Commercial (local beauty centre) <u>Practitioner</u> NR <u>Punctured site</u> Eyebrows <u>Time frame</u> 4 days	A 43-year-old woman with diabetes had significant periocular facial eruption with edema four days after microblading for both eyebrows, and another few days of local signs of right periorbital and orbital cellulitis were noticed. Necrosis started at the 10th day. She developed right eye proptosis and painful eye movement, besides associated systemic manifestations of infection. Periorbital (preseptal) and orbital cellulitis were diagnosed. Despite treatment, the patient developed progressive blurry vision, winding up with vision loss with a vast periorbital necrosis representing a case of necrotising fasciitis. There was a 12 × 7 cm forehead defect with bony exposure measuring 7 × 4 cm, surrounded by granulation tissue.
Suleman 2023 Chronic granulomatous reaction to semi-permanent eyebrow tint https://doi.org/10.7759/cureus.44070	<u>Study design</u> Case report <u>Outcome/s of interest</u> Chronic granulomatous dermatitis <u>Comparator intervention or control</u> NA <u>Data collection methods</u>	<u>Sample size</u> 1 <u>Participants</u> 49-year-old Hispanic woman <u>Setting</u> Unclear <u>Practitioner</u>	A 49-year-old Hispanic presented with a past history of type II diabetes mellitus and hypertension presented with a pruritic rash over her eyebrows, erythematous and indurated plaques over the entire left eyebrow and a smaller plaque with crusting over the right lateral eyebrow a month after microblading. Results of the biopsy showed discrete granulomas in the lower portions of the dermis, most of which were naked with no surrounding cuff of mononuclear cells. There was fine-black intracellular particulate material in the cytoplasm of histiocytes in the papillary dermis, but no polarizable material was evident. Given the biopsy results, negative chest X-ray findings, and normal ACE levels, the patient was diagnosed with a chronic granulomatous dermatitis secondary to microblading

	<p>NA</p> <p><u>Country</u> Mexico</p> <p><u>Quality rating</u> Scored 7 out of 8 on the JBI critical appraisal checklist for case reports</p>	<p>Unclear. Referred to as a doctor but later discussion suggests otherwise</p> <p><u>Puncture site</u> Eyebrows</p> <p><u>Time frame</u> NR</p>	<p>tint.</p>
<p>Sun 2023</p> <p>Granulomatous reaction to permanent eyebrow makeup successfully treated with oral tofacitinib</p> <p>https://doi.org/10.1111/jocd.15679</p>	<p><u>Study design</u> Case report</p> <p><u>Outcome/s of interest</u> Granulomatous reaction</p> <p><u>Comparator intervention or control</u> NA</p> <p><u>Data collection methods</u> NA</p> <p><u>Country</u> China</p> <p><u>Quality rating</u> Scored 8 out of 8 on the JBI critical appraisal checklist for case reports</p>	<p><u>Sample size</u> 1</p> <p><u>Participants</u> 52-year-old woman</p> <p><u>Setting</u> Commercial</p> <p><u>Practitioner</u> NR</p> <p><u>Puncture site</u> Eyebrows</p> <p><u>Time frame</u> NR</p>	<p>A 52-year-old woman presented with multiple small subcutaneous papules along the eyebrows for half a year. Those papules developed with a delay of several weeks after permanent eyebrow makeup. The skin lesion was diagnosed as a granulomatous reaction to the colourant.</p>
<p>Tierney 2021</p> <p>Koebnerization secondary to microblading</p> <p>https://doi.org/10.1111/jocd.13695</p>	<p><u>Study design</u> Case report</p> <p><u>Outcome/s of interest</u> Vitiligo, arising from the koebnerisation</p> <p><u>Comparator intervention or control</u> NA</p>	<p><u>Sample size</u> 1</p> <p><u>Participants</u> 28-year-old woman</p> <p><u>Setting</u> Commercial</p> <p><u>Practitioner</u> NR</p>	<p>A 28-year-old Lithuanian woman presented with bilateral, symmetrical periocular depigmentation after 8 years of repeated eyebrow microblading. Examination under Woods light showed symmetrical, sharply demarcated, periocular depigmentation extending beyond both eyebrows and toward the medial canthi bilaterally. She was also noted to have a patch of depigmentation on her right forearm measuring 4 × 6 cm which had been stable for a number of years. She was diagnosed with vitiligo, arising from the koebnerisation effect of microblading. Tacrolimus 0.1% ointment was prescribed with advice on sun protection and avoidance for the depigmented areas.</p>

	<u>Data collection methods</u> NA <u>Country</u> UK <u>Quality rating</u> Scored 6 out of 8 on the JBI critical appraisal checklist for case reports	<u>Puncture site</u> Eyebrows <u>Time frame</u> 8 years after repeated microblading	
Tittelbach 2018 Sarcoidal foreign body reaction as a severe side-effect to permanent makeup successful treatment with intralesional triamcinolone https://doi.org/10.2340/00015555-2876	<u>Study design</u> Case report <u>Outcome/s of interest</u> Granulomatous foreign body reaction of sarcoidal type <u>Comparator intervention or control</u> NA <u>Data collection methods</u> NA <u>Country</u> Germany <u>Quality rating</u> Scored 7 out of 8 on the JBI critical appraisal checklist for case reports	<u>Sample size</u> 1 <u>Participants</u> 41-year-old woman <u>Setting</u> Commercial <u>Practitioner</u> NR <u>Puncture site</u> Eyebrows <u>Time frame</u> 18 months	A 41-year-old woman presented with itchy red papules developing in the tattooed area, starting on one side, 18 months previously. She had permanent makeup 10 years previously, which had been refreshed after 5 years. Biopsy revealed a “granulomatous foreign body reaction”. The patient received laser treatment, which resulted in a temporary improvement, but was followed by new, now partially ulcerating, lesions. Dermatological examination revealed yellowish erythematous indurated papules with mild scaling accentuated on the medial eyebrows. Patch test showed positive test results at 72 h only for nickel (II) sulphate (+++) and methylisothiazolinone (++) which were not present in the tattoo material. A skin biopsy showed granulomatous accumulation of epithelioid cells in the whole dermis, surrounded by a sparse lymphocytic infiltrate and some multinucleated histiocytes on the dermatopathological investigation. A diagnosis of a granulomatous foreign body reaction of sarcoidal-type to tattoo-ink in the permanent makeup was made.
Tukenmez Demirci 2016 Is it a sarcoidal foreign-body granuloma or a cutaneous sarcoidosis on a permanent eyebrow make-up? https://doi.org/10.3109/14764172.2015.1052516	<u>Study design</u> Case report <u>Outcome/s of interest</u> Sarcoidal foreign-body reaction Non-caseating granulomas <u>Comparator intervention or control</u>	<u>Sample size</u> 1 <u>Participants</u> 34-year-old woman <u>Setting</u> Commercial <u>Practitioner</u>	A 34-year-old woman presented with multiple hard, shiny yellowish, 0.2–0.5-cm-sized papules on her eyebrows for a month. She has had cosmetic permanent make-up of these areas for several times during the last 10 years, with the last procedure 2 years prior. Histopathology of a papule disclosed several naked, non-caseating granulomas, which were composed of histiocytes, a few giant cells of foreign-body type, and sparse lymphocytes. All the laboratory investigations were within normal limits except for a mild elevation in angiotensin-converting enzyme or ACE level. A diagnosis of sarcoidal-type foreign-body reaction to tattoo pigments was made.

	<p>NA</p> <p><u>Data collection methods</u> NA</p> <p><u>Country</u> Turkey</p> <p><u>Quality rating</u> Scored 7 out of 8 on the JBI critical appraisal checklist for case reports</p>	<p>NR</p> <p><u>Puncture site</u> Eyebrows</p> <p><u>Time frame</u> Procedures over the past 10 years with last one 2 years ago</p>	<p>The lesions mostly improved after topical corticosteroid treatment.</p>
<p>Valbuena 2017</p> <p>Sarcoidal granulomatous reaction due to tattoos report of two cases</p> <p>http://dx.doi.org/10.1590/abd1806-4841.20175860</p>	<p><u>Study design</u> Case report</p> <p><u>Outcome/s of interest</u> Sarcoidal granulomatous</p> <p><u>Comparator intervention or control</u> NA</p> <p><u>Data collection methods</u> NA</p> <p><u>Country</u> Colombia</p> <p><u>Quality rating</u> Scored 6 out of 8 on the JBI critical appraisal checklist for case reports</p>	<p><u>Sample size</u> 1</p> <p><u>Participants</u> 55-year-old woman</p> <p><u>Setting</u> Commercial</p> <p><u>Practitioner</u> NR</p> <p><u>Puncture site</u> Eyebrows</p> <p><u>Time frame</u> 16 years</p>	<p>A 55-year-old woman with a 2-year history of itchy persistent lesions on the eyebrows. She had a permanent makeup cosmetic tattoo 16 years before the onset of lesions. Histopathological examination of one of the lesions showed thick dermis with lymphocytic infiltrates around epithelioid granulomas involving the entire dermis, with presence of black pigment in the central portion. She was diagnosed with sarcoidal granulomatous reaction secondary to tattoo.</p>
<p>Vera 2018</p> <p>Red and itchy bilateral supraorbital swellings</p> <p>https://doi.org/10.1111/ddg.13687</p>	<p><u>Study design</u> Case report</p> <p><u>Outcome/s of interest</u> Systemic sarcoidosis</p> <p><u>Comparator intervention or control</u> NA</p>	<p><u>Sample size</u> 1</p> <p><u>Participants</u> A 50-year-old woman</p> <p><u>Setting</u> Commercial</p>	<p>A 50-year-old woman with Fitzpatrick skin type IV presented with bilateral, symmetrical, livid red, and itchy supraorbital skin swellings and loss of both eyebrows. The lesions had grown progressively in size over the previous four months at the sites where she had cosmetic tattooing of the eyebrows 7 years prior. A punch biopsy showed orthokeratosis and collagen bundles in the papillary dermis, with black pigment between the bundles. The dermis showed a dense nodular infiltrate with epithelioid nodules, histiocytes, many giant multinucleated Langerhans cells as well as</p>

	<u>Data collection methods</u> NA <u>Country</u> Unclear, probably Venezuela <u>Quality rating</u> Scored 5 out of 8 on the JBI critical appraisal checklist for case reports	<u>Practitioner</u> NR <u>Puncture site</u> Eyebrows <u>Time frame</u> NA	intra- and extracellular foreign body-like black granulomas. A CT scan showed bilateral and symmetrical hilar lymphadenopathy, with lymph nodes up to 1.5 cm in diameter. A diagnosis of systemic sarcoidosis with tattoo-induced skin lesions was made.
--	---	--	--

Key ACE: Angiotensin-converting enzyme; CT: Computerised tomography; NA: not applicable; NR: not reported; PO: Per os (by mouth); PPD: Purified-protein derivative

Table 13. Summary of included systematic reviews – Body piercing

Citation	Review details Participants Outcomes of interest	Characteristics of included primary studies	Details of search Quality of the primary research Quality of the review	Findings
<p>Acuña-Chávez et al. 2022</p> <p>Bacterial infections in patients with nipple piercings: a qualitative systematic review of case reports and case series.</p> <p>https://doi.org/10.3205/id000080</p>	<p><u>Aim</u> To identify the most frequently isolated bacteria in nipple-piercing associated infections in case reports or case series, and to describe clinical presentations and antecedents</p> <p><u>Special procedure/s</u> Body piercing (21 studies, 27 participants)</p> <p><u>Punctured site</u> Nipple (n=21)</p> <p><u>Practitioner</u> Not reported</p> <p><u>Participants</u> Adults and children Female (85%) 15-60 years old Ethnicity not reported</p> <p><u>Outcomes of interest</u> <u>Primary outcome/s</u> - Most frequently isolated bacteria <u>Secondary outcome/s</u> - Clinical manifestations</p>	<p><u>Number of included studies</u> 21</p> <p><u>Study designs</u> Case report (n=17) Case series (n=4)</p> <p><u>Date period covered by primary studies</u> 1995-2020</p> <p><u>Time frame for reporting/experiencing adverse effects</u> Not reported (n=9) < 1 month (n=3) > 1 month < 6months (n=7) Equal/> 6 months < 1 year (n=6) > 1 year (n=3) *comes to 28 so error in reporting</p> <p><u>Countries</u> USA (n=12) Australia (n=2) Canada (n=2) Germany (n=2) The Netherlands (n=2) UK (n=1)</p> <p><u>Settings</u> Not reported</p>	<p><u>Date restrictions</u> Inception to November 15th, 2021</p> <p><u>Databases searched</u> PubMed Scopus Embase Web of Science Ovid-MEDLINE</p> <p><u>Language restrictions</u> No language restrictions</p> <p><u>Appraisal scale</u> JBI checklist for case reports JBI checklist for case series</p> <p><u>Appraisal rating</u> Acceptable quality if cases satisfied 5 appraisal items Acceptable quality (n=21)</p> <p><u>Review appraisal score</u> Scored 9 out of 11 on the JBI critical appraisal checklist for systematic reviews and research syntheses</p>	<p><u>Complications of nipple piercing</u> Bacterial infections</p> <p><u>Isolated bacteria genera</u> <i>Staphylococcus</i> (n=10) <i>Mycobacterium</i> – all non-tuberculous (n=9)</p> <p><u>Related infections</u> <i>M. fortuitum</i> (n=6) coagulase-negative <i>Staphylococcus</i> (n=8) <i>S. epidermidis</i> (n=4) <i>N. gonorrhoeae</i> (n=2) <i>S. aureus</i> (n=2) <i>S. agalactiae</i> (n=2) <i>P. acnes</i> (n=2)</p> <p>Found in only 1 patient each: <i>A. turicensis</i>, <i>G. terrae</i>, <i>P. melanogenica</i>, <i>P. intermedia</i>, <i>P. anaerobius</i>, <i>Nocardia sp.</i>, <i>M. chelonei</i>, <i>P. harei</i>, <i>M. abscessus</i>, <i>M. holsaticum</i>, <i>M. agri</i>, <i>M. brumae</i>, <i>Actinomyces</i>, <i>C. amycolatum</i>, <i>H. parainfluenzae</i>, group A beta-hemolytic <i>Streptococcus</i>, a “green microaerophilic <i>Streptococcus</i>”, a rare gram-positive coccus not otherwise specified</p> <p><u>Clinical Presentation</u> Breast fluid collection (n=22) Breast pain or tenderness (n=10) Breast swelling (n=9) Breast erythema (n=8) Granulomatous tissue (n=5)</p> <p>Found in only 1 patient each: Chest wall cellulitis, retro areolar cellulitis, dyspnoea and productive cough with bloody</p>

				sputum, hyperpigmentation, breast induration and endocarditis
<p>Hennequin-Hoenderdos et al. 2016</p> <p>The incidence of complications associated with lip and/or tongue piercings: a systematic review.</p> <p>https://doi.org/10.1111/j.1601-5037.2010.00504.x</p>	<p><u>Aim</u> To determine the incidence of complications associated with oral and/or perioral (lip and/or tongue) piercings</p> <p><u>Special procedure/s</u> Body piercing</p> <p><u>Punctured site</u> Tongue (14 studies, 451 participants) Lip (13 studies, 411 participants) Tongue and lip (3 studies, 40 participants)</p> <p><u>Practitioner</u> Unreported</p> <p><u>Participants</u> Adults and children Female (61%) 12-43 years old ($M = 22$) Ethnicity not reported</p> <p><u>Outcomes of interest</u> Gingival recessions Tooth injuries – chipped/cracked/broken teeth, tooth wear or fractures</p>	<p><u>Number of included studies</u> 15</p> <p><u>Study designs</u> Case control (n=7) Case series (n=8)</p> <p><u>Date period covered by primary studies</u> 2000-2012</p> <p><u>Time frame for reporting/experiencing adverse effects</u> Not reported</p> <p><u>Countries</u> Not reported</p> <p><u>Settings</u> Not reported</p>	<p><u>Date restrictions</u> Inception to January 2015</p> <p><u>Databases searched</u> PubMed Cochrane-CENTRAL Embase</p> <p><u>Language restrictions</u> Papers in English or Dutch</p> <p><u>Appraisal scale</u> Newcastle-Ottawa Scale for case control studies Institute of Health Economics checklist for case series</p> <p><u>Appraisal rating</u> Case series studies - Low risk of bias (n=1) - Moderate risk of bias (n=2) - High risk of bias (n=3) - Very high risk of bias (n=2)</p> <p>Case control studies - Low risk of bias (n=5) - Moderate risk of bias (n=2)</p> <p><u>Review appraisal score</u> Scored 8 out of 11 on the JBI critical appraisal checklist for systematic reviews and research syntheses</p>	<p><u>Complications for tongue piercing</u> <i>Incidence gingival recession</i> A total of 351 participants with tongue piercings included in the calculation. 147 participants had gingival recession (weighted mean average 41.8%). RR 2.77, 95% CI 1.99 to 3.85, p=0.00001, I²=14</p> <p><i>Incidence tooth injury</i> 426 participants with tongue piercings included in the calculation. 157 participants had tooth injuries (weighted mean average 36.8%) RR 2.44, 95% CI 1.35 to 4.41 p=0.003, I²=0</p> <p><u>Complications of lip piercings</u> <i>Incidence gingival recession</i> 411 participants with lip piercings included in the calculation. 177 participants had gingival recession (weighted mean average 43%). RR 4.14, 95% CI 1.54 to 11.13, p=0.005, I²=0.59</p> <p><i>Incidence tooth injury</i> 280 participants with lip piercings included in the calculation. 68 participants had tooth injuries (weighted mean average 24.3%) RR 1.33, 95% CI 0.74 to 2.41 p=0.34, I²=0</p> <p><u>Tongue & lip piercings</u> 40 participants, 15 had gingival recession (weighted mean average 37.5%)</p>
<p>Passos et al. 2022</p> <p>Oral manifestations arising from oral piercings: a systematic review and meta-analyses</p>	<p><u>Aim</u> To review the literature on the associations between the use of oral piercings and oral alterations, complications, or lesions</p>	<p><u>Number of included studies</u> 54</p> <p><u>Study designs</u></p>	<p><u>Date restrictions</u> Inception to January 2022</p> <p><u>Databases searched</u> PubMed Scopus</p>	<p><u>Complications</u> Pain (n=15) Infection (n=12) Swelling (n=11) Bleeding (n=10) Inflammation (n=9)</p>

<p>https://doi.org/10.1016/j.oooo.2022.04.051</p>	<p><u>Special procedure/s</u> Body piercing (54 studies)</p> <p><u>Punctured site</u> Tongue piercing (39 studies) Lip piercing (29 studies) Other locations (11 studies)</p> <p><u>Practitioner</u> Not reported</p> <p><u>Participants</u> 27,963 oral piercings Female (70%) Age not reported Ethnicity not reported</p> <p><u>Outcomes of interest</u> The occurrence of complications, lesions, or alterations - Complications (adornment aspiration, pain, swelling, oedema, bleeding, inflammation, infection, haematoma, scar, allergy, syncope, hospitalization, etc.) based on timetables (immediate, early: <6 months, late: >6months, or if time was not reported) - Oral lesions related to soft tissue and mucosa (fundamental lesions and pathology), periodontal and tooth damage related (tooth chipping and cracking) - Alterations (speech, mastication, deglutition and taste-related, saliva and galvanic current, temporomandibular disorders, soft plaque and calculus formation, and microbiology)</p>	<p>Cross sectional (n=36, of which 25 were prevalence studies) Case-control (n=14) Cohort study (n=3) Quasi-experimental study (n=1)</p> <p><u>Date period covered by primary studies</u> 2000-2021</p> <p><u>Time frame for reporting/experiencing adverse effects</u> Not reported (n=17) Immediate (n=11) < 6 months (n=3) > 6 months (n=7)</p> <p><u>Countries of interventions</u> Brazil (n=8) USA (n=5) Italy (n=5) Germany (n=4) Austria (n=4) Spain (n=4) Israel (n=3) Argentina (n=2) Belgium (n=2) Cuba (n=2) New Zealand (n=2) Australia (n=1) France (n=1) Greece (n=1) Mexico (n=1) Poland (n=1) Saudi Arabia (n=1) Slovenia (n=1) South Africa (n=1) Sweden (n=1) Switzerland (n=1) UK (n=1)</p>	<p>Embase Web of Science Cochrane Library Virtual health library Google scholar</p> <p><u>Language restrictions</u> No restrictions</p> <p><u>Appraisal scale</u> JBI checklists GRADE</p> <p><u>Appraisal rating</u> Good methodological quality (n=15) Overall certainty of evidence was very low for all reported outcomes</p> <p><u>Review appraisal score</u> Scored 11 out of 11 on the JBI critical appraisal checklist for systematic reviews and research syntheses</p>	<p>Allergy (n=6) Adornment aspiration (n=5) Other complications (n=8) grouped as problems related to wound healing, oedema, difficulty breathing, scarring, tearing of skin, headache, syncope and hospitalisation</p> <p><u>Alterations</u> Speech (n=18) Mastication, deglutition or taste (n=16) Soft plaque or calculus formation (n=13) Changes in saliva (n=11) Galvanic current (n=2) Microbiologic alterations (n=2) TMJ dysfunction (n=1)</p> <p><u>Lesions</u> Soft tissue or mucosal injury (n=13 studies):</p> <ul style="list-style-type: none"> • Fibrous hyperplasia (n=8) • Mucosal atrophy (n=6) • Macules, ulcers, papules, nodules and bruises (n=4) • Lesions on the hard palate (n=2) • Lichenoid reaction (n=1) <p>Periodontal issues (n=38 studies):</p> <ul style="list-style-type: none"> • Gingival recession (n=27) • Gingival injury (n=4) • Periodontitis (n=3) • Gingivitis (n=3) • Dental mobility (n=3) • Bleeding on probing, clinical attachment loss, and probing depth (n=8) <p>Teeth damage (n=37 studies):</p> <ul style="list-style-type: none"> • Tooth fracture (n=19) • Tooth chipping (n=12) • Dental hypersensitivity (n=5) • Nonspecific dental injuries (n=5) • Enamel abrasion or abnormal tooth wear (n=4) <p><u>ERs of gingival recession</u></p>
--	--	---	--	--

		Ukraine (n=1) Venezuela (n=1) <u>Settings</u> Not reported	33% (ER 0.329; 95% CI: 0.247 to 0.424; $I^2 = 87.9\%$) <u>ERs of dental alterations</u> <i>Dental damage (type of lesion not reported)</i> 27% (ER 0.270; 95% CI: 0.074 to 0.630; $I^2 = 99.1\%$) <i>Tooth chipping or enamel infraction</i> 22% (ER 0.219; 95% CI: 0.113 to 0.381; $I^2 = 86.6\%$) <i>Wear or abrasion</i> 34% (ER 0.344; 95% CI: 0.183 to 0.553; $I^2 = 69.8\%$) <i>Fracture</i> 34% (ER 0.338; 95% CI: 0.248 to 0.440; $I^2 = 86.5\%$) <u>Association between piercings and gingival recession</u> The odds of having gingival recession among individuals with piercings increased approximately 7 times in contrast to the odds among participants without piercings (OR 7.085; 95% CI: 4.252 to 11.805; $p < 0.001$; $I^2 = 45.8\%$) <u>Association between piercings and dental alterations</u> <i>No evidence was found for an association between the presence of tooth chipping or enamel infraction and use of piercing</i> (OR 2.2234; 95% CI 0.737 to 6.775, $p = 0.156$; $I^2 = 0\%$) <i>The odds of dental fracture in participants with piercing increased more than 3 times in contrast to the odds among individuals without piercing</i> (OR 3.293; 95% CI: 1.868 to 5.807; $p < 0.001$; $I^2 = 38.5\%$)
--	--	---	---

				Subgroup analyses showed that the results were not influenced by the anatomic location of the piercings
<p>Sindoni et al. 2022</p> <p>Health risks for body pierced community: a systematic review.</p> <p>https://doi.org/10.1016/j.puhe.2022.01.035</p>	<p><u>Aim</u> To examine the literature on body piercing complications to provide a comprehensive overview of the available scientific evidence to help increase public awareness and to plan and implement effective prevention measures</p> <p><u>Special procedure/s</u> Body piercing (n=84)</p> <p><u>Punctured site</u> Ear piercing (n=22) Tongue piercing (n=15) Oral piercing (n=15) Not reported (n=13) Nipple piercing (n=7) Lip and tongue (n=6) Lip piercing (n=2) Nose piercing (n=1) Genital piercing (n=1) Navel piercing (n=1)</p> <p><u>Practitioner</u> Not reported</p> <p><u>Participants</u> Participant characteristics not summarised</p> <p><u>Outcomes of interest</u> Adverse health outcomes as a result of body piercings - Microbiological adverse effects - Non-microbiological adverse effects</p>	<p><u>Number of included studies</u> 84</p> <p><u>Study designs</u> Case report (n=45) Cross sectional (n=28) Case series (n=3) Case-control (n=2) Cohort study (n=2) Descriptive study (n=1) Randomised clinical trial (n=1) Before-after design (n=1) Case report in cross sectional (n=1)</p> <p><u>Date period covered by primary studies</u> 1973-2020</p> <p><u>Time frame for reporting/experiencing adverse effects</u> Microbiological adverse effects: 43/53 studies reported diverse time frames: Up to 1 month (n=19) 1-6 months (n=13) 6-12 months (3) After 1 year (n=8 – latest recorded – 1 study: 8 years) Not reported (n=10)</p> <p>Non-microbiological adverse effects 6/11 studies reported: <1 year (n=1)</p>	<p><u>Date restrictions</u> Inception to April 2020</p> <p><u>Databases searched</u> PubMed Scopus Web of Science</p> <p><u>Language restrictions</u> English language</p> <p><u>Appraisal scale</u></p> <ul style="list-style-type: none"> • JBI checklist for case reports • National Institute of Health Study Quality Assessment Tools for case series • NewCastle-Ottawa Scale for cross-sectional studies, cohort studies and case-control studies • Jadad Scale for RCTs <p><u>Appraisal rating</u> Low risk of bias (n=36) Fair quality (n=18) Poor quality (n=13) High risk of bias (n=7) Good quality (n=6) Moderate risk of bias (n=4)</p> <p><u>Review appraisal score</u> Scored 9 out of 11 on the JBI critical appraisal checklist for systematic reviews and research syntheses.</p>	<p><u>Microbiological adverse effects (53 studies)</u> <i>Infections identified</i> Mastitis, endocarditis, glomerulonephritis, cephalic tetanus, viral hepatitis, herpes simplex hepatitis, cerebellar brain abscess and toxic shock syndrome</p> <p><i>Organisms identified as causative agents</i> <i>Streptococci and Staphylococci</i> Also, rarer agents including <i>Prevotella melanogenica</i>, <i>Mycobacterium fortuitum</i>, <i>Clostridium tetani</i>, <i>Pseudomonas aeruginosa</i>, <i>Haemophilus para-influenzae</i>, <i>Haemophilus aphrophilus</i>, <i>Neisseria gonorrhoeae</i>, <i>Neisseria mucosa</i>, <i>Mycobacterium tuberculosis causing tubercular verrucosa cutis</i>, <i>Mycobacterium abscessus</i>, <i>Candida dublinensis</i> and <i>Gordonia terrae</i></p> <p><u>Non-microbiological adverse effects (11 studies)</u> Bleeding, gingival recession, dental injuries, contact dermatitis, nickel sensitisation, granulomatous dermatitis and keloid formation or keloid development alone. Rare case of basal cell carcinoma Demineralized enamel, chronic generalised gingivitis and fibroma</p> <p><u>Microbiological and non-microbiological adverse effects (20 studies)</u> Bleeding, pain, deformity, swelling, oedema, fever and headache</p> <p>Local inflammation/irritation, acne, mucosal atrophy, skin tearing, lymphadenopathy and swollen glands were also all reported</p> <p>Adverse effects also included nipple ring ripped out, granulomatous perichondritis, rejection,</p>

		<p>>1 year (n=5 – latest recorded 1 study: 10 years) Not reported (n=5)</p> <p>Studies reporting both microbiological & non-microbiological adverse effects 8/20 studies reported <1 year (n=3) >1 year (n=5) Not reported (n=12)</p> <p><u>Countries</u> USA (n=33) UK (n=6) Australia (n=5) Canada (n=5) Israel (n=4) Italy (n=4) Belgium (n=3) Brazil (n=3) Germany (n=3) Spain (n=2) France (n=2) Greece (n=1) Ireland (n=1) Kenya (n=1) The Netherlands (n=1) Pakistan (n=1) South Africa (n=1) Sudan (n=1) Turkey (n=1) Slovenia (n=1)</p> <p><u>Settings</u> Not reported</p>		<p>discharge, embedded earring, enamel abrasions and enamel fractures.</p> <p><i>Sensitisation phenomena</i> Itching, allergy, contact eczema and atopic dermatitis</p> <p><i>Head and neck region</i> Dental damage, dentine hypersensitivity, gingival recession, tongue fissure, erythematous palatal mucosa, increased salivation, halitosis, metallic taste and split tongue</p> <p><i>Skin disorders</i> Cyst, scarification/keloid formation and tumours</p>
--	--	---	--	---

Key: CI: confidence intervals, ER: Event rate; OR: odds ratio; RR: relative risk

Table 14. Summary of included umbrella reviews – Acupuncture

Citation	Review details Participants Outcomes of interest	Characteristics of included primary studies	Details of search Quality of the primary research Quality of the review	Findings
<p>Xu et al. 2023</p> <p>Adverse effects associated with acupuncture therapies: Evidence mapping from 535 systematic reviews.</p> <p>https://doi.org/10.1186/s13020-023-00743-7</p>	<p><u>Aim</u> To systematically analyse acupuncture-related adverse events</p> <p><u>Special procedure/s</u> Acupuncture: Electroacupuncture (n = 67) Manual acupuncture (n = 47) Acupoint catgut embedding (n = 41) Dry needling therapy (n = 39) Auricular acupuncture (n = 22) Acupoint injection (n = 14) Scalp acupuncture (n = 9) Bee venom acupuncture (n = 1) Fire needling therapy (n = 9) Battlefield acupuncture (n = 5) Ear acupuncture (n = 5) Filiform acupuncture (n = 2) Wrist-ankle acupuncture (n = 3) Laser acupuncture (n = 2) Warm needling therapy (n = 2) Body acupuncture (n = 1) Abdominal acupuncture (n = 1) Eye acupuncture (n = 1) Excluded studies with no penetration into the skin</p> <p><u>Punctured site</u> See “Special procedure/s” subsection</p> <p><u>Reason for acupuncture</u> 23 different ICD-11 disease types</p> <p><u>Practitioner</u> NR</p>	<p><u>Number of included reviews</u> 535</p> <p><u>Study designs</u> SRs and meta-analyses</p> <p><u>Date period covered by included SRs</u> 1999-2022</p> <p><u>Countries of origin of SRs</u> 18 countries, with China having the largest number (n=336), followed by South Korea (n=90) and the United States (n=30)</p> <p><u>Settings</u> NR</p>	<p><u>Date restrictions</u> up to 15th June 2022</p> <p><u>Databases searched</u> PubMed Embase Web of Science Cochrane Library Epistemonikos</p> <p><u>Language restrictions</u> English</p> <p><u>Appraisal scale</u> AMSTAR-2</p> <p><u>Appraisal rating</u> Low quality: 106 SRs Critically low quality: 379 SRs Free of critical flaws: 22 SRs</p> <p><u>Review appraisal score</u> Scored 11 out of 11 on the JBI critical appraisal checklist for systematic reviews and research syntheses</p>	<p>Acupuncture-related adverse events were classified as:</p> <ul style="list-style-type: none"> • syncope (86 SRs) • organ or tissue injury (233 SRs) • systemic reactions (113 SRs) • infection (19 SRs) • and other adverse events (373 SRs) <p>The most common adverse reactions were:</p> <ul style="list-style-type: none"> • pain (144 SRs) • bleeding/bruising (120 SRs) • dizziness (86 SRs) • haematoma (70 SRs) • digestive system symptoms (46 SRs) <p>Only a few included studies reported adverse effects due to acupuncture therapists</p> <p><u>Evidence of a positive effect</u> 50 SRs with statistically significant acupuncture-related adverse effects, ranging from high to critically low-quality</p> <p><u>Evidence of a negative effect</u> Among the acupuncture-related adverse events, 76 were found to have no statistical difference when acupuncture alone or combined with other interventions was compared with other interventions. There was no significant difference in the adverse effects described in 44 studies that were rated as high quality (n = 11), moderate quality (n = 10) and low quality (n = 23)</p> <p><u>Evidence of unclear effects</u> More than 90 percent of the adverse reactions were only qualitatively described, and no statistical difference was reported</p> <p><u>Syncope</u> Reported in 86 SRs. May be attributed to excessive stress and fear of acupuncture in patients, especially those new to</p>

	<p><u>Participants</u> Both healthy people and people with various diseases. Includes 23 disease types classified by ICD-11</p> <p><u>Outcomes of interest</u> Any adverse reactions associated with acupuncture. 119 SRs were statistically analysed for adverse events, 176 SRs reported the occurrence of no adverse events, 120 SRs reported no specific adverse reaction type, 89 SRs showed that none of the included original studies reported adverse reactions, and 260 SRs reported different adverse reactions</p>		<p>acupuncture, frail, seriously ill, with excessive blood loss, with a history of dizziness from acupuncture, or in an improper posture</p> <p><u>Organ or tissue injury</u> Reported in 233 SRs, including:</p> <ul style="list-style-type: none"> • pain (144 SRs) • bleeding or bruising (120 SRs) • haematoma (70 SRs) • headache (27 SRs) • pruritus (23 SRs) • erythema (19 SRs) • neuromuscular disease (16 SRs) • aggravation of symptoms (14 SRs) • skin allergy reaction (14 SRs) • minor swelling (13 SRs) • numbness (13 SRs) • induration (11 SRs) • palpitations (10 SRs) • menoxenia (5 SRs) • mild oedema (3 SRs) • blisters (3 SRs) • motor disorders (2 SRs) <p>No serious adverse events were associated with the acupuncture treatments</p> <p><u>Systemic reactions</u> Reported in 113 SRs, including:</p> <ul style="list-style-type: none"> • digestive system symptoms such as nausea/vomiting, loss of appetite, dry mouth, constipation, diarrhoea, dyspepsia and heartburn (46 SRs) • tiredness (40 SRs) • discomforts (31 SRs), • psychological disorder (30 SRs) • fevers (10 SRs) • heat/sweating (8 SRs) <p><u>Infection</u> Reported in 19 studies Infections were mainly due to unsterilized needles, repeated use of needles, or contact with clothing at the needlepoint. All patients recovered after appropriate treatment. The rate of infections related to acupuncture is thought to have been</p>
--	---	--	---

				<p>decreasing in recent years due to the rise of health consciousness and disinfection.</p> <p><u>Other adverse events</u> 373 articles reported adverse reactions that were neither due to trauma nor infection, such as needle sticking, broken needle, and bent needle. 176 studies did not report any acupuncture-related adverse events, 120 studies did not specify which adverse events were involved, and 89 studies stated that no adverse events were reported in the original study</p> <p><u>Key findings</u> 53 studies reported that acupuncture adverse events were associated with the practitioners</p> <p>Severe needle-related adverse reactions were rare, with the incidence of adverse events ranging from 6.71% to 8.6%, and the incidence of serious adverse events was about 0.001%.</p>
<p>Yang et al. 2015</p> <p>Efficacy and safety of acupuncture in children: an overview of systematic reviews.</p> <p>https://doi.org/10.1038/pr.2015.91</p>	<p><u>Aim</u> To update the evidence for the efficacy and safety of acupuncture for children</p> <p><u>Special procedure/s</u> Acupuncture, unspecified Needle acupuncture Tongue acupuncture Scalp acupuncture Laser acupuncture Heat-producing needling Warm acupuncture</p> <p><u>Punctured site</u> NR</p> <p><u>Reason for acupuncture</u> Nocturnal enuresis (n=2) Autism spectrum disorder (n=2) Cerebral palsy (n=1) Asthma (n=1)</p> <p><u>Practitioner</u> NR</p>	<p><u>Number of included reviews</u> 24 reviews</p> <p><u>Study designs</u> SRs</p> <p><u>Date period covered by SRs reporting on AEs</u> 2010-2013</p> <p><u>Countries of origin of SRs</u> China (n=5) Korea (n=1)</p> <p><u>Settings</u> Unclear</p>	<p><u>Date restrictions</u> Up to 2014</p> <p><u>Databases searched</u> Cochrane Library PubMed EMBASE Chinese Biomedical Literature Database, China National Knowledge Infrastructure Chinese Science and Technique Journals Database Wanfang Data</p> <p><u>Language restrictions</u> English and Chinese</p> <p><u>Appraisal scale</u> AMSTAR</p> <p><u>Appraisal rating</u></p>	<p>Only six reviews reported AEs but none from the western countries</p> <p>Lee 2012 (Korea): 27.3% (3/11) of included studies mentioned AEs. One RCT reported no adverse events, while two RCTs reported minor side effects (minor superficial bleeding, crying), the frequency of AEs was unclear Relevance between AEs and acupuncture – Unclear</p> <p>Cheuk 2013 (China): Worsening of sleeping pattern (n = 1), superficial bleeding, crying due to fear or pain, the frequency of other AEs was unclear. Relevance between AEs and acupuncture – Unclear</p> <p>Wei 2013 (China): Painful bi-auricular stimulation (n = 3), eczema (n = 2), mild pain, heat or swelling while pressing, the frequency of other AEs was unclear Relevance between AEs and acupuncture – Unclear</p> <p>Zhang 2010 (China): Reported AEs, but the specific AEs were unclear Relevance between AEs and acupuncture – No relevance</p>

	<p><u>Participants</u> Children aged up to 18yrs</p> <p><u>Outcomes of interest</u> Any adverse reactions associated with acupuncture</p>		<p>2 good quality 4 moderate quality</p> <p><u>Review appraisal score</u> Scored 10 out of 11 on the JBI critical appraisal checklist for systematic reviews and research syntheses</p>	<p>Zhang 2012 (China): Reported AEs, but the specific AEs were unclear. <u>Only included laser acupuncture and so is not relevant to the review.</u> Relevance between AEs and acupuncture – No relevance</p> <p>Huang 2011 (China): One trial report stated that there were no adverse effects and the remainder did not mention them. Relevance between AEs and acupuncture – Unclear Some important data about the occurrence time, management of AEs, and the definite relationship between AEs and acupuncture was inadequately reported In general, acupuncture was well tolerated and no fatal side effects were reported</p>
--	---	--	---	--

Key: AE: adverse events; SR: systematic review; NR: not reported

Table 15. Summary of included primary research – Electrolysis

Citation	Study details Quality ratings	Participants Setting Time frame of reporting or experiencing adverse effects	Findings
<p>Morand et al. 2015</p> <p>Systemic sarcoidosis revealed by axillary electrolysis</p> <p>https://doi.org/10.1177/1203475415575016</p>	<p><u>Study design</u> Case report</p> <p><u>Outcome/s of interest</u> Cutaneous sarcoidosis</p> <p><u>Comparator intervention or control</u> NA</p> <p><u>Data collection methods</u> Clinical examination</p> <p><u>Country</u> Canada</p> <p><u>Quality rating</u> Scored 6 out of 8 on the JBI critical appraisal checklist for case reports</p>	<p><u>Sample size</u> 1</p> <p><u>Participants</u> 35-year-old woman</p> <p><u>Setting</u> NR</p> <p><u>Practitioner</u> NR</p> <p><u>Time frame</u> NA</p>	<p>The patient received electrolysis for many years and developed lesions distributed symmetrically bilaterally after her last treatment. On physical examination, follicular brownish papules were noted. The diagnosis of cutaneous sarcoidosis was suggested by the clinical manifestations and confirmed by histopathologic findings. This case report suggests that sarcoidosis can arise from skin that has received electrolysis hair removal treatments.</p>

Key: NA: not applicable; NR: not reported

6.3 Quality appraisal

Table 16. JBI critical appraisal scores of systematic reviews

Study	JBI Appraisal items											Score	Overall quality ⁶	
	1	2	3	4	5	6	7	8	9	10	11			
Tattooing														
Sindoni et al. 2021	Y	Y	Y	Y	Y	Y	U	Y	N	Y	n/a	8	+ Moderate	
Body piercing														
Acuña-Chavez et al. 2022	Y	Y	Y	Y	Y	U	Y	Y	N	Y	Y	9	+ Moderate	
Hennequin-Hoenderdos et al. 2016	Y	Y	Y	Y	Y	Y	Y	N	N	Y	N	8	- Low	
Passos et al. 2022	Y	Y	Y	Y	Y	Y	Y	Y	Y	Y	Y	11	++ High	
Sindoni et al. 2022	Y	Y	Y	Y	Y	Y	U	Y	N	Y	Y	9	+ Moderate	
Acupuncture														
Yang et al. 2015	Y	Y	Y	Y	Y	Y	Y	Y	Y	N	Y	10	++ High	
Xu et al. 2023	Y	Y	Y	Y	Y	Y	Y	Y	Y	Y	Y	11	++ High	

Key: Y – Yes; N – No; U – Unclear; n/a – not applicable

1. Is the review question clearly and explicitly stated?
2. Were the inclusion criteria appropriate for the review question?
3. **Was the search strategy appropriate?**
4. **Were the sources and resources used to search for studies adequate?**
5. **Were the criteria for appraising studies appropriate?**
6. Was critical appraisal conducted by two or more reviewers independently?
7. Were there methods to minimize errors in data extraction?
8. **Were the methods used to combine studies appropriate?**
9. Was the likelihood of publication bias assessed?
10. Were recommendations for policy and/or practice supported by the reported data?
11. Were the specific directives for new research appropriate?

⁶ Overall quality was assessed on four critical domains which relate to Q3, Q4, Q5 and Q8 (see section 5.5) which have been highlighted in red above.

Table 17. JBI critical appraisal scores for case reports

Study	JBI Appraisal items								Score
	1	2	3	4	5	6	7	8	
Semi-permanent make-up									
Abtahi-Naeini 2019	Y	Y	Y	Y	Y	Y	N	Y	7
Akoh 2021	Y	Y	Y	Y	Y	Y	Y	Y	8
Bashinskaya 2022	Y	Y	Y	Y	N	N	N	Y	5
Bombonato 2015	Y	N	Y	Y	N	N	N	Y	4
Castañó-Fernández 2023	Y	Y	Y	Y	N	N	N	Y	5
Ebrahimiadib 2021	Y	Y	Y	Y	Y	Y	N	Y	7
Gilhooley 2020	Y	Y	Y	Y	Y	Y	Y	Y	8
Goldberg 2018	Y	Y	Y	Y	Y	Y	Y	Y	8
Hinojosa 2017	Y	Y	Y	Y	Y	Y	Y	Y	8
Hirai 2022	Y	Y	Y	Y	Y	Y	N	Y	7
Huisman 2019	Y	Y	Y	Y	Y	Y	N	Y	7
Ibraheim 2023	Y	Y	Y	Y	Y	Y	N	Y	7
Iwayama 2017	Y	Y	Y	Y	Y	Y	N	Y	7
Lahouel 2022	Y	Y	Y	Y	Y	Y	N	Y	7
Leight-Dunn 2022	Y	Y	Y	Y	Y	Y	Y	Y	8
Maier 2015	Y	Y	Y	Y	Y	Y	N	Y	7
Marcelino 2021	Y	Y	Y	Y	Y	Y	N	Y	7
Mirzaei 2017	Y	Y	Y	Y	Y	Y	Y	Y	8
Motoki 2020	Y	Y	Y	Y	Y	Y	N	Y	7
Naeini 2017	Y	Y	Y	Y	Y	Y	N	Y	7
Navarro-Triviño 2021	Y	Y	Y	Y	Y	Y	N	Y	7
Nie 2022	Y	Y	Y	Y	Y	Y	N	Y	7
Sano 2022	Y	Y	Y	Y	Y	N	N	Y	6
Soltany 2023	Y	Y	Y	Y	Y	Y	Y	Y	8
Suleman 2023	Y	Y	Y	Y	Y	Y	N	Y	7
Sun 2023	Y	Y	Y	Y	Y	Y	Y	Y	8
Tierney 2021	Y	Y	Y	Y	Y	N	N	Y	6
Tittelbach 2018	Y	Y	Y	Y	Y	Y	N	Y	7
Tukenmez Demirci 2016	Y	Y	Y	Y	Y	Y	N	Y	7
Valbuena 2017	Y	Y	Y	Y	Y	N	N	Y	6
Vera 2018	Y	Y	Y	Y	Y	N	N	N	5
Electrolysis									
Morand et al. 2015	Y	N	Y	Y	Y	Y	N	Y	6

Key: Y – Yes; N – No; U – Unclear; n/a – not applicable

1. Were patient's demographic characteristics clearly described?
2. Was the patient's history clearly described and presented as a timeline?
3. Was the current clinical condition of the patient on presentation clearly described?
4. Were diagnostic tests or assessment methods and the results clearly described?
5. Was the intervention(s) or treatment procedure(s) clearly described?
6. Was the post-intervention clinical condition clearly described?
7. Were adverse events (harms) or unanticipated events identified and described?
8. Does the case report provide takeaway lessons?

6.4 Information available on request

The protocol is available on request.

7. ADDITIONAL INFORMATION

7.1 Conflicts of interest

The authors declare they have no conflicts of interest to report.

7.2 Acknowledgements

The authors would like to thank Sarah Jones, Sally Anstey and Nathan Davies for their contributions during stakeholder meetings in guiding the focus of the review. We would also like thank Nia Davies and Isobel Davies for their contributions to carrying out this review.

8. APPENDIX

APPENDIX 1: Glossary

Achromobacter turicensis: A species of bacteria found in the environment that can occasionally cause infections in humans, particularly in individuals with compromised immune systems.

Actinomyces: A genus of bacteria commonly found in the oral, gastrointestinal, and genital tracts, typically harmless but can cause infections, particularly actinomycosis, when invading deeper tissues.

Aggregatibacter aphrophilus (formerly ***Haemophilus aphrophilus***): Bacteria found in the oral cavity, typically harmless but can cause infections like endocarditis and brain abscesses.

Breast induration: Firmness or hardness in the breast tissue.

Candida dubliniensis: A yeast species that can cause fungal infections, particularly in individuals with weakened immune systems, often affecting the oral cavity.

Cellulitis: A bacterial skin infection marked by redness, swelling, and tenderness, often occurring due to bacteria entering through skin break.

Cephalic tetanus: A rare form of tetanus, a potentially life-threatening bacterial infection caused by *Clostridium tetani*.

Cerebellar brain abscess: A rare medical condition characterised by the formation of a pus-filled cavity (abscess) within the cerebellum, a region located at the back of the brain responsible for coordinating movements and maintaining balance.

Clostridium tetani: A bacterium responsible for causing tetanus, a serious bacterial infection affecting the nervous system.

Conjunctival injection: Redness or dilation of the blood vessels in the conjunctiva, which is the thin, transparent layer of tissue that covers the white part of the eye (sclera) and lines the inside of the eyelid.

Corynebacterium amycolatum: A bacterium typically residing harmlessly on human skin and mucous membranes but which can cause infections in individuals with weakened immune systems.

Cutaneous diphtheria: A skin infection caused by the bacterium *Corynebacterium diphtheriae*.

Cutaneous lymphoid hyperplasia: A benign skin condition marked by increased lymphocytes, macrophages, and dendritic cells in the skin, resulting in raised skin lesions.

Dental mobility: Dental mobility refers to the ability of a tooth to move within its socket in the jawbone.

Dentine hypersensitivity: Tooth sensitivity that is characterised by brief, sharp pain triggered by various stimuli due to exposed dentine.

Dermatofibroma: A benign skin nodule or bump, often found on the limbs, that typically appears as a small, firm, reddish-brown or tan growth in the skin.

Dermatofibrosarcoma protuberans: A rare, slow growing and locally aggressive skin tumour.

Dyspepsia: Upset stomach.

Dyspnoea: Difficulty breathing.

Eczema: A common skin condition characterized by redness, itching, and inflammation of the skin.

Endocarditis: Inflammation of the heart's inner lining and valves.

Epithelioid osteoblastoma: A rare bone tumour.

Erythema: Redness of the skin, often caused by increased blood flow to the skin's blood vessels.

Erythematous palatal mucosa: Red or reddened appearance of the mucous membrane (soft tissue) on the palate, which is the roof of the mouth.

Fibroma: A benign (non-cancerous) tumour that originates from fibrous or connective tissue.

Fibrous hyperplasia: A benign overgrowth of fibrous tissue in the oral cavity.

Gingival recession: The condition in which the gum tissue around teeth recedes or pulls back, exposing more of the tooth's root,

Gingivitis: Gingivitis is the mildest and earliest form of gum disease (periodontal disease), characterised by inflammation of the gums (gingiva).

Glomerulonephritis: A group of kidney diseases characterised by inflammation and damage to the glomeruli, the tiny filtering units in the kidneys.

Gordonia terrae: A bacterium commonly found in soil, occasionally causing infections in individuals with a compromised immune system.

Granulomatous dermatitis: Inflammation of the skin characterized by the formation of granulomas.

Granulomatous perichondritis: Inflammation and granuloma formation in the tissue surrounding cartilage, often affecting the ears or nose, leading to symptoms like pain, swelling, and deformity.

Granulomatous tissue: Tissue reaction involving the formation of organised clusters of immune cells, called granulomas, in response to infections, foreign substances, or inflammatory conditions.

Haemangioma: A noncancerous tumour of blood vessels.

Haematoma: A localized collection of blood outside blood vessels, typically caused by injury or bleeding,

Haemophilus parainfluenzae: A bacterium found in human respiratory and oral cavities, usually harmless but can cause infections, especially in immunocompromised individuals.

Halitosis: Persistent and unpleasant bad breath

Hepatitis: Inflammation of the liver, which can be caused by infections, toxins, or autoimmune reactions.

Herpes simplex hepatitis: A rare and serious condition in which the herpes simplex virus infects and causes inflammation in the liver

Hyperpigmentation: Darkening of the skin due to excess melanin.

Induration: Refers to the process of hardening or thickening of a tissue or organ.

Keloid formation: The creation of raised, enlarged scars called keloids, often resulting from excessive collagen production during the healing process.

Keratoacanthoma: A benign, rapidly growing skin tumour that typically appears as a dome-shaped nodule with a central crater or horn in the middle.

Koebnerization (Koebner Phenomenon): Skin conditions developing or worsening in areas of skin subjected to injury or trauma.

Leiomyosarcoma: A tumour of smooth muscle cells.

Lichenoid reaction: A skin condition characterized by the appearance of lichen planus-like eruptions on the tattooed area.

Löfgren's syndrome: A specific acute form of sarcoidosis characterized by symptoms such as fever, joint pain, erythema nodosum (painful skin nodules), and bilateral hilar lymphadenopathy (enlarged lymph nodes in the chest), typically with a good prognosis.

Lymphadenopathy: The enlargement or swelling of lymph nodes

Mastitis: Inflammation of the breast tissue, often caused by bacterial infection, which can result in pain, redness, swelling, and other symptoms

Menoxenia: An abnormal or irregular menstrual cycle.

Molluscum contagiosum: Viral skin infection with small, flesh-coloured bumps.

Monkeypox (Mpox) infection: A rare viral disease similar to smallpox, transmitted from animals to humans, causing fever and skin rash.

Mucosal atrophy: Thinning, weakening, or shrinking of the mucous membrane lining in a body organ or cavity.

***Mycobacterium chelonae* Infection:** A specific type of bacterial infection caused by the bacterium *Mycobacterium chelonae*.

Necrotising fasciitis: A severe bacterial infection causing rapid tissue death.

***Neisseria gonorrhoeae*:** A bacterium responsible for the sexually transmitted infection (STI) known as gonorrhoea.

***Neisseria mucosa*:** A bacterium commonly found in the upper respiratory tract and mucous membranes of the human body.

***Nocardia* species:** A diverse group of bacteria belonging to the *Nocardia* genus found in the environment and capable of causing infections, particularly in those with weakened immune systems.

Nodular dermal lymphohistiocytic infiltration: Abnormal accumulation of immune cells in the dermal layer of the skin.

Non-tuberculous *Mycobacterial* infections: An infection caused by mycobacteria other than *Mycobacterium tuberculosis*, which can affect various body systems, including the lungs, skin, and soft tissues.

Oedema: Abnormal accumulation of excess fluid within the body's tissue.

Oral Galvanism: The phenomenon in the mouth where dissimilar dental materials create an electrical circuit, causing symptoms like pain, metallic taste, sensitivity, and gum irritation.

Orbital cellulitis: A serious medical condition characterised by a bacterial infection and inflammation of the tissues within the eye socket (orbit).

Papulo-nodular reactions: Refer to skin changes characterised by the development of small papules and nodules on the skin's surface.

Periodontitis: A severe form of gum disease (periodontal disease) characterised by inflammation and infection of the tissues supporting the teeth, including the gums, ligaments, and bone

Periorbital cellulitis: Infection and inflammation of the soft tissues in the eyelid and the skin around the eye.

***Prevotella*:** A genus of anaerobic bacteria commonly found in the human body, including the oral, gastrointestinal, and genital tracts, with the potential for causing infections.

Priapism: Painful, prolonged erection unrelated to sexual arousal, requiring immediate medical attention.

***Propionibacterium*:** A genus of bacteria often involving skin and soft tissues, including conditions like acne and surgical site infections.

Proptosis: Abnormal protrusion or bulging of an eyeball from its normal position within the eye socket (orbit).

Pruritus: Itching.

Pseudoepitheliomatous hyperplasia: Unusual proliferation of skin cells that mimics the appearance of squamous cell carcinoma.

***Pseudomonas aeruginosa*:** A pathogenic bacterium known for causing various infections in the body.

***Pyoderma gangrenosum*:** Rare skin condition characterized by painful, rapidly progressing ulcers, often associated with immune system abnormalities, not caused by infection.

Sarcoidosis: A multisystem inflammatory disorder characterised by the presence of granulomas in various organs and tissues throughout the body.

***Staphylococcus*:** A genus of bacteria that commonly inhabit the skin, mucous membranes, and respiratory and gastrointestinal tracts.

***Streptococcus*:** A diverse group of bacteria, some of which are part of the normal microbiota, while others can cause a wide range of infections.

Syncope: A sudden and temporary loss of consciousness and posture, usually caused by a temporary decrease in blood flow to the brain.

Temporomandibular joint dysfunction: A condition affecting the jaw joints and surrounding muscles, characterized by symptoms such as jaw pain, limited movement, clicking sounds, and muscle tension.

Tongue fissure: Grooves or furrows on the tongue's surface, typically harmless and benign.

Toxic shock syndrome: A rare and potentially life-threatening medical condition caused by the release of toxins, often associated with certain bacterial infections.

Uveitis: Inflammation of the uvea, the middle layer of the eye.

Vitiligo: A chronic skin disorder characterised by the loss of pigmentation in specific areas of the skin, resulting in white patches or depigmented spots due to the destruction of melanocytes, the cells responsible for skin colouration.

APPENDIX 2: Search Results

Q1a: Tattooing

Medline (Ovid) 01.08.2023

#	Query	Results from 1 Aug 2023
1	exp Tattooing/	4,103
2	(tattoo* or body ink or body art or hand poke or hand poking or stick-and-poke).tw.	5,924
3	(microblading or microstroking).tw.	19
4	(eyebrow* adj2 (embroid* or feather* or enhance*)).tw.	9
5	((permanent or semi-permanent) adj2 (makeup or make-up or cosmetic* or skin colo?ring or skin colo?ration)).tw.	151
6	micropigment*.tw.	57
7	dermal pigmentation.tw.	54
8	1 or 2 or 3 or 4 or 5 or 6 or 7	6,735
9	(ae or co or in or to or bl or mo).fs.	6,447,430
10	(adverse effect* or adverse event* or adverse outcome* or adverse reaction* or complication* or harm* or risk* or hazard* or safe* or side effect* or tolera* or toxic* or undesirable effect* or undesirable event* or unexpected effect* or unexpected event*).tw.	6,000,253
11	(injur* or infect* or allerg* or anaphylax* or contra* or sepsis or septi* or inflam* or bacteria* or microb* or hygien* or granulom* or xanthom* or lichenoid* or streptococci or staphylococci or pseudomonas or mycobacteri* or hepatitis* or tuberculosis or syphilis or HIV or bleeding or scar* or keloid* or cicatri* or fung* or viral*).tw.	7,603,873
12	exp Risk Assessment/	310,876
13	bacterial infections/	74,916
14	exp Sepsis/	141,719
15	exp Blood-Borne Infections/	427,194
16	exp Methicillin-Resistant Staphylococcus aureus/	19,621
17	Mycobacterium/ or Lichenoid Eruptions/ or Pseudomonas/ or Granuloma/ or Xanthomatosis/	65,704
18	Streptococcal infections/	35,044
19	Staphylococcal infections/ or Staphylococcal skin infections/	66,949
20	Hepatitis/ or exp hepatitis, viral, human/	170,647
21	Tuberculosis/ or tuberculosis, cutaneous/	115,504
22	Syphilis/ or Syphilis, Cutaneous/	24,240
23	exp HIV/	107,665
24	cicatrix/ or keloid/	29,650
25	9 or 10 or 11 or 12 or 13 or 14 or 15 or 16 or 17 or 18 or 19 or 20 or 21 or 22 or 23 or 24	15,083,997
26	exp "Systematic Review"/	234,581
27	exp Meta-Analysis/	184,981
28	exp Systematic Reviews as Topic/	11,052
29	exp Meta-Analysis as Topic/	27,353
30	(systematic review* or meta-analysis or review*).pt.	3,356,147
31	(systematic adj3 (review* or overview*)).ti,ab,kf.	312,677
32	(quantitative adj3 (review* or overview* or synthes*)).ti,ab,kf.	8,458
33	(meta-analy* or metaanaly* or meta-synthes#s or metasyntes#s).tw.	277,778
34	rapid review*.ti,ab,kf.	2,014

35	26 or 27 or 28 or 29 or 30 or 31 or 32 or 33 or 34	3,455,925
36	8 and 25 and 35	570
37	limit 36 to (english language and yr="2015 -Current")	236

EMBASE (Ovid) 01.08.2023

#	Query	Results from 1 Aug 2023
1	exp tattooing/	4,098
2	(tattoo* or body ink or body art or hand poke or hand poking or stick-and-poke).tw.	8,771
3	(microblading or microstroking).tw.	21
4	(eyebrow* adj2 (embroid* or feather* or enhance*)).tw.	11
5	((permanent or semi-permanent) adj2 (makeup or make-up or cosmetic* or skin colo?ring or skin colo?ration)).tw.	216
6	micropigment*.tw.	78
7	dermal pigmentation.tw.	91
8	1 or 2 or 3 or 4 or 5 or 6 or 7	9,898
9	(co or si).fs.	2,855,329
10	(adverse effect* or adverse event* or adverse outcome* or adverse reaction* or complication* or harm* or risk* or hazard* or safe* or side effect* or tolera* or toxic* or undesirable effect* or undesirable event* or unexpected effect* or unexpected event*).tw.	8,639,309
11	(injur* or infect* or allerg* or anaphylax* or contra* or sepsis or septi* or inflam* or bacteria* or microb* or hygien* or granulom* or xanthom* or lichenoid* or streptococci or staphylococci or pseudomonas or mycobacteri* or hepatitis* or tuberculosis or syphilis or HIV or bleeding or scar* or keloid* or cicatri* or fung* or viral*).tw.	10,136,128
12	exp risk assessment/	737,099
13	exp adverse event/	997,582
14	exp bacterial infection/	1,158,817
15	exp sepsis/	347,731
16	exp bloodstream infection/	18,583
17	exp methicillin resistant Staphylococcus aureus/	56,389
18	Mycobacterium/ or Lichenoid Eruption/ or Pseudomonas/ or Granuloma/ or Xanthomatosis/	115,389
19	Streptococcus infection/	27,728
20	Staphylococcus infection/	36,437
21	exp hepatitis/	384,417
22	tuberculosis/	174,710
23	cutaneous syphilis/ or syphilis/	44,997
24	exp Human immunodeficiency virus/	220,415
25	exp scar/	112,223
26	9 or 10 or 11 or 12 or 13 or 14 or 15 or 16 or 17 or 18 or 19 or 20 or 21 or 22 or 23 or 24 or 25	17,794,402
27	exp "systematic review"/	423,648
28	exp meta analysis/	288,337
29	(systematic review* or meta-analysis or review*).pt.	3,149,146
30	(systematic adj3 (review* or overview*)).ti,ab,kf.	381,465
31	(quantitative adj3 (review* or overview* or synthes*)).ti,ab,kf.	9,792
32	(meta-analy* or metaanaly* or meta-synthes#s or metasynthes#s).tw.	353,228
33	rapid review*.ti,ab,kf.	2,421
34	27 or 28 or 29 or 30 or 31 or 32 or 33	3,571,527

35	8 and 26 and 34	598
36	limit 35 to (english and yr="2015 -Current")	229
37	conference abstract.pt.	4,843,274
38	36 not 37	215

Ovid EMCARE 01.08.2023

#	Query	Results from 1 Aug 2023
1	exp tattooing/	584
2	(tattoo* or body ink or body art or hand poke or hand poking or stick-and-poke).tw.	1,825
3	(microblading or microstroking).tw.	7
4	(eyebrow* adj2 (embroid* or feather* or enhance*)).tw.	3
5	((permanent or semi-permanent) adj2 (makeup or make-up or cosmetic* or skin colo?ring or skin colo?ration)).tw.	36
6	micropigment*.tw.	12
7	dermal pigmentation.tw.	10
8	1 or 2 or 3 or 4 or 5 or 6 or 7	1,992
9	(adverse effect* or adverse event* or adverse outcome* or adverse reaction* or complication* or harm* or risk* or hazard* or safe* or side effect* or tolera* or toxic* or undesirable effect* or undesirable event* or unexpected effect* or unexpected event*).tw.	1,990,510
10	(injur* or infect* or allerg* or anaphylax* or contra* or sepsis or septi* or inflam* or bacteria* or microb* or hygien* or granulom* or xanthom* or lichenoid* or streptococci or staphylococci or pseudomonas or mycobacteri* or hepatitis* or tuberculosis or syphilis or HIV or bleeding or scar* or keloid* or cicatri* or fung* or viral*).tw.	1,732,403
11	exp risk assessment/	154,500
12	exp adverse event/	143,131
13	exp bacterial infection/	118,694
14	exp sepsis/	53,567
15	exp bloodstream infection/	2,787
16	exp methicillin resistant Staphylococcus aureus/	9,790
17	lichenoid eruption/ or pseudomonas/ or granuloma/ or xanthomatosis/	6,833
18	exp Streptococcus infection/	8,292
19	exp Staphylococcus infection/	7,487
20	exp hepatitis/	34,679
21	tuberculosis/	19,918
22	syphilis/	4,607
23	exp Human immunodeficiency virus/	55,245
24	exp scar/	16,613
25	9 or 10 or 11 or 12 or 13 or 14 or 15 or 16 or 17 or 18 or 19 or 20 or 21 or 22 or 23 or 24	3,237,987
26	exp "systematic review"/	120,894
27	exp meta analysis/	58,543
28	(systematic review* or meta-analysis or review*).pt.	845,073
29	(systematic adj3 (review* or overview*)).ti,ab,kf.	159,122
30	(quantitative adj3 (review* or overview* or synthes*)).ti,ab,kf.	4,273
31	(meta-analy* or metaanaly* or meta-synthes#s or metasynthes#s).tw.	122,834
32	rapid review*.ti,ab,kf.	1,222
33	26 or 27 or 28 or 29 or 30 or 31 or 32	968,082
34	8 and 25 and 33	176

35	limit 34 to (english language and yr="2015 -Current")	66
----	---	----

AMED (Ovid) 01.08.23

#	Query	Results from 1 Aug 2023
1	(tattoo* or body ink or body art or hand poke or hand poking or stick-and-poke).tw.	22
2	(microblading or microstroking).tw.	0
3	(eyebrow* adj2 (embroid* or feather* or enhance*)).tw.	0
4	((permanent or semi-permanent) adj2 (makeup or make-up or cosmetic* or skin colo?ring or skin colo?ration)).tw.	0
5	micropigment*.tw.	0
6	dermal pigmentation.tw.	0
7	1 or 2 or 3 or 4 or 5 or 6	22
8	exp Meta analysis/	424
9	(systematic review* or meta-analysis or review*).pt.	13,761
10	(systematic adj3 (review* or overview*)).tw.	7,122
11	(quantitative adj3 (review* or overview* or synthes*)).tw.	204
12	(meta-analy* or metaanaly* or meta-synthes#s or metasynthes#s).tw.	3,794
13	rapid review*.tw.	40
14	8 or 9 or 10 or 11 or 12 or 13	16,520
15	7 and 14	1
16	limit 15 to (english and yr="2015 -Current")	1

CINAHL (EBSCO) 01.08.2023

#	Query	Results from 1 Aug 2023
1	(MH "Tattooing")	1,357
2	TI (tattoo* or "body ink" or "body art" or "hand poke" or "hand poking" or stick-and-poke) OR AB (tattoo* or "body ink" or "body art" or "hand poke" or "hand poking" or stick-and-poke)	1,678
3	TI (microblading or microstroking) OR AB (microblading or microstroking)	9
4	TI (eyebrow* N2 (embroid* or feather* or enhance*) OR AB (eyebrow* N2 (embroid* or feather* or enhance*)	1
5	TI ((permanent or semi-permanent) N2 (makeup or make-up or cosmetic* or skin colo#ring or skin colo#ration)) OR AB ((permanent or semi-permanent) N2 (makeup or make-up or cosmetic* or skin colo#ring or skin colo#ration))	32
6	TI micropigment* OR AB micropigment*	12
7	TI "dermal pigmentation" OR AB "dermal pigmentation"	6
8	OR 1-7	2,042
9	MW ae or mo or rf or bl or co or pc	1,882,053
10	TI ("adverse effect*" or "adverse event*" or "adverse outcome*" or "adverse reaction*" or complication* or harm* or risk* or hazard* or safe* or "side effect*" or tolera* or toxic* or "undesirable effect*" or "undesirable event*" or "unexpected effect*" or "unexpected event*") OR AB ("adverse effect*" or "adverse event*" or "adverse outcome*" or "adverse reaction*" or complication* or harm* or risk* or hazard* or safe* or "side effect*" or tolera* or toxic* or "undesirable effect*" or "undesirable event*" or "unexpected effect*" or "unexpected event*")	1,558,106
11	TI (injur* or infect* or allerg* or anaphylax* or contra* or sepsis or septi* or inflam* or bacteria* or microb* or hygien* or granulom* or xanthom* or	1,211,678

	lichenoid* or streptococci or staphylococci or pseudomonas or mycobacteri* or hepatitis* or tuberculosis or syphilis or HIV or bleeding or scar* or keloid* or cicatri* or fung* or viral*) OR AB (injur* or infect* or allerg* or anaphylax* or contra* or sepsis or septi* or inflam* or bacteria* or microb* or hygien* or granulom* or xanthom* or lichenoid* or streptococci or staphylococci or pseudomonas or mycobacteri* or hepatitis* or tuberculosis or syphilis or HIV or bleeding or scar* or keloid* or cicatri* or fung* or viral*)	
12	(MH "Risk Assessment")	150,332
13	(MH "Bacterial Infections+")	133,935
14	(MH "Sepsis+")	31,807
15	(MH "Methicillin-Resistant Staphylococcus Aureus")	5,872
16	(MH "Mycobacterium+")	6,055
17	(MH "Lichenoid Eruptions+")	1,225
18	(MH "Pseudomonas Infections")	2,961
19	(MH "Granuloma")	3,391
20	(MH "Lipid Metabolism, Inborn Errors")	4,171
21	(MH "Streptococcal Infections+")	11,679
22	(MH "Hepatitis+")	31,212
23	(MH "Tuberculosis+")	25,755
24	(MH "Syphilis+")	4,757
25	(MH "Human Immunodeficiency Virus+")	11,209
26	(MH "Cicatrix+")	6,909
27	(MH "Keloid")	642
28	OR 9-27	3,321,671
29	(MH "Systematic Review")	122,674
30	(MH "Meta Analysis")	70,113
31	PT "systematic review*" or "meta-analysis" or review*	504,595
32	TI (systematic N3 (review* or overview*) OR AB (systematic N3 (review* or overview*)	151,714
33	TI (quantitative N3 (review* or overview* or synthes*)) OR AB (quantitative N3 (review* or overview* or synthes*)	3,871
34	TI (meta-analy* or metaanaly* or meta-synthes?s or metasyntes?s) OR AB (meta-analy* or metaanaly* or meta-synthes?s or metasyntes?s)	111,207
35	TI "rapid review*" OR AB "rapid review*"	939
36	OR 29-35	606,362
37	8 AND 28 AND 36 Limited 20150101 – 20230831; English Language	38

COCHRANE LIBRARY 01.08.2023

#	Query	Results from 1 Aug 2023
1	MeSH descriptor: [Tattooing] explode all trees	51
2	(tattoo* or "body ink" or "body art" or "hand poke" or "hand poking" or "stick and poke").ti,ab,kw	278
3	(microblading or microstroking).ti,ab,kw	3
4	(eyebrow* NEAR (embroid* or feather* or enhance*)).ti,ab,kw	7
5	((permanent or semi-permanent) NEAR (makeup or make-up or cosmetic* or "skin colouring" or "skin colouration").ti,ab,kw (word variations have been searched)	8
6	(micropigment*).ti,ab,kw	4
7	("dermal pigmentation").ti,ab,kw	5

8	OR 1-7	301 (296 trials, 5 reviews)
---	--------	-----------------------------

EPISTEMONIKOS 01.08.2023

#	Query	Results from 1 Aug 2023
1	(title:(tattoo* OR "body ink" OR "body art" OR "hand poke" OR "hand poking" OR "stick-and-poke" OR microblading OR microstroking) OR abstract:(tattoo* OR "body ink" OR "body art" OR "hand poke" OR "hand poking" OR "stick-and-poke" OR microblading OR microstroking))	607
2	(title:((eyebrow*) AND (embroid* OR feather* OR enhance*)) OR abstract:((eyebrow*) AND (embroid* OR feather* OR enhance*)))	8
3	(title:((permanent OR semi-permanent OR "semi permanent") AND (makeup OR make-up OR "make up" OR cosmetic* OR "skin colouring" OR "skin coloring" OR "skin colouration" OR "skin coloration")) OR abstract:((permanent OR semi-permanent OR "semi permanent") AND (makeup OR make-up OR "make up" OR cosmetic* OR "skin colouring" OR "skin coloring" OR "skin colouration" OR "skin coloration")))	177
4	(title:(micropigment* OR "dermal pigmentation") OR abstract:(micropigment* OR "dermal pigmentation"))	5
5	OR 1-5	790
6	5 Limited to Systematic Review and English Language	86

Total References Added to Endnote

Database	References
Medline (Ovid)	236
EMBASE (Ovid)	215
Ovid EMCARE	66
AMED (Ovid)	1
CINAHL (EBSCO)	38
Cochrane Library (Reviews)	5
Epistemonikos	86
TOTAL	647
Duplicates Identified in Endnote	231
New TOTAL	416

Q1b: Semi-permanent make-up

MEDLINE (Ovid) 05.09.2023

#	Query	Results from 5 Sep 2023
1	(microblading or microstroking).tw.	20
2	(eyebrow* adj2 (embroid* or feather* or enhance*)).tw.	9
3	((permanent or semi-permanent) adj2 (makeup or make-up or cosmetic* or skin colo?r* or skin tone* or stain* or dye* or pigment*)).tw.	682
4	micropigment*.tw.	58
5	dermal pigmentation.tw.	55
6	1 or 2 or 3 or 4 or 5	810
7	(ae or co or in or to or bl or mo).fs.	6,457,990
8	(adverse effect* or adverse event* or adverse outcome* or adverse reaction* or complication* or harm* or risk* or hazard* or safe* or side effect* or tolera* or toxic* or undesirable effect* or undesirable event* or unexpected effect* or unexpected event*).tw.	6,034,405

9	(injur* or infect* or allerg* or anaphylax* or contra* or sepsis or septi* or inflam* or bacteria* or microb* or hygien* or granulom* or xanthom* or lichenoid* or streptococci or staphylococci or pseudomonas or mycobacteri* or hepatitis* or tuberculosis or syphilis or HIV or bleeding or scar* or keloid* or cicatri* or queloide* fung* or viral*).tw.	7,517,991
10	exp Risk Assessment/	311,318
11	Bacterial Infections/	74,975
12	exp Sepsis/	142,109
13	exp Blood-Borne Infections/	427,901
14	exp Methicillin-Resistant Staphylococcus aureus/	19,746
15	Mycobacterium/ or Lichenoid Eruptions/ or Pseudomonas/ or Granuloma/ or Xanthomatosis/	65,772
16	Streptococcal infections/	35,069
17	Staphylococcal infections/ or Staphylococcal skin infections/	67,062
18	Hepatitis/ or exp hepatitis, viral, human/	170,871
19	Tuberculosis/ or tuberculosis, cutaneous/	115,689
20	Syphilis/ or Syphilis, Cutaneous/	24,266
21	exp HIV/	107,787
22	exp Cicatrix/	44,818
23	exp Keloid/	4,312
24	7 or 8 or 9 or 10 or 11 or 12 or 13 or 14 or 15 or 16 or 17 or 18 or 19 or 20 or 21 or 22 or 23	15,051,665
25	6 and 24	579
26	limit 25 to (english language and yr="2015 -Current")	213

EMBASE (Ovid) 05.09.2023

#	Query	Results from 5 Sep 2023
1	(microblading or microstroking).tw.	21
2	(eyebrow* adj2 (embroid* or feather* or enhance*)).tw.	12
3	((permanent or semi-permanent) adj2 (makeup or make-up or cosmetic* or skin colo?r* or skin tone* or stain* or dye* or pigment*)).tw.	841
4	micropigment*.tw.	77
5	dermal pigmentation.tw.	87
6	1 or 2 or 3 or 4 or 5	1,022
7	(co or si).fs.	2,720,379
8	(adverse effect* or adverse event* or adverse outcome* or adverse reaction* or complication* or harm* or risk* or hazard* or safe* or side effect* or tolera* or toxic* or undesirable effect* or undesirable event* or unexpected effect* or unexpected event*).tw.	8,462,140
9	(injur* or infect* or allerg* or anaphylax* or contra* or sepsis or septi* or inflam* or bacteria* or microb* or hygien* or granulom* or xanthom* or lichenoid* or streptococci or staphylococci or pseudomonas or mycobacteri* or hepatitis* or tuberculosis or syphilis or HIV or bleeding or scar* or keloid* or cicatri* or queloide* or fung* or viral*).tw.	9,597,434
10	exp risk assessment/	742,126
11	exp adverse event/	976,040
12	exp bacterial infection/	954,386
13	exp sepsis/	334,964
14	exp bloodstream infection/	18,706
15	exp methicillin resistant Staphylococcus aureus/	56,649
16	Mycobacterium/ or Lichenoid Eruption/ or Pseudomonas/ or Granuloma/ or Xanthomatosis/	92,430

17	Streptococcus infection/	22,312
18	Staphylococcus infection/	29,422
19	exp hepatitis/	359,026
20	tuberculosis/	129,803
21	cutaneous syphilis/ or syphilis/	29,537
22	exp Human immunodeficiency virus/	220,961
23	exp scar/	99,346
24	7 or 8 or 9 or 10 or 11 or 12 or 13 or 14 or 15 or 16 or 17 or 18 or 19 or 20 or 21 or 22 or 23	16,892,555
25	6 and 24	729
26	conference abstract.pt.	4,871,325
27	25 not 26	595
28	limit 27 to (english language and yr="2015 -Current")	214

Ovid EMCARE 05.09.2023

#	Query	Results from 5 Sep 2023
1	(microblading or microstroking).tw.	7
2	(eyebrow* adj2 (embroid* or feather* or enhance*)).tw.	3
3	((permanent or semi-permanent) adj2 (makeup or make-up or cosmetic* or skin colo?r* or skin tone* or stain* or dye* or pigment*)).tw.	111
4	micropigment*.tw.	12
5	dermal pigmentation.tw.	10
6	1 or 2 or 3 or 4 or 5	141
7	(adverse effect* or adverse event* or adverse outcome* or adverse reaction* or complication* or harm* or risk* or hazard* or safe* or side effect* or tolera* or toxic* or undesirable effect* or undesirable event* or unexpected effect* or unexpected event*).tw.	2,006,836
8	(injur* or infect* or allerg* or anaphylax* or contra* or sepsis or septi* or inflam* or bacteria* or microb* or hygien* or granulom* or xanthom* or lichenoid* or streptococci or staphylococci or pseudomonas or mycobacteri* or hepatitis* or tuberculosis or syphilis or HIV or bleeding or scar* or keloid* or cicatri* or queloide* or fung* or viral*).tw.	1,744,788
9	exp risk assessment/	155,005
10	exp adverse event/	143,308
11	exp bacterial infection/	118,866
12	exp sepsis/	53,602
13	exp bloodstream infection/	2,796
14	exp methicillin resistant Staphylococcus aureus/	9,798
15	lichenoid eruption/ or pseudomonas/ or granuloma/ or xanthomatosis/	6,840
16	exp Streptococcus infection/	8,294
17	exp Staphylococcus infection/	7,490
18	exp hepatitis/	34,728
19	tuberculosis/	19,967
20	syphilis/	4,622
21	exp Human immunodeficiency virus/	55,306
22	exp scar/	16,620
23	exp keloid/	1,055
24	7 or 8 or 9 or 10 or 11 or 12 or 13 or 14 or 15 or 16 or 17 or 18 or 19 or 20 or 21 or 22 or 23	3,261,810
25	6 and 24	108
26	limit 25 to (english language and yr="2015 -Current")	51

AMED (Ovid) 05.09.2023

#	Query	Results from 5 Sep 2023
1	(microblading or microstroking).tw.	0
2	(eyebrow* adj2 (embroid* or feather* or enhance*)).tw.	0
3	((permanent or semi-permanent) adj2 (makeup or make-up or cosmetic* or skin colo?r* or skin tone* or stain* or dye* or pigment*)).tw.	1
4	micropigment*.tw.	0
5	dermal pigmentation.tw.	0
6	1 or 2 or 3 or 4 or 5	1

CINAHL (EBSCO) 05.09.2023

#	Query	Results from 5 Sep 2023
1	TI (microblading or microstroking) OR AB (microblading or microstroking)	9
2	TI ((eyebrow* N2 (embroid* or feather* or enhance*)) OR AB ((eyebrow* N2 (embroid* or feather* or enhance*)))	1
3	TI ((permanent or semi-permanent) N2 (makeup or make-up or cosmetic* or skin colo?r* or skin tone* or stain* or dye* or pigment*)) OR AB ((permanent or semi-permanent) N2 (makeup or make-up or cosmetic* or skin colo?r* or skin tone* or stain* or dye* or pigment*))	92
4	TI micropigment* OR AB mocropigment*	13
5	TI "dermal pigmentation" OR AB "dermal pigmentation"	6
6	1 or 2 or 3 or 4 or 5	119
7	MW ae or mo or rf or bl or co or pc	1,829,897
8	TI ("adverse effect*" or "adverse event*" or "adverse outcome*" or "adverse reaction*" or complication* or harm* or risk* or hazard* or safe* or "side effect*" or tolera* or toxic* or "undesirable effect*" or "undesirable event*" or "unexpected effect*" or "unexpected event*") OR AB ("adverse effect*" or "adverse event*" or "adverse outcome*" or "adverse reaction*" or complication* or harm* or risk* or hazard* or safe* or "side effect*" or tolera* or toxic* or "undesirable effect*" or "undesirable event*" or "unexpected effect*" or "unexpected event*")	1,567,613
9	TI (injur* or infect* or allerg* or anaphylax* or contra* or sepsis or septi* or inflam* or bacteria* or microb* or hygien* or granulom* or xanthom* or lichenoid* or streptococci or staphylococci or pseudomonas or mycobacteri* or hepatitis* or tuberculosis or syphilis or HIV or bleeding or scar* or keloid* or cicatri* or queloide* or fung* or viral*) OR AB (injur* or infect* or allerg* or anaphylax* or contra* or sepsis or septi* or inflam* or bacteria* or microb* or hygien* or granulom* or xanthom* or lichenoid* or streptococci or staphylococci or pseudomonas or mycobacteri* or hepatitis* or tuberculosis or syphilis or HIV or bleeding or scar* or keloid* or cicatri* or queloide* or fung* or viral*)	1,218,441
10	(MH "Risk Assessment")	152,447
11	(MH "Bacterial Infections")	10,920
12	(MH "Sepsis")	19,450
13	(MH "Methicillin-Resistant Staphylococcus Aureus")	5,884
14	(MH "Lichenoid Eruptions")	360
15	(MH "Pseudomonas Infections")	2,968
16	(MH "Granuloma")	3,393
17	(MH "Lipid Metabolism, Inborn Errors")	4,179
18	(MH "Streptococcal Infections")	5,550
19	(MH "Hepatitis")	3,037

20	(MH "Tuberculosis")	17,561
21	(MH "Syphilis")	4,181
22	(MH "Human Immunodeficiency Virus")	5,680
23	(MH "Cicatrix+")	6,924
24	(MH "Keloid")	643
25	OR 7-24	3,318,333
26	6 AND 25	89
27	26 Limited to English Language and 2015 – 31082023	46

Total References Added to Endnote

Database	References
Medline (Ovid)	213
EMBASE (Ovid)	214
Ovid EMCARE	51
AMED (Ovid)	1
CINAHL (EBSCO)	46
TOTAL	525
Duplicates Identified in Endnote	251
New TOTAL	274

Q2: Body Piercing

Medline (Ovid) 02.08.2023

#	Query	Results from 2 Aug 2023
1	exp Body Piercing/	670
2	piercing*.tw.	3,163
3	1 or 2	3,291
4	(ae or co or in or to or bl or mo).fs.	6,447,679
5	(adverse effect* or adverse event* or adverse outcome* or adverse reaction* or complication* or harm* or risk* or hazard* or safe* or side effect* or tolera* or toxic* or undesirable effect* or undesirable event* or unexpected effect* or unexpected event*).tw.	6,001,307
6	(injur* or infect* or allerg* or anaphylax* or contra* or sepsis or septi* or inflam* or bacteria* or microb* or hygien* or granulom* or xanthom* or lichenoid* or streptococci or staphylococci or pseudomonas or mycobacteri* or hepatitis* or tuberculosis or syphilis or HIV or bleeding or scar* or keloid* or cicatri* or fung* or viral*).tw.	7,604,837
7	exp Risk Assessment/	310,881
8	bacterial infections/	74,918
9	exp Sepsis/	141,729
10	exp Blood-Borne Infections/	427,206
11	exp Methicillin-Resistant Staphylococcus aureus/	19,622
12	Mycobacterium/ or Lichenoid Eruptions/ or Pseudomonas/ or Granuloma/ or Xanthomatosis/	65,705
13	Streptococcal infections/	35,045
14	Staphylococcal infections/ or Staphylococcal skin infections/	66,951
15	Hepatitis/ or exp hepatitis, viral, human/	170,655
16	Tuberculosis/ or tuberculosis, cutaneous/	115,504
17	Syphilis/ or Syphilis, Cutaneous/	24,240
18	exp HIV/	107,668
19	cicatrix/ or keloid/	29,651

20	4 or 5 or 6 or 7 or 8 or 9 or 10 or 11 or 12 or 13 or 14 or 15 or 16 or 17 or 18 or 19	15,085,768
21	exp "Systematic Review"/	234,624
22	exp Meta-Analysis/	185,019
23	exp Systematic Reviews as Topic/	11,055
24	exp Meta-Analysis as Topic/	27,362
25	(systematic review* or meta-analysis or review*).pt.	3,356,535
26	(systematic adj3 (review* or overview*)).ti,ab,kf.	312,801
27	(quantitative adj3 (review* or overview* or synthes*)).ti,ab,kf.	8,459
28	(meta-analy* or metaanaly* or meta-synthes#s or metasyntes#s).tw.	277,879
29	rapid review*.ti,ab,kf.	2,015
30	21 or 22 or 23 or 24 or 25 or 26 or 27 or 28 or 29	3,456,366
31	3 and 20 and 30	291
32	limit 31 to (english language and yr="2015 -Current")	89

EMBASE (Ovid) 02.08.2023

#	Query	Results from 2 Aug 2023
1	exp Body Piercing/	1,247
2	piercing*.tw.	4,190
3	1 or 2	4,550
4	(co or si).fs.	2,855,329
5	(adverse effect* or adverse event* or adverse outcome* or adverse reaction* or complication* or harm* or risk* or hazard* or safe* or side effect* or tolera* or toxic* or undesirable effect* or undesirable event* or unexpected effect* or unexpected event*).tw.	8,641,323
6	(injur* or infect* or allerg* or anaphylax* or contra* or sepsis or septi* or inflam* or bacteria* or microb* or hygien* or granulom* or xanthom* or lichenoid* or streptococci or staphylococci or pseudomonas or mycobacteri* or hepatitis* or tuberculosis or syphilis or HIV or bleeding or scar* or keloid* or cicatri* or fung* or viral*).tw.	10,138,096
7	exp risk assessment/	737,370
8	exp adverse event/	997,723
9	exp bacterial infection/	1,158,933
10	exp sepsis/	347,774
11	exp bloodstream infection/	18,590
12	exp methicillin resistant Staphylococcus aureus/	56,403
13	Mycobacterium/ or Lichenoid Eruption/ or Pseudomonas/ or Granuloma/ or Xanthomatosis/	115,398
14	Streptococcus infection/	27,728
15	Staphylococcus infection/	36,437
16	exp hepatitis/	384,462
17	tuberculosis/	174,733
18	cutaneous syphilis/ or syphilis/	45,003
19	exp Human immunodeficiency virus/	220,438
20	exp scar/	112,238
21	4 or 5 or 6 or 7 or 8 or 9 or 10 or 11 or 12 or 13 or 14 or 15 or 16 or 17 or 18 or 19 or 20	17,797,748
22	exp "systematic review"/	423,942
23	exp meta analysis/	288,470
24	(systematic review* or meta-analysis or review*).pt.	3,149,857
25	(systematic adj3 (review* or overview*)).ti,ab,kf.	381,679
26	(quantitative adj3 (review* or overview* or synthes*)).ti,ab,kf.	9,795

27	(meta-analy* or metaanaly* or meta-synthes#s or metasyntes#s).tw.	353,404
28	rapid review*.ti,ab,kf.	2,422
29	22 or 23 or 24 or 25 or 26 or 27 or 28	3,572,430
30	3 and 21 and 29	310
31	limit 30 to (english and yr="2015 -Current")	97
32	conference abstract.pt.	4,843,274
33	31 not 32	89

Ovid EMCARE 02.08.2023

#	Query	Results from 2 Aug 2023
1	exp Body Piercing/	379
2	piercing*.tw.	1,073
3	1 or 2	1,138
4	(adverse effect* or adverse event* or adverse outcome* or adverse reaction* or complication* or harm* or risk* or hazard* or safe* or side effect* or tolera* or toxic* or undesirable effect* or undesirable event* or unexpected effect* or unexpected event*).tw.	1,990,510
5	(injur* or infect* or allerg* or anaphylax* or contra* or sepsis or septi* or inflam* or bacteria* or microb* or hygien* or granulom* or xanthom* or lichenoid* or streptococci or staphylococci or pseudomonas or mycobacteri* or hepatitis* or tuberculosis or syphilis or HIV or bleeding or scar* or keloid* or cicatri* or fung* or viral*).tw.	1,732,403
6	exp risk assessment/	154,500
7	exp adverse event/	143,131
8	exp bacterial infection/	118,694
9	exp sepsis/	53,567
10	exp bloodstream infection/	2,787
11	exp methicillin resistant Staphylococcus aureus/	9,790
12	lichenoid eruption/ or pseudomonas/ or granuloma/ or xanthomatosis/	6,833
13	exp Streptococcus infection/	8,292
14	exp Staphylococcus infection/	7,487
15	exp hepatitis/	34,679
16	tuberculosis/	19,918
17	syphilis/	4,607
18	exp Human immunodeficiency virus/	55,245
19	exp scar/	16,613
20	4 or 5 or 6 or 7 or 8 or 9 or 10 or 11 or 12 or 13 or 14 or 15 or 16 or 17 or 18 or 19	3,237,987
21	exp "systematic review"/	120,894
22	exp meta analysis/	58,543
23	(systematic review* or meta-analysis or review*).pt.	845,073
24	(systematic adj3 (review* or overview*)).ti,ab,kf.	159,122
25	(quantitative adj3 (review* or overview* or synthes*)).ti,ab,kf.	4,273
26	(meta-analy* or metaanaly* or meta-synthes#s or metasyntes#s).tw.	122,834
27	rapid review*.ti,ab,kf.	1,222
28	21 or 22 or 23 or 24 or 25 or 26 or 27	968,082
29	3 and 20 and 28	110
30	limit 29 to (english language and yr="2015 -Current")	31

AMED (Ovid) 02.08.2023

#	Query	Results from 2 Aug 2023
1	piercing*.tw.	20
2	exp Meta analysis/	424
3	(systematic review* or meta-analysis or review*).pt.	13,761
4	(systematic adj3 (review* or overview*)).tw.	7,122
5	(quantitative adj3 (review* or overview* or synthes*)).tw.	204
6	(meta-analy* or metaanaly* or meta-synthes#s or metasynthes#s).tw.	3,794
7	rapid review*.tw.	40
8	2 or 3 or 4 or 5 or 6 or 7	16,520
9	1 and 8	0

CINAHL (EBSCO) 02.08.2023

#	Query	Results from 2 Aug 2023
1	(MH "Body Piercing")	614
2	TI (piercing*) OR AB (piercing*)	929
3	1 OR 2	1,107
4	MW ae or mo or rf or bl or co or pc	1,882,322
5	TI ("adverse effect*" or "adverse event*" or "adverse outcome*" or "adverse reaction*" or complication* or harm* or risk* or hazard* or safe* or "side effect*" or tolera* or toxic* or "undesirable effect*" or "undesirable event*" or "unexpected effect*" or "unexpected event*") OR AB ("adverse effect*" or "adverse event*" or "adverse outcome*" or "adverse reaction*" or complication* or harm* or risk* or hazard* or safe* or "side effect*" or tolera* or toxic* or "undesirable effect*" or "undesirable event*" or "unexpected effect*" or "unexpected event*")	1,558,607
6	TI (injur* or infect* or allerg* or anaphylax* or contra* or sepsis or septi* or inflam* or bacteria* or microb* or hygien* or granulom* or xanthom* or lichenoid* or streptococci or staphylococci or pseudomonas or mycobacteri* or hepatitis* or tuberculosis or syphilis or HIV or bleeding or scar* or keloid* or cicatri* or fung* or viral*) OR AB (injur* or infect* or allerg* or anaphylax* or contra* or sepsis or septi* or inflam* or bacteria* or microb* or hygien* or granulom* or xanthom* or lichenoid* or streptococci or staphylococci or pseudomonas or mycobacteri* or hepatitis* or tuberculosis or syphilis or HIV or bleeding or scar* or keloid* or cicatri* or fung* or viral*)	1,212,013
7	(MH "Risk Assessment")	150,386
8	(MH "Bacterial Infections+")	133,954
9	(MH "Sepsis+")	31,812
10	(MH "Methicillin-Resistant Staphylococcus Aureus")	5,873
11	(MH "Mycobacterium+")	6,056
12	(MH "Lichenoid Eruptions+")	1,225
13	(MH "Pseudomonas Infections")	2,962
14	(MH "Granuloma")	3,391
15	(MH "Lipid Metabolism, Inborn Errors")	4,171
16	(MH "Streptococcal Infections+")	11,680
17	(MH "Hepatitis+")	31,215
18	(MH "Tuberculosis+")	25,756
19	(MH "Syphilis+")	4,757
20	(MH "Human Immunodeficiency Virus+")	11,210
21	(MH "Cicatrix+")	6,910

22	(MH "Keloid")	642
23	OR 4-22	3,322,503
24	(MH "Systematic Review")	122,723
25	(MH "Meta Analysis")	70,128
26	PT "systematic review*" or "meta-analysis" or review*	504,699
27	TI (systematic N3 (review* or overview*) OR AB (systematic N3 (review* or overview*)	151,788
28	TI (quantitative N3 (review* or overview* or syntheses*) OR AB (quantitative N3 (review* or overview* or syntheses*)	3,871
29	TI (meta-analy* or metaanaly* or meta-synthes?s or metasynthes?s) OR AB (meta-analy* or metaanaly* or meta-synthes?s or metasynthes?s)	111,261
30	TI "rapid review*" OR AB "rapid review*"	940
31	OR 24-30	606,510
32	3 AND 23 AND 31 Limited 20150101 – 20230831; English Language	22

COCHRANE LIBRARY 02.08.2023

#	Query	Results from 2 Aug 2023
1	MeSH descriptor: [Body Piercing] explode all trees	8
2	(piercing*).ti,ab,kw	144
3	1 OR 2	(144 trials, 5 reviews)

Total References Added to Endnote

Database	References
MEDLINE (Ovid)	89
EMBASE (Ovid)	89
Ovid EMCARE	31
AMED (Ovid)	0
CINAHL (EBSCO)	22
COCHRANE LIBRARY (Reviews)	5
Epistemonikos	34
TOTAL	270
Duplicates Identified in Endnote	113
New TOTAL	157

Q3: Acupuncture

MEDLINE (Ovid) 03.08.2023

#	Query	Results from 3 Aug 2023
1	Acupuncture/	2,036
2	exp Acupuncture Therapy/	29,161
3	Dry Needling/	340
4	(acupuncture or acupoint).tw.	28,748
5	(electroacupuncture or electro-acupuncture).tw.	6,718
6	moxibustion.tw.	3,570
7	(dry needling or intramuscular stimulation).tw.	972
8	or/1-7	39,017
9	(ae or co or in or to or bl or mo).fs.	6,446,639

10	(adverse effect* or adverse event* or adverse outcome* or adverse reaction* or complication* or harm* or risk* or hazard* or safe* or side effect* or tolera* or toxic* or undesirable effect* or undesirable event* or unexpected effect* or unexpected event*).tw.	5,999,798
11	(injur* or infect* or allerg* or anaphylax* or contra* or sepsis or septi* or inflam* or bacteria* or microb* or hygien* or granulom* or xanthom* or lichenoid* or streptococci or staphylococci or pseudomonas or mycobacteri* or hepatitis* or tuberculosis or syphilis or HIV or bleeding or scar* or keloid* or cicatri* or fung* or viral*).tw.	7,603,536
12	exp Risk Assessment/	310,842
13	bacterial infections/	74,912
14	exp Sepsis/	141,692
15	exp Blood-Borne Infections/	427,100
16	exp Methicillin-Resistant Staphylococcus aureus/	19,627
17	Mycobacterium/ or Lichenoid Eruptions/ or Pseudomonas/ or Granuloma/ or Xanthomatosis/	65,705
18	streptococcal infections/	35,042
19	staphylococcal infections/ or staphylococcal skin infections/	66,946
20	hepatitis/ or exp hepatitis, viral, human/	170,622
21	tuberculosis/ or tuberculosis, cutaneous/	115,494
22	Syphilis/ or Syphilis, Cutaneous/	24,239
23	exp HIV/	107,650
24	cicatrix/ or keloid/	29,644
25	or/9-24	15,083,129
26	8 and 25	17,461
27	umbrella review.ti,ab,kf.	1,472
28	evidence map*.ti,ab,kf.	545
29	((review or overview or synthesis) adj3 reviews).ti,ab,kf.	5,254
30	"review* of systematic review*".tw,pt,kf.	2,183
31	"overview* of systematic review*".tw,pt,kf.	1,085
32	(meta-analys#s adj3 overview*).ti.	143
33	or/27-32	7,974
34	26 and 33	143
35	limit 34 to (english language and yr="2015 -Current")	114

EMBASE (Ovid) 03.08.2023

#	Query	Results from 3 Aug 2023
1	exp acupuncture/	57,793
2	exp dry needling/	741
3	(acupuncture or acupoint).tw.	40,674
4	(electroacupuncture or electro-acupuncture).tw.	8,331
5	moxibustion.tw.	4,633
6	(dry needling or intramuscular stimulation).tw.	1,204
7	1 or 2 or 3 or 4 or 5 or 6	63,681
8	(co or si).fs.	2,855,329
9	(adverse effect* or adverse event* or adverse outcome* or adverse reaction* or complication* or harm* or risk* or hazard* or safe* or side effect* or tolera* or toxic* or undesirable effect* or undesirable event* or unexpected effect* or unexpected event*).tw.	8,644,273
10	(injur* or infect* or allerg* or anaphylax* or contra* or sepsis or septi* or inflam* or bacteria* or microb* or hygien* or granulom* or xanthom* or	10,140,641

	lichenoid* or streptococci or staphylococci or pseudomonas or mycobacteri* or hepatitis* or tuberculosis or syphilis or HIV or bleeding or scar* or keloid* or cicatri* or fung* or viral*).tw.	
11	exp risk assessment/	737,674
12	exp adverse event/	997,896
13	exp bacterial infection/	1,159,045
14	exp sepsis/	347,848
15	exp bloodstream infection/	18,593
16	exp methicillin resistant Staphylococcus aureus/	56,414
17	Mycobacterium/ or Lichenoid Eruption/ or Pseudomonas/ or Granuloma/ or Xanthomatosis/	115,417
18	Streptococcus infection/	27,728
19	Staphylococcus infection/	36,437
20	exp hepatitis/	384,510
21	tuberculosis/	174,750
22	cutaneous syphilis/ or syphilis/	45,004
23	exp Human immunodeficiency virus/	220,475
24	exp scar/	112,267
25	8 or 9 or 10 or 11 or 12 or 13 or 14 or 15 or 16 or 17 or 18 or 19 or 20 or 21 or 22 or 23 or 24	17,802,228
26	umbrella review.ti,ab,kf.	1,562
27	evidence map*.ti,ab,kf.	597
28	((review or overview or synthesis) adj3 reviews).ti,ab,kf.	6,131
29	"review* of systematic review*".tw,pt,kf.	2,522
30	"overview* of systematic review*".tw,pt,kf.	1,274
31	(meta-analys#s adj3 overview*).ti.	157
32	26 or 27 or 28 or 29 or 30 or 31	9,140
33	7 and 25 and 32	231
34	limit 33 to (english and yr="2015 -Current")	168

Ovid EMCARE 03.08.2023

#	Query	Results from 3 Aug 2023
1	exp acupuncture/	17,865
2	exp acupuncture point/	879
3	exp dry needling/	240
4	(acupuncture or acupoint).tw.	16,535
5	(electroacupuncture or electro-acupuncture).tw.	2,986
6	moxibustion.tw.	1,742
7	(dry needling or intramuscular stimulation).tw.	730
8	1 or 2 or 3 or 4 or 5 or 6 or 7	24,413
9	(adverse effect* or adverse event* or adverse outcome* or adverse reaction* or complication* or harm* or risk* or hazard* or safe* or side effect* or tolera* or toxic* or undesirable effect* or undesirable event* or unexpected effect* or unexpected event*).tw.	1,990,510
10	(injur* or infect* or allerg* or anaphylax* or contra* or sepsis or septi* or inflam* or bacteria* or microb* or hygien* or granulom* or xanthom* or lichenoid* or streptococci or staphylococci or pseudomonas or mycobacteri* or hepatitis* or tuberculosis or syphilis or HIV or bleeding or scar* or keloid* or cicatri* or fung* or viral*).tw.	1,732,403
11	exp risk assessment/	154,500
12	exp adverse event/	143,131

13	exp bacterial infection/	118,694
14	exp sepsis/	53,567
15	exp bloodstream infection/	2,787
16	exp methicillin resistant Staphylococcus aureus/	9,790
17	lichenoid eruption/ or pseudomonas/ or granuloma/ or xanthomatosis/	6,833
18	exp Streptococcus infection/	8,292
19	exp Staphylococcus infection/	7,487
20	exp hepatitis/	34,679
21	tuberculosis/	19,918
22	syphilis/	4,607
23	exp Human immunodeficiency virus/	55,245
24	exp scar/	16,613
25	9 or 10 or 11 or 12 or 13 or 14 or 15 or 16 or 17 or 18 or 19 or 20 or 21 or 22 or 23 or 24	3,237,987
26	umbrella review.ti,ab,kf.	790
27	evidence map*.ti,ab,kf.	277
28	((review or overview or synthesis) adj3 reviews).ti,ab,kf.	3,223
29	"review* of systematic review*".tw,pt,kf.	1,249
30	"overview* of systematic review*".tw,pt,kf.	647
31	(meta-analys#s adj3 overview*).ti.	61
32	26 or 27 or 28 or 29 or 30 or 31	4,601
33	8 and 25 and 32	112
34	limit 33 to (english language and yr="2015 -Current")	76

AMED (Ovid) 03.08.23

#	Query	Results from 3 Aug 2023
1	exp Acupuncture/	3,538
2	exp Acupuncture therapy/	9,383
3	(acupuncture or acupoint).tw.	11,301
4	(electroacupuncture or electro-acupuncture).tw.	1,430
5	moxibustion.tw.	878
6	(dry needling or intramuscular stimulation).tw.	229
7	1 or 2 or 3 or 4 or 5 or 6	12,819
8	(adverse effect* or adverse event* or adverse outcome* or adverse reaction* or complication* or harm* or risk* or hazard* or safe* or side effect* or tolera* or toxic* or undesirable effect* or undesirable event* or unexpected effect* or unexpected event*).tw.	55,239
9	(injur* or infect* or allerg* or anaphylax* or contra* or sepsis or septi* or inflam* or bacteria* or microb* or hygien* or granulom* or xanthom* or lichenoid* or streptococci or staphylococci or pseudomonas or mycobacteri* or hepatitis* or tuberculosis or syphilis or HIV or bleeding or scar* or keloid* or cicatri* or fung* or viral*).tw.	73,313
10	exp Adverse effects/	6,832
11	exp Bacterial infections/	1,552
12	exp Septicemia/	70
13	exp Streptococcal infections/	40
14	exp Hepatitis/	326
15	exp Tuberculosis/	231
16	exp Syphilis/	21
17	exp Hiv/	61
18	exp Cicatrix/	104

19	8 or 9 or 10 or 11 or 12 or 13 or 14 or 15 or 16 or 17 or 18	111,727
20	7 and 19	3,377
21	umbrella review.tw.	14
22	evidence map*.tw.	14
23	((review or overview or synthesis) adj3 reviews).tw.	219
24	"review* of systematic review*".tw.pt.	43
25	"overview* of systematic review*".tw.pt.	70
26	(meta-analys#s adj3 overview*).tw.	25
27	21 or 22 or 23 or 24 or 25 or 26	260
28	20 and 27	30
29	limit 28 to (english and yr="2015 -Current")	21

CINAHL (EBSCO) 03.08.2023

#	Query	Results from 3 Aug 2023
1	(MH "Acupuncture+")	19,864
2	(MH "Dry Needling")	496
3	TI(acupuncture or acupoint) OR AB (acupuncture or acupoint)	16,573
4	TI (electroacupuncture or electro-acupuncture) OR AB (electroacupuncture or electro-acupuncture)	2,155
5	TI (moxibustion) OR AB (moxibustion)	1,061
6	TI ("dry needling" or "intramuscular stimulation") OR AB ("dry needling" or "intramuscular stimulation")	836
7	OR 1-6	24,561
8	MW ae or mo or rf or bl or co or pc	1,882,502
9	TI ("adverse effect*" or "adverse event*" or "adverse outcome*" or "adverse reaction*" or complication* or harm* or risk* or hazard* or safe* or "side effect*" or tolera* or toxic* or "undesirable effect*" or "undesirable event*" or "unexpected effect*" or "unexpected event*") OR AB ("adverse effect*" or "adverse event*" or "adverse outcome*" or "adverse reaction*" or complication* or harm* or risk* or hazard* or safe* or "side effect*" or tolera* or toxic* or "undesirable effect*" or "undesirable event*" or "unexpected effect*" or "unexpected event*")	1,558,850
10	TI (injur* or infect* or allerg* or anaphylax* or contra* or sepsis or septi* or inflam* or bacteria* or microb* or hygien* or granulom* or xanthom* or lichenoid* or streptococci or staphylococci or pseudomonas or mycobacteri* or hepatitis* or tuberculosis or syphilis or HIV or bleeding or scar* or keloid* or cicatri* or fung* or viral*) OR AB (injur* or infect* or allerg* or anaphylax* or contra* or sepsis or septi* or inflam* or bacteria* or microb* or hygien* or granulom* or xanthom* or lichenoid* or streptococci or staphylococci or pseudomonas or mycobacteri* or hepatitis* or tuberculosis or syphilis or HIV or bleeding or scar* or keloid* or cicatri* or fung* or viral*)	1,212,013
11	(MH "Risk Assessment")	150,453
12	(MH "Bacterial Infections+")	133,958
13	(MH "Sepsis+")	31,812
14	(MH "Methicillin-Resistant Staphylococcus Aureus")	5,873
15	(MH "Mycobacterium+")	6,055
16	(MH "Lichenoid Eruptions+")	1,225
17	(MH "Pseudomonas Infections")	2,962
18	(MH "Granuloma")	3,391
19	(MH "Lipid Metabolism, Inborn Errors")	4,171
20	(MH "Streptococcal Infections+")	11,680

21	(MH "Hepatitis+")	31,215
22	(MH "Tuberculosis+")	25,757
23	(MH "Syphilis+")	4,757
24	(MH "Human Immunodeficiency Virus+")	11,210
25	(MH "Cicatrix+")	6,910
26	(MH "Keloid")	642
27	OR 8-26	3,322,503
28	TI "umbrella review" OR AB "umbrella review" OR PT "umbrella review"	656
29	TI "evidence map" OR AB "evidence map" OR PT "evidence map"	127
30	TI ((review or overview or synthesis) N3 reviews) OR AB ((review or overview or synthesis) N3 reviews) OR PT ((review or overview or synthesis) N3 reviews)	12,515
31	TI "review* of systematic review*" OR AB "review* of systematic review*"	935
32	TI "overview* of systematic review*" AND AB "overview* of systematic review*"	124
33	TI (meta-analys?s N3 overview*) OR AB (meta-analys?s N3 overview*)	147
34	OR 28-33	13,245
35	7 AND 27 AND 34 Limited 20150101 – 20230831; English Language	86

COCHRANE LIBRARY 03.08.2023

#	Query	Results from 3 Aug 2023
1	MeSH descriptor: [Acupuncture] explode all trees	713
2	MeSH descriptor: [Dry Needling] explode all trees	164
3	(acupuncture or acupoint):ti,ab,kw (Word variations have been searched)	20,929
4	(electroacupuncture or electro-acupuncture):ti,ab,kw (Word variations have been searched)	3,452
5	(moxibustion):ti,ab,kw (Word variations have been searched)	2,413
6	("dry needling" or "intramuscular stimulation"):ti,ab,kw (Word variations have been searched)	1,115
7	OR 1-6	23,624
8	(adverse NEAR (effect* OR event* OR outcome* OR reaction*)):ti,ab,kw (Word variations have been searched)	353,753
9	(undesirable NEAR (event* OR effect*)):ti,ab,kw (Word variations have been searched)	1,635
10	(unexpected NEAR (event* OR effect*)):ti,ab,kw (Word variations have been searched)	1,836
11	(complication* or harm* or risk* or hazard* or safe* or tolera* or toxic*):ti,ab,kw (Word variations have been searched)	807,238
12	((side NEAR effect*)):ti,ab,kw (Word variations have been searched)	161,989
13	(injur* or infect* or allerg* or anaphylax* or contra* or sepsis or septi* or inflam* or bacteria* or microb* or hygien* or granulom* or xanthom* or lichenoid* or streptococci or staphylococci or pseudomonas or mycobacteri* or hepatitis* or tuberculosis or syphilis or HIV or bleeding or scar* or keloid* or cicatri* or fung* or viral*):ti,ab,kw (Word variations have been searched)	536,215
14	MeSH descriptor: [Risk Assessment] explode all trees	13,627
15	MeSH descriptor: [Bacterial Infections] explode all trees	21,585
16	MeSH descriptor: [Sepsis] explode all trees	6,783
17	MeSH descriptor: [Blood-Borne Infections] explode all trees	23,057
18	MeSH descriptor: [Mycobacterium] explode all trees	816
19	MeSH descriptor: [Lichenoid Eruptions] explode all trees	388

20	MeSH descriptor: [Pseudomonas] explode all trees	712
21	MeSH descriptor: [Granuloma] explode all trees	172
22	MeSH descriptor: [Xanthomatosis] explode all trees	19
23	MeSH descriptor: [Streptococcal Infections] explode all trees	2,031
24	MeSH descriptor: [Staphylococcal Infections] explode all trees	1,434
25	MeSH descriptor: [Staphylococcal Skin Infections] explode all trees	281
26	MeSH descriptor: [Hepatitis] explode all trees	8,403
27	MeSH descriptor: [Tuberculosis] explode all trees	3,311
28	MeSH descriptor: [Syphilis] explode all trees	228
29	MeSH descriptor: [HIV] explode all trees	3,755
30	MeSH descriptor: [Cicatix] explode all trees	2,118
31	MeSH descriptor: [Keloid] explode all trees	224
32	OR 8-31	1,159,972
33	7 AND 32	9,133 (142 Cochrane reviews, 10 Protocols)
34	Limited to 2015-2023 & Overviews	2

*Did look through the 142 reviews – no other relevant overviews missed by the overview filter

*10 protocols not relevant

Epistemonikos 03.08.2023

#	Query	Results from 3 Aug 2023
1	(title:(acupuncture OR acupoint OR electroacupuncture OR electro-acupuncture OR moxibustion OR "dry needling" OR "intramuscular stimulation") OR abstract:(acupuncture OR acupoint OR electroacupuncture OR electro-acupuncture OR moxibustion OR "dry needling" OR "intramuscular stimulation"))	15,299
2	(title:("adverse effect*" OR "adverse event*" OR "adverse outcome*" OR "adverse reaction*" OR complication* OR harm* OR risk* OR hazard* OR safe* OR "side effect*" OR tolera* OR toxic* OR "undesirable effect*" OR "undesirable event*" OR "unexpected effect*" OR "unexpected event*" OR injur* OR infect* OR allerg* OR anaphylax* OR contra* OR sepsis OR septi* OR inflam* OR bacteria* OR microb* OR hygien* OR granulom* OR xanthom* OR lichenoid* OR streptococci OR staphylococci OR pseudomonas OR mycobacteri* OR hepatitis* OR tuberculosis OR syphilis OR HIV OR bleeding OR scar* OR keloid* OR cicatri* OR fung* OR viral*) OR abstract:("adverse effect*" OR "adverse event*" OR "adverse outcome*" OR "adverse reaction*" OR complication* OR harm* OR risk* OR hazard* OR safe* OR "side effect*" OR tolera* OR toxic* OR "undesirable effect*" OR "undesirable event*" OR "unexpected effect*" OR "unexpected event*" OR injur* OR infect* OR allerg* OR anaphylax* OR contra* OR sepsis OR septi* OR inflam* OR bacteria* OR microb* OR hygien* OR granulom* OR xanthom* OR lichenoid* OR streptococci OR staphylococci OR pseudomonas OR mycobacteri* OR hepatitis* OR syphilis OR HIV OR bleeding OR scar* OR keloid* OR cicatri* OR fung* OR viral*))	1,812,067
3	(title:("umbrella review" OR "evidence map" OR "review of systematic review" OR overview*) OR abstract:("umbrella review" OR "evidence map" OR "review of systematic review" OR overview*))	19,628
	1 AND 2 = 5,311 (1,921 SR's 2015-2023) and (64 Broad Synthesis / Overview of SR's 2015-2023)	
4	1 AND 2 AND 3	111
5	4 Limited to 2015-2023 Systematic Reviews	44

6	4 Limited to 2015-2023 Broad synthesis / Overview of systematic reviews	42
	Exported to ENDNOTE	86

* Publication Type: Systematic review did contain umbrella reviews and evidence maps so included all. Of the 111 studies – 88 were published between 2015 and 2023. 2 of these were primary studies so the remainder (86) exported to Endnote.

Total References Added to Endnote

Database	References
MEDLINE (Ovid)	114
EMBASE (Ovid)	168
Ovid EMCARE	76
AMED (Ovid)	21
CINAHL (EBSCO)	86
COCHRANE LIBRARY (Reviews)	2
Epistemonikos	86
TOTAL	553
Duplicates Identified in Endnote	301
New Total	252

Q4: Electrolysis

MEDLINE (Ovid) 07.08.2023

#	Query	Results from 7 Aug 2023
1	exp Hair Removal/	2,057
2	exp Electrolysis/	5,374
3	(electrolysis or electroepilat* or electro-epilat* or electrolytic-epilat* or electrolytic-depilat* or needle-epilat* or thermolysis or electrologist* or electrology or epilatt* or depilat*).tw.	10,915
4	(hair* or cosmet*).tw.	194,887
5	2 or 3	14,442
6	4 and 5	878
7	1 or 6	2,530
8	(ae or co or in or to or bl or mo).fs.	6,447,732
9	(adverse effect* or adverse event* or adverse outcome* or adverse reaction* or complication* or harm* or risk* or hazard* or safe* or side effect* or tolera* or toxic* or undesirable effect* or undesirable event* or unexpected effect* or unexpected event*).tw.	6,002,405
10	(injur* or infect* or allerg* or anaphylax* or contra* or sepsis or septi* or inflam* or bacteria* or microb* or hygien* or granulom* or xanthom* or lichenoid* or streptococci or staphylococci or pseudomonas or mycobacteri* or hepatitis* or tuberculosis or syphilis or HIV or bleeding or scar* or keloid* or cicatri* or fung* or viral*).tw.	7,605,996
11	exp Risk Assessment/	310,875
12	bacterial infections/	74,921
13	exp Sepsis/	141,721
14	exp Blood-Borne Infections/	427,191
15	exp Methicillin-Resistant Staphylococcus aureus/	19,636
16	Mycobacterium/ or Lichenoid Eruptions/ or Pseudomonas/ or Granuloma/ or Xanthomatosis/	65,710
17	streptococcal infections/	35,045

18	staphylococcal infections/ or staphylococcal skin infections/	66,955
19	hepatitis/ or exp hepatitis, viral, human/	170,637
20	tuberculosis/ or tuberculosis, cutaneous/	115,508
21	Syphilis/ or Syphilis, Cutaneous/	24,242
22	exp HIV/	107,674
23	cicatrix/ or keloid/	29,646
24	or/8-23	15,087,644
25	7 and 24	1,501
26	limit 25 to (english language and yr="2015 -Current")	412

EMBASE (Ovid) 07.08.2023

#	Query	Results from 7 Aug 2023
1	exp Hair Removal/	1,367
2	exp Electrolysis/	10,870
3	(electrolysis or electroepilat* or electro-epilat* or electrolytic-epilat* or electrolytic-depilat* or needle-epilat* or thermolysis or electrologist* or electrology or epilat* or depilat*).tw.	12,711
4	(hair* or cosmet*).tw.	261,206
5	2 or 3	18,060
6	4 and 5	1,534
7	1 or 6	2,649
8	(co or si).fs.	2,857,996
9	(adverse effect* or adverse event* or adverse outcome* or adverse reaction* or complication* or harm* or risk* or hazard* or safe* or side effect* or tolera* or toxic* or undesirable effect* or undesirable event* or unexpected effect* or unexpected event*).tw.	8,649,158
10	(injur* or infect* or allerg* or anaphylax* or contra* or sepsis or septi* or inflam* or bacteria* or microb* or hygien* or granulom* or xanthom* or lichenoid* or streptococci or staphylococci or pseudomonas or mycobacteri* or hepatitis* or tuberculosis or syphilis or HIV or bleeding or scar* or keloid* or cicatri* or fung* or viral*).tw.	10,145,598
11	exp risk assessment/	737,782
12	exp adverse event/	998,469
13	exp bacterial infection/	1,159,461
14	exp sepsis/	348,072
15	exp bloodstream infection/	18,600
16	exp methicillin resistant Staphylococcus aureus/	56,465
17	Mycobacterium/ or Lichenoid Eruption/ or Pseudomonas/ or Granuloma/ or Xanthomatosis/	115,462
18	Streptococcus infection/	27,734
19	Staphylococcus infection/	36,454
20	exp hepatitis/	384,785
21	tuberculosis/	174,787
22	cutaneous syphilis/ or syphilis/	45,020
23	exp Human immunodeficiency virus/	220,487
24	exp scar/	112,326
25	8 or 9 or 10 or 11 or 12 or 13 or 14 or 15 or 16 or 17 or 18 or 19 or 20 or 21 or 22 or 23 or 24	17,811,493
26	7 and 25	1,649
27	conference abstract.pt.	4,847,411
28	26 not 27	1,303

29	limit 28 to (english language and yr="2015 -Current")	708
----	---	------------

Ovid EMCARE 07.08.2023

#	Query	Results from 7 Aug 2023
1	exp Hair Removal/	136
2	exp Electrolysis/	627
3	(electrolysis or electroepilat* or electro-epilat* or electrolytic-epilat* or electrolytic-depilat* or needle-epilat* or thermolysis or electrologist* or electrology or epilata* or depilat*).tw.	767
4	(hair* or cosmet*).tw.	34,198
5	2 or 3	1,116
6	4 and 5	197
7	1 or 6	313
8	(adverse effect* or adverse event* or adverse outcome* or adverse reaction* or complication* or harm* or risk* or hazard* or safe* or side effect* or tolera* or toxic* or undesirable effect* or undesirable event* or unexpected effect* or unexpected event*).tw.	1,997,778
9	(injur* or infect* or allerg* or anaphylax* or contra* or sepsis or septi* or inflam* or bacteria* or microb* or hygien* or granulom* or xanthom* or lichenoid* or streptococci or staphylococci or pseudomonas or mycobacteri* or hepatitis* or tuberculosis or syphilis or HIV or bleeding or scar* or keloid* or cicatri* or fung* or viral*).tw.	1,737,739
10	exp risk assessment/	154,771
11	exp adverse event/	143,225
12	exp bacterial infection/	118,785
13	exp sepsis/	53,590
14	exp bloodstream infection/	2,789
15	exp methicillin resistant Staphylococcus aureus/	9,792
16	lichenoid eruption/ or pseudomonas/ or granuloma/ or xanthomatosis/	6,835
17	exp Streptococcus infection/	8,294
18	exp Staphylococcus infection/	7,489
19	exp hepatitis/	34,707
20	tuberculosis/	19,943
21	syphilis/	4,614
22	exp Human immunodeficiency virus/	55,283
23	exp scar/	16,619
24	10 or 11 or 12 or 13 or 14 or 15 or 16 or 17 or 18 or 19 or 20 or 21 or 22 or 23	528,450
25	7 and 24	42
26	limit 25 to (english language and yr="2015 -Current")	20

AMED (Ovid) 07.08.2023

#	Query	Results from 7 Aug 2023
1	(electrolysis or electroepilat* or electro-epilat* or electrolytic-epilat* or electrolytic-depilat* or needle-epilat* or thermolysis or electrologist* or electrology or epilata* or depilat*).tw.	26
2	(hair* or cosmet*).tw.	904
3	1 and 2	1
4	(adverse effect* or adverse event* or adverse outcome* or adverse reaction* or complication* or harm* or risk* or hazard* or safe* or side	55,239

	effect* or tolera* or toxic* or undesirable effect* or undesirable event* or unexpected effect* or unexpected event*).tw.	
5	(injur* or infect* or allerg* or anaphylax* or contra* or sepsis or septi* or inflam* or bacteria* or microb* or hygien* or granulom* or xanthom* or lichenoid* or streptococci or staphylococci or pseudomonas or mycobacteri* or hepatitis* or tuberculosis or syphilis or HIV or bleeding or scar* or keloid* or cicatri* or fung* or viral*).tw.	73,313
6	exp Adverse effects/	6,832
7	exp Bacterial infections/	1,552
8	exp Septicemia/	70
9	exp Streptococcal infections/	40
10	exp Hepatitis/	326
11	exp Tuberculosis/	231
12	exp Syphilis/	21
13	exp Hiv/	61
14	exp Cicatrix/	104
15	4 or 5 or 6 or 7 or 8 or 9 or 10 or 11 or 12 or 13 or 14	111,727
16	3 and 15	0

CINAHL (EBSCO) 07.08.2023

#	Query	Results from 3 Aug 2023
1	(MH "Hair Removal")	739
2	(MH "Electrolysis")	136
3	TI(electrolysis or electroepilat* or electro-epilat* or electrolytic-epilat* or electrolytic-depilat* or needle-epilat* or thermolysis or electrologist* or electrology or epil* or depilat*) OR AB (electrolysis or electroepilat* or electro-epilat* or electrolytic-epilat* or electrolytic-depilat* or needle-epilat* or thermolysis or electrologist* or electrology or epil* or depilat*)	274
4	TI (hair* or cosmet*) OR AB (hair* or cosmet*)	22,687
5	2 or 3	364
6	4 and 5	120
7	1 or 6	798
8	MW ae or mo or rf or bl or co or pc	1,823,131
9	TI ("adverse effect*" or "adverse event*" or "adverse outcome*" or "adverse reaction*" or complication* or harm* or risk* or hazard* or safe* or "side effect*" or tolera* or toxic* or "undesirable effect*" or "undesirable event*" or "unexpected effect*" or "unexpected event*") OR AB ("adverse effect*" or "adverse event*" or "adverse outcome*" or "adverse reaction*" or complication* or harm* or risk* or hazard* or safe* or "side effect*" or tolera* or toxic* or "undesirable effect*" or "undesirable event*" or "unexpected effect*" or "unexpected event*")	1,559,616
10	TI (injur* or infect* or allerg* or anaphylax* or contra* or sepsis or septi* or inflam* or bacteria* or microb* or hygien* or granulom* or xanthom* or lichenoid* or streptococci or staphylococci or pseudomonas or mycobacteri* or hepatitis* or tuberculosis or syphilis or HIV or bleeding or scar* or keloid* or cicatri* or fung* or viral*) OR AB (injur* or infect* or allerg* or anaphylax* or contra* or sepsis or septi* or inflam* or bacteria* or microb* or hygien* or granulom* or xanthom* or lichenoid* or streptococci or staphylococci or pseudomonas or mycobacteri* or hepatitis* or tuberculosis or syphilis or HIV or bleeding or scar* or keloid* or cicatri* or fung* or viral*)	1,212,586
11	(MH "Risk Assessment")	150,630
12	(MH "Bacterial Infections+")	133,984

13	(MH "Sepsis+")	31,818
14	(MH "Methicillin-Resistant Staphylococcus Aureus")	5,875
15	(MH "Mycobacterium+")	6,056
16	(MH "Lichenoid Eruptions+")	1,225
17	(MH "Pseudomonas Infections")	2,962
18	(MH "Granuloma")	3,391
19	(MH "Lipid Metabolism, Inborn Errors")	4,172
20	(MH "Streptococcal Infections+")	11,681
21	(MH "Hepatitis+")	31,223
22	(MH "Tuberculosis+")	25,760
23	(MH "Syphilis+")	4,762
24	(MH "Human Immunodeficiency Virus+")	11,212
25	(MH "Cicatrix+")	6,911
26	(MH "Keloid")	642
27	OR 8-26	3,324,304
28	7 AND 27 Limited 20150101 – 20230831; English Language	158

Total References Added to Endnote

Database	References
Medline (Ovid)	412
EMBASE (Ovid)	708
Ovid EMCARE	20
AMED (Ovid)	0
CINAHL (EBSCO)	158
TOTAL	1298
Duplicates Identified in Endnote	412
New TOTAL	886

APPENDIX 3: Websites searched for grey literature

Websites
Academy of Medical Sciences https://acmedsci.ac.uk/
American Academy of Allergy, Asthma & Immunology https://www.aaaai.org/
American Academy of Dermatology https://www.aad.org/
American College of Allergy, Asthma & Immunology https://acaai.org/
Association of Medical Microbiology and Infectious Disease Canada https://ammi.ca/en/
Australasian College of Dermatologists https://www.dermcoll.edu.au/
Australasian Society of Clinical Immunology and Allergy https://www.allergy.org.au/
Australian Medical Association https://www.ama.com.au/
British Association of Dermatologists https://www.bad.org.uk/
British HIV Association https://www.bhiva.org/
British Society for Haematology https://b-s-h.org.uk/
British Society for Immunology https://www.immunology.org/
Canadian Medical Association https://www.cma.ca/
Centers for Disease Control and Prevention https://www.cdc.gov/
European Academy of Allergy and Clinical Immunology https://eaaci.org/
European Centre for Disease Prevention and Control https://www.ecdc.europa.eu/
European Hematology Association https://ehaweb.org/
Health Education and Improvement Wales https://heiw.nhs.wales/
Health Education England https://www.hee.nhs.uk/
Infectious Diseases Society of America https://www.idsociety.org/
Medical Council of New Zealand https://www.mcnz.org.nz/
National Institute for Health and Care Excellence https://www.nice.org.uk/
New Zealand Dermatological Society https://www.nzdsi.org/
Royal Australasian College of Physicians https://www.racp.edu.au/
Royal College of General Practitioners https://www.rcgp.org.uk/
Royal College of Physicians https://www.rcplondon.ac.uk/
Royal College of Physicians and Surgeons of Canada https://www.royalcollege.ca/

Royal College of Physicians and Surgeons of Glasgow https://rcpsg.ac.uk/
Royal College of Physicians of Edinburgh https://www.rcpe.ac.uk/
Royal New Zealand College of General Practitioners https://www.rnzcgp.org.nz/
Royal Society for Public Health (RSPH) https://www.rsph.org.uk/
Royal Society of Medicine https://www.rsm.ac.uk
World Health Organisation www.who.int
Public Health Wales https://phw.nhs.wales/
UK Health Security Agency https://researchportal.ukhsa.gov.uk/
Office for Health Improvement & Disparities https://www.gov.uk/government/organisations/office-for-health-improvement-and-disparities Filtered for research
Public Health Scotland https://publichealthscotland.scot/
Public Health Northern Ireland https://www.publichealth.hscni.net/
US Food and Drug Administration (FDA) https://www.fda.gov/
Google Advanced Search https://www.google.co.uk/advanced_search
Association of Professional Piercers https://safepiercing.org/
The United Kingdom's Association Of Professional Piercers https://www.ukapp.org.uk/
Accreditation Commission for Acupuncture and Herbal Medicine https://acahm.org/
American Association of Acupuncture and Oriental Medicine https://www.aaaomonline.org/
British Acupuncture Council https://acupuncture.org.uk/
International Academy of Medical Acupuncture, Inc. https://iama.edu/
National Certification Commission for Acupuncture and Oriental Medicine https://www.nccaom.org/
Society for Acupuncture Research https://www.acupunctureresearch.org/

APPENDIX 4: Excluded studies

Table 18. Studies excluded at full-text screening

Full citation	Exclusion reason(s)
Q1a. Tattooing (n=21)	
Dieckmann R, Boone I, Brockmann SO, et al. (2016). The risk of bacterial infection after tattooing – A systematic review of the literature. <i>Deutsches Arzteblatt International</i> . 113(40): 665-71. https://dx.doi.org/10.3238/arztebl.2016.0665	No critical appraisal
Huisman S, van der Bent SAS, Maijer KI, et al. (2020). Cutaneous non-allergic complications in tattoos: An overview of the literature. <i>Presse Medicale</i> . 49(4): 104049. https://dx.doi.org/10.1016/j.lpm.2020.104049	Wrong study design (narrative review), <2 databases searched
Ibraheim MK, Desai M, Tawfik M, et al. (2023). microblading-induced granulomatous reaction: case report and review of the literature. <i>American Journal of Dermatopathology</i> . 45(7): 487-91. https://dx.doi.org/10.1097/DAD.0000000000002449	Wrong study design (narrative review), <2 databases searched
Khodadost M, Maajani K, Arabsalmani M, et al. (2017). Is tattooing a risk factor for hepatitis C transmission?: An updated systematic review and meta-analysis. <i>Hepatitis Monthly</i> . 17. https://dx.doi.org/10.5812/hepatmon.14308	No critical appraisal
Kiszla BM, Elmets CA, Mayo TT. (2023). Quantitative analysis of restricted metals and metalloids in tattoo inks: A systematic review and meta-analysis. <i>Chemosphere</i> . 313: 137291. https://dx.doi.org/10.1016/j.chemosphere.2022.137291	No critical appraisal
Kluger N, Andraud M, Lartigau-Roussin C, et al. (2021). The Koebner phenomenon on tattoos and piercings in a patient with cutaneous lupus: a case report and review of the literature. <i>Acta Dermatovenerologica Alpina, Panonica et Adriatica</i> . 30(1): 43-6.	Wrong study design (narrative review), <2 databases searched
Laux P, Tralau T, Tentschert J, et al. (2016). A medical-toxicological view of tattooing. <i>Lancet</i> . 387(10016): 395-402. https://dx.doi.org/10.1016/S0140-6736(15)60215-X	Wrong study design (narrative review), <2 databases searched
Lim SH, Lee S, Lee YB, et al. (2022). Increased prevalence of transfusion-transmitted diseases among people with tattoos: A systematic review and meta-analysis. <i>PLoS ONE</i> . 17. https://dx.doi.org/10.1371/journal.pone.0262990	Wrong outcome
Mudedla S, Avendano EE, Raman G. (2015). Non-tuberculous mycobacterium skin infections after tattooing in healthy individuals: a systematic review of case reports. <i>Dermatology Online Journal</i> . 21(6): 16.	No critical appraisal
Munoz-Ortiz J, Gomez-Lopez MT, Echeverry-Hernandez P, et al. (2021). Dermatological and ophthalmological inflammatory, infectious, and tumoral tattoo-related reactions: a systematic review. <i>Permanente Journal</i> . 25(5): 26. https://dx.doi.org/10.7812/TPP/20.225	No critical appraisal
Negi S, Bala L, Shukla S, et al. (2022). Tattoo inks are toxicological risks to human health: A systematic review of their ingredients, fate inside skin, toxicity due to polycyclic aromatic hydrocarbons, primary aromatic amines, metals, and overview of regulatory frameworks. <i>Toxicology & Industrial Health</i> . 38(7): 417-34. https://dx.doi.org/10.1177/07482337221100870	Wrong study design (narrative review)
Patel M, Cobbs CG. (2015). Infections from Body Piercing and Tattoos. <i>Microbiology Spectrum</i> . 3(6): 12. https://dx.doi.org/10.1128/microbiolspec.IOL5-0016-2015	Wrong study design (narrative review), <2 databases searched
Rahbarinejad Y, Guio-Aguilar P, Vu AN, et al. (2023). Pathogenesis, diagnosis and management of squamous cell carcinoma and pseudoepithelial hyperplasia secondary to red ink tattoo: a case series and Review. <i>Journal of Clinical Medicine</i> . 12(6): 21. https://dx.doi.org/10.3390/jcm12062424	Wrong study design (narrative review), <2 databases searched

Rello J, Tejada S, Campogiani L, et al. (2022). Systemic infections associated with tattoos or permanent makeup: A systematic review. <i>Medicina Clinica</i> . 158(4): 159-66. https://dx.doi.org/10.1016/j.medcli.2021.01.014	<2 databases searched, no critical appraisal
Ricci F, Fania L, Antonelli F, et al. (2022). Melanoma on tattoos: a case study and review of the literature. <i>European Journal of Dermatology</i> . 32(6): 703-8. https://dx.doi.org/10.1684/ejd.2022.4353	Wrong study design (narrative review), <2 databases searched
Thomas S, Gouk C, Jayasakeera N, et al. (2016). The Sequelae of Metallosis Resulting in Skin Pigmentation and Tattooing: A Case Presentation and Literature Review. <i>The Surgery Journal</i> . 2(4): e143-e6. https://dx.doi.org/10.1055/s-0036-1596060	Wrong study design (narrative review), no critical appraisal
Thum CK, Biswas A. (2015). Inflammatory complications related to tattooing: a histopathological approach based on pattern analysis. <i>American Journal of Dermatopathology</i> . 37(1): 54-66. https://dx.doi.org/10.1097/DAD.0b013e3182974558	Wrong study design (narrative review), <2 databases searched
Tran NT, Dubost C, Baggio S, et al. (2018). Safer tattooing interventions in prisons: a systematic review and call to action. <i>BMC Public Health</i> . 18(1): 1015. https://dx.doi.org/10.1186/s12889-018-5867-x	Wrong outcome
Van Bresse MF, Van Waerebeek K, Duignan PJ. (2022). tattoo skin disease in cetacea: a review, with new cases for the Northeast Pacific. <i>Animals</i> [Electronic Resource]. 12(24): 18. https://dx.doi.org/10.3390/ani12243581	Wrong population, wrong study design
Van Remoortel H, Moorkens D, Avau B, et al. (2019). Is there a risk of transfusion-transmissible infections after percutaneous needle treatments in blood donors? A systematic review and meta-analysis. <i>Vox Sanguinis</i> . 114(4): 297-309. https://dx.doi.org/10.1111/vox.12780	Wrong outcome
Weis KT, Schreiber I, Siewert K, et al. (2021). Tattoos – more than just colored skin? Searching for tattoo allergens. <i>Journal der Deutschen Dermatologischen Gesellschaft</i> . 19(5): 657-69. https://dx.doi.org/10.1111/ddg.14436	Wrong study design (narrative review), <2 databases searched
Q1b. Permanent make-up (n=22)	
Bruhn C. (2016). Ornaments with risks: Health risks due to tattoos, permanent make-up and tattoo removal. <i>Deutsche Apotheker Zeitung</i> . 156: 395-402	Foreign language
Daruwalla SB, Dhurat RS, Hamid SAT. (2022). All that a dermatotrichologist needs to know about hair camouflage: a comprehensive review. <i>International Journal of Trichology</i> . 14(3): 77-83. https://dx.doi.org/10.4103/ijt.ijt_6_21	Wrong outcome, wrong population
De Cuyper C. (2015). Complications of cosmetic tattoos. <i>Current Problems in Dermatology</i> . 48: 61-70. https://dx.doi.org/10.1159/000369188	Wrong publication type
De Cuyper C. (2020a). How to advise a patient who wants a tattoo? <i>Presse Medicale</i> . 49(4): 104048. https://dx.doi.org/10.1016/j.lpm.2020.104048	Wrong publication type
De Cuyper C. (2020b). Tattoo allergy. Can we identify the allergen? <i>Presse Medicale</i> . 49(4): 104047. https://dx.doi.org/10.1016/j.lpm.2020.104047	Wrong publication type
Dirks M. (2022). Formulation and production of tattoo ink stock products for cosmetic and medical applications: pigment raw materials, ingredients, auxiliary substances and contaminants. <i>Current Problems in Dermatology</i> . 56: 23-9. https://dx.doi.org/10.1159/000521863	Wrong publication type, not available
Giulbudagian M, Schreiber I, Singh AV, et al. (2020). Safety of tattoos and permanent make-up: a regulatory view. <i>Archives of Toxicology</i> . 94(2): 357-69. https://dx.doi.org/10.1007/s00204-020-02655-z	Wrong publication type
Hvas D, Serup J. (2022). Microblading technique for tattooing of "hairstrokes" that simulate natural hair: eyebrow tattooing and correction of medical conditions. <i>Current Problems in Dermatology</i> . 56: 141-54. https://dx.doi.org/10.1159/000529810	Wrong publication type, not available
Kluger N. (2019). An update on cutaneous complications of permanent tattooing. <i>Expert Review of Clinical Immunology</i> . 15(11): 1135-43. https://dx.doi.org/10.1080/1744666X.2020.1676732	Wrong intervention

Kluger N. (2022). delayed granulomatous reaction after eyebrow microblading. <i>Dermatologic Surgery</i> . 48(4): 472-3. https://dx.doi.org/10.1097/DSS.0000000000003361	Wrong publication type
Marwah MK, Kerure AS, Marwah GS. (2021). Microblading and the science behind it. <i>Indian Dermatology Online Journal</i> . 12(1): 6-11. https://dx.doi.org/10.4103/idoj.IDOJ_230_20	Wrong study design (unpicked narrative review)
Park JH, Ho YH, Manonukul K. (2022). Natural results of scalp micropigmentation: a review. <i>Journal of Cosmetic Dermatology</i> . 21(11): 5509-13. https://dx.doi.org/10.1111/jocd.15297	Wrong outcome, wrong study design
Portilla Maya N, Kempf W, Perez Munoz N, et al. (2021). Histopathologic spectrum of findings associated with tattoos: multicenter study series of 230 cases. <i>American Journal of Dermatopathology</i> . 43(8): 543-53. https://dx.doi.org/10.1097/DAD.0000000000001695	Wrong intervention
Rello J, Tejada S, Campogiani L, et al. (2022). Systemic infections associated with tattoos or permanent makeup: a systematic review. <i>Medicina Clinica</i> . 158(4): 159-66. https://dx.doi.org/10.1016/j.medcli.2021.01.014	Wrong study design (unpicked narrative review)
Schubert S, Kluger N, Schreiber I. (2023). Hypersensitivity to permanent tattoos: Literature summary and comprehensive review of patch tested tattoo patients 1997-2022. <i>Contact Dermatitis</i> . 88(5): 331-50. https://dx.doi.org/10.1111/cod.14291	Wrong study design (unpicked narrative review)
Serup J. (2022). Technical and Clinical Complications of Cosmetic Tattooing. <i>Current Problems in Dermatology</i> . 56: 225-44. https://dx.doi.org/10.1159/000526048	Wrong study design (unpicked narrative review)
Shaji M, Merin KA, Kameswaran R. (2022). A Review on Cosmetics Causing Contact Urticaria. <i>Indian Journal of Dermatology</i> . 67(4): 392-8. https://dx.doi.org/10.4103/ij.d.1090_20	Wrong intervention, wrong study design
Spurr A, Hanna N, Colantonio S. (2022). Cutaneous sarcoidosis in eyebrows cosmetically pigmented with microblading method: A case report and review of the literature. <i>SAGE Open Medical Case Reports</i> . 10: 2050313X221117720. https://dx.doi.org/10.1177/2050313X221117720	Wrong study design (unpicked narrative review)
Tomita S, Mori K, Yamazaki H, et al. (2021). Complications of permanent makeup procedures for the eyebrow and eyeliner. <i>Medicine</i> . 100(18): e25755. https://dx.doi.org/10.1097/MD.00000000000025755	Wrong setting
van der Bent SAS, Rauwerdink D, Oyen EMM, et al. (2021). Complications of tattoos and permanent makeup: overview and analysis of 308 cases. <i>Journal of Cosmetic Dermatology</i> . 20(11): 3630-41. https://dx.doi.org/10.1111/jocd.14498	Data pertaining to SPMU cannot be extracted
Verdier C. (2015). Surveillance of tattoo-related adverse events by the EU RAPEX system and by national monitoring. <i>Current Problems in Dermatology</i> . 48: 210-7. https://dx.doi.org/10.1159/000369230	Wrong publication type, wrong study design,
Verhulst L, Goossens A. (2016). Cosmetic components causing contact urticaria: a review and update. <i>Contact Dermatitis</i> . 75(6): 333-44. https://dx.doi.org/10.1111/cod.12679	Wrong intervention, wrong study design
Q2. Body piercing (n=11)	
Domian N, Kasacka I. (2017). Local and systemic disorders caused by the presence of foreign bodies in the oral cavity. <i>Dental and Medical Problems</i> . 54: 267-72. https://dx.doi.org/10.17219/dmp/75553	Wrong study design (narrative review), <2 databases searched, no critical appraisal
Kluger N, Andraud M, Lartigau-Roussin C, et al. (2021). The Koebner phenomenon on tattoos and piercings in a patient with cutaneous lupus: a case report and review of the literature. <i>Acta Dermatovenerologica Alpina, Panonica et Adriatica</i> . 30(1): 43-6.	Wrong study design (narrative review), <2 databases searched, no critical appraisal
Lee B, Vangipuram R, Peterson E, et al. (2018). Complications associated with intimate body piercings. <i>Dermatology Online Journal</i> . 24. https://pubmed.ncbi.nlm.nih.gov/30261561/	Wrong study design (narrative review), <2 databases searched, no critical appraisal

Mclsaac KE. (2016). Incorrect application of epidemiologic concepts in The Incidence of Complications associated with Lip and/or Tongue piercings: a systematic review. <i>International Journal of Dental Hygiene</i> . 14(1): 74-5. https://dx.doi.org/10.1111/idh.12180	Wrong publication type (letter to the editor)
Offen E, Allison JR. (2022). Do oral piercings cause problems in the mouth? <i>Evidence-Based Dentistry</i> . 23(3): 126-7. https://dx.doi.org/10.1038/s41432-022-0816-z	Wrong publication type (commentary)
Patel M, Cobbs CG. (2015). Infections from Body Piercing and Tattoos. <i>Microbiology Spectrum</i> . 3(6): 12. https://dx.doi.org/10.1128/microbiolspec.IOL5-0016-2015	Wrong study design (narrative review), <2 databases searched, no critical appraisal
Saccomanno S, Ieria I, Manenti RJ, et al. (2021). Complications of oral piercing: a review of the literature and two case reports. <i>Journal of Biological Regulators & Homeostatic Agents</i> . 35(3): 167-78. https://dx.doi.org/10.23812/21-3supp1-19	Wrong study design (narrative review), <2 databases searched, no critical appraisal
Sosin M, Weissler JM, Pulcrano M, et al. (2015). Transcartilaginous ear piercing and infectious complications: a systematic review and critical analysis of outcomes. <i>Laryngoscope</i> . 125(8): 1827-34. https://dx.doi.org/10.1002/lary.25238	<2 databases searched, no critical appraisal
Van Remoortel H, Moorkens D, Avau B, et al. (2019). Is there a risk of transfusion-transmissible infections after percutaneous needle treatments in blood donors? A systematic review and meta-analysis. <i>Vox Sanguinis</i> . 114(4): 297-309. https://dx.doi.org/10.1111/vox.12780	Wrong outcome
Vane SCS. (2016). Oral and perioral piercings: An analysis of complications, management and use of oral hygiene techniques. <i>Research Journal of Pharmacy and Technology</i> . 8: 1007-10. https://dx.doi.org/10.5958/0974-360X.2015.00170.5	Wrong study design (narrative review), <2 databases searched, no critical appraisal
Yang S, Wang D, Zhang Y, et al. (2015). Transmission of hepatitis B and C virus infection through body piercing: a systematic review and meta-analysis. <i>Medicine</i> . 94(47): e1893. https://dx.doi.org/10.1097/MD.0000000000001893	Wrong outcome
Q3. Acupuncture (n=2)	
Nielsen A, Gereau S, Tick H. (2020). Risks and safety of extended auricular therapy: a review of reviews and case reports of adverse events. <i>Pain Medicine</i> . 21(6): 1276-93. https://dx.doi.org/10.1093/pm/pnz379	No critical appraisal
Paley CA, Johnson MI. (2019). Acupuncture for the relief of chronic pain: a synthesis of systematic reviews. <i>Medicina</i> . 56(1): 24. https://dx.doi.org/10.3390/medicina56010006	No critical appraisal, wrong outcome
Q4. Electrolysis (n=20)	
Butler SM, Smith NK, Collazo E, et al. (2015). Pubic hair preferences, reasons for removal, and associated genital symptoms: comparisons between men and women. <i>Journal of Sexual Medicine</i> . 12(1): 48-58. https://dx.doi.org/10.1111/jsm.12763	Wrong outcome
Cohen PR. (2020). Hypertrichosis and genital rejuvenation: cutaneous adverse events associated with pubic hair grooming. <i>SKINmed</i> . 18(5): 297-9.	Wrong intervention, wrong study design
Gaither TW, Fergus K, Sutcliffe S, et al. (2020). Pubic hair grooming and sexually transmitted infections: a clinic-based cross-sectional survey. <i>Sexually Transmitted Diseases</i> . 47(6): 419-25.	Wrong outcome
Gaither TW, Truesdale M, Harris CR, et al. (2015). The influence of sexual orientation and sexual role on male grooming-related injuries and infections. <i>Journal of Sexual Medicine</i> . 12(3): 631-40. https://dx.doi.org/10.1111/jsm.12780	Wrong outcome
Hodges AL, Holland AC. (2017). Prevention and treatment of injuries and infections related to pubic hair removal. <i>Nursing for women's health</i> . 21: 313-7. https://dx.doi.org/10.1016/j.nwh.2017.06.001	Wrong intervention, wrong study design

Kang CN, Shah M, Lynde C, et al. (2021). hair removal practices: a literature review. <i>Skin Therapy Letter</i> . 26(5): 6-11	Wrong study design (unpicked narrative review)
Luster J, Turner AN, Henry JP, Jr., et al. (2019). Association between pubic hair grooming and prevalent sexually transmitted infection among female university students. <i>PLoS ONE</i> [Electronic Resource]. 14(9): e0221303. https://dx.doi.org/10.1371/journal.pone.0221303	Wrong intervention
Matheson E, Bain J. (2019). Hirsutism in women. <i>American Family Physician</i> . 100(3): 168-75.	Wrong study design (unpicked narrative review)
Mezin-Sarbu E, Wohlrab J. (2023). Epilation and depilation in the genital area – motivation, methods, risks and recommendations from a dermatological point of view. <i>Journal der Deutschen Dermatologischen Gesellschaft</i> . 21(5): 455-62 https://dx.doi.org/10.1111/ddg.14993	Wrong study design (unpicked systematic review), not focused on electrolysis
Molgo M, Moll-Manzur C, Downey C. (2020). Follicular traction urticaria induced by electric epilation. <i>Cutis</i> . 105(5): E23-E4.	Wrong intervention
Osterberg EC, Gaither TW, Awad MA, et al. (2017). Correlation between pubic hair grooming and STIs: results from a nationally representative probability sample. <i>Sexually Transmitted Infections</i> . 93(3): 162-6.	Wrong outcome
Pany A, Klang V, Brunner M, et al. (2019). Effect of physical and chemical hair removal methods on skin barrier function in vitro: consequences for a hydrophilic model permanent. <i>Skin Pharmacology & Physiology</i> . 32(1): 8-21. https://dx.doi.org/10.1159/000493168	Wrong outcome, wrong population
Shukalek C, Parsons L, Somayaji R. (2017). Delving into skin and soft tissue infections (SSTI) Part II: Focus on superficial infections. <i>World Council of Enterostomal Therapists Journal</i> . 37(3): 20-4.	Full text not available
Staszczuk M. (2020). Just Zap It: Electrolysis is a permanent alternative to waxing and sugaring. <i>Skin Deep</i> . 32-3.	Wrong publication type
Swain TA, Tully AS, Redford T, et al. (2016). Hair removal-related injuries in the United States, 1991-2014. <i>Journal of Cosmetic Dermatology</i> . 15(4): 444-51. https://dx.doi.org/10.1111/jocd.12283	Wrong intervention
Trivedi MK, Kroumpouzou G, Murase JE. (2017). A review of the safety of cosmetic procedures during pregnancy and lactation. <i>International Journal of Women's Dermatology</i> . 3(1): 6-10. https://dx.doi.org/10.1016/j.ijwd.2017.01.005	Wrong outcome, wrong study design
Truesdale MD, Osterberg EC, Gaither TW, et al. (2017). prevalence of pubic hair grooming-related injuries and identification of high-risk individuals in the United States. <i>JAMA Dermatology</i> . 153(11): 1114-21. https://dx.doi.org/10.1001/jamadermatol.2017.2815	No breakdown of outcomes by type of hair removal
Williamson H. (2015). Social pressures and health consequences associated with body hair removal. <i>Journal of Aesthetic Nursing</i> . 4(3): 131-3.	Wrong study design
Wu Y, Dai Y, Wang T, et al. (2022). The application of electrolysis of depigmented hair using a trichiasis electrolyzer combined with single hair follicle transplantation for the treatment of vitiligo-associated leukotrichia. <i>Dermatologic Therapy</i> . 35(5): e15400. https://dx.doi.org/10.1111/dth.15400	Wrong setting, wrong intervention
Yuan N, Feldman AT, Chin P, et al. (2022). Comparison of Permanent Hair Removal Procedures before Gender-Affirming Vaginoplasty: Why We Should Consider Laser Hair Removal as a First-Line Treatment for Patients Who Meet Criteria. <i>Sexual Medicine</i> . 10(5): 100545. https://dx.doi.org/10.1016/j.esxm.2022.100545	Wrong setting, wrong intervention

APPENDIX 5: Table of unique primary studies of body piercing

Table 19. Unique primary studies from included SRs on body piercing

Primary study	Acuña-Chavez 2022	Hennequin-Hoenderdos 2016	Passos 2022	Sindoni 2022
2014 Abbass	1	0	0	0
2015 Abdulrahman	1	0	0	0
1984 Ahmedjushuf	0	0	0	1
2002 Akhondi	0	0	0	1
2007 Bader	1	0	0	0
2019 Baker	1	0	0	0
1991 Battin	0	0	0	1
2008 Bengualid	1	0	0	1
1998 Botha	0	0	0	1
2001 Brook	1	0	0	0
2002 Campbell	0	1	1	0
2019 Cenicerros	1	0	0	0
2008 Cerri	0	0	1	0
2005 Choe	0	0	0	1
2009 Cingi	0	0	0	1
2017 Cornelissen	1	0	0	0
2020 Covello	0	0	1	1
2001 de Kleer	1	0	0	1
2000 De Moor	0	1	1	1
2005 De Moor	0	1	1	1
2006 Deschesnes	0	0	0	1
2019 Domingo	0	0	1	0
2005 Dougherty	0	1	1	0
2007 Drifmeyer	1	0	0	0
2004 Dubose	0	0	0	1
2004 Dunn	0	0	0	1
2000 Dyce	0	0	0	1
2008 Ebrahim	0	1	1	0
2012 Eulalio	0	0	1	0
2018 Evans	0	0	0	1
2009 Firoozmand	0	0	1	1
2005 Fisher	0	0	0	1
2000 Folz	0	0	0	1
2003 Friedel	0	0	0	1
2017 Gabriel	0	0	0	1
2020 Galan	0	0	1	0
2011 Galle	0	0	0	1
2012 Galle	0	0	0	1
2008 Garcia-Pola	0	1	1	0
2009 Gareca	0	0	1	0
2012 Gill	0	0	1	1
2012 Giuca	0	1	0	0
2016 Goder	0	0	0	1
2005 Gold	0	0	0	1
2003 Goldrick	0	0	0	1
2002 Gonzalez_Arreaga	0	0	1	0
2006 Goossens	0	0	0	1
2002 Haboor	0	0	0	1
2014 Haces_Acosta	0	0	1	0
2013 Halim	0	0	0	1
2017 Heinen	0	0	1	0
2009 Herskovitz	0	0	0	1

2010 Hickey	0	0	1	1
2006 High	0	0	0	1
2008 Hounsfeld	0	0	0	1
2022 Ibraheem	0	0	1	0
2011 Inchingolo	0	0	1	1
2012 Jackson	0	0	0	1
2002 Jacobs	1	0	0	0
1974 Johnson	0	0	0	1
2012 Kapferer	0	1	1	0
2011 Kapferer	0	0	1	1
2007 Kapferer	0	1	1	0
2010 Kapferer	0	0	1	0
2004 Keene	0	0	0	1
2001 Keogh	0	0	0	1
2005 Kieser	0	1	1	1
2007 Kloppenburg	0	0	0	1
2019 Kluger	0	0	0	1
2019 Kolek	0	0	1	0
2006 Kovacs	0	0	1	0
2008 Lakhan	0	0	0	1
2015 Laumann	0	0	1	0
2006 Lee	0	0	0	1
2011 Lee	0	0	0	1
2011 Leibman	1	0	0	0
2006 Leichter	0	1	1	0
2005 Levin	0	0	1	1
2004 Lewis	1	0	0	1
2005 Lick	0	0	0	1
2006 Lopez-Jornet	0	0	1	1
2008 Lorenzini	0	0	1	0
2010 Lupi	0	0	1	0
2012 Maroun	1	0	0	0
2003 Martinello	0	0	0	1
2013 Martins	0	0	1	0
2008 Mayers	0	0	0	1
2002 Mayers	0	0	0	1
1988 McCarthy	0	0	0	1
1992 McDonagh	0	0	0	1
2016 Mejersjo	0	0	1	0
2008 Monteverde	0	0	1	0
2010 Oberholzer	0	0	1	0
2001 Ochsenfahrt	1	0	0	1
1998 Papanagiotou	0	0	0	1
1995 Pearlman	1	0	0	0
2016 Pendle	1	0	0	1
2018 Perry	0	0	0	1
2010 Pires	0	1	1	1
2012 Plessas	0	1	1	0
2014 Purim	0	0	0	1
2016 Ravelo	0	0	1	0
1984 Saleeby	0	0	0	1
2019 Samoilenko	0	0	1	0
2007 Sandhu	0	0	0	1
2009 Saquet	0	0	1	0
2011 Sauer	0	0	0	1
2019 Schmidt	0	0	1	1
2007 Schorzman	0	0	0	1
2003 Shacham	0	0	0	1

2018 Shoyele	1	0	0	0
1973 Shulman	0	0	0	1
2020 Siddique	1	0	0	0
2014 Simoes	0	0	1	0
2008 Slutzkey	0	0	1	0
2005 Soileau	0	0	0	1
2006 Stead	0	0	1	0
2017 Tomazevic	0	0	1	1
2011 Tripodi	0	0	1	0
2001 Tronel	0	0	0	1
2001 Trupiano	1	0	0	1
2007 Tsesmeli	0	0	0	1
1990 Turkeltaub	0	0	0	1
2016 Ventolini	0	0	0	1
2011 Vieira	0	0	1	0
2009 Vilchez-Perez	0	1	1	1
2017 Warshaw	0	0	0	1
2003 Weinberg	0	0	0	1
2004 Whittle	0	0	0	1
1992 Widick	0	0	0	1
2010 Zadik	0	0	1	0
2004 Zardawi	1	0	0	1
2009 Ziebolz_b	0	0	0	1
2012 Ziebolz	0	1	1	0
2009 Ziebolz_a	0	0	1	0
2020 Ziebolz	0	0	1	0



The Health and Care Research Wales Evidence Centre

Our dedicated team works together with Welsh Government, the NHS, social care, research institutions and the public to deliver vital research to tackle health and social care challenges facing Wales.

Funded by Welsh Government, through Health and Care Research Wales, the Evidence Centre answers key questions to improve health and social care policy and provision across Wales.

Along with our collaborating partners, we conduct reviews of existing evidence and new research, to inform policy and practice needs, with a focus on ensuring real-world impact and public benefit that reaches everyone.

Director: Professor Adrian Edwards

Associate Directors: Dr Alison Cooper, Dr Natalie Joseph-Williams, Dr Ruth Lewis



@EvidenceWales @tystiolaethcym



healthandcareevidence@cardiff.ac.uk



www.researchwalesevidencecentre.co.uk