medRxiv preprint doi: https://doi.org/10.1101/2023.12.01.23299300; this version posted December 4, 2023. The copyright holder for this preprint (which was not certified by peer review) is the author/funder, who has granted medRxiv a license to display the preprint in perpetuity. All rights reserved. No reuse allowed without permission.

Title: Endothelial sampling *in situ* enables genetic characterization of vein of Galen Malformation

Authors: Andrew T. Hale,[1*] Shanrun Liu,[3] Fengyuan Huang,[2] Yuwei Song,[2] Michael R. Crowley,[2] David K. Crossman,[2] Caroline Caudill,[4] Anastasia A. Smith,[4] Lindsey Chapman,[5] Michael J. Feldman,[4] Benjamin W. Saccomano,[1] Brandon G. Rocque,[1,4] Curtis J. Rozzelle,[1,4] Jeffrey P. Blount,[1,4] James M. Johnston,[1,4] Zechen Chong[3] and Jesse G. Jones[1,4*]

Affiliations: [1]Department of Neurosurgery, University of Alabama at Birmingham, Birmingham, AL; [2]Heflin Genetics Center and Genetics Research Division, University of Alabama at Birmingham, Birmingham, AL; [3]Single Cell and Flow Cytometry Core, University of Alabama at Birmingham, Birmingham, AL; [4]Division of Pediatric Neurosurgery, Children's of Alabama, Birmingham, AL. *To whom correspondence should be addressed.

Conflict of Interest: A.T.H. and J.G.J. received material support (i.e. coils) from Balt for the purposes of this study. Balt played no role in designing, collecting, interpreting, or reporting the data presented in this manuscript.
Disclosure of Funding: A.T.H. and J.G.J. received funding from The Aneurysm and AVM Foundation (TAAF), Joe Niekro Foundation (JNF), Robert J. Dempsy, MD Research Award from the American Association of Neurological Surgeons (AANS) and Congress of Neurological Surgeons (CNS) joint section for Cerebrovascular Neurosurgery, Kaul Pediatric Research Institute (KPRI) of Children's of Alabama, and the Center for Clinical and Translational Sciences (CCTS) at University of Alabama at Birmingham provided funding for this study.

This paper has been submitted for presentation consideration at the American Association of Neurological Surgeons (AANS) and Congress of Neurological Surgeons (CNS) joint section for Pediatric Neurosurgery in Oklahoma City, OK (USA) in December 2023.

Corresponding Authors:

Andrew T Hale, MD, PhD
Department of Neurosurgery
University of Alabama at Birmingham
FOT Suite 1060, 1720 2nd Ave S.
Birmingham, AL 35294
andrewthale@uabmc.edu

Jesse G. Jones, MD
Department of Neurosurgery
University of Alabama at Birmingham
FOT Suite 1060, 1720 2nd Ave S.
Birmingham, AL 35294
jessejones@uabmc.edu

NOTE: This preprint reports new research that has not been certified by peer review and should not be used to guide clinical practice.

medRxiv preprint doi: https://doi.org/10.1101/2023.12.01.23299300; this version posted December 4, 2023. The copyright holder for this preprint (which was not certified by peer review) is the author/funder, who has granted medRxiv a license to display the preprint in perpetuity. All rights reserved. No reuse allowed without permission.

Abstract

Background and Objectives:
Vein of Galen malformation (VOGM), the result of arteriovenous shunting between choroidal and/or subependymal arteries and the embryologic prosencephalic vein, is among the most severe cerebrovascular disorders of childhood. While endovascular treatment options have improved outcomes, morbidity and mortality remain high. We hypothesized that *in situ* analysis of the VOGM lesion using endoluminal tissue sampling (ETS) is feasible and may identify somatic mutations and transcriptional aberrations. A mechanistic understanding of VOGM genetics, pathogenesis, and maintenance will guide future therapeutic efforts.

Methods:
We utilized a Mendelian, trio-based study design, collecting germline DNA (cheek swab) from patients and their families for whole exome sequencing (WES). *In situ* VOGM 'endothelial' cells (EC), defined as CD31+ and CD45-, were obtained from coils via ETS during routine endovascular treatment. Autologous peripheral femoral ECs were also collected from the access sheath. Single-cell RNA sequencing (scRNA-seq) of both VOGM and femoral ECs was performed to demonstrate feasibility to define the transcriptional architecture. Comparison was also made to a published normative cerebrovascular transcriptome atlas. A subset of VOGM ECs was reserved for future DNA sequencing to assess for somatic and second-hit mutations.

Results:
Our cohort contains 6 patients who underwent 10 ETS procedures from arterial and/or venous access during routine VOGM treatment (aged 12 days to ~6 years). No periprocedural complications attributable to ETS occurred. Six unique coil types were used. ETS captured 98 ± 88 (mean ± SD; range 17-256) experimental 'endothelial' cells (CD31+ and CD45-). There was no discernable correlation between cell yield and coil type or route of access. Single cell RNA sequencing demonstrated hierarchical clustering and unique cell populations within the VOGM EC compartment compared to autologous femoral controls when annotated using a publicly available cerebrovascular cell atlas.

Conclusion:
We report the first successful utilization of ETS for VOGM. ETS appears safe and may supplement investigations aimed at development of a molecular-genetic taxonomic classification scheme for VOGM. Moreover, results may eventually inform the selection of personalized pharmacologic or genetic therapies for VOGM and cerebrovascular disorders more broadly.

Running title: Endoluminal biopsy of VOGM

Keywords: vein of Galen malformation, vein of Galen aneurysmal malformation, genomics, human genetics, functional genomics, endoluminal biopsy, endothelial biopsy, endovascular biopsy, somatic mutation, single cell RNA sequencing

medRxiv preprint doi: https://doi.org/10.1101/2023.12.01.23299300; this version posted December 4, 2023. The copyright holder for this preprint (which was not certified by peer review) is the author/funder, who has granted medRxiv a license to display the preprint in perpetuity. All rights reserved. No reuse allowed without permission.

Introduction

Vein of Galen malformation (VOGM) is a congenital high flow vascular lesion characterized by aberrant communication between the choroidal or subependymal cerebral arteries and median prosencephalic vein of Markowski. Arteriovenous (AV) shunting can lead to congestive heart failure in neonates and hydrovenous disorder of early childhood.[1] The latter condition involves venous hypertension with consequent brain atrophy, hydrocephalus, and epilepsy. Current methods for closing the AV shunt rely on percutaneous trans-arterial or trans-venous access with microcatheters, followed by vascular occlusion with liquid embolics and/or coils.[2] Endovascular embolization represents the primary treatment but typically requires several procedures, staged over months to years. Sequelae of prolonged venous hypertension during this period lead to permanent disability or death in ~40% of patients.[2,3] Intervention in the neonatal stage also carries a significant risk of peri-procedural stroke and death.[4] Thus, safer and more efficacious VOGM therapies are urgently needed.

Little is known about how VOGM develops between the 6th and 11th weeks of gestation[5] or how it maintains itself as a large vascular network consuming up to 70% of cardiac output.[6] These fundamental knowledge gaps impede development of improved therapies. Human genetics and functional genomics are well suited to VOGM because they integrate static (either inherited or somatic mutation) and dynamic (i.e., gene expression) approaches. For a congenital disease that lacks robust animal models, genomic analysis will complement observational and experimental studies. Specifically, whole-exome sequencing (WES) represents an established method for identifying inherited, *de novo*, and copy number aberrations in disease, including VOGM.[7,8] Functional genomics approaches such as single-cell RNA sequencing (scRNA seq) delineate molecular mechanisms underlying diseases with a genetic or shared molecular component.[9-16] Collectively, these approaches may enable (1) detection of potential causative or risk-conferring mutations; (2) elucidation of cellular composition *in situ*; and (3) identification of convergent molecular mechanisms amenable to pharmacologic or even gene therapy based approaches.

Recently, an endothelial tissue sampling (ETS) technique has emerged for obtaining lesional tissue *in situ*.[17,18] During routine endovascular treatment, a catheter is positioned within the pathologic region and a standard endovascular coil advanced into the vasculature. After ~ 2 minutes contact with the

medRxiv preprint doi: https://doi.org/10.1101/2023.12.01.23299300; this version posted December 4, 2023. The copyright holder for this preprint (which was not certified by peer review) is the author/funder, who has granted medRxiv a license to display the preprint in perpetuity. All rights reserved. No reuse allowed without permission.

vessel wall, it is completely withdrawn from the body.[19,20] Adherent endothelial cells are subsequently isolated using antibody mediated selection and flow cytometry. ETS has facilitated rapid advancement in the understanding of brain aneurysm and arteriovenous malformation (AVM) genomics and proteomics.[21,22] However, no study to our knowledge has reported successful use of ETS in patients with VOGM. Advances in genomic and molecular analyses now position ETS to enable discovery of mechanisms underlying VOGM pathogenesis and maintenance with the goal of developing personalized, biologically based therapies.

Methods

Study population

IRB approval was granted by the author's institution for this prospective observational study. Parents provided informed consent. Six pediatric (range: 12 days to ~6 years) VOGM patients undergoing standard of care embolization were recruited between 2022-2023. Diagnosis was confirmed by catheter angiography. Clinical presentation included neonatal congestive heart failure and hydrovenous disorder. All patients were seemed suitable for clinical intervention based on Bicetre score.[23] During each endovascular procedure, ETS was performed if deemed safe by the primary operator (J.G.J.). Staged embolization patients underwent ETS on more than one occasion. Information regarding the sampling location, coil type and other data were recorded on a templated form and entered into a secured Redcap database. Germline DNA was collected from all subjects and first-degree relatives who were available for consent via cheek swab. Pedigrees were assembled to eventually compare germline DNA against EC's retrieved by ETS to identify somatic and second-hit mutations.

Endoluminal tissue sampling (ETS) procedure

ETS protocols have been established previously for other cerebrovascular lesions.[24-27] However, VOGM poses novel challenges due to the shearing effect of high flowing blood and small patient size, which precludes many common endovascular devices. Clinical factors alone determined vessel selection, catheter selection, and access route. Trans-arterial embolization more often characterized earlier stages of treatment. Flow directed Magic (Balt, Montmorency) microcatheters are not amenable to ETS. Thus,

medRxiv preprint doi: https://doi.org/10.1101/2023.12.01.23299300; this version posted December 4, 2023. The copyright holder for this preprint (which was not certified by peer review) is the author/funder, who has granted medRxiv a license to display the preprint in perpetuity. All rights reserved. No reuse allowed without permission.

the sample selection was limited to treatments employing a Marathon microcatheter (EV3, Irvine CA) which accommodates smaller (up 6 mm) Blockade coils. Achieving a stable coil nest in such high flow pedicles is challenging and best done at a curve or narrowing in the vessel. Trans-venous embolization often allowed standard 0.017" microcatheters (and larger coils) given the less tortuous and delicate access route, except in cases of retrograde pedicle catheterization when an Apollo (EV3, Irvine CA) was used in conjunction with Onyx. Like Marathon, Apollo accommodates smaller Blockade coils for ETS. Coils were sized to approximate the vessel's diameter and conform to its walls. After 2 minutes of endoluminal dwell time, the coil was resheathed through the microcatheter, protecting it from contact with other vessel segments. At procedure's end, the vascular access sheath(s) were collected, and ECs were isolated.

Cell isolation and dissociation from coils

The explanted coil is immediately placed into a conical tube of DMEM on ice. The coil is then transported to the flow cytometry core within 30 minutes. DMEM is aspirated and the coil rinsed in DPBS (without Ca or Mg), incubated in 0.25% Trypsin-EDTA at room temperature for 5 minutes prior to neutralization with 1ml of FBS. The coil is then washed with a trypsin-FBS solution to ensure complete dissociation. The dissociate is then spun down (~500g, 5 minutes), the supernatant removed, and the pellet resuspended in ACK lysis buffer on ice, for 3~4 mins to lyse red blood cell contaminants. The ACK lysis buffer is then neutralized using 1X PBS or DMEM. Cells are pelleted again and resuspended in PBS 100ul with Alexa Fluor 647–conjugated monoclonal anti-human CD31 antibody (BD Biosciences, San Jose, CA; 1:200 dilution) and anti-human CD45 antibody (BD Biosciences, San Jose, CA; 1:200 dilution). The cell solution containing CD31 and CD45 antibodies are incubated on ice for 20 minutes prior to addition of propidium iodide (to exclude dead cells, 120ug/ml, 1:100 dilution in DPBS without Ca or Mg) for an additional 10-minute incubation on ice. Finally, 500ul DPBS (without Ca or Mg) is added, centrifuged for 5 minutes at 500g, the supernatant is removed, the cell pellet is resuspended in 300ul DPBS, and individual cells are sorted into a 96-well plate. Cells obtained from the shealth are processed in an analogous fashion.

medRxiv preprint doi: https://doi.org/10.1101/2023.12.01.23299300; this version posted December 4, 2023. The copyright holder for this preprint (which was not certified by peer review) is the author/funder, who has granted medRxiv a license to display the preprint in perpetuity. All rights reserved. No reuse allowed without permission.

Cell sorting and flow cytometry

Cells are subsequently fluorescently sorted on a BD FACSAria II Flow Cytometer (BD Biosciences). Nonviable cells were excluded based on propidium iodide (PI) positivity, monocyte populations were excluded based on CD45 positivity, and endothelial enrichment was performed through positive selection of CD31 cells. Viable cells enriched for endothelium were therefore considered to be CD31-positive, CD45-negative, and PI-negative cells. Cells are then sorted into single-cells in a 96-well plate (already containing 4ul of DPBS as indicated above) for either single-cell or bulk analysis. The plate is then sealed and frozen at -80°C for downstream human genetic and functional genomic analyses.

Single cell RNA sequencing

Raw sequencing data were processed with the Cell Ranger pipeline software (v.3.0.2; 10x Genomics). The Cell Ranger count pipeline was used to perform quality control, sample demultiplexing, barcode processing, alignment, and single-cell 5' gene counting. Cell ranger "count" was used to align raw reads against the hg38 genome (refdata-gex-GRCh38-2020-A) using CellRanger software (v.4.0.0) (10x Genomics). Subsequently, cell barcodes and unique molecular identifiers (UMI) underwent filtering and correction using default parameters in Cell Ranger. Reads with the retained barcodes were quantified and used to build the gene expression matrix.

Seurat (v.3.0.0), implemented using the R package, was applied to exclude low-quality cells.[28] Cells that expressed fewer than 200 and larger than 5000 genes were filtered out. The processed data was normalized using Seurat's 'NormalizeData' function, which used a global scaling normalization method, LogNormalize, to normalize the gene expression measurements for each cell to the total gene expression. Highly variable genes were then identified using the function 'FindVariableGenes' in Seurat. The anchors were identified using the 'FindIntegrationAnchors' function, and thus the matrices from different samples were integrated with the 'IntegrateData' function. The variation arising from library size and percentage of mitochondrial genes was regressed out using the function 'ScaleData' in Seurat. Principal component (PC) analysis was performed using the Seurat function 'RunPCA', and K-nearest neighbor graph was constructed using 'FindNeighbors' function in Seurat with the number of significant PCs identified from PCA analysis. Clusters were identified using 'FindClusters' function with resolution of

medRxiv preprint doi: https://doi.org/10.1101/2023.12.01.23299300; this version posted December 4, 2023. The copyright holder for this preprint (which was not certified by peer review) is the author/funder, who has granted medRxiv a license to display the preprint in perpetuity. All rights reserved. No reuse allowed without permission.

0.4. The clusters were visualized in two dimensions with UMAP. The normalization, integration, and clustering were performed under standard Seurat workflow.

Results

All six families that were solicited to participate in the study agreed and provided informed consent. ETS was performed a total of ten times (owing to staged procedures involving the same subject), in three arteries and seven veins. All coils yielded CD31+, CD45- experimental cells, although the number varied widely (98 ± 88 mean ± SD; range 17-256) (**Table 1**). No relationship between cell yields from the coil and coil size or sampling location could be discerned. No periprocedural complications related to ETS were encountered and no subjects were lost to follow-up.

This report focuses on technical aspects of ETS in VOGM. Complete trios were assembled in 2/6 families, mother and child only in 3/6, and father and child only in 1/6 (**Figure 1**). Cheek swab DNA from all individuals listed in **Figure 1** was collected. An overview of our approach can be found in **Figure 2**. ETS is performed (see Methods for full details) and specimens are immediately transported for flow cytometry sorting. After positive selection with CD31 and negative selection of CD45, experimental 'endothelial' cells are obtained (**Figure 3**). Pooled experimental cells are then lysed for DNA purification using standard methodologies.[29] This finding demonstrates ETS' potential to enable identification of coding mutations, copy number variants, deletions, insertions, genomic rearrangements, and the single cell/nucleus RNA transcriptional landscape unique to VOGM tissue *in situ*. Finally, single cell RNA sequencing (scRNA seq) was performed to demonstrate feasibility of this approach on VOGM samples obtained through ETS (**Figure 4**). Using hierarchical clustering, we identify 12 unique cell populations between VOGM *in situ* and femoral access samples. Collectively, these data illustrate the feasibility of ETS for VOGM and we offer an integrative strategy for advancing our molecular genetic understanding of VOGM pathogenesis and maintenance.

Discussion

While VOGM represents a severe cerebrovascular anomaly with profound systemic and neurologic consequences,[30] it is also rare and until now, pathologic studies were limited to post-mortem

medRxiv preprint doi: https://doi.org/10.1101/2023.12.01.23299300; this version posted December 4, 2023. The copyright holder for this preprint (which was not certified by peer review) is the author/funder, who has granted medRxiv a license to display the preprint in perpetuity. All rights reserved. No reuse allowed without permission.

specimens.[31] For these reasons, investigative studies into VOGM embryologic development, vascular maintenance, post-natal growth through angiogenesis, and cellular response to treatment have been hindered. Recent WES studies have identified putatively causative *de novo* and inherited gene mutations in ~30% of sporadic VOGM cases.[8,32] These studies identified a genome-wide significant burden of rare, damaging mutations in Ephrin B4 (EphB4).[32,33] Interestingly, deletion of EphB4 in zebrafish recapitulates anomalies in the dorsal cranial vessels representing the phylogenic homologue of the vein of Galen.[33] EphB4's role as a critical regulator of AV specification[32,33] suggests VOGM may share a common pathogenetic mechanism with other congenital AV shunts such as AV malformation (AVM). Specifically, incomplete AV differentiation and zonation are hallmarks of AVM, driven in part by EphB4[34] mutations as well as several other genes regulating the developmental cerebrovascular niche.[8,35] ETS, for the first time, enables *in situ* analysis to delineate these pathogenic mechanisms and pathways responsible for VOGM and cerebrovascular development more broadly.

The genetics underlying VOGM, and their relative contribution (compared to environmental factors) to disease, however, remain poorly understood.[30] ETS represents a novel method for investigating these unanswered questions by screening lesional VOGM EC's for *de novo,* somatic, and second hit mutations.[36,37] Complementary *in situ* scRNA seq may elucidate vascular maintenance and pro-growth molecular programs that are not strictly genetic or heritable, but triggered in response to environmental factors. The PI3K/AKT/MTOR[38] and RAS/RAF/MEK/ERK[39] signaling programs, for example, influence angiogenesis, cell growth, apoptosis, and differentiation. Both are dysregulated in AVM, but at various frequency and intensity. Upstream EphB4 mutations are responsible in some instances yet absent in others. Additional mutations and transcriptional aberrations have been described in other vascular malformations, the vast majority being mosaic and restricted to pathologic tissue. This highlights the potential role for ETS and other evolving approaches such as liquid biopsy as tools to understand VOGM biology and to guide treatment.[40-43]

Future studies of ETS for genomic analysis may inform personalized therapies for VOGM and cerebrovascular diseases more broadly. While several existing compounds modulate RAS/RAF/MAPK and PI3K/AKT/mTOR [44-47] signaling, these treatments may be misguided without patient-specific data. Somatic WES and scRNA seq have the potential to identify disease-causing mutations and disease-

medRxiv preprint doi: https://doi.org/10.1101/2023.12.01.23299300; this version posted December 4, 2023. The copyright holder for this preprint (which was not certified by peer review) is the author/funder, who has granted medRxiv a license to display the preprint in perpetuity. All rights reserved. No reuse allowed without permission.

propagating transcriptional aberrations. Both represent potential targets for gene therapy, novel or repurposed pharmacotherapies. However, protocols for reliably sequencing picogram DNA quantities and interpreting the "big data" inherent to scRNA seq remain a focus of ongoing study.

Limitations

VOGM is a rare disease and treatment limited to few comprehensive pediatric hospitals with the requisite expertise. However, even at tertiary referral centers only 2-3 new VOGM cases may be seen annually. The small sample size reported here reflects this limitation, which reduces statistical power and challenges the generalizability of our results. We have formed the VOGM Genetics Research Consortium (VOGM-GRC, www.vogm-genetics.com), a multi-institutional consortium of leading pediatric centers across the world to address this shortcoming in future studies.

Conclusions

We describe here a method for successfully performing ETS in VOGM that addresses unique properties of this formidable arteriovenous shunt. The potential benefits of ETS in VOGM are numerous and include (i) acquisition of lesional tissue to identify somatic mutations, (ii) ability to study molecular alterations in the shunt over time as they remodel, and (iii) enabling precision-medicine based approaches to pharmacologically targetable mutations. Nevertheless, ETS devices, sequencing platforms and genomic informatics all demonstrate substantial opportunities to improve. Our understanding of VOGM pathophysiology and vascular maintenance will grow in concert with such advances, potentially informing novel treatments to better outcomes across this specific population and cerebrovascular disease more broadly.

medRxiv preprint doi: https://doi.org/10.1101/2023.12.01.23299300; this version posted December 4, 2023. The copyright holder for this preprint (which was not certified by peer review) is the author/funder, who has granted medRxiv a license to display the preprint in perpetuity. All rights reserved. No reuse allowed without permission.

References

1. Lasjaunias PL, Chng SM, Sachet M, Alvarez H, Rodesch G, Garcia-Monaco R. The Management of Vein of Galen Aneurysmal Malformations. *Neurosurgery*. 2006;59:S3-184-S183-194. doi: 10.1227/01.NEU.0000237445.39514.16

2. Lasjaunias P, Garcia-Monaco R, Rodesch G, Ter Brugge K, Zerah M, Tardieu M, De Victor D. Vein of Galen malformation. *Child's Nervous System*. 1991;7:360-367.

3. Savage C, Hale AT, Parr MS, Hedaya A, Saccomano BW, Tsemo GB, Hafeez MU, Tanweer O, Kan P, Solomon LJ, et al. Outcomes of endovascular embolization for Vein of Galen malformations: An individual participant data meta-analysis. *Front Pediatr*. 2022;10:976060. doi: 10.3389/fped.2022.976060

4. Yan J, Wen J, Gopaul R, Zhang C-Y, Xiao S-w. Outcome and complications of endovascular embolization for vein of Galen malformations: a systematic review and meta-analysis. *Journal of neurosurgery*. 2015;123:872-890.

5. Raybaud CA, Strother CM, Hald JK. Aneurysms of the vein of Galen: embryonic considerations and anatomical features relating to the pathogenesis of the malformation. *Neuroradiology*. 1989;31:109-128. doi: 10.1007/BF00698838

6. Smith A, Abruzzo T, Mahmoud M. Vein of Galen Malformation and High-output Cardiac Failure. *Anesthesiology*. 2016;125:597. doi: 10.1097/ALN.0000000000001095

7. Rabbani B, Tekin M, Mahdieh N. The promise of whole-exome sequencing in medical genetics. *Journal of human genetics*. 2014;59:5-15.

8. Zhao S, Mekbib KY, van der Ent MA, Allington G, Prendergast A, Chau JE, Smith H, Shohfi J, Ocken J, Duran D, et al. Mutation of key signaling regulators of cerebrovascular development in vein of Galen malformations. *Nat Commun*. 2023;14:7452. doi: 10.1038/s41467-023-43062-z

9. Shalek AK, Satija R, Shuga J, Trombetta JJ, Gennert D, Lu D, Chen P, Gertner RS, Gaublomme JT, Yosef N. Single-cell RNA-seq reveals dynamic paracrine control of cellular variation. *Nature*. 2014;510:363-369.

10. Hammond TR, Dufort C, Dissing-Olesen L, Giera S, Young A, Wysoker A, Walker AJ, Gergits F, Segel M, Nemesh J. Single-cell RNA sequencing of microglia throughout the mouse lifespan and in the injured brain reveals complex cell-state changes. *Immunity*. 2019;50:253-271. e256.

11. Hale AT, Akinnusotu O, He J, Wang J, Hibshman N, Shannon CN, Naftel RP. Genome-Wide Association Study Identifies Genetic Risk Factors for Spastic Cerebral Palsy. *Neurosurgery*. 2021;89:435-442. doi: 10.1093/neuros/nyab184

12. Hale AT, Bastarache L, Morales DM, Wellons JC, 3rd, Limbrick DD, Jr., Gamazon ER. Multi-omic analysis elucidates the genetic basis of hydrocephalus. *Cell Rep*. 2021;35:109085. doi: 10.1016/j.celrep.2021.109085

13. Hale AT, He J, Jones J. Multinational Genome-Wide Association Study and Functional Genomics Analysis Implicates Decreased SIRT3 Expression Underlying Intracranial Aneurysm Risk. *Neurosurgery*. 2022;91:625-632. doi: 10.1227/neu.0000000000002082

14. Sadler B, Wilborn J, Antunes L, Kuensting T, Hale AT, Gannon SR, McCall K, Cruchaga C, Harms M, Voisin N, et al. Rare and de novo coding variants in chromodomain genes in Chiari I malformation. *Am J Hum Genet*. 2021;108:530-531. doi: 10.1016/j.ajhg.2021.01.014

medRxiv preprint doi: https://doi.org/10.1101/2023.12.01.23299300; this version posted December 4, 2023. The copyright holder for this preprint (which was not certified by peer review) is the author/funder, who has granted medRxiv a license to display the preprint in perpetuity. All rights reserved. No reuse allowed without permission.

15. Zhao S, Mekbib KY, van der Ent MA, Allington G, Prendergast A, Chau JE, Smith H, Shohfi J, Ocken J, Duran D, et al. Genetic dysregulation of an endothelial Ras signaling network in vein of Galen malformations. *bioRxiv*. 2023. doi: 10.1101/2023.03.18.532837

16. Hale AT, He J, Jones J. Integrative Genomics Analysis Implicates Decreased FGD6 Expression Underlying Risk of Intracranial Aneurysm Rupture. *Neurosurgery Practice*. 2022;3.

17. Winkler EA, Wu D, Gil E, McCoy D, Narsinh K, Sun Z, Mueller K, Ross J, Kim H, Weinsheimer S, et al. Endoluminal Biopsy for Molecular Profiling of Human Brain Vascular Malformations. *Neurology*. 2022. doi: 10.1212/wnl.0000000000200109

18. Cooke DL, Bauer D, Sun Z, Stillson C, Nelson J, Barry D, Hetts SW, Higashida RT, Dowd CF, Halbach VV, et al. Endovascular biopsy: Technical feasibility of novel endothelial cell harvesting devices assessed in a rabbit aneurysm model. *Interv Neuroradiol*. 2015;21:120-128. doi: 10.15274/inr-2014-10103

19. Alexander MD, Sun Z, Conrad MB, Cooke DL. Assessment of cell yield among different devices for endovascular biopsy to harvest vascular endothelial cells. *Biotechniques*. 2019;66:34-36. doi: 10.2144/btn-2018-0099

20. Sun Z, Su H, Long B, Sinclair E, Hetts SW, Higashida RT, Dowd CF, Halbach VV, Cooke DL. Endothelial cell high-enrichment from endovascular biopsy sample by laser capture microdissection and fluorescence activated cell sorting. *J Biotechnol*. 2014;192 Pt A:34-39. doi: 10.1016/j.jbiotec.2014.07.434

21. Narsinh KH, Narsinh K, McCoy DB, Sun Z, Halabi C, Meisel K, Tihan T, Chaganti K, Amans MR, Halbach VV, et al. Endovascular Biopsy of Vertebrobasilar Aneurysm in Patient With Polyarteritis Nodosa. *Front Neurol*. 2021;12:697105. doi: 10.3389/fneur.2021.697105

22. Winkler E, Wu D, Gil E, McCoy D, Narsinh K, Sun Z, Mueller K, Ross J, Kim H, Weinsheimer S, et al. Endoluminal Biopsy for Molecular Profiling of Human Brain Vascular Malformations. *Neurology*. 2022;98:e1637-e1647. doi: 10.1212/wnl.0000000000200109

23. Lasjaunias PL, Chng SM, Sachet M, Alvarez H, Rodesch G, Garcia-Monaco R. The management of vein of Galen aneurysmal malformations. *Neurosurgery*. 2006;59:S3-184.

24. Winkler E, Wu D, Gil E, McCoy D, Narsinh K, Sun Z, Mueller K, Ross J, Kim H, Weinsheimer S. Endoluminal biopsy for molecular profiling of human brain vascular malformations. *Neurology*. 2022;98:e1637-e1647.

25. Feng L, Stern DM, Pile-Spellman J. Human endothelium: endovascular biopsy and molecular analysis. *Radiology*. 1999;212:655-664.

26. Cooke DL, McCoy DB, Halbach VV, Hetts SW, Amans MR, Dowd CF, Higashida RT, Lawson D, Nelson J, Wang C-Y. Endovascular biopsy: in vivo cerebral aneurysm endothelial cell sampling and gene expression analysis. *Translational stroke research*. 2018;9:20-33.

27. Cooke DL, Su H, Sun Z, Guo Y, Guo D, Saeed MM, Hetts SW, Higashida RT, Dowd CF, Young WL. Endovascular biopsy: evaluating the feasibility of harvesting endothelial cells using detachable coils. *Interventional Neuroradiology*. 2013;19:399-408.

28. Satija R, Farrell JA, Gennert D, Schier AF, Regev A. Spatial reconstruction of single-cell gene expression data. *Nature biotechnology*. 2015;33:495-502. doi: 10.1038/nbt.3192

medRxiv preprint doi: https://doi.org/10.1101/2023.12.01.23299300; this version posted December 4, 2023. The copyright holder for this preprint (which was not certified by peer review) is the author/funder, who has granted medRxiv a license to display the preprint in perpetuity. All rights reserved. No reuse allowed without permission.

29. Gawad C, Koh W, Quake SR. Single-cell genome sequencing: current state of the science. *Nature Reviews Genetics*. 2016;17:175-188.

30. Winkler EA, Kim CN, Ross JM, Garcia JH, Gil E, Oh I, Chen LQ, Wu D, Catapano JS, Raygor K, et al. A single-cell atlas of the normal and malformed human brain vasculature. *Science (New York, NY)*. 2022:eabi7377. doi: 10.1126/science.abi7377

31. Raybaud C, Strother C, Hald J. Aneurysms of the vein of Galen: embryonic considerations and anatomical features relating to the pathogenesis of the malformation. *Neuroradiology*. 1989;31:109-128.

32. Duran D, Zeng X, Jin SC, Choi J, Nelson-Williams C, Yatsula B, Gaillard J, Furey CG, Lu Q, Timberlake AT. Mutations in chromatin modifier and ephrin signaling genes in vein of Galen malformation. *Neuron*. 2019;101:429-443. e424.

33. Vivanti A, Ozanne A, Grondin C, Saliou G, Quevarec L, Maurey H, Aubourg P, Benachi A, Gut M, Gut I, et al. Loss of function mutations in EPHB4 are responsible for vein of Galen aneurysmal malformation. *Brain*. 2018;141:979-988. doi: 10.1093/brain/awy020

34. Revencu N, Boon LM, Mendola A, Cordisco MR, Dubois J, Clapuyt P, Hammer F, Amor DJ, Irvine AD, Baselga E, et al. RASA1 mutations and associated phenotypes in 68 families with capillary malformation-arteriovenous malformation. *Hum Mutat*. 2013;34:1632-1641. doi: 10.1002/humu.22431

35. Nikolaev SI, Vetiska S, Bonilla X, Boudreau E, Jauhiainen S, Rezai Jahromi B, Khyzha N, DiStefano PV, Suutarinen S, Kiehl TR, et al. Somatic Activating KRAS Mutations in Arteriovenous Malformations of the Brain. *N Engl J Med*. 2018;378:250-261. doi: 10.1056/NEJMoa1709449

36. Wälchli T, Bisschop J, Carmeliet P, Zadeh G, Monnier PP, De Bock K, Radovanovic I. Shaping the brain vasculature in development and disease in the single-cell era. *Nat Rev Neurosci*. 2023;24:271-298. doi: 10.1038/s41583-023-00684-y

37. Winkler EA, Kim CN, Ross JM, Garcia JH, Gil E, Oh I, Chen LQ, Wu D, Catapano JS, Raygor K, et al. A single-cell atlas of the normal and malformed human brain vasculature. *Science (New York, NY)*. 2022;375:eabi7377. doi: 10.1126/science.abi7377

38. Karar J, Maity A. PI3K/AKT/mTOR pathway in angiogenesis. *Frontiers in molecular neuroscience*. 2011;4:51.

39. Kranenburg O, Gebbink MF, Voest EE. Stimulation of angiogenesis by Ras proteins. *Biochimica et Biophysica Acta (BBA)-Reviews on Cancer*. 2004;1654:23-37.

40. Al-Samkari H, Eng W. A precision medicine approach to hereditary hemorrhagic telangiectasia and complex vascular anomalies. *J Thromb Haemost*. 2022;20:1077-1088. doi: 10.1111/jth.15715

41. Maynard K, LoPresti M, Iacobas I, Kan P, Lam S. Antiangiogenic agent as a novel treatment for pediatric intracranial arteriovenous malformations: case report. *J Neurosurg Pediatr*. 2019:1-7. doi: 10.3171/2019.7.Peds1976

42. Nicholson CL, Flanagan S, Murati M, Boull C, McGough E, Ameduri R, Weigel B, Maguiness S. Successful management of an arteriovenous malformation with trametinib in a patient with capillary-malformation arteriovenous malformation syndrome and cardiac compromise. *Pediatr Dermatol*. 2022;39:316-319. doi: 10.1111/pde.14912

medRxiv preprint doi: https://doi.org/10.1101/2023.12.01.23299300; this version posted December 4, 2023. The copyright holder for this preprint (which was not certified by peer review) is the author/funder, who has granted medRxiv a license to display the preprint in perpetuity. All rights reserved. No reuse allowed without permission.

43. Triana P, Dore M, Cerezo VN, Cervantes M, Sánchez AV, Ferrero MM, González MD, Lopez-Gutierrez JC. Sirolimus in the Treatment of Vascular Anomalies. *Eur J Pediatr Surg*. 2017;27:86-90. doi: 10.1055/s-0036-1593383

44. Grabiner BC, Nardi V, Birsoy K, Possemato R, Shen K, Sinha S, Jordan A, Beck AH, Sabatini DM. A diverse array of cancer-associated MTOR mutations are hyperactivating and can predict rapamycin sensitivity. *Cancer Discov*. 2014;4:554-563. doi: 10.1158/2159-8290.Cd-13-0929

45. Adams DM, Trenor CC, 3rd, Hammill AM, Vinks AA, Patel MN, Chaudry G, Wentzel MS, Mobberley-Schuman PS, Campbell LM, Brookbank C, et al. Efficacy and Safety of Sirolimus in the Treatment of Complicated Vascular Anomalies. *Pediatrics*. 2016;137:e20153257. doi: 10.1542/peds.2015-3257

46. Nguyen HL, Boon LM, Vikkula M. Vascular Anomalies Caused by Abnormal Signaling within Endothelial Cells: Targets for Novel Therapies. *Semin Intervent Radiol*. 2017;34:233-238. doi: 10.1055/s-0037-1604296

47. Lekwuttikarn R, Lim YH, Admani S, Choate KA, Teng JMC. Genotype-Guided Medical Treatment of an Arteriovenous Malformation in a Child. *JAMA dermatology*. 2019;155:256-257. doi: 10.1001/jamadermatol.2018.4653

medRxiv preprint doi: https://doi.org/10.1101/2023.12.01.23299300; this version posted December 4, 2023. The copyright holder for this preprint (which was not certified by peer review) is the author/funder, who has granted medRxiv a license to display the preprint in perpetuity. All rights reserved. No reuse allowed without permission.

	Age range at ETS	Ethnicity	Access route	Vessel	Coil type	Experimental cell yield (#)
VOGMUAB_001	Child	Black	Arterial	Subependymal branch of L P1	Balt Barricade (1x2mm)	256
VOGMUAB_001	Child	Black	Venous	Ampulla	Cerenovous (3x6mm)	217
VOGMUAB_002	Child	White	Venous	PVM	Cerenovus Deltafill (8x35mm)	20
VOGMUAB_002	Child	White	Venous	PVM	Cerenovus Deltafill (8x35mm)	80
VOGMUAB_003	Child	Mixed	Venous	PVM	Balt Barricade (6mm x 20cm)	17
VOGMUAB_005	Infant	Black	Arterial	R posterior choroidal artery	Balt Barricade (1mm x 3cm)	24
VOGMUAB_006	Child	Black	Venous	PVM	Cerenovus Galaxy G3 12 (12mm x 30cm)	178
VOGMUAB_010	Neonate	White	Arterial	L posterior choroidal artery	Balt Barricade (4mm x 8cm)	18
VOGMUAB_010	Neonate	White	Venous	Ampulla	Balt Barricade (4mm x 6cm)	96
VOGMUAB_010	Neonate	White	Venous	Ampulla	Balt Barricade (5mm x 10cm)	78

Table 1. Overview of ETS results from patients with VOGM indicating participant ID, age at ETS, ethnicity, route of access for routine treatment and ETS, vessel sampling, coil type used for ETS, and experimental cell (i.e., CD31+, CD45-) yield. PVM = prosencephalic vein of Markowski. No patient identifiers were available to anyone outside of the research group. Age ranges were determined as follows: neonates (< 1 month), infant (1 month $\leq$ 2 years), and children ($\geq$ 2 years).

medRxiv preprint doi: https://doi.org/10.1101/2023.12.01.23299300; this version posted December 4, 2023. The copyright holder for this preprint (which was not certified by peer review) is the author/funder, who has granted medRxiv a license to display the preprint in perpetuity. All rights reserved. No reuse allowed without permission.

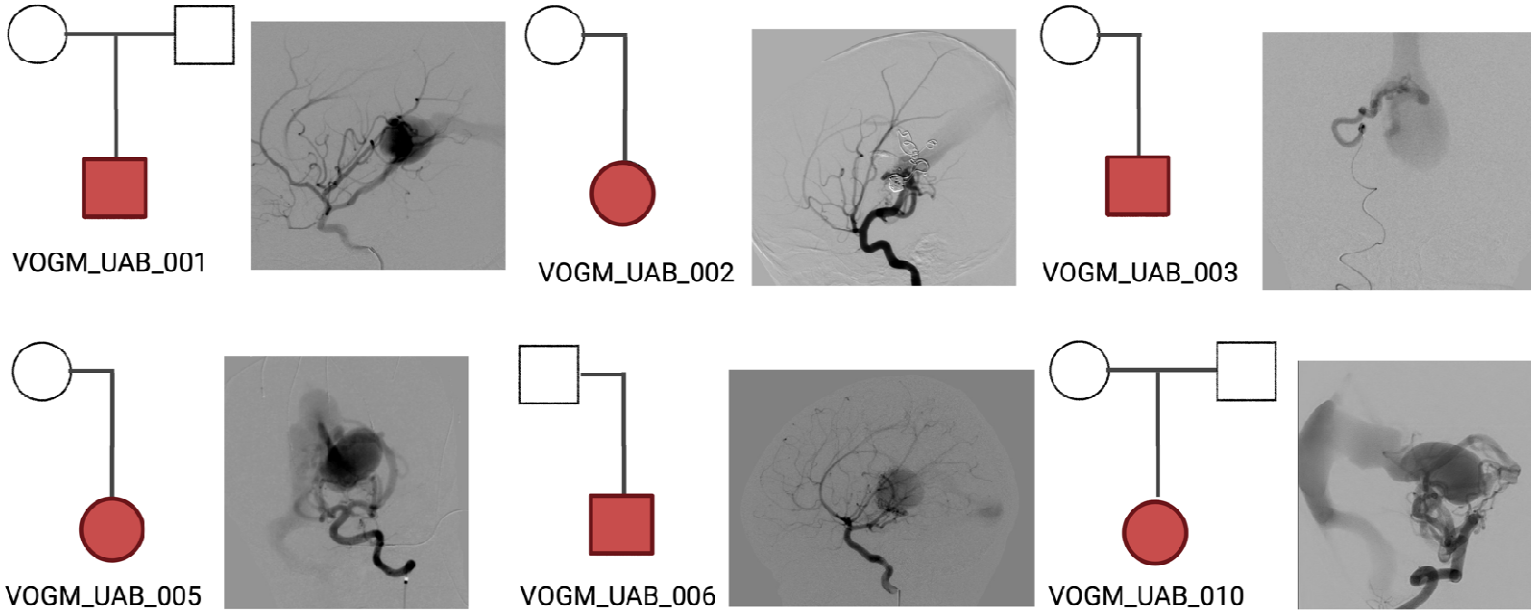

***Red indicates endothelial sampling (ETS) performed**

Figure 1. Pedigrees of VOGM families where the VOGM patient (proband) underwent endothelial sampling (red). Males are indicated with squares and females indicated with circles. No patient identifiers were available to anyone outside of the research group.

medRxiv preprint doi: https://doi.org/10.1101/2023.12.01.23299300; this version posted December 4, 2023. The copyright holder for this preprint (which was not certified by peer review) is the author/funder, who has granted medRxiv a license to display the preprint in perpetuity. All rights reserved. No reuse allowed without permission.

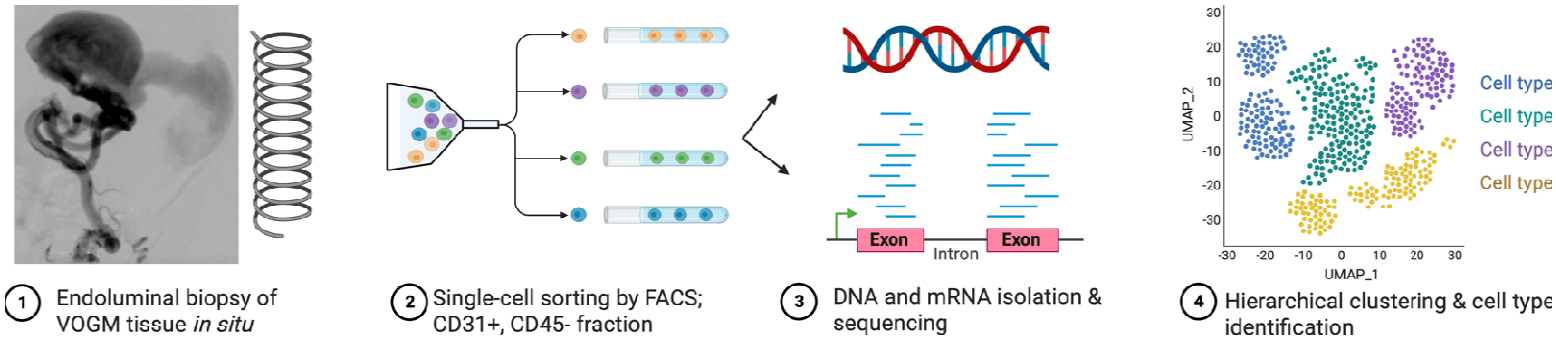

Figure 2. Overview of our approach to elucidate the genetic basis of VOGM. Figure was designed using Biorender.

medRxiv preprint doi: https://doi.org/10.1101/2023.12.01.23299300; this version posted December 4, 2023. The copyright holder for this preprint (which was not certified by peer review) is the author/funder, who has granted medRxiv a license to display the preprint in perpetuity. All rights reserved. No reuse allowed without permission.

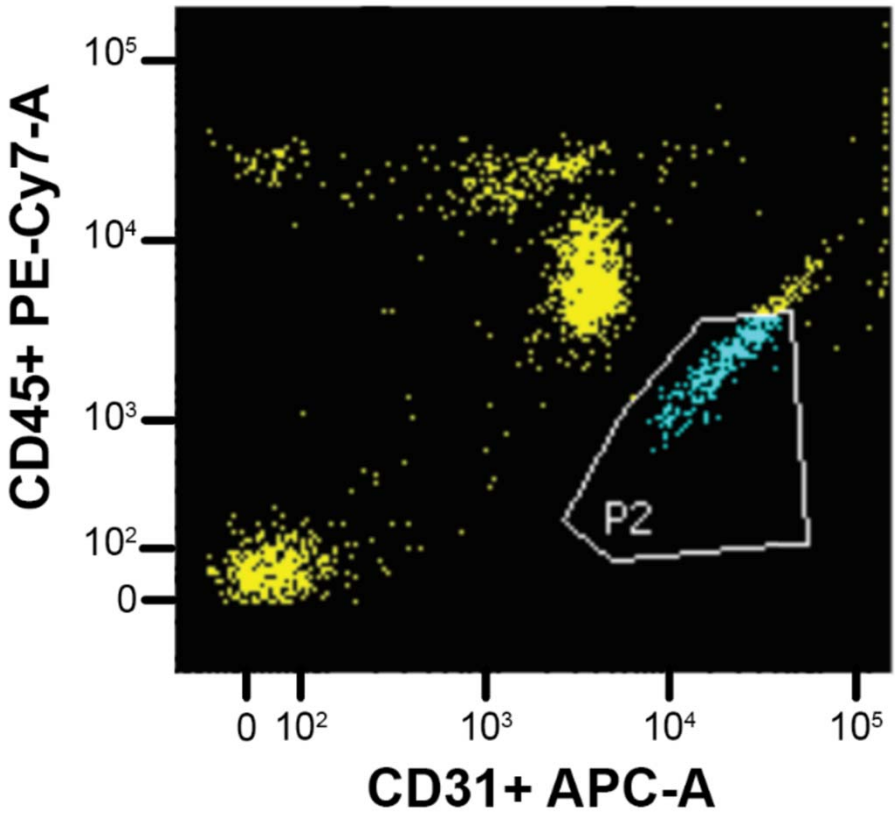

Figure 3. Representative flow cytometry plot demonstrating experimental 'endothelial' cell population (blue; CD31+, CD45-) obtained during ETS of VOGM lesion. The yellow cells represent the excluded fraction which are likely monocyte and red blood cell in origin.

medRxiv preprint doi: https://doi.org/10.1101/2023.12.01.23299300; this version posted December 4, 2023. The copyright holder for this preprint (which was not certified by peer review) is the author/funder, who has granted medRxiv a license to display the preprint in perpetuity. All rights reserved. No reuse allowed without permission.

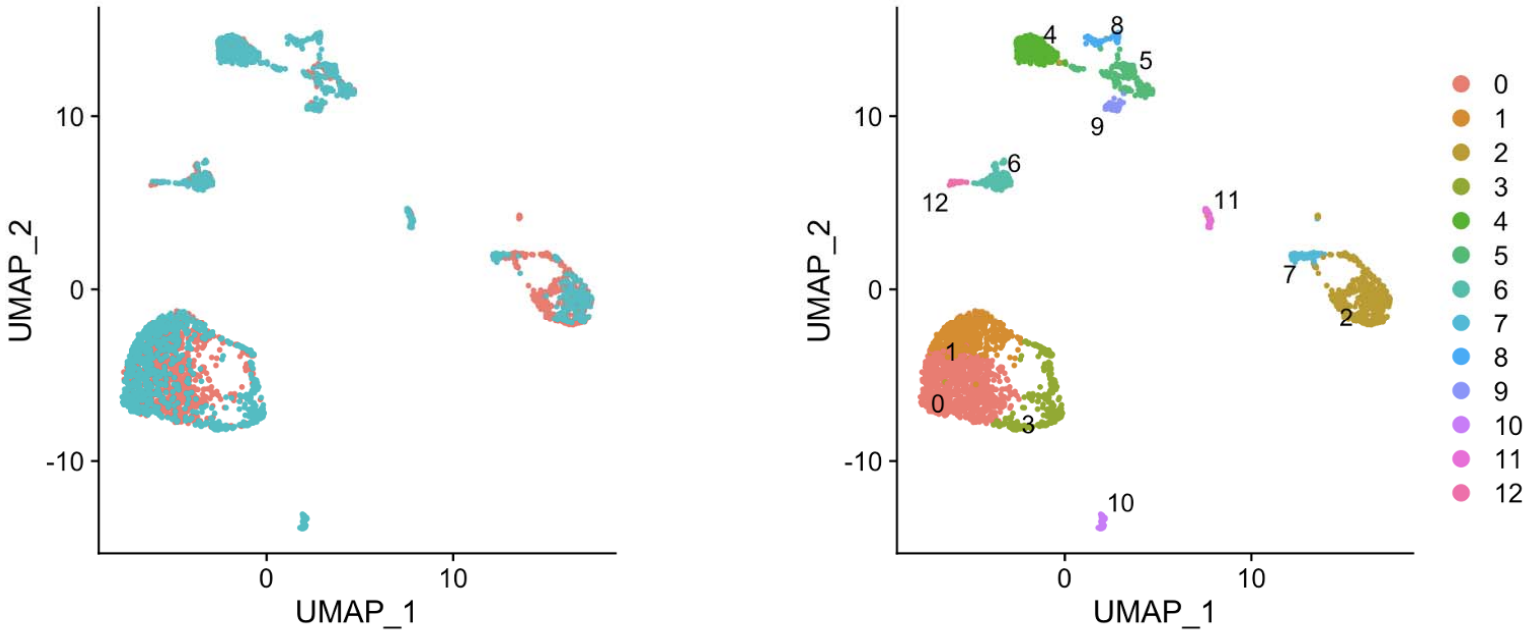

Figure 4. Single cell RNA sequencing (scRNA) of VOGM *in situ* identifies distinct cell types. (A) Pink represents ECs (CD31+, CD45 -) obtained from the femoral access sheath and blue represents *in situ* VOGM ECs obtained by ETS. (B) Hierarchical clustering identifies 12 unique cell populations across control and VOGM ECs using a published cerebrovascular transcriptome atlas for annotation.[30]