medRxiv preprint doi: https://doi.org/10.1101/2023.12.01.23297348; this version posted December 5, 2023. The copyright holder for this preprint (which was not certified by peer review) is the author/funder, who has granted medRxiv a license to display the preprint in perpetuity. All rights reserved. No reuse allowed without permission.

Chemical/technical risk analysis of a new multidirectional nebulizer (MDN) and its clinical implementation for the safe administration of Pressurized Intraperitoneal Aerosol Chemotherapy (MDN-PIPAC)

Short title:
MDN-PIPAC is feasible and safe

Fabian Kockelmann, MD[1], Daniel Göhler, Dipl.-Ing.[2,3], Sarah Barbey[4], Mehdi Ouaissi, Prof. MD, PhD[5,6,] Jürgen Zieren, Prof, MD[1,] Urs Giger-Pabst, Prof, MD[5,7]

[1] Department of Surgery, Klinikum Dortmund, Hospital of the Witten/Herdecke University, Germany
[2] Topas GmbH, Dresden, Germany
[3] Research Group Mechanical Process Engineering, Institute of Process Engineering and Environmental Technology, Technische Universität Dresden, Dresden, Germany
[4] Plateforme Pixanim, INRAE PRC, 37380, Nouzilly, France
[5] EA4245 Transplantation, Immunologie, Inflammation, Université de Tours, France
[6] Department of Digestive, Oncological, Endocrine, Hepato-Biliary, Pancreatic and Liver Transplant Surgery, University Hospital of Tours, France
[7] Fliedner Fachhochschule, University of Applied Sciences, Düsseldorf, Germany

Correspondence:
Professor Urs Giger-Pabst, MD
Fliedner Fachhochschule
University of Applied Sciences Düsseldorf, Germany
Phone: +49 (0) 163 729 44 07
Email: ursgiger@gmx.net

NOTE: This preprint reports new research that has not been certified by peer review and should not be used to guide clinical practice.

medRxiv preprint doi: https://doi.org/10.1101/2023.12.01.23297348; this version posted December 5, 2023. The copyright holder for this preprint (which was not certified by peer review) is the author/funder, who has granted medRxiv a license to display the preprint in perpetuity. All rights reserved. No reuse allowed without permission.

KEY WORDS

PIPAC, Multi-directional nebulizer (MDN), chemical compatibility, chemical risk analysis, CT-peritoneography, clinical safety, feasibility

ABBREVIATIONS

AET	Analytical Evaluation Threshold (ISO 10993-18 (2020)
BSA	Body Surface Area calculated according to DuBois
CE	Conformité Européenne
DGAV	Deutsche Gesellschaft für Allgemein- und Viszeralchirurgie
ECOG	Eastern Cooperative Oncology Group
FDA	U.S. Food and Drug Administration
GC-MS	Gas Chromatography coupled with Mass Spectrometry
HSGC-MS	Head-space Gas Chromatography coupled with Mass Spectrometry
IC	Ion Chromatography
ICP-OES	Inductively Coupled Plasma Atomic Emission Spectrometry
LC-MS	Liquid phase chromatography coupled to a Mass Spectrometer
MDN	Multi-Directional Nebulizer (Quattro Jet™, REGER, Medizintechnik GmbH, Villigendorf, Germany)
PCI	Peritoneal Carcinomatosis Index according to Sugarbaker
PIPAC	Pressurized IntraPeritoneal Aerosol Chemotherapy
PSM	Peritoneal Surface Malignancies
RIPAC	Rotational intraperitoneal aerosol chemotherapy

medRxiv preprint doi: https://doi.org/10.1101/2023.12.01.23297348; this version posted December 5, 2023. The copyright holder for this preprint (which was not certified by peer review) is the author/funder, who has granted medRxiv a license to display the preprint in perpetuity. All rights reserved. No reuse allowed without permission.

SDN	Single direction nebulizer
HD/HP PIPAC	High dosage/high pressure pressurized intraperitoneal chemotherapy

AUTHOR CONTRIBUTIONS

Fabian Kockelmann, Urs Giger-Pabst: study design, coordination of study, data acquisition, data interpretation, logistics, drafting of manuscript and critical revision for important content of the manuscript

Daniel Göhler and Mehdi Ouaissi: drafting of the manuscript and intellectual and scientific contributions depending on their field of expertise

Sarah Barbey: study protocol, coordination of animal experiments and perioperative management of animals

Jürgen Zieren: study design, PIPAC procedures, data acquisition, data interpretation, logistics, drafting of manuscript and critical revision for important content of the manuscript

DISCLOSURE

All authors have no conflicts of interest or financial ties to disclose. The animal experiments, were funded by the Association Tourangelle de recherche en oncologie du val de Loire (AT-ROVL). All data produced in the present study are available upon reasonable request to the authors All data produced in the present study are available upon reasonable request to the authors.

medRxiv preprint doi: https://doi.org/10.1101/2023.12.01.23297348; this version posted December 5, 2023. The copyright holder for this preprint (which was not certified by peer review) is the author/funder, who has granted medRxiv a license to display the preprint in perpetuity. All rights reserved. No reuse allowed without permission.

MINI ABSTRACT

Toxicological analyses confirm that doxorubicin, cisplatin and oxaliplatin nebulized with the MDN do not release leachables that pose a toxicological risk to patients. Through technical risk analysis and PIPAC simulations, a safety concept for the administration of MDN-PIPAC was established. No technical/medical intraoperative adverse events were observed. The perioperative course was comparable to that of the conventional axial single-direction nebulizer (SDN) PIPAC.

ABSTRACT

Background/Aim: To test the chemoresistance of a multi-directional nebulizer (MDN) and to establish and implement a perioperative clinical safety concept for its clinical use to deliver pressurised intraperitoneal aerosol chemotherapy (MDN-PIPAC).

Study design: Ex-vivo nebulization of cytostatic drugs with the MDN device to assess chemoresistance/toxicological risks. Establishment of a perioperative safety concept for the clinical administration of MDN-PIPAC by ex- and in-vivo porcine simulation studies. Unicentric case series of 30 MDN-PIPACs in patients with peritoneal surface malignancies (PSM). Endpoints were intraoperative adverse events and perioperative complications (Clavien-Dindo).

Results: Toxicological studies/risk assessment confirm the safety of administering PIPAC with the MDN. The horizontal nozzles must protrude at least 7 mm beyond the most distal end of the trocar tip and lateral tilting should be prevented by fixation of the device in a single-arm holder. A total of 21 patients (male/female ratio: 2:1) with a mean age of 62 (range: 38-86) years underwent 30 consecutive MDN-PIPACs for peritoneal surface malignancies of different origin. ECOG 0 and 1 were seen in five and 16 patients,

medRxiv preprint doi: https://doi.org/10.1101/2023.12.01.23297348; this version posted December 5, 2023. The copyright holder for this preprint (which was not certified by peer review) is the author/funder, who has granted medRxiv a license to display the preprint in perpetuity. All rights reserved. No reuse allowed without permission.

respectively. Thirteen, seven and one patient underwent one, two and three MDN-PIPACs, respectively. Two patients received only one cycle of MDN-PIPAC because they were considered candidates for cytoreductive surgery and heated intraperitoneal chemotherapy. There were no intraoperative technical/medical problems observed. Four patients suffered from postoperative grade I complications.

Conclusions: Compounds leached during chemotherapy nebulization with the MDN are toxicologically safe. MDN-PIPAC administration is safe and the postoperative course comparable to that of the conventional PIPAC nebulizer.

1.0 INTRODUCTION

For more than a decade, pressurised intraperitoneal aerosol chemotherapy (PIPAC) has been used worldwide for the treatment of peritoneal surface malignancies (PSM). Clinical results have been encouraging, but data from prospective randomised trials clearly demonstrating the efficacy of this treatment are still lacking [1 - 3]. A common feature of all currently available nebulizers for PIPAC is that all nebulizers have only one atomizing unit (axial single-direction nebulizer (SDN)), which ejects the chemotherapy droplets in an axial direction. The majority (97.5% by volume) of the nebulized chemotherapy directly impacts with the peritoneum located below the atomizer orifice [4]. It has also been suggested that the locally high drug deposition that occurs with the use of conventional PIPAC nebulizers leads to potential local toxicity that could result in an increase in perioperative complications, especially when additional surgical procedures such as complex adhesiolysis or bowel resection are performed concurrently with PIPAC [5 - 7]. However, recent clinical data seem to relativise an increased complication rate with PIPAC and concomitant extended surgery [8]. However, for such reasons, PIPAC nebulizer technology has been extended by integrating three additional atomizer units into the nebulizer head in the horizontal plane at a distance of

medRxiv preprint doi: https://doi.org/10.1101/2023.12.01.23297348; this version posted December 5, 2023. The copyright holder for this preprint (which was not certified by peer review) is the author/funder, who has granted medRxiv a license to display the preprint in perpetuity. All rights reserved. No reuse allowed without permission.

120 degrees. Initial ex-vivo data from such multi-directional nebulizer (MDN) report an improved spatial drug distribution [2, 9].

For some time now, a CE approved MDN has been available for clinical off-label PIPAC use (MDN-PIPAC). However, since there are still no documented in-vivo applications worldwide, we have decided to conduct additional extensive preclinical testing before the first clinical application. The aim of this study was to i) investigate any toxicological risk posed by leachables from the device when used in conjunction with cytotoxic drugs, ii) develop an intraoperative safety concept for the administration of MDN-PIPAC using an ex-vivo PIPAC model, in-vivo animal CT-peritoneography and iii) retrospective analysis of a consecutive case series of 30 patients to evaluate the perioperative safety of MDN-PIPAC in patients with peritoneal surface malignancies (PSM).

2.0 MATERIAL & METHODS

2.1 Research sites and institutes: Nebulization for cytostatic drug compatibility/toxicology studies of the MDN and the in-vivo animal experiments were carried out at the French National Research Institute for Agriculture, Food and Environment (INRAE), Centre Val de Loire Nouzilly, France. Chemical characterisation and toxicological evaluation by RESCOLL, Pessac, France and TentaConsult Pharma & Med GmbH, Münster, Germany, respectively. The ex-vivo MDN-PIPAC simulation studies and the Schlieren investigations were carried out at the Bauhaus University Weimar, Germany.

2.2 MDN chemotherapy compatibility study: Doxorubicin, cisplatin and oxaliplatin were purchased from Hexal AG, Holzkirchen, Germany, Accord Healthcare B.V. Utrecht, The Netherlands and Medac GmbH, Wedel, Germany. Drug doses (doxorubicin 6 mg, cisplatin 30 mg and oxaliplatin 120 mg per m^2 of body surface area (BSA)) were studied according to data of phase I safety studies and clinical use [10 - 12]. A patient with a height of 1.90 m and a

medRxiv preprint doi: https://doi.org/10.1101/2023.12.01.23297348; this version posted December 5, 2023. The copyright holder for this preprint (which was not certified by peer review) is the author/funder, who has granted medRxiv a license to display the preprint in perpetuity. All rights reserved. No reuse allowed without permission.

weight of 100 kg was assumed as scenario. The BSA was calculated according to the DuBois formula [13]. Glucose 5% and NaCl 0.9% were purchased from B. Braun, Melsungen, Germany. Oxaliplatin was diluted with glucose 5%, doxorubicin and cisplatin with NaCl 0.9% to a total of 50 ml and 150 ml, respectively. For blank control solution, doxorubicin 1.368 mg was diluted with 5 ml of 0.9% NaCl 0.9% and cisplatin 6.84 mg diluted with 15 ml of 0.9% NaCl 0.9% to a total volume 20 ml. Oxaliplatin 36.48 mg was diluted with 20 ml of 5% Glucose. Blank control solutions were immediately filled into sterile glass bottles (ref. # FRAA-250-60, Labbox GmbH, Düsseldorf, Germany) and stored protected from light at 4 °C. The chemotherapy solutions for nebulization experiments were filled into syringes (ELS 200 ml (S), MEDTRON AG, Saarbrücken, Germany), the syringe instated into the high-pressure injector head (Accutron® HP-D Vision, MEDTRON AG, Saarbrücken, Germany), vented and then connected to the high-pressure line of the MDN (Quattro Jet™, REGER Medizintechnik GmbH, Villigendorf, Germany). The shaft of the MDN was wrapped with sterile surgical compress proximal to the head of the nebulizer and then positioned vertically in a tight and stable position in the neck of a sterile 250 ml glass bottle (ref. # FRAA-250-60, Labbox GmbH, Düsseldorf, Germany). Nebulization could take place unhindered with the nebulizer head in the body of the bottle at a flow rate of 1.5 ml/s with an upper pressure limit of 300 psi. Nebulization was undertaken under a vertical laminar air flow bench. Doxorubicin and Cisplatin were nebulized one after the other but into the sample bottle. All experiments were performed in triplicates. The sample and blank control solution bottles were sealed air tight immediately after the experiments and stored protected from light at 4°C. Transport of the samples to the laboratory for further processing by courier within 4 hours while refrigeration was maintained.

2.3 Chemical characterisation and toxicological risk assessment: The MDN device was categorised according to ISO 10993-1:2018 and the chemical characterisation was performed

medRxiv preprint doi: https://doi.org/10.1101/2023.12.01.23297348; this version posted December 5, 2023. The copyright holder for this preprint (which was not certified by peer review) is the author/funder, who has granted medRxiv a license to display the preprint in perpetuity. All rights reserved. No reuse allowed without permission.

according to ISO 10993-18:2020. Head-Space Gas Chromatography coupled with Mass Spectrometry (HSGC-MS) were used for detection of volatile organic compounds, Gas Chromatography coupled with Mass Spectrometry (GC-MS) for detection of semi volatile organic compounds, Liquid Phase Chromatography coupled to a Mass Spectrometer (LC-MS) for detection of non-volatile organic compounds, Inductively Coupled Plasma Atomic Emission Spectrometry (ICP-OES) for quantification of the inorganic elements and Ion Chromatography (IC) for quantification of the ions. The Analytical Evaluation Threshold (AET) according to ISO 10993-18:2020 was applied. AET defines the threshold below which leachable or extractable substances cannot be identified or quantified and therefore it can be assumed without further evaluation that such a substance does not pose a toxicological risk.

The parameters used for the toxicological risk assessment were set to consider the worst case. Three consecutive MDN-PIPAC administrations were assumed with no time interval in between (instead of a treatment interval of four to six weeks between each PIPAC cycle). In addition, the exposure of children with a body weight of 10 kg was calculated with the amount used for the treatment of an adult. The toxicological risk associated with leachables was assessed by collecting data and identifying critical health endpoints through literature searches and toxicological risk assessment from PubChem (HSDB), PubMed, ChemIDplus, ECHA databases and various other online sources and databases (e.g., FDA.gov) in accordance with ISO 10993-17:2002

2.4 Preclinical assessment of the MDN-PIPAC safety checklist and Schlieren imaging: As a first step, a team of two surgeons and one PIPAC nurse analysed whether the use of the MDN could result in additional intraoperative risks or hazards for healthcare personnel. Potential risks were assessed for clinical relevance. Appropriate safety measures were then developed and integrated into our existing intraoperative PIPAC safety checklist [14]. In order to check whether a mispositioning of the MDN head in the trocar shaft could lead to a

medRxiv preprint doi: https://doi.org/10.1101/2023.12.01.23297348; this version posted December 5, 2023. The copyright holder for this preprint (which was not certified by peer review) is the author/funder, who has granted medRxiv a license to display the preprint in perpetuity. All rights reserved. No reuse allowed without permission.

possible retrograde leakage of chemotherapy aerosol into the environment, we additionally performed ex-vivo streaking studies on an established PIPAC model [15]. In a second step, using this adapted intraoperative PIPAC safety checklist, the team repeatedly simulated MDN-PIPAC applications in the operating room using NaCl 0.9% (B. Braun, Melsungen, Germany) on an established ex-vivo PIPAC model [15] to test the coherence of the adapted intraoperative PIPAC safety measures and the safety checklist. In summary, a final intraoperative MDN-PIPAC safety checklist was developed for in- vivo animal experiments.

2.5 In-vivo animal MDN-PIPAC and CT-peritoneography:

Domestic pigs were handled and cared for according to all relevant guidelines by authorised investigators. The study (file # 40583) was approved by the French Ministry of Higher Education and Research (Ministère de l'enseignement supérieur et de la recherche). A total of three male animals weighing from 47 to 42 kg were used. Anaesthesia was induced by intramuscular injection of ketamine 20 mg/kg, xylazine 2 mg/kg, and a subcutaneous injection of atropine 0.02 mg/kg, and then completed by endotracheal intubation. Animals were maintained under anaesthesia by isoflurane 3%, intravenous sufentanil, and cisatracurium. The animals were fixed in a supine position in the CT-scanner (SOMATOM Definition AS 128, Siemens, Germany) to deliver HP/HD PIPAC described previously [12]. The MDN was placed at the centre of the abdomen in a perpendicular position so that the horizontal nozzle openings protruded approx. 7 mm beyond the end of the 12-mm trocar. The orientation of these horizontal nozzle openings was chosen so that one nozzle was directed into the right and left upper abdomen and the third nozzle into the small pelvis. Another 5-mm trocar was inserted into the abdominal cavity to monitor the position of the nozzle head with a 5 mm camera and the nebulization process. CT-peritoneography was performed using a modified technique previously described [16]. For this purpose, 100 ml Imeron® 300 (Bracco Imaging GmbH, Konstanz, Germany) was diluted in 900 ml NaCl 0.9% (B Braun, Melsungen,

medRxiv preprint doi: https://doi.org/10.1101/2023.12.01.23297348; this version posted December 5, 2023. The copyright holder for this preprint (which was not certified by peer review) is the author/funder, who has granted medRxiv a license to display the preprint in perpetuity. All rights reserved. No reuse allowed without permission.

Germany) in a ratio of 1:10. 150 ml of this solution was then administered for HP/HP-PIPAC CT-peritoneography at a flow rate of 1.5 ml/s (Accutron CT-D Vision, MEDTRON AG, Saarbrücken, Germany). CT-peritoneography was performed immediately at the end of HP/HD-PIPAC. After CT acquisition, the animals were immediately euthanized by intravenous injection of phenobarbital.

2.6 Patients' selection criteria for MDN-PIPAC: The clinical study was performed in line with the guidelines of the Declaration of Helsinki at the Department of Surgery, Klinikum Dortmund, University Hospital of the University Witten/Herdecke, Germany. All patients gave oral and written informed consent. For the clinical trial, the approval of the Ethics Committee of the Medical Faculty of the University of Münster/Medical Association Westphalia-Lippe in Germany (file # 2021-360-f-s) and the German Clinical Trials Register at https://www.drks.de/DRKS00033077 was obtained.

All patients had histologically confirmed primary or metastatic peritoneal surface malignancies (PSM). Patients were selected by a multidisciplinary tumor board accredited by the German Society for General and Visceral Surgery (DGAV). The inclusion criteria have already been described in detail [10]. The time interval between cycles was between four to six weeks. Systemic chemotherapy was discontinued one week prior and after MDN-PIPAC. Patients were informed that PIPAC treatment was not provided within the framework of evidence-based therapy guidelines. All patients gave their oral and written consent. All procedures were performed as previously described in detail [10, 12] and were performed by one senior surgeon (J.Z.). Oxaliplatin at a dose of 120.0 mg/m^2 body surface area (BSA) diluted in a total of 150 ml glucose 5% was administered in case of PSM of colorectal and appendiceal primary tumours. For all other tumour entities, doxorubicin 6.0 mg/m^2 BSA diluted in 50 ml NaCl 0.9% followed by cisplatin 30.0 mg/m^2 BSA diluted in 150 ml NaCl 0.9% [10 - 12]. According to the manufacturer's instructions for use, the MDN was operated

medRxiv preprint doi: https://doi.org/10.1101/2023.12.01.23297348; this version posted December 5, 2023. The copyright holder for this preprint (which was not certified by peer review) is the author/funder, who has granted medRxiv a license to display the preprint in perpetuity. All rights reserved. No reuse allowed without permission.

at a liquid fluid volume flow of 1.5 ml/s with an upper pressure limit of 300 psi. Access to the peritoneal cavity was always obtained via an infraumbilical open Hasson approach. Before starting the drug nebulization, the capnoperitoneal pressure was increased from 12 to 20 mmHg and then kept constant for 30 minutes.

2.7 Perioperative short-term outcome and data acquisition: Retrospective data acquisition of a consecutive case series of 30 patients. The entire staging laparoscopy, including documentation of the Sugarbaker PCI score, the amount of ascites and the quality of chemotherapy nebulization, is monitored by video according to our standards for intraoperative documentation. All data are stored electronically in the patient's record. Data acquisition and data base management is carried out by J. Z. as part of the required quality assurance as a certified centre of the DGAV. Perioperative adverse events are graded according to the Clavien-Dindo Classification [13, 14]. Data are expressed as absolute numbers whereas continuous data are expressed as medians (range).

3.0 RESULTS

3.1 Chemical characterisation and toxicological risk assessment: The results of the chemical analyses of nebulized chemotherapy solutions are summarized in Table 1.

The independent systematic toxicological risk assessment based on the assumption of three consecutive PIPAC sessions on the same day in a child with a body weight of 10 kg revealed no toxicological risk for the few compounds detected after nebulization.

3.2 Preclinical technical, safety checklist and surgical approach assessment for MDN-PIPAC: The following three relevant sub-areas were defined and perioperative measures implemented as follows:

medRxiv preprint doi: https://doi.org/10.1101/2023.12.01.23297348; this version posted December 5, 2023. The copyright holder for this preprint (which was not certified by peer review) is the author/funder, who has granted medRxiv a license to display the preprint in perpetuity. All rights reserved. No reuse allowed without permission.

3.2.1 *Operational parameters:* According to previous research data and the manufacturer's specifications, the MDN is operated best with pressure of 150-250 psi with an upper safety limit pressure of 300 psi. In practice this pressure operating window corresponds to the liquid volume flowrate of 1.2 ml/s - 1.6 ml/s. [2]. Accordingly, these operating parameters were stored in the high-pressure injector as a separate MDN-PIPAC working programme. As there are no other differences in handling and technical operation compared to the conventional nebulizer used, no additional measures were necessary.

3.2.2 *Construction & Design:* Due to the three horizontal nozzles, there is a potential risk of drug nebulization in the trocar if the horizontal nozzles are not placed sufficiently beyond the distal end of the trocar into the abdominal cavity. In the worst case, retrograde leakage of chemotherapy through the trocar valve into the operating theatre could occur and harm healthcare workers. To avoid this, the correct positioning of the nebulizer head in the trocar has been added to our standard safety checklist. The four-eye principle is used to check that the horizontal nozzles extend beyond the most distal point of the trocar. It should be noted that most trocars are bevelled at an angle of approximately 15°. The most distal end of the trocar is therefore used as the reference point (Figure 1A).

3.2.3 *Surgical approach:* To optimize spatial aerosol distribution during MDN-PIPAC, the spraying distance between the nozzle orifice and the peritoneum should be as large as possible [2, 7]. Periumbilical, perpendicular placement of the MDN is therefore ideal, if surgically possible (Figure 2A). Additionally, we decided to orientate the MDN in that way that one horizontal spray jet pointed to the right upper and a second to the left upper abdominal quadrant and the third towards the small pelvis (Figure 2B). In addition, we decided to routinely fix the nebulizer intraoperatively in a single-arm

medRxiv preprint doi: https://doi.org/10.1101/2023.12.01.23297348; this version posted December 5, 2023. The copyright holder for this preprint (which was not certified by peer review) is the author/funder, who has granted medRxiv a license to display the preprint in perpetuity. All rights reserved. No reuse allowed without permission.

holder (M-TRAC, Braun, Melsungen, Germany) to further prevent tilting and axial sliding in the trocar. The central periumbilical perpendicular MDN position as well as the orientation of the horizontal nozzle orifices were integrated into our intraoperative safety checklist.

2.3 Ex-vivo MDN-PIPAC simulation and Schlieren imaging: As the distal end of the trocar is angled, special care must be taken to ensure that the distal end of the trocar is visible intraoperatively so as not to interfere with the nebulization of the horizontal nozzles. The correct position of the MDN head has therefore been included as a separate item in our extended safety checklist. The openings of the horizontal nozzles must extend at least 7 mm beyond the distal end of the trocar to avoid interference during nebulization (Figure 1 A). In addition, the vertical position of the MDN in the 10/12-mm trocar was found to cause the MDN to tend to slide inward in the trocar without additional fixation. To avoid MDN slippage into the trocar, the device is placed on the trocar head with a rubber ring (sterile, reusable trocar seal) previously pulled over the shaft of the nebulizer in such a way that the rubber ring fits tightly on the trocar head and prevents the nebuliser from slipping inside the trocar (Figure 1 B). To further stabilize the position of the MDN, the use of a single-arm holder turned out to be essential and was therefore also included in our safety checklist. In addition, it was investigated whether a mispositioning of the MDN head with the horizontal nozzles nebulizing in the trocar shaft could cause aerosol leakage into the environment but multiple simulations of such a scenario showed visually no detectable retrograde aerosol leakage into the environment.

2.4 In-vivo pig MDN-PIPAC CT-peritoneography: The CT-peritoneographies of the three pigs could be performed without perioperative complications. The animals showed no cardiorespiratory problems due to the capnoperitoneal pressure of 20 mmHg. Our previously prepared MDN-PIPAC safety checklist was implemented without any problems. The

medRxiv preprint doi: https://doi.org/10.1101/2023.12.01.23297348; this version posted December 5, 2023. The copyright holder for this preprint (which was not certified by peer review) is the author/funder, who has granted medRxiv a license to display the preprint in perpetuity. All rights reserved. No reuse allowed without permission.

subsequent CT-peritoneographies showed an excellent distribution pattern of the administered contrast agent aerosol. However, no contrast agent was visible in the ventral portions of the abdominal cavity. Figure 3 depicts representative images of pig N° 1.

2.5 Clinical baseline characteristics: A total of 21 patients (male/female ratio: 2:1) with a mean age of 62 (range: 38-86) years underwent 30 consecutive MDN-PIPACs. ECOG 0 and 1 were seen in five and 16 patients, respectively. Patients had PSM of the upper gastrointestinal tract (n = 6), ovarian cancer (n = 4), colorectal cancer (n = 3), hepato-pancreatico-biliary tract (n = 3), malignant epithelioid peritoneal mesothelioma (n = 2) and other (n = 3). Eleven patients had metachronous PSM. Prior to MDN-PIPAC, seventeen patients had undergone primary tumor resection. The median number of patients had 2 (range: 1-5) lines of systemic chemotherapy before undergoing MDN-PIPAC. Seven patients had previously undergone a median of 2 (range: 1 - 4) PIPACs with the conventional PIPAC nebulizer in our institutions. The patients' preoperative baseline data are listed in Table 2.

2.6 MDN-PIPAC procedure details, morbidity, and mortality: Abdominal access was achieved in all patients. Thirteen, seven and one patient underwent one, two and three MDN-PIPACs, respectively. Two patients received only one cycle of MDN-PIPAC because they were considered candidates for cytoreductive surgery (CRS) and heated intraperitoneal chemotherapy (HIPEC) at the time of staging laparoscopy for MDN-PIPAC.

The median Sugarbaker PCI score and ascites at the first MDN-PIPAC were 25 (1-35) and 200 ml (0 - 800ml), respectively. The overall mean (range) operative time was 52.3 (48 - 78) minutes. The gradual pressure build-up and the subsequent exposure phase of 30 minutes at a capnoperitoneal pressure of 20 mmHg were well tolerated. No patient showed signs of cardio-respiratory impairment from the procedure. No intraoperative surgical or technical problems occurred.

medRxiv preprint doi: https://doi.org/10.1101/2023.12.01.23297348; this version posted December 5, 2023. The copyright holder for this preprint (which was not certified by peer review) is the author/funder, who has granted medRxiv a license to display the preprint in perpetuity. All rights reserved. No reuse allowed without permission.

In total, four patients suffered grade I (Dindo-Clavien) complications after a total of 30 MDN-PIPACs (4/30). Three patients experienced persistent nausea and vomiting postoperatively, requiring prolonged intravenous rehydration and antiemetic therapy (without gastric tube) for 48 hours postoperatively. Another patient complained of abdominal pain, which could also be managed after extending intravenous analgesic therapy. No complications > grade 1 were observed. The German health system requires a minimum hospitalization of 3 days for PIPAC application in order to be fully reimbursed by the health insurance companies. All patients were discharged on the third postoperative day at home.

4.0 DISCUSSION

For more than a decade, a PIPAC nebulizer has been available for off-label clinical use. This technology, with an axially mounted nebulizer unit, has become the standard PIPAC device. Due to its design and performance characteristics, the distribution pattern of the atomized chemotherapy is not homogeneous. Below the opening of the nebulizer unit, approximately 97% by volume is deposited directly onto the underlying peritoneum by inertial impaction [4, 19 - 22]. Recently, other PIPAC nebulizers have become available on the market. However, all nebulizers are based on the same/similar design as the standard technology. Therefore, the problem of local chemotherapy accumulation and inhomogeneous drug distribution pattern in the peritoneal cavity remains unresolved [2], which may affect the oncological efficacy of PIPAC [23]. Therefore, the optimal position of the standard PIPAC nozzle has been investigated in recent years in order to optimize the spatial distribution of chemotherapy [14, 24, 25]. More recently, new experimental PIPAC nozzle technologies have been developed. Rotational intraperitoneal pressure aerosol chemotherapy (RIPAC) uses a modified nebulizer technology similar to the standard PIPAC nebulizer. However, to optimize drug distribution, the nozzle rotates 30° around its vertical axis in the abdominal cavity. In-vivo large animal

medRxiv preprint doi: https://doi.org/10.1101/2023.12.01.23297348; this version posted December 5, 2023. The copyright holder for this preprint (which was not certified by peer review) is the author/funder, who has granted medRxiv a license to display the preprint in perpetuity. All rights reserved. No reuse allowed without permission.

data indicate, that RIPAC leads to a significantly more homogeneous distribution pattern and higher penetration depths of doxorubicin into the tissue compared to the standard PIPAC [26, 27]. Another experimental approach is the use of a preclinical multi-directional nebulizer (MDN). Braet et al. observed in an ex-vivo PIPAC model that the use of their experimental MDN device improved the spatial drug distribution of nebulized nanoparticles compared to standard PIPAC technology [28].

Based on these experimental data, it seems obvious that PIPAC nozzles, which optimize drug distribution, could also be promising in clinical application. For some time now, a FDA and CE Class IIa certified MDN has been available for off-label clinical use of MDN-PIPAC [2]. We carried out extensive preclinical testing before introducing this new device into our daily practice.

After the premature discontinuation (https://clinicaltrials.gov/study/NCT04065139) of a French prospective, randomized phase II study (PIPAC EstoK 01) [29], it was vividly discussed whether toxic substances could arise during the application of PIPAC due to the interaction of the chemotherapy solution with the PIPAC nebulizer/syringe/tube system. Therefore, independent toxicological investigations were performed as a first step. For the worst-case scenario with the highest chemotherapy doses, the toxicological investigations showed that no relevant toxicologically questionable substances were observed. The risk assessment was further based on the assumption that three PIPACs are administered consecutively on one day to a patient with a body weight of 10 kg. Even this extreme scenario did not reveal any cumulative toxicological risk for patients. Furthermore, these data indicate that the MDN device could also be used in children with a body weight > 10 kg. It is important to emphasize that our toxicological data are only valid for this type of nozzle. According to our current knowledge, there are no data available for other types of nebulizers.

medRxiv preprint doi: https://doi.org/10.1101/2023.12.01.23297348; this version posted December 5, 2023. The copyright holder for this preprint (which was not certified by peer review) is the author/funder, who has granted medRxiv a license to display the preprint in perpetuity. All rights reserved. No reuse allowed without permission.

Our further technical analysis with PIPAC surgeons and scrub nurses in our department showed that the handling of the MDN differs only slightly from that of the standard nebulizer. The MDN unit requires a higher flow rate which can been programmed into the high-pressure injector. However, a major difference is the three additional nozzles built horizontally into the MDN head. Repetitive ex vivo simulations have shown that the correct mounting of the nozzle head is crucial. The lateral openings of the nebulizers must protrude at least 7 mm beyond the distal end of the trocar for correct atomization. Moreover, we observed that the MDN can slip into the trocar due to the increased weight of the device. Therefore, we have added a sterile rubber ring to the MDN that is pulled over the nozzle and positioned so that it rests directly on the trocar head, while at the same time achieving the ideal position for the MDN head. Finally, another important safety point is the consistent use of a single-arm holder, which additionally fixes the MDN in a strictly vertical position in the trocar. This measure also prevents the MDN from unintentionally tilting sideways during the spraying process, which could worsen the spatial distribution pattern of the drug. In order to better monitor this correct position intraoperatively, it would be desirable if the manufacturer could provide a safety mark indicating intraoperatively the ideal position of the MDN head. The manufacturer was informed of these points to improve the administrability and safety of MDN-PIPAC.

To further refine the intraoperative MDN-PIPAC safety checklist, based on our previous ex-vivo simulations, we performed MDN-PIPAC in the large animal model immediately followed by CT-peritoneography to visualize the quality of the spatial aerosol distribution. The administration of all three MDN-PIPACs went without any technical or safety problems. The CT-peritoneographies revealed wide aerosol deposition. In particular, areas such as the omental bursa, hepatic interlobar and deep entero-enteric regions were also affected. Only the ventral parts of the abdominal cavity showed no contrast. However, large gravity-dependent

medRxiv preprint doi: https://doi.org/10.1101/2023.12.01.23297348; this version posted December 5, 2023. The copyright holder for this preprint (which was not certified by peer review) is the author/funder, who has granted medRxiv a license to display the preprint in perpetuity. All rights reserved. No reuse allowed without permission.

fluid collections, as previously observed with the conventional PIPAC technique, did not occur [22].

The clinical application of the elaborated intraoperative MDR-PIPAC safety checklist enabled us to apply the procedure to thirty consecutive patients without intraoperative problems. The postoperative course was characterized by four patients with minor complications (Dindo-Clavien grade I). Based on this initial experience, no clinical difference from conventional PIPAC was observed at our institution [12].

5.0 CONCLUSION

Toxicological data show that the use of the MDN does not generate any leachable substances that could pose a risk to patients. Ex-vivo simulations confirm the importance of correct positioning and fixation of the MDN in the trocar and, if possible, in a periumbilical position. Ex-vivo streak tests show that chemotherapy aerosol does not escape from the trocar valve into the operating room even if the MDN head is incorrectly positioned in the trocar shaft. MDN handling is safe and poses no problems if the safety checklist is properly adapted to this device. Whether such new devices will have a positive impact on clinical outcomes remains uncertain. However, the superior spatial distribution of nebulized substances may have a positive effect on clinical outcome. It is unlikely that there will be prospective studies in the near future to clarify this issue. Therefore, we suggest that the type of nebulizer used for PIPAC should also be documented in the ISSPP PIPAC database [30]. Such a large database could provide insight into the role of different nebulizers used on oncological outcome.

medRxiv preprint doi: https://doi.org/10.1101/2023.12.01.23297348; this version posted December 5, 2023. The copyright holder for this preprint (which was not certified by peer review) is the author/funder, who has granted medRxiv a license to display the preprint in perpetuity. All rights reserved. No reuse allowed without permission.

REFERENCES

1. Di Giorgio A, Macrì A, Ferracci F, Robella M, Visaloco M, De Manzoni G, Sammartino P, Sommariva A, Biacchi D, Roviello F, Pastorino R, Pires Marafon D, Rotolo S, Casella F, Vaira M. 10 Years of Pressurized Intraperitoneal Aerosol Chemotherapy (PIPAC): A Systematic Review and Meta-Analysis. Cancers. 2023; 15(4):1125. https://doi.org/10.3390/cancers15041125
2. Daniel Göhler, Kathrin Oelschlägel, Mehdi Ouaissi, Urs Giger-Pabst. Performance of different nebulizers in clinical use for Pressurized Intraperitoneal Aerosol Chemotherapy (PIPAC). medRxiv 2023.03.24.23287646; doi: https://doi.org/10.1101/2023.03.24.23287646
3. Nadiradze G, Horvath P, Sautkin Y, Archid R, Weinreich F-J, Königsrainer A, Reymond MA. Overcoming Drug Resistance by Taking Advantage of Physical Principles: Pressurized Intraperitoneal Aerosol Chemotherapy (PIPAC). Cancers. 2020; 12(1):34. https://doi.org/10.3390/cancers12010034
4. Göhler D, Khosrawipour V, Khosrawipour T, Diaz-Carballo D, Falkenstein TA, Zieren J, Stintz M, Giger-Pabst U. Technical description of the microinjection pump (MIP®) and granulometric characterization of the aerosol applied for pressurized intraperitoneal aerosol chemotherapy (PIPAC). Surg Endosc. 2017 Apr;31(4):1778-1784. doi: 10.1007/s00464-016-5174-5. Epub 2016 Sep 8. PMID: 27631320.
5. Tempfer CB, Rezniczek GA, Ende P, Solass W, Reymond MA. Pressurized Intraperitoneal Aerosol Chemotherapy with Cisplatin and Doxorubicin in Women with Peritoneal Carcinomatosis: A Cohort Study. Anticancer Res. 2015 Dec;35(12):6723-9. doi: 10.1055/s-0035-1560004. PMID: 26637888.
6. Tavernier C, Passot G, Vassal O, Allaouchiche B, Decullier E, Bakrin N, Alyami M, Davigo A, Bonnet JM, Louzier V, Paquet C, Glehen O, Kepenekian V. Pressurized intraperitoneal aerosol chemotherapy (PIPAC) might increase the risk of anastomotic

medRxiv preprint doi: https://doi.org/10.1101/2023.12.01.23297348; this version posted December 5, 2023. The copyright holder for this preprint (which was not certified by peer review) is the author/funder, who has granted medRxiv a license to display the preprint in perpetuity. All rights reserved. No reuse allowed without permission.

leakage compared to HIPEC: an experimental study. Surg Endosc. 2020 Jul;34(7):2939-2946. doi: 10.1007/s00464-019-07076-3. Epub 2019 Aug 27. PMID: 31456025.

7. Davigo A, Passot G, Vassal O, Bost M, Tavernier C, Decullier E, Bakrin N, Alyami M, Bonnet JM, Louzier V, Paquet C, Allaouchiche B, Glehen O, Kepenekian V. PIPAC versus HIPEC: cisplatin spatial distribution and diffusion in a swine model. Int J Hyperthermia. 2020;37(1):144-150. doi: 10.1080/02656736.2019.1704891. PMID: 32003300.
8. Graversen M, Rouvelas I, Ainsworth AP, Bjarnesen AP, Detlefsen S, Ellebaek SB, Fristrup CW, Liljefors MG, Lundell L, Nilsson M, Pfeiffer P, Tarpgaard LS, Tsekrekos A, Mortensen MB. Feasibility and Safety of Laparoscopic D2 Gastrectomy in Combination with Pressurized Intraperitoneal Aerosol Chemotherapy (PIPAC) in Patients with Gastric Cancer at High Risk of Recurrence-The PIPAC-OPC4 Study. Ann Surg Oncol. 2023 Mar 3. doi: 10.1245/s10434-023-13278-w. Epub ahead of print. PMID: 36867174.
9. Braet, Helena and Andretto, Valentina and Mariën, Remco and Yücesan, Beyza and Haegebaert, Ragna and Lollo, Giovanna and De Smedt, Stefaan C. and Remaut, Katrien, The Effect of Electrostatic High Pressure Nebulization (ePIPAC) on the Stability, Activity and Ex Vivo Distribution of Ionic Self-Assembled Nanomedicines. Available at SSRN: https://ssrn.com/abstract=4418821 or http://dx.doi.org/10.2139/ssrn.4418821
10. Guowei Kim, Hon Lyn Tan, Raghav Sundar, Bettina Lieske, Cheng Ean Chee, Jingshan Ho, Asim Shabbir, Maria V. Babak, Wee Han Ang, Boon Cher Goh, Wei Peng Yong, Lingzhi Wang and Jimmy B.Y. So. PIPAC-OX: A Phase I Study of Oxaliplatin-Based Pressurized Intraperitoneal Aerosol Chemotherapy in Patients with Peritoneal Metastases. Clin Cancer Res April 1 2021 (27) (7) 1875-1881; DOI: 10.1158/1078-0432.CCR-20-2152

medRxiv preprint doi: https://doi.org/10.1101/2023.12.01.23297348; this version posted December 5, 2023. The copyright holder for this preprint (which was not certified by peer review) is the author/funder, who has granted medRxiv a license to display the preprint in perpetuity. All rights reserved. No reuse allowed without permission.

11. Robella M, De Simone M, Berchialla P, Argenziano M, Borsano A, Ansari S, Abollino O, Ficiarà E, Cinquegrana A, Cavalli R, Vaira M. A Phase I Dose Escalation Study of Oxaliplatin, Cisplatin and Doxorubicin Applied as PIPAC in Patients with Peritoneal Carcinomatosis. Cancers (Basel). 2021 Mar 3;13(5):1060. doi: 10.3390/cancers13051060. PMID: 33802269; PMCID: PMC7958944.
12. Ramos Arias G, Sindayigaya R, Ouaissi M, Buggisch JR, Schmeding M, Giger-Pabst U, Zieren J. Safety and Feasibility of High-Pressure/High-Dose Pressurized Intraperitoneal Aerosol Chemotherapy (HP/HD-PIPAC) for Primary and Metastatic Peritoneal Surface Malignancies. Ann Surg Oncol. 2022 Nov 18. doi: 10.1245/s10434-022-12698-4. Epub ahead of print. PMID: 36400887.
13. Du Bois, D. and Du Bois, E.F. (1916) A Formula to Estimate the Approximate Surface Area if Height and Weight Be Known. Archives of Internal Medicine, 17, 863-871. http://dx.doi.org/10.1001/archinte.1916.00080130010002
14. Giger-Pabst U, Tempfer CB. How to Perform Safe and Technically Optimized Pressurized Intraperitoneal Aerosol Chemotherapy (PIPAC): Experience After a Consecutive Series of 1200 Procedures. Journal of Gastrointestinal Surgery: Official Journal of the Society for Surgery of the Alimentary Tract. 2018 Dec;22(12):2187-2193.
15. Solaß, W., Giger-Pabst, U., Zieren, J. et al. Pressurized Intraperitoneal Aerosol Chemotherapy (PIPAC): Occupational Health and Safety Aspects. Ann Surg Oncol 20, 3504–3511 (2013). https://doi.org/10.1245/s10434-013-3039-x
16. Meyers, M.A. (1976). Peritoneography: Normal and Pathologic Anatomy. In: Dynamic Radiology of the Abdomen. Springer, New York, NY. https://doi.org/10.1007/978-1-4757-3955-8_3
17. Dindo D, Demartines N, Clavien PA. Classification of surgical complications: a new proposal with evaluation in a cohort of 6336 patients and results of a survey. Ann Surg.

medRxiv preprint doi: https://doi.org/10.1101/2023.12.01.23297348; this version posted December 5, 2023. The copyright holder for this preprint (which was not certified by peer review) is the author/funder, who has granted medRxiv a license to display the preprint in perpetuity. All rights reserved. No reuse allowed without permission.

2004 Aug;240(2):205-13. doi: 10.1097/01.sla.0000133083.54934.ae. PMID: 15273542; PMCID: PMC1360123.

18. Clavien PA, Barkun J, de Oliveira ML, Vauthey JN, Dindo D, Schulick RD, de Santibañes E, Pekolj J, Slankamenac K, Bassi C, Graf R, Vonlanthen R, Padbury R, Cameron JL, Makuuchi M. The Clavien-Dindo classification of surgical complications: five-year experience. Ann Surg. 2009 Aug;250(2):187-96. doi: 10.1097/SLA.0b013e3181b13ca2. PMID: 19638912.
19. Khosrawipour V, Khosrawipour T, Diaz-Carballo D, Förster E, Zieren J, Giger-Pabst U. Exploring the Spatial Drug Distribution Pattern of Pressurized Intraperitoneal Aerosol Chemotherapy (PIPAC). Ann Surg Oncol. 2016 Apr;23(4):1220-4. doi: 10.1245/s10434-015-4954-9. Epub 2015 Nov 9. PMID: 26553440.
20. Axel Davigo, Guillaume Passot, Olivia Vassal, Muriel Bost, Clément Tavernier, Evelyne Decullier, Naoual Bakrin, Mohammad Alyami, Jeanne-Marie Bonnet, Vanessa Louzier, Christian Paquet, Bernard Allaouchiche, Olivier Glehen & Vahan Kepenekian (2020) PIPAC versus HIPEC: cisplatin spatial distribution and diffusion in a swine model, International Journal of Hyperthermia, 37:1, 144-150, DOI: 10.1080/02656736.2019.1704891
21. Giger-Pabst U, Bucur P, Roger S, Falkenstein TA, Tabchouri N, Le Pape A, Lerondel S, Demtröder C, Salamé E, Ouaissi M. Comparison of Tissue and Blood Concentrations of Oxaliplatin Administrated by Different Modalities of Intraperitoneal Chemotherapy. Ann Surg Oncol. 2019 Dec;26(13):4445-4451. doi: 10.1245/s10434-019-07695-z. Epub 2019 Aug 9. PMID: 31399820.
22. Bellendorf A, Khosrawipour V, Khosrawipour T, Siebigteroth S, Cohnen J, Diaz-Carballo D, Bockisch A, Zieren J, Giger-Pabst U. Scintigraphic peritoneography reveals a non-uniform 99mTc-Pertechnetat aerosol distribution pattern for Pressurized Intra-Peritoneal

medRxiv preprint doi: https://doi.org/10.1101/2023.12.01.23297348; this version posted December 5, 2023. The copyright holder for this preprint (which was not certified by peer review) is the author/funder, who has granted medRxiv a license to display the preprint in perpetuity. All rights reserved. No reuse allowed without permission.

Aerosol Chemotherapy (PIPAC) in a swine model. Surg Endosc. 2018 Jan;32(1):166-174. doi: 10.1007/s00464-017-5652-4. Epub 2017 Jun 22. PMID: 28643076.

23. Dedrick RL, Flessner MF. Pharmacokinetic problems in peritoneal drug administration: tissue penetration and surface exposure. J Natl Cancer Inst. 1997 Apr 2;89(7):480-7. doi: 10.1093/jnci/89.7.480. PMID: 9086004.

24. Khosrawipour V, Khosrawipour T, Falkenstein TA, Diaz-Carballo D, Förster E, Osma A, Adamietz IA, Zieren J, Fakhrian K. Evaluating the Effect of Micropump© Position, Internal Pressure and Doxorubicin Dosage on Efficacy of Pressurized Intra-peritoneal Aerosol Chemotherapy (PIPAC) in an Ex Vivo Model. Anticancer Res. 2016 Sep;36(9):4595-600. doi: 10.21873/anticanres.11008. PMID: 27630300.

25. Piao J, Park SJ, Lee H, Kim J, Park S, Lee N, Kim SI, Lee M, Song G, Lee JC, Kim HS; KORIA TRIAL GROUP. Ideal Nozzle Position During Pressurized Intraperitoneal Aerosol Chemotherapy in an Ex Vivo Model. Anticancer Res. 2021 Nov;41(11):5489-5498. doi: 10.21873/anticanres.15362. PMID: 34732419.

26. Mun J, Park SJ, Kim HS. Rotational intraperitoneal pressurized aerosol chemotherapy in a porcine model. Gland Surg. 2021 Mar;10(3):1271-1275. doi: 10.21037/gs-2019-ursoc-11. PMID: 33842275; PMCID: PMC8033043.

27. Park SJ, Lee EJ, Lee HS, Kim J, Park S, Ham J, Mun J, Paik H, Lim H, Seol A, Yim GW, Shim SH, Kang BC, Chang SJ, Lim W, Song G, Kim JW, Lee N, Park JW, Lee JC, Kim HS; KoRIA* trial group. Development of rotational intraperitoneal pressurized aerosol chemotherapy to enhance drug delivery into the peritoneum. Drug Deliv. 2021 Dec;28(1):1179-1187. doi: 10.1080/10717544.2021.1937382. PMID: 34121568; PMCID: PMC8204987.

28. Braet H, Andretto V, Mariën R, Yücesan B, van der Vegte S, Haegebaert R, Lollo G, De Smedt SC, Remaut K. The effect of electrostatic high-pressure nebulization on the

medRxiv preprint doi: https://doi.org/10.1101/2023.12.01.23297348; this version posted December 5, 2023. The copyright holder for this preprint (which was not certified by peer review) is the author/funder, who has granted medRxiv a license to display the preprint in perpetuity. All rights reserved. No reuse allowed without permission.

stability, activity and ex vivo distribution of ionic self-assembled nanomedicines. Acta Biomater. 2023 Aug 19:S1742-7061(23)00492-0. doi: 10.1016/j.actbio.2023.08.027. Epub ahead of print. PMID: 37598790.

29. Eveno C, Jouvin I, Pocard M. PIPAC EstoK 01: Pressurized IntraPeritoneal Aerosol Chemotherapy with cisplatin and doxorubicin (PIPAC C/D) in gastric peritoneal metastasis: a randomized and multicenter phase II study. Pleura Peritoneum. 2018 Jun 21;3(2):20180116. doi: 10.1515/pp-2018-0116. PMID: 30911659; PMCID: PMC6405009.
30. Mortensen MB, Glehen O, Horvath P, Hübner M, Hyung-Ho K, Königsrainer A, Pocard M, Reymond MA, So J, Fristrup CW. The ISSPP PIPAC database: design, process, access, and first interim analysis. Pleura Peritoneum. 2021 Apr 22;6(3):91-97. doi: 10.1515/pp-2021-0108. PMID: 34676282; PMCID: PMC8482445.

medRxiv preprint doi: https://doi.org/10.1101/2023.12.01.23297348; this version posted December 5, 2023. The copyright holder for this preprint (which was not certified by peer review) is the author/funder, who has granted medRxiv a license to display the preprint in perpetuity. All rights reserved. No reuse allowed without permission.

Figures and Tables

Table 1: Toxicological analyses after nebulization of chemotherapy with the MDN

	Doxorubicin + Cisplatin	**Oxaliplatin**
HSGC-MS analysis for Volatile Organic Compounds	Not detected	Not detected
GC-MS analysis for Semi-Volatile Organic Compounds		
- 1,6,11,16-Tetraoxacycloeicosane	Not detected	0.03 µg/ml
- 1,6,11,16,21-Pentaoxacyclopentacosane	Not detected	0.04 µg/ml
LC-MS analysis for Non-Volatile Organic Compounds		
- Cyclic polybutylene glycol (C20)	0.144 µg/ml	0.131 µg/ml
- Cyclic polybutylene glycol (C24)	0.246 µg/ml	0.123 µg/ml
- Cyclic polybutylene glycol (C32)	0.083 µg/ml	0.045 µg/ml
ICP-MS analysis for inorganic elements		
- Cu	0.049 µg/ml	Not detected
- Fe	0.057 µg/ml	0.011 µg/ml
- Mn	0.015 µg/ml	0.014 µg/ml
IC analysis for anions		
- Acetates	Not detected	Not detected
- Fluorides	Not detected	Not detected
- Chlorides	Not detected	Not detected
- Bromides	Not detected	Not detected
- Nitrites	Not detected	Not detected
- Nitrates	Not detected	Not detected
- Sulfates	Not detected	Not detected
- Phosphates	Not detected	Not detected

Legend: HSGC-MS = Head-space Gas Chromatography coupled with Mass Spectrometry; GC-MS = Gas Chromatography coupled with Mass Spectrometry; LC-MS = Liquid phase chromatography coupled to a Mass Spectrometer; ICP-OES = Inductively Coupled Plasma Atomic Emission Spectrometry; IC = Ion Chromatography; Cu = Cupper; Fe = Ferrum; Mn = Manganese

medRxiv preprint doi: https://doi.org/10.1101/2023.12.01.23297348; this version posted December 5, 2023. The copyright holder for this preprint (which was not certified by peer review) is the author/funder, who has granted medRxiv a license to display the preprint in perpetuity. All rights reserved. No reuse allowed without permission.

Figure 1: *Ex vivo* evaluation of the optimal position of the MDN in the 12-mm trocar



Legend: A = MDN inserted into a 12 mm balloon trocar. The position of the MNN head must be checked visually so that the lateral nozzles do not nebulize into the trocar. White triangles mark the distal end of the trocar. Note that the trocar is angled 15° at the distal end. Black arrows point to the horizontal nozzle openings. These should protrude at least 7 mm beyond the most distal end of the trocar (left white arrow). B = MDN inserted into a 12 mm balloon trocar. The black arrow points to the sterile rubbering ring pulled over the nebulizer shaft and that rests on the trocar head to avoid gliding of the nebulizer in the trocar.

medRxiv preprint doi: https://doi.org/10.1101/2023.12.01.23297348; this version posted December 5, 2023. The copyright holder for this preprint (which was not certified by peer review) is the author/funder, who has granted medRxiv a license to display the preprint in perpetuity. All rights reserved. No reuse allowed without permission.

Figure 2: Periumbilical position of the MDN for optimized nebulization

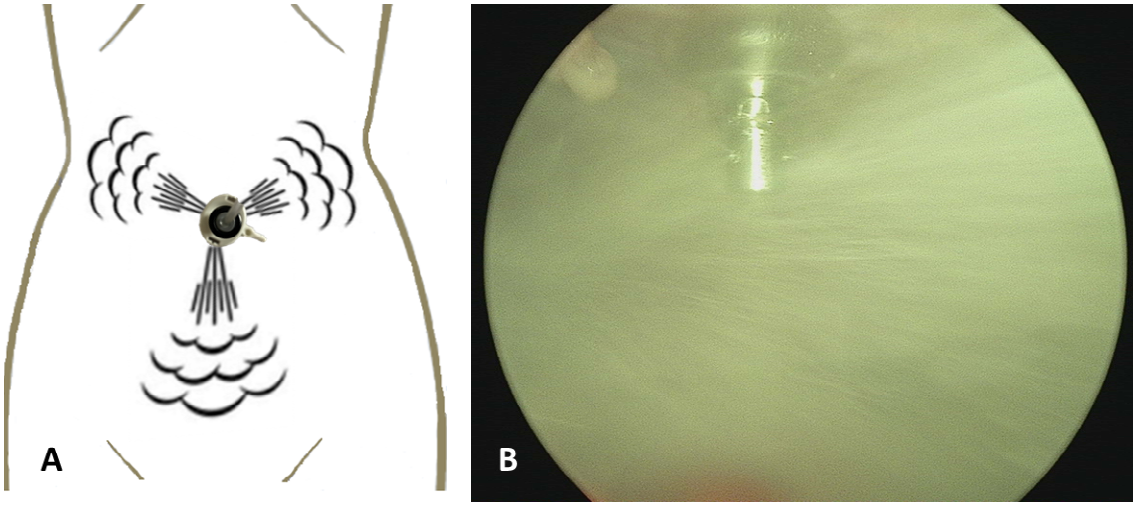

Legend: A = Sketch of infraumbilical position of the MDN for optimized nebulization of all four nozzles; B = intraoperative view on the MDN head

medRxiv preprint doi: https://doi.org/10.1101/2023.12.01.23297348; this version posted December 5, 2023. The copyright holder for this preprint (which was not certified by peer review) is the author/funder, who has granted medRxiv a license to display the preprint in perpetuity. All rights reserved. No reuse allowed without permission.

Figure 3: Representative MDN-PIPAC CT-peritoneography images of pig N° 1

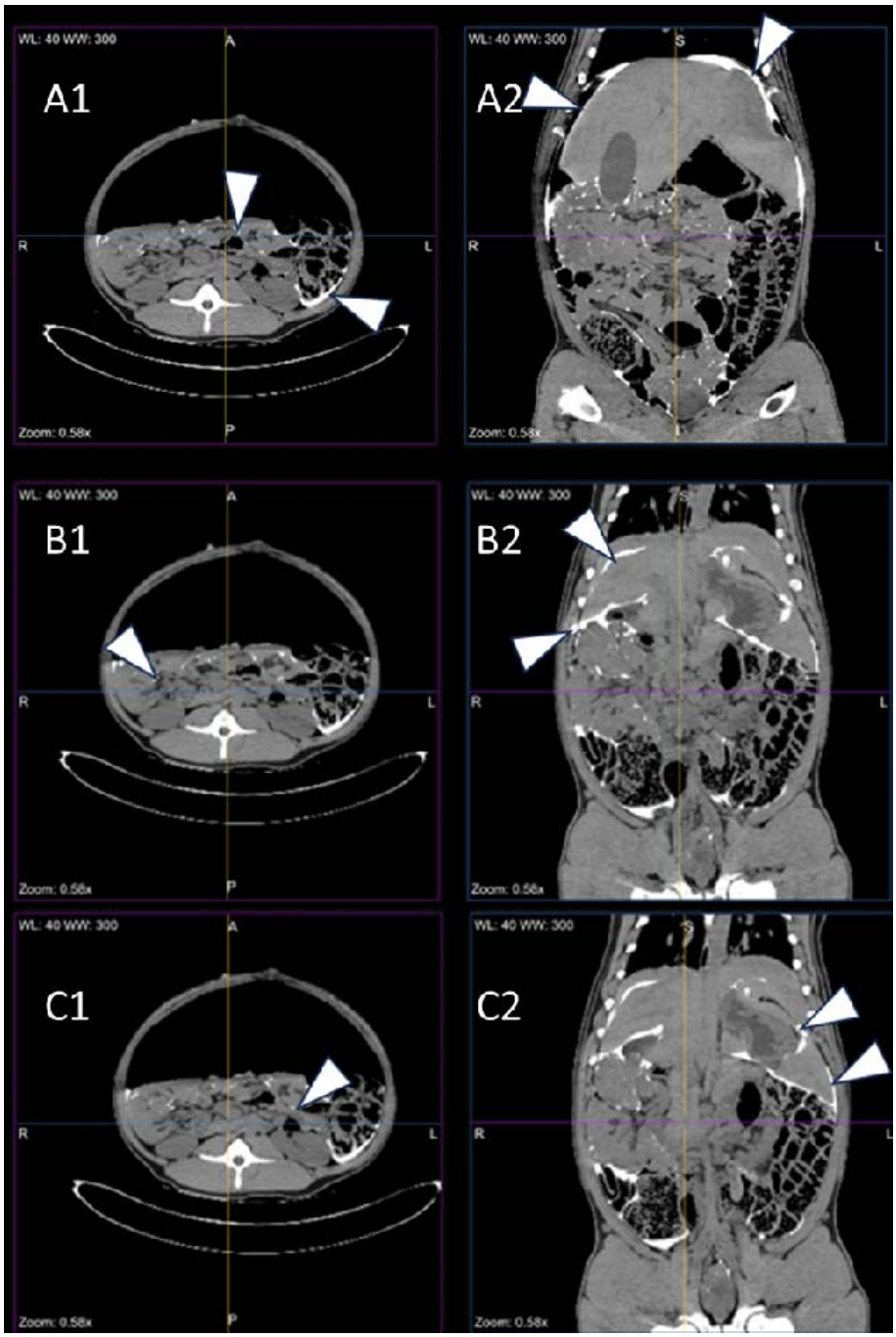

Legend: A1-C1 = horizontal section planes; A2-C2 = coronal section planes. White triangles indicate to contrast agent accumulation: A1-C1 = enter-enteric and paracolic left; A2 = subdiaphragmatic bilateral; B2 = homogeneous on the Glisson capsule, subhepatic and interlobar; C2 = perigastric and perilienal

medRxiv preprint doi: https://doi.org/10.1101/2023.12.01.23297348; this version posted December 5, 2023. The copyright holder for this preprint (which was not certified by peer review) is the author/funder, who has granted medRxiv a license to display the preprint in perpetuity. All rights reserved. No reuse allowed without permission.

Table 2: Baseline clinical characteristics of the patients with MDN-PIPAC

Variables	**Total population (n = 21)**
Age at first MDN-PIPAC (years, mean (range))	62 (38-86)
Primary origin (n)	
- Colo-Rectal	3
- UGI	6
- HPB	3
- MPM	2
- Ovarian	4
- Other	3
ECOG (n)	
- 0	5
- 1	16
Synchronous PSM (n)	10
Prior primary tumor resection (n)	17
Prior systemic chemotherapy lines (median, range)	2 (1-5)
Prior standard PIPAC applications before MDP-PIPAC (median, range)	1 (1-4)
Ongoing systemic chemotherapy between MDN-PIPAC procedures (n)	14
Time between primary and metachronous PSM diagnosis (months, median (range))	21 (2-56)

Legend: PIPAC = pressurized intraperitoneal aerosol chemotherapy; MDN = multi-directional nebulizer; UGI = upper gastrointestinal; HPB = hepato- biliary tract; ECOG = Eastern Cooperative Oncology Group performance status; PSM = peritoneal surface malignancy