medRxiv preprint doi: https://doi.org/10.1101/2023.11.23.23298888; this version posted November 27, 2023. The copyright holder for this preprint (which was not certified by peer review) is the author/funder, who has granted medRxiv a license to display the preprint in perpetuity.

It is made available under a CC-BY-NC-ND 4.0 International license .

Neurohistopathological Findings of the Brain Parenchyma After Long-Term Deep Brain Stimulation: Case Series and Systematic Literature Review

AUTHORS
Juan Vivanco-Suarez[1*], MD; Timothy Woodiwiss[1*], MD; Kimberly L. Fiock[2], PhD; Marco M. Hefti[2], MD; Nandakumar S. Narayanan[3], MD, PhD; Jeremy D. W. Greenlee[1], MD
[*] Both authors contributed equally.

AFFILIATIONS
[1] Department of Neurosurgery, University of Iowa, Iowa City, IA, United States
[2] Department of Pathology, University of Iowa, Iowa City, IA, United States.
[3] Department of Neurology, University of Iowa, Iowa City, IA, United States.

CORRESPONDENCE
Jeremy D. W. Greenlee, MD,
Department of Neurosurgery, University of Iowa Hospitals and Clinics,
200 Hawkins Dr, 1826 JPP, Iowa City, IA 52242, United States.
E-mail address: jeremy-greenlee@uiowa.edu, phone: (319) 356-2771

SHORT RUNNING TITLE
Neurohistopathological findings after deep brain stimulation

KEYWORDS
Parkinson's disease; Neuropathology; Gliosis; Postmortem

ELEMENTS COUNTS
Abstract: 302 words
Text: 3529 words
References: 48
Tables: 2
Figures: 1
Supplemental tables: 5
Supplemental figures: 0

PREVIOUS PRESENTATION
None

ETHICS
None

CONFLICTS OF INTEREST
The authors report no disclosures.

FUNDING
This research received no specific grant from any funding agency in public, commercial, or not-for-profit sectors.

NOTE: This preprint reports new research that has not been certified by peer review and should not be used to guide clinical practice.

medRxiv preprint doi: https://doi.org/10.1101/2023.11.23.23298888; this version posted November 27, 2023. The copyright holder for this preprint (which was not certified by peer review) is the author/funder, who has granted medRxiv a license to display the preprint in perpetuity.

It is made available under a CC-BY-NC-ND 4.0 International license .

Neurohistopathological Findings of the Brain Parenchyma After Long-Term Deep Brain Stimulation: Case Series and Systematic Literature Review

ABSTRACT

Introduction: The efficacy of deep brain stimulation (DBS) has been established to treat several movement and psychiatric disorders. However, several aspects, such as the mechanism of action and tissue changes after treatment are incompletely described. Hence, we aimed to describe the neurohistopathological findings of 9 patients who underwent DBS for movement disorders. Additionally, we performed a systematic literature review on postmortem studies after DBS implantation.

Methods: We performed a retrospective study of patients who underwent DBS for movement disorders between 2000-2023 and had postmortem autopsy. Demographics, clinical features, and outcomes were collected. Levodopa equivalent daily dose (LEDD) and total electrical energy delivered (TEED) were calculated. Neurohistopathological assessments were performed from autopsies. A systematic literature review was conducted to summarize the literature.

Results: Postmortem neurohistopathologic assessment of 9 patients who underwent DBS for movement disorders (8 Parkinson's disease [multiple system atrophy was final diagnosis in 1], and 1 parkinsonism) was performed. Median age at DBS implantation was 65 years (range, 54-69), and most were male (8 patients, 89%). Most common DBS target was the subthalamic nucleus (8 patients, 89%). Median DBS duration was 65 months (range, 7-264 months). Post-DBS reduction in LEDD was found in 7/9 patients, and TEED was increased over time in 5/7 patients. No patients died due to DBS. Neurohistopathological assessment showed gliosis in 7 (78%) patients and activated microglial infiltration in 1 (11%). Additionally, postmortem findings (after DBS) of 59 patients (between 1977-2021) were identified in the literature: 26 (44%) for Parkinson's disease, 20 (34%) for pain, and 13 (22%) for other conditions.

Conclusion: Our findings confirm the presence of a local tissue reaction, including gliosis and activated microglial infiltration around the implanted DBS electrodes. The effect of the local changes on the clinical efficacy of DBS is not established. Further DBS postmortem studies and standardization of tissue processing are needed.

ABBREVIATIONS

DBS, deep brain stimulation; LEDD, Levodopa equivalent daily dose; MSA, multiple system atrophy; PD, Parkinson's disease; TEED, total electrical energy delivered.

medRxiv preprint doi: https://doi.org/10.1101/2023.11.23.23298888; this version posted November 27, 2023. The copyright holder for this preprint (which was not certified by peer review) is the author/funder, who has granted medRxiv a license to display the preprint in perpetuity.

It is made available under a CC-BY-NC-ND 4.0 International license .

INTRODUCTION

The efficacy of deep brain stimulation (DBS) has been established for the treatment of several movement and psychiatric disorders.[1] Furthermore, its experimental application for chronic pain, obesity, and other neurocognitive disorders has continually expanded, aiming to benefit a broader group of patients.[2] However, several aspects of this treatment are not completely defined, including the specific interaction and activation of surrounding structures, the local tissue changes in the brain caused by long-term stimulation, the potential adverse tissue responses induced by the electrode, and the existence of neuronal damage.[1,3] A deeper understanding of the chronic local glial responses after electrode implantation may provide helpful insights for the improvement of anatomical targets and the optimization of electrode design according to the target tissue.

Previously published postmortem studies have begun the characterization of histological changes occurring around electrodes in response to implantation and chronic stimulation. A comprehensive review performed by DiLorenzo et al. reported 40 cases with implanted systems from as early as 1977.[4] The authors showed that in more than 50% of the cases, there was local fibrosis, astrocytosis, multinucleated giant cells, mononuclear leukocytes, macrophages, activated microglia, and neuronal loss.[4,5] Of note, persistent efficacy was more commonly observed when tissue injury was absent. More recently, Vedam-Mai et al. found that 3 out of 4 DBS cases exhibited histopathological evidence of a glial collar or scar around the electrode, but there was no significant association between DBS duration and the amount of gliosis. As the technologies and techniques employed for DBS continue to evolve, the evidence regarding the local changes around the electrode is contradictory.[6-9] For instance, data on the comparison of histological samples from patients with active and inactive electrodes is limited, the effect of the size of the gliotic scar is uncertain, and evidence of the distance (from the electrode) where neuronal loss or preservation is observed is unclear.[10]

Hence, this study aims to characterize and describe the neurohistopathological environment of the brain parenchyma surrounding DBS electrodes in 9 patients who underwent surgical treatment for Parkinson's disease (PD) or a parkinsonism syndrome. Additionally, we present an updated and expanded summary of the literature on this topic with a systematic review of postmortem studies after DBS implantation.

METHODS

Study design, patient protocol, tissue acquisition, and storage

This was a retrospective study of adult patients who underwent DBS for movement disorders at a tertiary academic center between July 2000 and April 2023. All tissue was obtained from autopsies conducted at the University of Iowa Hospitals and Clinics as part of routine clinical care in accordance

medRxiv preprint doi: https://doi.org/10.1101/2023.11.23.23298888; this version posted November 27, 2023. The copyright holder for this preprint (which was not certified by peer review) is the author/funder, who has granted medRxiv a license to display the preprint in perpetuity.

It is made available under a CC-BY-NC-ND 4.0 International license .

with all applicable federal and state laws and regulations. Consent for the use of tissue in research was obtained from the next of kin as part of the autopsy consent. This project was reviewed by the University of Iowa Institutional Review Board and determined not to represent human subjects research under the National Institutes of Health Revised Common Rule. Based on the database created for each donor, for this study, we extracted the age at diagnosis, sex, duration of disease, calculated Levodopa equivalent daily dose (LEDD)[11] (before implantation, 6 [± 3] months after DBS, and at last clinical follow-up), age at DBS implantation, intraoperative and hospitalization complications, DBS duration, post-implantation stimulation parameters (at 6 [± 3] months after DBS, at last clinical follow-up), and age at death. To assess the stimulation parameters, we calculated total electrical energy delivered (TEED)[12] (impedance was set to 1000Ω to standardize calculations).

Neurohistopathological techniques and evaluation

Tissue processing was done as previously described.[13-15] Briefly, brains were fixed in 20% neutral buffered formalin for 10-14 days and then sectioned, sampled, processed, and stained (both histochemical and immunohistochemical stains) in the Emory Warner Clinical Pathology Laboratories of the University of Iowa according to standard protocols. A board-certified neuropathologist (MMH) and PhD-trained research neuropathologist (KLF) reviewed all tissue sections and stains.

Systematic literature review and data extraction

A comprehensive literature search of the MEDLINE (via PubMed) database using medical subject heading terms, entrees, and free text to identify all published postmortem neurohistopathological reports of DBS cases (end-of-search date: August 9, 2023). The complete search strategy is found in **Supplemental Table 1**. All DBS cases, regardless of indication or anatomical target in the human brain, were included. Review articles or meta-analyses that did not describe disaggregated data on DBS cases were excluded. Two independent reviewers (TW and JV-S) screened the articles using the Rayyan tool (https://www.rayyan.ai/). Any difference between reviewers was settled through discussion. After the initial selection of eligible studies, the reference lists were thoroughly searched to identify additional eligible studies based on the "snowball" methodology.[16] Because DiLorenzo et al. thoroughly reviewed the literature in 2014, we expanded our review to new cases either missed by the aforementioned authors or reported after the review was completed. The following data were collected using a standardized data extraction form: demographic and patient characteristics, information about implanted hardware, stimulation parameters, clinical course, and neuropathological findings. Clinical efficacy and decline after DBS were extracted as defined by the authors of each study. When critical or disaggregated information was missing, the studies were excluded.

medRxiv preprint doi: https://doi.org/10.1101/2023.11.23.23298888; this version posted November 27, 2023. The copyright holder for this preprint (which was not certified by peer review) is the author/funder, who has granted medRxiv a license to display the preprint in perpetuity.

It is made available under a CC-BY-NC-ND 4.0 International license .

RESULTS

Patient demographics, clinical, and DBS characteristics

A total of 9 patients who had DBS implantation were identified from our institutional autopsy database. The patient and neurohistopathologic characteristics are described in **Table 1**. The median age of disease onset was 52 (range, 47-64 years), and 8 (89%) were male. On preoperative clinical evaluation, PD was diagnosed in 8 (89%) patients and parkinsonism in 1 (11%). Of note, patient 9 presented clinically as PD with a very robust response to levodopa for several years. However, dysautonomic symptoms and ataxia emerged throughout the disease course, pointing to the diagnosis of a slowly evolving Parkinsonian variant multiple system atrophy (MSA), which was confirmed on postmortem neurohistopathologic evaluation.

Regarding the DBS characteristics, the median disease course before DBS implantation was 7 years (range, 3-20 years). The median patient age at DBS implantation was 65 years (range, 54-69 years). All patients received bilateral DBS lead implantation; the majority received electrodes targeting the bilateral subthalamic nuclei (8, 89%). One (11%) patient received leads targeting the globus pallidus interna. Patient 3 had an additional lead implanted in the left ventralis intermedius thalamic nucleus due to refractory right-sided tremor. All electrodes were made of platinum/iridium (Medtronic, Inc.). The median DBS duration was 65 months (range, 7-262 months). Patient 5 underwent unilateral DBS removal (extension and battery) 16 years after bilateral implantation due to a neck infection surrounding the left-sided extension wire. No intracranial infection was identified. He was successfully reimplanted 3 months later after adequate infection management with replacement of the left STN lead and extension and battery replacement. Patient 8 had a right lead incision/burr hole erosion and infection necessitating complete bilateral DBS hardware removal 13 months after implantation. No intracranial infection was identified At last follow-up, the TEED increased in 5 of 7 patients with available data by a mean of 151 J·s compared to their initial DBS settings. However, in patients 8 and 9, the TEED decreased slightly (1 and 21 J·s, respectively) from their initial parameters. A mean LEDD reduction of 28% was observed in 7 patients after DBS began. On the other hand, LEDD increased in patients 4 and 6 by 67% and >100%, respectively. Additional details about the LEDD and TEED are presented in **Supplemental Table 2**. In terms of mortality, 1 patient (11%, case 9) passed away due to disease progression, 4 (44%) died due to unknown causes, and the remaining 4 (44%) passed away due to reasons unrelated to the primary disease or an unknown cause.

Postmortem neurohistopathological characteristics

medRxiv preprint doi: https://doi.org/10.1101/2023.11.23.23298888; this version posted November 27, 2023. The copyright holder for this preprint (which was not certified by peer review) is the author/funder, who has granted medRxiv a license to display the preprint in perpetuity.

It is made available under a CC-BY-NC-ND 4.0 International license .

An example of the gross and microscopic findings is presented in **Figure 1 (A-E)**. **Table 1** shows a descriptive summary of the postmortem neurohistopathologic findings. All patients except 2 showed gliosis at the DBS lead site. One of the 2 only had DBS for 7 months due to a fatal fall, while the other showed no gliosis despite DBS for 140 months. Activated microglial infiltration was seen around the lead in 1 patient. For the 7 patients who developed gliosis around the DBS lead, the median DBS duration was 65 months (range, 13-262). TEED increased over time in 4 patients (mean of 178 J·s) and decreased in 2 (1 and 21 J·s, respectively). A mean LEDD reduction of 32% was observed in 5/7 patients after DBS compared to pre-operative values. Two patients required an increase of their LEDD over time of 67% and >100%, including the lone PD patient treated with globus pallidus interna DBS. Notable neurohistopathologic changes from the tissue sections are the following: substantia nigra depigmentation was found in 2 (22%) patients (cases: 1 and 3) and nigra cell loss in 7 (78%; cases: 1, 4, 5, 6, 7, 8, and 9). Patient 1 had a combination of nigra depigmentation and nigra cell loss. There were a variety of additional neurodegenerative pathologic findings, including the presence of Lewy bodies in 5 patients (56%; cases: 2, 3, 4, 5, and 6) at different anatomical structures, neurofibrillary tangles in 4 (44%; cases: 5, 6, 8, and 9), tau aggregates in 4 (44%; cases: 2, 5, 8, and 9), beta-amyloid plaques in 3 (33%; cases: 5, 6, and 8), TDP-43 inclusions in 2 (22%; cases: 2 and 5), and inclusions of alpha-synuclein in 1 (11%, case 9). Of note, all but one assessed patients with 12 years or longer of PD duration at the time of death showed Lewy bodies. Finally, other pathological findings (distant to the tract) including hemorrhages and subacute infarcts were reported in 3 (33%) patients (cases 6, 7, and 8).

Systematic review update: study selection and characteristics

The literature review yielded 1249 articles, from which 18 duplicates were removed. As a result of the initial screening by title and abstract, there were 48 potentially eligible articles. In the full-text evaluation, 16 documents were excluded for the following reasons: ineligible study type (*n*=6), insufficient data available (*n*=5), ineligible outcomes (*n*=3), and ineligible patient population (*n*=2). Ultimately, 32 studies (25 case reports and 7 case series) from the final systematic search were included.

From the studies, a total of 59 patients who had a postmortem neurohistopathological assessment after DBS implantation (for different conditions) were identified. The studies were performed between 1977 and 2021. Fifteen were conducted in Europe [6,7,10,17-28], 13 in North America[29-41], 3 in Australia[42-44], and 1 in Asia[45]. The number of patients per study ranged from 1 to 8. In terms of the conditions for which DBS was implanted, 26 (44%) patients were treated for PD between 1994 and 2021 (**Table 2**; 2 MSA cases were initially misdiagnosed as PD), 6 (10%) for epilepsy (4 cases had cerebellar stimulation) between 1979 and 2020 (**Supplemental material Table 3**), 20 (34%) for pain between 1977 and 1991

medRxiv preprint doi: https://doi.org/10.1101/2023.11.23.23298888; this version posted November 27, 2023. The copyright holder for this preprint (which was not certified by peer review) is the author/funder, who has granted medRxiv a license to display the preprint in perpetuity.

It is made available under a CC-BY-NC-ND 4.0 International license .

(**Supplemental material Table 4**), and 7 (12%) for other conditions (tremor, chorea-acanthocytosis, and diffuse Lewy body disease) between 2000 and 2011 (**Supplemental material Table 5**).

Literature PD patients: DBS characteristics

Regarding the 26 PD patients (cases 11[18] and 15[30] were confirmed to be MSA on autopsy), the age at DBS implantation ranged from 24 to 81 years, and most were males (21; 81%). The DBS targets were the subthalamic nucleus in 16 (62%) patients (15 bilateral and 1 left side), the ventralis intermedius thalamic nucleus in 8 (31%; 3 bilateral, 3 right, 2 left, and 1 unknown), the left centromedian-parafasicular complex thalamic region in 1 (4%), and the bilateral zona incerta in 1 (4%). Platinum/iridium electrodes were the most employed. DBS duration ranged from 2 days to 144 months. Three cases passed away within 1 month after DBS implantation. Case 9 passed away 2 days after implantation due to myocardial infarction.[10] Case 11 was readmitted 19 days after lead placement surgery due to abnormal behavior, impaired gait, fever, and lethargy. DBS was discontinued, and medical management was started.[18] However, after transient improvement, the patient died 2 days later due to a massive pulmonary embolism (identified in autopsy). Case 13 died 4 days after implantation due to cardiorespiratory arrest secondary to pulmonary embolus (identified in autopsy). Clinical efficacy (as reported by the authors of each study) was observed in 24 patients (92%), and decline was reported in 4 (15%). Death causes were diverse. However, none of them were encountered intraoperatively during DBS implantation.

Literature PD patients: postmortem neurohistopathological characteristics

In terms of the postmortem neurohistopathological analysis, fibrillary gliosis (which represents a chronic tissue reaction) was reported in 23/24 (92%) patients, and in 2/26 (8%) patients, it could not be assessed due to precipitated death (details discussed above). In the patients who passed away within 1 month after implantation, fresh hemorrhage was evidenced in 2/3 (67%). Reactive astrocytosis (mostly reflective of an acute tissue reaction) was observed in 14/25 (56%) patients. Microglial activation was found in 9/17 (53%) patients, and neuronal loss was observed in 7/19 (37%) patients. Multinucleated giant cells were reported in 8/25 (32%) patients. Regarding the pathologic findings of PD, nigra depigmentation was reported in 24/24 (100%) patients, and nigra cell loss in 21 (81%). Of note, in the cases where MSA was confirmed on autopsy (2/26, 8%), DBS showed clinical efficacy only in case 11.

DISCUSSION

In this study of the neurohistopathological findings of 9 patients implanted with platinum/iridium DBS electrodes for parkinsonism (1 patient), PD (7 patients), and parkinsonian type MSA (1 patient), we found that at a median time of 65 months after DBS implantation, the brain tissue surrounding the DBS

medRxiv preprint doi: https://doi.org/10.1101/2023.11.23.23298888; this version posted November 27, 2023. The copyright holder for this preprint (which was not certified by peer review) is the author/funder, who has granted medRxiv a license to display the preprint in perpetuity.

It is made available under a CC-BY-NC-ND 4.0 International license .

resulted in gliosis in 7 patients (78%) and the presence of activated microglia in 1 patient (11%). In general, these results are consistent with previous postmortem studies showing that a glial response is consistently generated around the DBS electrodes. Additionally, our systematic review spanning between 1977 and 2021 of postmortem neuropathological studies reporting findings after DBS identified 59 unique patients who underwent treatment for PD, epilepsy, pain, and other conditions such as tremor, chorea-acanthocytosis, and diffuse Lewy body disease. As the number of patients treated with DBS (for a wide variety of conditions) increases and the technologies continue to evolve, our study represents an addition to the body of evidence on the postmortem findings after DBS and represents the most comprehensive and current review of this topic.

Gliosis surrounding the implantation site

The presence of a gliotic response surrounding the DBS electrode described in this study is similar to the findings reported in previous postmortem human studies and animal models.[2] Yet, our rate of 78% (7/9 patients) gliotic response after a range of 7-262 months following DBS implantation is lower than the overall rate of gliotic responses reported in the literature (92%, 22/24 patients). Notably, one of our patients without gliosis had DBS for 7 months. Previous studies have attributed the reaction of the brain parenchyma to the electrode itself and/or the chronic stimulation.[32] More study is needed to understand if these factors, such as the biocompatibility of the implanted electrodes, the variability in the stimulation parameters, degradation of the metal contacts, and the length of stimulation (and others), could be implicated in the process of gliotic scar formation. The clinical implication (effect upon efficacy variation) of the gliotic response around the DBS electrode is poorly described. The plausibility that an increased gliotic response negatively affects DBS efficacy seems reasonable and intuitive. However, in our study, from the 7 patients who developed gliotic changes, 5 had a 32% reduction in their LEDD at the last follow-up compared to pre-DBS dosage. This contrasted with the 2 patients who needed a greater than 50% LEDD increase over their post-implantation course. Of note, these patients (4 and 6 from Table 1) had the lowest pre-DBS LEDD levels and a prolonged DBS treatment (65 and 94 months, respectively). Also, patient 6 was the only one who received stimulation of the globus pallidus interna, which is known to not reduce LEDD after DBS compared to patients treated with STN DBS. Given the variability in our findings, the limited sample size, and the lack of standardization in the assessment of gliosis around the DBS electrode, additional studies will be needed with objective clinical findings, such as LEDD and TEED, compared to in depth histological evaluation, such as volume and density of gliosis, before robust conclusions can be made. Separating the gliosis produced by the implantation lesion and the simulation-induced effects is also relevant for optimizing clinical efficacy. Thus, we recommend that future studies evaluate the potential correlation between the gliotic scar and the clinical efficacy of DBS

medRxiv preprint doi: https://doi.org/10.1101/2023.11.23.23298888; this version posted November 27, 2023. The copyright holder for this preprint (which was not certified by peer review) is the author/funder, who has granted medRxiv a license to display the preprint in perpetuity.

It is made available under a CC-BY-NC-ND 4.0 International license .

treatment to provide needed insights for developing biocompatible materials, optimizing stimulation parameters, and implantation techniques that optimize patient outcomes.

Additional neurohistopathologic findings

Evidence of additional markers of local tissue response (to the implanted electrodes), such as activated microglia, reactive astrocytosis, giant multinuclear cells, hemosiderin-laden macrophages, and neuronal loss, have been reported in previous studies.[2,4,8] In our series, only one (11%) case (patient 2) demonstrated activated microglia infiltration, which was lower than the 53% we found in the literature review. The presence of activated microglia lacks specificity but supports the presence of an ongoing inflammatory response regardless of the chronicity of the electrode implantation. Furthermore, in the literature review, we found additional tissue responses such as astrogliosis (53%), multinucleated giant cells (32%), and neuronal loss (37%). Although these findings are unspecific and were not assessed in our series, their description, characterization, and role in the therapeutic action of DBS are of great interest. Support for more postmortem neurohistopathologic after DBS is also supported by our findings of change in diagnosis over time in our series and the literature. In our study 1 patient was confirmed to have MSA after DBS implantation for PD, while in the literature, 2 cases[18,30] had a similar update to MSA after postmortem assessment. The lack of consistent efficacy in these cases confirms the need for an accurate diagnosis to obtain the best clinical results. Clinical research would benefit from pathologically confirmed diagnosis to ensure data is accurate. Additional knowledge about DBS and its mechanisms could allow for the inclusion of other indications in which the therapy could have potential benefits.

Future directions

Although the neurohistopathological changes observed in the tissue surrounding the DBS electrodes show characteristics of a classical foreign body reaction, the presence of additional changes (around the active electrodes) and their underlying mechanisms are yet to be elucidated. The response of different cellular lines (neurons, glial cells, immune cells, and vasculature-related cells) to electrical stimulation is not established.[1] Determination of the influence of electrical currents (at varying intensities and charge densities) on neuronal signaling, neural function, astrocyte response, and overall cellular metabolism could provide valuable insights to tailor and optimize the stimulation parameters to favor minimal injury, maximal long-lasting efficacy, and expansion of the contemporary indications for DBS. Additionally, the development and testing of electrodes (and coatings) with novel functional biomaterials aiming to minimize the immune response, decrease tissue resistance to stimulation (impedance), favor the attraction of the neuronal processes (potentially enhancing the benefits of DBS), and optimize the charge transfer density. Such efforts are underway employing nanomaterials and nanoparticles that minimize the tissue

medRxiv preprint doi: https://doi.org/10.1101/2023.11.23.23298888; this version posted November 27, 2023. The copyright holder for this preprint (which was not certified by peer review) is the author/funder, who has granted medRxiv a license to display the preprint in perpetuity.

It is made available under a CC-BY-NC-ND 4.0 International license .

reaction, favor neural recordings, and improve charge transfer efficiency.[46] Despite this, the use of postmortem neurohistopathological data continues to provide valuable and fundamental insights to guide future directions. However, the postmortem literature is largely dominated by studies with low-level evidence (case reports and case series), lacking standard tissue handling and assessment protocols. The formation of an integrated network of researchers, the adoption of common protocols for the collection and management of specimens, and the implementation of new techniques for tissue evaluation seem to be the natural next step in the evolution of the study of human neurodegenerative and neuropsychiatric disease and the role of DBS with them.[47,48]

Limitations

We acknowledge that our study has limitations. First, the sample size was small, and the analysis was retrospective. Next, the clinical outcome data were limited by availability and patient follow-up Additionally, the handling, processing, and evaluation of the neurohistopathological samples were performed according to local protocols, which limits the comparison and generalizability of our findings. Regarding the systematic review, the included studies were small (case reports and series) and retrospective. The clinical data and postmortem neurohistopathological findings were heterogeneously reported based on the individual selection and preference of the authors from each study. However, considering the limited availability of such data and the lack of standardization on the protocols for neurohistopathological tissue handling, we included all the available reports aiming to comprehensively summarize the existing literature.

CONCLUSION

Our findings confirm the presence of a local tissue reaction, including gliosis and activated microglial infiltration around the implanted DBS electrodes. The presence of additional histologic changes has been reported in the literature however, the implication of these findings needs to be clearly established. The effect of the local changes on the clinical efficacy of DBS is not clearly established. As the continual effort to expand the use, efficacy, and safety of DBS for neuromodulation and neuroaugmentation moves forward, the value of postmortem neurohistopathological evidence will undoubtedly shed more light on the mechanism behind this powerful clinical and surgical tool. Further DBS postmortem studies and standardization of tissue processing are needed to expand the understanding of the interaction between the local brain parenchyma and the implanted DBS electrode.

ACKNOWLEDGMENTS

medRxiv preprint doi: https://doi.org/10.1101/2023.11.23.23298888; this version posted November 27, 2023. The copyright holder for this preprint **(which was not certified by peer review)** is the author/funder, who has granted medRxiv a license to display the preprint in perpetuity.

It is made available under a CC-BY-NC-ND 4.0 International license .

The authors would like to acknowledge the incredible contribution of the patient donors and their families, as this research would not be possible without their generous gift to the advancement of science. They would also like to acknowledge the support staff at the University of Iowa who worked tirelessly behind the scenes to keep our facilities running. If there are additional comments/suggestions, please let us know.

medRxiv preprint doi: https://doi.org/10.1101/2023.11.23.23298888; this version posted November 27, 2023. The copyright holder for this preprint **(which was not certified by peer review)** is the author/funder, who has granted medRxiv a license to display the preprint in perpetuity.

It is made available under a CC-BY-NC-ND 4.0 International license .

REFERENCES

1. Evers J, Lowery M. The Active Electrode in the Living Brain: The Response of the Brain Parenchyma to Chronically Implanted Deep Brain Stimulation Electrodes. *Oper Neurosurg (Hagerstown)*. Jan 13 2021;20(2):131-140. doi:10.1093/ons/opaa326

2. Orlowski D, Michalis A, Glud AN, et al. Brain Tissue Reaction to Deep Brain Stimulation-A Longitudinal Study of DBS in the Goettingen Minipig. *Neuromodulation*. Jul 2017;20(5):417-423. doi:10.1111/ner.12576

3. Fenoy AJ, Goetz L, Chabardès S, Xia Y. Deep brain stimulation: are astrocytes a key driver behind the scene? *CNS Neurosci Ther*. Mar 2014;20(3):191-201. doi:10.1111/cns.12223

4. DiLorenzo DJ, Jankovic J, Simpson RK, Takei H, Powell SZ. Neurohistopathological findings at the electrode-tissue interface in long-term deep brain stimulation: systematic literature review, case report, and assessment of stimulation threshold safety. *Neuromodulation*. Jul 2014;17(5):405-18; discussion 418. doi:10.1111/ner.12192

5. Moss J, Ryder T, Aziz TZ, Graeber MB, Bain PG. Electron microscopy of tissue adherent to explanted electrodes in dystonia and Parkinson's disease. *Brain*. Dec 2004;127(Pt 12):2755-63. doi:10.1093/brain/awh292

6. Al-Helli O, Thomas DL, Massey L, et al. Deep brain stimulation of the subthalamic nucleus: histological verification and 9.4-T MRI correlation. *Acta Neurochir (Wien)*. Dec 2015;157(12):2143-7. doi:10.1007/s00701-015-2599-x

7. De Vloo P, Thal D, van Kuyck K, Nuttin B. Histopathology after microelectrode recording and twelve years of deep brain stimulation. *Brain Stimul*. Sep-Oct 2018;11(5):1183-1186. doi:10.1016/j.brs.2018.05.005

8. Vedam-Mai V, Rodgers C, Gureck A, et al. Deep Brain Stimulation associated gliosis: A post-mortem study. *Parkinsonism Relat Disord*. Sep 2018;54:51-55. doi:10.1016/j.parkreldis.2018.04.009

9. Vedam-Mai V, Martinez-Ramirez D, Hilliard JD, et al. Post-mortem Findings in Huntington's Deep Brain Stimulation: A Moving Target Due to Atrophy. *Tremor Other Hyperkinet Mov (N Y)*. 2016;6:372. doi:10.7916/d8zp462h

10. Haberler C, Alesch F, Mazal PR, et al. No tissue damage by chronic deep brain stimulation in Parkinson's disease. *Ann Neurol*. Sep 2000;48(3):372-6.

11. Tomlinson CL, Stowe R, Patel S, Rick C, Gray R, Clarke CE. Systematic review of levodopa dose equivalency reporting in Parkinson's disease. *Mov Disord*. Nov 15 2010;25(15):2649-53. doi:10.1002/mds.23429

medRxiv preprint doi: https://doi.org/10.1101/2023.11.23.23298888; this version posted November 27, 2023. The copyright holder for this preprint **(which was not certified by peer review)** is the author/funder, who has granted medRxiv a license to display the preprint in perpetuity.

It is made available under a CC-BY-NC-ND 4.0 International license .

12. Koss AM, Alterman RL, Tagliati M, Shils JL. Calculating total electrical energy delivered by deep brain stimulation systems. *Ann Neurol*. Jul 2005;58(1):168; author reply 168-9. doi:10.1002/ana.20525

13. Fiock KL, Hook J, Hefti MM. Determinants of Astrocytic Pathology in Stem Cell Models of Primary Tauopathies. *bioRxiv*. Jul 26 2023;doi:10.1101/2023.07.18.549558

14. Fiock KL, Smalley ME, Crary JF, Pasca AM, Hefti MM. Increased Tau Expression Correlates with Neuronal Maturation in the Developing Human Cerebral Cortex. *eNeuro*. May/Jun 2020;7(3)doi:10.1523/eneuro.0058-20.2020

15. Conway KS, Ghafoor F, Gottschalk AC, et al. The Neuropathology of 1p36 Deletion Syndrome: An Autopsy Case Series. *J Neuropathol Exp Neurol*. Sep 27 2021;80(9):856-860. doi:10.1093/jnen/nlab072

16. Wohlin C. Guidelines for snowballing in systematic literature studies and a replication in software engineering. presented at: Proceedings of the 18th International Conference on Evaluation and Assessment in Software Engineering; 2014; London, England, United Kingdom. https://doi.org/10.1145/2601248.2601268

17. Caparros-Lefebvre D, Ruchoux MM, Blond S, Petit H, Percheron G. Long-term thalamic stimulation in Parkinson's disease: postmortem anatomoclinical study. *Neurology*. Oct 1994;44(10):1856-60. doi:10.1212/wnl.44.10.1856

18. Berciano J, Valldeoriola F, Ferrer I, et al. Presynaptic parkinsonism in multiple system atrophy mimicking Parkinson's disease: a clinicopathological case study. *Mov Disord*. Jul 2002;17(4):812-6. doi:10.1002/mds.10190

19. Jarraya B, Bonnet AM, Duyckaerts C, et al. Parkinson's disease, subthalamic stimulation, and selection of candidates: a pathological study. *Mov Disord*. Dec 2003;18(12):1517-20. doi:10.1002/mds.10607

20. Nielsen MS, Bjarkam CR, Sørensen JC, Bojsen-Møller M, Sunde NA, Østergaard K. Chronic subthalamic high-frequency deep brain stimulation in Parkinson's disease--a histopathological study. *Eur J Neurol*. Feb 2007;14(2):132-8. doi:10.1111/j.1468-1331.2006.01569.x

21. Guehl D, Vital A, Cuny E, et al. POSTMORTEM PROOF OF EFFECTIVENESS OF ZONA INCERTA STIMULATION IN PARKINSON DISEASE. *Neurology*. 2008;70(16 Part 2):1489-1490. doi:10.1212/01.wnl.0000310426.18409.11

22. Gelpi E, Haberler C, Micko A, et al. Focal Subthalamic Atrophy after Long-Term Deep Brain Stimulation in Parkinson's Disease. *Mov Disord*. Aug 2021;36(8):1987-1989. doi:10.1002/mds.28653

medRxiv preprint doi: https://doi.org/10.1101/2023.11.23.23298888; this version posted November 27, 2023. The copyright holder for this preprint **(which was not certified by peer review)** is the author/funder, who has granted medRxiv a license to display the preprint in perpetuity.

It is made available under a CC-BY-NC-ND 4.0 International license .

23. Wright GD, Weller RO. Biopsy and post-mortem findings in a patient receiving cerebellar stimulation for epilepsy. *J Neurol Neurosurg Psychiatry*. Mar 1983;46(3):266-73. doi:10.1136/jnnp.46.3.266

24. Giordano F, Caporalini C, Peraio S, et al. Post-mortem histopathology of a pediatric brain after bilateral DBS of GPI for status dystonicus: case report and review of the literature. *Childs Nerv Syst*. Sep 2020;36(9):1845-1851. doi:10.1007/s00381-020-04761-w

25. Gybels J, Dom R, Cosyns P. Electrical stimulation of the central gray for pain relief in human: autopsy data. *Acta Neurochir Suppl (Wien)*. 1980;30:259-68. doi:10.1007/978-3-7091-8592-6_31

26. Boivie J, Meyerson BA. A correlative anatomical and clinical study of pain suppression by deep brain stimulation. *Pain*. Jun 1982;13(2):113-126. doi:10.1016/0304-3959(82)90022-7

27. Burbaud P, Vital A, Rougier A, et al. Minimal tissue damage after stimulation of the motor thalamus in a case of chorea-acanthocytosis. *Neurology*. Dec 24 2002;59(12):1982-4. doi:10.1212/01.wnl.0000038389.30437.1e

28. Valldeoriola F, Tolosa E, Alegret M, et al. Cognitive changes in Parkinson's disease during subthalamic stimulation: a clinicopathologic study. *J Neurol Neurosurg Psychiatry*. Apr 2006;77(4):565-6. doi:10.1136/jnnp.2005.077990

29. Counelis GJ, Simuni T, Forman MS, Jaggi JL, Trojanowski JQ, Baltuch GH. Bilateral subthalamic nucleus deep brain stimulation for advanced PD: correlation of intraoperative MER and postoperative MRI with neuropathological findings. *Mov Disord*. Sep 2003;18(9):1062-5. doi:10.1002/mds.10489

30. Chou KL, Forman MS, Trojanowski JQ, Hurtig HI, Baltuch GH. Subthalamic nucleus deep brain stimulation in a patient with levodopa-responsive multiple system atrophy. Case report. *J Neurosurg*. Mar 2004;100(3):553-6. doi:10.3171/jns.2004.100.3.0553

31. Sun DA, Yu H, Spooner J, et al. Postmortem analysis following 71 months of deep brain stimulation of the subthalamic nucleus for Parkinson disease. *J Neurosurg*. Aug 2008;109(2):325-9. doi:10.3171/jns/2008/109/8/0325

32. Vedam-Mai V, Yachnis A, Ullman M, Javedan SP, Okun MS. Postmortem observation of collagenous lead tip region fibrosis as a rare complication of DBS. *Mov Disord*. Apr 2012;27(4):565-9. doi:10.1002/mds.24916

33. Pilitsis JG, Chu Y, Kordower J, Bergen DC, Cochran EJ, Bakay RA. Postmortem study of deep brain stimulation of the anterior thalamus: case report. *Neurosurgery*. Feb 2008;62(2):E530-2; discussion E532. doi:10.1227/01.neu.0000316024.81786.78

medRxiv preprint doi: https://doi.org/10.1101/2023.11.23.23298888; this version posted November 27, 2023. The copyright holder for this preprint **(which was not certified by peer review)** is the author/funder, who has granted medRxiv a license to display the preprint in perpetuity.

It is made available under a CC-BY-NC-ND 4.0 International license .

34. Robertson LT, Dow RS, Cooper IS, Levy LF. Morphological changes associated with chronic cerebellar stimulation in the human. *J Neurosurg*. Oct 1979;51(4):510-20. doi:10.3171/jns.1979.51.4.0510

35. Hosobuchi Y, Adams JE, Linchitz R. Pain relief by electrical stimulation of the central gray matter in humans and its reversal by naloxone. *Science*. Jul 8 1977;197(4299):183-6. doi:10.1126/science.301658

36. Baskin DS, Mehler WR, Hosobuchi Y, Richardson DE, Adams JE, Flitter MA. Autopsy analysis of the safety, efficacy and cartography of electrical stimulation of the central gray in humans. *Brain Res*. Apr 23 1986;371(2):231-6. doi:10.1016/0006-8993(86)90358-6

37. Boockvar JA, Telfeian A, Baltuch GH, et al. Long-term deep brain stimulation in a patient with essential tremor: clinical response and postmortem correlation with stimulator termination sites in ventral thalamus. Case report. *J Neurosurg*. Jul 2000;93(1):140-4. doi:10.3171/jns.2000.93.1.0140

38. Gross RE, Jones EG, Dostrovsky JO, Bergeron C, Lang AE, Lozano AM. Histological analysis of the location of effective thalamic stimulation for tremor. Case report. *J Neurosurg*. Mar 2004;100(3):547-52. doi:10.3171/jns.2004.100.3.0547

39. McClelland S, 3rd, Vonsattel JP, Garcia RE, et al. Relationship of clinical efficacy to postmortem-determined anatomic subthalamic stimulation in Parkinson syndrome. *Clin Neuropathol*. Nov-Dec 2007;26(6):267-75. doi:10.5414/npp26267

40. DiLorenzo DJ, Jankovic J, Simpson RK, Takei H, Powell SZ. Long-term deep brain stimulation for essential tremor: 12-year clinicopathologic follow-up. *Mov Disord*. Jan 30 2010;25(2):232-8. doi:10.1002/mds.22935

41. Hughes PS, Krcek JP, Hobson DE, Del Bigio MR. An unusual inflammatory response to implanted deep brain electrodes. *Can J Neurol Sci*. Jan 2011;38(1):168-70.

42. Henderson JM, O'Sullivan DJ, Pell M, et al. Lesion of thalamic centromedian– parafascicular complex after chronic deep brain stimulation. *Neurology*. 2001;56(11):1576-1579. doi:10.1212/wnl.56.11.1576

43. Henderson JM, Pell M, O'Sullivan DJ, et al. Postmortem analysis of bilateral subthalamic electrode implants in Parkinson's disease. *Mov Disord*. Jan 2002;17(1):133-7. doi:10.1002/mds.1261

44. Henderson J, Rodriguez M, O'Sullivan D, et al. Partial lesion of thalamic ventral intermediate nucleus after chronic high-frequency stimulation. *Mov Disord*. Jun 2004;19(6):709-11. doi:10.1002/mds.10709

45. Kuroda R, Nakatani J, Yamada Y, Yorimae A, Kitano M. Location of a DBS-electrode in lateral thalamus for deafferentation pain. An autopsy case report. *Acta Neurochir Suppl (Wien)*. 1991;52:140-2. doi:10.1007/978-3-7091-9160-6_38

medRxiv preprint doi: https://doi.org/10.1101/2023.11.23.23298888; this version posted November 27, 2023. The copyright holder for this preprint **(which was not certified by peer review)** is the author/funder, who has granted medRxiv a license to display the preprint in perpetuity.

It is made available under a CC-BY-NC-ND 4.0 International license .

46. Angelov SD, Koenen S, Jakobi J, et al. Electrophoretic deposition of ligand-free platinum nanoparticles on neural electrodes affects their impedance in vitro and in vivo with no negative effect on reactive gliosis. *J Nanobiotechnology*. Jan 12 2016;14:3. doi:10.1186/s12951-015-0154-9

47. Vedam-Mai V. Biovalue in Human Brain Banking: Applications and Challenges for Research in Neurodegenerative Diseases. *Methods Mol Biol*. 2022;2389:209-220. doi:10.1007/978-1-0716-1783-0_17

48. Vedam-Mai V, Krock N, Ullman M, et al. The national DBS brain tissue network pilot study: need for more tissue and more standardization. *Cell Tissue Bank*. Aug 2011;12(3):219-31. doi:10.1007/s10561-010-9189-1

TABLES

Table 1. Demographic, clinical, and neurohistopathological (around the electrode track) characteristics of the patients who underwent DBS implantation

DBS case n.	Age at onset/ sex	Disease	Age at DBS	DBS target	PD duration at death (years)	DBS duration in months [a]	LEDD change [b]	TEED change [c]	Cause of death	Gliosis at DBS site	Activated microglia at DBS lead	Nigra depigmentation	Nigra cell loss	Other neurodegenerative pathology	Other pathology
1	61-65/M	Parkinsonism	66-70	B STN	5	24	- 13% (- 200 mg)	+ 2,600% (+ 156 J·s)	Lung cancer	Yes	No	Yes	Yes	None	None
2	46-50/M	PD	66-70	B STN	32	140	- 10% (-100 mg)	NA	Unknown	No	No	No	No	• Tau limited to the amygdala • Lewy bodies in the limbic system and cingulate gyrus • Scant TDP-43 inclusions in the hippocampus	None
3	51-55/M	PD	56-60	B STN L VIM	15	126 [d]	- 32% (- 350 mg)	+ 233% (+ 221 J·s)	Unknown	Yes	Yes	Yes	No	• Scant Lewy bodies in the cortex and cingulate • Pigment incontinence in the substantia nigra and locus coeruleus	None
4	51-55/M	PD	61-65	B STN	18	65	+ 67% (+ 470 mg)	NA	COPD	Yes	No	No	Yes	• Scattered Lewy bodies in the neocortex and amygdala	None
5	46-50/M	PD	51-55	B STN	28	262 [e]	- 46% (- 425 mg)	+ 133% (+ 187 J·s)	Unknown	Yes	No	No	Yes	• Lewy bodies in the amygdala and cingulate gyrus • Beta-amyloid plaques in the neocortex (Thal 1) • Neurofibrillary tangles extending into the hippocampus (Braak III/IV) • Scattered subpial astrocytic tau in the neocortex • TDP-43 inclusions in the hippocampus	None
6	56-60/M	PD	61-65	B GPI	12	94	+ 213% (+ 1,785 mg)	+ 89% (+ 147 J·s)	Unknown	Yes	No	No	Yes	• Scattered Lewy bodies in the amygdala and cingulate gyrus • Beta-amyloid plaques extending into the basal ganglia (Thal 3, CERAD 1) • Neurofibrillary tangles extending into the primary visual cortex (Braak V/VI)	• Remote hemorrhage in the internal capsule
7	56-60/F	PD	66-70	B STN	12	7	- 23 % (- 410 mg)	+ 219% (+ 46 J·s)	Head trauma	No	No	No	Yes	Not assessed	• Intraparenchymal hemorrhages in the basal ganglia, thalamus, corpus callosum, pons, and midbrain
8	56-60/M	PD	61-65	B STN	14	13 [f]	- 13% (- 200 mg)	- 2% (- 1 J·s)	Cardiac disease	Yes	No	No	Yes	• Diffuse beta-amyloid plaques in the middle frontal gyrus • Rare neurofibrillary tangles in the hippocampus	• Multifocal subacute infarcts in the middle frontal gyrus and cerebellum with foamy macrophages and gliosis
9	51-55/M	Initial: PD Definitive: MSA – Parkinsonian type	51-55	B STN	8	62	- 56% (-1,086 mg)	- 31% (- 21 J·s)	Disease progresion	Yes	No	No	Yes	• Focal Purkinje cell loss and Bergmann gliosis in the cerebellum • Glial cytoplasmic inclusions of alpha synuclein with rare neuronal inclusions in the middle frontal gyrus, cingulate gyrus, corpus callosum, hippocampus, amygdala, pons, substantia nigra, cerebellar white matter, dentate nucleus, and basal ganglia • Rare neurofibrillary tangles in the hippocampus • Scattered tau positive aggregates in the white matter, neocortex, amygdala, substantia nigra, pons, and cerebellum	None

[a] DBS duration was calculated from the first activation until removal or death. [b] LEDD change from last follow-up versus pre-DBS. [c] TEED change from last follow-up versus 6 (± 3) months. [d] An additional lead (VIM) was implanted due to refractory right-sided tremor after the initial bilateral STN stimulation. [e] 198 months after implantation, the patient underwent left battery and extension removal due to neck infection. Left STN lead replacement, extension, and battery re-implantation was performed 3 months later. The total time accounts only for the time when DBS stimulation was active. [f] Entire DBS system removed due to right burr hole erosion and infection.

Abbreviations: B, bilateral; COPD, chronic obstructive pulmonary disease; DBS, deep brain stimulation; F, female; GPI, globus pallidus interna; LEDD, Levodopa equivalent daily dose; M, male; MSA, multiple system atrophy; n., number; NA, not available, STN, subthalamic nucleus; TEED, total electrical energy delivered; VIM, ventral intermediate nucleus.

medRxiv preprint doi: https://doi.org/10.1101/2023.11.23.23298888; this version posted November 27, 2023. The copyright holder for this preprint (which was not certified by peer review) is the author/funder, who has granted medRxiv a license to display the preprint in perpetuity. It is made available under a CC-BY-NC-ND 4.0 International license.

Table 2. Characteristics of the postmortem neurohistopathological findings around the DBS electrode track for Parkinson's disease

Author, year	DBS case n.	Age at DBS	Sex	DBS targets	Electrode surface material	Clinical efficacy after DBS	Clinical decline after DBS	DBS duration in months	Cause of death	Gliosis at DBS site	Activated microglia at DBS lead	Neuronal loss at DBS site	Other findings at DBS site	Nigra depigmentaion	Nigra cell loss
Caparros-Lefebvre et al., 1994[17]	1	56-60	M	Vim	Pt/Ir	Yes	No	43	Stroke	Yes (1 mm perimeter)	NR	NR	Accumulation of lymphoid cells, macrophages, and giant cells (2 mm) around the electrode	Yes	Yes
Haberler et al., 2000[10]	2	NR	NR	L Vim	Pt/Ir	Yes	No	70	Myocardial infarction	Yes	No	No	-	Yes	Yes
"	3	71-75	M	BL Vim	Pt/Ir	Yes	No	54	Cardiovascular failure	Yes	No	No	Mononuclear leukocytes	Yes	Yes
"	4	51-55	M	L Vim	Pt/Ir	Yes	No	45	Cardiovascular failure	Yes	No	No	Macrophages and reactive astrocytes	Yes	Yes
"	5	56-60	M	BL Vim	Pt/Ir	Yes	No	45	Cardiovascular failure	Yes	NR	No	Multinucleated giant cells and reactive astrocytes	Yes	Yes
"	6	41-45	M	R Vim	Pt/Ir	Yes	No	1	Astrocytoma	Yes	NR	No	Multinucleated giant cells	Yes	Yes
"	7	76-80	M	BL Vim	Pt/Ir	Yes	No	15	Cardiovascular failure	Yes	Yes	No	More pronounced gliosis around lead track, multinucleated giant cells, and reactive astrocytes	Yes	Yes
"	8	66-70	F	BL STN	Pt/Ir	Yes	No	3	Drowning	Yes	Yes	No	More pronounced gliosis around lead track, multinucleated giant cells, and reactive astrocytes	Yes	Yes
"	9	61-65	M	L STN	Pt/Ir	Yes	No	2 days	Myocardial infarction	-	No	No	Fresh hemorrhage, perifocal edema, and numerous axonal spheroids	Yes	Yes
Henderson et al., 2001[42]	10	66-70	M	L CM-Pf	Pt/Ir	Yes	Yes	48	Sepsis	Yes	NR	Yes	Extensive astrocytosis and small thalamotomy greater than the dimension of the electrode tip penetration	Yes	Yes
Berciano et al., 2002[18]	11*	61-65	M	BL STN	NR	Yes	No	21 days	Pulmonary embolus	NR	NR	NR	NR	Yes	Yes
Henderson et al., 2002[43]	12	51-55	M	BL STN	Pt/Ir	Yes	No	2	Aspiration pneumonia	Yes	Yes	Yes (mild)	TUNEL staining and analysis of cellular morphology did not show features of apoptosis, and astrocytosis	Yes	Yes
Counelis et al., 2003[29]	13	61-65	M	BL STN	Pt/Ir	Yes	-	4 days	Pulmonary embolus	No	No	No	Fresh hemorrhage along tracks and minimal reactive changes	NR	Yes
Jarraya et al., 2003[19]	14	21-25	F	BL STN	NR	Yes	Yes	24	Pulmonary embolus	Yes	NR	NR	Large number of activated macrophages around the cavity and in the vicinity, and astrocytosis	Yes	Yes
Chou et al., 2004[30]	15*	51-55	M	BL STN	NR	No	Yes	3	Aspiration pneumonia	Yes	NR	NR	Tracks associated with hemosiderin deposition, multinucleated giant cells, and neovascularization	Yes	Yes
Henderson et al., 2004[44]	16	61-65	M	L Vim	Pt/Ir	Yes	Yes	84	Ischemic heart disease	Yes	No	Yes	Hemosiderin deposition along the electrode track and astrocytosis	Yes	Yes
Nielsen et al., 2007[20]	17	71-75	M	BL STN	Pt/Ir	Yes	No	29	Accident	Yes (capsule)	NR	No	Lymphocytes, macrophages, neutrophilic granulocytes, occasional neurons in the capsule, and astrocytosis	Yes	Yes
Guehl et al., 2008[21]	18	51-55	M	BL ZI	Pt/Ir	Yes	No	72	Dystonia (rhabdomyolysis)	Yes	NR	NR	None of the electrode contacts were located within the STN	NR	NR

medRxiv preprint doi: https://doi.org/10.1101/2023.11.23.23298888; this version posted November 27, 2023. The copyright holder for this preprint (which was not certified by peer review) is the author/funder, who has granted medRxiv a license to display the preprint in perpetuity. It is made available under a CC-BY-NC-ND 4.0 International license.

Sun et al., 2008[31]	19	81-85	M	BL STN	Pt/Ir	Yes	No	71	Pnemonia	Yes	Yes	NR	Capsule with hemosiderin-laden macrophages, scattered lymphocytes, Rosenthal fibers, focal foreign-body giant cell reaction, and astrocytosis	Yes	Yes
Vedam-Mai et al., 2012[32]	20	71-75	M	BL STN	NR	Yes	No	13	Cardiac arrest	Yes	No	No	Marked fibrosis around the cavity (right DBS lead tip), fibrocollagenous "capsule" confirmed by Mason's trichrome	Yes	Yes
Al-Helli et al., 2015[6]	21	66-70	M	BL STN	NR	NR	NR	72	NR	Yes	Yes	NR	Small collagenous scar with gliosis (Perl's stain positive) around track	Yes	Yes
De Vloo et al., 2018[7]	22	66-70	F	BL STN	Pt/Ir	Yes	No	144	Pneumonia	Yes	No	No	Minimal reactive astrocytosis, macrophages, fibrillary gliosis, and perivascular lymphocytic infiltration	Yes	Yes
Gelpi et al., 2021[22]	23	61-65	M	BL STN	NR	Yes	No	51	Peritonitis	Yes	Yes	Yes	Astrogliosis	Yes	NR
"	24	66-70	F	BL STN	NR	Yes	No	52	Pneumonia	Yes	Yes	Yes	Rosenthal fibers and astrogliosis	Yes	NR
"	25	46-50	M	BL STN	NR	Yes	No	36	Pneumonia	Yes	Yes	Yes	Multinucleated giant cells, Rosenthal fibers, and astrogliosis	Yes	NR
"	26	51-55	M	BL STN	NR	Yes	No	48	Cardiac arrest	Yes	Yes	Yes	Rosenthal fibers and astrogliosis	Yes	NR

* DBS indicated for PD, but postmortem examination established diagnosis of multiple system atrophy

Abbreviations: BL, bilateral; CM-Pf, centromedian-parafasicular complex thalamic region; DBS, deep brain stimulation; F, female; L, left; M, male; n., number; NR, not reported; Pt/Ir, platinum/iridium; R, right; STN, subthalamic nucleus; TUNEL, (TdT)-mediated UTP nick and labelling; Vim, ventralis intermedius thalamic nucleus; ZI, zona incerta.

medRxiv preprint doi: https://doi.org/10.1101/2023.11.23.23298888; this version posted November 27, 2023. The copyright holder for this preprint (which was not certified by peer review) is the author/funder, who has granted medRxiv a license to display the preprint in perpetuity. It is made available under a CC-BY-NC-ND 4.0 International license .

medRxiv preprint doi: https://doi.org/10.1101/2023.11.23.23298888; this version posted November 27, 2023. The copyright holder for this preprint (which was not certified by peer review) is the author/funder, who has granted medRxiv a license to display the preprint in perpetuity.

It is made available under a CC-BY-NC-ND 4.0 International license .

FIGURES AND FIGURE LEGENDS

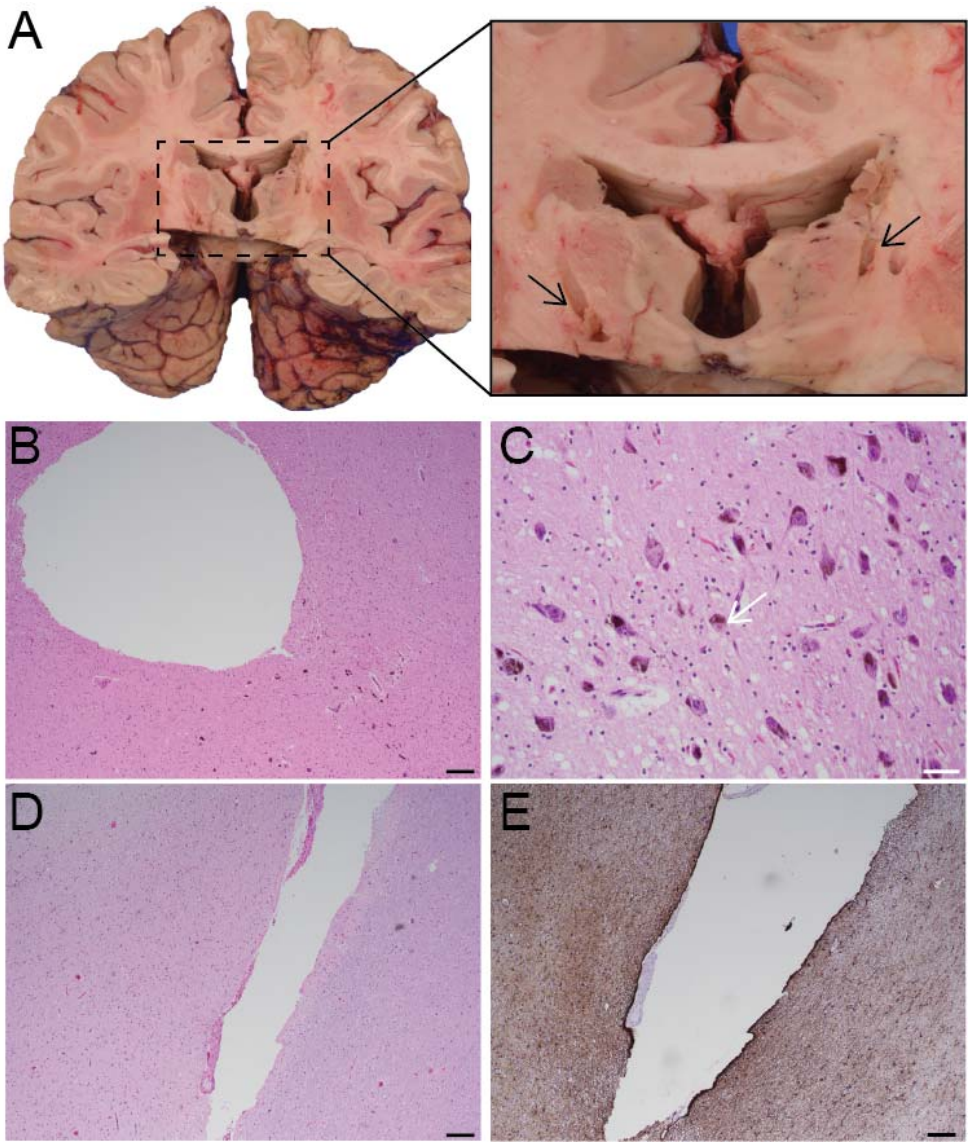

Figure 1 (A-E). Macroscopic and microscopic tissue representations. (**A**) Coronal brain slice depicting gross bilateral tracts with close-up pop-out. Arrows denote tracts. (**B**) Hematoxylin & Eosin stain slide of midbrain with electrode tract in the nigra. Black scale = 200 µm. (**C**) Lewy bodies in the nigra, arrow denotes Lewy body. White scale = 50 µm. (**D**) Luxol fast blue stain on thalamus with electrode tract. Black scale = 200 µm. (**E**) Glial fibrillary acidic protein statin on thalamus with tract. Black scale = 200 µm.