Treatment of thoracic outlet syndrome to alleviate chronic migraine headache

Short title: TOS treatment to relieve migraine

L Randall[1], S. Ahn[2,3], J. Weber[4], Y.H. Cha[5]

[1] Mayo Clinic Alix School of Medicine, Rochester, MN.

[2] Texas Christian University, School of Medicine, Fort Worth, TX.

[3] Dallas Fort Worth Vascular Surgery, Dallas, TX.

[4] St. Francis Medical Center, Tulsa, OK.

[5] Department of Neurology, University of Minnesota, Minneapolis, MN.

Corresponding Author:
Yoon-Hee Cha
717 Delaware Street SE
Minneapolis, MN. 55414
Email: ycha@umn.edu

Abstract: 288
Manuscript: 3850
Tables: 4
Supplemental: 2
Figures: 3

Keywords: thoracic outlet syndrome, headache, migraine, brachial plexus, subclavian vein

Conflict of interest: The authors declared no potential conflicts of interest concerning the research, authorship, and/or publication of this article.

Funding: The authors received no financial support for the research, authorship, and/or publication of this article.

ABSTRACT

Background: Prior case reports have indicated that treating thoracic outlet syndrome (TOS) may relieve intractable migraine headaches, but the reported experience is limited. We report how a strategy to treat concurrent TOS can help relieve migraine headaches in patients with dual diagnoses.

Methods: Retrospective chart review for diagnostic and interventional data on patients with migraine and TOS followed by a questionnaire to investigate specific migraine features and changes in headache burden before and after treatment of TOS.

Results: 50 patients (48 women, 2 men, age = 43.9+/12.7years) with dual diagnoses of chronic migraine and venous TOS were included (20 migraine with aura, 28 migraine without aura, two hemiplegic migraines). Based on a chart review of available data, headaches had become chronic within one year of onset in 21 patients (42%) and included these characteristics: side-locked or greater headache ipsilateral to limb paresthesia (38/50 patients), presence of limb swelling (32/48 patients), and worsened by recumbency (32/38 patients). Interventions included physical therapy, percutaneous transluminal venoplasty, 1st rib removal, scalenectomy, pectoralis minor tenotomy, and vein patching. Thirty-two patients eventually needed surgery. Mean patient-reported improvement of headaches on the treated side was 72+/-26.7%; 12 patients experienced complete resolution of headaches after surgical treatment of TOS (follow-up 7.2+/-5.2 months). Questionnaire responders reported significant reductions in headache days (18.3+/-8.6 to 11.1+/-10.8 days/month, $p<0.0016$), severity (7.8+/2.5 to 5.4+/-2.9, $p<0.00079$), and need for emergency care (3.6+/-4.0 to 0.71+/-1.3 visits/year, $p<0.0029$) were noted by questionnaire responders after having had their TOS treated. Questionnaire responders and non-responders were not substantially different in underlying clinical features.

Conclusions: Chronic migraines can be important manifestations of TOS. Early transition to a chronic state, headaches worsened by recumbency, and headaches with lateralized myofascial pain are clues to a contribution by TOS pathology.

INTRODUCTION

Migraine headaches lead to tremendous disability and loss of productivity, particularly when they become intractable and therapeutic options have been exhausted [1]. While migraine is considered to be a primary headache disorder and should be diagnosed when explicit criteria as outlined in the International Classification of Headache Disorders (ICHD) are met, non-headache-related symptoms may provide clues that a structural cause may be a secondary contributor [2-4]. An underrecognized contributor to migraine is compression of the brachial plexus, subclavian artery, and/or subclavian vein leading to thoracic outlet syndrome (TOS) [5-7]. In patients whose migraines are secondary to TOS, the associated neck and limb pain should be recognized as clues to a structural contributor.

Previous studies have demonstrated that migraines can be a prominent symptom of TOS but studies have generally been limited to case reports [8-11]. The exception is a 1985 report by Raskin on 30 patients with TOS whose migraine headaches preceded the onset of arm symptoms and had significantly improved headache control after treatment of TOS [8]. Given the era, there had been no routine imaging performed to diagnose vascular TOS but contemporary criteria for neurogenic TOS had been met. In 1999, Saxton and colleagues reported detailed anatomical imaging with MRI and MRA of the brachial plexus in a 36-year-old woman with childhood-onset migraine headaches whose premonitory symptoms of the migraine headache were bilateral hand pain and paresthesia [10]. Her imaging showed bilateral cervical ribs and an aberrant subclavian artery compressing the vagus and recurrent laryngeal nerves, the axillary-subclavian vein, and the stellate ganglia. The patient's migraines resolved with unilateral 1st rib resection, middle and anterior scalenectomy, and extensive brachial plexus neurolysis. In 2017, Chahwala detailed a case showing retrograde flow of contrast from the subclavian veins to the internal jugular vein on arm adduction with enhanced collateralization in a patient with chronic migraine [9]. The migraines were relieved by scalenectomy and 1st rib resection. Unfortunately, despite the prominence of

myofascial pain and lateralized motor and sensory symptoms in migraines, recognition of TOS as an underlying contributor to intractable migraines has been almost completely neglected.

TOS is designated according to whether the subclavian vein, subclavian artery, or brachial plexus is affected. Neurogenic TOS (nTOS) relates to symptoms caused by compression of the brachial plexus and manifests with paresthesia, numbness, pain, and weakness of the affected arm and hand [12]. Arterial TOS (aTOS) is due to compression or damage of the subclavian artery leading to symptoms such as pain and pallor due to ischemia, including the production of emboli to the hand, usually associated with cervical ribs or bony abnormalities in the thorax [13, 14]. Venous TOS (vTOS) relates to compression or thrombosis of the axillary or subclavian vein; it may present as McCleery syndrome when there is no thrombosis or as Paget Schroetter's, or "effort thrombosis," leading to pain, swelling, and redness when there is an associated deep vein thrombosis [15, 16]. Compression of these thoracic outlet structures frequently occurs together making it difficult to distinguish symptoms due to each structure difficult [5, 17]. For example, subclavian vein compressions can occur in as many as 65% of patients with neurogenic TOS with dominant symptoms fluctuating depending on which structures are compressed[11, 18].

This is a retrospective chart review and questionnaire study with the goal of delineating the pattern of headaches in adult patients with concurrent chronic migraines and underlying TOS. While most data presented is from chart review, patients with a dual diagnosis of chronic migraine and TOS were asked to provide more detailed information about treatment effects in the form of a questionnaire. The goal is to bring awareness to clinical features that should prompt consideration of TOS contributing to migraine. Treatment of the TOS was a significant factor in relieving migraine headaches in a substantial portion of these patients, including those that had started in childhood. The recognition of TOS contributing to migraine headache is critical in converting intractable headaches to manageable ones and sometimes to completely relieve them.

METHODS

Participant inclusion criteria

Patients experiencing chronic migraines defined by ICHD-3 criteria as ≥15 days of headaches per month in which at least 8 are migraine headaches lasting more than 4 hours a day for ≥3 months were included in the study [2]. Patients could also meet the criteria for New Daily Persistent Headaches (NDPH) as a secondary diagnosis. The entry criteria for TOS were based on nTOS since these are the most clearly defined criteria by Consortium for Education and Outcomes Research on Thoracic Outlet Syndrome (CORE-TOS) and the Society for Vascular Surgery (SVS) [19] and can be diagnosed by clinical history and exam [19]. This includes at least 4 of 5 clinical features being met: 1] pain or paresthesias in the neck, upper back, shoulders, arm, and/or hands, 2] symptoms exacerbated by arm elevation, repetitive use, or radiation of pain/paresthesias from the supra or infraclavicular regions, 3] a mechanism for injuries such as overuse, or prior trauma to the head, neck or chest, 4] tenderness over the scalene muscles or subcoracoid areas, 5] a positive upper limb tension test or elevated arm stress test [19]. In addition, concurrent vTOS was evaluated with CT chest with contrast, digital subtraction venography, and evaluation for the presence of hand and arm swelling [20] (**Figure 1**).

Patients underwent CT chest with contrast injected into the symptomatic arm to determine the presence of subclavian vein thrombosis, stenosis between the clavicle and 1st thoracic rib, cervical ribs, or structural chest abnormalities such as pectus excavatum, and axillary masses with digital subtraction venography in high-risk patients (**Figure 2A-C**). Arterial TOS was evaluated by chest CT ruling out cervical ribs and by arteriography for high-risk cases. MRI cervical spine, MRI shoulder, and EMGs were performed to resolve diagnostic ambiguity when there was a suggestion of cervical radiculopathy, ulnar, or median neuropathy. MRI or CT of the brain was performed to rule out other secondary causes of headache.

Patients in whom neurogenic and venous TOS was identified underwent an escalating series of treatments including physical therapy, percutaneous transluminal venoplasty (PTV), and surgical decompression including 1st rib resection plus scalenectomy, scalenectomy alone, pectoralis minor tenotomy, or vein patching as recommended by the consulting vascular surgeon. Patients with limb swelling were treated with diuretics. Medical management with standard headache prevention protocols continued through the TOS treatment course for as long as the patient presented for follow-up. Improvement in headaches was attributed to the treatment of TOS by temporal association after specific intervention for TOS.

A chart review of all patients seen by the principal investigator over the course of 3 years for a dual diagnosis of chronic migraine and TOS was performed with data extracted as the patients were being followed. Institutional approval to send questionnaires outside of regular clinical care was obtained from the Saint Francis Health Systems Institutional Research Ethics Board with protocol number 2250-19. Informed consent was obtained from all participants with research performed in accordance with the Declaration of Helsinki. Participant surveys were conducted to assess for more detailed TOS and headache features, therapies attempted, changes in symptoms following treatment, and general well-being and quality of life. Patients were sent a SurveyMonkey® weblink with a unique study identifier that only they could access.

Measures

Descriptive data on headache time course and diagnoses are reported on all patients for which that information could be reliably obtained. All post-treatment values were compared against pretreatment values (e.g. headache days before surgery vs after surgery). Statistically significant changes in metrics such as the average number of headache days, severity of headaches, and number of yearly urgent care/emergency room visits before and after treatment of TOS were

calculated as two-tailed paired t-tests with a significance of $p<0.05$. Data are presented for the number of participants who had sufficient information for that measure with the number of data points reported. Therefore, some data reported have different denominators.

RESULTS

Clinical features

A total of 50 patients from a base of approximately 600 patients referred for headaches met the criteria for both chronic migraine and TOS between March 2016 and April 2019. Clinical features of 48 women and two men (age 43.9+/-12.7 years, median 44 years) are detailed in **Table 1**.

Headaches were side-locked to the right or left sides in 17 patients, and when bilateral were worse on the side of the greater arm symptoms in an additional 21 patients (**Table 2**). Thirty-two patients endorsed swelling in their hands and arms, 16 denied swelling, and two did not comment. Twenty-two of 50 patients noted being woken up in the middle of the night with headaches; 26 of 50 noted waking up in the morning with headaches. Positional effects were known in 36 patients. Of these, 30 reported having headaches that were worse being reclined, sometimes requiring them to sleep with the head elevated.

All 50 patients underwent chest CT, in which there were 26 cases of narrowed subclavian or innominate veins equally split between the right and left sides (**Table 3**). Other findings relevant to the diagnosis included three cases of cervical ribs, three cases of thymic hyperplasia causing mediastinal crowding, a thoracic schwannoma impinging on the subclavian vein of the symptomatic arm, and one aberrant 2nd rib insertion into the sternum on the symptomatic arm. MRI of the brain was available in 36 patients and head CT in 26 patients, some of whom had both showing four cases of cerebellar ectopia, two strokes that occurred after the onset of the migraines, and one case of demyelinating disease. Fifteen patients underwent digital subtraction

venography. All confirmed severe large vessel stenosis (≥50%). Thirteen of these patients also had the internal jugular vein imaged; 12 had concurrent internal jugular vein stenosis of at least 50%; 6 were stenosed over 75%. Seven underwent additional arteriography with two showing mild concurrent subclavian artery stenosis (≤25%).

Of the 50 patients, 15 had a lumbar puncture with CSF opening pressure measurements. Pressures ranged from 14-36 cmH20, mean 21.8+/-6.9 cmH20, median 21.0 cmH20. Only one patient in the series exhibited papilledema and had a pressure of 36cmH20. This patient developed migraines and ipsilateral neurogenic and venous TOS after a T1 schwannoma resection.

Patients had tried a mean of 4.0+/-2.4 preventative migraine medications before starting treatment for TOS (antihypertensives, anticonvulsants, antidepressants, Botox, CGRP inhibitors) (median number tried = 4, range 0-11). Patients who eventually had surgery showed a trend towards having tried more medical treatments for migraines than those who did not have surgery (4.5+/-1.9 vs 3.1+/-2.4 medications, two-tailed *p-value* 0.0885).

All patients had a course of physical therapy with a total of 32 patients eventually undergoing surgical decompressive procedures during the observation period with the same patient sometimes undergoing more than one procedure. Twenty patients underwent bilateral 1st rib resections with scalenectomy, five right-sided 1st rib resections with scalenectomy, six left-sided 1st rib resections with scalenectomy, five additional separate scalenectomies, four pectoralis minor tenotomies, two vein patches (one internal jugular vein, one subclavian vein), and 13 a trial of PTV. All TOS surgical treatments were done to improve arm symptoms rather than for headaches despite improvement in headaches being of primary interest in this study. Patients

were followed for an average of 7.2+/-5.2 months (median 7 months, range 1-19 months) after their last procedure. The follow-up was done by either the vascular surgeon or the neurologist; both reported headache status. One patient in this series developed subclavian vein thrombosis before she had her 1st rib/scalenectomy surgery. This was complicated by a pulmonary embolus. Two patients had posterior circulation strokes with cryptogenic sources before being diagnosed with TOS.

Risk factors for the development of TOS are detailed in **(Supplemental Table 1)**. Thirty-seven patients had a history of trauma to the head, neck, or chest that ranged from overuse injury to the instrumentation of the neck or chest to crush injuries. Some patients had more than one risk factor.

Treatment response

Twenty-eight of 41 patients in whom post-treatment clinical status was known reported >50% better headache control after treating their TOS. Twelve reported 100% headache relief. Nine patients did not follow up after treatment was initiated to know their response. Overall head relief averaged 72+/-26.7% (range 50-100%) by patients' global assessments in these 41 patients. This included the two patients with hemiplegic migraines who had hemiplegic symptoms resolved with surgery (cervical rib removal in one, bilateral 1st rib resections in one). In seven patients, headaches recurred after a period of 1-5 months on the side opposite to the decompressed side which prompted surgery of the contralateral side. Patients whose symptoms did not improve were typically in the middle of treatment at the time data were summarized and were waiting for second-side surgery. Two patients reported no improvement in headache but had resolved or majority improvement in syncopal spells. One patient had no improvement in headache but had resolved supine chest pain and palpitations after bilateral 1st rib resections.

Survey participants

Of the 50 patients invited to take the survey, 26 started the survey, and 24 completed enough sections to allow data analysis. Of the remaining, one patient declined to participate; one had an inactive email address, and 22 did not respond. To determine whether there were any systematic biases in participants (n=26) and non-participants (n=24) in the survey, the general characteristics of each group were compared (**Supplemental Table 2)**. Demographic features were similar including sex distribution, age, years of migraine, and years of chronic migraine, but were significantly different in duration of care (1.5+/-0.9 years participants vs 1.0+/-0.9 years non-participants, *p=0.0276*) and a greater proportion of participants who had started the survey who had undergone surgery (19 of 24 participants =79%) than non-participants (11 of 24 =49%).

Clinical features of survey participants

Eighteen of 24 patients who completed the survey reported baseline chronic daily headaches with no headache-free days of which 11 patients had headaches that were chronic from the onset. The most frequent area of maximal pain was the skull base, with the most frequent description of the pain being, “pressure, head exploding,” followed by “throbbing.” The relationship between the onset of headache and limb symptoms of TOS was answered by 23 participants. Limb symptoms with headaches occurred either “always,” or “sometimes,” with headaches in 87% of participants **Table 4**.

Treatment responses from survey participants

Participants rated the change in their headache burden from before to after treatment for TOS with reports corroborated with the clinical record. The average number of headache days per month decreased from 18.3+/-8.6 to 11.1+/-10.8 ($p<0.0016$) with the average severity of

headache on a 0-10 scale decreasing from 7.8+/2.5 to 5.4+/-2.9 ($p<0.00079$). The average number of visits to an urgent care or emergency room per year decreased from 3.6+/-4.0 to 0.71+/-1.3, $p<0.0029$). For the 19 of 24 survey participants with completed data and who had undergone any surgical procedures, the survey was reported at a mean of 10.0+/-6.1 months (median 9 months, range 0.5-20.7 months) after their last surgical procedure. Of note, patients did not have to have completed all planned surgical procedures.

Eighteen patients made responses on a 5-point Likert scale of “strongly disagree (-2),” to “strongly agree (+2),” for general statements assessing their well-being and physical capabilities at home and at work, both before and after their TOS diagnosis and intervention. The mean change for “I am fully functional at work," was positive (mean 1.22+/-1.48; range 0-4). Similarly, “I am fully functional at home,” indicated a positive change (mean 1.17+/-1.34; range 0-3) (**Figure 3**).

DISCUSSION

This study reports the real-life clinical experience of how treating concurrent TOS can alleviate chronic migraine headaches in patients with dual diagnoses. It increases the number of patients reported in the literature for which this association is important and could thus buttress the rationale for future controlled trials for this underappreciated association. One reason why this association is underappreciated is that the treatment of TOS has traditionally fallen under the treatment scope of vascular surgeons whereas detailed clinical features of migraines that point to TOS as a contributor may not be appreciated by neurologists who treat the headaches associated with TOS.

Thoracic outlet syndrome as a contributor to chronic migraines should be considered in patients with certain clinical features. Our study indicates that these patterns include: 1. Headaches ipsilateral to myofascial symptoms including skull base, neck, and shoulder pain, along with arm

and hand symptoms of numbness, tingling, and weakness 2. Headaches associated with edema or the face, arm, and/or hand, 3. Symptoms worse on recumbency or that frequently wake a person from sleep, 4. Headaches developing in the context of neck and chest trauma, 5. Headaches that are chronic within one year of onset, including NDPH. While no feature is specific to TOS, the combination of supporting features should raise consideration for an underlying structural disorder such as TOS contributing to migraine pathology.

In this study, all patients met the criteria for both neurogenic and venous TOS based on CORE TOS SVS through imaging and clinical evidence of both neural compression and venous obstruction. These two compressive etiologies could not be dissociated, however, as they overlap in the majority of patients. The mechanism for the association between migraine and TOS can be postulated and is most intuitive based on a venous obstruction etiology since that can be seen on imaging. Subclavian vein obstruction in vTOS impedes drainage from the external jugular vein and potentially the internal jugular vein when the obstruction is near the confluence of the innominate vein. During digital subtraction venography, the external jugular vein was frequently noted to be overdeveloped with exuberant collaterals (**Figure 2B**). This may lead to elevated venous pressure in tributaries upstream from the compression that can lead to neck pain and skull-base pressure that triggers a migraine [21, 22]. The areas drained by these veins include the skull base, lateral neck, periauricular, and suprascapular areas--all areas in which both swelling and pain have been noted in these patients. Because emissary veins carrying blood from the internal jugular veins collateralize with the external jugular vein at the skull base, subclavian vein obstruction may potentially impact flow in the internal jugular vein leading to downstream effects on drainage from the cavernous sinus around the eye and the superior and inferior petrosal sinuses that drain the inner ear [23, 24]. The superior petrosal sinus sits over the trigeminal nerve and sometimes wraps around it creating a potential mechanism for the direct triggering of facial

pain with venous congestion [25]. Moreover, the increasingly recognized role of the jugular venous system in regulating intracranial pressure may be a mechanism for headaches, particularly those triggered by postural changes [26-28]. Notably, most patients experienced worse headaches in the supine position when venous outflow is most dependent on the jugular pathway as opposed to the paravertebral venous plexus that carries greater venous outflow in the upright position [26-28]. Almost half of the patients in this series noted being woken up in the middle of the night by headaches. Further, the re-routing of venous blood through intrathoracic veins in upper extremity venous compressive disorders could be an important factor in the associated symptoms of neck pain and chest pain, particularly those worsened by supine positioning when venous pressure is high [9, 10, 29, 30].

Special cases

The two patients with hemiplegic migraines are of particular interest. One mechanism of hemiplegic symptoms in vTOS relates to the parallel path of venous outflow between the paravertebral venous plexus and the jugular system which bidirectionally shunts with postural changes [28, 30-32]. Compression of the jugular system shunts venous blood to the vertebral veins which drain the cervical spinal cord [33]. Over-shunting of venous blood due to either fixed or frequent obstruction of the jugular venous system could lead to venous hypertension, reduced perfusion pressure of the ipsilateral spinal cord, and hemiplegic symptoms. In the patient with the cervical rib, decompression also likely removed a component of subclavian artery compression causing limb ischemia.

Two patients had a history of cryptogenic embolic strokes. While one patient had a history of hyperlipidemia, she was only in her 30s and otherwise in excellent health when she developed a

cerebellar hemispheric stroke. The other patient was in her 40s and developed an occipital stroke in the setting of a particularly bad migraine headache. Strokes have been reported in TOS, generally in the context of obstructed flow through a stenosed subclavian artery and stagnation of blood in an adjacent aneurysm [34, 35].

Limitations

This report expands the scope of clinical features reported on patients with both chronic migraine and TOS. It is not a controlled clinical trial, however, and thus has limitations. Baseline clinical features were reported from chart review over a limited time period with different durations of follow-up. There was no natural control arm for this study other than showing that standard migraine strategies had failed in these patients.

Compared to non-participants, there were proportionately more participants who had responded to the questionnaires who had undergone surgical procedures, who came to follow-up appointments, and who had reported having better headache control at the last clinical follow-up. Mitigating these biases is that patients were frequently in the middle of treatment during their reports and there were no significantly different baseline characteristics in clinical features between responders and non-responders to the questionnaire. The retrospective nature of this study may further allow for selection bias as patients with better responses may be happier patients more likely to participate, however. Ideally, a longitudinal approach could be taken to establish recurrent surveys over the course of several years with the caveat that more demanding studies may lead to reduced participation while still selecting for more conscientious patients and those with better responses. Finally, the sample size is small relative to other headache and vascular studies but a report of 50 patients with combined TOS and chronic migraine represents the largest case series presented on this association to date in the English world literature. With

the recognition that these disorders are more related than currently suspected, these cases may appreciably increase with time.

CONCLUSION

Chronic migraines can be important manifestations of TOS that can improve with the treatment of TOS. TOS should be suspected when neck pain, shoulder pain, and limb paresthesia or swelling are present, particularly when ipsilateral to the headache, and when headaches are described as a pressure that is worse with recumbency. We propose that this association is much more common than is usually appreciated due to the frequency of head, neck, and chest trauma from overuse injury and some iatrogenic causes in patients with migraines. TOS-associated headaches may be chronic from the onset and should be considered in the differential in patients who meet the criteria for migraine and NDPH. Identifying secondary causes of headaches such as TOS is of critical importance to avoid losing a window of opportunity to treat before fibrosis and venous stenosis become permanent and drastic measures such as vein patching are needed. The consideration of TOS as a possible contributor to chronic migraines may help address at least one segment of the chronic migraine population and expedite appropriate therapy. We hope that this report will help justify research resources to study the association between TOS and migraine more comprehensively.

Ethics approval and consent to participate: Institutional approval was obtained from the Saint Francis Health Systems Institutional Research Ethics Board (Tulsa, OK), protocol number 2250-19. A chart review of all patients seen by the principal investigator over the course of 3.5 years was reviewed for a diagnosis of thoracic outlet syndrome. Data are presented

anonymously. Patients in the questionnaire study provided information with participant IDs. They were allowed to withdraw from the study at any time. All data were treated as confidential.

Consent for publication: Data from chart review are presented anonymously without personally identifying information. There are no identifying features in the images. Patients who were in the questionnaire study provided consent for participation and publication.

Availability of data and materials: The dataset supporting the conclusions of this article is available in the Harvard Dataverse:
https://dataverse.harvard.edu/dataset.xhtml?persistentId=doi:10.7910/DVN/Y4AEPL

Authors' contributions: LR performed data analysis, drafted the paper, and reviewed the interim and final manuscripts. JW provided patient data and reviewed the interim and the final manuscript. SA provided patient data and reviewed the interim and the final manuscript. YHC conceived the study, provided patient data, administered the questionnaire study, and reviewed all drafts of the manuscript.

Acknowledgments: The authors thank the patients who participated in the study. The authors received no compensation outside of routine clinical care for these patients. There was no external funding for this study and no involvement of 3rd party institutions in the collection of data or development of this manuscript.

FIGURE LEGENDS:

Figure 1: Examples of clinical signs of venous obstruction. A1] Left supraclavicular fossa, dashed arrow showing normal concavity. A2] Right supraclavicular fossa, solid arrow showing loss of definition of the lower sternocleidomastoid posterior border due to swelling in a patient with right vTOS. B1] Arms at the sides, dashed arrows showing flat external jugular veins. B2] Arms abducted to 90 degrees, solid arrows showing dilated external jugular veins in a patient with bilateral vTOS. C] Flushness and swelling of an arm in a patient with bilateral vTOS (only one arm shown), compared to the normal skin tone of the leg.

Figure 2: Representative examples of imaging in this cohort of chronic headache and TOS patients. Relevant abnormalities are marked by either open arrowheads or closed arrowheads. A] Right subclavian vein narrowing between the clavicle and 1st rib (open arrowhead) with contrast reflux into the internal jugular vein and lack of flow into the innominate vein (closed arrowhead), B] Overdeveloped external vein (closed arrowheads) with extensive collaterals (open arrowheads) in the setting of a stenosed subclavian vein. C] 3D reconstruction of venous system showing bilateral subclavian vein narrowing (open arrowheads) as well as a narrowed right-sided internal jugular vein (closed arrowhead).

Figure 3: Change in patient participants' rating of statements related to their functional capabilities before and after treating underlying TOS. Scales go from Strongly Disagree (-2) to Strongly Agree (+2) for a maximum possible change of 4 points.

REFERENCES

1. Serrano D, Manack AN, Reed ML, Buse DC, Varon SF, Lipton RB. Cost and predictors of lost productive time in chronic migraine and episodic migraine: results from the American Migraine Prevalence and Prevention (AMPP) Study. Value Health. 2013;16(1):31-8.
2. Headache Classification Committee of the International Headache Society (IHS) The International Classification of Headache Disorders, 3rd edition. Cephalalgia. 2018;38(1):1-211.
3. Dodick DW. Diagnosing Secondary and Primary Headache Disorders. Continuum (Minneap Minn). 2021;27(3):572-85.
4. Yancey JR, Sheridan R, Koren KG. Chronic daily headache: diagnosis and management. Am Fam Physician. 2014;89(8):642-8.
5. Illig KA, Donahue D, Duncan A, Freischlag J, Gelabert H, Johansen K, et al. Reporting standards of the Society for Vascular Surgery for thoracic outlet syndrome. J Vasc Surg. 2016;64(3):e23-35.
6. Grunebach H, Arnold MW, Lum YW. Thoracic outlet syndrome. Vasc Med. 2015;20(5):493-5.
7. Klaassen Z, Sorenson E, Tubbs RS, Arya R, Meloy P, Shah R, et al. Thoracic outlet syndrome: a neurological and vascular disorder. Clin Anat. 2014;27(5):724-32.
8. Raskin NH, Howard MW, Ehrenfeld WK. Headache as the leading symptom of the thoracic outlet syndrome. Headache. 1985;25(4):208-10.
9. Chahwala V, Tashiro J, Li X, Baqai A, Rey J, Robinson HR. Venous Thoracic Outlet Syndrome as a Cause of Intractable Migraines. Ann Vasc Surg. 2017;39:285 e5- e8.
10. Saxton EH, Miller TQ, Collins JD. Migraine complicated by brachial plexopathy as displayed by MRI and MRA: aberrant subclavian artery and cervical ribs. J Natl Med Assoc. 1999;91(6):333-41.
11. Ahn SS, Miller TJ, Chen JF, Chen SW, Feldtman R, Hwang W. Internal Jugular Vein Stenosis in Patients with Thoracic Outlet Symptoms. Journal of Vascular Surgery. 2013:100S.
12. Karam J, Thompson R. Neurogenic thoracic outlet syndrome. In: Hans SS, Shepard AD, Weaver MR, Bove PG, Long GW, editors. Endovascular and Open Vascular Reconstruction: A practical approach. 1st ed: CRC Press, Taylor & Francis Group; 2017. p. 377-82.
13. Gelabert M, Gelabert H. ATOS Consensus Guidelines. 2nd ed. llig KA, Thompson RW, Freischlag JA, Donahue DM, Jordan SE, Lum YW, et al., editors. Switzerland: Springer; 2021.
14. Karam J, Thompson R. Vascular Thoracic Outlet Syndrome. In: Hans SS, Shepard AD, Weaver MR, Bove PG, Long GW, editors. Endovascular and Open Vascular Reconstruction: A practical approach. 1st ed: CRC Press, Taylore & Francis Group; 2017. p. 371-5.
15. Illig KA, Doyle AJ. A comprehensive review of Paget-Schroetter syndrome. J Vasc Surg. 2010;51(6):1538-47.
16. Likes K, Rochlin DH, Call D, Freischlag JA. McCleery syndrome: etiology and outcome. Vasc Endovascular Surg. 2014;48(2):106-10.
17. Likes K, Rochlin DH, Call D, Freischlag JA. Coexistence of arterial compression in patients with neurogenic thoracic outlet syndrome. JAMA Surg. 2014;149(12):1240-3.
18. Ahn SS, Miller TJ, Chen SW, Chen JF. Internal jugular vein stenosis is common in patients presenting with neurogenic thoracic outlet syndrome. Ann Vasc Surg. 2014;28(4):946-50.

19. Thompson R. Diagnosis of Neurogenic Thoracic Outlet Syndrome: 2016 Consensus Guidelines and Other Strategies. 2nd ed. Illig KA, Thompson RW, Freischlag JA, Donahue DM, Jordan SE, Lum YW, et al., editors. Switzerland: Springer; 2021.
20. Illig KA. Diagnosis of vTOS: 2016 Consensus Guidelines. 2nd ed. Illig KA, Thompson RW, Freischlag JA, Donahue DM, Jordan SE, Lum YW, et al., editors. Switzerland: Springer; 2021.
21. Balachandra N, Padmalatha K, Prakash B, Ramesh B. Variation of the veins of the head and neck-external jugular and facial vein. Int J Anat Var. 2012;5:99-101.
22. Deslaugiers B, Vaysse P, Combes JM, Guitard J, Moscovici J, Visentin M, et al. Contribution to the study of the tributaries and the termination of the external jugular vein. Surg Radiol Anat. 1994;16(2):173-7.
23. Pekcevik Y, Sahin H, Pekcevik R. Prevalence of clinically important posterior fossa emissary veins on CT angiography. J Neurosci Rural Pract. 2014;5(2):135-8.
24. Zhou D, Ding JY, Ya JY, Pan LQ, Yan F, Yang Q, et al. Understanding jugular venous outflow disturbance. CNS Neurosci Ther. 2018;24(6):473-82.
25. Akobo S, Tubbs RS. Superior Petrosal Sinus. In: Tubbs RS, editor. Anatomy, Imaging and Surgery of the Intracranial Dural Venous Sinuses: Elsevier; 2020. p. 117-24.
26. Holmlund P, Johansson E, Qvarlander S, Wahlin A, Ambarki K, Koskinen LD, et al. Human jugular vein collapse in the upright posture: implications for postural intracranial pressure regulation. Fluids Barriers CNS. 2017;14(1):17.
27. Holmlund P, Eklund A, Koskinen LD, Johansson E, Sundstrom N, Malm J, et al. Venous collapse regulates intracranial pressure in upright body positions. Am J Physiol Regul Integr Comp Physiol. 2018;314(3):R377-R85.
28. Kosugi K, Yamada Y, Yamada M, Yokoyama Y, Fujiwara H, Yoshida K, et al. Posture-induced changes in the vessels of the head and neck: evaluation using conventional supine CT and upright CT. Sci Rep. 2020;10(1):16623.
29. Collins JD, Saxton EH, Miller TQ, Ahn SS, Gelabert H, Carnes A. Scheuermann's disease as a model displaying the mechanism of venous obstruction in thoracic outlet syndrome and migraine patients: MRI and MRA. J Natl Med Assoc. 2003;95(4):298-306.
30. Marini TJ, Chughtai K, Nuffer Z, Hobbs SK, Kaproth-Joslin K. Blood finds a way: pictorial review of thoracic collateral vessels. Insights Imaging. 2019;10(1):63.
31. Qureshi AI, Saleem MA, Naveed O, Qureshi MA, Wallery SS. Upright Catheter-Based Cerebral Angiography. J Vasc Interv Neurol. 2017;9(6):14-9.
32. Griessenauer CJ, Raborn J, Foreman P, Shoja MM, Loukas M, Tubbs RS. Venous drainage of the spine and spinal cord: a comprehensive review of its history, embryology, anatomy, physiology, and pathology. Clin Anat. 2015;28(1):75-87.
33. Carpenter K, Decater T, Iwanaga J, Maulucci CM, Bui CJ, Dumont AS, et al. Revisiting the Vertebral Venous Plexus-A Comprehensive Review of the Literature. World Neurosurg. 2021;145:381-95.
34. Angappan D, Garrett M, Henry C, Riddle A, Wilson JL. Pediatric Stroke due to Thoracic Outlet Syndrome Treated with Thrombolysis and Thrombectomy: A Case Report. Children (Basel). 2022;9(6).
35. Meumann EM, Chuen J, Fitt G, Perchyonok Y, Pond F, Dewey HM. Thromboembolic stroke associated with thoracic outlet syndrome. J Clin Neurosci. 2014;21(5):886-9.

Table 1: Timeline and diagnosis of chronic migraine TOS patients

Headache time frame (n=50)	*Mean +/- s.d.*	*Median (range)*
Age at presentation	43.9+/-12.7 years	44 (17-78) years
Age at onset any migraine	23.9+/-14.9 years	23.5 (5-62) years
Age at onset chronic migraine	34.8+/-13.4 years	36 (5-62) years
Duration chronic migraine	9.3+/-12.7 years	5.8 (0.3-73) years
Headache types (n=50)		
Migraine without aura total		28
(+) NDPH*		7
Migraine with aura total		20
(+) NDPH*		1
Hemiplegic migraine		2
Chronic migraine within 1 year of headache onset		21
*New Daily Persistent Headache		

Table 2: Laterality and associated symptoms with migraine

Associated symptoms	Skull base or neck pain	Shoulder or shoulder blade pain	Chest pain	Arm-hand numbness, tingling, weakness	Syncope or presyncope	Visual problems	Vertigo	Tinnitus	Ear fullness
Symptom present	39	36	31	50	14	25	24	15	20
Ipsilateral to headache	24 (62%)	26 (72%)	10 (32%)	30 (60%)	na	7 (28%)	na	7 (47%)	9 (45%)
Contralateral to headache	0 (0%)	0 (0%)	0 (0%)	1 (2%)	na	0 (0%)	na	0 (0%)	0 (0%)
Bilateral	8 (21%)	5 (14%)	1 (3%)	15 (30%)	na	18 (72%)	na	4 (27%)	6 (30%)
Unclear laterality	7 (18%)	5 14%)	20 (65%)	4 (8%)	na	0 (0%)	na	4 (27%)	5 (25%)
Symptom absent	2	3	16	0	22	14	12	19	18
Symptom unqueried	9	11	3	0	14	11	14	16	12

Table 3: Imaging characteristics of chronic migraine TOS patients

MRI brain with or without contrast (n=36)			**CT chest with contrast (n=50)**	
Normal	24		Right SCV or BCV stenosis	13
Small vessel disease	4		Left SCV or BCV stenosis	13
Cerebellar ectopia	4			
Occipital lobe stroke	1		Normal	13
Cerebellar stroke	1		Non-diagnostic (poor contrast)	3
Middle cerebral artery aneurysm	1			
Demyelination	1		*Structural abnormalities*	
Cervical spine syrinx	1		Cervical rib	3
			Thymic hyperplasia	3
CT head without contrast (n=26)			Thoracic schwannoma	1
Normal	21		Anomalous rib insertion	1
Arachnoid cyst	1			
Parietal cyst	1		**SCV=subclavian vein*	
Middle cerebral artery aneurysm coiled	1		**BCV=brachiocephalic vein*	
Vertebral occlusion	1			
Cerebellar ectopia	1			
No MRI or CT head	5			

Table 4: Features of headache quality and temporal qualities in survey responders

Headache features	***Participants* (n=24)**	**%**
Laterality		
Predominantly unilateral	15	63
Right	10	42
Left	5	21
Alternating unilateral	4	17
Always bilateral	5	21
Unsure	1	4
Area of maximum pain		
Skull base	11	46
Forehead	5	21
Vertex	4	17
Temples	4	17
Around ear	1	4
Headache description		
"Pressure, head exploding"	10	42
"Throbbing"	5	21
"Pressure, head squeezing"	5	21
"Sharp shooting"	3	12
"Dull"	2	8
Years between onset of migraine and arm symptoms	***Participants (n=23)***	*%*
within 1 year	10	43
1-5 years	6	26
5-10 years	1	4
>10 years	6	26
Relative onset of migraine to arm symptoms in years		
Migraine onset before arm symptoms	17	74
Arm symptoms onset before migraine	5	22
Migraine and arm symptoms onset same time	1	4

Synchronicity of headache and arm symptoms for each migraine episode		
Always together	4	17
Sometimes together	16	70
Never together	3	13

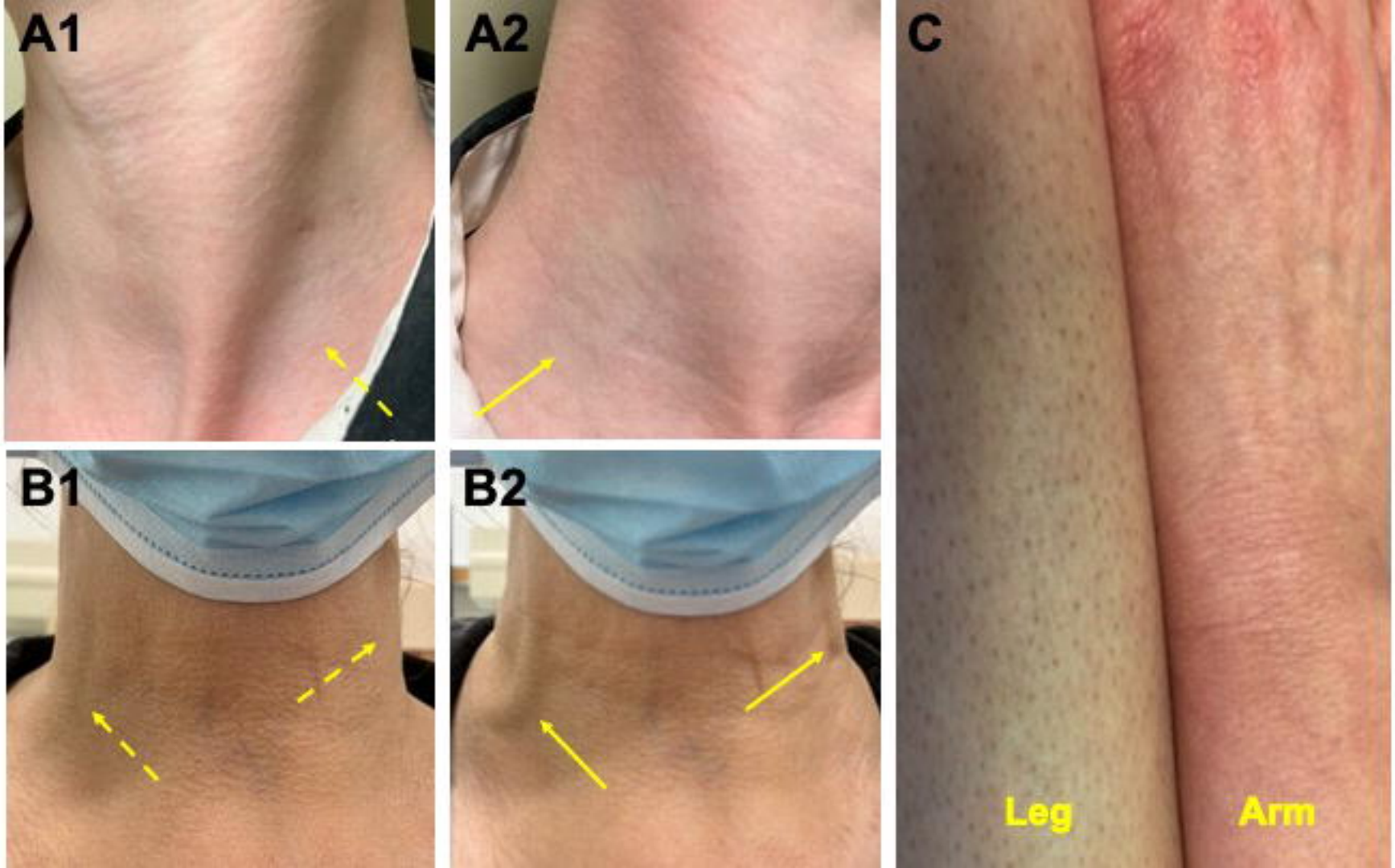
A1
A2
C
B1
B2
Leg
Arm

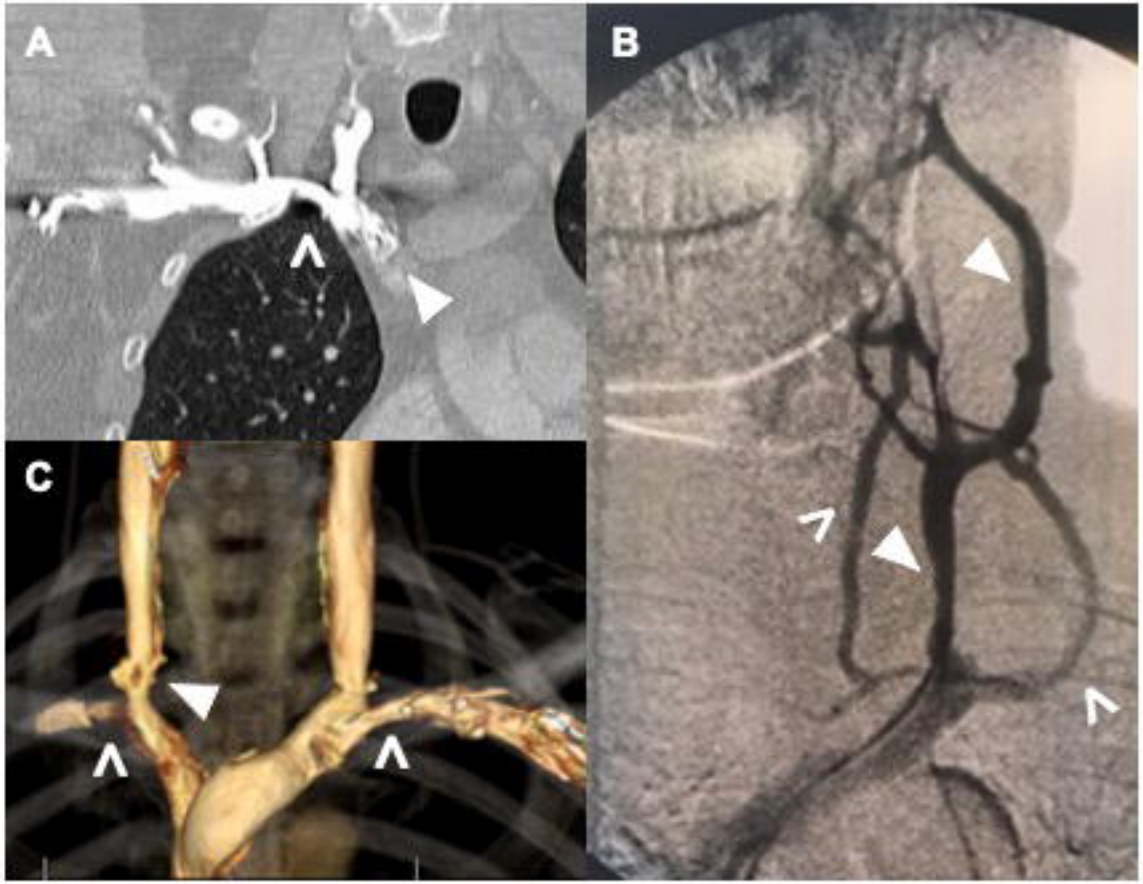
A
B
C

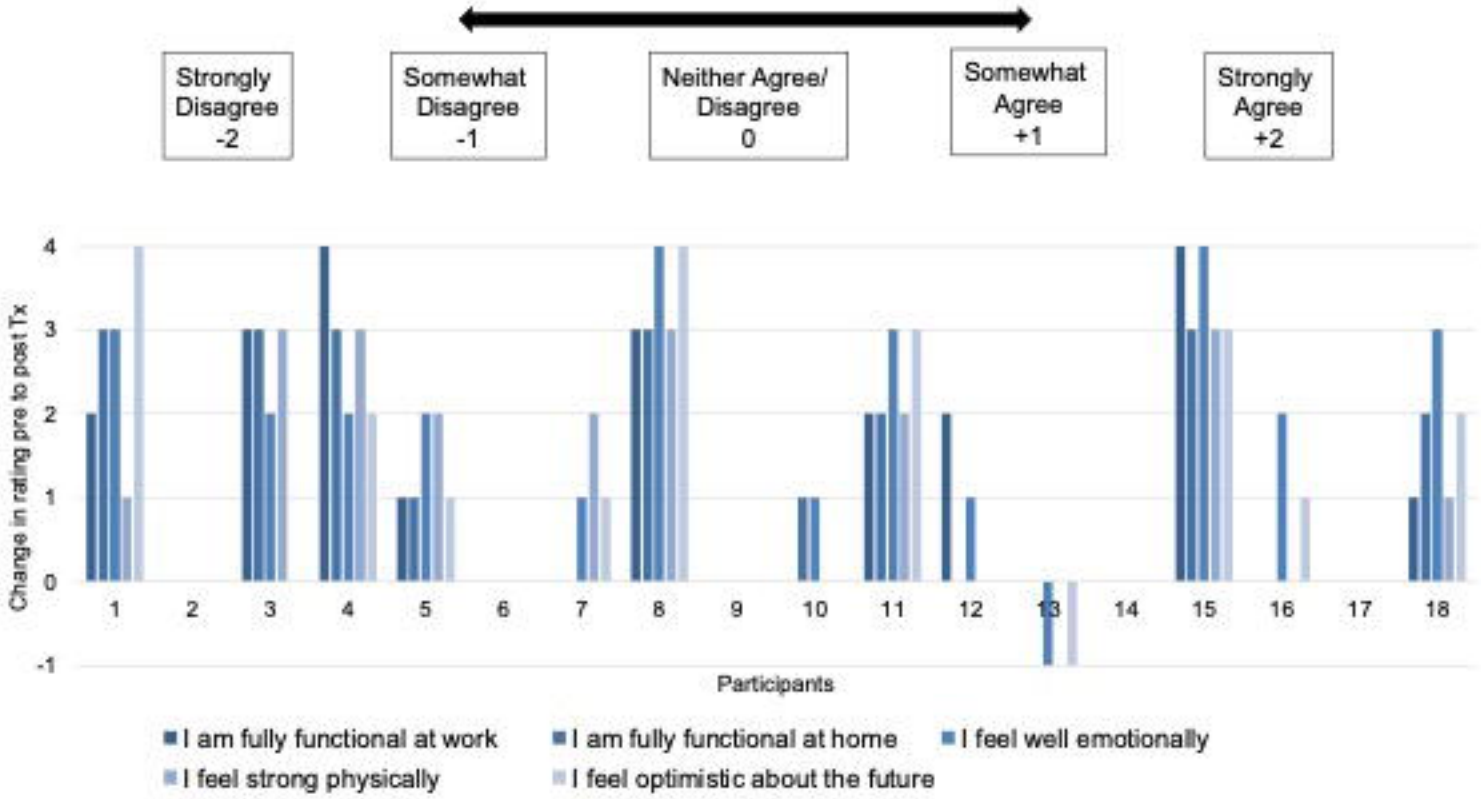
Strongly Disagree -2
Somewhat Disagree -1
Neither Agree/ Disagree 0
Somewhat Agree +1
Strongly Agree +2
Change in rating pre to post Tx
4
3
2
1
0
-1
1 2 3 4 5 6 7 8 9 10 11 12 13 14 15 16 17 18
Participants
I am fully functional at work
I am fully functional at home
I feel well emotionally
I feel strong physically
I feel optimistic about the future