Normal values for mitral and tricuspid early inflow blood flow velocity variation using real time phase contrast cardiovascular magnetic resonance

Simon Thalén MD[1], Einar Heiberg PhD[2], Peder Sörensson MD PhD[3], Daniel Giese PhD[4,5], Andreas Sigfridsson PhD[1*], Martin Ugander MD PhD[1,6*§]

[1]Department of Clinical Physiology, Karolinska University Hospital, and Karolinska Institutet, Stockholm, Sweden.

[2]Department of Clinical Sciences Lund, Lund University, Lund, Sweden

[3]Department of Cardiology, Karolinska University Hospital, and Karolinska Institutet, Stockholm, Sweden.

[4]Siemens Healthcare, Erlangen, Germany.

[5]Institute of Radiology, University Hospital Erlangen, Friedrich-Alexander-Universität Erlangen-Nürnberg (FAU), Erlangen, Germany

[6]Kolling Institute, Royal North Shore Hospital, and University of Sydney, Sydney, Australia.

* Denotes equal contribution

§ Corresponding author

Abstract (max 250 words)

Background: Diastolic ventricular interdependence influences the breathing-induced variation in early diastolic blood flow velocities across the mitral and tricuspid valve. The aim of this study was to develop a method to measure the respiratory variation in mitral and tricuspid early inflow velocities using semi-automatic analysis of real time phase contrast (RT-PC) cardiovascular magnetic resonance (CMR) images, and describe normal reference values. ***Methods:*** Clinically referred patients (n=24, median [interquartile range] age 55 [46–65] years, 48% female) with no pericardial effusion or pericardial thickening underwent through-plane RT-PC CMR imaging using a research sequence at 3T in a basal short-axis view over a 30 s acquisition during free breathing. One patient with constrictive pericarditis and one patient with a hemodynamically significant pericardial effusion were imaged to illustrate clinical feasibility. Image analysis was performed using an in-house developed plugin. A region of interest was prescribed over encompassing the mitral and tricuspid orifices, respectively. The highest (Vmax) and lowest (Vmin) early inflow velocities were then automatically recorded. Respiratory variation was defined as (Vmax-Vmin)/Vmax. ***Results:*** The respiratory variation in mitral and tricuspid early inflow velocity in patients without constrictive pericarditis or pericardial effusion was (mean±SD) 22±7% (upper limit 35%) and 38±7% (upper limit 51%). The patient with constrictive pericarditis had a respiratory variation in mitral and tricuspid early inflow velocities of 60% and 44%, respectively. The patient with 35 mm pericardial effusion had a respiratory variation in mitral and tricuspid early inflow velocities of 62% and 64%, respectively.

Introduction

Diastolic ventricular interdependence, sometimes also referred to as interaction or coupling, occurs as an increased pressure gradient between the atrium and ventricle in one side of the heart causes a decreased pressure gradient between the atrium and ventricle on the other side of the heart (1). This phenomenon is more pronounced with an intact pericardium, but also occurs post pericardectomy (2). Ventricular interdependence is measured using Doppler echocardiography or invasive cardiac catheterization where the respiratory variation in velocity or pressure is measured.

An increase or exaggeration of ventricular interdependence can occur in several different clinical settings, most notably pericardial effusion/cardiac tamponade (3) and constrictive pericarditis (4). During respiration, negative intrapleural pressures increase the venous return and rate of filling of the right heart, thus decreasing the rate of filling of the left heart. During expiration the opposite occurs. In the case of a pericardial effusion compressing the heart, the finite volume of the ventricles is decreased, and the venous return to the right heart occurs at a greater expense of the left, causing an increased ventricular interdependence.

The pericardium can stretch to accommodate several litres of effusion fluid provided the increase is gradual, but a comparatively small yet rapid increase can cause cardiac tamponade in a matter of minutes (5,6). Therefore, a single measurement of effusion volume is not sufficient to predict the onset of cardiac tamponade. However, as a pericardial effusion progresses towards cardiac tamponade a range of hemodynamic events occur (5). The earliest is considered right atrial early systolic collapse and others include right ventricular early diastolic collapse in addition to increased diastolic ventricular interdependence measured as respiratory changes in transvalvular early flow velocities (7). Pulsus paradoxus, considered an important clinical sign of imminent tamponade, defined as a decrease of over 10 mmHg systolic blood pressure during inspiration, is a physiological consequence of diastolic

ventricular interdependence (8–10) and respiratory changes in transvalvular early inflow velocities have been described by some as a Doppler surrogate marker for pulsus paradoxus (11) and even flow velocity paradoxus (12).

The diagnosis of constrictive pericarditis remains a challenge and respiratory variation in transvalvular inflow velocities measured using Doppler echocardiography is considered a valuable tool in separating constrictive and restrictive physiologies (4,13–15). The increased diastolic ventricular interdependence in the case of constrictive pericarditis is caused by a decreased pulmonary venous return to the left ventricle during inspiration rather than an increased systemic venous return to the right ventricle (16).

In one study using real time phase contrast (RT-PC) CMR, the amount of ventricular interdependence was evaluated and found to be increase in patients with constrictive pericarditis by quantifying the respiratory difference in maximal septal excursion, normalized to the biventricular diameter (17). In another study real time phase contrast (RT-PC) CMR was used to measure the respiratory variation in transvalvular early velocities and achieved excellent results in identifying constrictive physiology (18).

The current methodology for quantification of respiratory variation in early transvalvular inflow velocity as well as normalized differences in maximal septal excursion using RT-PC CMR has seen limited clinical adoption in part due to the cumbersome and manual post-processing required.

The aim of this study was to develop a user-friendly method to measure diastolic ventricular interdependence by simultaneously quantifying the respiratory variation in mitral and tricuspid early inflow velocities using semi-automatic analysis of RT-PC CMR images, and derive normal reference values.

Materials and methods

Study design

This was an observational retrospective imaging study of 27 patients who had undergone CMR. The primary outcome was respiratory variation in mitral inflow velocity.

Patients

Patients were included if they had undergone a clinically indicated CMR exam and had provided written consent to participate in retrospective imaging studies. CMR imaging took place between June 2020 and Sept 2020 in the Department of Clinical Physiology, Karolinska Universitetsjukhuset, Stockholm, Sweden.

Patients without pericardial effusion, pericardial thickening, or septal bounce (n=27) were randomly selected, as well as one patient with constrictive pericarditis and one patient with hemodynamically significant pericardial effusion of 35 mm. Exclusion criteria during screening included the presence of congenital heart defects, chronic obstructive lung disease, inaccurate slice planning, irregular breathing pattern, and contraindications to CMR.

Image acquisition

CMR studies were performed at 3T (MAGNETOM Skyra, Siemens Healthcare, Erlangen, Germany) in a basal short-axis view over a 30 s acquisition during free breathing using a research sequence. Typical image acquisition parameters were: repetition time 3.7 ms, water excitation pulse with flip angle 10°, slice thickness 8 mm, FOV 360x266 mm², matrix 208x135, aliasing velocity (venc) 150 cm/s and shared velocity encoding enabled (19). Compressed sensing with an acceleration factor of 7.7 was used to achieve a temporal resolution of 48 ms (20). RT-PC velocity-encoded imaging data were acquired with through-plane velocity encoding and a slice position across the atrioventricular plane from a horizontal long-axis view in end-systole (Figure 4C). A 30 second dataset of RT-PC data was acquired

per patient, spanning several cardiac and respiratory cycles. All subjects were in sinus rhythm at the time of CMR imaging. Phase offset errors were corrected based on estimation in stationary tissue (21).

RT-PC velocity measurements and analysis were performed off-line using an in-house developed software as a plugin to the software program Segment (Medviso AB, Lund, Sweden) (22). The plugin was developed using source code available for research, in the software development environment MATLAB (The MathWorks, Inc., Natick, Massachusetts, United States).

The plugin was designed to allow the user to manually define a region of interests (ROI) encompassing the mitral and tricuspid orifices, respectively, and propagate them across all time frames. The ROIs could be reviewed in each frame to ensure correct placement. The negative component of the flow velocity present in the mitral ROI during systole, part of the aortic outflow, is then used to segment the data into individual cardiac cycles by considering the peak negative flow as separating the cardiac cycles. Spectral plots of mitral and tricuspid velocities are displayed and the mean of the ten pixels with the highest velocities is used to construct a velocity-time curve for subsequent identification of peak early filling velocities. The user can increase or decrease the number of pixels used to construct the velocity-time curve, the visibility of which can be toggled, to ensure a visually acceptable fit with the spectral plot.

The peak early filling velocity is then identified within each cardiac cycle by identifying the first local maxima with a value exceeding the mean plus one standard deviation of the velocity in that timeframe. An example spectral velocity-time plot is shown in Figure 2. The respiratory variation in early inflow velocities is then defined as the absolute value of the change as a percentage of the maximum early inflow velocity as described in Equation 1.

$$\text{respiratory variation} = \frac{\text{maximum velocity} - \text{minimum velocity}}{\text{maximum velocity}} \; x\; 100\#(1)$$

For the sake of completeness an second definition was also used following (23) as follows:

$$\text{respiratory variation} = \frac{\text{expiratory velocity} - \text{inspiratory velocity}}{\text{expiratory velocity}} \; x\; 100\#(2)$$

##

Finally a third definition following (18) was used as follows:

$$\text{mitral respiratory variation} = \frac{\text{expiratory velocity} - \text{inspiratory velocity}}{\text{inspiratory velocity}} \; x\; 100\;\#(3)\#$$

##

$$\text{tricuspid respiratory variation} = \frac{\text{inspiratory velocity} - \text{expiratory velocity}}{\text{expiratory velocity}} \; x\; 100\;\#(4)\#$$

##

Statistical analysis

The normality of distributions was assessed both visually and the Shapiro-Wilks test, and data are reported as median [interquartile range] or mean±SD as appropriate. Normal reference ranges were calculated as mean ± 1.96*standard deviation. Statistical calculations were performed using the software package R (R Core Team 2020, Vienna, Austria).

Results

Three patients were excluded from analysis, two due to inaccurate slice planning and one due to a highly irregular breathing, leaving a total of (n=24) patients included in the final analysis. Clinical characteristics are summarized in Table 1.

The respiratory variation in mitral and tricuspid early inflow velocity using Equation 1. in patients without constrictive pericarditis or pericardial effusion was (mean±SD) 22±7% (upper normal limit 35%) and 38±7% (upper normal limit 51%). Using Equation 2 the respiratory variation in mitral inflow velocities was for arithmetical reasons identical, and the tricuspid early inflow velocity (mean±SD) -62±19% (lower normal limit -99%). Using

Equations 3 and 4, the respiratory variation in mitral inflow velocities was 29±12% and tricuspid early inflow velocities 62±19% (upper limit 99%).

The patient with constrictive pericarditis had a respiratory variation in mitral and tricuspid early inflow velocities using the definition in equation 1 of 51% and 44%, using the definition in equation 2 of 51% and -79% and using equations 3 and 4, 103% and 79%.

The patient with 35 mm pericardial effusion had a respiratory variation in mitral and tricuspid early inflow velocities using the definition in equation 1 of 62% and 64%, using the definition in equation 2 of 62 % and -178% and using equations 2 and 3, 160% and 178%.

Discussion

This study shows clinical feasibility and presents normal values for respiratory variation in early transvalvular velocities measured using RT-PC CMR.

The normal values of the current study are higher when compared to normal values obtained with Doppler echocardiography. In the original ground breaking study on respiratory variation in cardiac tamponade and pericardial effusion almost no respiratory variation in mitral inflow velocity in normal subjects could be detected (3). Likewise a later study reported almost no respiratory variation in velocity-time integrals of mitral inflow in normal subjects (24). Using the same definition of maximal respiratory variation as a recent study also using RT-PC CMR, as described in Equations 3 and 4, our normal values are markedly higher. One possible explanation could be the longer acquisition time on our part. It stands to reason that a longer acquisition time, 30 s vs 10-20 s, will have a greater probability of capturing a mitral or tricuspid early inflow coinciding perfectly with an inspiration or expiration and thus causing a greater variation.

Due to the differences in early inflow velocities between patients, respiratory variation has historically been specified as a percentage, a fraction with the positive, negative or in

some cases the absolute difference between inspiratory (V_{insp}) and expiratory (V_{exp}) early inflow velocities as the numerator and either one of V_{insp} or V_{exp} as the denominator.

Conceptually, for mitral velocities, V_{insp} as denominator corresponds to an expiratory increase as a fraction of V_{insp}, whereas the choice of V_{exp} as a denominator corresponds to an inspiratory decrease as a fraction of V_{exp}. For the tricuspid velocities, the situation is reversed with V_{insp} as a denominator corresponding to an expiratory decrease in velocities as a fraction of V_{insp}, and V_{exp} as an inspiratory increase in velocities as a fraction of V_{exp}. The method of calculation, in effect the choice of denominator, is not always specified in the literature, although an implicit definition can in some cases be inferred.

Most authors have favoured conceptualizing mitral respiratory variation as an inspiratory decrease in percent of early mitral inflow velocities and tricuspid respiratory variation as an inspiratory increase (2,3,23,25–29), possibly due to the prior definition of pulsus paradoxus as a drop in systolic pressure during inspiration (8). Others report maximal respiratory change defined as the expiratory increase in mitral early inflow velocities and expiratory decrease in tricuspid early inflow velocities (18). Others report the respiratory variation as the change in early inflow velocity during inspiration and expiration as compared to apnea (4,30). Others still reported respiratory absolute change in velocities (31). As has already been pointed out and is evident from our study, the results will be radically different depending on the choice of denominator (32).

Current guidelines from the American Society for Echocardiography states that respiratory variation in both mitral and tricuspid velocities should calculated as the difference between V_{exp} and V_{insp}, positive or negative, and V_{exp} as the denominator (23). This means that mitral early inflow is described as a percent decrease in velocity whereas the tricuspid early inflow as a percent increase. A percent increase will always be greater than the same change calculated as a percentage decrease by simple arithmetic, it would therefore make

more conceptual sense to describe the tricuspid variation as a decrease as well, hence using V_{insp} as denominator. In this study we therefore calculated respiratory variation in mitral and tricuspid early inflow velocities as the absolute change in velocity divided by the maximum velocity.

Strengths and limitations

A strength of this study is the use of a semi-automatic methodology for analysis of RT-PC data. Besides drawing two ROIs, evaluation using our software plugin typically requires no further user input. Historically, measurements of respiratory variations in transvalvular inflow velocities by Doppler echocardiography have relied upon observations of chest movements (24), thermistor recordings (3,33) or transducer recordings (24) to keep track patients respiratory motion as well as manual calculations on paper tracings for analysis of flow velocity data. In our study, the lung-diaphragm interface in MRI cine images was used to visualize and separate inspiration from expiration.

A limitation of this study is that it included one patient with a hemodynamically significant pericardial effusion and one patient with constrictive pericarditis for purposes of illustration. Future studies are justified to prospectively test the diagnostic performance of the methodology described in the current study.

Another limitation is that the imaging plane of RT-PC acquisition was the short-axis plane and some displacement is to be expected due to breathing. This problem is not limited to RT-PC CMR imaging. Doppler echocardiography, widely used in previous studies of respiratory variation in transvalvular inflow velocities, is also vulnerable to displacement during breathing. We sought to minimize the effect of in-plane displacement due to breathing by ensuring that the mitral valve was contained within the ROI for each timeframe. Our software plugin automatically generates the velocity-time graph by averaging the ten, or a number selected by the user, highest velocities within each timeframe of the ROI.

The method presented in this study differs from a purely morphological imaging method such as 2D echocardiography or cine CMR which are used to quantify the size of the effusion or thickness of the pericardium in millimetres. The method presented in this study measures a physiological consequence of an altered cardiac pressure-volume relationship. It has been found that 0.6% of CMR exams had incidental findings of clinically significant pericardial effusion (34). The ability to in immediately evaluate ventricular interdependence to provide information as to the hemodynamical significance would be advantageous. In the case of constrictive pericarditis an evaluation of ventricular interdependence is also advantageous as 18% of surgically proven cases have been found to lack pericardial thickening and thus require hemodynamic evaluation (35).

Conclusions

This study reports normal values and demonstrates that semi-automatic analysis of magnetic resonance RT-PC flow measurement is feasible and can be used to evaluate diastolic ventricular interdependence by measuring the respiratory variation in transvalvular inflow velocities. The method used is made freely available as open-source software.

References

1. Bove AA, Santamore WP. Ventricular interdependence. Prog Cardiovasc Dis. 1981 Mar 1;23(5):365–88.

2. Ginghina C, Beladan C, Iancu M, Calin A, Popescu BA. Respiratory maneuvers in echocardiography: A review of clinical applications. Vol. 7. 2009. 42 p.

3. Appleton CP, Hatle LK, Popp RL. Cardiac tamponade and pericardial effusion: respiratory variation in transvalvular flow velocities studied by Doppler echocardiography. J Am Coll Cardiol. 1988;11(5):1020–30.

4. Hatle LK, Appleton CP, Popp RL. Differentiation of constrictive pericarditis and restrictive cardiomyopathy by Doppler echocardiography. Circulation. 1989;79(2):357–70.

5. Shabetai R. Pericardial effusion: haemodynamic spectrum. Heart. 2004 Mar 1;90(3):255–6.

6. Saito Y, Donohue A, Attai S, Vahdat A, Brar R, Handapangoda I, et al. The Syndrome of Cardiac Tamponade with “Small” Pericardial Effusion. Echocardiography. 2008;25(3):321–7.

7. Roy CL, Minor MA, Brookhart MA, Choudhry NK. Does this patient with a pericardial effusion have cardiac tamponade? JAMA. 2007;297(16):1810–8.

8. Dornhorst AC, Howard P, Leathart GL. Pulsus paradoxus. Lancet Lond Engl. 1952 Apr 12;1(6711):746–8.

9. Curtiss EI, Reddy PS, Uretsky BF, Cecchetti AA. Pulsus paradoxus: Definition and relation to the severity of cardiac tamponade. Am Heart J. 1988 Feb 1;115(2):391–8.

10. Hamzaoui O, Monnet X, Teboul JL. Pulsus paradoxus. Eur Respir J. 2013 Dec 1;42(6):1696–705.

11. Alerhand S, Carter JM. What echocardiographic findings suggest a pericardial effusion is causing tamponade? Am J Emerg Med. 2019;37(2):321–6.

12. Shyy W, Knight RS, Kornblith A, Teismann NA. Point-of-Care Diagnosis of Cardiac Tamponade Identified by the Flow Velocity Paradoxus. J Ultrasound Med. 2017;36(11):2197–201.

13. Nishimura RA. Constrictive pericarditis in the modern era: a diagnostic dilemma. Heart. 2001;86(6):619–23.

14. Oh JK, Hatle LK, Seward JB, Danielson GK, Schaff HV, Reeder GS, et al. Diagnostic role of Doppler echocardiography in constrictive pericarditis. J Am Coll Cardiol. 1994 Jan;23(1):154–62.

15. Hancock EW. Differential diagnosis of restrictive cardiomyopathy and constrictive pericarditis. Heart. 2001 Sep 1;86(3):343–9.

16. Shabetai R, Oh JK. Pericardial Effusion and Compressive Disorders of the Heart: Influence of New Technology on Unraveling its Pathophysiology and Hemodynamics. Cardiol Clin. 2017 Nov 1;35(4):467–79.

17. Francone M, Dymarkowski S, Kalantzi M, Bogaert J. Real-time cine MRI of ventricular septal motion: A novel approach to assess ventricular coupling. J Magn Reson Imaging. 2005;21(3):305–9.

18. Thavendiranathan P, Verhaert D, Walls MC, Bender JA, Rajagopalan S, Chung YC, et al. Simultaneous Right and Left Heart Real-Time, Free-Breathing CMR Flow Quantification Identifies Constrictive Physiology. JACC Cardiovasc Imaging. 2012 Jan;5(1):15–24.

19. Lin HY, Bender JA, Ding Y, Chung YC, Hinton AM, Pennell ML, et al. Shared velocity encoding: a method to improve the temporal resolution of phase-contrast velocity measurements. Magn Reson Med. 2012 Sep;68(3):703–10.

20. Lustig M, Donoho D, Pauly JM. Sparse MRI: The application of compressed sensing for rapid MR imaging. Magn Reson Med. 2007;58(6):1182–95.

21. Nickander J, Lundin M, Abdula G, Jenner J, Maret E, Sörensson P, et al. Stationary tissue background correction increases the precision of clinical evaluation of intra-cardiac shunts by cardiovascular magnetic resonance. Sci Rep. 2020 Dec;10(1):5053.

22. Heiberg E, Sjögren J, Ugander M, Carlsson M, Engblom H, Arheden H. Design and validation of Segment--freely available software for cardiovascular image analysis. BMC Med Imaging. 2010;10:1.

23. Klein AL, Abbara S, Agler DA, Appleton CP, Asher CR, Hoit B, et al. American Society of Echocardiography Clinical Recommendations for Multimodality Cardiovascular Imaging of Patients with Pericardial Disease. J Am Soc Echocardiogr. 2013 Sep;26(9):965-1012.e15.

24. Leeman DE, Levine MJ, Come PC. Doppler echocardiography in cardiac tamponade: exaggerated respiratory variation in transvalvular blood flow velocity integrals. J Am Coll Cardiol. 1988;11(3):572–8.

25. Burstow DJ, Oh JK, Bailey KR, Seward JB, Tajik AJ. Cardiac Tamponade: Characteristic Doppler Observations. Mayo Clin Proc. 1989 Mar;64(3):312–24.

26. Simeonidou E, Hamouratidis N, Tzimas K, Tsounos J, Roussis S. Respiratory variation in mitral flow velocity in pericardial effusion and cardiac tamponade. Angiology. 1994;45(3):213–8.

27. Zhang S, Kerins DM, Iii BFB. Doppler Echocardiography in Cardiac Tamponade and Constrictive Pericarditis. Echocardiography. 1994;11(5):507–21.

28. Kim JS, Ha JW, Im E, Park S, Choi EY, Cho YH, et al. Effects of pericardiectomy on early diastolic mitral annular velocity in patients with constrictive pericarditis. Int J Cardiol. 2009 Mar 20;133(1):18–22.

29. Appleton C, Gillam L, Koulogiannis K. Cardiac Tamponade. Cardiol Clin. 2017 Nov 1;35(4):525–37.

30. Picard MH, Sanfilippo AJ, Newell JB, Rodriguez L, Guerrero JL, Weyman AE. Quantitative relation between increased intrapericardial pressure and Doppler flow velocities during experimental cardiac tamponade. J Am Coll Cardiol. 1991 Jul;18(1):234–42.

31. Gonzalez MS, Basnight MA, Appleton CP. Experimental pericardial effusion: relation of abnormal respiratory variation in mitral flow velocity to hemodynamics and diastolic right heart collapse. J Am Coll Cardiol. 1991;17(1):239–48.

32. Siniorakis E, Arvanitakis S, Zarreas E, Barlagiannis D, Skandalakis N, Karidis C. Calculating the respiratory flow velocity fluctuations in pericardial diseases. Int J Cardiol. 2010 Nov;145(1):92–3.

33. Wayne VS, Bishop RL, Spodick DH. Dynamic effects of pericardial effusion without tamponade. Respiratory responses in the absence of pulsus paradoxus. Br Heart J. 1984 Feb;51(2):202–4.

34. McKenna DA, Laxpati M, Colletti PM. The Prevalence of Incidental Findings at Cardiac MRI. Open Cardiovasc Med J. 2008 Apr 2;2:20–5.

35. Talreja DR, Edwards WD, Danielson GK, Schaff HV, Tajik AJ, Tazelaar HD, et al. Constrictive Pericarditis in 26 Patients With Histologically Normal Pericardial Thickness. Circulation. 2003 Oct 14;108(15):1852–7.

Declarations

Ethics approval and consent to participate

This study is a retrospective study of clinically acquired imaging data. All patients provided written informed consent prior to enrolment. The patients were already scheduled to undergo CMR imaging as part their clinical examination. All patient data were anonymized prior to analysis to ensure the integrity of the patients' identities. Approval from the Stockholm regional ethics board was obtained (Number 2011/1077-31/3).

Consent for publication

Written informed consent was obtained from patients for publication of their individual details on a group level and anonymized images in this manuscript. The consent form is held in the patients' clinical notes and is available for review by the Editor-in-Chief.

Software and data availability

The plugin used is available as part of the software Segment which is freely available for research purposes from https://medviso.com/. Platform independent MATLAB source code is also available as a fork of the source code version of Segment at https://github.com/SuperSimon81/segment-open-and-respiratory-variation with DOI 10.5281/zenodo.7462668. All data produced in the present study are available upon reasonable request to the corresponding author.

Funding

The research was funded in part by the Swedish Research Council, Swedish Heart and Lung Foundation, the Stockholm County Council and Karolinska Institutet. Karolinska

University Hospital has a research and development agreement regarding CMR with Siemens Healthineers.

Author contributions

Simon Thalén designed the study, performed data acquisition, data analysis and wrote the manuscript. Einar Heiberg PhD provided crucial support in development of the software plugin. Daniel Giese participated in the development of the research pulse sequence used for data acquisition. Andreas Sigfridsson supervised the technical aspects of data acquisition. Henrik Engblom and Peder Sörensson participated in data acquisition. All authors substantially contributed to the interpretation of the results. Martin Ugander designed the study and supervised the project.

Conflict of interests

EH is the founder of Medviso AB, Lund, Sweden, which sells a commercial version of the software Segment. The other authors declare no conflict of interests.

Acknowledgements

We acknowledge the support provided by the CMR technologists at the Department of Clinical Physiology, Karolinska University Hospital.

Table 1. Clinical characteristics

Clinical characteristics and CMR findings in 24 patients without increased pericardial thickening or effusion.

Characteristic	
Mitral respiratory variation*, %	22±7%
Tricuspid respiratory variation*, %	38±7%
Maximum mitral early inflow velocity, m/s	0.39±0.10
Minimum mitral early inflow velocity, m/s	0.30±0.09
Maximum tricuspid early inflow velocity, m/s	0.27±0.07
Minimum tricuspid early inflow velocity, m/s	0.17±0.05
Left ventricular ejection fraction, %	51 (39-61)
Age, years	55 (46-65)
Female, %	42%

Continuous data is given as mean±SD, median (interquartile range) or number (%).

* Calculated as described in Equation 1.

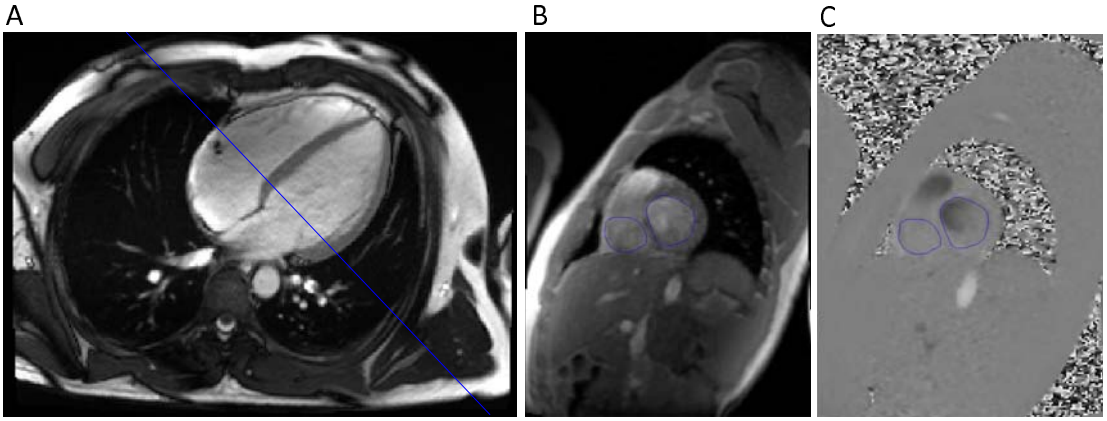

Figure 1. A four chamber long-axis cine acquisition in end systole that shows how the plane for through-plane RT-PC imaging was prescribed (A). Regions of interest for the mitral and tricuspid valves are shown in magnitude and phase images (B and C).

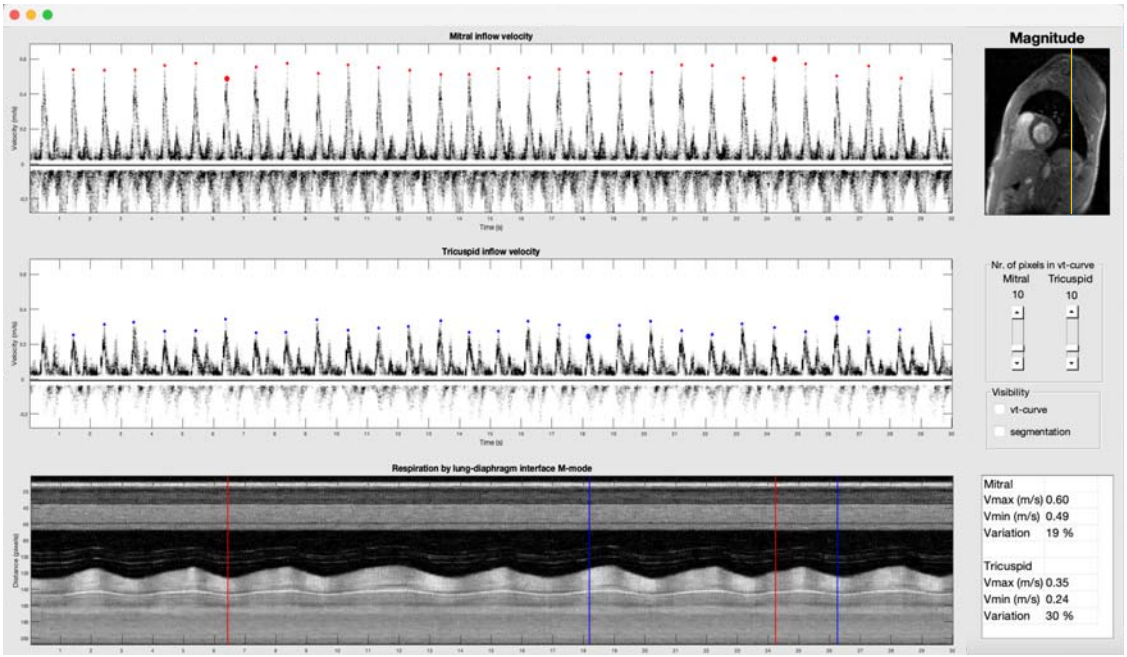

the vertical axis is also created. This amounts to a time-motion graph not unlike M-mode (motion mode) echocardiograph which enables visual tracking of the lung-diaphragm interface. In this graph, white lines are used to indicate each mitral and tricuspid Vmax and Vmin and thus allows the user to ensure that each reported peak occurred during inspiration or expiration respectively.