

1 **Application of 4D flow MRI for exploring the anatomical and haemodynamic**
2 **characteristics of pelvic veins and their correlations**

3 **Author**

4 Chengli Nie^{1#} 390988893@qq.com

5 Li Tao^{1#} tlhunter@163.com

6 Jiangwei Chen¹ chenjiangwei@163.com

7 Jianghu Yang¹ 1983801360@qq.com

8 Wen Huang^{1*} 382269637@qq.com

9 #: Chengli Nie and Li Tao contributed equally.

10 *: Correspondence author

11 **Affiliation**

12 1: The First Affiliated Hospital of Chongqing Medical University

13 **Abstract:**

14 Objective: There is currently a lack of studies evaluating the anatomy and
15 haemodynamics of the pelvic veins in clinical practice. Four-dimensional flow
16 magnetic resonance imaging (4D flow MRI) can simultaneously obtain information on
17 vascular anatomy and haemodynamics. The goal of this study was to use 4D flow MRI
18 to explore the anatomical and haemodynamic characteristics of pelvic veins and their
19 correlations in an asymptomatic population.

20 Methods: Four-dimensional flow MRI was used to measure anatomical
21 parameters, including the pelvic vein area, common iliac vein-inferior vena cava angle,
22 iliac vein tortuosity, and common iliac vein stenosis rate, and haemodynamic

23 parameters, including the pelvic venous blood flow, average blood flow velocity, and
24 external iliac vein-inferior vena cava pressure difference, in 30 asymptomatic
25 volunteers. The correlation between iliac vein anatomy and haemodynamics was
26 analysed.

27 Results: There were correlations between the anatomical parameters of the iliac
28 vein and the haemodynamic parameters. A larger iliac vein area was correlated with a
29 higher blood flow. A greater iliac vein stenosis rate was correlated with a lower blood
30 flow, lower mean velocity of the external iliac vein, and higher external iliac
31 vein-inferior vena cava pressure difference. A greater common iliac vein-inferior vena
32 cava angle was associated with a lower iliac vein flow velocity and a higher external
33 iliac vein-inferior vena cava pressure difference. Finally, a greater the iliac vein
34 tortuosity was correlated with a lower iliac vein velocity and higher external iliac
35 vein-inferior vena cava pressure difference. There were differences in the anatomical
36 and haemodynamic parameters of the bilateral common iliac vein and external iliac
37 vein. The left pelvic vein common iliac-inferior vena cava angle, iliac vein tortuosity
38 and iliac vein stenosis rate were higher than those of the right side. The flow and
39 average velocity of the left common iliac vein and the left external iliac vein were lower
40 than those of the right, and the pressure of the left external iliac vein was higher than
41 that of the right.

42 Conclusion: The anatomical structure of the pelvic vein, including the iliac vein
43 area, common iliac vein-inferior vena cava angle, iliac vein tortuosity, and iliac vein
44 stenosis rate, are important factors that affect haemodynamic changes in the pelvic vein.

45 There are correlations between parameters related to the anatomical structures and
46 haemodynamic changes of the pelvic veins. Differences in the anatomy and
47 haemodynamics of the bilateral pelvic veins may be one reason why the left extremity
48 is more prone to chronic venous disease (CVD)-related symptoms.

49 **Key words:** Pelvic veins, Anatomic, Haemodynamics, Asymptomatic population,
50 Four-dimensional flow magnetic resonance imaging

51 **1. Introduction**

52 Chronic venous disease (CVD) of the lower extremities is a common clinical
53 syndrome whose incidence increases with age. Patients often present with symptoms
54 such as lower extremity heaviness, lethargy and swelling and signs such as lower
55 extremity varicose veins, lower extremity oedema, skin pigmentation, and venous
56 ulcers. The reason for these symptoms is the development of lower extremity venous
57 stasis caused by various factors, including obstructive factors such as pulmonary
58 hypertension, heart failure, Budd-Chiari syndrome and iliac vein stenosis and
59 regurgitation factors such as tricuspid regurgitation and lower extremity venous valve
60 insufficiency. Clinical studies have found that iliac vein stenosis is an important factor
61 leading to venous reflux disorders in the lower extremities, but it is not clear how it
62 leads to changes in iliac vein haemodynamics. Iliac vein stenosis can be identified and
63 treated in clinical practice, but sometimes these treatments cannot relieve the symptoms
64 of lower extremity venous insufficiency. Therefore, it is clinically important to
65 understand the characteristics of pelvic vein haemodynamics.

66 4D flow MRI can simultaneously obtain vascular anatomy and haemodynamic
67 information and dynamically display haemodynamic changes, including blood flow
68 velocity, blood flow shear force, and kinetic energy. It can also visualise the direction
69 and state of blood flow in the form of flow diagrams and trace diagrams and aid in
70 quantitatively and qualitatively analysing blood vessels¹, which can help in
71 investigating the causes of vascular disease and the factors affecting disease
72 progression. In addition, by excluding contrast enhancement from 4D flow MRI
73 analysis, its interference on blood flow is excluded, resulting in a more realistic
74 reflection of the haemodynamic state of the body.

75 We used 4D flow MRI for the first time to investigate the haemodynamic
76 characteristics of the iliac veins in young asymptomatic people. We intend to study
77 baseline pelvic vein anatomy and haemodynamics data and provide a basis for further
78 research on the pathogenesis of CVD of the lower extremities.

79 **2. Method**

80 2.1 Study subjects

81 This study was approved by the Research Ethics Committee of our hospital. A
82 homemade questionnaire was distributed to young volunteers from September 2022 to
83 March 2023 to determine whether they have symptoms related to chronic venous
84 insufficiency of the lower extremity and to determine whether the lower extremities had
85 signs of oedema, varicose veins, skin pigmentation and/or venous ulcers by physical
86 examination. Subjects were recruited according to the results of the questionnaire and
87 physical examination according to the following inclusion criteria:(1) no

88 vascular-related symptoms (swelling, oedema, hyperpigmentation and venous ulcers)
89 or confirmed vascular disease (ulcers varicose, deep vein thrombosis,
90 thrombophlebitis); (2) body mass index (BMI) $<28\text{kg/m}^2$; (3) no vein-related pressure
91 or drug treatment; (4) no contraindications related to MRI scanning. Four-dimensional
92 flow MRI examinations were performed after obtaining informed consent from the
93 included subjects. The exclusion criteria were congenital heart valve insufficiency,
94 anatomic abnormalities of the inferior vena cava and iliac vein, a venous
95 thromboembolism (VTE)-related family history, and lateral branch formation. The
96 demographic and medical records of the volunteers were collected, and their initial
97 clinical status was assessed according to the VCSS and Villalta scores.

98 2.2 Anatomical and haemodynamic parameters

99 Anatomical images were obtained with an MR device (Ingenia DNA 3.0T, Philips,
100 The Netherlands) using the Qflow_BH sequence during end-expiratory breath-hold
101 with the patient in the supine position at standard coronal and sagittal orientations,
102 starting 1 cm above the iliac vein bifurcation (slice thickness 8 mm). QFLOW analysis
103 software was used to initially measure the inferior vena cava blood flow velocity V_c ,
104 and the velocity encoding (VENC) value was calculated as $V_c \cdot (1 \pm 20\%)$.
105 Haemodynamic information from the inferior vena cava, bilateral common iliac veins
106 and proximal external iliac veins for 1 cardiac cycle was acquired using the
107 4D-FLOW-PC sequence in the axial orientation. After the original sequence scan was
108 completed, two sets of data, the modular (M) image and the phase contrast MR
109 angiography (PCA) image, were automatically generated. The PCA image was

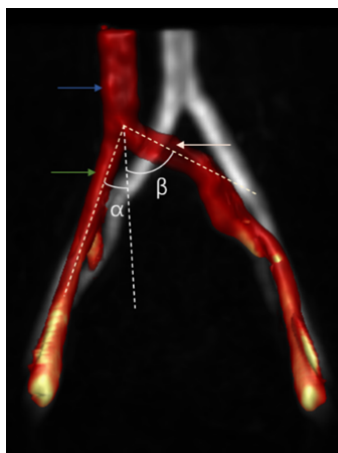
110 removed, and the M image of the first group and the reconstructed phase (P) image in
111 the right-left (RL), foot-head (FH), and anterior-posterior (AP) directions were used for
112 postprocessing analysis.

113 2.3 Anatomical parameters: vessel area, stenosis rate, common iliac vein-inferior
114 vena cava angle, and tortuosity

115 To determine the vessel area, vessel regions of interest (ROIs) were delineated at
116 the distal end of the inferior vena cava, the proximal end of the bilateral common iliac
117 vein (wherein the proximal end of the left common iliac artery is the distal end of the
118 right common iliac artery crossing the left common iliac vein), and the proximal vessel
119 area of bilateral external iliac vein.

120 Stenosis rate: We used the area stenosis rate of the vessel in the axial orientation to
121 calculate the vessel stenosis rate. In the axial plane, we measured the areas where the
122 vessel was narrowest (S_{min}) and widest (S_{max}) at the distal end of the common iliac
123 vein, attempting to avoid the bifurcation of the common iliac vein and the site where it
124 converges into the inferior vena cava when selecting the largest plane. Then, the
125 vascular stenosis rate was calculated as $\left(1 - \frac{S_{min}}{S_{max}}\right) \times 100\%$.

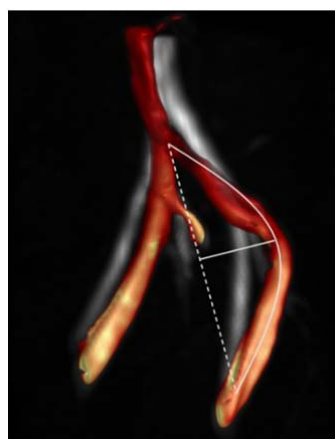
126 Common iliac vein-inferior vena cava angle: Using the postprocessed coronal 4D
127 flow MR images, the angle between the central line of the bilateral common iliac vein
128 and the extension line of the inferior vena cava was measured as the iliac-inferior vena
129 cava angle (Figure1).



130

131 Figure1: The blue arrow is the IVC, the white arrow is the LCIV, the green arrow is the RCIV. The
132 angles α and β are the angles of the extension lines of the inferior vena cava and central line of
133 right and left common iliac vein.

134 Tortuosity: The length L between the two ends of the iliac vein and the actual vessel
135 length H were measured and used to define the tortuosity as $S=H/L*100\%$ (Figure2).



136

137 Figure2: Length of iliac vein center line is L and maximum chord height is H

138 2.4 Haemodynamic parameters: flow, velocity, pressure difference

139 After the vascular ROIs were delineated on cvi42 from Circle Cardiovascular
140 Imaging (Version 5.14, Calgary, Canada), the following parameters were calculated;
141 blood flow and average flow velocity at the distal end of the inferior vena cava, the
142 proximal ends of the bilateral common iliac veins (wherein the proximal end of the left
143 common iliac artery is the distal end of the right common iliac artery crossing the left

144 common iliac vein), and the proximal vessel of bilateral external iliac vein; the flow
145 difference between the bilateral common iliac vein and the external iliac vein; and the
146 pressure difference between the proximal end of the bilateral external iliac vein and the
147 distal end of the inferior vena cava. The inferior vena cava plane was selected 2-3 cm
148 away from the site where the bilateral common iliac converges into the inferior vena
149 cava to reduce the impact of confluent blood flow on the measurement.

150 **3. Data analysis**

151 All statistical analyses were performed using SPSS version 23.0 statistical
152 package (IBM, Armonk, NY, USA). Continuous variables are reported as mean \pm
153 standard deviation (SD) or median (quartile) and categorical variables as frequency or
154 percentage of events. The bivariate Spearman's test was used for correlation analysis.
155 The relationships among the common iliac vein-inferior vena cava angle, stenosis rate,
156 tortuosity, vessel area and iliac vein flow, velocity and pressure difference were
157 analysed. A P value <0.05 was considered statistically significant.

158 **4. Results**

159 4.1 Volunteers' characteristics

160 Thirty-three people were initially recruited to undergo 4D flow MRI scans, 3 of
161 whom were excluded: 1 person failed the scan due to an excessively elevated heart rate
162 (>110 beats/min), 1 person could not complete the scan due to large heart rate
163 fluctuations, and 1 person could not fully display the bilateral iliac veins after
164 reconstruction. A total of 30 people (60 limbs) were included in the study. The mean
165 age of all volunteers was 24 years, the female to male ratio was 1:1, and the average

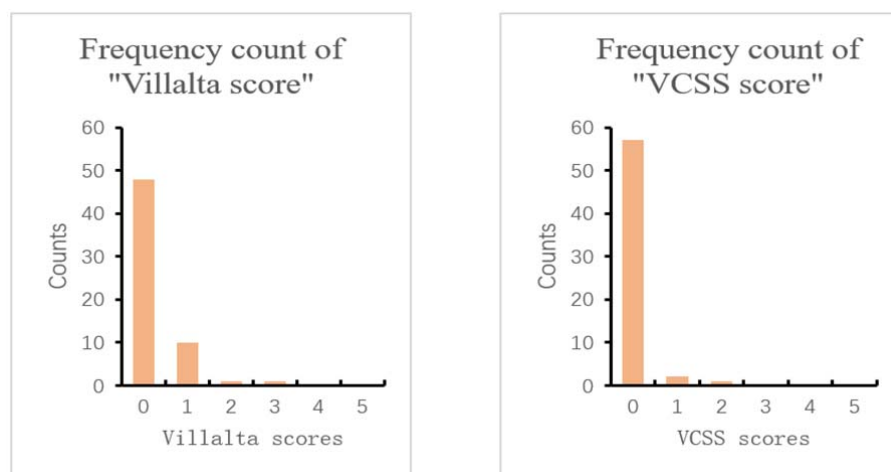
166 BMI was 21.71 ± 2.69 kg/m² (as shown in Table I).

167 Table I. Volunteer characteristics (n=30)

Characteristic	Median (range) or % (No.)
Age, years	24 (24~26)
Female gender	15 (30)
Height, cm	166.83 \pm 7.85
Weight, kg	60.88 \pm 11.23
BMI, kg/m ²	21.71 \pm 2.69

168 4.2 The median (interquartile range) of the Villalta score for all lower extremities

169 was 0 (0-0), and the median venous clinical severity score (VCSS) was 0 (Figure 3).



170

171 Figure 3: Histogram of frequency distribution of Villalta and VCSS scores for all sixty limbs.

172 4.3 Anatomical parameters

173 All limbs anatomical parameters are shown in Table II.

174 Vessel area: The median area of the inferior vena cava in all volunteers was 211.50

175 (170.00~307.00) mm², and the areas of the left common iliac and external iliac veins

176 were larger than those of the opposite side, but the difference was not statistically

177 significant.

178 Stenosis rate: The average stenosis rate of the left iliac vein was significantly
179 higher than that of the right side. The median stenosis rate of all limbs was 23.35%
180 (15.73%-30.29%); the average stenosis rate was 28.13% (12.87%~57.74%) on the left
181 side and 17.12%±7.33% on the right side (P<0.001) .

182 Common iliac vein-inferior vena cava angle and tortuosity: The left iliac
183 vein-inferior vena cava angle and tortuosity were greater than those of the right. The
184 average iliac-vena cava angle of all limbs was 36.37±21.88°; on the left and right sides,
185 the average angles were 51.67±17.75° and 17.07±6.30° (P<0.001) , respectively. The
186 median tortuosity of all limbs was 14.94% (10.07%~19.70%) ; the average tortuosity
187 of the left limb was 19.41%±3.32%, and that of the right limb was 10.94%±2.78%,
188 (P<0.001) .

189 Table II. Anatomical parameters of all limbs(n=60)

Anatomical parameters	Average(median)		P value
	Left	Right	
CIV area(mm2)	154.30±60.39	135.10±52.43	0.194
EIV area (mm2)	116.63±39.41	108.47±39.73	0.427
Stenosis rate (%)	28.13% (12.87%~57.74%)	17.12%±7.33%	<0.001
CIV-IVC angle (°)	51.67±17.75°	17.07±6.30°	<0.001
Iliac vein tortuosity (%)	19.41%±3.32%	10.94%±2.78%	<0.001

190 CIV, Common iliac vein; EIV, external iliac vein;IVC ,inferior vena cava

191 Data presented as median (range) or mean±standard deviation. A P value <0.05 was

192 considered statistically significant.

193 4.4 Haemodynamic parameters

194 All limbs haemodynamic parameters are shown in Table III.

195 Flow velocity: We found that the average flow velocity of the left common iliac
196 and external iliac veins was lower than that of the contralateral side. The average flow
197 velocity of the inferior vena cava in all volunteers was 12.71 ± 3.15 cm/s. The average
198 flow velocity of the common iliac vein of all limbs was 10.84 ± 3.94 cm/s, among which
199 that of the left common iliac was 9.27 ± 4.43 cm/s, and that of the right common iliac
200 was 12.41 ± 3.83 cm/s ($P=0.001 < 0.01$) . The average flow velocity of external iliac vein
201 of all limbs was 8.69 ± 2.37 cm/s, among which the average velocity of the left iliac was
202 7.43 ± 1.65 cm/s, and the average velocity of the right iliac was 9.94 ± 2.34 cm/s
203 ($P < 0.001$) .

204 Flow: The blood flow of the left common iliac and external iliac veins was lower
205 than that of the opposite side. The mean blood flow of inferior vena cava of all
206 volunteers was 14.53 ± 4.74 ml/s. The mean blood flow of common iliac vein across all
207 volunteers and that of the left and right common iliac veins were 7.50 ± 3.12 ml/s,
208 6.70 ± 2.88 ml/s, and 8.31 ± 3.19 ml/s ($P=0.045 < 0.05$) . For all limbs, the mean blood
209 flow of external iliac vein was 5.60 ± 1.96 ml/s, that of left external iliac was 5.08 ± 1.85
210 ml/s, and that of right external iliac was 6.11 ± 1.96 ml/s.

211 Flow difference: The average common iliac vein-external iliac vein flow
212 difference of all limbs was 1.66 ($0.675 \sim 3.250$ ml/s), while the flow differences between
213 the left and right common iliac vein and the external iliac vein were 1.62 ± 1.68 ml/s, and
214 2.19 ± 2.69 ml/s ($P=0.36 > 0.05$), respectively. The right iliac vein flow difference was

215 higher than that of the left iliac vein, but the difference was not statistically significant.

216 Pressure difference: We found that the left external iliac vein pressure was higher
 217 than that of the right side. The pressure difference between the proximal end of the
 218 bilateral external iliac vein and the proximal end of the inferior vena cava at rest was
 219 measured. The results showed that the average pressure difference on the left side was
 220 0.046 ± 0.173 mmHg, the average pressure difference on the right side was
 221 -0.088 ± 0.164 mmHg ($P=0.003 < 0.01$), and the difference between the two sides (right
 222 vs left) was -0.13 ± 0.22 mmHg.

223 **Table III.** Hemodynamic parameters of all limbs (n=60)

Haemodynamic parameters	Average (median)		P value
	Left	Right	
CIV blood flow ml/s	6.70 ± 2.88 ml/s	8.3 ± 3.19 ml/s	0.045
EIV blood flow ml/s	5.08 ± 1.85 ml/s	6.11 ± 1.96 ml/s	0.041
CIV-EIV flow difference ml/s	1.62 ± 1.68 ml/s	2.19 ± 2.69 ml/s	0.360
CIV average flow velocity cm/s	9.27 ± 3.43 cm/s	12.41 ± 3.83 cm/s	0.001
EIV average flow velocity cm/s	7.43 ± 1.65 cm/s	9.94 ± 2.34 cm/s	<0.001
EIV-IVC pressure difference (mmHg)	0.046 ± 0.173 mmHg	-0.088 ± 0.164 mmHg	<0.001

224 CIV, Common iliac vein; EIV, external iliac vein; IVC, inferior vena cava

225 Data presented as median (range) or mean± standard deviation. A P value <0.05 was
 226 considered statistically significant.

227 4.5 The relationship between anatomy and haemodynamics

228 The relationship between anatomy and haemodynamics is shown in Table IV. We
 229 found correlations between pelvic vein anatomical parameters and haemodynamic
 230 parameters. A larger iliac vein area was correlated with a higher the blood flow; a
 231 higher iliac vein stenosis rate was correlated with a lower blood flow, leading to a
 232 decrease in the average external iliac vein velocity and an increase in the external
 233 iliac-inferior vena cava pressure difference; a greater common iliac vein-inferior vena
 234 cava angle was correlated with a lower iliac vein flow velocity and higher the external
 235 iliac vein-inferior vena cava pressure difference. A greater iliac vein tortuosity was
 236 correlated with a lower iliac vein velocity and higher external iliac vein-inferior vena
 237 cava pressure difference. Limbs with a greater tortuosity and angle had a lower
 238 common iliac vein flow, external iliac vein flow, average common iliac vein flow
 239 velocity, and average external iliac vein flow velocity and a higher external
 240 iliac-inferior vena cava pressure difference.

241 **Table IV.** Correlation between anatomy and haemodynamics of iliac vein

	CIV blood flow	EIV blood flow	CIV average flow velocity	EIV average flow velocity	EIV-IVC pressure difference
Spearman's correlation					
CIV-IVC angle (°)	-0.331**	-0.260*	-0.359**	-0.519**	0.407** (0.001)
Iliac vein	-0.142	-0.198	-0.299*	-0.499**	0.406** (0.001)

tortuosity					
(%)					
Stenosis	-0.394*	-0.388*	-0.155	-0.380**	0.272* (0.036)
rate (%)					
CIV area	0.524**	-	-0.059	-	0.134 (0.306)
(mm ²)					
EIV area	-	0.511**	-	0.021	0.197 (0.131)
(mm ²)					

242 Note:*and**mean significant correlation at P<0.05 and extremely significant

243 correlation at P<0.01

244 5. Discussion

245 Venous stasis in the lower extremities is considered to be an important
246 haemodynamic change in the occurrence and development of CVD. Some studies have
247 reported that the obstruction and reflux disorder of the lower extremities caused by iliac
248 vein stenosis are a reason for venous insufficiency of the lower extremities and the
249 subsequent formation of CVD^{2,3}. The clinical use of iliac vein stents to correct stenosis
250 has been shown to be effective⁴⁻⁶, but studies have shown that iliac vein stenosis rates
251 do not exactly match symptom severity⁷. Asymptomatic iliac vein stenosis is a normal
252 anatomical variation rather than a pathological change^{8,9}.

253 In recent years, studies have found that abnormal haemodynamics are closely
254 related to the occurrence and development of vascular diseases. The common iliac and
255 external iliac veins are the channels for venous reflux of the lower extremities. We

256 believe that the anatomical parameters of the iliac veins, such as vessel area, stenosis
257 rate, and vessel course, may affect iliac vein haemodynamic parameters, such as flow,
258 velocity, and pressure, which will lead to progression in CVD. In addition, in clinical
259 practice, the prevalence of CVD on the left and right sides has been shown to be
260 inconsistent^{10,11}, and we hypothesize that this inconsistency is related to a certain
261 degree with the anatomical differences between the bilateral limbs.

262 At present, the diagnosis and evaluation of vascular diseases are very dependent
263 on imaging data, such as Doppler ultrasound, computed tomography angiography
264 (CTA), magnetic resonance angiography (MRA), digital subtraction angiography
265 (DSA), and intravascular ultrasound (IVUS), but few of the above methods can
266 accurately, objectively and dynamically collect the haemodynamic parameters of the
267 patients. 4D flow MRI has great application prospects in the research of vascular
268 diseases due to its noninvasiveness, lack of radiation, lack of contrast agent
269 enhancement, and wide coverage. It can provide a large number of haemodynamic
270 parameters and visualize blood flow status and changes and allows analysis of
271 postprocessed images offline for retrospectively assessing blood flow parameters¹².
272 The ability of 4D flow MRI to perform qualitative and quantitative analysis allows a
273 comprehensive assessment of pelvic venous blood flow and can help clarify the
274 relationship between haemodynamic changes and the development of CVD. In this
275 paper, 4D flow MRI was first used to collect the anatomical and haemodynamic
276 parameters of the pelvic vein and to explore the anatomical and haemodynamic

277 characteristics of the iliac vein in asymptomatic people and their correlations,
278 providing a reference for further exploring abnormal changes in fluid dynamics.

279 We measured the anatomical parameters of the iliac vein in asymptomatic
280 individuals and found that the average angle of the common iliac vein as it converged
281 into the inferior vena cava in all limbs was $36.37 \pm 21.88^\circ$, with average angles on the
282 left and right of $51.67 \pm 17.75^\circ$ and $17.07 \pm 6.30^\circ$ ($P < 0.001$), respectively. The angle at
283 which the left common iliac vein converged into the inferior vena cava was larger than
284 that on the right side. This suggests that it may be more appropriate to choose about 50°
285 for the bevelled opening angle of the iliac vein-specific stent in current clinical practice.
286 The median (interquartile range) tortuosity of all limbs was 14.94% (10.07%-19.70%),
287 among which the mean tortuosity of the left iliac vein was $19.41\% \pm 3.32\%$, and the
288 mean tortuosity of the right iliac vein was $10.94\% \pm 2.78\%$ ($P < 0.001$), showing that the
289 tortuosity of the left iliac vein was greater than that of the contralateral side. The course
290 of the right common iliac vessels is steeper and straighter than the left, which is
291 consistent with the research results of Arjun Jayaraj¹³ et al. The tortuosity of the left
292 iliac vein is large, a greater tortuosity requires higher compliance for the middle section
293 of the iliac vein stent, as this would allow better adaptation to the tortuosity of the iliac
294 vein and adherence to the vein wall, suggesting that support and flexibility should be
295 considered when selecting materials for the design of iliac vein stents. Raju¹⁴ et al. used
296 colour Doppler ultrasound to measure the common iliac and external iliac diameters of
297 healthy volunteers, obtaining values of 13.3 (11-15.8) mm and 11.5 (8.7-13.9) mm,
298 respectively; this study found that the average diameters of left and right common iliac

299 veins of the volunteers were 14.02 mm and 12.19 mm, respectively, while the average
300 diameters of the left and right external iliac veins were 13.12 mm and 11.75 mm,
301 respectively, which may also serve as reference values for the design of iliac vein
302 stents.

303 Iliac vein stenosis is very common worldwide, but most people have iliac vein
304 stenosis without obvious clinical symptoms. Iliac vein compression syndrome (IVCS)
305 often occurs in the left lower extremity and is more common in women than in men¹⁵.
306 Kibbe et al.⁸ found that among asymptomatic patients with lower extremity
307 compression, approximately 24% had left common iliac vein compression greater than
308 50%. In this study, the iliac vein stenosis rate was >50% in 20% (6/30) of the left limbs
309 of all volunteers as measured by 4D flow MRI, consistent with the findings of Kibbe et
310 al. The mean stenosis rate of the left limb was higher than that of the right side
311 (34.04%±13.74% vs. 17.12%±7.33%, P<0.001).

312 Currently, the relationship between iliac vein anatomy and haemodynamics is
313 unclear. We used 4D flow MRI to measure the mean velocity and blood flow of the
314 bilateral iliac veins and the pressure difference between the external iliac vein and
315 inferior vena cava in an asymptomatic population. This study found significant
316 correlations between iliac vein anatomy and haemodynamic parameters. A larger iliac
317 vein area was correlated with a higher blood flow; a larger common iliac vein-inferior
318 vena cava angle was correlated with a lower iliac vein velocity and a higher external
319 iliac-inferior cavity pressure difference. Finally, a greater iliac vein tortuosity was
320 correlated with a lower iliac vein velocity and a higher external iliac vein-inferior vena

321 cava pressure difference.

322 This study found that an iliac vein stenosis rate of more than 50% affected the
 323 blood flow and pressure differences of the iliac vein. Specifically, compared with a
 324 stenosis rate of less than 50%, the absolute blood flow of the iliac vein decreased. While
 325 the relative blood flow (the difference between the common iliac and external iliac
 326 blood flows) decreased, the venous pressure increased, and the average iliac vein
 327 velocity decreased. However, none of these differences was significant, suggesting that
 328 compensatory velocity acceleration may occur at the site of venous stenosis (Table V).
 329 According to Poiseuille's law, changes in intravascular flow velocity and pressure
 330 differences will lead to changes in blood flow. The flow velocity can be compensatorily
 331 increased at the site of stenosis and decreased at sites near the stenosis, so the flow
 332 velocity does not objectively reflect the status of venous reflux. Another study by our
 333 center¹⁶ suggested that changes in the common iliac-external iliac flow difference at the
 334 lower extremities, that is, a decrease in relative flow, may be related to the severity of
 335 the patient's symptoms. A low or even negative flow difference may be associated with
 336 more severe limb symptoms (higher Villalta scores).

337 **TableV.** Correlation of degree of stenosis and hemodynamics

Hemodynamic parameters mean ± standard deviation					
CIV blood	EIV blood	CIV-EIV	CIV	EIV	EIV-IVC
flow ml/s	flow ml/s	flow	average	average	pressure
		difference	flow	flow	difference
		ml/s	velocity	velocity	mmHg
			cm/s	cm/s	

Stenosis rate ≤50%	7.26±2.79	5.47±1.71	1.78±1.68	9.46±3.34	7.58±1.76	0.029±0.169
Stenosis rate >50%	4.47±2.17	3.53±1.71	0.94±1.67	8.50±4.00	6.83±1.05	0.113±0.189
P value	0.031	0.019	0.280	0.550	0.332	0.295

338 Twenty percent of the volunteers had a left iliac vein stenosis rate of >50% but no
339 symptoms related to lower extremity venous insufficiency (such as varicose veins or
340 oedema). We believe that stenosis can lead to changes in iliac vein haemodynamics, but
341 the reason for the lack of clinical symptoms is related to the fact that although a certain
342 degree of iliac vein stenosis is a physiological anatomical structure, it is also a potential
343 pathological change. The changes in venous flow due to venous stenosis in the normal
344 population may have a "threshold effect", and a decrease in venous flow may not be
345 sufficient to cause symptoms or signs related to the veins of the lower extremities.
346 Symptoms associated with venous insufficiency of the lower extremity may be induced
347 if the stenosis causes the flow or flow difference to reach this threshold.

348 After stratified analysis of iliac vein angle and tortuosity, we found that the
349 common iliac vein flow, external iliac vein flow, average common iliac vein velocity,
350 and average external iliac vein flow velocity were all lower in limbs with greater iliac
351 vein angles and tortuosity values, while the external iliac-inferior vena cava pressure
352 difference was higher (Table VI, VII). Compared with those of the right side, the
353 tortuosity and common iliac vein-inferior vena cava angle of the left side were larger.
354 The average flow and velocity in the right common and external iliac veins were higher
355 than in the left limb, and the pressure in the left external iliac vein was higher than that

356 in the right side. The average pressure difference between the left external iliac vein and
 357 the right external iliac vein was 0.13 ± 0.22 mmHg. We believe that the differences in the
 358 bilateral iliac vein tortuosity and venous inflow angle may also be a reason for the
 359 difference in haemodynamic parameters of bilateral iliac veins, which can explain why
 360 lower extremity venous insufficiency in CVD patients mostly occurs in the left side.
 361 Lower extremity venous insufficiency was also more common on the left side in
 362 patients with no iliac vein stenosis on angiography. This is closely related to the larger
 363 angle of the left common iliac vein as it converges into the inferior vena cava and its
 364 larger tortuosity.

365 **Table VI.** Correlation of curvature and hemodynamics

Limbs	Hemodynamic parameters mean \pm standard deviation					
	CIV blood flow ml/s	EIV blood flow ml/s	CIV-EIV flow difference ml/s	CIV average flow velocity cm/s	EIV average flow velocity cm/s	EIV-IVC pressure difference mmHg
curvature \leq 15%	8.25 \pm 2.82	6.10 \pm 1.93	2.15 \pm 2.31	12.35 \pm 3.88	10.05 \pm 2.32	-0.084 \pm 0.170
curvature $>$ 15%	6.40 \pm 2.36	4.54 \pm 1.40	1.84 \pm 1.78	9.33 \pm 3.44	7.32 \pm 1.48	0.427 \pm 0.170
P value	0.008	0.001	0.564	0.002	$<$ 0.001	0.005

366 **Table VII.** Correlation of angle of common iliac vein-inferior vena cava and
 367 hemodynamics

Limbs	Hemodynamic parameters mean \pm standard deviation					
	CIV blood flow ml/s	EIV blood flow ml/s	CIV-EIV flow difference	CIV average flow	EIV average flow	EIV-IVC pressure difference

		ml/s	velocity cm/s	velocity cm/s	mmHg	
Angle \leq 37°	8.10 \pm 2.67	5.88 \pm 1.85	2.20 \pm	12.01 \pm 3.67	9.48 \pm 2.34	-0.092 \pm 0.15
Angle $>$ 37°	6.08 \pm 2.42	4.43 \pm 1.48	1.68 \pm	8.96 \pm 3.68	7.41 \pm 1.85	0.093 \pm 0.16
P value	0.005	0.002	0.166	0.003	0.001	0.000

368 6. Conclusion

369 The anatomical structure of the pelvic vein, including the iliac vein area, common
370 iliac vein-inferior vena cava angle, iliac vein tortuosity, and iliac vein stenosis rate, are
371 important factors that affect the haemodynamic changes in the pelvic vein. There are
372 correlations between parameters related to anatomical structure and haemodynamic
373 changes in the pelvic veins. Differences in the anatomy and haemodynamics of the
374 bilateral pelvic veins may be one of the reasons why the left extremity is more prone to
375 CVD-related symptoms.

376 7. Limitations

377 It is important to bear in mind the limitations of this study. First, the sample size of
378 this study was small. Second, our study failed to explain the effect of circadian rhythm,
379 respiratory rate, body position, and exercise on blood flow. In addition, when the
380 participant is in the supine position, the 4D flow MRI scan is not dynamic and may not
381 reflect the anatomic structures when the participant is standing and moving. We also did
382 not acquire measurement data for IVCS patients and older persons as controls. More

383 prospective studies with high quality and larger sample sizes should be designed in
384 the future.

385 Reference:

- 386 1.Takehara Y. 4D Flow when and how? *Radiol med.* 2020 Sep;125(9):838–50.
- 387 2.Larkin TA, Hovav O, Dwight K, Villalba L. Common iliac vein obstruction in a
388 symptomatic population is associated with previous deep venous thrombosis, and with
389 chronic pelvic pain in females. *J Vasc Surg Venous Lymphat Disord.* 2020
390 Nov;8(6):961–9.
- 391 3.Lattimer CR, Mendoza E, Kalodiki E. The current status of air-plethysmography in
392 evaluating non-thrombotic iliac vein lesions. *Phlebology.* 2018 Feb;33(1):3–4.
- 393 4.Raju S. Best management options for chronic iliac vein stenosis and occlusion. *J*
394 *Vasc Surg.* 2013 Apr;57(4):1163–9.
- 395 5.Lattimer CR, Mendoza E, Kalodiki E. The current status of air-plethysmography in
396 evaluating non-thrombotic iliac vein lesions. *Phlebology.* 2018 Feb;33(1):3–4.
- 397 6.Speranza G, Sadek M, Jacobowitz G. Common iliac vein stenting for May-Thurner
398 syndrome and subsequent pregnancy. *J Vasc Surg Venous Lymphat Disord.* 2022
399 Mar;10(2):348–52.
- 400 7.Cheng L, Zhao H, Zhang FX. Iliac Vein Compression Syndrome in an
401 Asymptomatic Patient Population: A Prospective Study. *Chin Med J (Engl).* 2017 Jun
402 5;130(11):1269–75.
- 403 8.Kibbe MR, Ujiki M, Goodwin AL, Eskandari M, Yao J, Matsumura J. Iliac vein
404 compression in an asymptomatic patient population. *Journal of Vascular Surgery.*
405 2004 May 1;39(5):937–43.
- 406 9.Brinegar KN, Sheth RA, Khademhosseini A, Bautista J, Oklu R. Iliac vein
407 compression syndrome: Clinical, imaging and pathologic findings. *World J Radiol.*
408 2015 Nov 28;7(11):375–81.
- 409 10.Joseph N, B A, Thouseef MF, Devi UM, Abna A, Juneja I. A multicenter review
410 of epidemiology and management of varicose veins for national guidance. *Annals of*
411 *Medicine & Surgery.* 2016 Jun;8:21–7.
- 412 11.Das K, Ahmed S, Abro S, Arain MS. VARICOSE VEINS;: OUTCOME OF
413 SURGICAL MANAGEMENT AND RECURRENCES. *The Professional Medical*
414 *Journal.* 2014 Jun 10;21(03):509–13.
- 415 12.Stankovic Z. Four-dimensional flow magnetic resonance imaging in cirrhosis.
416 *WJG.* 2016;22(1):89.
- 417 13.Jayaraj A, Raju S. Iliofemoral venous configurations from three-dimensional
418 computed tomography venogram and their relevance to stent design. *J Vasc Surg*
419 *Venous Lymphat Disord.* 2022 Nov;10(6):1310-1317.e1.
- 420 14.Raju S, Buck WJ, Crim W, Jayaraj A. Optimal sizing of iliac vein stents.
421 *Phlebology.* 2018 Aug;33(7):451–7.
- 422 15.Vuylsteke ME, Thomis S, Guillaume G, Modliszewski ML, Weides N, Staelens I.
423 Epidemiological study on chronic venous disease in Belgium and Luxembourg:

424 prevalence, risk factors, and symptomatology. *Eur J Vasc Endovasc Surg.* 2015
425 Apr;49(4):432–9.

426 16.Chen ZH, Huang Y, Wang LP, Peng MY, Li C, Huang W. Preliminary study of
427 hemodynamics of iliac venous compression syndrome using magnetic resonance
428 imaging. *J Vasc Surg Venous Lymphat Disord.* 2022 Jan;10(1):131-138.e3.

429