Modified Technique for Dissection of Working Space in Retroperitoneal Laparoscopic Surgery

Authors:

Xiaofeng Xu[1,#], Wen Cheng[1,#], Zhe Liu[1], Changjie Shi[1], Jianping Da[1], Xiumin Zhou[2,*], Jingping Ge[1,*]

[#]These authors contributed equally to this work

* Correspondence author

Author Affiliations:

1.Department of Urology, Jinling Hospital, Medical School of Nanjing University, Nanjing, Jiangsu, China.

2.Department of Oncology, First Affiliated Hospital of Soochow University, Suzhou, Jiangsu, China.

Corresponding author and e-mail address:

Jingping Ge

Telephone: +86-25-80860025; Email: gjp_doctor@qq.com

Xiumin Zhou

Telephone: +86-512-67973213; Email: alice-xm@163.com

Word count (main text): 2010

Word count (abstract): 242

Keywords: Modified dissection technique, Retroperitoneal working space, Laparoscopic dissection, Balloon dilation, Laparoscopic surgery

Abstract

Introduction: The existing techniques to creat working space for retroperitoneal laparoscopic surgery are often accompanied by air leakage or poor visibility due to blood and fat tissues smudging during dissection.This single-center experience describes a modified dissection technique to create a retroperitoneal working space during laparoscopic surgery.

Materials and Methods: From May 2021 to December 2022, we performed a modified dissection technique to create a retroperitoneal working space prior retroperitoneal laparoscopic surgery in 47 patients. During the procedure, laparoscopic dissection and balloon dilation are successively performed. The retroperitoneum is initially accessed by puncturing the trocar through a 10-mm transverse skin incision in the midaxillary line. Under endoscopic monitoring, the tip of the trocar is adjusted to a relative avascular layer between the transversus abdominis muscle and the pararenal fat. Laparoscopic dissection is performed to develop the initial space. Thereafter, a homemade balloon is inserted through the trocar sheath for further dilation. Finally, the working space is fully established. All data referring to patient demographics, surgery, dilation-related complication, and perioperative outcomes were collected retrospectively.

Results: In all cases, a satisfactory retroperitoneal space was created for surgery. The median time of creating retroperitoneal working space was 6 (IQR:5,7) minutes. No dissection-related complications were noted within a median follow-up period of 9 (IQR:7,15) months.

Conclusion: Modified retroperitoneal dissection combined with laparoscopy and balloon insertion is a safe, simple, effective, and minimally invasive technique. It provides an adequate working space and an excellent view without obvious bleeding.

Introduction

Creating an appropriate working space within the retroperitoneum is an essential prerequisite for retroperitoneal laparoscopic surgery. Early attempts at creating adequate space were mostly unsuccessful until the balloon dilation technique was first described by Gaur in 1992[1]. Consequently, the use of this technique has become increasingly popular worldwide. However, this technique utilizes an open surgical approach and air leakage is an inevitable problem after dilation because the incision for digital dissection is larger than the diameter of the trocar [2].

To overcome the complications associated with the existing techniques, we have implemented a modified dilation technique at our institution. This technique achieves retroperitoneal access by direct trocar puncture through a 10-mm incision. The laparoscopic dissection technique in combination with a custom-made balloon dilation is used to dissect pararenal fat (PF) from the transversus abdominis muscle (TAM). Herein, we report our experience with this modified dilation technique.

Materials and methods

Patients

We have successfully applied this modified dilation technique in 47 cases of benign and malignant diseases of the upper retroperitoneum at our institution. Informed consent was obtained from all the patients. Perioperative data were collected retrospectively. Follow-up data were obtained by reviewing patient charts or via telephone calls. Institutional Review Board of Jinling Hospital gave ethical approval for this work.

Step-by-step technique

After inducing general anesthesia, the patient is placed in a full-flank position with the kidney bridge elevated. The surgical table is flexed to increase the distance between the ribs and iliac crest. A 10-mm transverse incision is made in the midaxillary line, approximately 2 cm above the iliac crest (Fig. 1a). A 10-mm trocar is punctured perpendicularly through the muscular layers and transverse fascia and a 10-mm, 30-degree laparoscope is inserted into the trocar. The laparoscopic view is turned to 30-degrees up. Under laparoscopic monitoring, the trocar is adjusted until its tip is within the layer between the TAM and the PF (Fig. 1b). This layer consists of semi-transparent loose and flimsy fibroareolar tissue and is relatively avascular. The eyepiece of the laparoscope is subsequently pushed downward. Using

this angle ensures that endoscopic vision remains in the proper layer (Fig. 1c). Thereafter, to-and-fro and side-to-side laparoscopic movements are performed to separate the fibrous septae, and the PF is bluntly detached from the undersurface of the flank abdominal wall. Accordingly, a working space is created between the TAM and PF.

There are several technical tips to ensure that laparoscopic dissection remains in the appropriate layer while using this technique. (1) Laparoscopic focus should be adjusted promptly when object distance is too small which will lead to obscure view. (2) The retroperitoneal fat is yellow, the TAM is red, and the fibroareolar tissue is semi-transparent. As the laparoscopic view is out of focus during dissection, these characteristics can be regarded as landmarks (Fig. 1d-1f). (3) Strong light from the laparoscope can transilluminate muscle and form a light spot on the skin. This can aid in locating the tip of the laparoscope (Fig. 1g). (4) The tip of the laparoscope should be pressed onto the undersurface of the flank abdominal wall and the wall will be tented during laparoscopic dissection. Thus, the movements of the laparoscope under the skin are palpable (Fig. 1g).

The dissection area extends from the anterior axillary line to the posterior axillary line. PF is mobilized en bloc from the transversalis fascia. Once the working space is dissected, the outer part of the trocar is tilted towards the iliac crest, which causes the tip of the trocar to be cephalad. Thereafter, a balloon dilator is inserted through the trocar into the dissected space. We created a dilator using the middle finger of a surgical glove (size 8), mounted on a 24 Fr red rubber catheter. The glove finger is affixed to the catheter using 0-silk suture (Fig. 1h). The tip of the trocar is redirected to the iliac fossa after inflating the balloon with 180 mL of air. The balloon is then inflated with an additional 120 mL of air to expand the space and is kept in this position for a few seconds. Once the working space is fully established (Fig. 1i), additional ports are inserted under laparoscopic guidance. Subsequently, the surgical procedure can be performed.

Statistical analysis

The following demographic and intraoperative variables were recorded: age, gender, body mass index (BMI), and the time of creating retroperitoneal working space which is defined as the time elapsed from the initial incision to the placement of all trocars. Complications were classified according to the Clavien-Dindo system.

Median and inter-quartile range (IQR) was used for continuous variables. Categorical variables were reported as percentages. Statistical analysis was performed by SPSS software version 22.0.

Results

Patient demographic and clinical characteristics are detailed in Table 1. Using the laparoscope and the balloon we were able to adequately dissect the retroperitoneal space and obtain a satisfactory surgical field for all patients. The median time of creating retroperitoneal working space was 6 (IQR:5,7) min. The balloon did not detach or burst during inflation. All procedures were completed successfully. At a median follow-up of 9 (IQR:7,15) months, no dissection-related complications were observed.

Discussion

Currently, the Hasson and Veress needle techniques are the two major approaches used for retroperitoneal access and creating space for retroperitoneal laparoscopic surgery.

The Hasson technique is commonly used, wherein initial access and balloon placement for retroperitoneal laparoscopy are established using an open approach [1-4]. A 1.5-2.0 cm incision is made just below the tip of the 12th rib in the posterior axillary line, and the lumbodorsal fascia and muscle fibers are bluntly separated using artery forceps [1,3]. Thereafter, the peritoneum is digitally pushed forward to create a retroperitoneal space. Lastly, a balloon is inserted to fully dilate the retroperitoneal space.

Using this technique, intracorporeal manipulation is not performed under direct vision and it is associated with the risk of improper dilation between muscle layers caused by balloon misplacement. Intramuscular dilation can lead to musculature tearing and bleeding, possibly resulting in conversion to an open procedure or postoperative hernia [4]. Furthermore, if the balloon is inserted too deep and dilates within the Gerota fascia, the renal vein can tear [5]. These complications can be avoided by direct visualization using a commercially available transparent balloon where the laparoscope is inserted into the balloon and the proper position of the balloon is confirmed endoscopically. However, this results in higher costs. Another alternative is the use of ultrasound to confirm the position of the balloon [6]. In addition, even if the incision is as small as possible, air leakage around the balloon trocar remains a problem because the index finger is thicker than the 10-mm trocar. Thus, airtight instruments or sutures must be adopted to ensure an airtight incision [2].

During the Veress needle technique, the Veress needle is inserted and followed by “blind” trocar puncture at the midaxillary or posterior axillary lines through a 10-mm skin incision. However, this

procedure is associated with several complications [7]. First, the fibroareolar tissue binds to the PF in the retroperitoneum and can not be sufficiently broken down by CO_2 insufflation via the Veress needle alone. It is thus difficult to obtain an adequate working space, and breaking the fibroareolar septa via laparoscopy is needed. Second, the tip of the trocar will be inserted into the PF (between the psoas muscle posteriorly and Gerota's fascia anteriorly) or perirenal fat (within Gerota's fascia) due to the "blind" puncture [8]. Further laparoscopic dissection is performed within fatty tissues, and en bloc fat is separated into several parts, which is often accompanied by vascular breakage. Lastly, laparoscopic visibility is often obscured by blood and fat tissue, and this technique is associated with frequent smudging of the laparoscope and a lack of anatomical landmarks [9]. An insufficient endoscopic view may result in complications, such as pneumothorax [6,7].

Because of the disadvantages of the existing dilation techniques, a modified technique for creating a retroperitoneal working space was introduced at our institution. In this procedure, initial access is obtained by trocar puncture through a 10-mm skin incision without the use of digital dissection. Therefore, air leakage due to a larger incision can be avoided. The tip of the trocar is adjusted to the plane between the TAM and the PF under laparoscopic monitoring. This is important because this layer is composed of semi-transparent loose and flimsy fibroareolar tissue and is nearly avascular. This facilitates a clear laparoscopic view during dissection and en bloc dissection of the PF from the transversalis fasci.

After proper layer entry, dissection movements of the laparoscope are performed. The different visual characteristics of the transversus abdominis muscle, PF, and fibroareolar tissue act as laparoscopic anatomical landmarks, which guarantees that the correct layer is dissected. In our experience, proper layer entry can fill areolar tissue with gas, which contributes to the en bloc mobilization of the PF from the transversalis fasci.

Furthermore, both the tented portion of the flank abdominal wall and the light spot on the skin from the laparoscope could indicate the precise position of the dilation. These factors also contribute to the avoidance of mis- or overdistention.

The strain from laparoscopic dissection can lead to rupture and hemorrhage of occasional perforator vessels in the fibroareolar tissue (Fig. 2). Therefore, we have modified this technique. After preliminary dissection using the laparoscope, further dilation of the retroperitoneum is performed using a homemade balloon. As balloon inflation is progressive, the risk of vessel rupture is minimized. We

found that it is unnecessary to keep the balloon inflated for 5 min to achieve hemostasis, as in Gaur's technique [1,6]. Ultimately, a clear laparoscopic view with rare hemorrhage is possible.

In our modified procedure, balloon dilation is performed in two different directions, and the second dilation significantly expands the iliac fossa, which has the following advantages: (1) it facilitates exposure of the juxta vesical ureter during retroperitoneal laparoscopic nephroureterectomy, and (2) after being displaced, the PF can be placed in the space of the iliac fossa.

This modified technique offers several unique advantages. First, the skin incision is small, and no blunt dissection of the fascia and muscle with artery forceps is performed. Therefore, intraoperative air leakage is avoided. Mattress sutures or airtight systems are not necessary. Second, a preliminary blunt dissection is performed between the PF and transversalis fasci and not inside the PF. This ensures a clean laparoscopic view because this layer is a relatively avascular semi-transparent reticular fibrous structure. Lastly, manipulation of the entire process is performed using endoscopic monitoring. Therefore, the complications associated with balloon misplacement can be avoided.

Conclusion

This modified technique is simple and requires limited experience and technical skills. The procedure is performed under distinct endoscopic monitoring, which minimizes the risk of injury from obscured vision or "blind" manipulation. It not only provides a clear working space but also facilitates further dissection of the PF en bloc off Gerota's fascia. In summary, the modified dilation technique was initially proven safe and effective.

Author contributions X.F.X. conceived the idea, initial drafting of the article. Cheng: Data collection and data analysis, initial drafting of the article. Z.L., C.J.S., and J.P.D. Data collection. X.M.Z. Interpretation of data, critical revision of the article. J.P.G. Interpretation of data, critical revision of the article.

Author Disclosure Statement

The authors declare no conflict of interest.

Funding Information

This work was supported by National Natural Science Foundation of China (NSFC81972841).

Supplementary Material

Supplementary Video S1: https://pan.baidu.com/s/1fLv0Q-4PKBQznFwptPZXpA?pwd=l0ts (Extract Code: l0ts)

References

1. Gaur DD. Laparoscopic operative retroperitoneoscopy: use of a new device. J Urol 1992;148(4):1137-1139; doi: 10.1016/s0022-5347(17)36842-8.

2. Gill IS. Retroperitoneal laparoscopic nephrectomy. Urol Clin North Am 1998;25(2):343-360; doi: 10.1016/s0094-0143(05)70023-9.

3. Gaur DD, Agarwal DK, Purohit KC. Retroperitoneal laparoscopic nephrectomy: initial case report. J Urol 1993;149(1):103-105; doi: 10.1016/s0022-5347(17)36012-3.

4. Adams JB 2nd, Micali S, Moore RG, et al. Complications of extraperitoneal balloon dilation. J Endourol 1996;10(4):375-378; doi: 10.1089/end.1996.10.375.

5. Gaur DD, Rathi SS, Ravandale AV, et al. A single-centre experience of retroperitoneoscopy using the balloon technique. BJU Int 2001;87(7):602-606; doi: 10.1046/j.1464-410x.2001.02149.x.

6. Rassweiler JJ, Henkel TO, Stoch C, et al. Retroperitoneal laparoscopic nephrectomy and other procedures in the upper retroperitoneum using a balloon dissection technique. Eur Urol 1994;25(3):229-236; doi: 10.1159/000475289.

7. Kerbl K, Figenshau RS, Clayman RV, et al. Retroperitoneal laparoscopic nephrectomy: laboratory and clinical experience. J Endourol 1993;7(1):23-26; doi: 10.1089/end.1993.7.23.

8. McDougall EM, Clayman RV, Fadden PT, et al. Retroperitoneoscopy: the Washington University Medical School experience. Urology 1994;43(4):446-452; doi: 10.1016/0090-4295(94)90228-3.

9. Partin AW, Domochowski RR, Kavoussi LR, Peters CA (eds). Campbell-Walsh-Wein Urology, 12th edn. Elsevier, Philadelphia, PA, 2021.

Figure Legends

Fig. 1 Key procedures of the modified dissection technique for creating an adequate retroperitoneal working space.

a The patient in a full-flank position. The first trocar is punctured perpendicularly through a 10-mm incision (black arrow) in the midaxillary line, approximately 2 cm above the iliac crest. The 12th rib and iliac crest have been marked. **b** Telescopic view of the 30-degree up from the first trocar. The trocar tip (black arrow) is adjusted to the relatively avascular layer (RAL) between the transversus abdominis muscle (TAM) and pararenal fat (PF). **c** Laparoscopic dissection within the RAL. **d,e,f** The laparoscopic view is out of focus during dissection. The PF is yellow, the TAM is red, and the RAL is semi-transparent. These characteristics can be regarded as landmarks. **g** Strong light from the laparoscope transilluminates the muscle and forms a light spot on the skin. Movements of the laparoscope are palpable by hand simutaneously. **h** Custom-made balloon dilator. The balloon dilator consists of the middle finger of a surgical glove (size 8) mounted on a 24 Fr red rubber catheter. **i** After the balloon expands the space further, the working space is fully established. PF is mobilized en bloc from the transversalis fascia. A clear laparoscopic view without hemorrhage is observed

Fig. 2 Perforator vessel in fibroareolar tissue (black arrow)

Table 1 Demographic and clinical characteristics of the 47 patients with modified dissection technique.

Variable	Value
Age, years, median (IQR)	54 (47.5, 62)
Gender, n (%)	
Male	22 (46.8)
Female	25 (53.2)
BMI, kg/m^2, median (IQR)	25.68 (21.7, 27.6)
Retroperitoneoscopic procedures	
Radical nephrectomy	5
Nephrectomy	3
Partial nephrectomy	23
Adrenalectomy	13
Renal pedicle lymphatic disconnection for chyluria	1
Renal cyst decortication	1
Nephroureterectomy	1
Total	47
Time of creating retroperitoneal working space (minutes), median (IQR)	6 (5, 7)
Dissection-related complications (%)	0 (0)

BMI=body mass index; IQR=inter-quartile range;

1A

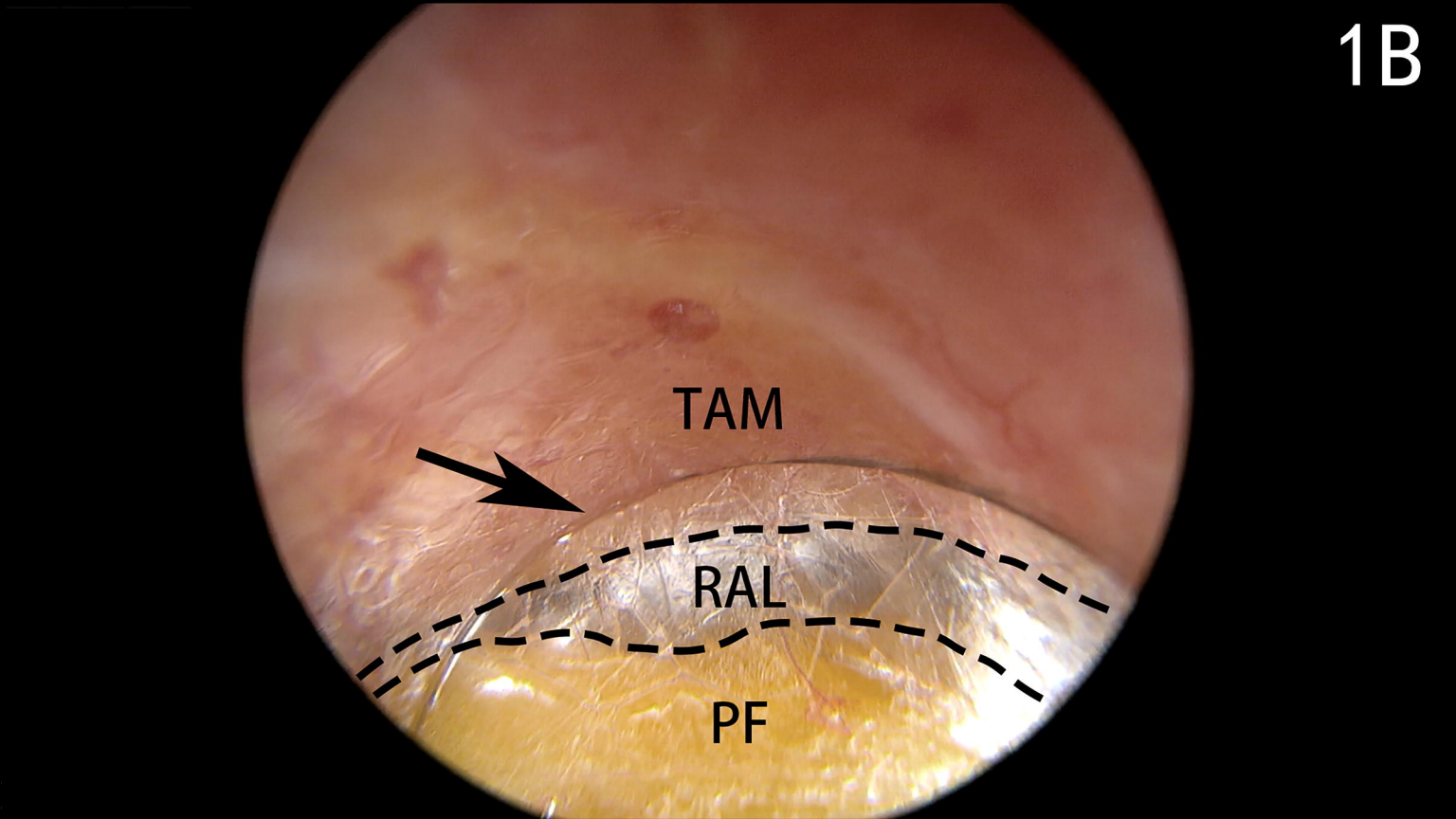
1B
TAM
RAL
PF

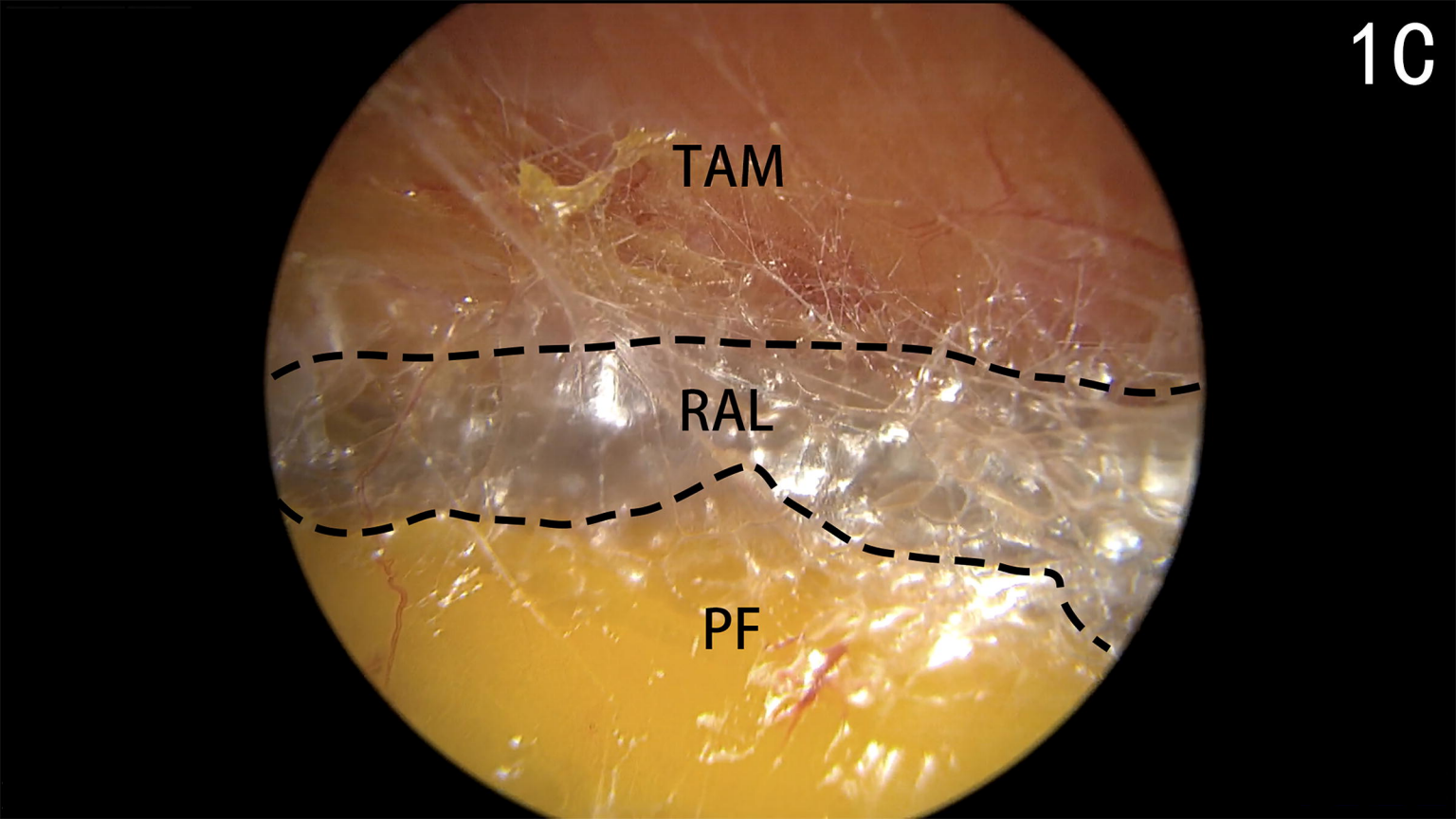
1C
TAM
RAL
PF

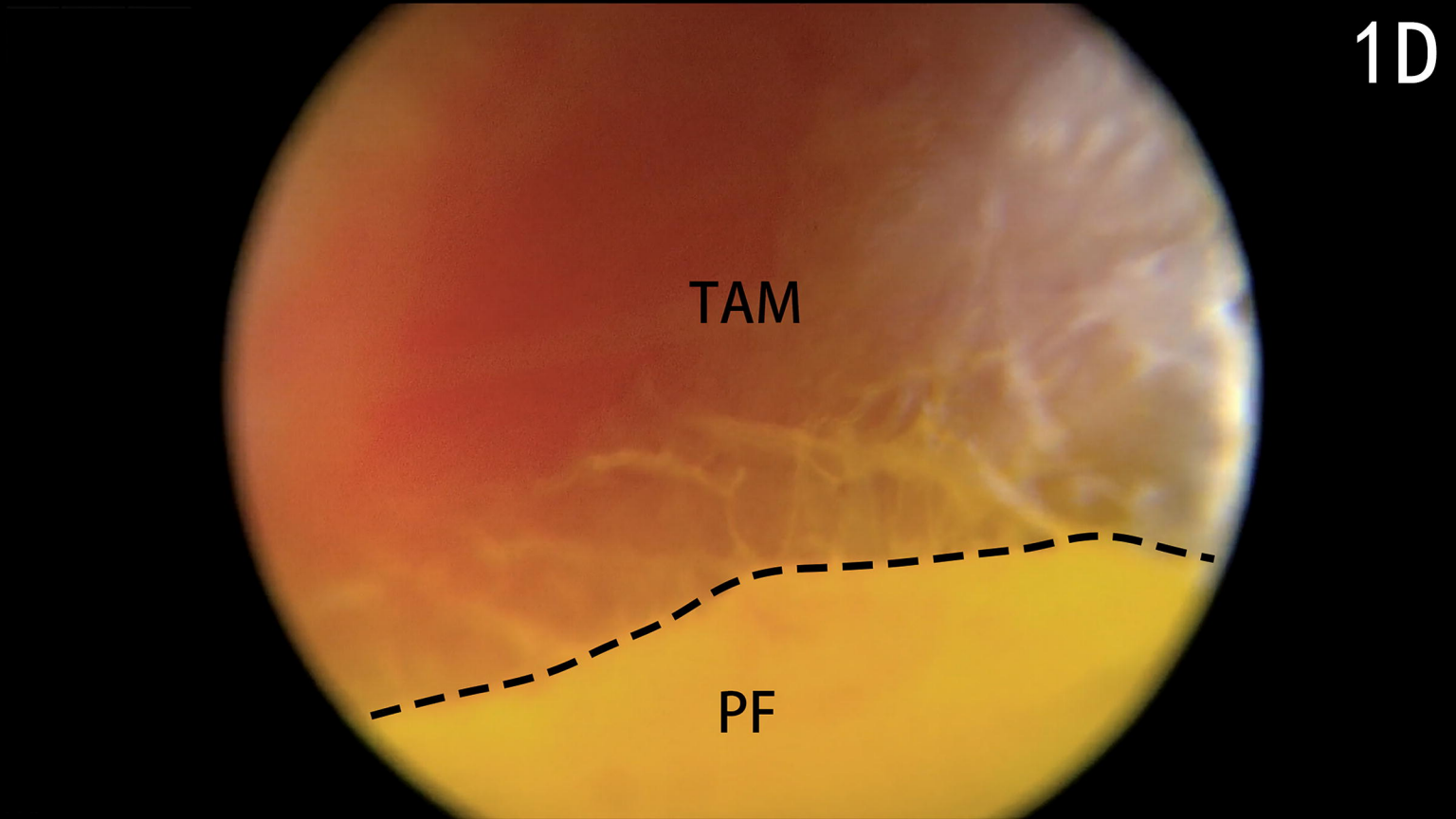
1D
TAM
PF

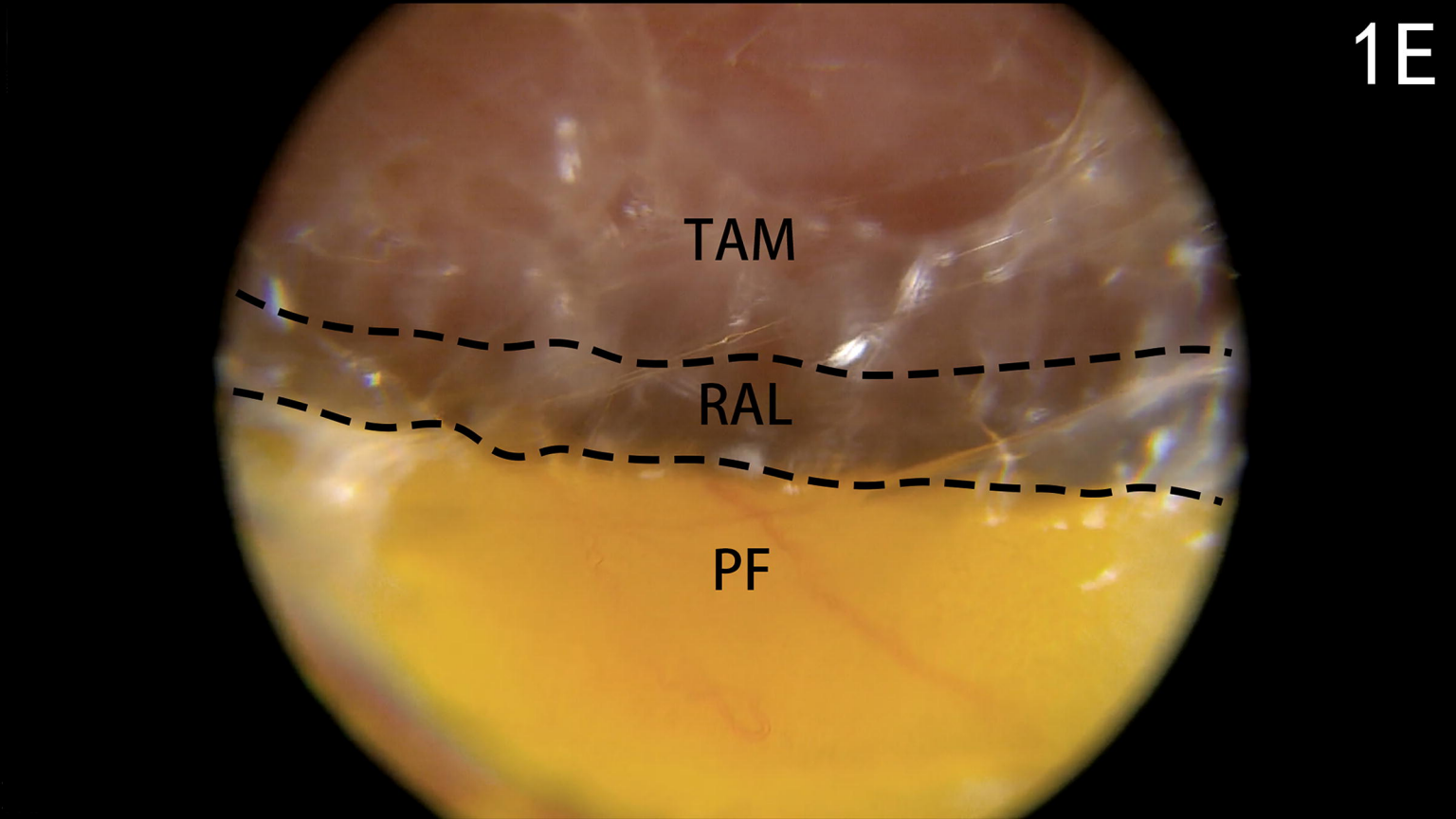
1E
TAM
RAL
PF

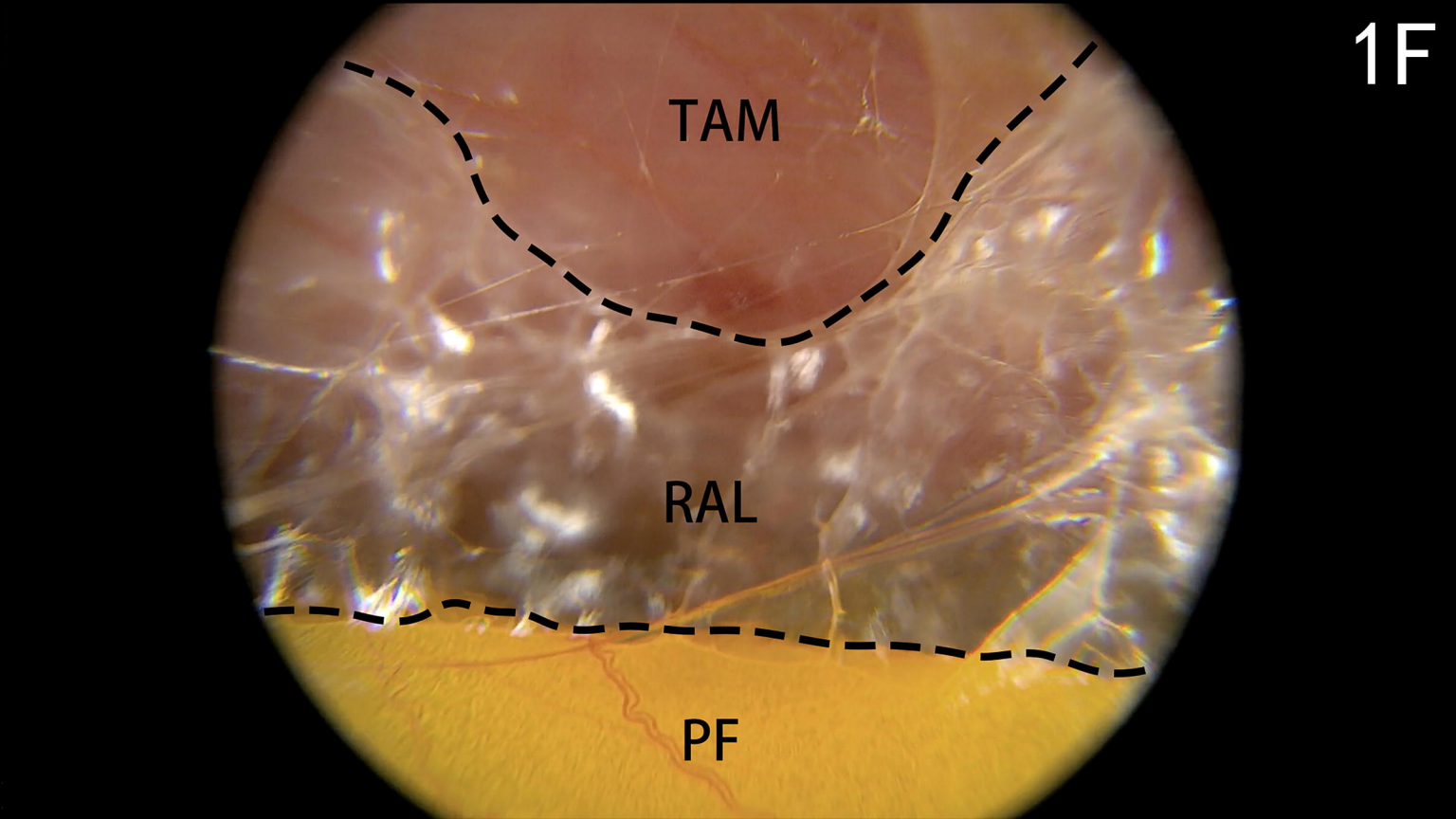
1F
TAM
RAL
PF

1G

1H

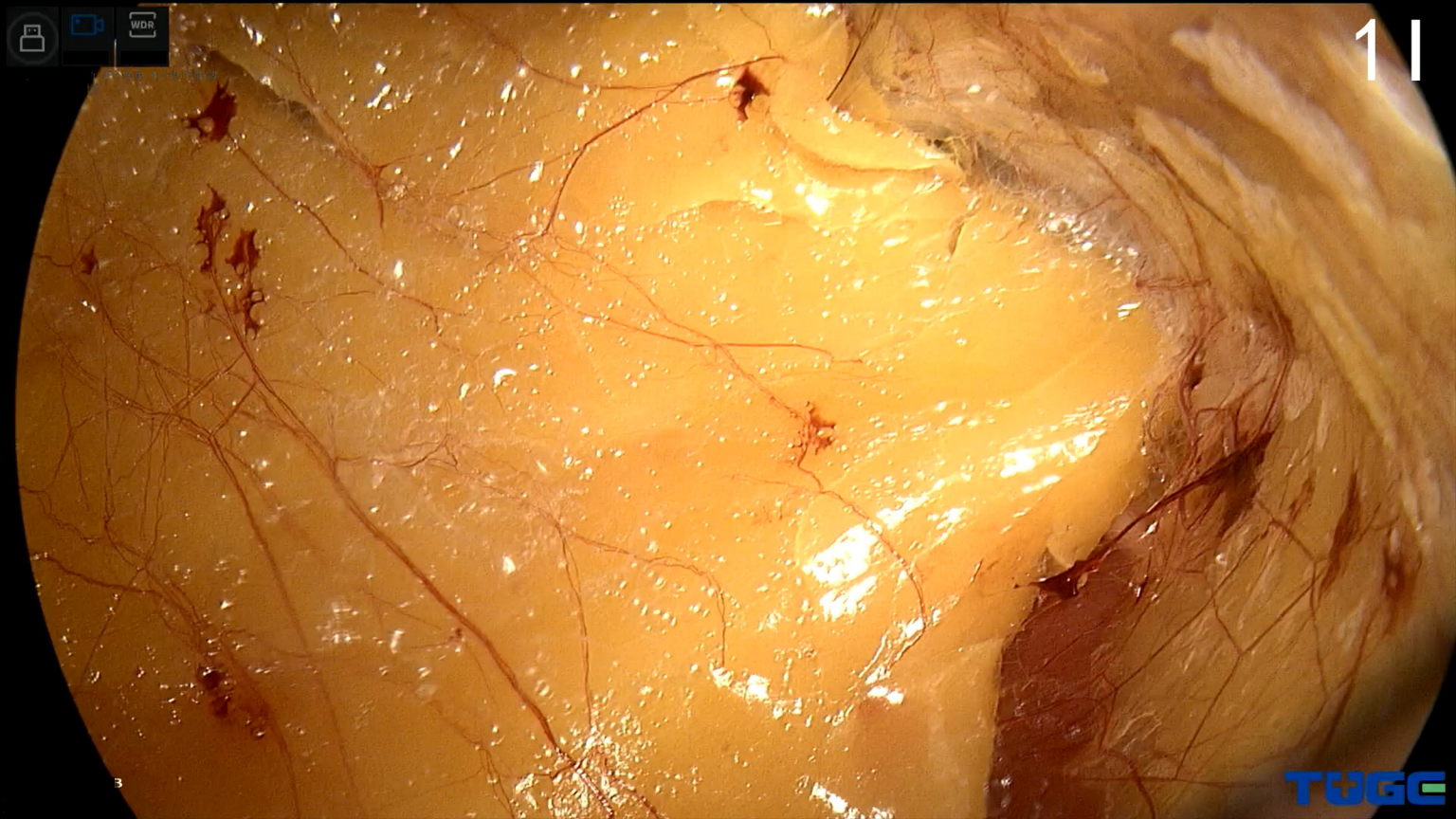
1
WDR
TUGE

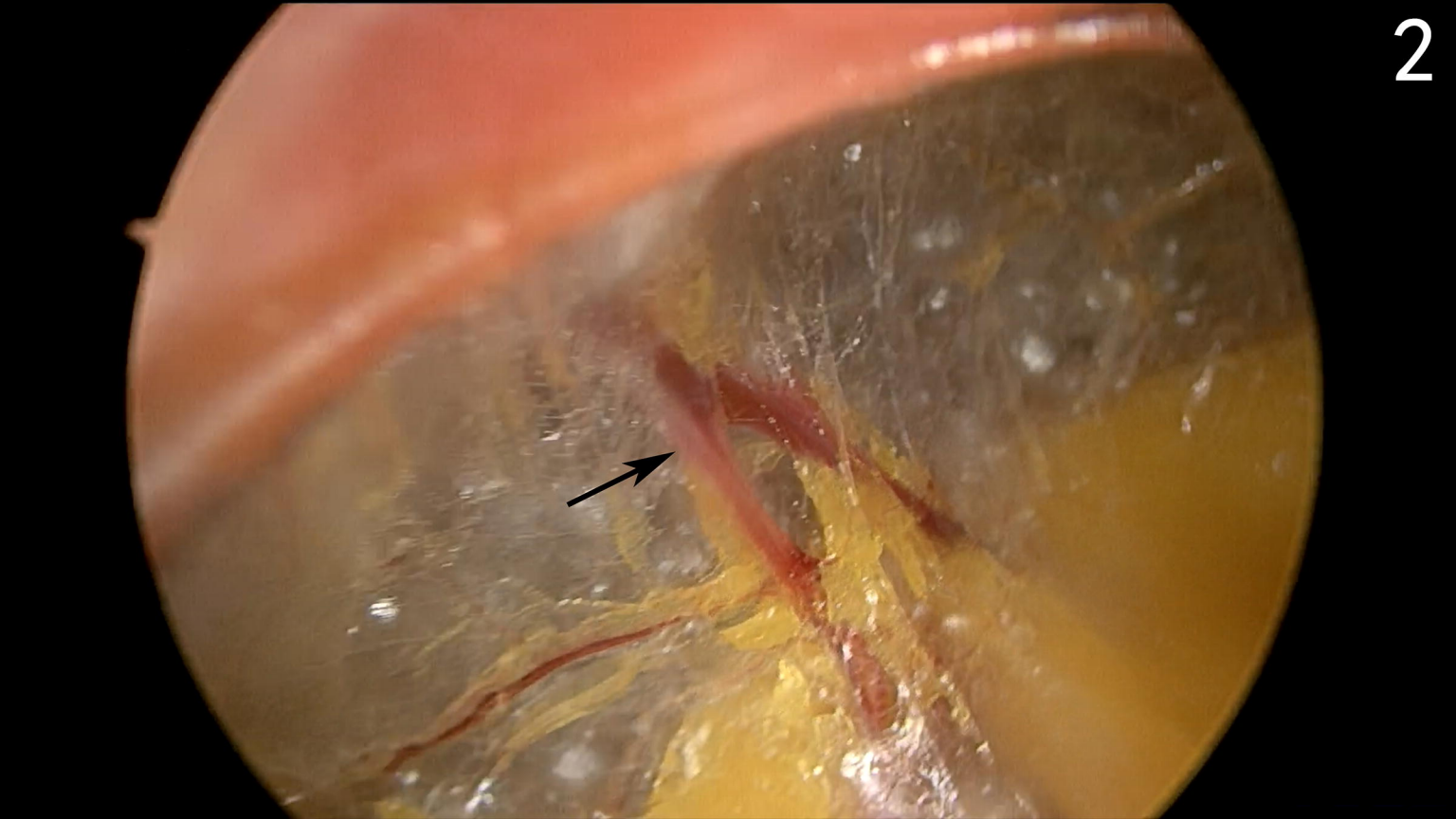
2