medRxiv preprint doi: https://doi.org/10.1101/2023.05.17.23290093; this version posted May 25, 2023. The copyright holder for this preprint (which was not certified by peer review) is the author/funder, who has granted medRxiv a license to display the preprint in perpetuity. It is made available under a CC-BY-NC-ND 4.0 International license .

# Real-world performance and safety of Halova® ovules in reducing the vaginal symptoms associated with vulvovaginal atrophy and postmenopausal sexual disfunction

**Dominic-Gabriel Iliescu [a, b], Ramona Petrita [c], * Cristina Teodorescu [d], Raluca Alexandra Olaru [e, f] and Andreea-Denisa Toma [g]**

[a] Discipline of Obstetrics and Gynecology VIII, University of Medicine and Pharmacy Craiova, 2 Petru Rares Street, 200349 Craiova, Romania
[b] 2nd Clinic of Obstetrics and Gynecology, Emergency County University Hospital Craiova, 1 Tabaci Street, 200642 Craiova, Romania,
[c] Biometrics Unit, MDX Research, 1-3 Vasile Loichita Street, 300633 Timisoara, Romania
[d] Discipline of Obstetrics and Gynecology, "Nicolae Malaxa" Clinical Hospital, 12 Soseaua Vergului, 022441 Bucharest, Romania
[e] Department of Obstetrics and Gynecology III, Institutul National pentru Sanatatea Mamei si Copilului Alessandrescu Rusescu, Clinic of Obstetrics and Gynecology „Polizu", 38-52 Gheorghe Polizu Street, District 1, 011061 Bucharest, Romania
[f] Discipline of Obstetrics, Gynecology and Neonatology Spitalul Clinic Polizu "Carol Davila" University of Medicine and Pharmacy Bucharest, 8 Eroii Sanitari Boulevard, District 5, 050471 Bucharest, Romania
[g] Pharmacy Unit of Municipal Hospital "Dr. Karl Diel" Jimbolia, 4 Contele Csekonics, 305400 Jimbolia, Romania
* Corresponding authors: dominic.iliescu@yahoo.com; ramona.petrita@mdxresearch.eu; Contact phone number: 40723 888 773; 40 721 893 630

**Abstract:** Decreasing of sex hormones during postmenopausal period results in atrophy of the tissues and physiological changes, such as thinning of the vaginal epithelium, prolapse, decreased pelvic floor strength and control. Sexual disfunction, correlated with vaginal dryness is frequently reported among postmenopausal women. The present study was designed as an observational, multicentric, real-world evidence clinical investigation to evaluate the performance and safety of the medical device Halova® ovules in reducing the vaginal symptoms associated with vulvovaginal atrophy and sexual disfunction. A total of 249 female participants were treated with Halova® ovules, both in single therapy and associated with concomitant medication. The primary objective was to evaluate the tolerability of Halova® ovules in the management of symptoms associated with perimenopause or with genitourinary syndrome of menopause. The evolution of clinical manifestations such as vaginal dryness, dysuria, dyspareunia and endometrial thickness in patients with aforementioned conditions were defined as secondary objectives. Halova® ovules was rated with "excellent" clinical performance for 92.74% of study participants as a standalone treatment and for 95.71% of study participants when used in association. Sexual disfunction related parameters, such as vaginal dryness and dyspareunia were reduced, with similar percentages in each arm. There have been no reported adverse reactions related to the treatment with Halova®. Halova® might be a therapeutic alternative in patients in whom local estrogenic treatment remains controversial, such as patients with breast cancer. The study and its details are registered with number NCT05654610.

**Keywords**: **vulvovaginal atrophy, perimenopause, menopause, medical device, vaginal dryness, natural lubrication, vaginal pH, sexual dysfunction.**

**NOTE: This preprint reports new research that has not been certified by peer review and should not be used to guide clinical practice.**

medRxiv preprint doi: https://doi.org/10.1101/2023.05.17.23290093; this version posted May 25, 2023. The copyright holder for this preprint (which was not certified by peer review) is the author/funder, who has granted medRxiv a license to display the preprint in perpetuity. It is made available under a CC-BY-NC-ND 4.0 International license .

## 1. Introduction

*1.1 Prevalence and etiology of the genitourinary syndrome of menopause*

One out of two perimenopausal and postmenopausal women experience, as a consequence of the reduction in estrogen and other sex steroids in the menopause, a collection of symptoms and signs called the genitourinary syndrome of menopause (GSM) (1,2). The GSM replaced the term " vulvovaginal atrophy" while it implicates a plethora of changes in the genital area and the lower urinary tract (2,3.) Its prevalence ranges from 36% to almost 84%, being very often underdiagnosed and undertreated (4,5). The condition may also occur earlier, in perimenopausal women who take antiestrogenic medications or who have medical characterized by decreased levels of estrogen (6).

Clinicians play an important role in recognizing the signs of GSM because many women relate this progressing condition to ageing or are reluctant in approaching the subject due to sexual embarrassment. (7).

During reproductive age, the ovaries produce a large proportion of circulating estrogens (6,8). Normally, the vaginal walls are kept lubricated by the cervical-vaginal fluid produced by the cervix at the top of the vagina. This the cervical-vaginal fluid has the following effects: protecting the vagina from infections, cleaning the vagina by removing dead cells and menstrual bleeding and also lubrication of the vagina during intercourse. *Lactobacillus sp*. and an acidic vaginal pH also protect the lower female reproductive tract from the migration of exogenous bacteria or overpopulation of the endogenous vaginal microflora that cause vaginal infections.

Decreasing of sex hormones during postmenopausal period affects all layers of the vagina leading to anatomical and physiological changes, such as shortening and narrowing of the vagina, loss of rugae, and flattening, keratinization of the surface and thinning of the vaginal epithelium. Thin vaginal epithelium leads to an increased susceptibility of trauma, with clinical signs such as bleeding, petechiae, and ulceration with any type of pressure including sexual activity or a simple gynecological maneuver (6,9).

In addition to the onset of menopause, estrogen levels can drop significantly due to other causes, such as: birth or breastfeeding, cancer treatments, surgical removal of the ovaries, anti-estrogen drugs used to treat uterine fibroids and endometriosis. Other causes of vulvovaginal atrophy can be: Sjogren's syndrome - an autoimmune disease that attacks the cells in the body that are involved in the secretion of saliva, tears, i.e. those cells that pro-duce moisture, allergies, cold medicines, antidepressants, vaginal washings, dehydration determined by insufficient liquid intake, excessive vasoconstriction, and also anxiety and stress overload (8,10).

*1.2 Clinical manifestations*

The main symptoms in GSM include vaginal dryness and reduced lubrication during sexual activity, with loss of elasticity, petechiae, ulceration, inflammation, itching, discomfort, atypical vaginal discharge, dyspareunia, fibrosis and vaginal obliteration, greatly affecting quality of life (8). Also, GSM

medRxiv preprint doi: https://doi.org/10.1101/2023.05.17.23290093; this version posted May 25, 2023. The copyright holder for this preprint (which was not certified by peer review) is the author/funder, who has granted medRxiv a license to display the preprint in perpetuity. It is made available under a CC-BY-NC-ND 4.0 International license .

affects progressively the genitourinary system, with dysuria, urinary frequency/urgency, urinary incontinence, vaginal prolapse and recurrent urinary tract infections reported on a frequent basis (3).

*1.3 Clinical management of urinary complaints*

Urinary complaints in postmenopausal women should be managed following a physical examination and laboratory diagnose testing, including serum hormone levels and Papanicolaou smear. A differential diagnosis should be considered to eliminate any vaginal infections (candidiasis, trichomoniasis or bacterial vaginosis) or other conditions that cause chronic vaginal and vulvar itching, discharge, or pain such as irritants and vulvovaginal dermatoses (11). Irritants that can cause chronic vaginal itch include perfumes, any locally applied lubricant or moisturizer, and soaps. Vulvovaginal dermatoses that may also cause similar symptoms include lichen sclerosus, lichen planus, and lichen simplex chronicus.

The principal therapeutic target in the management of the GSM is to relieve symptoms, especially vaginal dryness. Treatment strategies are mainly based on the use of moisturizers and lubricants, and also include physical therapy, low-dose vaginal estrogen therapy, vaginal dehydroepiandrosterone, and oral ospemifene, with a more modern approach including the use of vaginal laser (12,13). Patients who experience problems with the natural lubrication of the vagina due to hormonal changes can often benefit from estrogen therapy. In addition to estrogen treatment or if side effects caused by hormone treatment are difficult to bear, preparations with moisturizing agents that help to introduce and maintain water in the vaginal mucosa are recommended.

Non-hormonal treatment includes vaginal/topical moisturizers and lubricants, such as combination of Hippophaë rhamnoides oil, hyaluronic acid and glycogen or hyaluronic acid, collagen, isoflavones and vitamins (14,15). Lubricants provide short-term relief for patients and are typically used for vaginal dryness during intercourse, while moisturizers have a long-er-lasting effect and may be used daily to every 2-3 days per week (16).

Hormonal replacement therapy may be systemic (oral estrogen replacement) or localized (intravaginal/topical estrogen, estrogen intravaginal releasing ring, and vaginal dehydroepiandrosterone). The hormonal therapy with estrogen is considered the most effective treatment used for vaginal atrophy, vaginal dryness and dyspareunia in women with estrogen deficiency. On the other hand, estrogen therapy is known for its increased risk of stroke and tromboembolism. Also, estrogen therapy should be administered with precaution in patients who have survived hormone-sensitive cancers as systemic absorption of estrogen can stimulate the growth of breast cancer cells. Although systemic estrogen therapy improves symptoms of vaginal atrophy, systemic doses are higher than those used for topical application and should be administered only if other menopausal symptoms requiring treatment are present (6,9,17).

Post-marketing studies are primarily used to answer an important clinical question: “Is this medical device effective and safe in a non-controlled, real life setting? As such, the primary objective was to observe the tolerability of Halova® ovules in treating vaginal dryness and restoring the natural

medRxiv preprint doi: https://doi.org/10.1101/2023.05.17.23290093; this version posted May 25, 2023. The copyright holder for this preprint (which was not certified by peer review) is the author/funder, who has granted medRxiv a license to display the preprint in perpetuity. It is made available under a CC-BY-NC-ND 4.0 International license .

lubrication of the vaginal mucosa. The secondary objective of this study was to evaluate the performance of the medical device by clinical examination, in reducing the symptomatology correlated with vulvovaginal atrophy, the evaluation of the endometrium thickness and vaginal pH. Additionally, the degree of patient satisfaction related to the use of the medical device (Likert scale) was collected.

## 2. Methods

### *2.1 Study design*

The present study was designed as part of the medical device post-marketing clinical follow-up, involving routine care from a variety of clinical practices. The study included an open-label, multicentric, non-randomized, real-world evidence study design. The data was collected between 1st of March 2022 and 31st of July 2022. Clinical practices and their locations are listed in table 1.

| Institution | City, Country (Romania) |
|---|---|
| SC Pan Medical SRL | Sibiu |
| Gynecological office of Dr. Ispasoiu Corina | Sibiu |
| Natisan Medical Center | Pitesti |
| Gynecological office of Dr Rădulescu G. Mihaela Elena | Ramnicu Valceea |
| Medical office of Dr Saleh K. Majed | Craiova |
| Hospital MedLife Humanitas Cluj-Napoca | Cluj-Napoca |
| Gynecological office of Dr Ioana Trotea Targu Jiu | Targu Jiu |
| Medical office of Dr Surpanelu Oana | Iasi |
| Medsan | Cluj |
| Medical clinic of Dr. Cioata Ionel Trifon | Timisoara |
| Clinical Hospital 'Dr Ion Cantacuzino' Bucharest | Bucharest |
| Tulcea County Emergency Hospital | Tulcea |
| Clinical Hospital 'Dr Ion Cantacuzino' Bucharest | Bucharest |
| iMED Clinic | Sibiu |
| Medical office of Obstetrics and Gynecology of Dr Popescu Dragos SRL | Sibiu |
| Gynecological office of Dr. Iliescu Irina | Iasi |
| Medical office of Obstetrics and Gynecology of Dr Sterie Ionut SRL | Tulcea |
| Dr Todorut Florina | Timisoara |
| Total sites, 17 | |

medRxiv preprint doi: https://doi.org/10.1101/2023.05.17.23290093; this version posted May 25, 2023. The copyright holder for this preprint (which was not certified by peer review) is the author/funder, who has granted medRxiv a license to display the preprint in perpetuity. It is made available under a CC-BY-NC-ND 4.0 International license .

*Table 1. Clinical practices and their locations*

### *2.2 Participant population*

The participant population included women aged between 18-70 years, of Caucasian ethnicity with several clinical manifestations associated with the following conditions: dryness complaint in the vaginal region, perimenopause, vulvovaginal atrophy, menopausal disorder or vaginal prolapse. Two hundred forty-nine women have been evaluated. One hundred seventy-nine patients have only undergone treatment with Halova® ovules in monotherapy, while 70 have used Halova® ovules in association with other medication (polytherapy). Subjects with psoriasis, vitiligo, plantar ulcer, lipoid necrobiosis, granuloma annulare, vulvar or cervical cancer were excluded. Based on other similar pivotal studies, the sample size included initially a total of 240 subjects, by using a one-sided Wilcoxon Signed-rank test (matched pairs), a significance level of 0.05 and a power of 0.95.

The study involved 17 Romanian specialist physicians as investigators, each with 4 to 20 patients under treatment with Halova® ovules. Endometrial evaluation was performed with transvaginal ultrasonography. The total study duration was 30 days. The medical device was applied once a day for a sequence of 10 consecutive days.

Prospective data were collected from each patient, such as initial diagnosis, transvaginal ultrasonography, vaginal pH value, vaginal symptoms, any worsening symptoms and adverse events. To assess pH, a piece of litmus paper was placed on the lateral vaginal wall until moistened. A pH of 4.6 or greater indicated vulvovaginal atrophy, assuming the patient did not have bacterial vaginosis. Premenopausal women without vulvovaginal atrophy typically have a pH between 3.8- 4.5. Primary and secondary outcomes were collected at baseline and at 30 days.

### *2.3 The medical device*

Halova® *ovules* is a medical device manufactured by Perfect Care Manufacturing S.R.L and identified under the European Medical Device Regulation with device identification number 5944754000754. It is intended for intravaginal administration in order to promote and accelerate the hydration, healing, epithelialization and/or soothing of injured, atrophic or irritated vaginal mucosa. Halova® ovules have the following composition: sodium hyaluronate (5mg), marigold extract (60mg), vitamin E (10mg), aloe vera oil (60mg), semi-synthetic glycerides (1587mg), lanolin (50mg), silicon dioxide (25mg), xylitol (3mg).

The ovules melt evenly in the vaginal mucosa forming a cream that contributes to restoring the normal lubrication of the vaginal mucosa and helps preserving a normal pH and vaginal flora. Halova® ovules are intended for use in adult women (including those in menopause) and are indicated for: vaginal dryness caused by age, various pathologies or other drug treatments, relief of pain and discomfort during sexual intercourse, balancing of the vaginal flora and vaginal pH preserving. Halova® ovules have a content of ingredients that give it beneficial properties in restoring normal lubrication of the vaginal mucosa and helps preserving a normal vaginal pH and flora.

medRxiv preprint doi: https://doi.org/10.1101/2023.05.17.23290093; this version posted May 25, 2023. The copyright holder for this preprint (which was not certified by peer review) is the author/funder, who has granted medRxiv a license to display the preprint in perpetuity. It is made available under a CC-BY-NC-ND 4.0 International license .

Hyaluronic acid is an alternative to non-hormonal treatments for the signs of vaginal atrophy and dyspareunia. Sodium hyaluronate retains a large amount of water, provides moisture to the vaginal tissue and can be an effective way to treat vulvovaginal discomfort. Hyaluronic acid is contained in the medical device Halova® in the amount of 5mg / ovule, used to promote hydration of dry vaginal mucosa and re-epithelialization of damaged tissue. The mechanism of action of hyaluronic acid with a high molecular mass at the level of the vaginal mucosa is realized by the formation of an extracellular matrix with water trapped in the structure.

In the Halova® ovules medical device, the extract of Calendula officinalis is in a quantity of 3,3%, used to prevent contamination with exogenous bacteria during the handling of the medical device and to prevent microbiological contamination of the fat base with Gram-negative bacteria and fungi.

Xylitol contained in the medical device Halova® in an amount of 3mg/ovule and has the role of a nutritional substrate. The ovule base is composed of a mixture of fatty base, lanolin and oily extract of Aloe Vera. Vitamin E prevents the oxidative degradation of the fatty base.

The medical device is in the form of ovules of 1.8 g each, ovoid in shape, white or pale yellow in color, with a smooth appearance, without spots of color or areas with agglomerated powders. In the longitudinal section, the ovules have a homogeneous appearance, without agglomerations of particles and air bubbles. The medical device was administered for 10 days in patients meeting the eligibility criteria.

*2.4 Ethical and regulatory aspects of the study*

Written consent for study participation was collected from all patients. General Data Protection Regulation (GDPR) consent forms were collected from all patients. Due to legal considerations (GDPR directive effective from 21 May 2018 in all European Union countries), patients or their legal representatives have an absolute right to request that their data be removed from the study database. A Notified Body (ENTE CERTIFICATIONE MACCHINE SRL) reviewed the post-marketing clinical follow-up plan, including ethical considerations.

The study was conducted in accordance with the Guide to medical devices: 'Post-market clinical follow-up studies' (https://www.imdrf.org/sites/default/files/docs/imdrf/final/technical/imdrf-tech-210325-wng65.pdf) and the International Society for Pharmacoepidemiology (ISPE; 2015) Guidelines for 'Good pharmacoepidemiology practices (GPP)' (https://www.pharmacoepi.org/resources/policies/guidelines-08027/)

The collected data and study procedures were conducted in accordance with the ethical principles that have their origin in the Declaration of Helsinki. Data were stored according to Annex E of ISO 14155:2020 (https://www.iso.org/standard/). The study and its details are registered in *www.clinicaltrials.gov* under ID NCT05654610.

*2.4 Statistical analysis*

medRxiv preprint doi: https://doi.org/10.1101/2023.05.17.23290093; this version posted May 25, 2023. The copyright holder for this preprint (which was not certified by peer review) is the author/funder, who has granted medRxiv a license to display the preprint in perpetuity. It is made available under a CC-BY-NC-ND 4.0 International license .

All statistical analyses were performed using the Excel Analysis ToolPak, version 16.69.1, from Microsoft. $P<0.05$ was considered to indicate a statistically significant difference. The quality and completeness of the collected data were preliminarily assessed in comparison with data analysis. No study participant was involved in any violation of inclusion/exclusion criteria. To examine the treatment significance over time, Fisher's exact test was performed for categorical variables, and Mann-Whitney U test was employed to perform comparative analysis for variables non-normally distributed.

## 3. Results

### *3.1. Primary objectives*

The primary objective was to evaluate the tolerability of Halova® ovules in treating vaginal dryness and restoring the natural lubrication of the vaginal mucosa. There have been no reported adverse reactions related to the treatment with Halova® after 30 days of administration, which makes the medical device safe to administer. The medical device is considered a safe and effective alternative to alleviate specific signs and symptoms of GSM in postmenopausal women (dysuria, dyspareunia and vaginal dryness), especially when hormonotherapy is not recommended. Some limitations of this study include the absence of a control group, a short treatment follow-up and the heterogenicity of the sample population. The CONSORT diagram is presented in figure 1.

medRxiv preprint doi: https://doi.org/10.1101/2023.05.17.23290093; this version posted May 25, 2023. The copyright holder for this preprint (which was not certified by peer review) is the author/funder, who has granted medRxiv a license to display the preprint in perpetuity. It is made available under a CC-BY-NC-ND 4.0 International license .

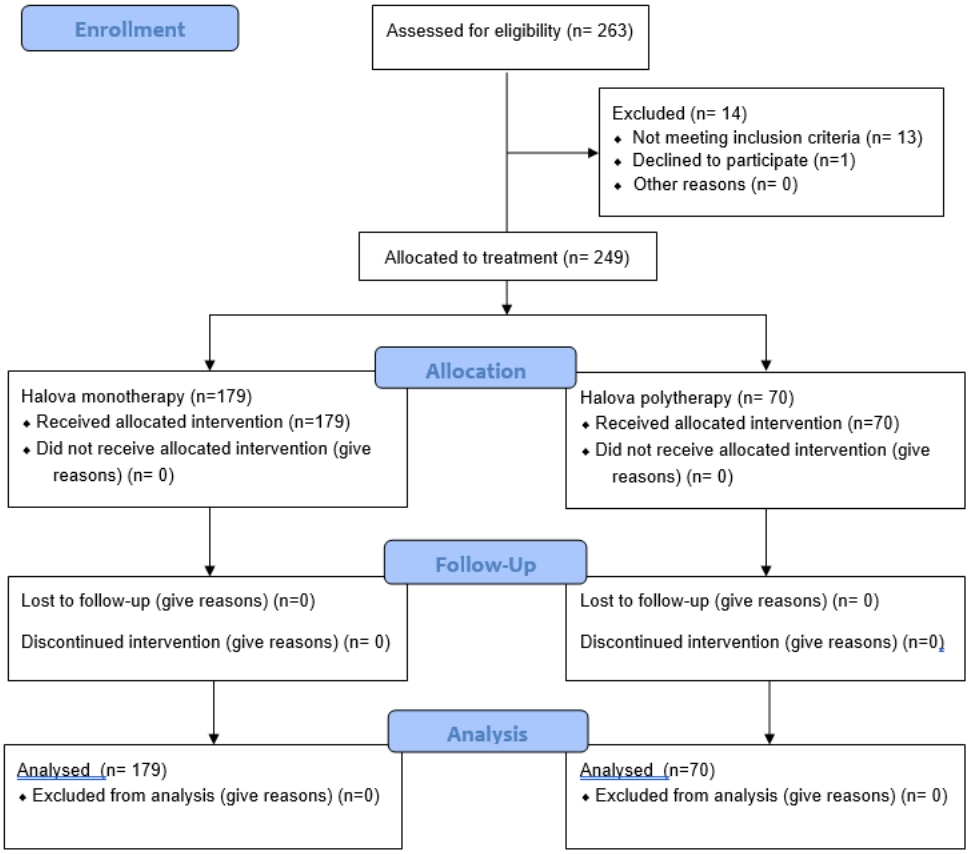


Figure 1. The CONSORT diagram

*3.2. Secondary objectives*

The secondary objective of this clinical investigation was to evaluate the performance of the medical device by clinical examination, together with the degree of patient satisfaction related to the use of the medical device (5-points Likert scale).

In order to calculate the statistical significance related to the performance/improvement of the secondary objective indicators, we have used a one-tailed z-test (0.05 significance level) with the first screening visit as baseline (null hypothesis that there is no statistically significant difference between baseline visit and the follow-up visit planned at 30 days interval). The p-values are detailed in table 1.

| Type of treatment | Clinical performance | Vaginal pH | Endometrial thickness | Dyspareunia | Dysuria | Vaginal dryness |
|---|---|---|---|---|---|---|

medRxiv preprint doi: https://doi.org/10.1101/2023.05.17.23290093; this version posted May 25, 2023. The copyright holder for this preprint (which was not certified by peer review) is the author/funder, who has granted medRxiv a license to display the preprint in perpetuity. It is made available under a CC-BY-NC-ND 4.0 International license .

| | | | | | | |
|---|---|---|---|---|---|---|
| Monotherapy | p < 0.0001 | p < 0.001 | p < 0.0001 | p < 0.0001 | p < 0.05 | p < 0.0001 |
| Polytherapy | p < 0.01 | p < 0.01 | p < 0.001 | p < 0.05 | p < 0.05 | p < 0.0001 |

*Table 2. p-values for significance at 30 days*

*3.2.1. Medical device performance evaluation*

1. Clinical performance

As shown in figure 2, regarding the clinical performance we observed in the monotherapy group the treatment was rated for the majority of patients as “excellent” (84.35%) and with similar percentages, in the polytherapy group, the treatment was rated as “excellent” or “highly effective” for 67 (95.71%) patients.

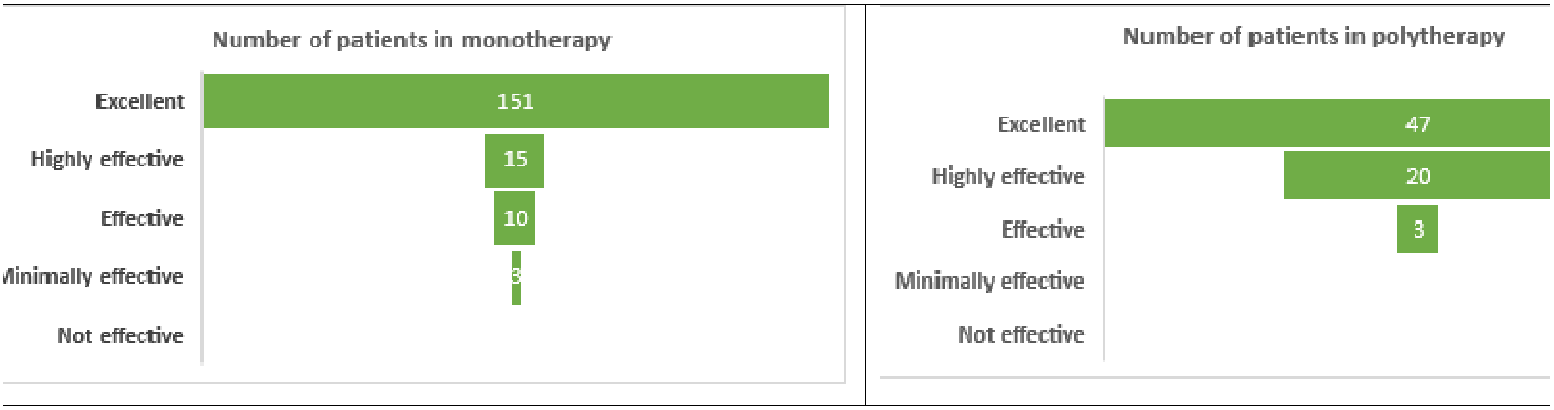


Figure 2. Clinical performance

2. Vaginal pH level evaluation

Patients were evaluated in relation with their vaginal pH level at the follow-up visit, as shown in figure 3. The score “normal” was observed in 75% of patients treated with Halova® ovules and in 84% of patients receiving the treatment comprising of Halova® ovules and other specific medication.

medRxiv preprint doi: https://doi.org/10.1101/2023.05.17.23290093; this version posted May 25, 2023. The copyright holder for this preprint (which was not certified by peer review) is the author/funder, who has granted medRxiv a license to display the preprint in perpetuity. It is made available under a CC-BY-NC-ND 4.0 International license .

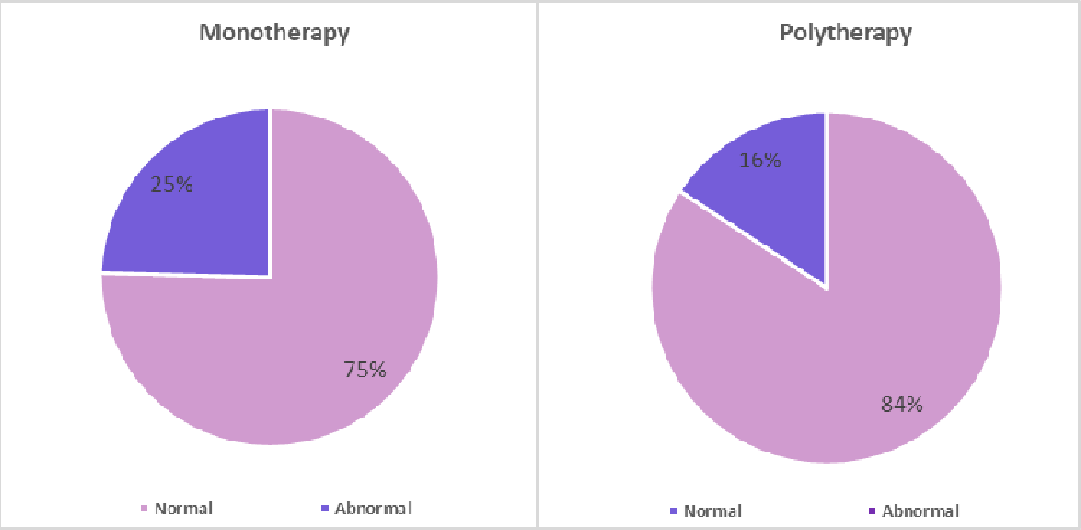


Figure 3. Measurement of the vaginal pH in both arms

3. Dyspareunia symptoms

Regarding dyspareunia symptoms, patients were evaluated, during a brief interview, using a 5-point Scale, from “Absent” to “Severe” as shown in figure 4. We observed that in patients using Halova® ovules as monotherapy, a significant proportion of 72 % was reported with the score “Absent”, while in patients receiving associated treatment, the highest proportion was reported with the score “Absent” (52% followed by “Mild dyspareunia” (52%).

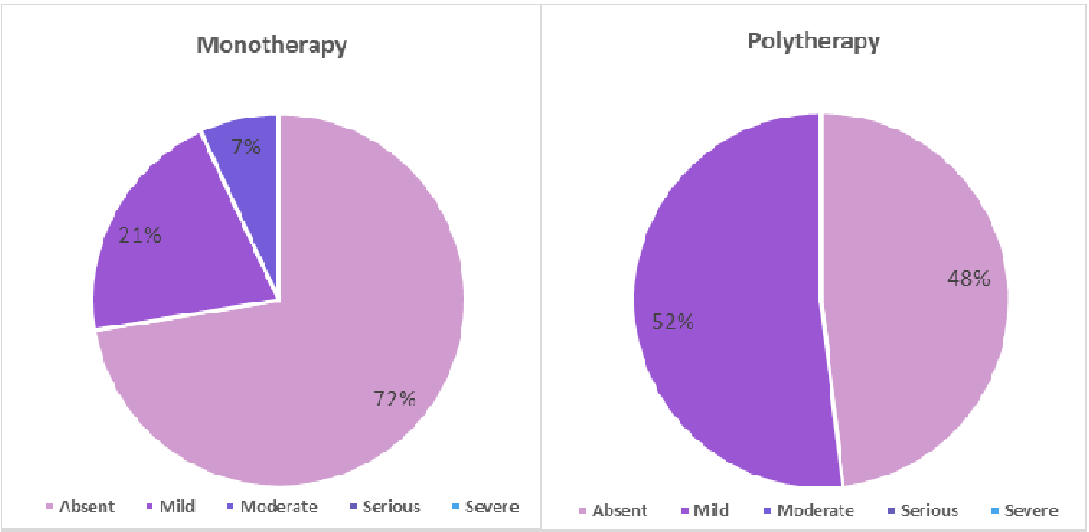


Figure 4: Dyspareunia symptoms – evaluation results at 30 days

4. Dysuria symptoms

As shown in supplemental figure 5, regarding the presence of dysuria, the highest proportion of patients reported the score “Absent” 64% in monotherapy. When Halova® was administered as polytherapy, 78% of the study participants reported the symptom as “Absent”.

medRxiv preprint doi: https://doi.org/10.1101/2023.05.17.23290093; this version posted May 25, 2023. The copyright holder for this preprint (which was not certified by peer review) is the author/funder, who has granted medRxiv a license to display the preprint in perpetuity. It is made available under a CC-BY-NC-ND 4.0 International license .

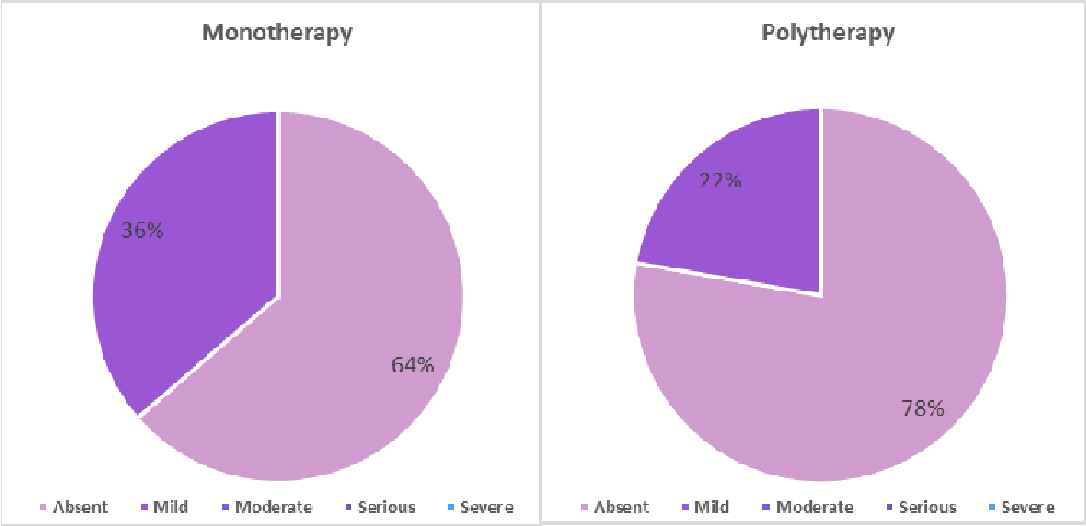


Figure 5: Dysuria symptoms – evaluation results at 30 days

5. Endometrium thickness evaluation

Regarding endometrium thickness, ultrasound was performed in study participants treated with Halova®. The results are shown in supplemental figure 6. We observed a significant proportion of patients with a rating of endometrial thickness as “Absent”. “Mild” and “Moderate” endometrial thickness were encountered for 20%, respectively 4% of the study participants in the monotherapy group. In the polytherapy, the percentages were similar, with 78% patients with a rating of endometrial thickness as “Absent”, 20% with a rating of endometrial thickness as “Mild” and 2% with a rating of endometrial thickness as “Moderate”.

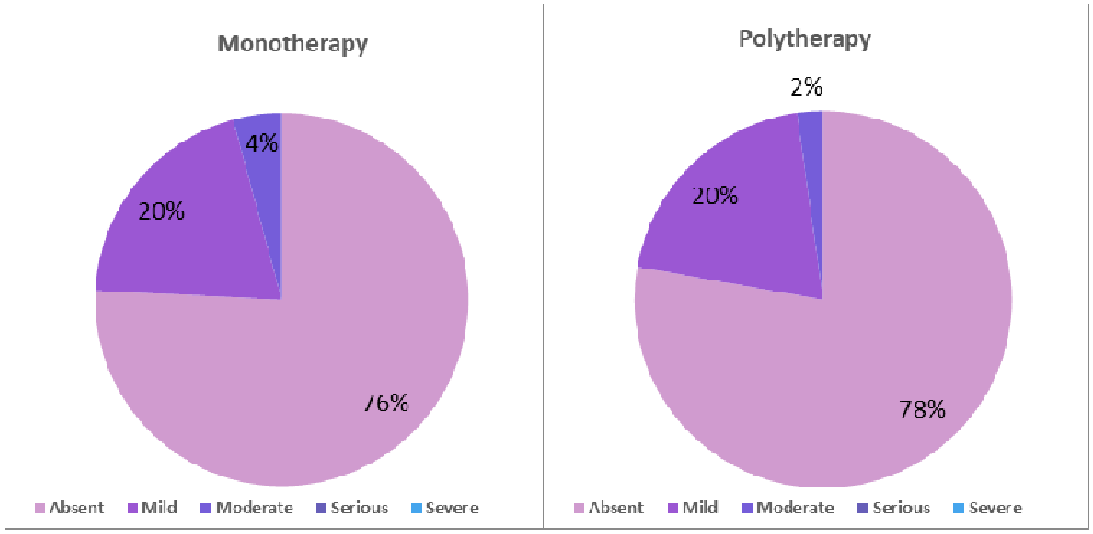


Figure 6: Endometrium thickness – evaluation results at 30 days

6. Vaginal dryness symptoms

medRxiv preprint doi: https://doi.org/10.1101/2023.05.17.23290093; this version posted May 25, 2023. The copyright holder for this preprint (which was not certified by peer review) is the author/funder, who has granted medRxiv a license to display the preprint in perpetuity. It is made available under a CC-BY-NC-ND 4.0 International license .

The results of vaginal dryness symptoms evaluation are shown in supplemental figure 7. The efficacy of the medical device in reducing vaginal dryness was observed in a high proportion of patients, 82% and 80%, respectively.

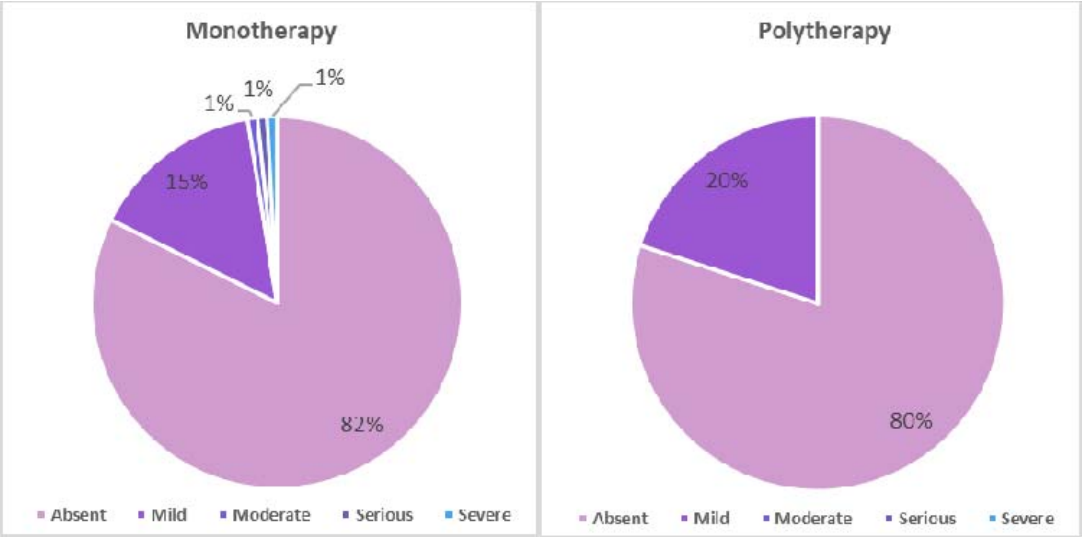


Figure 7: Vaginal dryness symptoms – evaluation results at 30 days

*3.2.2. Degree of satisfaction after using Halova® ovules*

In terms of degree of satisfaction offered, participants in the largest population (94.38% of patients treated with Halova® monotherapy rated the treatment as “Excellent”. Also 85,71% of patients treated with Halova® ovules as polytherapy) rated the device as “Excellent” or “Highly effective”, 14.29% (supplemental figure 8).

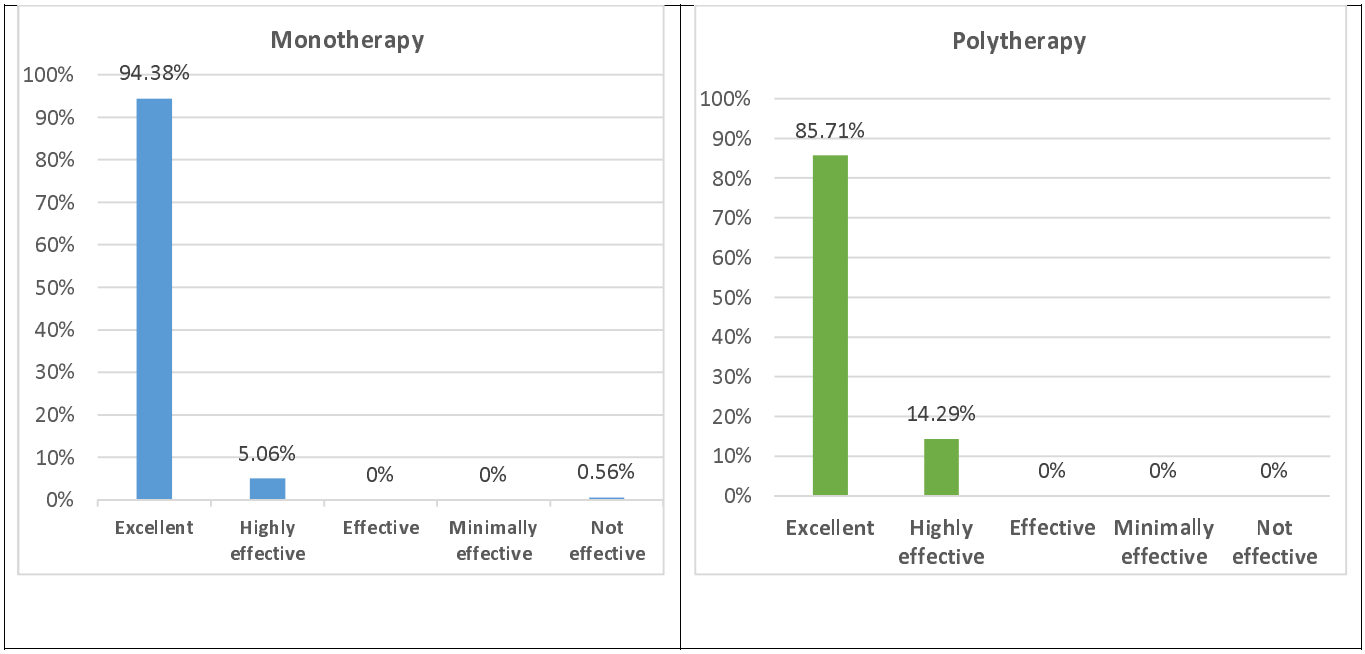

medRxiv preprint doi: https://doi.org/10.1101/2023.05.17.23290093; this version posted May 25, 2023. The copyright holder for this preprint (which was not certified by peer review) is the author/funder, who has granted medRxiv a license to display the preprint in perpetuity. It is made available under a CC-BY-NC-ND 4.0 International license .

Figure 8: Participant Satisfaction Score: Likert Scale

## 4. Discussion

Vaginal atrophy and its main symptoms (vaginal dryness and dyspareunia) are closely related to all domains of female sexuality. Vaginal irritation can be severe and debilitating enough to affect both daily activities but the ability to have pleasurable pain-free sexual intercourse (19). Approximately 40% of women with vaginal atrophy report dyspareunia. Dyspareunia is defined as persistent, recurrent urogenital pain occurring before, during, or after sexual intercourse (or penetration) (5). Sexuality and sexual function is regarded as one of the issues, which can be considered in this regard. During menopause, women will face many problems and complications from the lack of sex hormones. Both healthcare professionals and patients often find it difficult to approach the subject of sexual problems associated with menopause and vulvovaginal atrophy (20). With the administration of Halova® ovules, symptoms of dyspareunia were greatly reduced, thus favoring normal sexual functioning in affected patients.

Halova®'s beneficial effects in reducing vaginal dryness are explained by the local action of sodium hyaluronate. Multiple studies confirmed the advantages of using topical sodium hyaluronate in vaginal dryness since it's a modern, safe and well- tolerated product (21,22). With its highly anionic proprieties, sodium hyaluronate can attract water to swell, create volume and provide structural support, acting as a topical lubricant. Sodium hyaluronate is the salt form of hyaluronic acid, with a smaller molecular structure that increase the stability and resistance to oxidation. The water solubility is associated with better skin and mucosal penetration, leading to better hydration. The mechanical protection of the vaginal endothelium is ensured by its high viscosity. Sodium hyaluronate is used successfully from 1980 in the treatment of various other diseases, such as dry eye, joint diseases, cystitis, atopic dermatitis, cataract extraction, osteoarthritis and as filler for skin wrinkles (23,24). It provides a high safety profile, being previously studies in postmenopausal women.

The estrogenic diminishing activity along with other factors, such as a rise in vaginal pH and alteration of the vaginal microflora led to an increasing susceptibility to urinary tract infections and vaginitis in postmenopausal women but also in sexually active women. Postmenopausal women are therefore at increased risk not only of recurrent urinary tract infections but also of dyspareunia, vaginal irritation, pruritus, pain, and symptoms of urgency, frequency, dysuria, and urinary incontinence (25).

A very interesting aspect in our study is the fact that the medical device Halova® is efficient in maintaining a healthy vaginal pH. The normal vaginal pH level (between 3.8 – 4.5) is very important for its protective role in blocking yeast and bacteria multiplication. Thus, the supportive role of the medical device in preventing vaginal infections is proven on the basis of its effective role in correction of the unbalanced vaginal pH, with 88.79% of patients in single therapy arm and 95.35% in the add-on arm reporting normal vaginal pH.

The claimed therapeutic indications of the device are linked to the treatment of vaginal dryness caused by age or various pathologies or other drug treatments, relief of pain and discomfort during sexual

medRxiv preprint doi: https://doi.org/10.1101/2023.05.17.23290093; this version posted May 25, 2023. The copyright holder for this preprint (which was not certified by peer review) is the author/funder, who has granted medRxiv a license to display the preprint in perpetuity. It is made available under a CC-BY-NC-ND 4.0 International license .

intercourse, balancing of the vaginal flora, treatment of vaginal pH disturbances and boosting the vaginal lubrication. Vitamin E is a key element in stabilizing estrogen levels and can greatly improve menopausal symptoms including hot flashes, irritability, insomnia, dizziness, palpitations, shortness of breath and vaginal dryness. Applied locally, it favors the healing and re-epithelialization processes through its nourishing and moisturizing effect. A recent review conducted by Porterfield and colleagues elaborated on the evidence for vaginal vitamin E efficacy in reducing patient-reported genitourinary symptoms in healthy postmenopausal women compared to placebo or vaginal control therapy. (26)

Particular concerns and controversies are related to the treatment of vaginal atrophy and its symptoms in patients with breast cancer. The increasing usage of aromatase inhibitors in the past few years has led to an increased incidence of vaginal atrophy with a high impact on the quality of life of breast cancer patients (27). The use of a systemic or, respectively, topical hormone therapy is, however, contraindicated for breast cancer patients and thus, Halova® might be an excellent therapeutic alternative in these patients and also in patients in whom local estrogenic treatment remains controversial, such as in uterine cancer, patients with a history of deep vein thrombosis or pulmonary embolism, a history of stroke or myocardial infarction, or a history of blood clotting disorders (28).

## 5. Conclusions

Halova® significantly alleviates the symptoms such as vaginal dryness, dyspareunia and dysuria while restoring the normal pH and thus harnessing the protective features of the vaginal microbiome. Applied once a day for a sequence of 10 consecutive days, Halova® may be a suitable treatment option in vulvovaginal atrophy and urogenital complaints in both women of reproductive age and postmenopausal women. The medical device is proved safe and effective in alleviating most bothersome signs and symptoms of atrophic vaginitis in postmenopausal women, such as dysuria, dyspareunia and vaginal dryness. Halova® might be an excellent therapeutic alternative in patients in whom local estrogenic treatment remains controversial.

The medical device has demonstrated anti-atrophic activity in the genitourinary tract and this has resulted in significantly improved symptoms associated with normal sexual functioning. Future research is needed to confirm its tolerability and performance in extending timeframes and also during pregnancy. Some limitations of this study include the absence of a control group, a short treatment follow-up and the heterogenicity of the sample population.

**Conflict of interest statement:** MDX Research (Ramona Petrita) received a grant support for data management and statistical analysis. The decisions on preparation of the manuscript and decision to submit the article for publication remained with the authors. All the other authors declare no competing interests.

**Funding:** Perfect Care Distribution S.R.L. (https://www.perfectcare.ro/), the study Sponsor, offered the tested medical devices and a partial grant support for data management services. The funder Perfect

medRxiv preprint doi: https://doi.org/10.1101/2023.05.17.23290093; this version posted May 25, 2023. The copyright holder for this preprint (which was not certified by peer review) is the author/funder, who has granted medRxiv a license to display the preprint in perpetuity. It is made available under a CC-BY-NC-ND 4.0 International license .

Care Distribution SRL had no role in the design of the study, or in the collection, analyses, or interpretation of data, in the writing of the manuscript, or in the decision to publish the results.

**References**

1. Goldstein I, Dicks B, Kim NN, Hartzell R. Multidisciplinary Overview of Vaginal Atrophy and Associated Genitourinary Symptoms in Postmenopausal Women. Sexual Medicine. 2013 Dec 1;1(2):44–53.

2. Moral E, Delgado JL, Carmona F, Caballero B, Guillán C, González PM, et al. Genitourinary syndrome of menopause. Prevalence and quality of life in Spanish postmenopausal women. The GENISSE study. Climacteric. 2018 Apr;21(2):167–73.

3. Portman DJ, Gass MLS, Vulvovaginal Atrophy Terminology Consensus Conference Panel. Genitourinary syndrome of menopause: new terminology for vulvovaginal atrophy from the International Society for the Study of Women's Sexual Health and the North American Menopause Society. Menopause. 2014 Oct;21(10):1063–8.

4. Sarmento ACA, Costa APF, Vieira-Baptista P, Giraldo PC, Eleutério J, Gonçalves AK. Genitourinary Syndrome of Menopause: Epidemiology, Physiopathology, Clinical Manifestation and Diagnostic. Frontiers in Reproductive Health [Internet]. 2021 [cited 2023 May 2];3. Available from: https://www.frontiersin.org/articles/10.3389/frph.2021.779398

5. Cagnacci A, Venier M, Xholli A, Paglietti C, Caruso S, ANGEL Study. Female sexuality and vaginal health across the menopausal age. Menopause. 2020 Jan;27(1):14–9.

6. Alvisi S, Gava G, Orsili I, Giacomelli G, Baldassarre M, Seracchioli R, et al. Vaginal Health in Menopausal Women. Medicina (Kaunas). 2019 Sep 20;55(10):615.

7. Gandhi J, Chen A, Dagur G, Suh Y, Smith N, Cali B, et al. Genitourinary syndrome of menopause: an overview of clinical manifestations, pathophysiology, etiology, evaluation, and management. American Journal of Obstetrics & Gynecology. 2016 Dec 1;215(6):704–11.

8. Goncharenko V, Bubnov R, Polivka J, Zubor P, Biringer K, Bielik T, et al. Vaginal dryness: individualised patient profiles, risks and mitigating measures. EPMA J. 2019 Mar;10(1):73–9.

9. Donders GGG, Bellen G, Grinceviciene S, Ruban K, Vieira-Baptista P. Aerobic vaginitis: no longer a stranger. Res Microbiol. 2017 Dec;168(9–10):845–58.

10. Waetjen LE, Crawford SL, Chang PY, Reed BD, Hess R, Avis NE, et al. Factors associated with developing vaginal dryness symptoms in women transitioning through menopause: a longitudinal study. Menopause. 2018 Oct;25(10):1094–104.

11. O'Connell TX, Nathan LS, Satmary WA, Goldstein AT. Non-neoplastic epithelial disorders of the vulva. Am Fam Physician. 2008 Feb 1;77(3):321–6.

12. Palacios S, Mejía A, Neyro JL. Treatment of the genitourinary syndrome of menopause. Climacteric. 2015;18 Suppl 1:23–9.

13. Shifren JL. Genitourinary Syndrome of Menopause. Clinical Obstetrics and Gynecology. 2018 Sep;61(3):508.

medRxiv preprint doi: https://doi.org/10.1101/2023.05.17.23290093; this version posted May 25, 2023. The copyright holder for this preprint (which was not certified by peer review) is the author/funder, who has granted medRxiv a license to display the preprint in perpetuity. It is made available under a CC-BY-NC-ND 4.0 International license .

14. Tersigni C, Di Simone N, Tempestilli E, Cianfrini F, Russo R, Moruzzi MC, et al. Non-hormonal treatment of vulvo-vaginal atrophy-related symptoms in post-menopausal women. J Obstet Gynaecol. 2015;35(8):835–8.

15. Castelo-Branco C, Cancelo MJ, Villero J, Nohales F, Juliá MD. Management of post-menopausal vaginal atrophy and atrophic vaginitis. Maturitas. 2005 Nov 15;52 Suppl 1:S46-52.

16. Potter N, Panay N. Vaginal lubricants and moisturizers: a review into use, efficacy, and safety. Climacteric. 2021 Feb;24(1):19–24.

17. Bleibel B, Nguyen H. Vaginal Atrophy [Internet]. StatPearls [Internet]. StatPearls Publishing; 2022 [cited 2023 Apr 6]. Available from: https://www.ncbi.nlm.nih.gov/books/NBK559297/

18. 14:00-17:00. ISO 14971:2007 [Internet]. ISO. [cited 2022 Oct 14]. Available from: https://www.iso.org/cms/render/live/en/sites/isoorg/contents/data/standard/03/81/38193.html

19. Goldstein I, Alexander JL. Practical Aspects in the Management of Vaginal Atrophy and Sexual Dysfunction in Perimenopausal and Postmenopausal Women. The Journal of Sexual Medicine. 2005 Sep 1;2(Supplement_3):154–65.

20. Heidari M, Ghodusi M, Rezaei P, Kabirian Abyaneh S, Sureshjani EH, Sheikhi RA. Sexual Function and Factors Affecting Menopause: A Systematic Review. J Menopausal Med. 2019 Apr;25(1):15–27.

21. Stute P. Is vaginal hyaluronic acid as effective as vaginal estriol for vaginal dryness relief? Arch Gynecol Obstet. 2013 Dec;288(6):1199–201.

22. Chen J, Geng L, Song X, Li H, Giordan N, Liao Q. Evaluation of the Efficacy and Safety of Hyaluronic Acid Vaginal Gel to Ease Vaginal Dryness: A Multicenter, Randomized, Controlled, Open-Label, Parallel-Group, Clinical Trial. The Journal of Sexual Medicine. 2013 Jun 1;10(6):1575–84.

23. Ling P xue, Liang H, He Y li, Zhang T min. [The application of sodium hyaluronate in joint diseases]. Zhongguo Xiu Fu Chong Jian Wai Ke Za Zhi. 2002 Jan;16(1):1–4.

24. Altman RD. Intra-articular sodium hyaluronate in osteoarthritis of the knee. Semin Arthritis Rheum. 2000 Oct;30(2 Suppl 1):11–8.

25. Cardozo L. Postmenopausal cystitis. BMJ. 1996 Jul 20;313(7050):129.

26. Porterfield L, Wur N, Delgado ZS, Syed F, Song A, Weller SC. Vaginal Vitamin E for Treatment of Genitourinary Syndrome of Menopause: A Systematic Review of Randomized Controlled Trials. J Menopausal Med. 2022 Apr;28(1):9–16.

27. Moegele M, Buchholz S, Seitz S, Lattrich C, Ortmann O. Vaginal Estrogen Therapy for Patients with Breast Cancer. Geburtshilfe Frauenheilkd. 2013 Oct;73(10):1017–22.

28. Tavani A, La Vecchia C. The adverse effects of hormone replacement therapy. Drugs Aging. 1999 May;14(5):347–57.

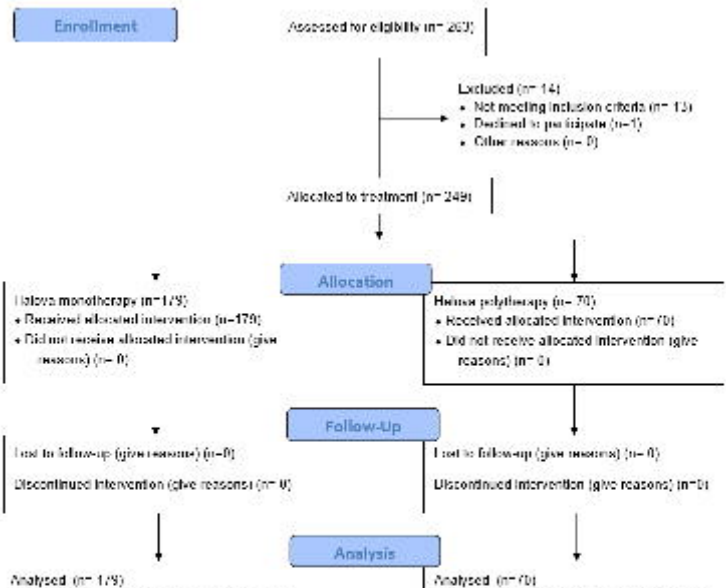
Enrollment
Assessed for eligibility (n= 263)
Excluded (n= 14)
• Not meeting inclusion criteria (n= 13)
• Declined to participate (n=1)
• Other reasons (n= 0)
Allocated to treatment (n= 249)
Allocation
Helixa monotherapy (n= 179)
• Received allocated intervention (n=179)
• Did not receive allocated intervention (give reasons) (n= 0)
Helixa polytherapy (n= 70)
• Received allocated intervention (n= 70)
• Did not receive allocated intervention (give reasons) (n= 0)
Follow-Up
Lost to follow-up (give reasons) (n=0)
Discontinued intervention (give reasons) (n= 0)
Lost to follow-up (give reasons) (n= 0)
Discontinued intervention (give reasons) (n=0)
Analysis
Analysed (n= 179)
• Excluded from analysis (give reasons) (n=0)
Analysed (n= 70)
• Excluded from analysis (give reasons) (n= 0)

medRxiv preprint doi: https://doi.org/10.1101/2023.05.17.23290093; this version posted May 25, 2023. The copyright holder for this preprint (which was not certified by peer review) is the author/funder, who has granted medRxiv a license to display the preprint in perpetuity. It is made available under a CC-BY-NC-ND 4.0 International license .

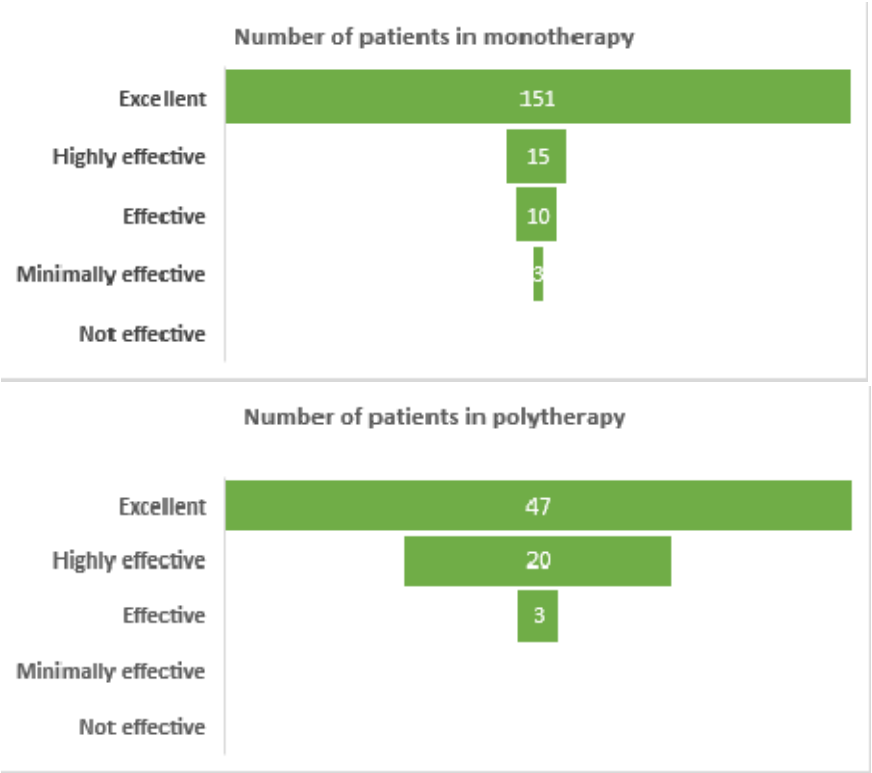


Figure 1. Clinical performance observed at 30 days

medRxiv preprint doi: https://doi.org/10.1101/2023.05.17.23290093; this version posted May 25, 2023. The copyright holder for this preprint (which was not certified by peer review) is the author/funder, who has granted medRxiv a license to display the preprint in perpetuity. It is made available under a CC-BY-NC-ND 4.0 International license .

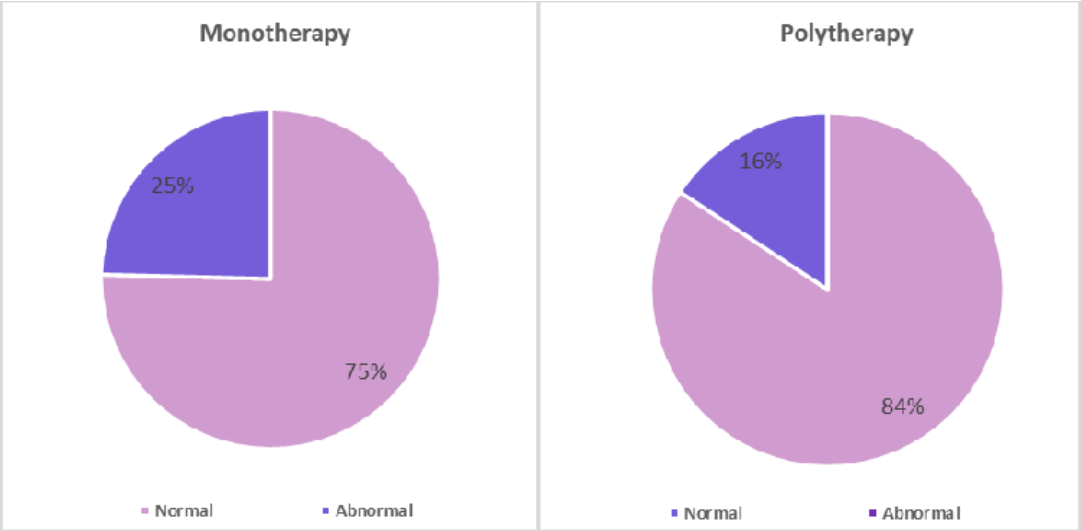


Figure 2. Measurement of the vaginal pH in both arms

medRxiv preprint doi: https://doi.org/10.1101/2023.05.17.23290093; this version posted May 25, 2023. The copyright holder for this preprint **(which was not certified by peer review)** is the author/funder, who has granted medRxiv a license to display the preprint in perpetuity. It is made available under a CC-BY-NC-ND 4.0 International license .

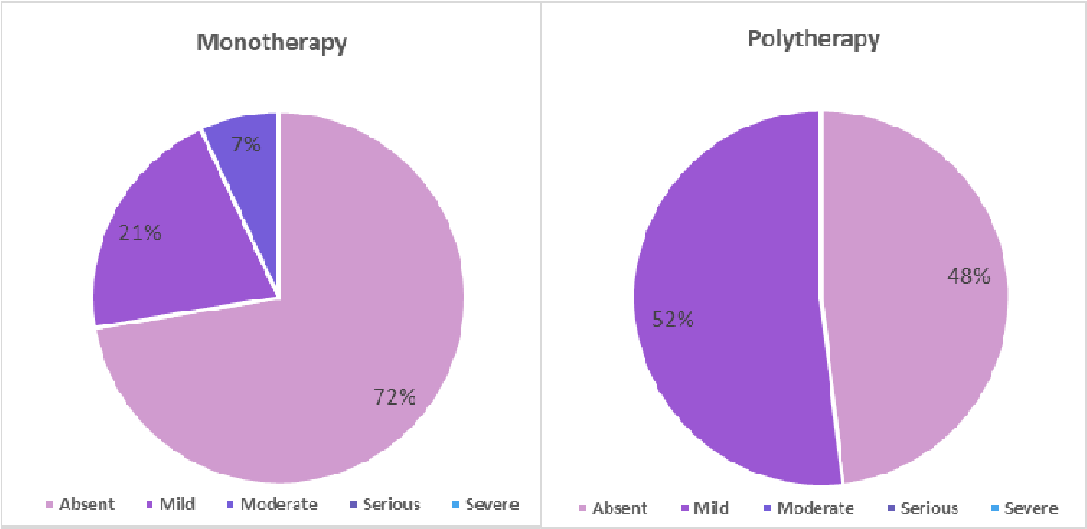


Figure 3: Dyspareunia symptoms – evaluation results at 30 days