

1 **Real-world study of Cerviron[®] vaginal ovules in the treatment of cervical lesions of various**
2 **etiologies**

3 IZABELLA PETRE^{1,2}, DANIELA TEODORA SIRBU³, RAMONA PETRITA⁴, ANDREEA-
4 DENISA TOMA⁵, EMA PETA⁶ AND FLORENTINA DIMCEVICI-POESINA⁶

5
6 ¹Discipline of Obstetrics and Gynecology XII, 'Victor Babes' University of Medicine and Pharmacy, 300041
7 Timisoara; ²University Clinic of Obstetrics and Gynecology, Emergency Clinic Hospital 'Pius Brinzeu', 300226
8 Timisoara; ³Dr Sirbu Daniela Private Practice, 300269 Timisoara; ⁴Biometrics Unit, MDX Research, 300633
9 Timisoara; ⁵Pharmacy Unit of Municipal Hospital 'Dr Karl Diel' Jimbolia, 305400 Jimbolia; ⁶Quality Assurance,
10 Perfect Care Distribution SRL, Bucharest, Romania

11
12 *Correspondence to:* Mrs Ramona Petrita, Biometrics Unit, MDX Research Romania, 1-3 Vasile Loichita Street,
13 300633 Timisoara, Romania; E-mail: ramona.petruta@mdxresearch.eu
14 Dr Izabella Petre, Discipline of Obstetrics and Gynecology XII, 'Victor Babes' University of Medicine and
15 Pharmacy, 2 Eftimie Murgu Square, 300041 Timisoara; E-mail: dr.petreizabella@yahoo.com

16
17 **Abstract.** Cervical lesions can be caused by pathogens, hormonal changes or by cervical injury.
18 The recommended treatment in all cases is excision. Local re-epithelialization therapy should be
19 initiated preoperatively and postoperatively. The present study assessed the post-market
20 performance and tolerability of Cerviron[®] ovules in the treatment and management of cervical
21 lesions postoperatively. The study population included 345 participants aged 20-70 years with
22 either a cervical lesion under treatment or with recent surgical removal of a cervical lesion. The
23 degree of re-epithelialization of the cervical mucosa was improved in 73.17% of the patients
24 evaluated during routine colposcopy exams and 92.73% of patients recorded no bleeding. When
25 adding Cerviron[®] either as monotherapy or in association with other antimicrobials in
26 postoperative care of the cervical ectropion, improved postoperative outcomes such as reduced
27 post-interventional bleeding and a superior quality of healing were observed. The study and its
28 details are registered in www.clinicaltrials.gov under ID NCT05668806.

29 Key words: medical device, cervical lesions, cervical mucosa, vaginal pH, vaginal pain, vaginal bleeding

30 **Introduction**

31 A cervical erosion (or cervical ectropion) can occur for numerous reasons among women of
32 childbearing age (1). It is considered a benign condition caused by pathogens or induced by
33 increased exposure of the cervical epithelium to estrogen. Moreover, cervical erosions can be of
34 traumatic, mechanical etiology, such as intrauterine devices or foreign bodies introduced into the
35 vagina (2). Its prevalence ranges from 17 to 50% (3,4). The presence of ectropion is detected
36 especially after the menarche, during pregnancy or with use of the combined oral contraceptive
37 pill and is very rare in postmenopausal women (5).

38 Epithelialization of the vaginal mucus and cervix is crucial in the management of cervical
39 erosions. Acute inflammation of the cervix as a result from direct infection or trauma translates
40 into several symptoms, such as white to yellow vaginal discharge (predominant symptom caused
41 by the mucus-secreting glandular epithelium), post-coital or intermenstrual bleeding, dysuria,
42 pelvic pain, vulvovaginal irritation and dyspareunia (6). Symptomatic women should be screened
43 for infective agents (7). Cervical ectropion has been associated with both the combined oral
44 contraceptive pill and intrauterine contraceptive devices as highlighted by the study conducted
45 by Wright *et al* (4). Concurrently, a number of studies have highlighted that the use of combined
46 oral contraceptives is highly associated with the development of cervical ectopy, edema and
47 erythema of the ectopic zone (7-9).

48 Pathogens such as streptococci, staphylococci, or enterococci can be promoters of acute
49 inflammation of the cervix and cervical ectropion (10). Cervicitis (inflammation of the cervix) is
50 often asymptomatic and can cause complications of the upper genital tract with ectopia and
51 cervical infection by *Chlamidia trachomatis*, *Neisseria gonorrhoeae*, herpes simplex virus, and
52 cytomegalovirus (11). Some factors involved in the pathogenesis of cervical ectopy involve the
53 action of estrogen (12). Estrogens influence immune and inflammatory processes, by regulating
54 chemokines and chemokine receptors. In a previous study by Straub, the complex processes of
55 inflammation related to estrogen signaling toward immune cell trafficking were studied (13). The
56 T helper 17 cells producing IL-17 are the main T cells responsible for chronic inflammation. The
57 cervical epithelium is highly responsive to estrogen production. Mechanistically, it is considered
58 that estrogens induce apoptosis in cervical cells and also increase gene expression of human
59 papillomavirus-16 and -18, the two genotypes frequently associated with cervical cancer (14).

60 Exposure to high levels of estrogen is also linked to an increased risk of breast cancer (15).
61 Estrogen influences immune and inflammatory processes by modulating the production of pro-
62 inflammatory cytokines, chemokines and other immune mediators. Specifically, estrogen can
63 activate pathways that lead to the production of anti-inflammatory cytokines, such as interleukin-
64 4 (IL-4), and chemokines, such as interferon- γ (IFN- γ) (16). Furthermore, estrogen can inhibit
65 the production of pro-inflammatory mediators such as tumor necrosis factor (TNF) and IL-6.
66 Estrogen can also regulate the expression of chemokine receptors on immune cells, which in turn
67 helps regulate the migration of immune cells to sites of inflammation (17). For example, estrogen
68 can downregulate the expression of the CCR5 receptor, which is involved in the migration of T
69 cells to sites of inflammation. Estrogen can also upregulate the expression of the CXCR4
70 receptor, which is involved in the migration of macrophages and neutrophils to sites of
71 inflammation (18).

72 The presence of endocervical columnar epithelium on the ectocervix favors an increased
73 exposure to infections due to low cell-mediated immunity. In these areas, the subpopulation of T
74 lymphocytes, namely, T helper cells, CD8 cells, and CD1 lymphocytes are reduced in number
75 (19). Therefore, the columnar epithelium cells are more susceptible to infections such as
76 *Chlamydia trachomatis* or *Neisseria gonorrhoeae* (20). Estrogens are capable of markedly
77 altering the responses of host cells to microbes. In adolescence, pregnancy, during hormonal
78 contraception, or during the years of menstruation (mostly in the ovulatory phase), the
79 probability of developing cervical ectopy is very high, and sometimes goes undetected (5).
80 Furthermore, cervical ectopy implies further risks of acquiring sexually-transmitted diseases
81 (gonorrhea, chlamydia and human papilloma virus). In the study conducted by Sanchez *et al* a
82 causal relationship was found between cervical erosion and bacterial vaginosis that alter the
83 mucosal barrier and decrease defense mechanisms of the cervix and vagina (21).

84 An ongoing debate remains of whether ectopy requires a specific treatment. The association
85 between squamous metaplasia and induction of squamous cell carcinoma of the cervix is well
86 known. Moreover, the dysplastic cells are more susceptible to carcinogens (22). Notwithstanding
87 this, according to a recent study conducted by Kleppa *et al*, ectopy may be a biological risk
88 factor for chlamydia infection and for human immunodeficiency virus (HIV) in adolescents and
89 in young women (7).

90 Currently, cryotherapy (cryosurgery) of the cervix is the standard treatment for symptomatic,
91 benign cervical ectropion (23). Cryosurgery improves the cervical mucus characteristics and
92 therefore it is recommended in patients with hostile cervical mucus and ectropion (24). Prior to
93 and after surgery, adjuvant treatments should be promoted with the support of local, re-
94 epithelizing treatments (25). For example, Belfiore *et al* reported the effectiveness of a topical
95 treatment for cervical ectropion with 5 mg of deoxyribonucleic acid (26).

96 Cerviron has a substance content that provides beneficial properties in non-infectious 100
97 vulvovaginitis and cervical erosion. The ovule melts in the vaginal mucosa forming a cream that 101
98 ensures dispersion of the substances contained and acts as a protective barrier with astringent 102
99 effect, favoring the reepithelization of damaged tissue and the restoration of the initial 103
100 colpoecosystem without affecting the Doderlein bacilli. The main mechanism of action of the 104
101 medical device is the dispersion of the substances in the vagina and the formation of a protective 105
102 barrier that accelerates the natural healing process of the damaged epithelium. Performance and
103 safety data on Cerviron[®] vaginal ovules have been reported from multiple sources. Three clinical
104 investigations on Cerviron were reported (NCT04735705, NCT04735718 and NCT05652959
105 available at <https://clinicaltrials.gov/ct2/show/NCT04735705>;
106 <https://clinicaltrials.gov/ct2/show/NCT04735718>; and
107 <https://clinicaltrials.gov/ct2/show/NCT05652959>, respectively) and published articles on
108 Cerviron[®] include the characterization of its utility in the management of cervical uterine
109 fibroids and on vaginal atrophy after surgical treatment and adjuvant radiation therapy for
110 cervical cancer (27,28). However, previous safety data was limited and included only a
111 restricted, homogenous population, including 50 participants in study NCT04735705 and only 27
112 participants in study NCT04735718.

113 Cerviron[®] is a medical device marketed by Perfect Care Distribution in the following
114 countries: Albania, Latvia, Lithuania, Estonia, Kosovo, Montenegro, Romania, Kuwait, and the
115 United Arab Emirates. With a complex composition consisting of three topical pharmaceutical
116 products including hexylresorcinol, collagen and bismuth subgallate, and four phytotherapeutic
117 extracts including *Calendula officinalis*, *Hydrastis canadensis*, *Thymus vulgaris* extract and
118 *Curcuma longa*, it is intended as adjuvant treatment for the management of cervical lesions and
119 vulvovaginitis.

120 **Materials and methods**

121 *Study objectives.* The present study was designed as part of the medical device post-marketing
122 clinical follow-up, involving routine care from a variety of clinical practices. The study includes
123 an open-label, multicentric, non-randomized, single-arm, real-world evidence study design. The
124 data were collected between the 20th of May 2021 and 31st of July 2021.

125 Real-world evidence studies are post-marketing studies bringing valuable information related
126 to the medical devices' safety and performance profiling and a broader understanding of the
127 practice pattern and the clinical outcomes. The rationale of the study was aimed at capturing
128 safety data in a broader, more heterogenous population. Cerviron[®] vaginal ovules have been used
129 with success in the treatment of acute and chronic vulvovaginitis of mechanical etiology, and in
130 cervical lesions of mechanical origin, but with a limited number of study participants
131 (NCT04735705 and NCT04735718). Real-world evidence studies and clinical trials are
132 complementary. The present study is considered a real-world evidence study as it reflects actual
133 clinical aspects with data collected in the context of routine delivery of care, as opposed to data
134 collected within a clinical trial, where study design controls variability in ways that are not
135 representative of real-world care and outcomes.

136 The primary objective was to evaluate the tolerability of Cerviron[®] ovules in the treatment
137 and management of cervical erosions of various etiologies. The secondary objective of this study
138 was the assessment of performance of the medical device by clinical exam and patients' degree
139 of satisfaction related to the use of the medical device.

140 *Study population.* The target population included women aged 20 to 70 years with
141 symptomology associated with cervical ectropion of various etiology such as cervix trauma,
142 postpartum injuries, vaginal infections and cervicitis. A total of 345 women were evaluated. A
143 number of patients were treated with Cerviron[®] ovules as monotherapy (n=210) and other
144 patients were prescribed Cerviron[®] ovules as an adjuvant in therapeutic schemas containing
145 antibiotics, antivirals and/or anti-inflammatory drugs (n=135). Subjects with a previous history
146 of any malignancy, including subjects with vulvar, vaginal, or cervical cancer or with
147 undiagnosed abnormal genital bleeding were excluded.

148 The study involved 30 Romanian specialist physicians as investigators from 16 institutions
149 each treating between 6 and 22 patients. The participating clinical practices and their locations
150 are listed as Table 1. Upon study entry and at 1, 2 and 3 months after the initial visit, participants

151 were interviewed and received visual cervical examinations by colposcopy. At each visit,
 152 participants received a standardized pelvic exam with placement of a speculum and visualization
 153 of the cervix.

Institution	City, Country (Romania)
Clinical Hospital ‘Dr Ion Cantacuzino’ Bucharest	Bucharest
Hospital MedLife Humanitas Cluj-Napoca	Cluj-Napoca
Medical office of Dr Saleh K. Majed	Craiova
Medical office of Dr Surpanelu Oana	Iasi
Natisan Medical Center	Pitesti
Gynecological office of Dr Rădulescu G. Mihaela Elena	Râmnicu Vâlcea
Medical office of Dr. Popescu	Sibiu
MediBlue Medical Clinic	Iasi
SC Pan Medical SRL	Sibiu
Medical clinic of Dr. Cioata Ionel Trifon	Timisoara
iMED Clinic	Sibiu
Tulcea County Emergency Hospital	Tulcea
Bradmed SRL	Targu Jiu
Gynecological office of Dr Ioana Trotea Targu Jiu	Targu Jiu
Medical office of Obstetrics and Gynecology of Dr Sirbu Daniela SRL	Timisoara
Dr Todorut Florina	Timisoara
Total sites, 16.	

154

155 Table 1. Clinical practices and their locations

156 Prospective data were collected from each patient, such as initial diagnosis, colposcopy
 157 examination results, re-epithelialization degree, vaginal pH value, vaginal symptoms, any
 158 worsening symptoms and adverse events.

159 *Ethical and regulatory aspects of the study.* Written consent for study participation was collected
 160 from all patients. General Data Protection Regulation (GDPR) consent forms were collected
 161 from all patients. Due to legal considerations (GDPR directive effective from 21 May 2018 in all
 162 European Union countries), patients or their legal representatives have an absolute right to

163 request that their data be removed from the study database. A Notified Body (ENTE
164 CERTIFICAZIONE MACCHINE SRL) reviewed the post marketing clinical follow-up plan,
165 including ethical considerations. As this is a post-marketing clinical follow-up study, an Ethics
166 Committee approval was not required, as per the regulations described below.

167 The study was conducted in accordance with the Guide to medical devices: ‘Post-market
168 clinical follow-up studies’
169 ([https://www.imdrf.org/sites/default/files/docs/imdrf/final/technical/imdrf-tech-210325-
170 wng65.pdf](https://www.imdrf.org/sites/default/files/docs/imdrf/final/technical/imdrf-tech-210325-wng65.pdf)) and the International Society for Pharmacoepidemiology (ISPE; 2015) Guidelines
171 for ‘Good pharmacoepidemiology practices (GPP)’
172 (<https://www.pharmacoepi.org/resources/policies/guidelines-08027/>)

173 The collected data and study procedures were conducted in accordance with the ethical
174 principles that have their origin in the Declaration of Helsinki.

175 The study followed the definition of the non-interventional (observational) study provided by
176 the Guide to Good Pharmacovigilance Practices (GVP; 2017): Module VIII - Post-authorization
177 safety studies ([https://www.ema.europa.eu/en/documents/scientific-guideline/guideline-good-
178 pharmacovigilance-practices-gvp-module-viii-post-authorisation-safety-studies-rev-3_en.pdf](https://www.ema.europa.eu/en/documents/scientific-guideline/guideline-good-pharmacovigilance-practices-gvp-module-viii-post-authorisation-safety-studies-rev-3_en.pdf)).

179 The study followed the nature of the non-interventional (observational) studies mentioned in the
180 ICH Harmonized Tripartite Guide Pharmacovigilance Planning E2E (ICH, 2004;
181 https://database.ich.org/sites/default/files/E2E_Guideline.pdf).

182 Revision risk analysis was carried out in accordance with the medical device regulation,
183 available from: [https://www.anm.ro/en/dispozitive-medicale/regulamentele-europene-privind-
184 dispozitivele-medicale](https://www.anm.ro/en/dispozitive-medicale/regulamentele-europene-privind-dispozitivele-medicale). Data were stored according to Annex E of ISO 14155:2020
185 (<https://www.iso.org/standard/>). The study and its details are registered in www.clinicaltrials.gov
186 under ID NCT05668806.

187 *Statistical consideration.* All statistical analyses were performed using the Excel Analysis
188 ToolPak, version 16.69.1, from Microsoft. $P < 0.05$ was considered to indicate a statistically
189 significant difference.

190 The quality and completeness of the collected data were preliminarily assessed in comparison
191 with data analysis. No study participant was involved in any violation of inclusion/exclusion
192 criteria. To examine the treatment significance over time, Fisher’s exact test was performed for

193 categorical variables, and Mann-Whitney U test was employed to perform comparative analysis
194 for variables non-normally distributed.

195 **Results**

196 *Range of gynecological conditions and medical history of selected patients.* The selected patients
197 presented with various gynecological conditions consistent with the instructions for the use of
198 the medical device. Some patients presented with other conditions with similar symptoms. As the
199 evaluation of the performance of the device was a secondary objective, other conditions that
200 would enable further investigations for expanding the use of the medical device were also
201 selected (Table 2).

Gynecological condition	Number of patients (n=345) Age, 20-70 years
Anexitis	4
Atypical squamous cells cannot exclude high grade squamous intraepithelial lesion	5
Atypical squamous cells of undetermined significance	39
Cervical dysplasia	7
Cervical ectropion	47
Cervicitis	59
Dyspareunia	6
Endocervicitis	8
Endocervicosis	11
Exocervicitis	61
Low-grade squamous intraepithelial lesions	6
Metroanexitis	2
Negative for intraepithelial lesion or malignancy	2
Ovarian cyst	2
Post Conization	10
Uterine fibroids	1
Uterus filaments	1
Vaginal atrophy	2
Vaginal polyps	1
Vaginal prolapse	1
Vulvovaginitis	70

202

203 Table 2. Medical history of selected patients

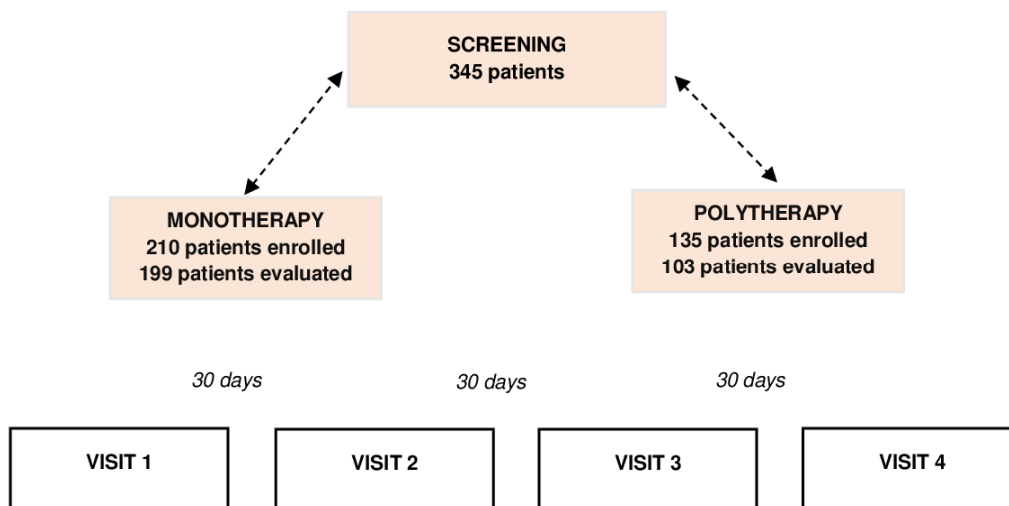
204 Subjects were followed undergoing treatment with Cerviron[®] vaginal ovules for ~3 months.

205 Each enrolled subject visited the clinic four times, at 30-day intervals each. The study visit

206 scheme is listed in figure 1. In the monotherapy group, 11 patients (5.23%) were considered

207 dropouts due to the fact that they did not attend all the study visits and could not be evaluated. In

208 the polytherapy group, 32 patients (23.7%) were considered dropouts (figure 1).



209

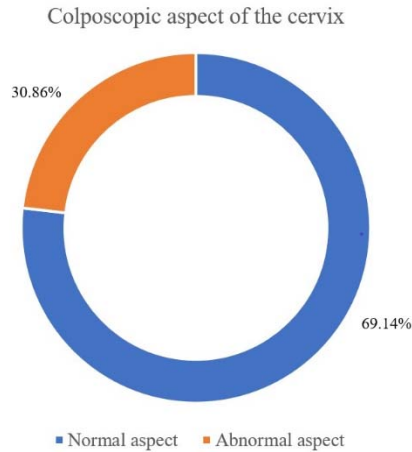
210 Figure 1. Schematic diagram for the present study.

211 *Primary objectives.* The study primary objective was to assess the tolerability of the medical
 212 device by the number of possible adverse reactions observed during the treatment. In one patient
 213 treated exclusively with Cerviron[®] ovules, during the routine gynecological examination one
 214 adverse reaction was noted, which was erythema. The erythema was followed by itching and
 215 abnormal vaginal discharge. The investigators determined that this was not related to treatment
 216 with the medical device. At the following visit, the reaction was absent.

217 Two other patients received combined treatment with antibiotics and Cerviron[®] ovules. After
 218 30 days, both patients reported an adverse reaction of itching and erythema. Investigators
 219 determined that the symptoms were consistent with the initial diagnosis. After 60 days, these
 220 reactions were absent in both patients. All the aforementioned incidents were linked to
 221 preexisting conditions and the investigators decided that they must not be regarded as adverse
 222 reactions to the medical device Cerviron[®].

223 *Secondary objectives*

224 *Clinical performance assessed by the investigator by colposcopy.* A significant proportion of
 225 69.14% patients were rated with the indicator ‘normal aspect’ during colposcopy, as shown in
 226 figure 2.



227

228 Figure 2. Clinical performance assessed by the investigator by colposcopy

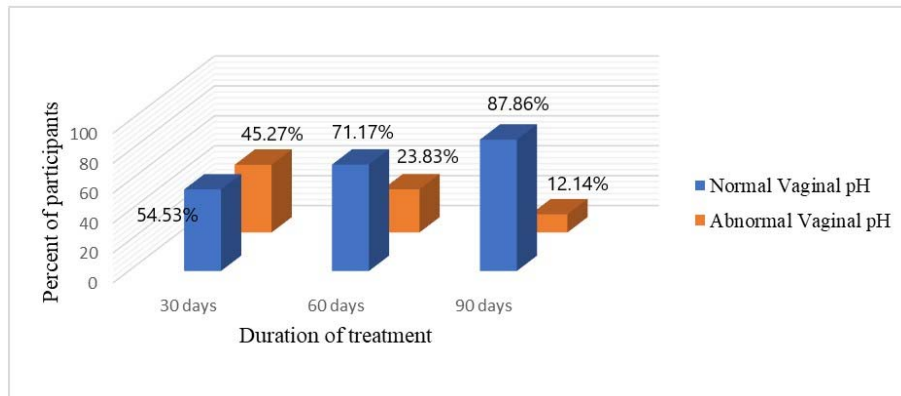
229 *Re-epithelialization degree of the cervical mucosa by gynecological examination.* For only 302
 230 patients out of 345, medical records evaluating the degree of epithelialization of the cervical
 231 mucosa were available. At the initial visit, 302 participants were assessed, of which 3.64% were
 232 rated with ‘complete epithelization’, 40.40% were rated with degree of ‘partial re-
 233 epithelialization’ and 55,96% were rated with ‘absent, ulcerations present’. At 30 days, 47.68%
 234 of the 302 women assessed, had a favorable degree of re-epithelialization, with only 4.30% rated
 235 as ‘absent, ulcerations present’. After 3 months, 73.17% of the 287 patients were rated with
 236 ‘complete epithelization’, as shown in table 3.

Degree of re-epithelialization	Initial evaluation	At 30 days	At 90 days
Absent	169 (55.96%)	13 (4.30%)	6 (2.09%)
Partial	122 (40.40%)	145 (48.01%)	71 (24.74%)
Complete	11 (3.64%)	144 (47.68%)	210 (73.17%)
Total (N)	302	302	287

237

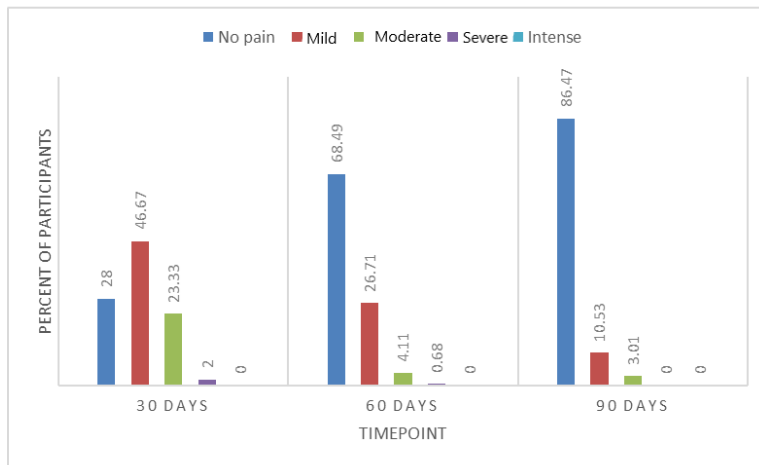
238 Table 3. Degree of re-epithelization at initial evaluation, 30 and 90 days.

239 *Vaginal pH level evaluation.* It was observed that following a 3-month treatment with
 240 Cerviron®, 87.86% of the patients presented with a normal pH, as revealed in figure 3.



241 Figure 3. Changes in vaginal pH throughout the study (90 days).
 242

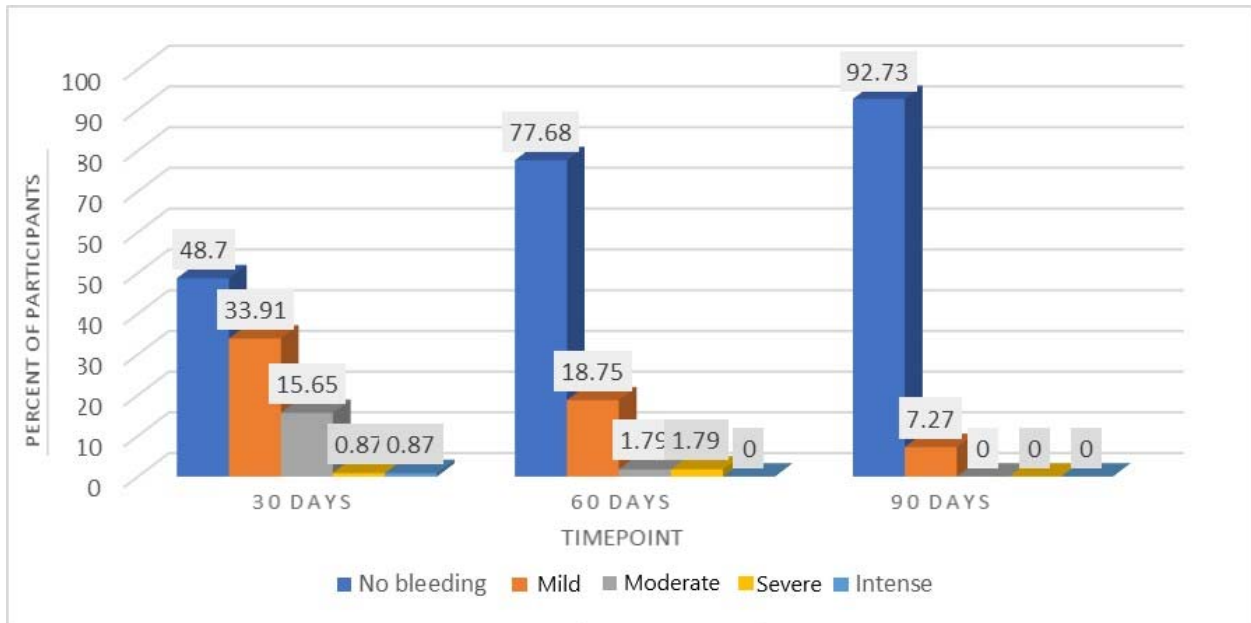
243 *Evaluation of the level of pain.* Of the total number (n=302) of patients examined at visit 1,
 244 46.67% reported mild pain levels and 28.00% had no pain at all. At the second visit, 68.49% of
 245 the population (207) rated pain severity as no pain or mild severity in 26.71%. A very high
 246 proportion (86.47%) was pain free at the last visit after 3 months of treatment with Cerviron® (as
 247 shown in figure 4). Figure 4 also provides the corresponding data related to pain level across the
 248 treatment period.



249 Figure 4. Evaluation of pain level between the study visits (90 days).
 250

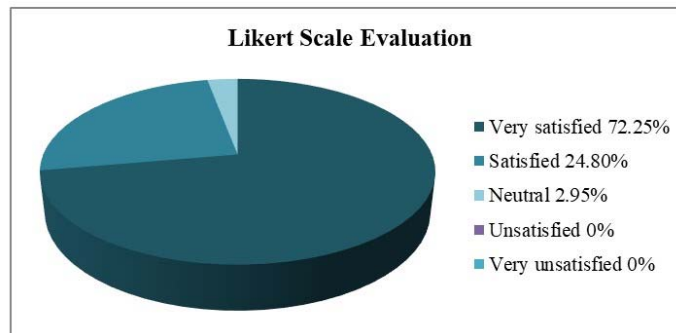
251 *Evaluation of the level of vaginal bleeding.* At the first visit, 302 women included in the study
 252 were evaluated, of whom 48.70% reported no bleeding observed after treatment with Cerviron®
 253 and 33.91% reported low amounts of vaginal bleeding. The efficacy of medical device was more
 254 clearly observed at visit 2, where 77.68% of patients experienced no bleeding at all and 1.79%

255 experienced moderate or severe bleeding. After 3 months of treatment, this improvement was
 256 noteworthy when 92.73% of patients reported no bleeding and only 7.27% of patients reported a
 257 mild level of bleeding, as observed in figure 5.



258
 259 Figure 5. Evaluation of the level of vaginal bleeding throughout the study (90 days).

260 *Degree of satisfaction after using Cerviron® ovules.* In terms of degree of satisfaction offered,
 261 participants in the largest population (72.25%) were reported to be ‘very satisfied’ with the
 262 medical device. The degree of satisfaction was measured by a 5-point Likert scale, as revealed in
 263 figure 6. (30).



264
 265 Figure 6. Likert Scale evaluation at the end of the study.

266 **Discussion**

267 A very important aspect that influences the management of cervical ectopy is age. Cervical
268 ectopy is predominant in young adolescents, with a prevalence of up to 80% in sexually active
269 adolescents. (31) However, factors associated with the evolution and devolution of cervical
270 ectopy are diverse and mechanisms have yet to be elucidated. Since ectopy is observed
271 frequently in adolescent girls and pregnant women, it may vary in response to hormonal
272 fluctuations observed in pregnancy and during contraception with combined oral contraceptives
273 (32). Screening for *Chlamydia trachomatis* and *Neisseria gonorrhoeae* can prevent a range of
274 gynecological conditions, such as urethritis, cervicitis, cervical erosions (33). Infection in the
275 lower genital tract can result in upper genital tract complications, such as pelvic inflammatory
276 diseases, ectopic pregnancy, chronic pelvic pain, and infertility in asymptomatic women, and
277 transmission of infection during pregnancy and labor (34).

278 Cryotherapy (cryosurgery) of the cervix is an effective treatment for symptomatic cervical
279 ectropion (35). Other surgical techniques have been applied for ablation of the squamocolumnar
280 junction. Cauterization has been applied for this purpose since 1920, but it involves additional
281 risks, such as burning lesions if the safeguard plate is not located correctly (36). Some
282 specialists even consider the cervical ectropion as a normal finding that does not require
283 treatment despite the red and inflamed appearance of the cervix. However, cervical ectropion is
284 considered as one of the most common types of chronic cervicitis worldwide (37). Topical
285 treatments for cervical ectropion, including cervical painting with gentian violet paint or
286 microwave tissue coagulation, are still widely used (4). Although the debate is still ongoing, a
287 harmonized treatment strategy would reduce complications of cervical ectropion, such as
288 developing abnormal metaplasia and/or vaginal infection. Applying an intervention to treat
289 cervical ectopy is recommended, especially when considering taking preventive action against
290 cervical cancer. Ectopic cells are modified over time by squamous metaplasia and
291 epithelialization, cervical infection with *Neisseria gonorrhoea* or *Chlamydia trachomatis*, low pH
292 values or trauma (38). Cerviron[®] appears to have a very potent action in rebalancing the vaginal
293 pH. In a previous clinical investigation, NCT04735705, vaginal pH values measured over 90
294 days showed that Cerviron[®] restores altered vaginal pH. The difference in vaginal pH values
295 between baseline versus 90 days, at a 5% significance level was statistically significant (P<0.05).

296 A literature review conducted by Machado *et al* indicated that treatment can be used to
297 relieve occasional symptoms associated with ectopy, but does not support routine treatment for
298 ectopy (12).

299 By contrast, a study conducted by Soares *et al*, showed a positive association between
300 cervical ectopy and human papillomavirus, HIV, bacterial vaginosis, cervical epithelial atypia,
301 postcoital bleeding, and desquamative inflammatory vaginitis (39). Recognition of cervical
302 ectopy should alert the clinician to the possibility of a genital chlamydia infection. Opportunistic
303 screening for chlamydia in young people should be offered to reduce the prevalence of infection
304 and its sequelae. *Chlamydia trachomatis* is the most common bacterial sexually transmitted
305 disease. In women, chlamydial infection usually presents as cervicitis, which can lead to up to 30
306 to 50% of pelvic inflammatory disease episodes. Pelvic inflammatory disease has significant
307 reproductive sequelae, such as tubal infertility and ectopic pregnancy (40).

308 The main mechanism of action of the medical device is the dispersion of the substances in
309 the vagina and the formation of a protective barrier that accelerates the natural healing process
310 of the damaged epithelium. The effect of the medical device is obtained due to the presence of
311 the Bismuth subgallate and vegetable collagen. Bismuth subgallate is an insoluble solution, with
312 a very low bio-availability which will create a physical barrier over the affected area of the
313 vaginal mucosa and therefore will not allow oxygen and pathogens to come in contact with it. In
314 this way, the substances create the premises that allow the damaged tissue to heal naturally. The
315 role of exogenous collagen is to be a "sacrificial substrate" in order to reduce excess
316 metalloproteins that delay wound healing and to regulate the healing of the damaged tissue (14,
317 40-43). As such, Cerviron® supportive therapy may be prescribed in sexually active patients for
318 at least 1-3 months, during 10-15 consecutive days, to prevent these infections.

319 The findings in the present study revealed that a 90-day treatment (3 treatment sessions of 30
320 days each) with Cerviron vaginal ovules was beneficial in providing a complete degree of
321 cervical epithelialization and reduced the multitude of the vaginal symptoms, including bleeding,
322 inflammation, malodor, dysuria, dyspareunia, pain and leukorrhea. This result is consistent with
323 previous clinical studies that included the same medical device, NCT04735705 and
324 NCT04735718 (46).

325 In conclusion, the findings of the present study revealed that administration of Cerviron®
326 vaginal ovules provided a complete degree of epithelization in majority of patients attending a

327 90-days treatment. Moreover, subjects presenting a high grade of ulceration at the baseline visit,
328 following treatment with Cerviron[®] presented a complete degree of epithelization. Cerviron[®]
329 ovules are an exceptional adjuvant for acceleration of healing of cervical erosions. They favor
330 the re-epithelialization of the damaged tissue and restoration of the initial colpo-ecosystem. Their
331 topical application was observed to be effective in reducing unpleasant symptoms such as
332 vaginal discharge, pelvic pain, and vaginal bleeding. In terms of adverse events, the medical
333 device is considered safe. The only contraindication to Cerviron[®] ovules has been determined as
334 hypersensitivity to the active substance or to any of the excipients within the medical device.

335

336 **Acknowledgements**

337 We would like to thank Mrs Florentina Liliana Calancea (MDX Research, Timisoara, Romania)
338 for medical writing and Mr Alexandru Pinta (Labcorp Austria GmbH, Vienna Austria) for
339 support in data management and statistical analysis.

340 **Funding**

341 Perfect Care Distribution SRL (<https://www.perfectcare.ro/>), the study sponsor, offered the tested
342 medical devices and a partial grant support.

343 **Availability of data and materials**

344 The data that support the findings of this study are available from the corresponding author upon
345 reasonable request.

346 **Authors' contributions**

347 IP, RP and ADT were involved in the study design, methodology and original draft preparation.
348 IP and DTS performed the data collection and data analysis. RP, ADT and IP were involved in
349 analysis and interpretation of data. EP and FD-P were involved in manuscript review and editing.
350 IP, DTS and ADT participated in the interpretation of the study results. FD-P and EP confirm the
351 authenticity of all the raw data. All authors approved the final version of the manuscript to be
352 published.

353 **Ethics approval and consent to participate**

354 Only participants that voluntarily provided their written consent to the collection of their study
355 data were included. The collected data and study procedures were conducted in accordance with

356 the ethical principles that have their origin in the Declaration of Helsinki. Ethics committee/IRB
357 of Comisia Nationala de Bioetica a Medicamentului si a Dispozitivelor Medicale (CNBMDM)
358 waived the ethical approval for this work, according to the European Medical Device Regulation
359 MDR 2017/745, concerning data collected in the post-marketing clinical follow-up plan for
360 medical devices, Annex XIV, part B.

361 **Patient consent for publication**

362 Not applicable.

363 **Competing interests**

364 FD-P and EP are employed at Perfect Care Distribution SRL. RP and MDX Research, as CRO
365 provided services in another similar study. All other authors declare no conflicts. The funder
366 Perfect Care Distribution SRL had no role in the design of the study, or in the collection,
367 analyses, or interpretation of data, or in the writing of the manuscript, or in the decision to
368 publish the results.

369 **References**

- 370 1. Wildenberg JC, Yam BL, Langer JE, Jones LP. US of the Nongravid Cervix with
371 Multimodality Imaging Correlation: Normal Appearance, Pathologic Conditions, and
372 Diagnostic Pitfalls. *Radiographics*. 2016 Apr;36(2):596–617.
- 373 2. Ferenczy A. Benign Lesions of the Cervix. In: Blaustein A, editor. *Pathology of the Female*
374 *Genital Tract* [Internet]. New York, NY: Springer; 1977 [cited 2022 Nov 22]. p. 124–42.
375 Available from: https://doi.org/10.1007/978-1-4757-6143-6_6
- 376 3. Kuhn L, Denny L, Pollack AE, Wright TC. Prevalence of visible disruption of cervical
377 epithelium and cervical ectopy in African women using Depo-Provera. *Contraception*. 1999
378 Jun;59(6):363–7.
- 379 4. Wright KO, Mohammed AS, Salisu-Olatunji O, Kuyinu YA. Cervical Ectropion and Intra-
380 Uterine Contraceptive Device (IUCD): a five-year retrospective study of family planning
381 clients of a tertiary health institution in Lagos Nigeria. *BMC Res Notes*. 2014 Dec 23;7:946.
- 382 5. Aggarwal P, Ben Amor A. Cervical Ectropion. In: *StatPearls* [Internet]. Treasure Island (FL):
383 StatPearls Publishing; 2023 [cited 2023 Mar 22]. Available from:
384 <http://www.ncbi.nlm.nih.gov/books/NBK560709/>
- 385 6. Mitchell L, King M, Brillhart H, Goldstein A. Cervical Ectropion May Be a Cause of
386 Desquamative Inflammatory Vaginitis. *Sex Med*. 2017 Sep;5(3):e212–4.

- 387 7. Kleppa E, Holmen SD, Lillebø K, Kjetland EF, Gundersen SG, Taylor M, et al. Cervical
388 ectopy: associations with sexually transmitted infections and HIV. A cross-sectional study of
389 high school students in rural South Africa. *Sex Transm Infect.* 2015 Mar;91(2):124–9.
- 390 8. Goldacre MJ, Loudon N, Watt B, Grant G, Loudon JD, McPherson K, et al. Epidemiology
391 and clinical significance of cervical erosion in women attending a family planning clinic. *Br*
392 *Med J.* 1978 Mar 25;1(6115):748–50.
- 393 9. Dugas LR, Lie L, Plange-Rhule J, Bedu-Addo K, Bovet P, Lambert EV, et al. Gut microbiota,
394 short chain fatty acids, and obesity across the epidemiologic transition: the METS-
395 Microbiome study protocol. *BMC Public Health.* 2018 Aug 6;18(1):978.
- 396 10. Critchlow CW, Wölner-Hanssen P, Eschenbach DA, Kiviat NB, Koutsky LA, Stevens
397 CE, et al. Determinants of cervical ectopia and of cervicitis: age, oral contraception, specific
398 cervical infection, smoking, and douching. *Am J Obstet Gynecol.* 1995 Aug;173(2):534–43.
- 399 11. Ortiz-de la Tabla V, Gutiérrez F. Cervicitis: Etiology, diagnosis and treatment. *Enferm*
400 *Infec Microbiol Clin (Engl Ed).* 2019 Dec;37(10):661–7.
- 401 12. Machado Junior LC, Dalmaso ASW, Carvalho HB de. Evidence for benefits from
402 treating cervical ectopy: literature review. *Sao Paulo Med J.* 2008 Mar;126:132–9.
- 403 13. Straub RH. The Complex Role of Estrogens in Inflammation. *Endocrine Reviews.* 2007
404 Aug 1;28(5):521–74.
- 405 14. Curcumin counteracts the proliferative effect of estradiol and induces apoptosis in
406 cervical cancer cells | SpringerLink [Internet]. [cited 2023 Feb 14]. Available from:
407 <https://link.springer.com/article/10.1007/s11010-010-0606-3>
- 408 15. Yue W, Wang JP, Li Y, Fan P, Liu G, Zhang N, et al. Effects of estrogen on breast cancer
409 development: role of estrogen receptor independent mechanisms. *Int J Cancer.* 2010 Oct
410 15;127(8):1748–57.
- 411 16. Kassi E, Moutsatsou P. Estrogen Receptor Signaling and Its Relationship to Cytokines in
412 Systemic Lupus Erythematosus. *J Biomed Biotechnol.* 2010;2010:317452.
- 413 17. Chakraborty B, Byemerwa J, Krebs T, Lim F, Chang CY, McDonnell DP. Estrogen
414 Receptor Signaling in the Immune System. *Endocrine Reviews.* 2023 Feb 1;44(1):117–41.
- 415 18. Rodriguez-Lara V, Peña-Mirabal E, Baez-Saldaña R, Esparza-Silva AL, García-Zepeda
416 E, Cerbon Cervantes MA, et al. Estrogen receptor beta and CXCR4/CXCL12 expression:
417 differences by sex and hormonal status in lung adenocarcinoma. *Arch Med Res.* 2014
418 Feb;45(2):158–69.
- 419 19. De Luca Brunori I, Facchini V, Filippeschi M, Battini L, Giusti G, Romani L, et al. Cell-
420 mediated immunity in the course of cervical ectropion. *Clin Exp Obstet Gynecol.*
421 1994;21(2):105–7.

- 422 20. Wang LC, Yu Q, Edwards V, Lin B, Qiu J, Turner JR, et al. *Neisseria gonorrhoeae*
423 infects the human endocervix by activating non-muscle myosin II-mediated epithelial
424 exfoliation. *PLoS Pathog.* 2017 Apr 13;13(4):e1006269.
- 425 21. A S, A R, F C, S O. Cervical erosion as result of infectious vaginitis. *European Journal of*
426 *Experimental Biology.* 2(5):0–0.
- 427 22. Çekmez Y, Şanlıkan F, Göçmen A, Vural A, Türkmen SB. Is Cryotherapy Friend or Foe
428 for Symptomatic Cervical Ectopy? *MPP.* 2016;25(1):8–11.
- 429 23. Yildiz S, Alay I, Eren E, Karaca I, Gultekin G, Kaya C, et al. The impact of cryotherapy
430 for symptomatic cervical ectropion on female sexual function and quality of life. *J Obstet*
431 *Gynaecol.* 2021 Jul;41(5):815–20.
- 432 24. Baram A, Paz GF, Peyser MR, Schachter A, Homonnai ZT. Treatment of cervical
433 ectropion by cryosurgery: effect on cervical mucus characteristics. *Fertil Steril.* 1985
434 Jan;43(1):86–9.
- 435 25. Zhu T, Chen Z, Xia Q, Jiang S, Jin Q, Farahani MRD, et al. A suppository for treating
436 cervical erosion and its preparation method. *Clin Exp Obstet Gynecol.* 2013;40(3):361–6.
- 437 26. Belfiore P, Costa E, De Cantis S, Vassallo R, Marino A. Effectiveness and persistence of
438 a topical treatment for cervical ectropion with deoxyribonucleic acid. *Minerva Ginecol.* 2005
439 Aug;57(4):461–6.
- 440 27. Bacalbasa N, Balescu IC. 2022-RA-462-ESGO The effects of Cerviron on vaginal
441 atrophy after surgically treated and adjuvant radiation therapy for cervical cancer.
442 *International Journal of Gynecologic Cancer* [Internet]. 2022 Oct 1 [cited 2023 Jan
443 25];32(Suppl 2). Available from: https://ijgc.bmj.com/content/32/Suppl_2/A391.1
- 444 28. Bacalbasa N, Balescu I, Aloul A, Bohiltea R, Socea B, Ursut B, et al. The role of topic
445 vaginal products in posthysterectomy vaginal atrophy. *Romanian Medical Journal.* 2021 Oct
446 1;LXVIII:344–6.
- 447 29. 14:00-17:00. ISO 14971:2007 [Internet]. ISO. [cited 2022 Oct 14]. Available from:
448 <https://www.iso.org/cms/render/live/en/sites/isoorg/contents/data/standard/03/81/38193.html>
- 449 30. Robinson J. Likert Scale. In: Michalos AC, editor. *Encyclopedia of Quality of Life and*
450 *Well-Being Research* [Internet]. Dordrecht: Springer Netherlands; 2014 [cited 2023 Mar 22].
451 p. 3620–1. Available from: https://doi.org/10.1007/978-94-007-0753-5_1654
- 452 31. Bright PL, Turner AN, Morrison CS, Wong EL, Kwok C, Yacobson I, et al. Hormonal
453 contraception and area of cervical ectopy: a longitudinal assessment. *Contraception.* 2011
454 Nov;84(5):512.
- 455 32. Bright PL, Turner AN, Morrison CS, Wong EL, Kwok C, Yacobson I, et al. Hormonal
456 contraception and area of cervical ectopy: a longitudinal assessment. *Contraception.* 2011
457 Nov;84(5):512–9.

- 458 33. Pillay J, Wingert A, MacGregor T, Gates M, Vandermeer B, Hartling L. Screening for
459 chlamydia and/or gonorrhea in primary health care: systematic reviews on effectiveness and
460 patient preferences. *Syst Rev*. 2021 Apr 19;10:118.
- 461 34. Senn T. Sexually Transmitted Diseases (STDs). In: Gellman MD, Turner JR, editors.
462 *Encyclopedia of Behavioral Medicine* [Internet]. New York, NY: Springer; 2013 [cited 2022
463 Nov 22]. p. 1782–4. Available from: https://doi.org/10.1007/978-1-4419-1005-9_671
- 464 35. Agah J, Sharifzadeh M, Hosseinzadeh A. Cryotherapy as a Method for Relieving
465 Symptoms of Cervical Ectopy: A Randomized Clinical Trial. *Oman Med J*. 2019
466 Jul;34(4):322–6.
- 467 36. Chen J, Zhou D, Liu Y, Peng J, Li C, Chen W, et al. A comparison between ultrasound
468 therapy and laser therapy for symptomatic cervical ectopy. *Ultrasound Med Biol*. 2008
469 Nov;34(11):1770–4.
- 470 37. Liu Y, Yang K, Wu T, Roberts H, Li J, Tian J, et al. Microwave therapy for cervical
471 ectropion. *Cochrane Database Syst Rev*. 2007 Oct 17;2007(4):CD006227.
- 472 38. Machado Junior LC, Dalmaso ASW, Carvalho HB de. Evidence for benefits from
473 treating cervical ectopy: literature review. *Sao Paulo Med J*. 2008 Mar 6;126(2):132–9.
- 474 39. Soares LC, Braz FLTA, Araújo AR, Oliveira MAP. Association of Sexually Transmitted
475 Diseases With Cervical Ectopy: A Systematic Review. *Sex Transm Dis*. 2019 Jul;46(7):452–
476 7.
- 477 40. Jacobson DL, Peralta L, Graham NMH, Zenilman J. Histologic Development of Cervical
478 Ectopy: Relationship to Reproductive Hormones. *Sexually Transmitted Diseases*. 2000
479 May;27(5):252.
- 480 41. Tramontina VA, Machado MAN, Nogueira Filho G da R, Kim SH, Vizzioli MR, Toledo
481 S de. Effect of bismuth subgallate (local hemostatic agent) on wound healing in rats.
482 Histological and histometric findings. *Braz Dent J*. 2002;13(1):11–6.
- 483 42. Thorisdottir H, Ratnoff OD, Maniglia AJ. Activation of Hageman factor (factor XII) by
484 bismuth subgallate, a hemostatic agent. *J Lab Clin Med*. 1988 Oct;112(4):481–6.
- 485 43. Jafari B, Jafari-Sales A, Khaneshpour H, Fatemi S, Pashazadeh M, Al-Snafi AE, et al.
486 Antibacterial effects of *Thymus vulgaris*, *Mentha pulegium*, *Crocus sativus* and *Salvia*
487 *officinalis* on pathogenic bacteria: A brief review study based on gram-positive and gram-
488 negative bacteria. *Jorjani Biomedicine Journal*. 2020 Oct 10;8(3):58–74.
- 489 44. Jafari B, Ahmadizadeh C. The In Vitro Study of Antimicrobial Effect of Marigold
490 (*Calendula officinalis*) Extract on Infectious Microorganisms. *Electronic Journal of Biology*
491 [Internet]. 2018 Jan 3 [cited 2023 Jan 23];13(4). Available from:
492 [https://ejbio.imedpub.com/abstract/the-in-vitro-study-of-antimicrobial-effect-of-](https://ejbio.imedpub.com/abstract/the-in-vitro-study-of-antimicrobial-effect-of-marigoldrncalendula-officinalis-extract-on-infectious-microorganisms-21459.html)
493 [marigoldrncalendula-officinalis-extract-on-infectious-microorganisms-21459.html](https://ejbio.imedpub.com/abstract/the-in-vitro-study-of-antimicrobial-effect-of-marigoldrncalendula-officinalis-extract-on-infectious-microorganisms-21459.html)

- 494 45. Dai C, Lin J, Li H, Shen Z, Wang Y, Velkov T, et al. The Natural Product Curcumin as
495 an Antibacterial Agent: Current Achievements and Problems. *Antioxidants*. 2022
496 Mar;11(3):459.
- 497 46. Petrita R. Real-World Performance and Safety of Cerviron® Medical Device in the
498 Treatment of Various Types of Vaginitis. *BJSTR*. 2022 Nov 22;47(2):38364–73.
- 499