Real-world study of Cerviron® vaginal ovules in the treatment of cervical lesions of various etiologies

IZABELLA PETRE[1,2], DANIELA TEODORA SIRBU[3], RAMONA PETRITA[4], ANDREEA-DENISA TOMA[5], EMA PETA[6] AND FLORENTINA DIMCEVICI-POESINA[6]

[1]Discipline of Obstetrics and Gynecology XII, 'Victor Babes' University of Medicine and Pharmacy, 300041 Timisoara; [2]University Clinic of Obstetrics and Gynecology, Emergency Clinic Hospital 'Pius Brinzeu', 300226 Timisoara; [3]Dr Sirbu Daniela Private Practice, 300269 Timisoara; [4]Biometrics Unit, MDX Research, 300633 Timisoara; [5]Pharmacy Unit of Municipal Hospital 'Dr Karl Diel' Jimbolia, 305400 Jimbolia; [6]Quality Assurance, Perfect Care Distribution SRL, Bucharest, Romania

Correspondence to: Mrs Ramona Petrita, Biometrics Unit, MDX Research Romania, 1-3 Vasile Loichita Street, 300633 Timisoara, Romania
E-mail: ramona.petrita@mdxresearch.eu
Dr Izabella Petre, Discipline of Obstetrics and Gynecology XII, 'Victor Babes' University of Medicine and Pharmacy, 2 Eftimie Murgu Square, 300041 TimisoaraE-mail: dr.petreizabella@yahoo.com

Key words: medical device, cervical lesions, cervical mucosa, cervix re-epithelialization degree, vaginal pH, vaginal pain, vaginal bleeding

Abstract. Cervical lesions can be caused by pathogens, hormonal changes or by cervical injury. The recommended treatment in all cases is excision. Local re-epithelialization therapy should be initiated preoperatively and postoperatively. The present study assessed the post-market performance and tolerability of Cerviron® ovules in the treatment and management of cervical lesions postoperatively. The study population included 345 participants aged 20-70 years with either a cervical lesion under treatment or with recent surgical removal of a cervical lesion. The degree of re-epithelialization of the cervical mucosa was improved in 73.17% of the patients

evaluated during routine colposcopy exams and 92.73% of patients recorded no bleeding. When adding Cerviron® either as monotherapy or in association with other antimicrobials in postoperative care of the cervical ectropion, improved postoperative outcomes such as reduced post-interventional bleeding, stimulation of the granulation tissue, and a superior quality of healing were observed. The study and its details are registered in *www.clinicaltrials.gov* under ID NCT05668806.

Introduction

A cervical erosion (or cervical ectropion) can occur for numerous reasons among women of childbearing age (1). It is considered a benign condition caused by pathogens or induced by increased exposure of the cervical epithelium to estrogen. Moreover, cervical erosions can be of traumatic, mechanical etiology, such as intrauterine devices or foreign bodies introduced into the vagina (2). Its prevalence ranges from 17 to 50% (3,4). The presence of ectropion is detected especially after the menarche, during pregnancy or with use of the combined oral contraceptive pill and is very rare in postmenopausal women (5).

Epithelialization of the vaginal mucus and cervix is crucial in the management of cervical erosions. Acute inflammation of the cervix as a result from direct infection or trauma translates into several symptoms, such as white to yellow vaginal discharge (predominant symptom caused by the mucus-secreting glandular epithelium), post-coital or intermenstrual bleeding, dysuria, pelvic pain, vulvovaginal irritation and dyspareunia (6). Symptomatic women should be screened for infective agents (7). Cervical ectropion has been associated with both the combined oral contraceptive pill and intrauterine contraceptive devices as highlighted by the study conducted by Wright *et al* (4). Concurrently, a number of studies have highlighted that the use of combined oral contraceptives is highly associated with the development of cervical ectopy, edema and erythema of the ectopic zone (7-9).

Pathogens such as streptococci, staphylococci, or enterococci can be promoters of acute inflammation of the cervix and cervical ectropion (10). Cervicitis (inflammation of the cervix) is often asymptomatic and can cause complications of the upper genital tract with ectopia and cervical infection by *Chlamidia trachomatis*, *Neisseria gonorrhoeae*, herpes simplex virus, and cytomegalovirus (11). Some factors involved in the pathogenesis of cervical ectopy involve the action of estrogen (12). Estrogens influence immune and inflammatory processes, by regulating

59 chemokines and chemokine receptors. In a previous study by Straub, the complex processes of
60 inflammation related to estrogen signaling toward immune cell trafficking were studied (13). The
61 T helper 17 cells producing IL-17 are the main T cells responsible for chronic inflammation. The
62 cervical epithelium is highly responsive to estrogen production. Mechanistically, it is considered
63 that estrogens induce apoptosis in cervical cells and also increase gene expression of human
64 papillomavirus-16 and -18, the two genotypes frequently associated with cervical cancer (14).
65 Exposure to high levels of estrogen is also linked to an increased risk of breast cancer (15).
66 Estrogen influences immune and inflammatory processes by modulating the production of pro-
67 inflammatory cytokines, chemokines and other immune mediators. Specifically, estrogen can
68 activate pathways that lead to the production of anti-inflammatory cytokines, such as interleukin-
69 4 (IL-4), and chemokines, such as interferon-γ (IFN-γ) (16). Furthermore, estrogen can inhibit the
70 production of pro-inflammatory mediators such as tumor necrosis factor (TNF) and IL-6. Estrogen
71 can also regulate the expression of chemokine receptors on immune cells, which in turn helps
72 regulate the migration of immune cells to sites of inflammation (17). For example, estrogen can
73 downregulate the expression of the CCR5 receptor, which is involved in the migration of T cells
74 to sites of inflammation. Estrogen can also upregulate the expression of the CXCR4 receptor,
75 which is involved in the migration of macrophages and neutrophils to sites of inflammation (18).

76 The presence of endocervical columnar epithelium on the ectocervix favors an increased
77 exposure to infections due to low cell-mediated immunity. In these areas, the subpopulation of T
78 lymphocytes, namely, T helper cells, CD8 cells, and CD1 lymphocytes are reduced in number
79 (19). Therefore, the columnar epithelium cells are more susceptible to infections such as
80 *Chlamydia trachomatis* or *Neisseria gonorrhoeae* (20). Estrogens are capable of markedly altering
81 the responses of host cells to microbes. In adolescence, pregnancy, during hormonal contraception,
82 or during the years of menstruation (mostly in the ovulatory phase), the probability of developing
83 cervical ectopy is very high, and sometimes goes undetected (5). Furthermore, cervical ectopy
84 implies further risks of acquiring sexually-transmitted diseases (gonorrhea, chlamydia and human
85 papilloma virus). In the study conducted by Sanchez *et al* a causal relationship was found between
86 cervical erosion and bacterial vaginosis that alter the mucosal barrier and decrease defense
87 mechanisms of the cervix and vagina (21).

88 An ongoing debate remains of whether ectopy requires a specific treatment. The association
89 between squamous metaplasia and induction of squamous cell carcinoma of the cervix is well

known. Moreover, the dysplastic cells are more susceptible to carcinogens (22). Notwithstanding this, according to a recent study conducted by Kleppa *et al*, ectopy may be a biological risk factor for chlamydia infection and for human immunodeficiency virus (HIV) in adolescents and in young women (7).

Currently, cryotherapy (cryosurgery) of the cervix is the standard treatment for symptomatic, benign cervical ectropion (23). Cryosurgery improves the cervical mucus characteristics and therefore it is recommended in patients with hostile cervical mucus and ectropion (24). Prior to and after surgery, adjuvant treatments should be promoted with the support of local, re-epithelizing treatments (25). For example, Belfiore *et al* reported the effectiveness of a topical treatment for cervical ectropion with 5 mg of deoxyribonucleic acid (26).

Cerviron has a substance content that provides beneficial properties in non-infectious vulvovaginitis and cervical erosion. The ovule melts in the vaginal mucosa forming a cream that ensures dispersion of the substances contained and acts as a protective barrier with astringent effect, favoring the reepithelization of damaged tissue and the restoration of the initial colpoecosystem without affecting the Doderlein bacilli. The main mechanism of action of the medical device is the dispersion of the substances in the vagina and the formation of a protective barrier that accelerates the natural healing process of the damaged epithelium. Performance and safety data on Cerviron® vaginal ovules have been reported from multiple sources. Three clinical investigations on Cerviron were reported (NCT04735705, NCT04735718 and NCT05652959 available at https://clinicaltrials.gov/ct2/show/NCT04735705; https://clinicaltrials.gov/ct2/show/NCT04735718; and https://clinicaltrials.gov/ct2/show/NCT05652959, respectively) and published articles on Cerviron® include the characterization of its utility in the management of cervical uterine fibroids and on vaginal atrophy after surgical treatment and adjuvant radiation therapy for cervical cancer (27,28). However, previous safety data was limited and included only a restricted, homogenous population, including 50 participants in study NCT04735705 and only 27 participants in study NCT04735718.

Cerviron® is a medical device marketed by Perfect Care Distribution in the following countries: Albania, Latvia, Lithuania, Estonia, Kosovo, Montenegro, Romania, Kuwait, and the United Arab Emirates. With a complex composition consisting of three topical pharmaceutical products including hexylresorcinol, collagen and bismuth subgallate, and four phytotherapeutic extracts

121 including *Calendula officinalis*, *Hydrastis canadensis*, *Thymus vulgaris* extract and *Curcuma*
122 *longa*, it is intended as adjuvant treatment for the management of cervical lesions and
123 vulvovaginitis.

124 **Materials and methods**

125 *Study objectives*. The present study was designed as part of the medical device post-marketing
126 clinical follow-up, involving routine care from a variety of clinical practices. The study includes
127 an open-label, multicentric, non-randomized, single-arm, real-world evidence study design. The
128 data were collected between the 20th of May 2021 and 31st of July 2021.

129 Real-world evidence studies are post-marketing studies bringing valuable information related
130 to the medical devices' safety and performance profiling and a broader understanding of the
131 practice pattern and the clinical outcomes. The rationale of the study was aimed at capturing safety
132 data in a broader, more heterogenous population. Cerviron® vaginal ovules have been used with
133 success in the treatment of acute and chronic vulvovaginitis of mechanical etiology, and in cervical
134 lesions of mechanical origin, but with a limited number of study participants (NCT04735705 and
135 NCT04735718). Real-world evidence studies and clinical trials are complementary. The present
136 study is considered a real-world evidence study as it reflects actual clinical aspects with data
137 collected in the context of routine delivery of care, as opposed to data collected within a clinical
138 trial, where study design controls variability in ways that are not representative of real-world care
139 and outcomes.

140 The primary objective was to evaluate the tolerability of Cerviron® ovules in the treatment and
141 management of cervical erosions of various etiologies. The secondary objective of this study was
142 the assessment of performance of the medical device by clinical exam and patients' degree of
143 satisfaction related to the use of the medical device.

144 *Study population***.** The target population included women aged 20 to 70 years with symptomology
145 associated with cervical ectropion of various etiology such as cervix trauma, postpartum injuries,
146 vaginal infections and cervicitis. A total of 345 women were evaluated. A number of patients were
147 treated with Cerviron® ovules as monotherapy (n=210) and other patients were prescribed
148 Cerviron® ovules as an adjuvant in therapeutic schemas containing antibiotics, antivirals and/or
149 anti-inflammatory drugs (n=135). Subjects with a previous history of any malignancy, including

150 subjects with vulvar, vaginal, or cervical cancer or with undiagnosed abnormal genital bleeding
151 were excluded.

152 The study involved 30 Romanian specialist physicians as investigators from 16 institutions
153 each treating between 6 and 22 patients. The participating clinical practices and their locations are
154 listed as Table 1. Upon study entry and at 1, 2 and 3 months after the initial visit, participants were
155 interviewed and received visual cervical examinations by colposcopy. At each visit, participants
156 received a standardized pelvic exam with placement of a speculum and visualization of the cervix.

Institution	City, Country (Romania)
Clinical Hospital 'Dr Ion Cantacuzino' Bucharest	Bucharest
Hospital MedLife Humanitas Cluj-Napoca	Cluj-Napoca
Medical office of Dr Saleh K. Majed	Craiova
Medical office of Dr Surpanelu Oana	Iasi
Natisan Medical Center	Pitesti
Gynecological office of Dr Rădulescu G. Mihaela Elena	Râmnicu Vâlcea
Medical office of Dr. Popescu	Sibiu
MediBlue Medical Clinic	Iasi
SC Pan Medical SRL	Sibiu
Medical clinic of Dr. Cioata Ionel Trifon	Timisoara
iMED Clinic	Sibiu
Tulcea County Emergency Hospital	Tulcea
Bradmed SRL	Targu Jiu
Gynecological office of Dr Ioana Trotea Targu Jiu	Targu Jiu
Medical office of Obstetrics and Gynecology of Dr Sirbu Daniela SRL	Timisoara
Dr Todorut Florina	Timisoara
Total sites, 16.	

157

158 Table 1. Clinical practices and their locations

159 Prospective data were collected from each patient, such as initial diagnosis, colposcopy
160 examination results, re-epithelialization degree, vaginal pH value, vaginal symptoms, any
161 worsening symptoms and adverse events.

Ethical and regulatory aspects of the study. Written consent for study participation was collected from all patients. General Data Protection Regulation (GDPR) consent forms were collected from all patients. Due to legal considerations (GDPR directive effective from 21 May 2018 in all European Union countries), patients or their legal representatives have an absolute right to request that their data be removed from the study database. A Notified Body (ENTE CERTIFICATIONE MACCHINE SRL) reviewed the post marketing clinical follow-up plan, including ethical considerations. As this is a post-marketing clinical follow-up study, an Ethics Committee approval was not required, as per the regulations described below.

The study was conducted in accordance with the Guide to medical devices: 'Post-market clinical follow-up studies' (https://www.imdrf.org/sites/default/files/docs/imdrf/final/technical/imdrf-tech-210325-wng65.pdf) and the International Society for Pharmacoepidemiology (ISPE; 2015) Guidelines for 'Good pharmacoepidemiology practices (GPP)' (https://www.pharmacoepi.org/resources/policies/guidelines-08027/)

The collected data and study procedures were conducted in accordance with the ethical principles that have their origin in the Declaration of Helsinki.

The study followed the definition of the non-interventional (observational) study provided by the Guide to Good Pharmacovigilance Practices (GVP; 2017): Module VIII - Post-authorization safety studies (https://www.ema.europa.eu/en/documents/scientific-guideline/guideline-good-pharmacovigilance-practices-gvp-module-viii-post-authorisation-safety-studies-rev-3_en.pdf). The study followed the nature of the non-interventional (observational) studies mentioned in the ICH Harmonized Tripartite Guide Pharmacovigilance Planning E2E (ICH, 2004; https://database.ich.org/sites/default/files/E2E_Guideline.pdf).

Revision risk analysis was carried out in accordance with the medical device regulation, available from: https://www.anm.ro/en/dispozitive-medicale/regulamentele-europene-privind-dispozitivele-medicale. Data were stored according to Annex E of ISO 14155:2020 (https://www.iso.org/standard/). The study and its details are registered in *www.clinicaltrials.gov* under ID NCT05668806.

190 *Statistical consideration*. All statistical analyses were performed using the Excel Analysis
191 ToolPak, version 16.69.1, from Microsoft. $P<0.05$ was considered to indicate a statistically
192 significant difference.
193 The quality and completeness of the collected data were preliminarily assessed in comparison with
194 data analysis. No study participant was involved in any violation of inclusion/exclusion criteria.
195 To examine the treatment significance over time, Fisher's exact test was performed for categorical
196 variables, and Mann-Whitney U test was employed to perform comparative analysis for variables
197 non-normally distributed.

198 **Results**

199 *Range of gynecological conditions and medical history of selected patients*. The selected patients
200 presented with various gynecological conditions consistent with the instructions for the use of the
201 medical device. Some patients presented with other conditions with similar symptoms. As the
202 evaluation of the performance of the device was a secondary objective, other conditions that would
203 enable further investigations for expanding the use of the medical device were also selected (Table
204 2).

Gynecological condition	Number of patients (n=345) Age, 20-70 years
Anexitis	4
Atypical squamous cells cannot exclude high grade squamous intraepithelial lesion	5
Atypical squamous cells of undetermined significance	39
Cervical dysplasia	7
Cervical ectropion	47
Cervicitis	59
Dyspareunia	6
Endocervicitis	8
Endocervicosis	11
Exocervicitis	61
Low-grade squamous intraepithelial lesions	6
Metroanexitis	2
Negative for intraepithelial lesion or malignancy	2
Ovarian cyst	2
Post Conization	10
Uterine fibroids	1
Uterus filaments	1
Vaginal atrophy	2
Vaginal polyps	1
Vaginal prolapse	1
Vulvovaginitis	70

205

206 Table 2. Medical history of selected patients

207 Subjects were followed undergoing treatment with Cerviron® vaginal ovules for ~3 months. Each
208 enrolled subject visited the clinic four times, at 30-day intervals each. The study visit scheme is
209 listed in figure 1. In the monotherapy group, 11 patients (5.23%) were considered dropouts due to
210 the fact that they did not attend all the study visits and could not be evaluated. In the polytherapy
211 group, 32 patients (23.7%) were considered dropouts (figure 1).

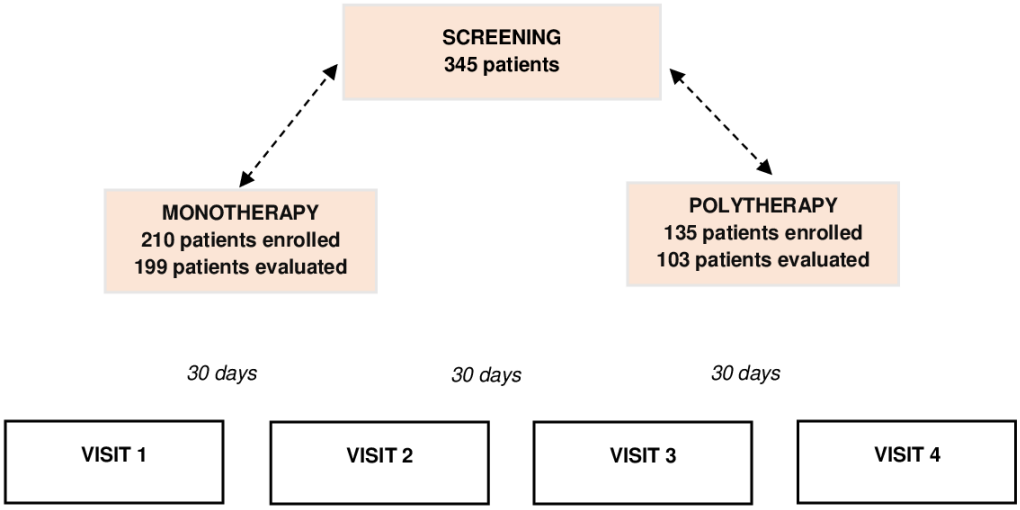

Figure 1. Schematic diagram for the present study.

Primary objectives. The study primary objective was to assess the tolerability of the medical device by the number of possible adverse reactions observed during the treatment. In one patient treated exclusively with Cerviron® ovules, during the routine gynecological examination one adverse reaction was noted, which was erythema. The erythema was followed by itching and abnormal vaginal discharge. The investigators determined that this was not related to treatment with the medical device. At the following visit, the reaction was absent.

Two other patients received combined treatment with antibiotics and Cerviron® ovules. After 30 days, both patients reported an adverse reaction of itching and erythema. Investigators determined that the symptoms were consistent with the initial diagnosis. After 60 days, these reactions were absent in both patients. All the aforementioned incidents were linked to preexisting conditions and the investigators decided that they must not be regarded as adverse reactions to the medical device Cerviron®.

Secondary objectives

Clinical performance assessed by the investigator by colposcopy. A significant proportion of 69.14% patients were rated with the indicator 'normal aspect' during colposcopy, as shown in figure 2.

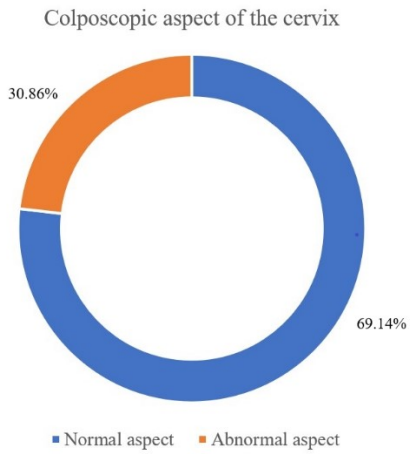

Figure 2. Clinical performance assessed by the investigator by colposcopy

Re-epithelialization degree of the cervical mucosa by gynecological examination. For only 302 patients out of 345, medical records evaluating the degree of epithelialization of the cervical mucosa were available. At the initial visit, 302 participants were assessed, of which 3.64% were rated with 'complete epithelization', 40.40% were rated with degree of 'partial re-epithelialization' and 55,96% were rated with 'absent, ulcerations present'. At 30 days, 47.68% of the 302 women assessed, had a favorable degree of re-epithelialization, with only 4.30% rated as 'absent, ulcerations present'. After 3 months, 73.17% of the 287 patients were rated with 'complete epithelization', as shown in table 3.

Degree of re-epithelialization	Initial evaluation	At 30 days	At 90 days
Absent	169 (55.96%)	13 (4.30%)	6 (2.09%)
Partial	122 (40.40%)	145 (48.01%)	71 (24.74%)
Complete	11 (3.64%)	144 (47.68%)	210 (73.17%)
Total (N)	302	302	287

Table 3. Degree of re-epithelization at initial evaluation, 30 and 90 days.

Vaginal pH level evaluation. It was observed that following a 3-month treatment with Cerviron®, 87.86% of the patients presented with a normal pH, as revealed in figure 3.

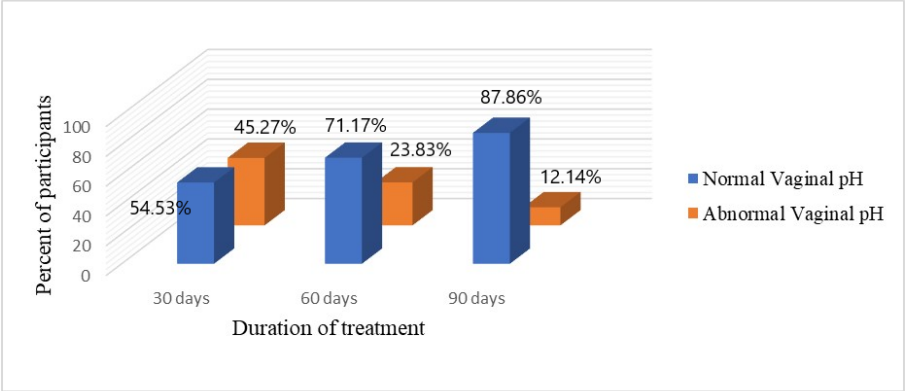

Figure 3. Changes in vaginal pH throughout the study (90 days).

Evaluation of the level of pain. Of the total number (n=302) of patients examined at visit 1, 46.67% reported mild pain levels and 28.00% had no pain at all. At the second visit, 68.49% of the population (207) rated pain severity as no pain or mild severity in 26.71%. A very high proportion (86.47%) was pain free at the last visit after 3 months of treatment with Cerviron® (as shown in figure 4). Figure 4 also provides the corresponding data related to pain level across the treatment period.

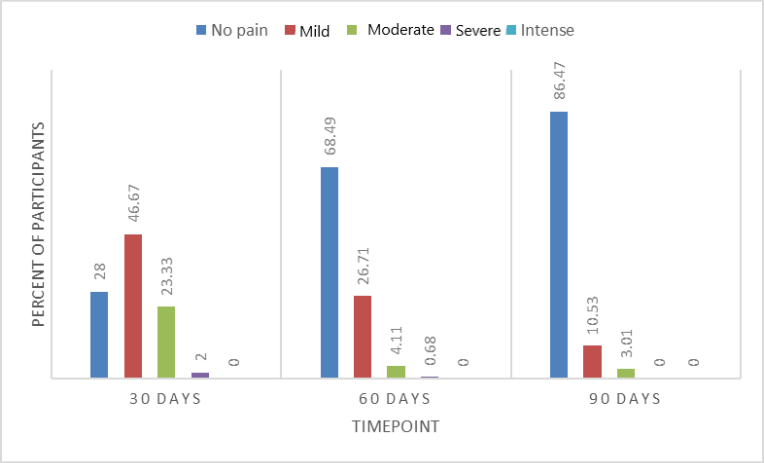

Figure 4. Evaluation of pain level between the study visits (90 days).

Evaluation of the level of vaginal bleeding. At the first visit, 302 women included in the study were evaluated, of whom 48.70% reported no bleeding observed after treatment with Cerviron® and 33.91% reported low amounts of vaginal bleeding. The efficacy of medical device was more clearly observed at visit 2, where 77.68% of patients experienced no bleeding at all and 1.79%

experienced moderate or severe bleeding. After 3 months of treatment, this improvement was noteworthy when 92.73% of patients reported no bleeding and only 7.27% of patients reported a mild level of bleeding, as observed in figure 5.

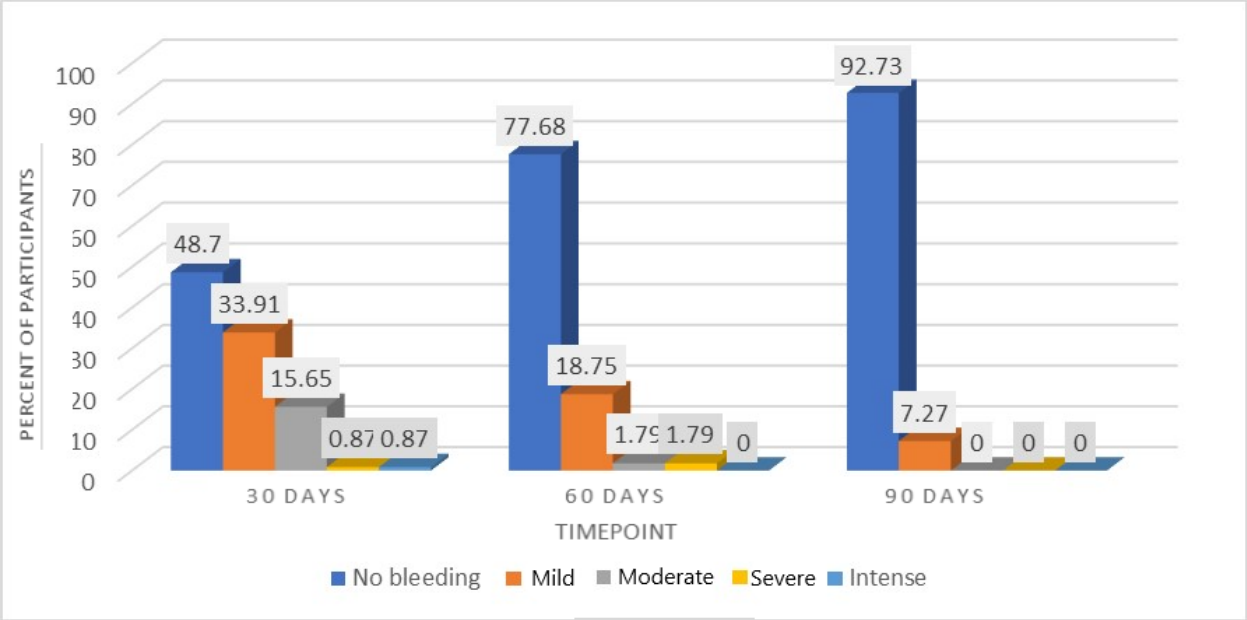

Figure 5. Evaluation of the level of vaginal bleeding throughout the study (90 days).

Degree of satisfaction after using Cerviron® ovules. In terms of degree of satisfaction offered, participants in the largest population (72.25%) were reported to be 'very satisfied' with the medical device. The degree of satisfaction was measured by a 5-point Likert scale, as revealed in figure 6. (30).

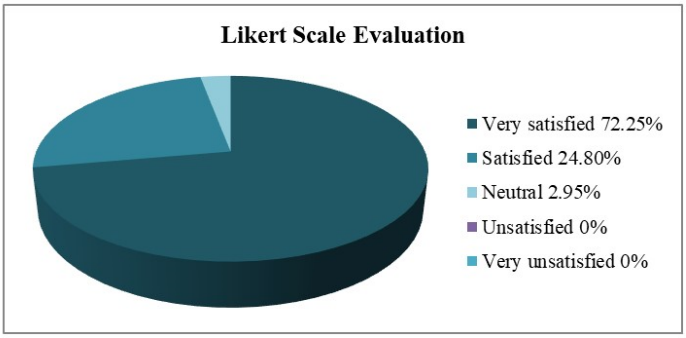

Figure 6. Likert Scale evaluation at the end of the study.

Discussion

270 A very important aspect that influences the management of cervical ectopy is age. Cervical
271 ectopy is predominant in young adolescents, with a prevalence of up to 80% in sexually active
272 adolescents. (31) However, factors associated with the evolution and devolution of cervical ectopy
273 are diverse and mechanisms have yet to be elucidated. Since ectopy is observed frequently in
274 adolescent girls and pregnant women, it may vary in response to hormonal fluctuations observed
275 in pregnancy and during contraception with combined oral contraceptives (32). Screening for
276 C*hlamydia trachomatis* and *Neisseria gonorrhoeae* can prevent a range of gynecological
277 conditions, such as urethritis, cervicitis, cervical erosions (33). Infection in the lower genital tract
278 can result in upper genital tract complications, such as pelvic inflammatory diseases, ectopic
279 pregnancy, chronic pelvic pain, and infertility in asymptomatic women, and transmission of
280 infection during pregnancy and labor (34).

281 Cryotherapy (cryosurgery) of the cervix is an effective treatment for symptomatic cervical
282 ectropion (35). Other surgical techniques have been applied for ablation of the squamocolumnar
283 junction. Cauterization has been applied for this purpose since 1920, but it involves additional
284 risks, such as burning lesions if the safeguard plate is not located correctly (36). Some specialists
285 even consider the cervical ectropion as a normal finding that does not require treatment despite the
286 red and inflamed appearance of the cervix. However, cervical ectropion is considered as one of the
287 most common types of chronic cervicitis worldwide (37). Topical treatments for cervical
288 ectropion, including cervical painting with gentian violet paint or microwave tissue coagulation,
289 are still widely used (4). Although the debate is still ongoing, a harmonized treatment strategy
290 would reduce complications of cervical ectropion, such as developing abnormal metaplasia and/or
291 vaginal infection. Applying an intervention to treat cervical ectopy is recommended, especially
292 when considering taking preventive action against cervical cancer. Ectopic cells are modified over
293 time by squamous metaplasia and epithelialization, cervical infection with *Neisseria* gonorrhea or
294 *Chlamidia trachomatis*, low pH values or trauma (38). Cerviron® appears to have a very potent
295 action in rebalancing the vaginal pH. In a previous clinical investigation, NCT04735705, vaginal
296 pH values measured over 90 days showed that Cerviron® restores altered vaginal pH. The
297 difference in vaginal pH values between baseline versus 90 days, at a 5% significance level was
298 statistically significant ($P<0.05$).

299 A literature review conducted by Machado *et al* indicated that treatment can be used to relieve
300 occasional symptoms associated with ectopy, but does not support routine treatment for ectopy
301 (12).
302 By contrast, a study conducted by Soares *et al*, showed a positive association between cervical
303 ectopy and human papillomavirus, HIV, bacterial vaginosis, cervical epithelial atypia, postcoital
304 bleeding, and desquamative inflammatory vaginitis (39). Recognition of cervical ectopy should
305 alert the clinician to the possibility of a genital chlamydia infection. Opportunistic screening for
306 chlamydia in young people should be offered to reduce the prevalence of infection and its sequelae.
307 *Chlamydia trachomatis* is the most common bacterial sexually transmitted disease. In women,
308 chlamydial infection usually presents as cervicitis, which can lead to up to 30 to 50% of pelvic
309 inflammatory disease episodes. Pelvic inflammatory disease has significant reproductive sequelae,
310 such as tubal infertility and ectopic pregnancy (40).

311 The main mechanism of action of the medical device is the dispersion of the substances in the
312 vagina and the formation of a protective barrier that accelerates the natural healing process of the
313 damaged epithelium. The effect of the medical device is obtained due to the presence of the
314 Bismuth subgallate and vegetable collagen. Bismuth subgallate is an insoluble solution, with a
315 very low bio-availability which will create a physical barrier over the affected area of the vaginal
316 mucosa and therefore will not allow oxygen and pathogens to come in contact with it. In this way,
317 the substances create the premises that allow the damaged tissue to heal naturally. The role of
318 exogenous collagen is to be a " sacrificial substrate" in order to reduce excess metalloproteins that
319 delay wound healing and to regulate the healing of the damaged tissue (14, 40-43). As such,
320 Cerviron® supportive therapy may be prescribed in sexually active patients for at least 1-3 months,
321 during10-15 consecutive days, to prevent these infections.

322 The findings in the present study revealed that a 90-day treatment (3 treatment sessions of 30 days
323 each) with Cerviron vaginal ovules was beneficial in providing a complete degree of cervical
324 epithelialization and reduced the multitude of the vaginal symptoms, including bleeding,
325 inflammation, malodor, dysuria, dyspareunia, pain and leukorrhea. This result is consistent with
326 previous clinical studies that included the same medical device, NCT04735705 and NCT04735718
327 (46).
328 In conclusion, the findings of the present study revealed that administration of Cerviron®
329 vaginal ovules provided a complete degree of epithelization in majority of patients attending a 90-

330 days treatment. Moreover, subjects presenting a high grade of ulceration at the baseline visit,
331 following treatment with Cerviron® presented a complete degree of epithelization. Cerviron®
332 ovules are an exceptional adjuvant for acceleration of healing of cervical erosions. They favor the
333 re-epithelialization of the damaged tissue and restoration of the initial colpo-ecosystem. Their
334 topical application was observed to be effective in reducing unpleasant symptoms such as vaginal
335 discharge, pelvic pain, and vaginal bleeding. In terms of adverse events, the medical device is
336 considered safe. The only contraindication to Cerviron® ovules has been determined as
337 hypersensitivity to the active substance or to any of the excipients within the medical device.
338

339 **Acknowledgements**

340 We would like to thank Mrs Florentina Liliana Calancea (MDX Research, Timisoara, Romania)
341 for medical writing and Mr Alexandru Pinta (Labcorp Austria GmbH, Vienna Austria) for support
342 in data management and statistical analysis.

343 **Funding**

344 Perfect Care Distribution SRL (https://www.perfectcare.ro/), the study sponsor, offered the tested
345 medical devices and a partial grant support.

346 **Availability of data and materials**

347 The data that support the findings of this study are available from the corresponding author upon
348 reasonable request.

349 **Authors' contributions**

350 IP, RP and ADT were involved in the study design, methodology and original draft preparation.
351 IP and DTS performed the data collection and data analysis. RP, ADT and IP were involved in
352 analysis and interpretation of data. EP and FD-P were involved in manuscript review and editing.
353 IP, DTS and ADT participated in the interpretation of the study results. FD-P and EP confirm the
354 authenticity of all the raw data. All authors approved the final version of the manuscript to be
355 published.

356 **Ethics approval and consent to participate**

357 Only participants that voluntarily provided their written consent to the collection of their study
358 data were included. The collected data and study procedures were conducted in accordance with

359 the ethical principles that have their origin in the Declaration of Helsinki. As this is a post-
360 marketing clinical follow-up study, an Ethics Committee approval was not required, but the study
361 protocol was approved by a Notified Body, ENTE CERTIFICATIONE MACCHINE SRL.

362 **Patient consent for publication**

363 Not applicable.

364 **Competing interests**

365 FD-P and EP are employed at Perfect Care Distribution SRL. All the other authors declare no
366 competing interests. The funder Perfect Care Distribution SRL had no role in the design of the
367 study, or in the collection, analyses, or interpretation of data, or in the writing of the manuscript,
368 or in the decision to publish the results.

369 **References**

370 1. Wildenberg JC, Yam BL, Langer JE, Jones LP. US of the Nongravid Cervix with
371 Multimodality Imaging Correlation: Normal Appearance, Pathologic Conditions, and
372 Diagnostic Pitfalls. Radiographics. 2016 Apr;36(2):596–617.

373 2. Ferenczy A. Benign Lesions of the Cervix. In: Blaustein A, editor. Pathology of the Female
374 Genital Tract [Internet]. New York, NY: Springer; 1977 [cited 2022 Nov 22]. p. 124–42.
375 Available from: https://doi.org/10.1007/978-1-4757-6143-6_6

376 3. Kuhn L, Denny L, Pollack AE, Wright TC. Prevalence of visible disruption of cervical
377 epithelium and cervical ectopy in African women using Depo-Provera. Contraception. 1999
378 Jun;59(6):363–7.

379 4. Wright KO, Mohammed AS, Salisu-Olatunji O, Kuyinu YA. Cervical Ectropion and Intra-
380 Uterine Contraceptive Device (IUCD): a five-year retrospective study of family planning
381 clients of a tertiary health institution in Lagos Nigeria. BMC Res Notes. 2014 Dec 23;7:946.

382 5. Aggarwal P, Ben Amor A. Cervical Ectropion. In: StatPearls [Internet]. Treasure Island (FL):
383 StatPearls Publishing; 2023 [cited 2023 Mar 22]. Available from:
384 http://www.ncbi.nlm.nih.gov/books/NBK560709/

385 6. Mitchell L, King M, Brillhart H, Goldstein A. Cervical Ectropion May Be a Cause of
386 Desquamative Inflammatory Vaginitis. Sex Med. 2017 Sep;5(3):e212–4.

387 7. Kleppa E, Holmen SD, Lillebø K, Kjetland EF, Gundersen SG, Taylor M, et al. Cervical
388 ectopy: associations with sexually transmitted infections and HIV. A cross-sectional study of
389 high school students in rural South Africa. Sex Transm Infect. 2015 Mar;91(2):124–9.

390 8. Goldacre MJ, Loudon N, Watt B, Grant G, Loudon JD, McPherson K, et al. Epidemiology
391 and clinical significance of cervical erosion in women attending a family planning clinic. Br
392 Med J. 1978 Mar 25;1(6115):748–50.

393 9. Dugas LR, Lie L, Plange-Rhule J, Bedu-Addo K, Bovet P, Lambert EV, et al. Gut microbiota,
394 short chain fatty acids, and obesity across the epidemiologic transition: the METS-
395 Microbiome study protocol. BMC Public Health. 2018 Aug 6;18(1):978.

396 10. Critchlow CW, Wölner-Hanssen P, Eschenbach DA, Kiviat NB, Koutsky LA, Stevens
397 CE, et al. Determinants of cervical ectopia and of cervicitis: age, oral contraception, specific
398 cervical infection, smoking, and douching. Am J Obstet Gynecol. 1995 Aug;173(2):534–43.

399 11. Ortiz-de la Tabla V, Gutiérrez F. Cervicitis: Etiology, diagnosis and treatment. Enferm
400 Infecc Microbiol Clin (Engl Ed). 2019 Dec;37(10):661–7.

401 12. Machado Junior LC, Dalmaso ASW, Carvalho HB de. Evidence for benefits from
402 treating cervical ectopy: literature review. Sao Paulo Med J. 2008 Mar;126:132–9.

403 13. Straub RH. The Complex Role of Estrogens in Inflammation. Endocrine Reviews. 2007
404 Aug 1;28(5):521–74.

405 14. Curcumin counteracts the proliferative effect of estradiol and induces apoptosis in
406 cervical cancer cells | SpringerLink [Internet]. [cited 2023 Feb 14]. Available from:
407 https://link.springer.com/article/10.1007/s11010-010-0606-3

408 15. Yue W, Wang JP, Li Y, Fan P, Liu G, Zhang N, et al. Effects of estrogen on breast cancer
409 development: role of estrogen receptor independent mechanisms. Int J Cancer. 2010 Oct
410 15;127(8):1748–57.

411 16. Kassi E, Moutsatsou P. Estrogen Receptor Signaling and Its Relationship to Cytokines in
412 Systemic Lupus Erythematosus. J Biomed Biotechnol. 2010;2010:317452.

413 17. Chakraborty B, Byemerwa J, Krebs T, Lim F, Chang CY, McDonnell DP. Estrogen
414 Receptor Signaling in the Immune System. Endocrine Reviews. 2023 Feb 1;44(1):117–41.

415 18. Rodriguez-Lara V, Peña-Mirabal E, Baez-Saldaña R, Esparza-Silva AL, García-Zepeda
416 E, Cerbon Cervantes MA, et al. Estrogen receptor beta and CXCR4/CXCL12 expression:
417 differences by sex and hormonal status in lung adenocarcinoma. Arch Med Res. 2014
418 Feb;45(2):158–69.

419 19. De Luca Brunori I, Facchini V, Filippeschi M, Battini L, Giusti G, Romani L, et al. Cell-
420 mediated immunity in the course of cervical ectropion. Clin Exp Obstet Gynecol.
421 1994;21(2):105–7.

422 20. Wang LC, Yu Q, Edwards V, Lin B, Qiu J, Turner JR, et al. Neisseria gonorrhoeae
423 infects the human endocervix by activating non-muscle myosin II-mediated epithelial
424 exfoliation. PLoS Pathog. 2017 Apr 13;13(4):e1006269.

425 21. A S, A R, F C, S O. Cervical erosion as result of infectious vaginitis. European Journal of
426 Experimental Biology. 2(5):0–0.

427 22. Çekmez Y, Şanlıkan F, Göçmen A, Vural A, Türkmen SB. Is Cryotherapy Friend or Foe
428 for Symptomatic Cervical Ectopy? MPP. 2016;25(1):8–11.

429 23. Yildiz S, Alay I, Eren E, Karaca I, Gultekin G, Kaya C, et al. The impact of cryotherapy
430 for symptomatic cervical ectropion on female sexual function and quality of life. J Obstet
431 Gynaecol. 2021 Jul;41(5):815–20.

432 24. Baram A, Paz GF, Peyser MR, Schachter A, Homonnai ZT. Treatment of cervical
433 ectropion by cryosurgery: effect on cervical mucus characteristics. Fertil Steril. 1985
434 Jan;43(1):86–9.

435 25. Zhu T, Chen Z, Xia Q, Jiang S, Jin Q, Farahani MRD, et al. A suppository for treating
436 cervical erosion and its preparation method. Clin Exp Obstet Gynecol. 2013;40(3):361–6.

437 26. Belfiore P, Costa E, De Cantis S, Vassallo R, Marino A. Effectiveness and persistence of
438 a topical treatment for cervical ectropion with deoxyribonucleic acid. Minerva Ginecol. 2005
439 Aug;57(4):461–6.

440 27. Bacalbasa N, Balescu IC. 2022-RA-462-ESGO The effects of Cerviron on vaginal
441 atrophy after surgically treated and adjuvant radiation therapy for cervical cancer.
442 International Journal of Gynecologic Cancer [Internet]. 2022 Oct 1 [cited 2023 Jan
443 25];32(Suppl 2). Available from: https://ijgc.bmj.com/content/32/Suppl_2/A391.1

444 28. Bacalbasa N, Balescu I, Aloul A, Bohiltea R, Socea B, Ursut B, et al. The role of topic
445 vaginal products in posthysterectomy vaginal atrophy. Romanian Medical Journal. 2021 Oct
446 1;LXVIII:344–6.

447 29. 14:00-17:00. ISO 14971:2007 [Internet]. ISO. [cited 2022 Oct 14]. Available from:
448 https://www.iso.org/cms/render/live/en/sites/isoorg/contents/data/standard/03/81/38193.html

449 30. Robinson J. Likert Scale. In: Michalos AC, editor. Encyclopedia of Quality of Life and
450 Well-Being Research [Internet]. Dordrecht: Springer Netherlands; 2014 [cited 2023 Mar 22].
451 p. 3620–1. Available from: https://doi.org/10.1007/978-94-007-0753-5_1654

452 31. Bright PL, Turner AN, Morrison CS, Wong EL, Kwok C, Yacobson I, et al. Hormonal
453 contraception and area of cervical ectopy: a longitudinal assessment. Contraception. 2011
454 Nov;84(5):512.

455 32. Bright PL, Turner AN, Morrison CS, Wong EL, Kwok C, Yacobson I, et al. Hormonal
456 contraception and area of cervical ectopy: a longitudinal assessment. Contraception. 2011
457 Nov;84(5):512–9.

458 33. Pillay J, Wingert A, MacGregor T, Gates M, Vandermeer B, Hartling L. Screening for
459 chlamydia and/or gonorrhea in primary health care: systematic reviews on effectiveness and
460 patient preferences. Syst Rev. 2021 Apr 19;10:118.

461 34. Senn T. Sexually Transmitted Diseases (STDs). In: Gellman MD, Turner JR, editors.
462 Encyclopedia of Behavioral Medicine [Internet]. New York, NY: Springer; 2013 [cited 2022
463 Nov 22]. p. 1782–4. Available from: https://doi.org/10.1007/978-1-4419-1005-9_671

464 35. Agah J, Sharifzadeh M, Hosseinzadeh A. Cryotherapy as a Method for Relieving
465 Symptoms of Cervical Ectopy: A Randomized Clinical Trial. Oman Med J. 2019
466 Jul;34(4):322–6.

467 36. Chen J, Zhou D, Liu Y, Peng J, Li C, Chen W, et al. A comparison between ultrasound
468 therapy and laser therapy for symptomatic cervical ectopy. Ultrasound Med Biol. 2008
469 Nov;34(11):1770–4.

470 37. Liu Y, Yang K, Wu T, Roberts H, Li J, Tian J, et al. Microwave therapy for cervical
471 ectropion. Cochrane Database Syst Rev. 2007 Oct 17;2007(4):CD006227.

472 38. Machado Junior LC, Dalmaso ASW, Carvalho HB de. Evidence for benefits from
473 treating cervical ectopy: literature review. Sao Paulo Med J. 2008 Mar 6;126(2):132–9.

474 39. Soares LC, Braz FLTA, Araújo AR, Oliveira MAP. Association of Sexually Transmitted
475 Diseases With Cervical Ectopy: A Systematic Review. Sex Transm Dis. 2019 Jul;46(7):452–
476 7.

477 40. Jacobson DL, Peralta L, Graham NMH, Zenilman J. Histologic Development of Cervical
478 Ectopy: Relationship to Reproductive Hormones. Sexually Transmitted Diseases. 2000
479 May;27(5):252.

480 41. Tramontina VA, Machado MAN, Nogueira Filho G da R, Kim SH, Vizzioli MR, Toledo
481 S de. Effect of bismuth subgallate (local hemostatic agent) on wound healing in rats.
482 Histological and histometric findings. Braz Dent J. 2002;13(1):11–6.

483 42. Thorisdottir H, Ratnoff OD, Maniglia AJ. Activation of Hageman factor (factor XII) by
484 bismuth subgallate, a hemostatic agent. J Lab Clin Med. 1988 Oct;112(4):481–6.

485 43. Jafari B, Jafari-Sales A, Khaneshpour H, Fatemi S, Pashazadeh M, Al-Snafi AE, et al.
486 Antibacterial effects of Thymus vulgaris, Mentha pulegium, Crocus sativus and Salvia
487 officinalis on pathogenic bacteria: A brief review study based on gram-positive and gram-
488 negative bacteria. Jorjani Biomedicine Journal. 2020 Oct 10;8(3):58–74.

489 44. Jafari B, Ahmadizadeh C. The In Vitro Study of Antimicrobial Effect of Marigold
490 (Calendula officinalis) Extract on Infectious Microorganisms. Electronic Journal of Biology
491 [Internet]. 2018 Jan 3 [cited 2023 Jan 23];13(4). Available from:
492 https://ejbio.imedpub.com/abstract/the-in-vitro-study-of-antimicrobial-effect-of-
493 marigoldrncalendula-officinalis-extract-on-infectious-microorganisms-21459.html

494 45. Dai C, Lin J, Li H, Shen Z, Wang Y, Velkov T, et al. The Natural Product Curcumin as
495 an Antibacterial Agent: Current Achievements and Problems. Antioxidants. 2022
496 Mar;11(3):459.

497 46. Petrita R. Real-World Performance and Safety of Cerviron® Medical Device in the
498 Treatment of Various Types of Vaginitis. BJSTR. 2022 Nov 22;47(2):38364–73.

499

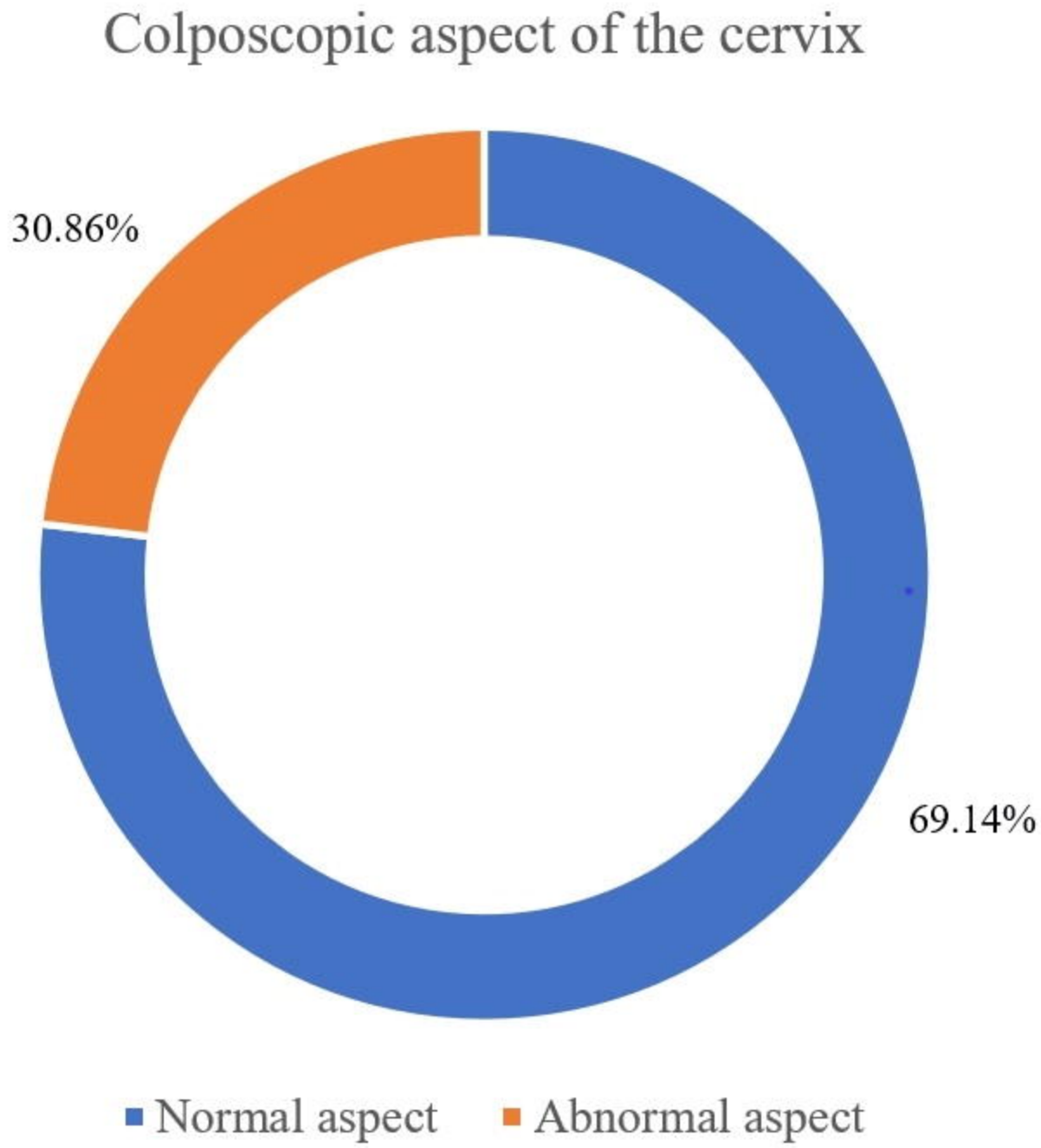
Colposcopic aspect of the cervix
30.86%
69.14%
Normal aspect
Abnormal aspect

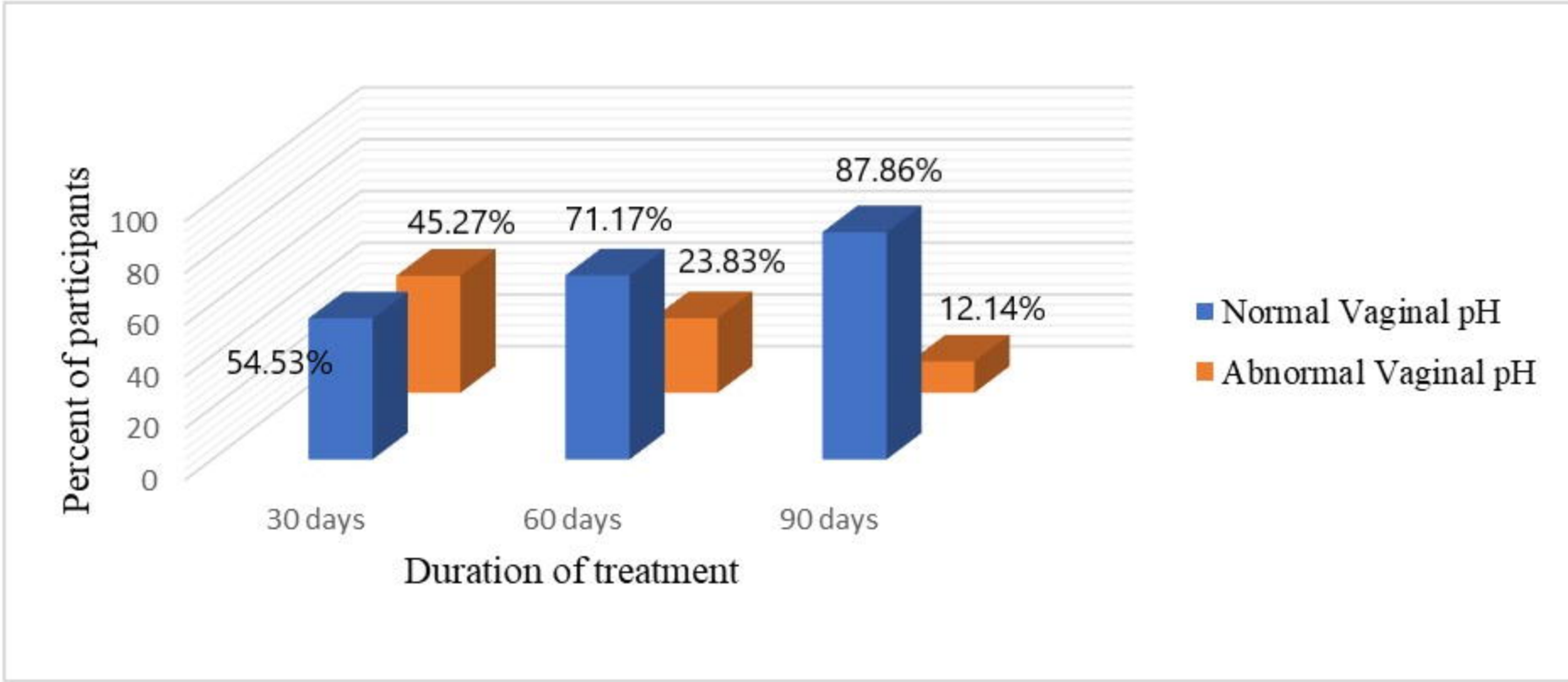
Percent of participants
100
80
60
40
20
0
54.53%
45.27%
71.17%
23.83%
87.86%
12.14%
30 days
60 days
90 days
Duration of treatment
Normal Vaginal pH
Abnormal Vaginal pH

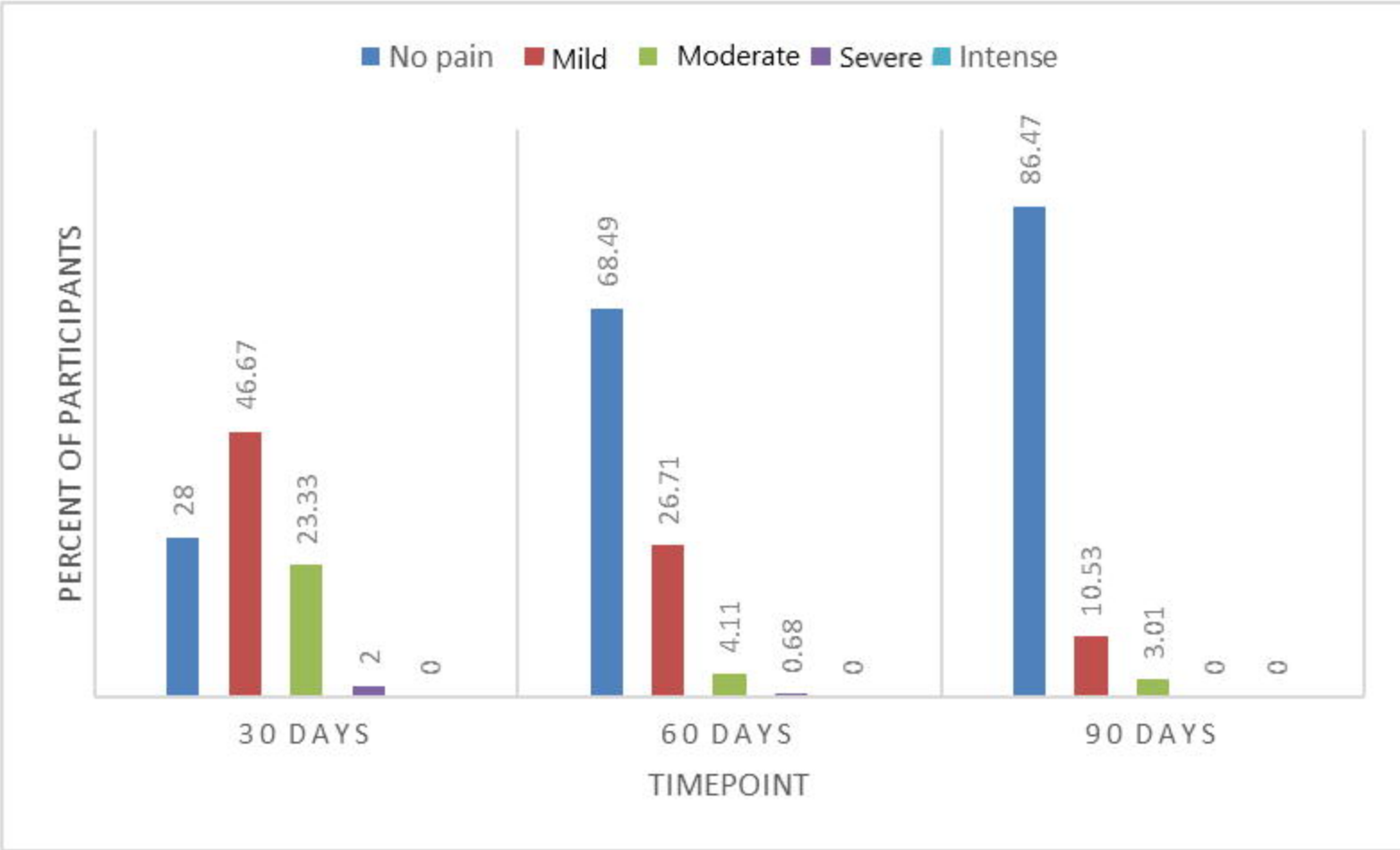
No pain
Mild
Moderate
Severe
Intense
PERCENT OF PARTICIPANTS
28
46.67
23.33
2
0
68.49
26.71
4.11
0.68
0
86.47
10.53
3.01
0
0
30 DAYS
60 DAYS
90 DAYS
TIMEPOINT

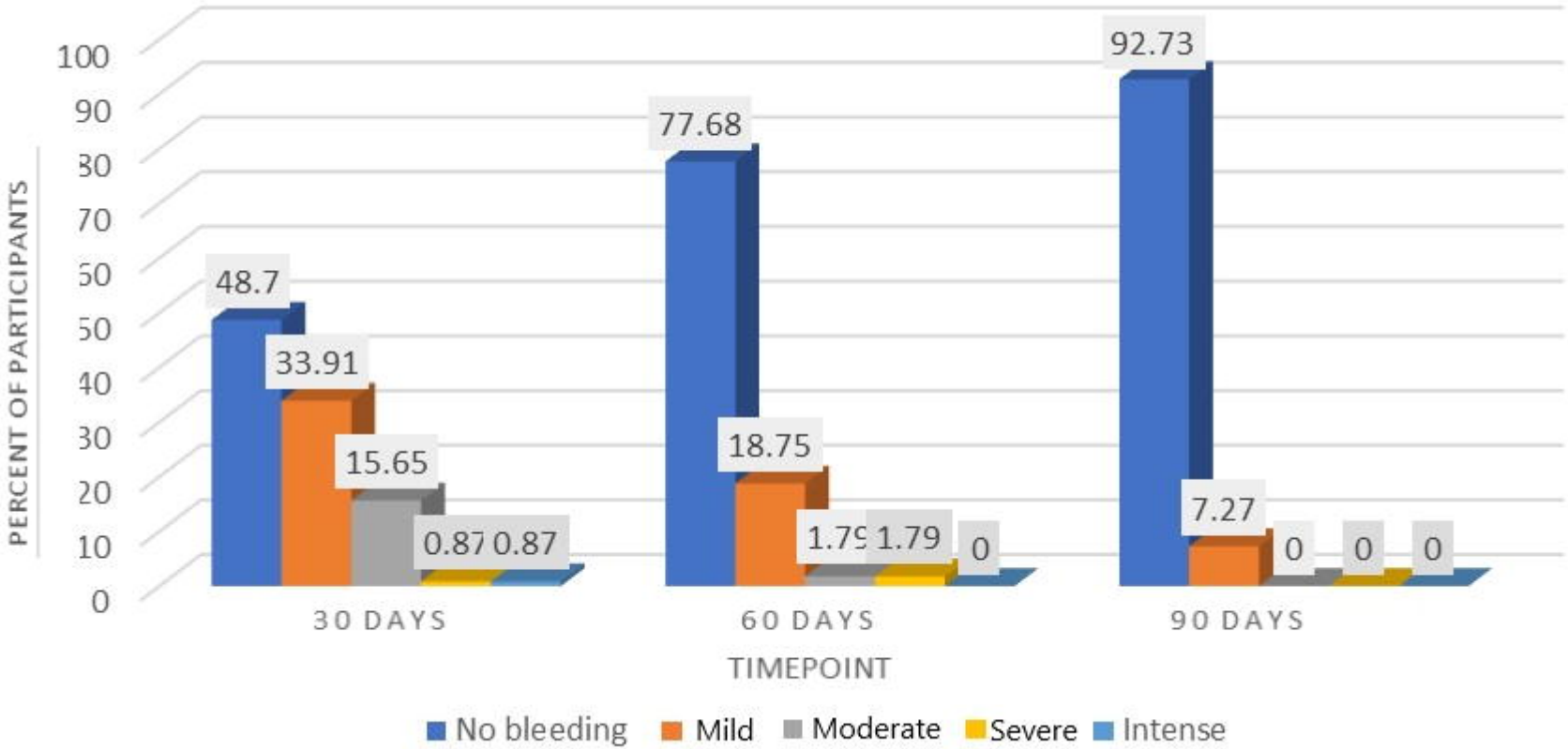
100
90
80
70
60
50
40
30
20
10
0
PERCENT OF PARTICIPANTS
48.7
33.91
15.65
0.87
0.87
77.68
18.75
1.79
1.79
0
92.73
7.27
0
0
0
30 DAYS
60 DAYS
90 DAYS
TIMEPOINT
No bleeding
Mild
Moderate
Severe
Intense

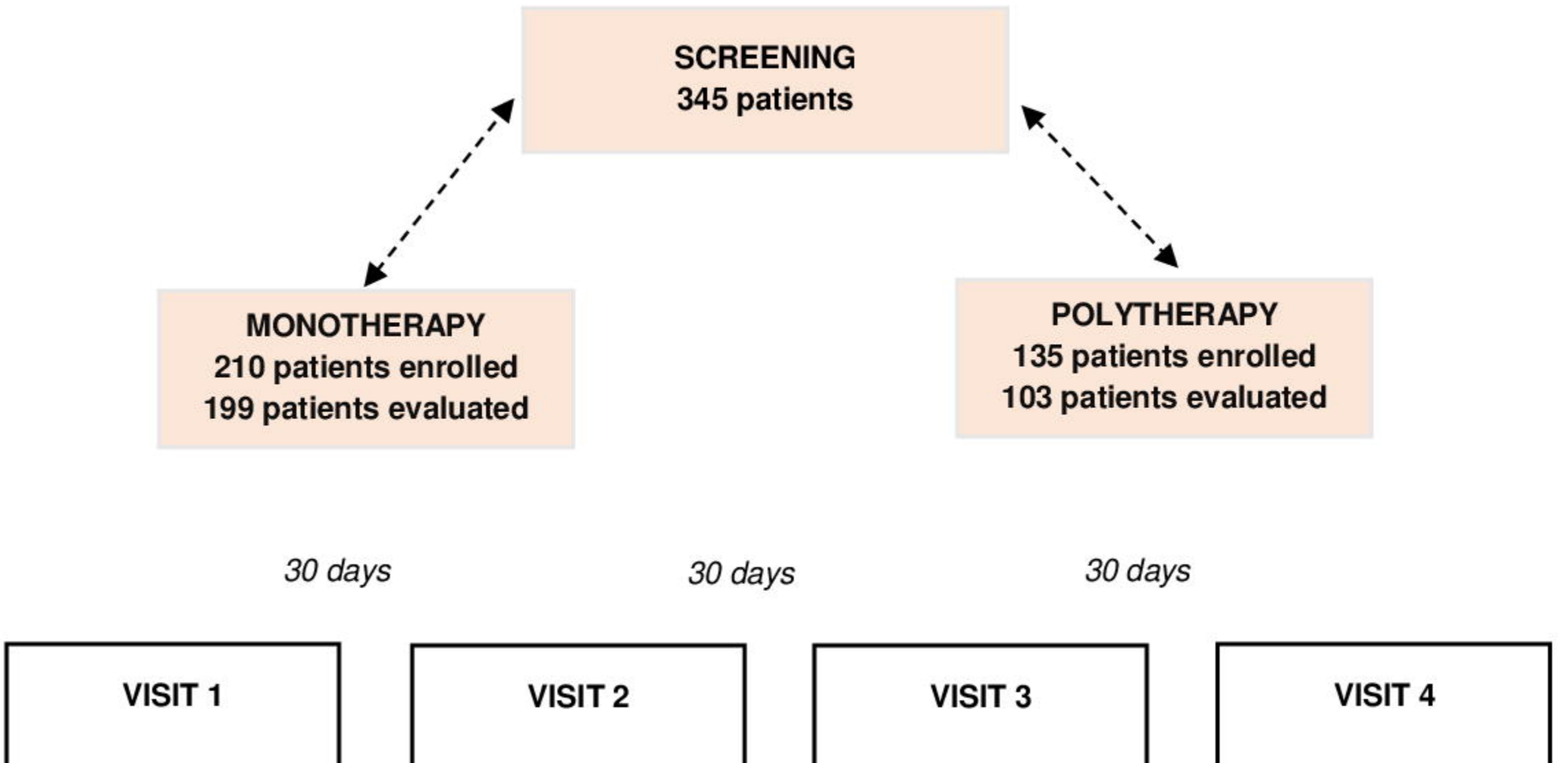
SCREENING
345 patients
MONOTHERAPY
210 patients enrolled
199 patients evaluated
POLYTHERAPY
135 patients enrolled
103 patients evaluated
30 days
30 days
30 days
VISIT 1
VISIT 2
VISIT 3
VISIT 4

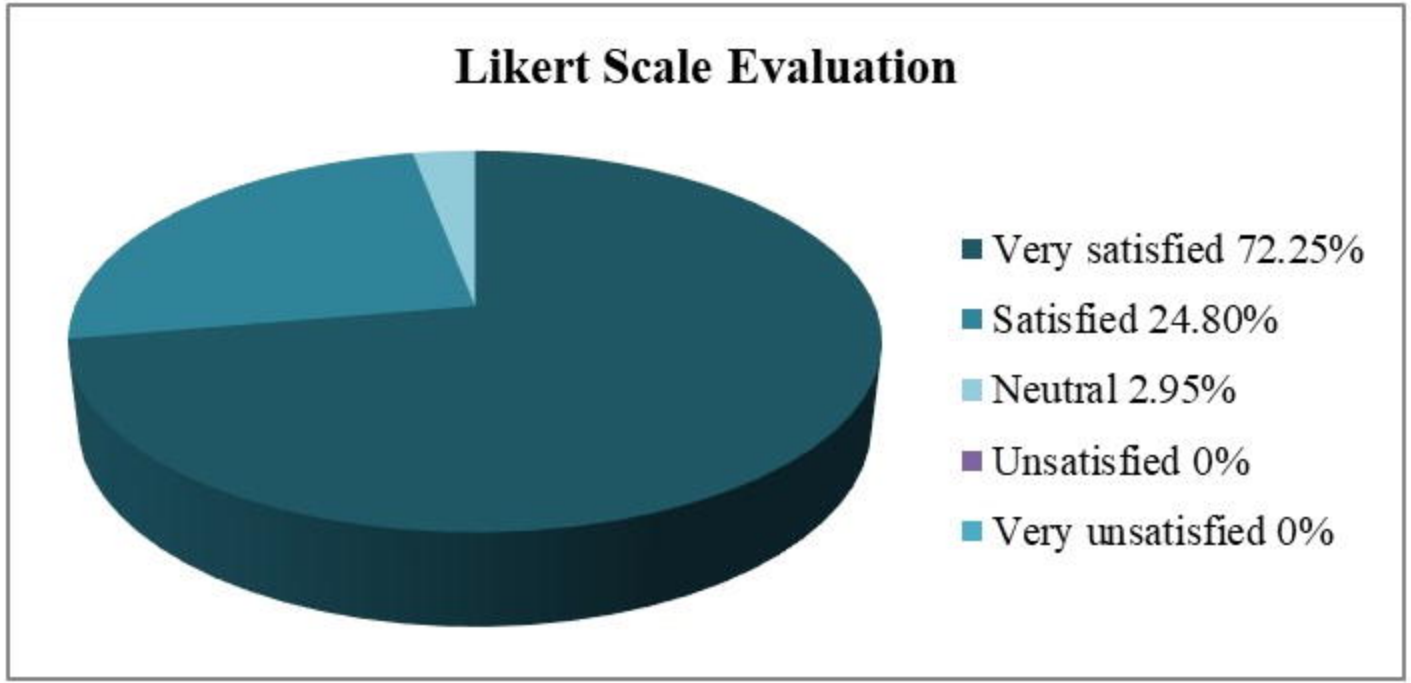
Likert Scale Evaluation
Very satisfied 72.25%
Satisfied 24.80%
Neutral 2.95%
Unsatisfied 0%
Very unsatisfied 0%