

Diagnostic accuracy of MRI in diagnosing Cardiac Sarcoidosis - A Meta-analysis

Authors:

- 1) Dr. Naqeeya Mustafa Sabuwala
Smt. NHLMMC, Ahmedabad, India
Email: Sabuwalananaqeeya@gmail.com
- 2) Dr. Dwija Raval
Dr.M.K.Shah Medical College and Research Centre, Ahmedabad, India
Email: dwijaraval2005@gmail.com
- 3) Dr. Hetvi Parikh
Smt. NHLMMC, Ahmedabad, India
Email: hetvip2808@gmail.com
- 4) Dr. Falak Saiyed
Smt. NHLMMC, Ahmedabad, India
Email: falaksaiyad2000@gmail.com
- 5) Dr. Dev Desai (Corresponding Author)
Smt. NHLMMC, Ahmedabad, India
Email: devhdesai01@gmail.com
Mobile no: +91 9173655551

Abstract:

Introduction

A multisystem inflammatory illness- sarcoidosis is characterized by organ failure, noncaseating granuloma development, and inflammation. The most frequently affected tissues are the lungs and pulmonary lymph nodes, although other tissues can also be affected including the heart. Cardiac Sarcoidosis can be lethal and result in conduction abnormalities, arrhythmias, and sudden cardiac death. As endocardial biopsy is invasive, Advanced imaging techniques, such as cardiac magnetic resonance (CMR) could be used to diagnose cardiac sarcoidosis and evaluate prognosis. Small and focal cardiac abnormalities have been successfully identified by (DE)-MRI. This comprehensive study and meta-analysis was carried out to aid in the CS diagnosis.

Methodology

Using a strategy based on the search terms- sarcoidosis and CMR/MRI separately, we searched- Pubmed, Google Scholar, Embase, Cochrane Library. Studies were disqualified if they lacked enough data to fill out a 2*2 contingency table. We strictly adhered to the Japanese criteria for diagnosing cases. Data from 12 studies with a total of 785 cases with TP of 212 was included.

Results

We found the cardiac MRI Sensitivity= 0.934 (95% CI = 0.904 to 0.964), Specificity = 0.875 (95% CI = 0.826 to 0.923), PPV= 0.752 (95% CI = 0.682 to 0.822), Youden index= 0.808 and AUC (Area under curve) for ROC plot= 0.904 with a Diagnostic accuracy of 0.892 for detecting sarcoidosis.

Conclusion

Cardiac MRI is a good and reliable screening and diagnostic tool that can be employed as a non-interventional method for diagnosis of Cardiac Sarcoidosis and future prognosis. Diagnostic accuracy of cardiac sarcoidosis using MRI, a meta-analysis.

Keywords: cardiac sarcoidosis, CMR, MRI, Japanese criteria, meta-analysis

Introduction:

Sarcoidosis is an inflammatory disease that affects many organs in the body, but mostly the lungs and lymph glands. In patients suffering from sarcoidosis, abnormal masses or nodules, inflamed tissues form in certain organs of the body.¹ Other organs are also involved, one of them being the heart. Cardiac involvement in patients with sarcoidosis is being recognized widely and is associated with poor prognosis.² Initially uncommon, now Asians have recently been reported to have significant rates of cardiac involvement and unfavorable outcomes with 5-year mortality rates for cardiac sarcoidosis (CS) ranging from 25-67%.

The clinical symptoms of cardiac sarcoidosis (CS) include heart block, atrial arrhythmias, ventricular arrhythmias, and heart failure. The diagnosis of CS can be tough due to patchy infiltration of the myocardium.³ Early options for treatment include corticosteroids or other immunosuppressive agents. Other treatments that can be used are placement of a pacemaker or implantable defibrillator to prevent sudden death.⁴

Cardiac involvement in sarcoidosis is difficult to diagnose clinically. A positive endomyocardial biopsy can help in the diagnosis of cardiac sarcoidosis but the sensitivity of biopsy is low, hence advanced imaging techniques, such as cardiac magnetic resonance (CMR) could be used to diagnose cardiac sarcoidosis and determine prognosis. Currently, CMR is recommended as the first-line imaging study for the diagnosis of CS, as it has a high negative predictive value.⁵

The patient's risk of getting exposed to ionizing radiation is very low, and myocardial MRI has a good spatial resolution. Small and focal cardiac abnormalities have been successfully identified by (DE)-MRI. This comprehensive study and meta-analysis was carried out to aid in the CS diagnosis.

Methodology:

Data collection

Using a strategy based on the search terms- sarcoidosis and CMR/MRI separately we searched -Pubmed, GoogleScholar, Embase, Cochrane Library. This systematic review was conducted following the Preferred Reporting Items for Systematic Reviews and Meta-Analyses (PRISMA) statement.

Inclusion and Exclusion Criteria

Studies were considered if they (1) evaluated the CMR's diagnostic efficacy for sarcoidosis, and (2) used Japanese diagnostic criteria. Studies were disregarded if they did not assess cardiac sarcoidosis using CMR or if there was inadequate information in them.

We preferred studies that had biopsy-proven diagnoses as a comparison over others.

Data Extraction and Quality Assessment

Two reviewers independently retrieved and carefully screened the abstracts of articles to identify relevant articles. The same two reviewers independently collected data from the primary studies including publication details (author name and year of publication), number of patients, and then the Sensitivity, Specificity, Positive Predictive Value (PPV), Area Under the Curve of Receiver Operating Characteristic Curve (AUC of ROC) and Youden's Index (YI) of DECT as diagnostic tools were calculated.

We didn't limit the searches to specific study methodologies or publication dates. We used a technique based on the search terms (sarcoidosis and magnetic resonance imaging) separately to conduct a search from January 1, 1980, to January 18, 2023, and we included all research on the reliability of diagnostic tests. Studies that lacked the data necessary to fill out a 2*2 table were disregarded. We incorporated the most recent findings from studies conducted on the same population.

Statistical analysis

Analysis of data was performed using Excel, RevMan (Review Manager, version 5.33), SPSS (Statistical Package for Social Sciences), and Stata 14.0. The presence of bias in the included studies was evaluated by Quadas-2. Individual study sensitivity and specificity were plotted on forest plots and in the receiver operating characteristic (ROC) curve. ⁶We calculated the summary positive and negative likelihood ratios using the Fagan plot analysis command strata 14.0

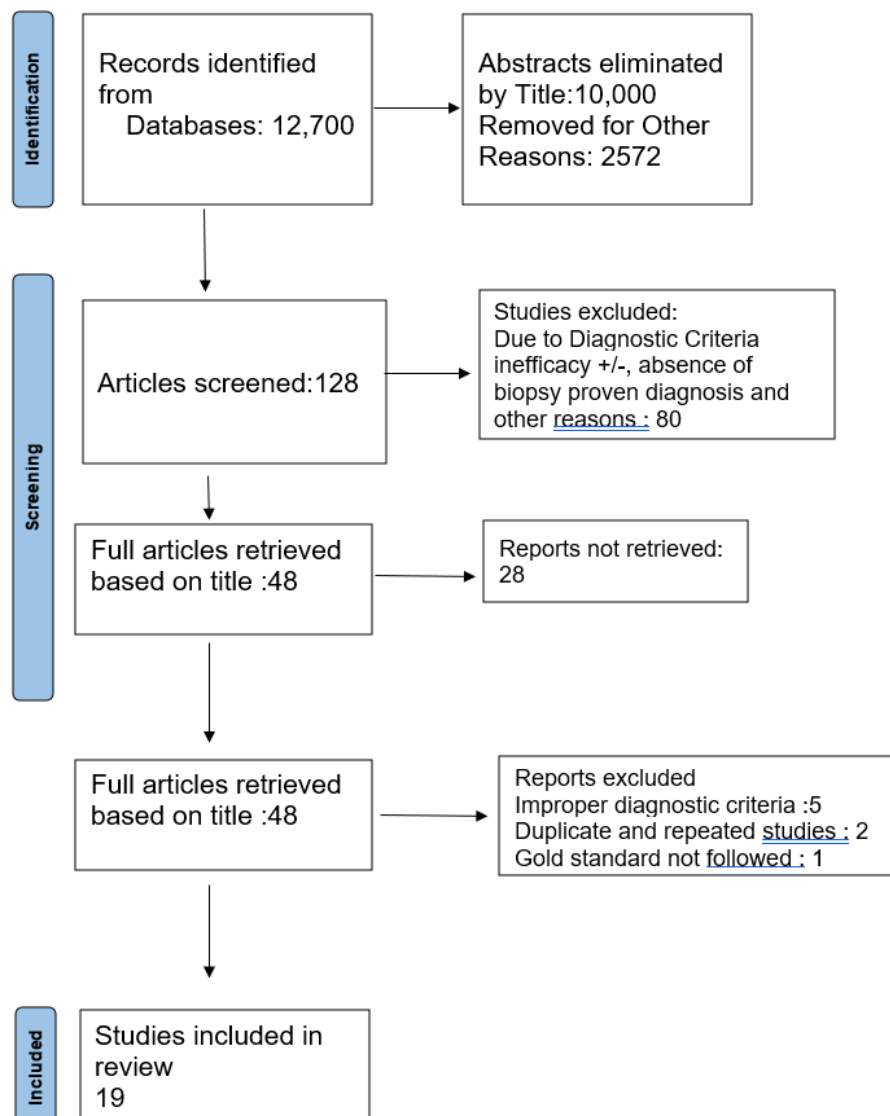


Fig. 5 PRISMA CHART

RESULTS:

PubMed database, Google Scholar search, Embase, and the Cochrane Library were used for the collection of 966 articles. After reviewing the titles, abstracts, study types, and full texts and excluding duplicate and unrelated articles, twelve studies were included in this meta-analysis. A total of 785 patients with CS were available for the meta-analysis. The main information and characteristics of the included studies are summarised in Table 1. Cardiac MRI has an overall sensitivity of 0.934 (95% CI = 0.904 to 0.964) and specificity of 0.875 (95% CI = 0.826 to 0.923) in the diagnosis of CS on forest plot (Figure 1). The summary of the ROC curve is given in Figure 2. The area under the curve was 0.904 with a Diagnostic accuracy of 0.892 for detecting sarcoidosis. The overall diagnostic odds ratio was 98.530. The Fagan plot analysis is shown in Figure 3. It showed a pretest probability of .29; a positive likelihood ratio of 7.44; A positive posterior probability of .75; a negative likelihood ratio, of 0.008; and the negative posterior probability of .03. The Youden index is 0.808. The diagnostic accuracy is 0.892. Figure 4 and Table 2 is bias study of the meta-analysis. The tool used for this is QUADAS-2 analysis.

TABLE 1: Characteristics of the study

STUDY	YEAR	NO.OF PATIENTS	SENSITIVITY	SPECIFICITY	TP	FP	FN	TN
Kouranos ⁷	2017	321	0.97	1	90	0	3	228
Manins ⁸	2009	20	1.00	0.75	8	3	0	9
Mori ⁹	2020	50	0.75	0.89	3	5	1	41
Ohira ¹⁰	2008	21	0.75	0.77	6	3	2	10
Patel ¹¹	2009	81	0.80	0.82	8	13	2	58
Smedema ¹²	2005	58	1.00	0.78	12	10	0	36
Soussan ¹³	2013	35	1.00	0.72	10	7	0	18
Stanton ¹⁴	2007	46	1.00	0.82	2	8	0	36
Tezuka ¹⁵	2015	24	1.00	0.33	15	6	0	3
Vourinen ¹⁶	2022	11	1.00	0.75	7	1	0	3
Wicks ¹⁷	2018	51	0.84	0.95	27	1	5	18

Yokoyama 18	2015	67	0.92	0.68	24	13	2	18
-----------------------	------	----	------	------	----	----	---	----

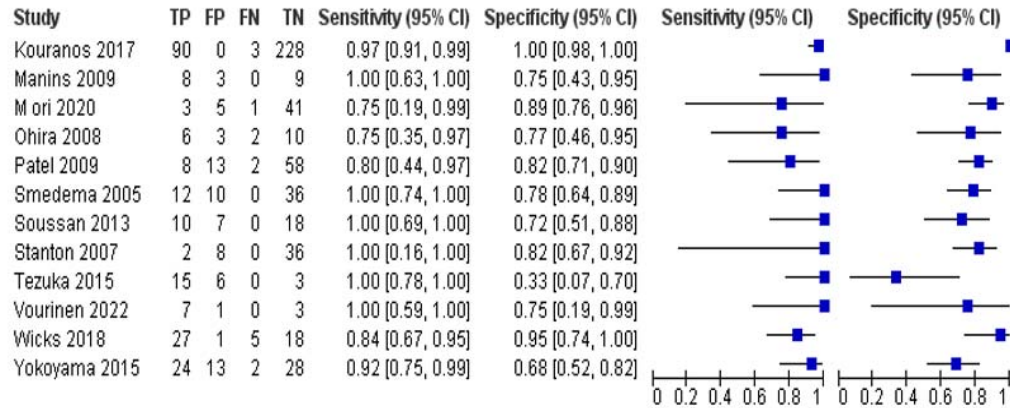


FIGURE 1: Forest plots of sensitivity and specificity. Cardiac MRI has an overall sensitivity of 0.934 (95% CI = 0.904 to 0.964) and specificity of 0.875 (95% CI = 0.826 to 0.923) in the diagnosis of CS.

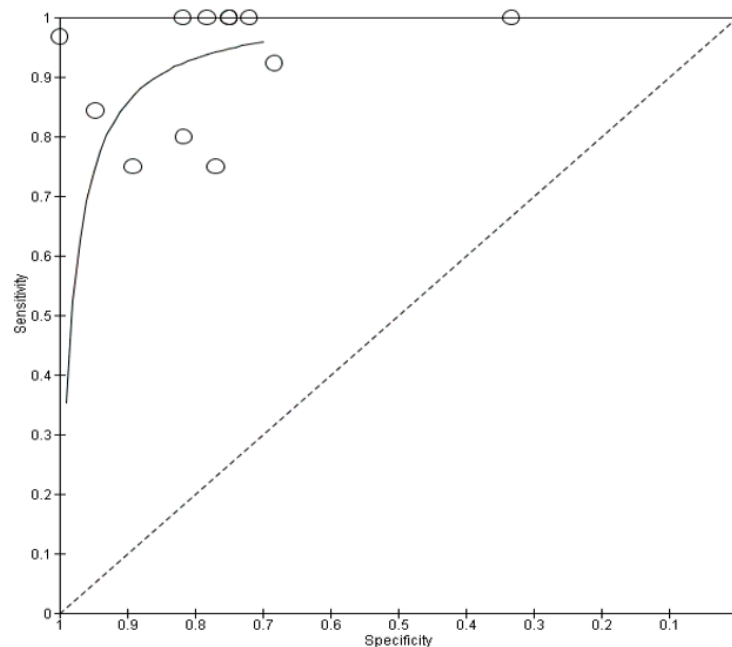


FIGURE 2: The summary of the receiver operating characteristic (ROC) curve. The area under the curve was 0.904. The overall diagnostic odds ratio was 98.530.

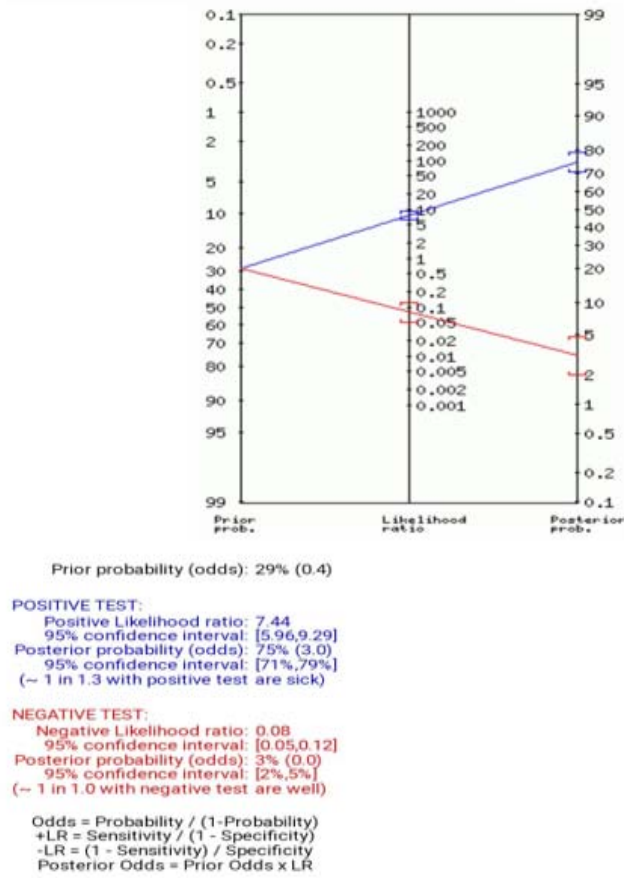


FIGURE 3 : Fagan Plot analysis. pretest probability .29; positive likelihood ratio 7.44; A positive posterior probability of .75; negative likelihood ratio, 0.008; and the negative posterior probability of .03

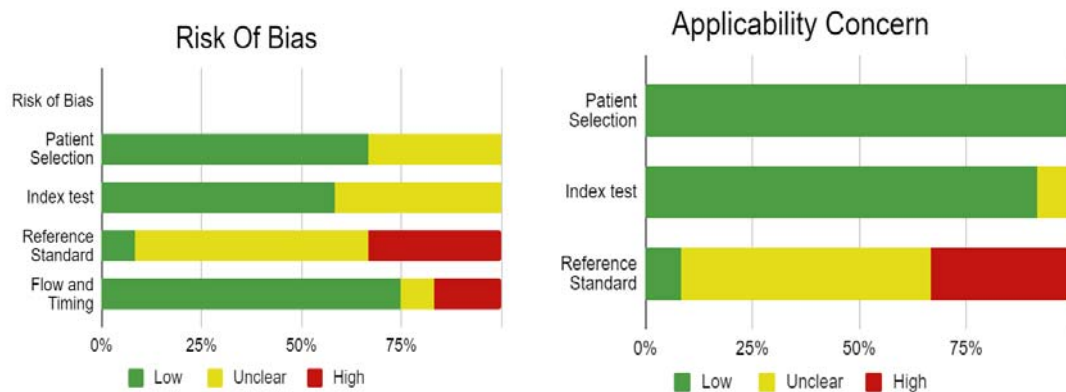

Figure 4: Bias study by QUADAS-2 analysis

Table 2: Bias Study by QUADAS-2 Analysis

No. s	Author Name and Year	Risk Of Bias				Applicability Concerns		
		Patient Selection	Index Test	Reference Standard	Flow and Timing	Patient Selection	Index Test	Reference Standard
1	Kouranos 2017	LOW	LOW	HIGH	LOW	LOW	LOW	HIGH
2	M ori 2020	LOW	LOW	HIGH	LOW	LOW	LOW	HIGH
3	Manins 2009	UNCLEAR	LOW	UNCLEAR	LOW	LOW	LOW	UNCLEAR
4	Ohira 2008	LOW	UNCLEAR	UNCLEAR	LOW	LOW	LOW	UNCLEAR
5	Patel 2009	LOW	UNCLEAR	UNCLEAR	LOW	LOW	UNCLEAR	UNCLEAR
6	Smedema 2005	UNCLEAR	LOW	UNCLEAR	LOW	LOW	LOW	UNCLEAR
7	Soussan 2013	LOW	LOW	UNCLEAR	HIGH	LOW	LOW	UNCLEAR
8	Stanton 2007	LOW	UNCLEAR	HIGH	LOW	LOW	LOW	HIGH
9	tezuka 2015	UNCLEAR	LOW	LOW	UNCLEAR	LOW	LOW	LOW
10	vourinen 2022	UNCLEAR	LOW	UNCLEAR	LOW	LOW	LOW	UNCLEAR
11	wicks 2018	LOW	UNCLEAR	UNCLEAR	LOW	LOW	LOW	UNCLEAR
12	Yokoyama 2015	LOW	UNCLEAR	HIGH	HIGH	LOW	LOW	HIGH

Discussion:

Sarcoidosis is an inflammatory disorder that affects multiple organs. In cardiac sarcoidosis, collections of immune cells form granulomas in the heart. This can result in arrhythmias, such as ventricular tachycardia or heart block. In this study, cardiac magnetic resonance (CMR) is used to diagnose cardiac sarcoidosis and evaluate prognosis. Fourteen studies were included in this study. These studies have different values of sensitivity and specificity. According to Kim¹¹, in consecutive patients with biopsy-proven extracardiac sarcoidosis who were prospectively screened for cardiac involvement, the principal finding was that DE-CMR identified myocardial abnormalities in significantly more patients than a standard clinical evaluation. They found that DE-CMR is more than twice as sensitive for cardiac involvement as current consensus criteria in patients with sarcoidosis. Smedema¹² evaluated the diagnostic role of cardiac MRI in 58 patients with suspected CS and reported that DE showed favorable sensitivity and specificity of 100% and 78%, respectively.

According to a study done by Matthew¹⁹, cardiac MRI and FDG PET had sensitivities of 92% and 81% and specificities of 72% and 82%, respectively, implicating that Cardiac MRI has a higher sensitivity but similar specificity than fluorodeoxyglucose PET. According to Jianxiong²⁰, CMR had an overall sensitivity of 0.93 (95% CI, 0.87–0.97) and specificity of 0.85 (95% CI, 0.68–0.94) in the diagnosis of cardiac sarcoidosis. They also stated that CMR holds promise for the detection of regional interstitial edema and scarring consistent with CS.

Wicks¹⁷ suggested that the presence of LGE and FDG uptake on hybrid cardiac PET/MR identifies patients at higher risk of death, arrhythmia, and decompensated heart failure and should be considered in the assessment of all patients presenting with suspected CS to determine disease activity and prognosis. According to Shimada²¹, images of the heart obtained by Gd-MRI may reflect active inflammation with interstitial edema in patients with sarcoidosis. Gd-MRI may be a useful noninvasive method for the early detection of cardiac sarcoidosis and for evaluating the effects of steroid therapy.

However, as per Sharma²², CMR has currently one limitation: it cannot be performed in patients with CS who carry cardiac devices, such as cardiac defibrillators (AICD) or pacemakers, which are contraindications to CMR. Another limitation as stated by Isobe²³, is the inability to use gadolinium to image patients with renal impairment.

The clinical presentation of Cardiac sarcoidosis may range from an accidental discovery to Heart failure, various arrhythmias, and sudden death. Hence, in addition to Cardiac MRI, various other methods like electrocardiography, 24-h Holter monitoring, echocardiography, FDG-PET, etc are used to identify this condition as early as possible. Tomas Vita²⁴ concluded that among patients with suspected CS, combining CMR and PET provides complementary value for estimating the likelihood of CS and guiding patient management. Furthermore, many studies are needed to determine the diagnostic accuracy of Cardiac MRI in patients with cardiac sarcoidosis.

Conclusion:

As a result of this meta-analysis, it is possible to diagnose cardiac sarcoidosis and screen people who may have the disease. The diagnostic efficacy of MRI increased along with the technique's advancement. It is essential to thoroughly test the patients when cardiac involvement is suspected. Corticosteroid medication should be started as soon as possible to reduce negative effects.

We suggest, based on these findings, that non-invasive imaging modalities be used to diagnose iCS without histologic evidence in order to prevent the underdiagnosis of cases that may be treated. The clinical definition of iCS requires additional assessment, which is required.

References:

1. Sarcoidosis: Symptoms, Stages, Causes, Diagnosis, and Treatment.
2. Doughan, A. R. Cardiac sarcoidosis. *Heart* **92**, 282–288 (2006).
3. Gilotra, N., Okada, D., Sharma, A. & Chrispin, J. Management of Cardiac Sarcoidosis in 2020. *Arrhythm Electrophysiol Rev* **9**, 182–188 (2020).
4. Feger, J. & Gaillard, F. Sarcoidosis (cardiac manifestations). in *Radiopaedia.org* (Radiopaedia.org, 2010). doi:10.53347/rID-9146.
5. Hussain, K., Mrin, ; & Affiliations, S. *Cardiac Sarcoidosis Continuing Education Activity*. <https://www.ncbi.nlm.nih.gov/books/NBK578192/?report=printable>.
6. Dr. Dev Desai. Dev's Formulae for Diagnostic Test Accuracy Meta analysis. (<https://www.medrxiv.org/content/10.1101/2023.03.27.23287186v1.full>.)
7. Kouranos, V. *et al.* Complementary Role of CMR to Conventional Screening in the Diagnosis and Prognosis of Cardiac Sarcoidosis. *JACC Cardiovasc Imaging* **10**, 1437–1447 (2017).
8. Manins, V., Habersberger, J., Pfluger, H. & Taylor, A. J. Cardiac magnetic resonance imaging in the evaluation of cardiac sarcoidosis: an Australian single-centre experience. *Intern Med J* **39**, 77–82 (2009).
9. Orii, M. *et al.* Diagnostic accuracy of cardiac magnetic resonance imaging for cardiac sarcoidosis in complete heart block patients implanted with magnetic resonance-conditional pacemaker. *J Cardiol* **76**, 191–197 (2020).
10. Ohira, H. *et al.* Myocardial imaging with 18F-fluoro-2-deoxyglucose positron emission tomography and magnetic resonance imaging in sarcoidosis. *Eur J Nucl Med Mol Imaging* **35**, 933–941 (2008).
11. Patel, M. R. *et al.* Detection of Myocardial Damage in Patients With Sarcoidosis. *Circulation* **120**, 1969–1977 (2009).
12. Smedema, J.-P. *et al.* Evaluation of the Accuracy of Gadolinium-Enhanced Cardiovascular Magnetic Resonance in the Diagnosis of Cardiac Sarcoidosis. *J Am Coll Cardiol* **45**, 1683–1690 (2005).
13. Soussan, M. *et al.* Clinical value of a high-fat and low-carbohydrate diet before FDG-PET/CT for evaluation of patients with suspected cardiac sarcoidosis. *Journal of Nuclear Cardiology* **20**, 120–127 (2013).
14. Stanton, K. M. *et al.* The Utility of Cardiac Magnetic Resonance Imaging in the Diagnosis of Cardiac Sarcoidosis. *Heart Lung Circ* **26**, 1191–1199 (2017).
15. Tezuka, D. *et al.* Clinical characteristics of definite or suspected isolated cardiac sarcoidosis: Application of cardiac magnetic resonance imaging and 18F-fluoro-2-deoxyglucose positron-emission tomography/computerized tomography. *J Card Fail* **21**, 313–322 (2015).
16. Vuorinen, A. M. *et al.* Cardiac Magnetic Resonance Imaging– Based Screening for Cardiac Sarcoidosis in Patients With Atrioventricular Block Requiring Temporary Pacing. *J Am Heart Assoc* **11**, (2022).
17. Wicks, E. C. *et al.* Diagnostic accuracy and prognostic value of simultaneous hybrid 18 F-fluorodeoxyglucose positron emission tomography/magnetic resonance imaging in cardiac sarcoidosis. *Eur Heart J Cardiovasc Imaging* **19**, 757–767 (2018).
18. Yokoyama, R. *et al.* Quantitative analysis of myocardial 18F-fluorodeoxyglucose uptake by PET/CT for detection of cardiac sarcoidosis. *Int J Cardiol* **195**, 180–187 (2015).
19. Aitken, M. *et al.* Diagnostic Accuracy of Cardiac MRI versus FDG PET for Cardiac Sarcoidosis: A Systematic Review and Meta-Analysis. *Radiology* **304**, 566–579 (2022).
20. Zhang, J., Li, Y., Xu, Q., Xu, B. & Wang, H. Cardiac Magnetic Resonance Imaging for Diagnosis of Cardiac Sarcoidosis: A Meta-Analysis. *Can Respir J* **2018**, 1–10 (2018).

21. Shimada, T. *et al.* Diagnosis of cardiac sarcoidosis and evaluation of the effects of steroid therapy by gadolinium-DTPA-enhanced magnetic resonance imaging. *Am J Med* **110**, 520–527 (2001).
22. Sharma, S. Cardiac imaging in myocardial sarcoidosis and other cardiomyopathies. *Curr Opin Pulm Med* **15**, 507–512 (2009).
23. Isobe, M. & Tezuka, D. Isolated cardiac sarcoidosis: Clinical characteristics, diagnosis and treatment. *Int J Cardiol* **182**, 132–140 (2015).
24. Vita, T. *et al.* Complementary Value of Cardiac Magnetic Resonance Imaging and Positron Emission Tomography/Computed Tomography in the Assessment of Cardiac Sarcoidosis. *Circ Cardiovasc Imaging* **11**, (2018).