

## AUTHORS

Shingiro Eric<sup>1,4</sup> MD, Munyemana Paulin<sup>2</sup> MD, Inyange<sup>1</sup> Sylvie MD, Rudakemwa Emmanuel<sup>2</sup> MD, Muneza Severien<sup>3</sup> MD, Hakizimana David MD<sup>1,4</sup>, Nkusi Agaba Emmy<sup>1,2</sup> MD

## AFFILIATIONS

1. University Of Rwanda College of Medicine and Health Sciences, Department of Surgery
2. Rwanda Military Hospital, Department of Neurosurgery
3. Kigali University Teaching Hospital, Department Of Neurosurgery
4. King Faisal Hospital, Kigali

## TITLE:

ASSESSMENT OF RELATIONSHIP BETWEEN CLINICAL MANIFESTATION OF CHIARI MALFORMATION TYPE I AND CEREBELLAR TONSILS HERNIATION MEASUREMENT WITHIN THE FORAMEN MAGNUM

## ABSTRACT

Chiari malformation type I (CMI) is a common condition. It is a subject of controversy from diagnosis to the management (16). Classically the diagnosis is made on clinical basis and radiological measurement of cerebellar tonsils herniation of 5mm or more below the opisthion-basion line in mid-sagittal plane (McRae line.) The aim of our study was to determine the relationship between clinical presentation of CMI and cerebellar tonsil herniation measured in three dimensions, cerebellar tonsils volume and the volume ratio (cerebellar tonsils volume/Foramen magnum volume) within foramen magnum. Can the volume of cerebellar tonsils herniation and the volume ratio (cerebellar tonsils volume/volume foramen magnum) reflect better the severity of patients with CMI? The study is the first in current literature eliciting the relationship between myelopathy severity and headache severity in CMI patients; cerebellar tonsils volume and T/F volume ratio (cerebellar tonsils volume /Foramen magnum volume)

## Methods

We conducted an observational cross-sectional analytical study. Patients with clinical and radiological confirmation of CMI evaluated on cranial cervical MRI were enrolled. Three-dimensional morphometric measures of cerebellar tonsils were made, the volume of cerebellar tonsils was calculated using ellipsoid volume formula. The transverse diameter of foramen magnum was measured and the volume of foramen magnum was calculated using sphere formula. We computed various non-parametric statistical tests and hypothesis testing to analyze variation of cerebellar tonsils uniplanar measurements, cerebellar tonsils volume, and T/F volume ratio (Cerebellar tonsils volume/ foramen magnum volume), and to analyze correlation between these measurements with the severity of myelopathy using modified Japanese orthopedics association score (mJOA) and headache severity using pain numeric rating scale. We did all the calculations in Python 3 using scipy, stats, Wilcoxon, Pearson, seaborn, and matplotlib.pyplot packages and pandas library.

## Results.

Chiari malformation type I was more common in female with 61.5% and male patients with CMI was 38.5%. The majority of patients with CMI were in fourth and fifth decade. Occipital headache was the most presenting symptom followed by limb paraesthesia, vertigo, difficulty walking and bulbar symptoms. Scoliosis associated with CMI was found in 5% while syringomyelia associated with CMI was found in 8%. According to numeric pain scale; patients with CMI mostly presented with severe headache and moderate headache with 58.3% and 41.7% respectively.

There is difference between right and left sagittal tonsils measurement; the left median sagittal measurement is 7.8 mm while the right median sagittal measurement is 8.8 mm with P-value  $<0.001$

The coronal and sagittal cerebellar tonsils measurements are statistically different. The median difference and interquartile range(IQR) between coronal and sagittal measurements were 0.6(-0.4 1.8) and p-value  $<0.001$  respectively

The finding showed a correlation between myelopathy severity and the volume of herniated cerebellar tonsils as well as correlation between myelopathy severity and T/F volume ratio (Cerebellar tonsils volume/Foramen magnum volume). There was no correlation between headache severity and sagittal measurement as we failed to reject hypothesis  $p=0.661$   
Spearman's correlation coefficient: -0.045

In contrast there was a correlation between headache severity and cerebellar tonsils volume as well as T/F volume ratio with P-value 0.03 in our study.

## Conclusion

Two dimensions radiological measurements in assessment of CMI is not reflecting the clinical severity of patients with CMI. Consideration of both clinical presentation and radiological measurement in assessment of severity of CMI is of great importance rather than only considering the cut off 5 mm descent of cerebellar tonsils herniation in midsagittal plan. Cerebellar tonsils volume and T/F volume ratio (cerebellar tonsils volume /foramen magnum volume) are the indicators of severity of myelopathy and headache severity as shown in our study.

**Key words:** Chiari malformation type I, headache and myelopathy severity, cerebellar tonsils volume and T/F volume ratio within foramen magnum.

## BACKGROUND

The description of CMI was initially based on pathological and anatomical anomaly related to the cerebellar tonsils (1). Based on anatomical definition; CMI is characterized by hindbrain deformity and elongation of the cerebellar tonsils resulting into their descent into the foramen magnum. The classic definition of CMI is radiological and is defined as herniation of the cerebellar tonsils below the foramen magnum of  $> 3$  mm in children and  $> 5$  mm in adults(2). There are questions about the most accurate radiological criteria to diagnose CMI which remain unanswered. Is CMI a sagittal disease? should we only rely on the cut off descent of cerebellar tonsils of 5mm below foramen magnum in sagittal plane in diagnosis of CMI ? can the descent of cerebellar tonsils in coronal plane reflect the severity of CMI? Can the volume of cerebellar tonsils herniation reflect better the severity of CMI ? Can T/F volume ratio (Cerebellar tonsil volume/Foramen magnum volume) reflect better the severity CMI patients .

## METHODS

This study was conducted in 3 teaching hospitals: King Faisal Hospital(KFH)- ,University Teaching Hospital of Kigali (CHUK) and Rwanda Military Hospital(RMH). All of these hospitals are major tertiary referral hospitals having neurosurgeons treating CMI. Cerebellar tonsils measurements were taken from CIM Patients who underwent cranial cervical 1.5T MRI at King Faisal Hospital 1.5T during the study period. We conducted a prospective observational cross sectional analytical study. Patients with clinical and radiological confirmation of CMI were enrolled based on most common clinical findings in patients with CMI; clinical inclusion criteria was at least patients presenting with occipital headache or neck pain, dizziness , limb paraesthesia and increased deep tendon reflex 3+ on physical exam. Cerebellar tonsils herniation at the level of foramen magnum measured in sagittal, coronal and axial planes reflecting respectively the length, height and width of the herniated cerebellar tonsils using cranio- cervical MRI was measured.

Cerebellar tonsils were considered to be ellipsoid structures and its volume was calculated based on the following formula:  $\text{volume} = \text{length} * \text{height} * \text{width} * 0.52$  (Adopted from radiological calculation of prostate volume and prostate ellipsoid formula)(17)(18). The most inlet of the foramen magnum which is the inner diameter of opisthion-basion plane was used as reference point for the above mentioned measurements. Foramen magnum was considered to be sphere

shaped; the volume of foramen magnum at the largest point was calculated using the following sphere formula:  $V=4/3\pi r^3$

Figure 1: Illustrative drawing showing measurement of cerebellar tonsils in sagittal, coronal, axial plane and transverse diameter of foramen magnum used to calculate tonsil volume, foramen magnum volume and T/F volume ratio.

## DATA MANAGEMENT AND STATISTICAL ANALYSIS

To assess the relationship between clinical manifestation of CMI and cerebellar tonsils, we computed various non-parametric statistical tests and hypothesis testing to analyze correlation and variation of cerebellar tonsils measurement in sagittal, coronal and axial planes, cerebellar tonsils volume, and the T/F volume ratio (cerebellar tonsils volume/foramen magnum volume) we run spearman rank correlation to analyze correlation between headache severity and both sagittal and coronal measurements (right and left), correlation between total cerebellar tonsils volume and foramen magnum, correlation between cerebellar tonsils volume and headache severity, myelopathy severity and tonsils volume, and T/F volume ratio and myelopathy. The hypothesis tests using Wilcoxon rank sum tests were also constructed to assess the significance of variation between right and left cerebellar tonsils measurements (coronal and sagittal measurements) in diagnosis of CMI, cerebellar volume (left and right), and sagittal and coronal measurements. we computed descriptive analysis to determine demographic characteristics of the study participants, occurrence of signs and symptoms among patients with CMI. Before running every test, we assessed the skewness of the data by variable and made a log-transformation whenever suitable likely, we found none. When we found that the data were skewed, we went on running and look for a suitable non-parametric tests. We did all the calculations in python 3 using scipy, stats, Wilcoxon, pearsonr, seaborn, and matplotlib.pyplot packages and pandas library

## RESULTS

Our study included ninth six (96) patients based on calculated sample size and statistical power of the study. the study results are presented on basis of the study objectives and statistical findings. CMHI was most common in female patients. Fifty-nine patients in ninety-six patients(59/96) representing 61.4% was female while the male patients with CMI was thirty-seven in ninth six patient(37/96) representing 38.5% of the study population. The majority of patients with CMI in our study was in fourth and fifth decade with age ranges : less than 20 years of age, between 20-30 years of age, between 40-50 years of age and Above 50 years representing 7.3%, 12.5%, 39.6%, 32.3% and 8.3% respectively. The table1 below summarizes the results on demographic information of our study population.

Referring to the figure2 above , summarizing the finding on distribution of signs among CMI patients. Myelopathy followed by sensory loss were the common finding .Upper motor neuron lesion like Hoffman sign, spasticity and clonus was found to be 8% and 18% respectively. The motor weakness as result of CMI was found in 15% of our study population. Scoliosis as result of CMI was found in 5% of our study population. The Syringomyelia was defined as cerebral spinal fluid cavitation within the spinal cord seen as high signal intensity on T2W MRI image sequence and was found in 8% of our study population.

Referring to the figure 3,4 showing headache and myelopathy severity according to NRS and modified Japanese Orthopedics Association (mJOA) respectively; patients with CMI mostly presented with severe headache, moderate headache with 58.3% and 41.7 % respectively according to pain numeric rating scale in our study. The severity of myelopathy is classified into mild , moderate and severe according to mJOA. Most patients with CMI was mild myelopathic with 81.2 % followed by moderate myelopathy with 11.5 % and severe myelopathy in 7.3% of study subjects.

Referring to the table 2 summarizing tri-dimensional radiological measurements of cerebellar tonsils herniation and foramen magnum; the measurements of herniated cerebellar tonsils within foramen magnum was done in three dimensions; coronal measurement, sagittal measurement, axial measurement and volume of herniated cerebellar tonsils was calculated.

The diameter of FM was measured and the volume of FM calculated using circle formula and transverse diameter of FM diameter respectively.

The left median coronal measurement were 11.2 mm with interquartile(IQR) range (9.3 mm- 13.1 mm)

The right median coronal measurement were 11.4 mm with interquartile range of (10.3 mm- 14.1mm)

The left median sagittal measurement were 7.8 mm with interquartile range of (6.2 mm - 10.4mm)

The right median sagittal measurement were 8.8 mm with interquartile range of (7.2mm-11.3mm)

The median transverse diameter of FM were 38.25 mm with interquartile range of ( 36.2mm- 40.63mm)

The median volume of foramen magnum were 29,571.3 mm<sup>3</sup> with interquartile range of(24,774.6mm<sup>3</sup>- 35,088.1mm<sup>3</sup>)

The median of total cerebellar tonsils volume were 2,427.61mm<sup>3</sup> with interquartile range of (1,706.01mm<sup>3</sup> - 3,625.2mm<sup>3</sup>)

The median and interquartile range of T/F volume ratio(Cerebellar tonsils volume/FM volume) were 0.082(0.053 - 0.177) respectively

Referring to the figure10 above showing the relationship between myelopathy severity and the volume of herniated cerebellar tonsils as well as the relationship between T/F volume ratio and myelopathy severity according to mJOA; there was a correlation between myelopathy severity and the volume of herniated cerebellar tonsils. The more patient has increased volume of herniated cerebellar tonsils , the more the severity of myelopathy on mJOA scale.

Referring to the figure 11 above; there is a crescendo relationship between T/F volume ratio (cerebellar tonsils volume/Foramen magnum volume) and severity of myelopathy. The increase of volume ratio is proportional to the severity of myelopathy on mJOA scale.

## DISCUSSIONS

The majority of patient with CMI in our study were in fourth and fifth decade with age ranges: less than 20 years of age, between 20-30 years of age, between 40-50 years of age and Above 50 years representing 7.3%, 12.5%, 39.6%, 32.3% and 8.3% respectively. Our findings are similar to the finding of Aska Arnautovic and colleagues in their review of study on demographics, operative treatment and outcome showed that peak age of presentation in the pediatric studies were 8 years, followed by 9 years, and in the adult series, 41 years, followed by 46 years old with female to male ratio 1.3:1(23). James R Houston et al in their study on evidence for sex difference in morphological abnormality in CMI report no sex difference of morphometric abnormalities of CMI malformation.(24)

Patients with CMI mostly presented with severe headache and moderate headache with 58.3% and 41.7% respectively according to pain numeric rating scale in our study. There was no correlation between headache severity and cerebellar descent measurement in both sagittal and coronal. In contrast there was proportional correlation between headache severity and T/F volume ratio (cerebellar tonsils volume/ foramen magnum volume ratio). Our findings are similar to the study by Dan S. Heffez et al who report no correlation between symptoms severity with extent of cerebellar descent in CMI patients (5).

Jonathan Pindrik et al in their study on clinical presentation of CMI and syringomyelia in pediatric population report headache or neck pain in 27%–70%, motor or sensory deficits of the extremities, 6%–17%, Scoliosis 18%–50%, Ataxia or gait impairment, decreased coordination 4%–9%, Spasticity 6% (27)

The syringomyelia is defined as cerebral spinal fluid cavitation within the spinal cord seen as high signal intensity on T2W image MRI sequence. Syringomyelia was found in 8% of our study population.

The pathogenesis of syringx associated with CMI has not been clarified. Many theories explaining the presence of syringx in CMI have been postulated in literature, however disorder in CSF pathway around FM is thought to be main cause of syringx (28)

The prevalence of syringx in CMI is variable among adults and pediatric population. The occurrence of a syringx in association with CMI varies between 35 to 75% in pediatric patients while in adults syringx associated with CMI varies between 40 to 60% (26).

Aitken and colleagues identified spinal syringomyelia in 12% of patients with CMI(29).

The scoliosis associated with CMI in our study is 5% of the study population.

The exact mechanism of scoliosis in association with CMI is not well known. It is thought to result from chronic compression of cervico-medullary junction by cerebellar tonsils, abnormality in posterior column tracts affect postural reflex resulting in difficulty sustaining appropriate posture thereby by subsequent scoliosis. However others authors associated the scoliosis with the presence of syringomyelia(30)

Our findings are similar to the result of Mohammad Hassan A. et al who report scoliosis resulting from isolated CMI in 3.0% (30). On the other hand Palma Ciaramitaro et al found scoliosis in 18%–50% of CMI(26)

Siri Sahib S. et al in their study on morphometric and volumetric in pediatric population with CMI found no clinical usefulness of 2D or 3D measurements that can help to differentiate symptomatic pediatric patients with CM-I from those who are asymptomatic CMI in their study hence, recommend an other diagnostic criteria beyond classic measurement of tonsil position useful for detecting best candidates for surgical management in patients with CMI(33). Our study showed a correlation between myelopathy severity and the volume of herniated cerebellar tonsils. There was a proportional increase of volume of herniated cerebellar tonsils and the severity of myelopathy. In addition, our study found a crescendo relationship between T/F volume ratio ( cerebellar tonsils volume/foramen magnum volume) and severity of myelopathy. The increase of T/F volume ratio is proportional to the severity of myelopathy. Currently, there is paucity of data in literature showing the relationship of severity of myelopathy and cerebellar tonsil volume as well as the relationship between T/F volume ratio ( cerebellar tonsils volume/foramen magnum volume ) and severity of myelopathy as discussed in our study. The T/F volume ratio (cerebellar tonsil volume/Foramen magnum volume ) and cerebellar tonsil volume can be an additional tool to be used in diagnosis and predict the severity of CMI.

## CONCLUSIONS

Many studies have showed no correlation between cerebellar tonsils herniation and clinical severity in patients with CMI and suggests other diagnostic criteria beyond standard measurement of cerebellar tonsil position which can help in determining the best candidates who need surgical management for patients suffering from CMI. Our study is the first in literature to show the correlation between the tonsil volume and T/F volume ratio( cerebellar tonsil volume/ foramen magnum volume ) and headache severity using pain numeric rating scale( NRS) as well as severity of myelopathy.

Our study shed light on cerebellar tonsil volume and T/F volume ratio as predictors of severity in patients with CMI.

Further study is recommended to find out if cerebellar tonsils volume and T/F volume ratio( cerebellar tonsil volume/foramen magnum volume) can be used as diagnostic tool in patients with CMI.

It is of great importance to calculate both sagittal and coronal measures in assessment of patients with CMI.

## LIST OF FIGURE

Figure 1 :

Illustrative drawing showing measurement of cerebellar tonsils in sagittal, coronal , axial plane and transverse diameter of foramen magnum used to calculate tonsil volume , foramen magnum volume and T/F volume ratio

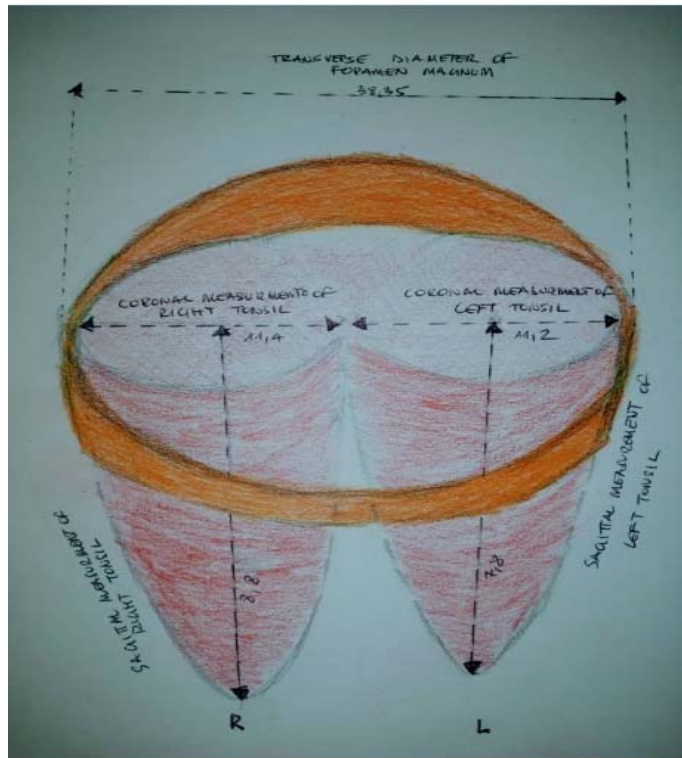


Figure 2: **Distribution of signs among patients Chiari malformation type I**

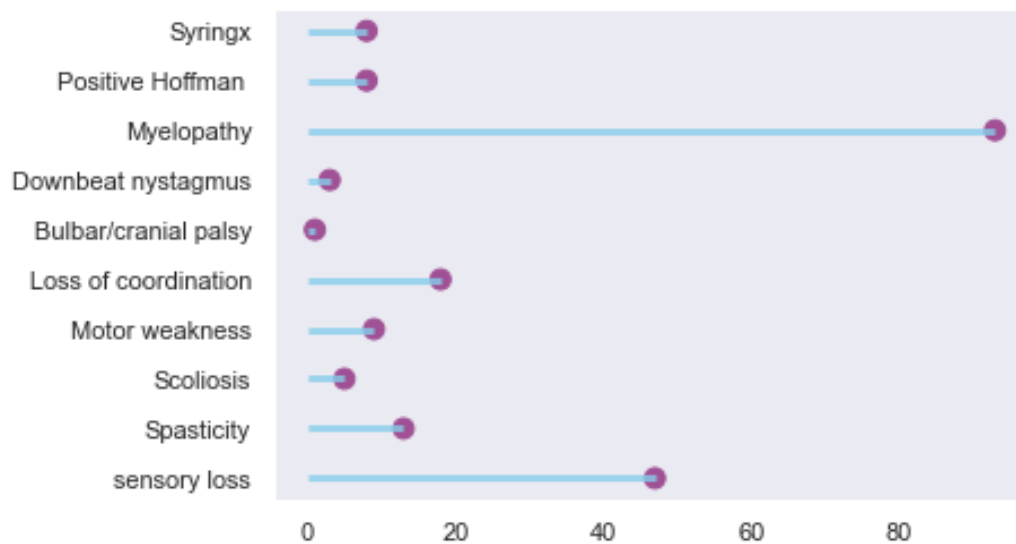




Figure 3: : **Headache severity according to pain Numeric rating scale(NRS) among CMI patients**

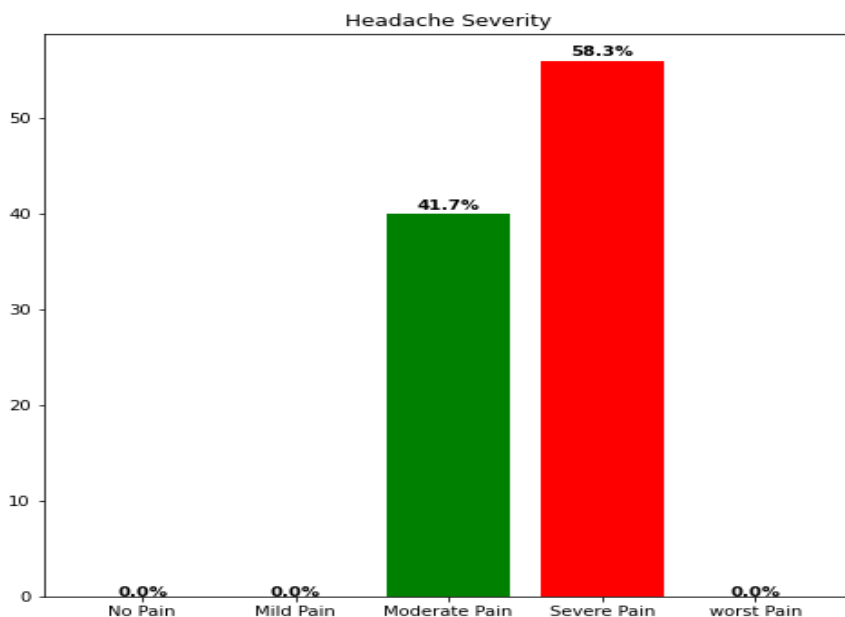


Figure 4: **Myelopathy severity according to Modified Japanese Orthopedics Association (mJOA)**

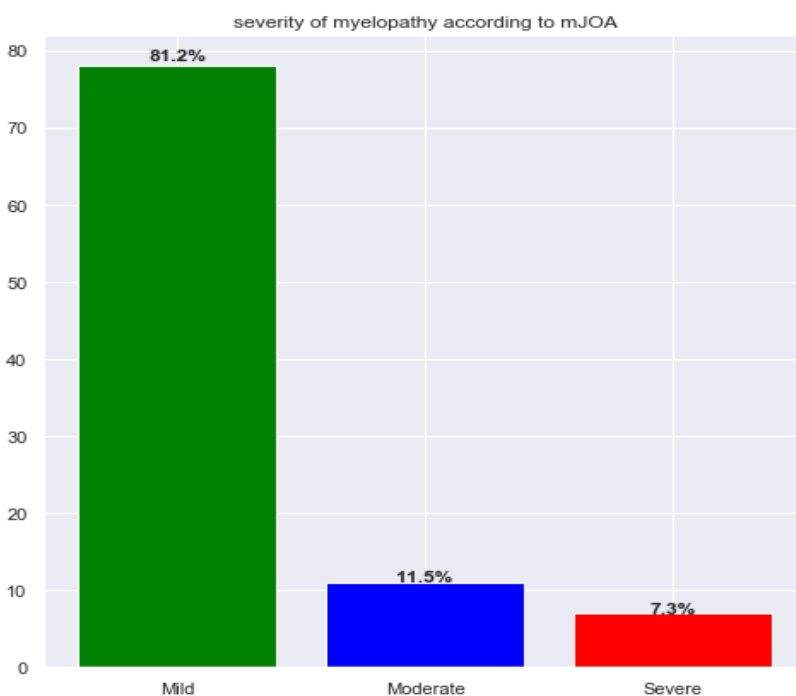
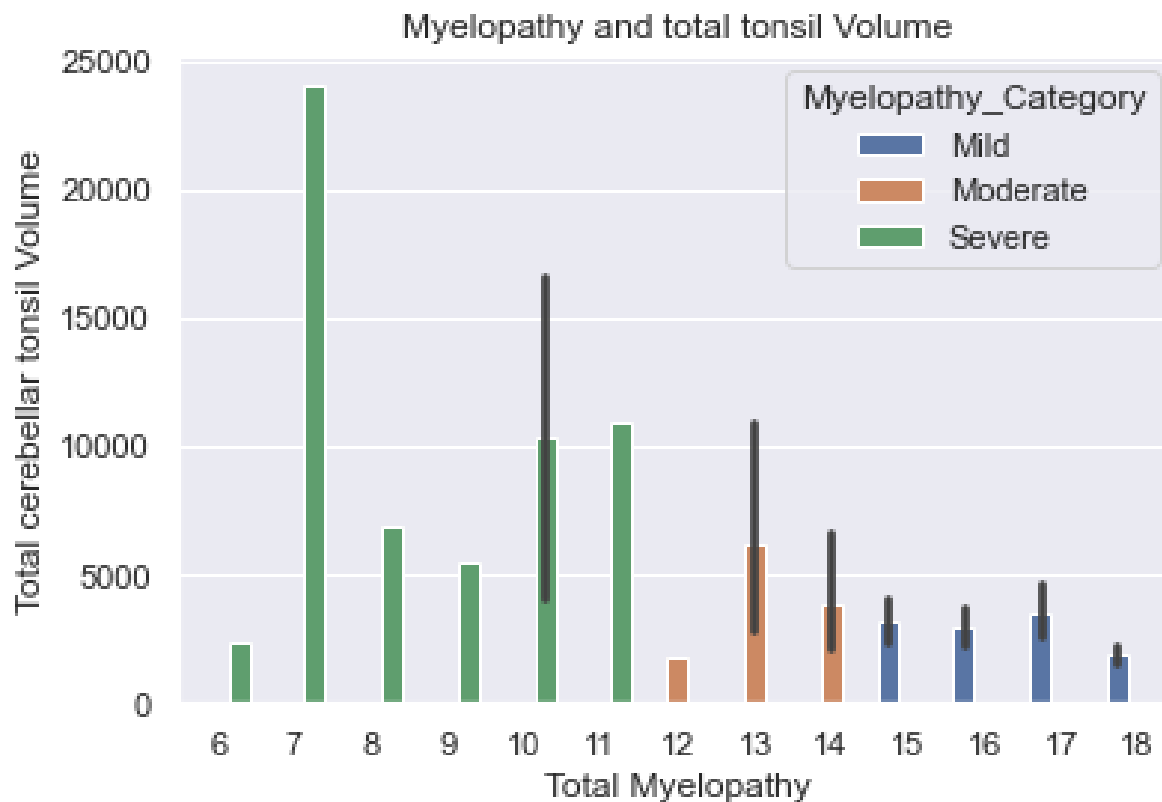


Figure 5: **Correlation between myelopathy severity and cerebellar tonsils volume**



LIST OF TABLE

TABLE 1: **Demographic information in patients with CMI**

	<b>Frequencies</b>	<b>Percentage (%)</b>
<b>Sex</b>		
Male	37	38.5
Female	59	61.4
<b>Age</b>		
< 20 years	7	7.3
20-30 years	12	12.5
30-40 years	38	39.6
40-50 years	31	32.3
Above 50 years	8	8.3

**Table2 : . RADIOLOGICAL MEASUREMENT OF FORAMEN MAGNUM AND CEREBELLAR TONSILS**

Coronal (mm)	Median(IQR)	Sagittal (mm)	Median(IQR)
left	11.2(9.3 13.1)	left	7.8(6.2 10.4)
right	11.4(10.2 14.1)	Right	8.8(7.2 11.3)
<b>Transverse Diameter of Foramen magnum</b>			
<b>Median (IQR)mm</b>			
38.35(36.2 40.63)			
<b>Foramen Magnum volume</b>			
<b>Median (IQR)mm<sup>3</sup></b>			
29,517.3(24,774.6 35,088.1)mm <sup>3</sup>			
<b>Cerebellar tonsils volume</b>			
<b>Median (IQR)</b>			
2,427.61(1,706.01 3,625.2)mm <sup>3</sup>			
<b>T/F volume ratio (Cerebellar tonsils volume/FM_ volume)</b>			
<b>Median (IQR)</b>			
0.082(0.053 0.177)			

## REFERENCES

- 1.R. Shane Tubbs & Michael J. Lyerly & Marios Loukas & Mohammadali M. Shoja & W. Jerry Oakes. The pediatric Chiari I malformation: a review. *Childs Nerv Syst* (2007) 23:1239–1250. DOI 10.1007/s00381-007-0428-0
2. A. J. Barkovich, F. J. Wippold, J. L. Sherman, C. M. Citrin. Significance of Cerebellar Tonsillar Position on MR. *AJNR*:7, September/October 1986
3. Andrea Strayer. Chiari I malformation: Clinical presentation and management. *Journal of neuroscience*. April 2001. volume 33, number 2.
4. Samuel G. McCluggage III, MD, and W. Jerry Oakes. The Chiari I malformation. *J Neurosurg Pediatr* 24:217–226, 2019. DOI: 10.3171/2019.5.PEDS18382.
5. Dan S. Heffez, John Broderick, Michael Connor, Michael Mitchell, JoAnna Galezowska, Ramin Golchini and Jugal Ghorai. Is there a relationship between the extent of tonsillar ectopia and the severity of the clinical Chiari syndrome? *Acta Neurochirurgica*. doi.org/10.1007/s00701-019-04171-1
6. W. James Gardner, A CD Robert J. Goodall. The surgical treatment of Arnold -Chiari Malformation in adults. An explanation of its mechanism and importance of encephalography in diagnosis. Cleveland clinic, and the Frank E. Bunts Educational Institute, Cleveland, Ohio. August 12, 1949.
7. Atul Goel. Is atlantoaxial instability the cause of Chiari malformation? Outcome analysis of 65 patients treated by atlantoaxial fixation. *J Neurosurg Spine* 22:116–127, 2015. doi/abs/10.3171/2014.10.SPINE14176.
8. R. Shane Tubbs, Joshua Beckma, Robert P. Naftel, Joshua J. Chern, John C. Wellons III, Curtis J. Rozzelle, Jeffrey P. Blount, and W. Jerry Oakes. Institutional experience with 500 cases of surgically treated pediatric Chiari malformation Type
9. Adams RD, Schatzki R, Scoville WB. The Arnold-Chiari malformation. Diagnosis, demonstration by intraspinal lipoidal and successful surgical treatment. *N Engl J Med* 1941;225:125–31).
10. Jennifer W. McVige, Jody Leonardo. Imaging of Chiari type I malformation and syringohydromyelia. *Neurol Clin*. 2014 Feb;32(1):95-126. doi: 10.1016/j.ncl.2013.07.002
11. Bhadelia RA, Wolpert SM. CSF flow dynamics in Chiari I malformation. *AJNR Am J Neuroradiol* 2000;21:1564.
12. Akın Akakın, Baran Yılmaz, Murat Şakir Ekşi, Türker Kılıç. Treatment of Syringomyelia due to Chiari Type I Malformation with Syringo-Subarachnoid-Peritoneal Shunt. *J Korean Neurosurg Soc* 57 (4) : 311-313, 2015. doi.org/10.3340/jkns.2015.57.4.311.
13. S Tord D. Alden, Jeffrey G. Ojemann and T.S. Park. surgical treatment of Chiari I malformation: indications and approaches. *Neurosurg Focus* 11 (1):Article 2, 2001.
14. Nkusi AE, Muneza S, Hakizimana D, Nshuti S and Munyemana P. Surgical Outcome of Chiari Malformations Type 1 in Rwanda. *SM Brain Res & Ther*. 2018; 1(1): 1001.
15. Luca Massimi, Simone Peraio, Elisabetta Peppucci, Gianpiero Tamburrini, Concezio Di Rocco. Section of the filum terminale: is it worthwhile in Chiari type I malformation? *Neurol Sci* (2011) 32 (Suppl 3):S349–S351 DOI 10.1007/s10072-011-0691-4
16. Milhorat TH, Bolognese PA, Nishikawa M, Francomano CA, McDobbell NB, Roonprapunt C, Kula RW (2009) Association of Chiari malformation type I and tethered cord syndrome: preliminary results of sectioning filum terminale. *Surg Neurol* 72:20–35
17. Nicholas R. Paterson, Luke T. Lavallée, Laura N. Nguyen, Kelsey Witiuk, James Ross, Ranjeeta Mallick, Wael Shabana, Blair MacDonald, MD; Nicola Scheida et al. Prostate volume estimations using magnetic resonance imaging and transrectal ultrasound compared to radical prostatectomy specimens. *Can Urol Assoc J* 2016;10(7-8):264-8. <http://dx.doi.org/10.5489/cuaj.3236>.
18. M.S. Nathan, K. Seenivasagam, Q. Mei, J.E.A. Wickham and R.A. Miller. Transrectal ultrasonography: why are estimates of prostate volume and dimension so inaccurate? *British Journal of Urology* (1996), 77, 401–407

19. G. Bradley Schaefer, John B. Bodensteiner James N. Thompson, Don A. Wilson. Clinical and Morphometric Analysis of the Hypoplastic Corpus Callosum. *Arch neurol*-vol48, September 1991.
20. Jeffery meadows, Michael Kraut, Michael Guarnieri, Raymond I, Haroun, and Benjamin S Carson . Asymptomatic Chiari Type I malformations identified on magnetic resonance imaging. *J Neurosurg* 92:920–926, 2000
21. Speer MC, Enterline DS, Mehlretter L, Hammock P, Joseph J, Dickerson M, et al. Chiari type I malformation with or without syringomyelia: Prevalence and genetics. *J Genet Couns.* 2003. 12:297-311. doi.org/10.1023/A:1023948921381
22. Mohamad Amin Pourhoseingholi,<sup>1</sup> Mohsen Vahedi and Mitra Rahimzadeh . sample size calculation in medical studies. *Gastroenterol Hepatol Bed Bench.* 2013 Winter; 6(1): 14–17
23. Aska Arnautovic, Bruno Splavski, Frederick A. Boop and Kenan I. Arnautovic. Pediatric and adult Chiari malformation Type I surgical series 1965–2013: a review of demographics, operative treatment, and outcomes. *J Neurosurg Pediatr* December 5, 2014
24. James R Houston, Natalie J Allen, Maggie S Eppelheimer, Jayapalli Rajiv Bapuraj<sup>3</sup>, Dipankar Biswas, Philip A Allen, Sarel J Vorster, Mark G Luciano and Francis Loth. Evidence for sex differences in morphological abnormalities in type I Chiari malformation. *The Neuroradiology Journal* 0(0) 1–9 .DOI: 10.1177/1971400919857212
25. Marcella Curone. L. G. Valentini I. Vetrano , E. Beretta • M- Furlanetto L. Chiapparini • A. Erbetta • G. Bussone. Chiari malformation type 1-related headache: the importance of a multidisciplinary study. *Neurol Sci* (2017) 38 (Suppl 1):S91–S93. DOI 10.1007/s10072-017-2915-8
26. Palma Ciaramitaro , Marilena Ferraris, Fulvio Massaro, Diego Garbossa. Clinical diagnosis—part I: what is really caused by Chiari I. *Child's Nervous System.* doi.org/10.1007/s00381-019-04206-z
27. Jonathan Pindrik and James M. Johnston Jr. Clinical Presentation of Chiari I Malformation and Syringomyelia in Children. *Neurosurg Clin N Am* 26 (2015) 509–514 .doi.org/10.1016/j.nec.2015.06.004
28. Izumi Koyanagi & Kiyohiro Houkin. Pathogenesis of syringomyelia associated with Chiari type 1 malformation: review of evidences and proposal of a new hypothesis. *Neurosurg Rev* (2010) 33:271–285 DOI 10.1007/s10143-010-0266-5
29. Aitken LA, Lindan CE, Sidney S, Gupta N, Barkovich AJ, Sorel M, Wu YW. Chiari type I malformation in a pediatric population. *Pediatr Neurol* 2009;40:449-454.
30. Mohammad Hassan A. Noureldine<sup>1</sup> & Nir Shimony<sup>1,2,3</sup> & George I. Jallo<sup>1,4</sup> & Mari L. Groves. Scoliosis in patients with Chiari malformation type I. *Child's Nervous System* doi.org/10.1007/s00381-019-04309-7
31. Sumit Thakar, Vidyasagar Kanneganti, Blaise Simplicio Talla Nwotchouang. Are Two-Dimensional Morphometric Measures Reflective of Disease Severity in Adult Chiari I Malformation?. *World Neurosurgery* 157(2 Suppl). 10.1016/j.wneu.2021.10.138
32. James R. Houston, Maggie S. Eppelheimer, Soroush Heidari Pahlavian, Dipankar Biswas, Aintzane Urbizu, Bryn A. Martin, Jayapalli Rajiv Bapuraj, Mark Luciano, Philip A. Allen, Francis Loth. A morphometric assessment of type I Chiari malformation above the McRae line: A retrospective case-control study in 302 adult female subjects. *Journal of Neuroradiology* . doi.org/10.1016/j.neurad.2017.06.006
33. Siri Sahib S. Khalsa, Ndi Geh Bryn A. Martin, Philip A. Allen, Jennifer Strahle, Francis Loth, Desale Habtzghi, Aintzane Urbizu Serrano, Daniel McQuaide, Hugh J. L. Garton, Karin M. Muraszko, and Cormac O. Maher. Morphometric and volumetric comparison of 102 children with symptomatic and asymptomatic Chiari malformation Type I. *J Neurosurg Pediatr* November 10, 2017. DOI: 10.3171/2017.8.PEDS17345.
34. Braden J. Lawrence<sup>1</sup>, Aintzane Urbizu, Philip A. Allen, Francis Loth, R. Shane Tubbs, Alexander C. Bunck, Jan Robert Kröger, Brandon G. Rocque, Casey Madura Jason A. Chen, Mark G. Luciano, Richard G. Ellenbogen, John N. Oshinski, Bermans J. Iskandar and Bryn A. Martin. Cerebellar tonsil ectopia measurement in type I Chiari malformation patients show poor interoperator reliability. *Fluids and Barriers of the CNS.* (2018) 15:33 doi.org/10.1186/s12987-018-0118-1

## **LIST OF ABBREVIATIONS**

CMI: Chiari Malformation type I

CSF: Cerebral Spinal Fluid

MRI: Magnetic Resonance Imaging

CT: Computed tomography

VAS : Visual Analog Scale

NRS: Numeric rating scale

m JOA: Modified Japanese Orthopedic Association

NRS: Numeric rating scale

CHUK: Centre Hospitalier Universitaire de Kigali.

KFH: King Faisal Hospital

RMH: Rwanda Military Hospital

UR: University of Rwanda

CMHS: College of Medicine and Health Sciences.

IRB: Institutional Review Board

MC Rae line:

FM: Foramen magnum

CSI: Chiari Severity index

T/F volume ratio: Cerebellar tonsils volume /Foramen magnum volume