

1 **Non-Metastatic Axillary Lymph Nodes Have Distinct Morphology and**
2 **Immunophenotype in Obese Breast Cancer patients at Risk for**
3 **Metastasis**

4 Qingyuan Song^{1†}, Kristen E. Muller^{2†}, Liesbeth M. Hondelink³, Roberta M. diFlorio-Alexander⁴, Margaret Karagas⁵,
5 Saeed Hassanpour^{1,5,6*}

6

7 ¹Department of Biomedical Data Science, Dartmouth College, 1 Medical Center Drive, HB 7261, Lebanon, NH,
8 03756, USA

9 ²Department of Pathology, Dartmouth-Hitchcock Medical Center, 1 Medical Center Drive, Lebanon, NH, 03756,
10 USA

11 ³Department of Pathology, Leiden University Medical Center, Albinusdreef 2, 2333 ZA Leiden, The Netherlands

12 ⁴Department of Radiology, Dartmouth-Hitchcock Medical Center, Geisel School of Medicine at Dartmouth,
13 Dartmouth Cancer Center, 1 Medical Center Drive, Lebanon, NH, 03756, USA

14 ⁵Department of Epidemiology, Dartmouth College, 1 Medical Center Drive, Lebanon, NH, 03756, USA

15 ⁶Department of Computer Science, Dartmouth College, Hanover, NH, 03755, USA

16

17 Corresponding Author:

18 Saeed Hassanpour, PhD

19 One Medical Center Drive, HB 7261

20 Lebanon, NH 03756

21 Email: Saeed.Hassanpour@dartmouth.edu

22

23 [†]These authors contributed equally to this work

24 *Corresponding author

25

26 **Abstract**

27 Obese patients have worse breast cancer outcomes than normal weight women including a 50%
28 to 80% increased rate of axillary nodal metastasis. Recent studies have shown a potential link
29 between increased lymph node adipose tissue and breast cancer nodal metastasis. Further
30 investigation into potential mechanisms underlying this link may reveal potential prognostic
31 utility of fat-enlarged lymph nodes in breast cancer patients. In this study, a deep learning
32 framework was developed to identify morphological differences of non-metastatic axillary nodes
33 between node-positive and node-negative obese breast cancer patients. Pathology review of the
34 model-selected patches found an increase in the average size of adipocytes (p-value=0.004), an
35 increased amount of white space between lymphocytes (p-value<0.0001), and an increased
36 amount of red blood cells (p-value<0.001) in non-metastatic lymph nodes of node-positive breast
37 cancer patients. Our downstream immunohistology (IHC) analysis showed a decrease of CD3
38 expression and increase of leptin expression in fat-replaced axillary lymph nodes in obese node-
39 positive patients. In summary, our findings suggest a novel direction to further investigate the
40 crosstalk between lymph node adiposity, lymphatic dysfunction, and breast cancer nodal
41 metastases.

42 **Introduction**

43 Breast cancer is the most prevalent cancer in women worldwide, and it is one of the leading
44 causes of death in women^{1,2}. Obesity, currently affecting over 30% adult females in the United
45 States³, significantly increases the incidence and worsens the prognosis of breast cancer patients,
46 among all breast cancer subtypes^{4,5}. Specifically, obese women are 50-80% more likely to
47 develop axillary metastasis⁴⁻⁶ and have higher breast-cancer specific mortality than normal
48 weight women⁷.

49
50 The interaction between obesity, immunity, and breast cancer progression is complex, and the
51 understanding of this link is an evolving field of research. Studies have demonstrated an
52 increased risk of poor cancer prognosis among obese patients with ectopic fat within organs such
53 as liver, muscle, and heart⁸⁻¹⁰. Enlarged adipocytes within ectopic fatty depots leads to the
54 secretion of pro-inflammatory cytokines and metabolic dysregulation that creates a tumor-
55 permissive micro-environment⁶. In particular, leptin has been identified as an adipokine that is
56 increased in breast cancer patients^{11,12}. The adipocyte-rich environment can also provide local
57 fatty acids to fuel tumor growth^{13,14}. With the prevalence of obesity rapidly increasing in almost
58 all countries¹⁵, further investigation of the underlying mechanisms that put obese patients at an
59 increased risk for axillary nodal metastases is crucial. Findings could support the evaluation of
60 lymph node fat content in the workup of breast cancer patients and may inform prognosis,
61 personalized treatment strategies and future targeted therapies.

62

63 As was recently shown by Almekinders et al, peritumoral breast hyperadiposity results in local
64 steroid hormone biosynthesis and endocrine dysregulation, and is a potentially strong prognostic
65 biomarker for invasive breast cancer in patients with ductal carcinoma in situ (DCIS)¹⁶. Prior
66 studies have shown that non-metastatic axillary nodes may be enlarged by excess hilar fat
67 deposition and are more commonly seen in women with obesity^{17,18}. Fat-enlarged non-metastatic
68 axillary lymph nodes identified on mammography and breast MRI are associated with a high risk
69 of axillary metastasis in obese patients with invasive breast cancer, and this association is
70 maintained when adjusting for patient and tumor characteristics¹⁹. Our hypothesis is that,
71 hyperadiposity and micro-immune dysregulation may also occur in axillary nodal adiposity,
72 creating a pre-metastatic niche for nodal metastases in women with invasive breast cancer. Our
73 study aimed to investigate whether there are changes in the morphology and immunophenotype
74 of nodal hyperadiposity and the immune microenvironment in non-metastatic axillary lymph
75 nodes that are associated with lymph node metastasis in breast cancer.

76

77 **Methods**

78 We developed and trained a deep learning (DL) framework to identify differences in
79 morphological patterns in non-metastatic axillary lymph nodes from node-positive and node-
80 negative patients. The DL model evaluated scanned whole slide images (WSI) of hematoxylin
81 and eosin (H&E) stained slides using a histological image feature extractor to learn interpretable
82 morphological patterns that may be shed light on underlying structural changes that contribute to
83 the increased risk of nodal metastases in obese patients. We also assessed possible alterations of
84 lymphatic, lipid and metabolic-related protein expression related to nodal metastasis through a
85 detailed immunohistochemistry (IHC) analysis.

86

87 **Study Population and Data Collection**

88 The study included obese patients (BMI > 30 kg/m²) with histologically confirmed invasive
89 breast cancer who underwent sentinel lymph node excision (SLN) or axillary lymph node
90 dissection (ALND) at Dartmouth-Hitchcock Medical Center (DHMC), Lebanon, NH. A total of
91 180 breast cancer cases were identified, including 88 patients with axillary nodal metastasis
92 (labeled as node-positive) and 92 patients without nodal metastasis (labeled as node-negative).
93 Patients' demographics, clinical, and pathological information including age and BMI at the time
94 of cancer diagnosis, tumor size, tumor grade, hormone receptor and HER2 status, and the
95 presence of lymphovascular invasion (LVI) were collected from electronic medical records
96 (**Table 1**). All patients included in this study did not receive neo-adjuvant treatment, including
97 chemotherapy, prior to surgery. The detailed data collection workflow is illustrated in

98 **Supplementary Figure 1.**

99

100 **Table 1. Study cohort characteristics**

	Overall	Node-Negative	Node-positive
n	180	92	88
Age (years), mean (SD)	60.9 (11.0)	62.1 (9.9)	59.6 (11.9)
BMI, mean (SD)	36.4 (5.8)	36.5 (6.1)	36.3 (5.6)
Tumor Grade, n (%)			
1	26 (14.9)	17 (19.5)	9 (10.2)
2	94 (53.7)	43 (49.4)	51 (58.0)
3	55 (31.4)	27 (31.0)	28 (31.8)
Tumor Size, mean (SD)	28.5 (23.6)	24.1 (19.6)	32.8 (26.4)
Molecular Subtypes, n (%)			
ER+ and/or PR+, HER2-	151 (84.8)	74 (82.2)	77 (87.5)

HER2+	11 (6.2)	3 (3.3)	8 (9.1)
TNBC	16 (9.0)	13 (14.4)	3 (3.4)
LVI, n (%)			
Absent	96 (55.5)	66 (76.7)	30 (34.5)
Present	77 (44.5)	20 (23.3)	57 (65.5)

101 Abbreviations: SD – standard deviation; ER – estrogen receptor; PR – progesterone receptor; HER2 –
102 human epidermal growth factor receptor 2; TNBC – triple-negative breast cancer; LVI – lymphvascular
103 invasion.

104

105 **WSI of Axillary Lymph Nodes**

106 Breast cancer patients underwent SLN or ALND at the time of their breast cancer surgery (partial
107 or full mastectomy). Lymph nodes received from breast cancer patients were grossed according
108 to standard procedures; all nodes were dissected longitudinally into 2 mm increments and
109 submitted completely for histologic evaluation of metastatic disease. Tissue is formalin fixed and
110 embedded into paraffin blocks (FFPE), sliced at 5-micron sections and stained with Hematoxylin
111 and Eosin (H&E) for microscopic evaluation. The lymph node slides were retrieved and
112 reviewed by a board-certified anatomic pathologist who specializes in breast pathology (KEM).
113 For both study sets (node-positive and node-negative groups), only the non-metastatic lymph
114 nodes were chosen for evaluation. Lymph nodes with metastatic foci of cancer were excluded
115 from the dataset. The slides were scanned using the Leica Aperio-AT2 scanner (Leica Biosystem,
116 IL, USA) at 20x and stored in SVS image format. A total of 636 WSI (303 node-positive and 333
117 node-negative) were collected.

118

119 **Lymph Node Annotation and Patch Extraction from WSI**

120 The data preparation pipeline is illustrated in **Figure 1a**. We manually annotated regions of
121 axillary lymph nodes containing lymphoid tissue and intranodal adipocytes on WSI with ASAP
122 software (Version 1.9; Netherlands, 2018). Patches of 224x224 pixels were extracted from the
123 pathologist-annotated regions at 10x magnification level to reduce the number of resulted
124 patches. A total of 575,906 patches were extracted from the annotated regions from the H&E
125 WSI (251,341 from node-positive patients and 324,565 from node-negative patients).

126

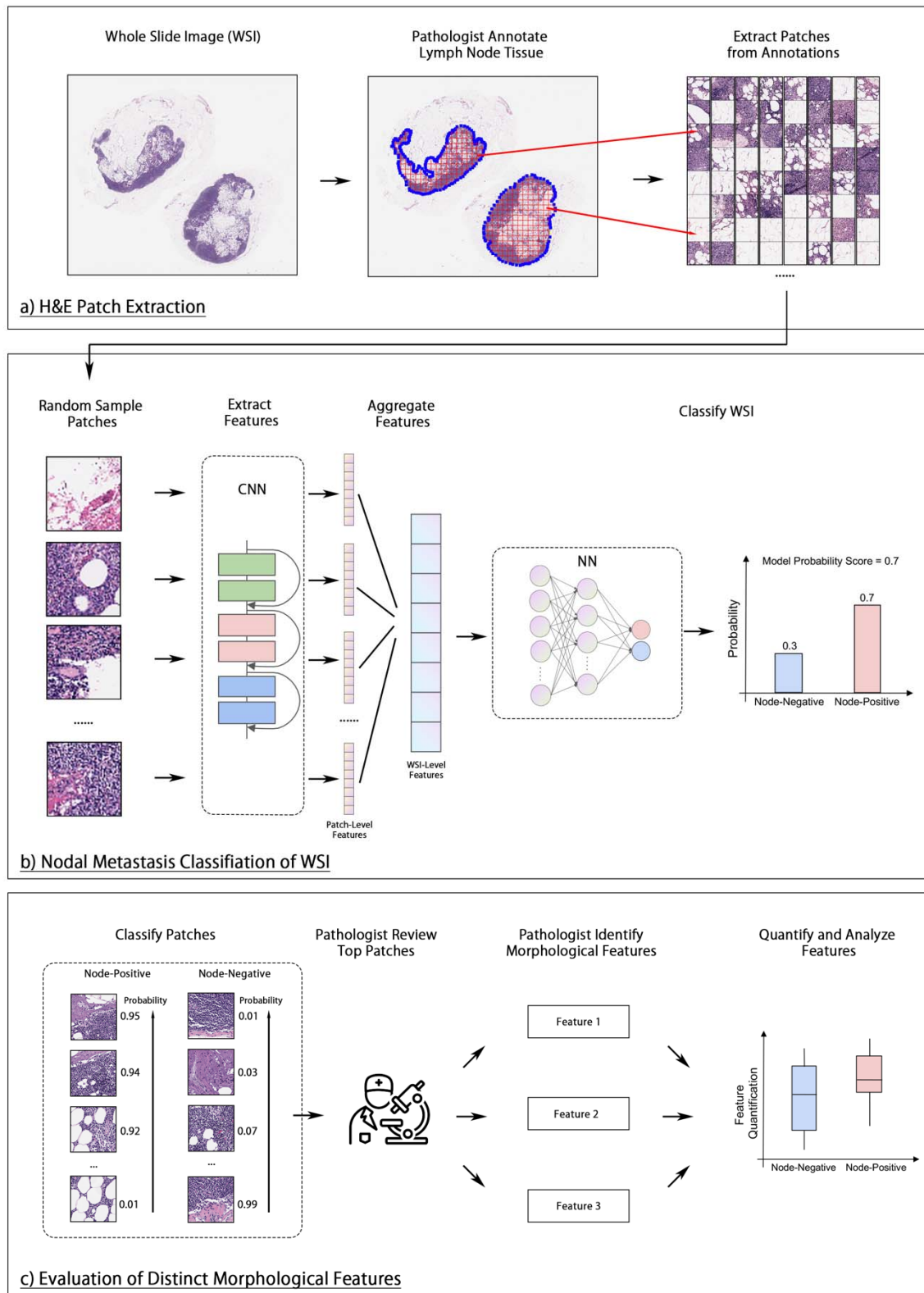
127 **DL Framework for Histological Feature Extraction**

128 We trained a DL framework based on previous work including Wulczyn et al.²⁰ and Jiang et al.²¹
129 to classify the patients' breast cancer nodal status using the non-metastatic lymph node
130 histopathology. Given that the number of WSIs per patient varied, the patients' nodal status was
131 assigned to each WSI as the label, and the model was trained to classify each WSI separately. To
132 start, randomly selected patches from each WSI were input into a convolutional neural network
133 (CNN) with a ResNet-18 backbone and with ImageNet-pretrained weights^{22,23}. The patches were
134 converted to patch-level feature vectors of size 512, which were then averaged into a WSI-level
135 feature vector. The resulting vector was fed into a 2-layer fully connected neural network (NN),
136 with a hidden layer of 128 neurons and an output size of 2, indicating predictions of node-
137 positive and negative classes. Lastly, a SoftMax normalization was applied to the model output
138 to generate a probability score. The WSI was classified as node-positive if the resulting
139 probability score was greater than 0.5, or as negative otherwise. The patient-level classification
140 was determined by averaging the probability scores of all WSIs from the patient, and then
141 converting to average score to a binary outcome using a threshold of 0.5. The model pipeline is

142 illustrated in **Figure 1b**. The detailed model training and evaluation pipeline is shown in

143 **Supplementary Materials I**.

144



146 **Figure 1. Summary of study design.** a) Pathologist's annotation of axillary lymph nodes
147 (circled in blue) and patch extraction from WSI for use in model training. b) A CNN was used to
148 extract image features from random sampled patches from a WSI. The resulted feature vectors
149 were then averaged and fed into a fully connected NN to predict the node-positive probability of
150 the WSI. c) The trained model was applied to each patch to classify their nodal status. Then, the
151 patches were ranked by their model probability score within their label groups. The top-ranked
152 patches were then examined by a pathologist to identify any differences in morphological
153 features between the node-positive and -negative classes. These features were then quantified
154 and evaluated for statistical differences.

155

156

157 **Model Visualization and Statistical Analysis of Morphological Features**

158 **Figure 1c** illustrates the process of identifying morphological features from model-selected
159 patches, as well as the quantification and statistical analysis of these features. Specifically, the
160 trained model was applied to all patches from each patient to calculate a patch-level probability
161 score. The 64 most-predictive patches from each patient were selected and grouped by patients'
162 labels for pathologist review. A pathologist (LH), blinded to the patients' labels and nodal status,
163 reviewed the selected patches to search for any distinct histological patterns between these two
164 groups. The visual findings of morphological patterns were subsequently quantified using image
165 processing techniques (**Supplementary Materials III**). The statistical significance of the
166 difference in the quantified patterns between the two classes was determined by the Mann-
167 Whitney U test, with a statistical significance considered at a p-value of less than 0.05.

168

169 **Immunohistochemistry (IHC) of Selected Markers**

170 A total of 30 lymph node samples were selected for IHC analysis. Our goal was to select a
171 combination of immunohistochemical stains to evaluate T-cell (CD3) and B-cell (CD20)

172 proportions, fatty acid metabolism (fatty acid synthase (FASN), lipoprotein lipase (LPL), Spot14,
173 and fatty acid translocase (CD36)), and adipose inflammation (leptin, adiponectin, tumor
174 necrosis factor α (TNF α), and interleukin-6 (IL6)). A radiologist selected lymph node samples
175 based on the extent of fat replacement within the lymph nodes using radiologic studies, with 15
176 samples obtained from patients who had positive lymph nodes and 15 from patients who had
177 negative lymph nodes. Specifically, the 15 node-positive samples had high levels of fat
178 replacement, while and 15 node-negative samples had low levels of fat replacement. Briefly,
179 slides were deparaffinized and rehydrated. Primary antibodies against CD3 (Leica Cat# PA0553,
180 Clone LN10), CD20 (Leica Cat# NCL-L-CD20-L26, Clone L26), FASN (Abcam Cat# ab22759,
181 Polyclonal), LPL²⁴, Spot14²⁵, CD36 (Abcam Cat# ab133625, Clone EPR6573), leptin (Abcam
182 Cat# ab16227, Polyclonal), adiponectin (Abcam Cat# ab75989, Clone EPR3217), TNF (Abcam
183 Cat# ab220210, Clone TNFA/1172), IL6 (Abcam Cat# ab9324, Clone 1.2-2B11-2G10) were
184 processed and stained according to manufacturers' protocols. The expression level of the IHC
185 stains were digitally quantified; the detailed methodology is described in **Supplementary**
186 **Materials IV**.

187

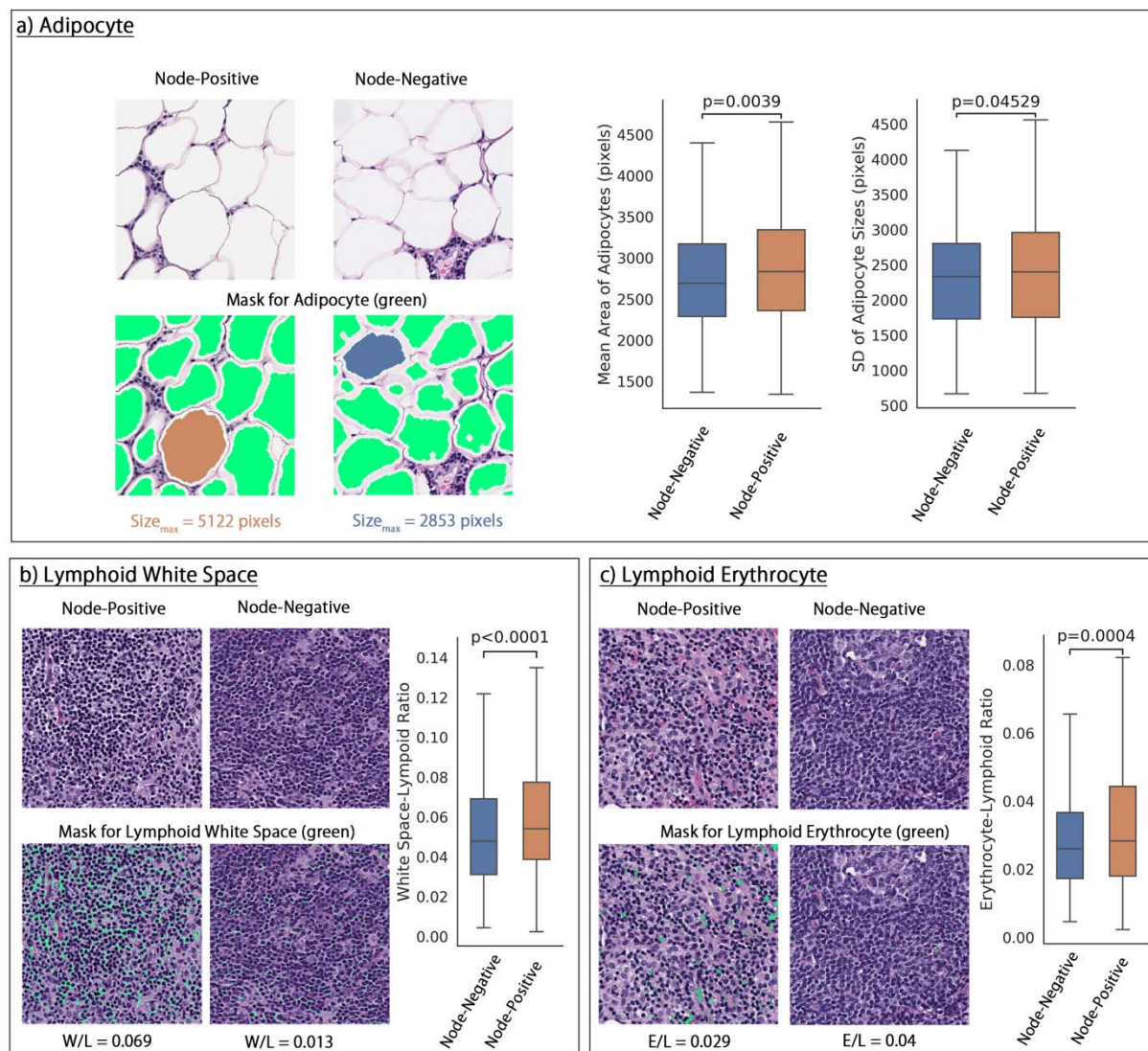
188 **Results**

189

190 **DL-Aided Interpretation of Distinct Lymph Node Morphological Features**

191 Our DL-model trained on the WSI patches achieved an area under the receiver operating
192 characteristic curve (AU-ROC) of 0.67 (95% CI: 0.59, 0.75) and the detailed model performance
193 is shown in **Supplementary Table 2**. Through examination of the model-selected predictive
194 patches, pathologists identified notable variations in histological characteristics between node-

195 positive and node-negative cases. These differences were confirmed with our quantification
196 metrics using our image analysis pipeline. The histological features that are considered and
197 quantified in this study include: the number and size of adipocytes, the proportion of white space
198 between the lymphocytes (defined by white space-lymphoid ratio), and the proportion of red
199 blood cells (defined by erythrocyte-lymphoid ratio). The results and some examples of these
200 measurements and analysis are illustrated in **Figure 2**, and further details on the quantification
201 methodology can be found in the **Supplementary Materials III**. Based on this analysis, we
202 found that node-positive patients had significantly larger intranodal adipocytes, with more
203 variation in adipocyte size, compared to node-negative patients (**Figure 2a**). Additionally, there
204 was a significantly increased proportion of white space between lymphocytes and red blood cells
205 in the lymph node parenchyma of node-positive patients (**Figures 2b and 2c**). These
206 morphological differences were also significantly distinct between the model-assigned labels
207 (**Supplementary Figure 2**). In addition, we found a positive correlation between the increase of
208 average size of adipocytes and higher white space-lymphoid ratio with a Pearson's correlation
209 coefficient of 0.26 (p-value < 0.001) (**Supplementary Figure 3**).



210

211 **Figure 2. Distinct morphological characteristics of axillary lymph nodes in node-positive**
 212 **and node-negative patients. a)** Left: example quantification of lymph node adipocyte size in
 213 fat-enlarged lymph nodes of node-positive and node-negative patients. The largest adipocyte
 214 from each patch was highlighted with orange or blue. Right: Box and whisker plot of the average
 215 size of adipocyte and the standard deviation (SD) of the adipocyte size in node-positive and -
 216 negative samples. **b)** Left: example quantification of lymphoid white space defined by white
 217 space-lymphoid ratio (W/L). Right: Box and whisker plot of the W/L ratio in node-positive and -
 218 negative samples. **c)** Left: example quantification of red blood cells in lymph node tissue defined
 219 by erythrocyte-lymphoid ratio (E/L). Right: Box and whisker plot of the E/L ratio in node-
 220 positive and -negative samples.

221

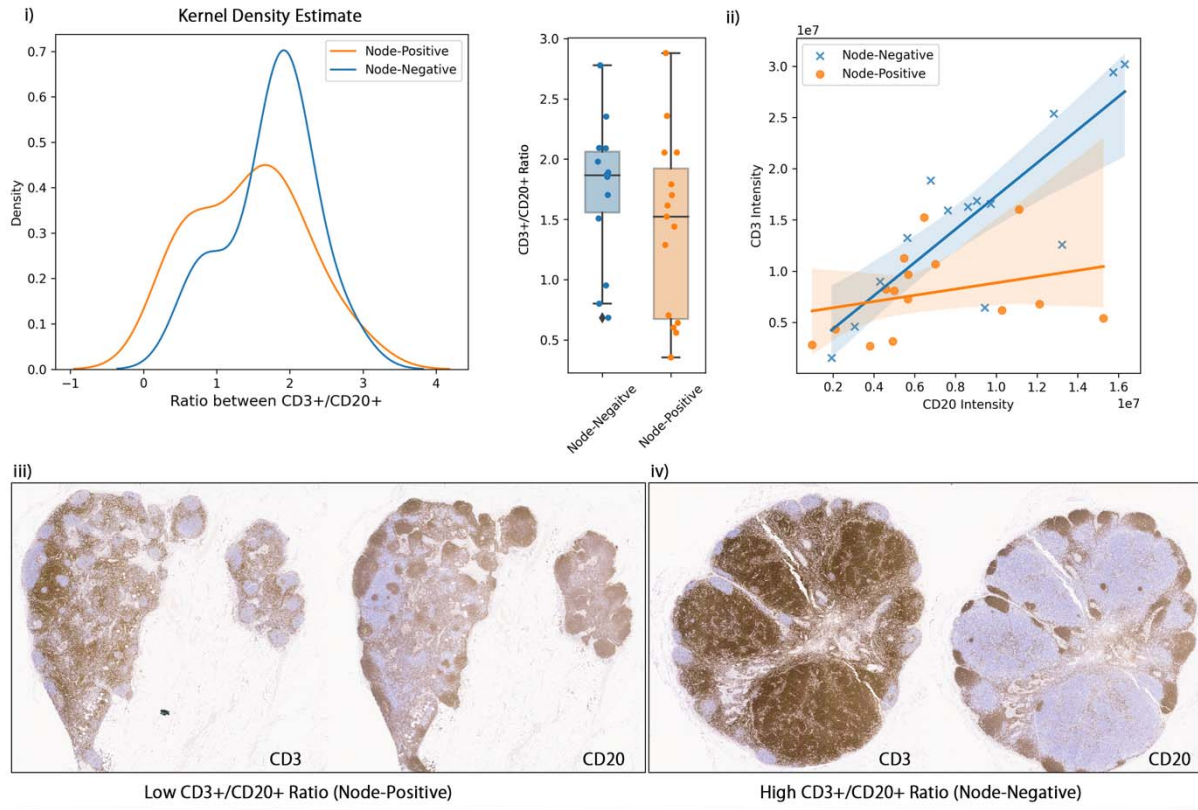
222 **Distinct Expression Pattern of IHC Stains in Lymph Node Lymphoid and Adipose Tissue**

223 Although no statistical significance was observed in IHC analysis, the visual analysis of
224 distribution of IHC stains revealed that fat-enlarged lymph nodes from node-positive patients
225 displayed a lower ratio between CD3+ and CD20+ cells due to decreased CD3 expression
226 (**Figure 3a-i**). Specifically, the intensity of CD3 and CD20 is significantly positively correlated
227 in non-fatty lymph nodes from node-negative samples (Pearson correlation coefficient = 0.83, p-
228 value < 0.001), while no significant correlation was found in fat-replaced lymph nodes from
229 node-positive samples (Pearson correlation coefficient = 0.28, p-value = 0.30) (**Figure 3a-ii**).
230 **Figure 3a-iii** and **3a-iv** show examples of a fat-replaced node from a node-positive patient with
231 low CD3+/CD20+, and a non-fat-replaced node from a node-negative patient with high
232 CD3+/CD20+.

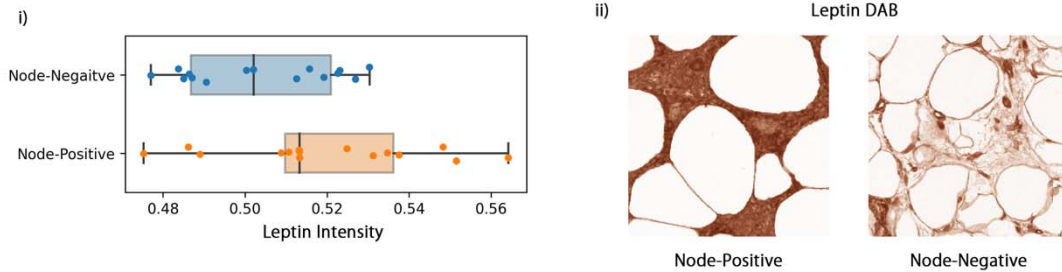
233 Additionally, node-positive patients exhibited a slightly elevated expression of leptin in
234 intranodal and perinodal adipose tissue compared to node-negative patients, as demonstrated in
235 **Figure 3b**.

236

a) Expression of CD3 and CD20 in Lymphoid Tissue



b) Expression of Leptin in Adipose Tissue



237

238 **Figure 3. Distribution of IHC markers in node-positive and node-negative group. a-i)**
 239 **Kernel density estimate and boxplot of the distribution of CD3+/CD20+ ratio. a-ii)** Correlation
 240 **between CD3 and CD20 expression in node-positive and -negative node with fitted regression**
 241 **line. a-iii)** A fat-enlarged node from a node-positive patient with low CD3+/CD20+ **a-iv)** A non-
 242 **fat-replaced node from a node-negative patient with high CD3+/CD20+.** **b-i)** Boxplot of
 243 **distribution of leptin intensity in node-positive and -negative groups. b-ii)** Comparison of leptin
 244 **stain in the adipose tissue of lymph nodes from a node-positive and a node-negative sample.**

245

246 **Discussion**

247 This study investigated the morphological and immunophenotypic characteristics of non-
248 metastatic axillary lymph nodes in relation to the risk of breast cancer nodal metastasis among
249 obese women. Using a cohort of 88 node-positive and 92 node-negative patients, we trained a
250 DL model that identified several morphological features that were distinct in axillary lymph
251 nodes from node-positive patients, including significantly increased average size of adipocytes, a
252 higher proportion of white spaces within lymphoid tissue, and a higher number of erythrocytes
253 within lymphoid tissue. In addition, the IHC analysis of 30 axillary lymph node samples showed
254 visually decreased CD3 staining, lower CD3+/CD20+ ratios, and elevated leptin expression
255 around nodal adipocytes in the fat-enlarged lymph nodes from node-positive patients, compared
256 to that of the normal lymph nodes from node-negative patients. Together, our findings suggest a
257 link between several histological characteristics of fat-enlarged axillary lymph nodes and nodal
258 metastases in breast cancer patients with obesity.

259

260 Patients with obesity have poor breast cancer outcomes that are not fully explained by BMI.
261 Understanding the factors that contribute to variable breast cancer outcomes among obese
262 women is essential for improving prognosis and identifying potential therapeutic targets,
263 ultimately leading to better outcomes for patients. Studies have found that adipose cells can
264 contribute to cancer progression through the release of signaling molecules, extracellular proteins,
265 lipids, and metabolites that support tumor growth and invasiveness²⁶. Although there have many
266 studies examining ectopic adipose located in and around organs, there is limited research
267 investigating the impact of ectopic adipose within lymph nodes on cancer outcomes²⁷. A recent
268 study found that the presence of enlarged axillary lymph nodes due to fat infiltration as seen on

269 mammography and breast MRI is correlated with an increased risk of nodal metastasis in obese
270 patients when adjusting for patient and tumor characteristics²⁸. Our current study identified
271 distinct histologic features that could contribute to a tumor-promoting adipose microenvironment.
272 These findings support the prior radiology study, which has shown a strong correlation between
273 fat-enlarged lymph nodes and nodal metastases.

274
275 We observed a greater average adipocyte size within the axillary lymph nodes of node-positive
276 patients than that of the node-negative patients. Previous research has established a link between
277 adipocyte hypertrophy in obesity and impaired metabolic regulation that promotes cancer
278 progression, partly due to hypoxia of hypertrophic adipocytes that leads to altered adipokine
279 secretion and ensuing inflammation^{29,30}. Our results align with those of Almekinders et al., who
280 found a correlation between larger adipocyte size and an elevated risk of invasive breast cancer
281 following DCIS. This underscores the importance of further research on the role of ectopic nodal
282 adiposity in the development breast cancer nodal metastases.

283
284 Metastatic sites are selectively primed by the primary tumor even before the initiation of
285 metastases occurs, resulting in a premetastatic niche that is devoid of cancer cells³¹. Our H&E
286 analysis revealed an increased proportion of lymphoid white spaces in lymph nodes from node-
287 positive patients, and a positive correlation between lymphoid white spaces and average
288 adipocyte size of the lymph node. Possible theories to account for the increased white space
289 include interstitial fluid caused by impaired lymphatic drainage³², which promotes migration of
290 tumor cells. Another potential explanation is the production of soluble factors, such as protein
291 ligands or extracellular matrix-modifying proteins that are secreted to induce remodeling of

292 metastatic sites to facilitate seeding, as explained by Follain et al.³³. Dissemination of tumor-
293 related factors such as cytokines, chemokines, growth factors, matrix metalloproteinases, and
294 extracellular vesicles have been shown to promote dissemination of tumor cells through
295 stimulation of inflammatory cells and angiogenesis and leads to remodeling of the extracellular
296 matrix³³⁻³⁵. We also noted an increased amount of extravasated red blood cells in the nodal tissue
297 in the node-positive group. While speculation, one theory could be linked to the increased shear
298 fluid forces in vessels with circulating tumor cells, while endothelial cell remodeling to promote
299 tumor cell extravasation can provide an explanation for the leaky vasculature³⁶. Vascular leakage
300 and immunosuppression, among others, are changes that have been described in the
301 premetastatic niche³¹. We postulate that the increased white space and extravasated red blood
302 cells could represent morphologic evidence of preconditioning the premetastatic niche in axillary
303 lymph nodes in obese patients.

304

305 Our downstream IHC analysis identified changes in immune cell populations and adipokine
306 expression, though these results were not statistically significant due to the limited statistical
307 power of the small sample size. CD3 intensity was lower in fat-enlarged nodes which may reflect
308 decreased immune function in fatty nodes, a finding that has been reported in lymph nodes of
309 obese mice^{37,38}. Furthermore, non-metastatic fat-enlarged nodes of patients with nodal metastases
310 also showed increased leptin expression. Leptin has been shown to stimulate proliferation,
311 angiogenesis, migration, and metastasis in breast cancer cell lines by activating the oncogenic
312 pathways, and high serum leptin is associated with a 2 to 5 fold increase in breast cancer risk³⁹.
313 Therefore, increased leptin expression in fat-enlarged nodes may also be associated with a pre-
314 metastatic niche and requires further evaluation through large-scale IHC analysis.

315 This study is a pioneering effort that examined premetastatic morphological changes in lymph
316 nodes in a cohort of obese patients with a focus on fat-enlarged lymph nodes. There are several
317 limitations to our study. This study has a relatively small sample size, in particular the IHC
318 analysis was restricted to a small number of patients due to limited resources. Our data is from a
319 single institution which may introduce bias and chance of overfitting, and thereby limit the
320 generalization of the findings to a larger population. A nested cross-validation approach was
321 employed to mitigate this limitation. Further validation of our findings is necessary through
322 large-scale, multi-center studies that include a diverse patient population and external validation.
323 Our study is also limited by its retrospective design. Histologic images of axillary lymph nodes
324 obtained via sentinel lymph node biopsy or axillary lymph node dissection were only available at
325 the time of the cancer diagnosis. This temporal limitation makes it challenging to establish a
326 causal relationship between the identified lymph node features and the development of nodal
327 metastasis. However, future studies could investigate the relationship between lymph node
328 characteristics related to nodal hyperadiposity and prospective outcomes, including cancer
329 recurrence, distant metastasis, and long-term patient prognosis to further investigate the clinical
330 importance of the identified morphological features.

331
332 In conclusion, this study identified several histopathological and immunohistochemical features
333 of non-metastatic axillary lymph nodes in relation to breast cancer nodal metastases in obese
334 breast cancer patients. These findings suggest that nodal hyperadiposity and alterations in the
335 immune microenvironment may play a role in forming the pre-metastatic niche. These results
336 emphasize the need for further research into increased lymph node adiposity. Further
337 investigation into features of the fat-enlarged nodes that account for an increased likelihood of

338 nodal metastases is warranted. If confirmed with larger studies, fatty axillary lymph nodes may
339 serve as a prognostic imaging marker that can be readily assessed in all breast cancer patients.
340 This information may inform personalized treatment strategies and targeted therapies in obese
341 patients with breast cancer.
342

343 **Funding**

344 This research was supported in part by grants from the US National Library of Medicine
345 (R01LM012837 & R01LM013833), the US National Cancer Institute (R01CA249758) and
346 National Institute of General Medical Sciences (P20GM104416).

347 **Competing Interests**

348 The authors declare no competing interests.

349 **Ethics Approval and Consent to Participate**

350 This study, and the usage of human participant data in this project, were approved by the
351 Dartmouth-Hitchcock Medical Center Institutional Review Board (IRB) with a waiver of
352 informed consent.

353 **Author's Contributions**

354 All authors contributed to the design of the study. KEM was responsible for collecting the
355 histological and immunohistochemistry image data, LMH annotated the histology images and
356 RdA collected the clinical data. LMH and KEM analyzed and interpreted the histological
357 findings. QS cleaned and preprocessed the data, implemented the methods, conducted statistical
358 analysis, and wrote the first draft of the manuscript. All authors revised the manuscript and
359 verified the presented results. SH supervised the study.

360 **Data Availability Statement**

361 The datasets used and/or analyzed during the current study are available from the corresponding
362 author on reasonable request.

363

364 **References**

- 365 1. Loibl S, Poortmans P, Morrow M, Denkert C, Curigliano G. Breast cancer. *The Lancet*.
366 2021;397(10286):1750-1769. doi:10.1016/S0140-6736(20)32381-3
- 367 2. Harbeck N, Penault-Llorca F, Cortes J, et al. Breast cancer. *Nature Reviews Disease*
368 *Primers*. 2019;5(1):1-31. doi:10.1038/s41572-019-0111-2
- 369 3. Products - Data Briefs - Number 360 - February 2020. Published February 28, 2020.
370 Accessed March 9, 2020. <https://www.cdc.gov/nchs/products/databriefs/db360.htm>
- 371 4. Lorincz AM, Sukumar S. Molecular links between obesity and breast cancer. *Endocrine-*
372 *Related Cancer*. 2006;13(2):279-292. doi:10.1677/erc.1.00729
- 373 5. Lohmann AE, Soldera SV, Pimentel I, et al. Association of Obesity With Breast Cancer
374 Outcome in Relation to Cancer Subtypes: A Meta-Analysis. *J Natl Cancer Inst*.
375 2021;113(11):1465-1475. doi:10.1093/jnci/djab023
- 376 6. Devericks EN, Carson MS, McCullough LE, Coleman MF, Hursting SD. The obesity-
377 breast cancer link: a multidisciplinary perspective. *Cancer Metastasis Rev*. 2022;41(3):607-
378 625. doi:10.1007/s10555-022-10043-5
- 379 7. Manson JE, Aragaki AK, Rossouw JE, et al. Menopausal Hormone Therapy and Long-term
380 All-Cause and Cause-Specific Mortality: The Women's Health Initiative Randomized
381 Trials. *JAMA*. 2017;318(10):927-938. doi:10.1001/jama.2017.11217
- 382 8. Kanwal F, Kramer JR, Mapakshi S, et al. Risk of Hepatocellular Cancer in Patients With
383 Non-Alcoholic Fatty Liver Disease. *Gastroenterology*. 2018;155(6):1828-1837.e2.
384 doi:10.1053/j.gastro.2018.08.024
- 385 9. Zhang XM, Dou QL, Zeng Y, Yang Y, Cheng ASK, Zhang WW. Sarcopenia as a predictor
386 of mortality in women with breast cancer: a meta-analysis and systematic review. *BMC*
387 *Cancer*. 2020;20(1):172. doi:10.1186/s12885-020-6645-6
- 388 10. S S, R O, K K, et al. The Prognostic Impact of Pericardial Fat Volumes in Resected Non-
389 small Cell Lung Cancer. *Annals of surgical oncology*. 2020;27(2). doi:10.1245/s10434-019-
390 07703-2
- 391 11. Sánchez-Jiménez F, Pérez-Pérez A, de la Cruz-Merino L, Sánchez-Margalet V. Obesity and
392 breast cancer: role of leptin. *Front Oncol*. 2019;9:596. doi:10.3389/fonc.2019.00596
- 393 12. Delort L, Rossary A, Farges MC, Vasson MP, Caldefie-Chézet F. Leptin, adipocytes and
394 breast cancer: Focus on inflammation and anti-tumor immunity. *Life Sci*. 2015;140:37-48.
395 doi:10.1016/j.lfs.2015.04.012
- 396 13. Micallef P, Wu Y, Bauzá-Thorbrügge M, et al. Adipose Tissue—Breast Cancer Crosstalk
397 Leads to Increased Tumor Lipogenesis Associated with Enhanced Tumor Growth. *Int J Mol*
398 *Sci*. 2021;22(21):11881. doi:10.3390/ijms222111881

- 399 14. Zaidi N, Lupien L, Kuemmerle NB, Kinlaw WB, Swinnen JV, Smans K. Lipogenesis and
400 lipolysis: the pathways exploited by the cancer cells to acquire fatty acids. *Prog Lipid Res.*
401 2013;52(4):585-589. doi:10.1016/j.plipres.2013.08.005
- 402 15. Boutari C, Mantzoros CS. A 2022 update on the epidemiology of obesity and a call to
403 action: as its twin COVID-19 pandemic appears to be receding, the obesity and
404 dysmetabolism pandemic continues to rage on. *Metabolism.* 2022;133:155217.
405 doi:10.1016/j.metabol.2022.155217
- 406 16. Almekinders MMM, Schaapveld M, Thijssen B, et al. Breast adipocyte size associates with
407 ipsilateral invasive breast cancer risk after ductal carcinoma in situ. *NPJ Breast Cancer.*
408 2021;7:31. doi:10.1038/s41523-021-00232-w
- 409 17. diFlorio Alexander RM, Haider SJ, MacKenzie T, Goodrich ME, Weiss J, Onega T.
410 Correlation between obesity and fat-infiltrated axillary lymph nodes visualized on
411 mammography. *Br J Radiol.* 2018;91(1089):20170110. doi:10.1259/bjr.20170110
- 412 18. Keshavarz E, Ahangaran A, Pouya EK, Maheronnaghsh R, Chavoshi M, Rouzrokh P.
413 Effects of Obesity on Axillary Lymph Node Structure: Association of Hilar Fat Deposition
414 and Alterations in Cortex Width. *Maedica (Bucur).* 2020;15(1):99-104.
415 doi:10.26574/maedica.2020.15.1.99
- 416 19. diFlorio Alexander RM, Song Q. Fat-Infiltrated Axillary Lymph Nodes are Associated with
417 Node Positive Breast Cancer in Obese Patients.
- 418 20. Wulczyn E, Steiner DF, Xu Z, et al. Deep learning-based survival prediction for multiple
419 cancer types using histopathology images. *PLOS ONE.* 2020;15(6):e0233678.
420 doi:10.1371/journal.pone.0233678
- 421 21. Jiang S, Zanazzi GJ, Hassanpour S. Predicting prognosis and IDH mutation status for
422 patients with lower-grade gliomas using whole slide images. *Sci Rep.* 2021;11(1):1-9.
423 doi:10.1038/s41598-021-95948-x
- 424 22. He K, Zhang X, Ren S, Sun J. Deep Residual Learning for Image Recognition.
425 *arXiv:151203385 [cs]*. Published online December 10, 2015. Accessed March 3, 2021.
426 <http://arxiv.org/abs/1512.03385>
- 427 23. Deng J, Dong W, Socher R, Li L, Kai Li, Li Fei-Fei. ImageNet: A large-scale hierarchical
428 image database. In: *2009 IEEE Conference on Computer Vision and Pattern Recognition.* ;
429 2009:248-255. doi:10.1109/CVPR.2009.5206848
- 430 24. Lupien LE, Bloch K, Dehairs J, et al. Endocytosis of very low-density lipoproteins: an
431 unexpected mechanism for lipid acquisition by breast cancer cells [S]. *Journal of Lipid*
432 *Research.* 2020;61(2):205-218. doi:10.1194/jlr.RA119000327
- 433 25. Wells WA, Schwartz GN, Morganelli PM, Cole BF, Gibson JJ, Kinlaw WB. Expression of
434 “Spot 14” (THRSP) predicts disease free survival in invasive breast cancer:

- 435 immunohistochemical analysis of a new molecular marker. *Breast Cancer Res Treat.*
436 2006;98(2):231-240. doi:10.1007/s10549-005-9154-z
- 437 26. D'Esposito V, Ambrosio MR, Giuliano M, et al. Mammary Adipose Tissue Control of
438 Breast Cancer Progression: Impact of Obesity and Diabetes. *Front Oncol.* 2020;10:1554.
439 doi:10.3389/fonc.2020.01554
- 440 27. Li M, Xian H chun, Tang YJ, Liang X hua, Tang Y ling. Fatty acid oxidation: driver of
441 lymph node metastasis. *Cancer Cell International.* 2021;21(1):339. doi:10.1186/s12935-
442 021-02057-w
- 443 28. diFlorio-Alexander RM, Song Q, Dwan D, et al. Fat-enlarged Axillary Lymph Nodes are
444 Associated with Node-Positive Breast Cancer in Obese Patients. *medRxiv.* Published online
445 February 18, 2021:2021.02.17.20246504. doi:10.1101/2021.02.17.20246504
- 446 29. Stenkula KG, Erlanson-Albertsson C. Adipose cell size: importance in health and disease.
447 *American Journal of Physiology-Regulatory, Integrative and Comparative Physiology.*
448 2018;315(2):R284-R295. doi:10.1152/ajpregu.00257.2017
- 449 30. Ye RZ, Richard G, Gévry N, Tchernof A, Carpentier AC. Fat Cell Size: Measurement
450 Methods, Pathophysiological Origins, and Relationships With Metabolic Dysregulations.
451 *Endocrine Reviews.* 2022;43(1):35-60. doi:10.1210/endrev/bnab018
- 452 31. Peinado H, Zhang H, Matei IR, et al. Pre-metastatic niches: organ-specific homes for
453 metastases. *Nat Rev Cancer.* 2017;17(5):302-317. doi:10.1038/nrc.2017.6
- 454 32. Lent-Schochet D, Jialal I. Physiology, Edema. In: *StatPearls.* StatPearls Publishing; 2022.
455 Accessed January 15, 2023. <http://www.ncbi.nlm.nih.gov/books/NBK537065/>
- 456 33. Bruni D, Angell HK, Galon J. The immune contexture and Immunoscore in cancer
457 prognosis and therapeutic efficacy. *Nat Rev Cancer.* 2020;20(11):662-680.
458 doi:10.1038/s41568-020-0285-7
- 459 34. Weber M, Hauschild R, Schwarz J, et al. Interstitial dendritic cell guidance by haptotactic
460 chemokine gradients. *Science.* 2013;339(6117):328-332. doi:10.1126/science.1228456
- 461 35. Pastushenko I, Brisebarre A, Sifrim A, et al. Identification of the tumour transition states
462 occurring during EMT. *Nature.* 2018;556(7702):463-468. doi:10.1038/s41586-018-0040-3
- 463 36. Follain G, Osmani N, Azevedo AS, et al. Hemodynamic Forces Tune the Arrest, Adhesion,
464 and Extravasation of Circulating Tumor Cells. *Dev Cell.* 2018;45(1):33-52.e12.
465 doi:10.1016/j.devcel.2018.02.015
- 466 37. García Nores GD, Cuzzone DA, Albano NJ, et al. Obesity but not high-fat diet impairs
467 lymphatic function. *Int J Obes.* 2016;40(10):1582-1590. doi:10.1038/ijo.2016.96

- 468 38. Weitman ES, Aschen SZ, Farias-Eisner G, et al. Obesity impairs lymphatic fluid transport
469 and dendritic cell migration to lymph nodes. *PLOS ONE*. 2013;8(8):e70703.
470 doi:10.1371/journal.pone.0070703
- 471 39. Tenvooren I, Jenks MZ, Rashid H, et al. Elevated leptin disrupts epithelial polarity and
472 promotes premalignant alterations in the mammary gland. *Oncogene*. 2019;38(20):3855-
473 3870. doi:10.1038/s41388-019-0687-8
- 474
- 475