medRxiv preprint doi: https://doi.org/10.1101/2023.04.13.23288483; this version posted April 17, 2023. The copyright holder for this preprint (which was not certified by peer review) is the author/funder, who has granted medRxiv a license to display the preprint in perpetuity. All rights reserved. No reuse allowed without permission.

Transcutaneous Spinal Cord Stimulation to Reduce Phantom Limb Pain in People with a Transtibial Amputation

Ashley N Dalrymple[1,2,3,4], Lee E Fisher[5,6,7,8], Douglas J Weber[1,2,9]

1 Department of Mechanical Engineering, Carnegie Mellon University, Pittsburgh, PA, USA
2 NeuroMechatronics Lab, Carnegie Mellon University, Pittsburgh, PA, USA
3 Department of Biomedical Engineering, University of Utah, Salt Lake City, UT, USA
4 Department of Physical Medicine & Rehabilitation, University of Utah, Salt Lake City, UT, USA
5 Department of Physical Medicine & Rehabilitation, University of Pittsburgh, Pittsburgh, PA, USA
6 Department of Bioengineering, University of Pittsburgh, Pittsburgh, PA, USA
7 Center for Neural Basis of Cognition, Pittsburgh, PA, USA
8 Rehab Neural Engineering Labs, University of Pittsburgh, Pittsburgh, PA, USA
9 Neuroscience Institute, Carnegie Mellon University, Pittsburgh, PA, USA

Correspondence

Douglas J Weber
dougweber@cmu.edu
5000 Forbes Ave, Wean 1323
Pittsburgh, PA, USA 15213

Ashley N Dalrymple
ashley.dalrymple@utah.edu
20 S 2030 E, BPRB 506D
Salt Lake City, UT, USA 84132

Key words: transtibial amputation, phantom limb pain, transcutaneous spinal cord stimulation, spinal reflexes, neuromodulation

NOTE: This preprint reports new research that has not been certified by peer review and should not be used to guide clinical practice.

medRxiv preprint doi: https://doi.org/10.1101/2023.04.13.23288483; this version posted April 17, 2023. The copyright holder for this preprint (which was not certified by peer review) is the author/funder, who has granted medRxiv a license to display the preprint in perpetuity. All rights reserved. No reuse allowed without permission.

SUMMARY

Phantom limb pain (PLP) is debilitating and affects over 70% of people with a lower-limb amputation. In chronic pain conditions, there are plastic changes at the spinal cord level, typically causing increased excitability. Altered spinal excitability can be measured using reflexes, such as the posterior root-muscle (PRM) reflex. Neuromodulation of the spinal cord can be used to reduce chronic pain in a variety of conditions. Here we propose using a non-invasive neuromodulation method, transcutaneous spinal cord stimulation (tSCS), to reduce PLP in people with transtibial amputation. We recruited three participants, two males (5- and 9-years post-amputation; alcohol-induced neuropathy, traumatic) and one female (3 months post-amputation; diabetic dysvascular) for this 5-day study. We measured their pain using pain questionnaires and the pain pressure threshold test. We measured spinal reflex excitability using PRM reflexes. We provided neuromodulation using tSCS at 30 Hz with a carrier frequency of 10 kHz for 30 minutes/day for 5 days. Mean pain scores decreased from 34.0±7.0 on Day 1 to 18.3±6.8 on Day 5, which was a clinically meaningful difference. Two participants had increased pain pressure thresholds across the residual limb (Day 1: 5.4±1.6 lbf; Day 5: 11.4±1.0 lbf). PRM reflexes had high thresholds (59.5±6.1 μC) and low amplitudes, suggesting that in PLP, reflexes are hypoexcitable. After 5 days of tSCS, reflex thresholds decreased significantly (38.6±12.2 μC; $p<0.001$). Overall, tSCS is a non-invasive neuromodulation method that can reduce PLP and modulate spinal reflexes.

medRxiv preprint doi: https://doi.org/10.1101/2023.04.13.23288483; this version posted April 17, 2023. The copyright holder for this preprint (which was not certified by peer review) is the author/funder, who has granted medRxiv a license to display the preprint in perpetuity. All rights reserved. No reuse allowed without permission.

INTRODUCTION

It is estimated that over 3.6 million people will be living with a lower-limb amputation in the United States by the year 2050 (1). The most common causes of a limb amputation are vascular disease (such as diabetes) or trauma (2). Following a lower-limb amputation, over 70% of people experience phantom limb pain (PLP) (1,3,4), with up to 50% of people reporting experiencing PLP within 24 hours post-amputation (5). Pain in the residual limb, as well as phantom sensations, are also common following limb amputation (6,7). PLP can be described as sharp, shooting, squeezing, burning, itching, piercing, dull, tingling, throbbing and/or cramping (6,8,9). PLP is menacing and significantly reduces the quality of life of those who suffer from it (4). People who experience PLP have described how their PLP disrupts their sleep, appetite, ability to focus, hygiene, socialization, and mood (10).

Currently available treatments for PLP include mirror therapy, pharmacologic treatments, and surgical interventions. While there are many reports of the success of mirror therapy (11,12), a systematic review highlighted a lack of evidence for its efficacy (13). Pharmacologic treatments often lose efficacy over time, have serious side effects, and can lead to addiction (6,14). Surgical interventions are typically explored when other treatment methods have been ineffective (15). Surgical interventions are permanent solutions with varied efficacy for PLP (16,17), and can also result in a loss of function, such as a further loss of sensation (18,19).

Neuromodulatory therapies using electrical stimulation have been used, more so as a last resort, for treating PLP (7). Transcutaneous electrical nerve stimulation (TENS) is a non-invasive neuromodulatory technique in which electrical stimulation is delivered through adhesive electrodes placed on the surface of the skin near the pain site and has been shown to relieve PLP, but is more effective for stump pain (20,21). Epidural spinal cord stimulation (eSCS) of the dorsal columns has been shown to reduce PLP (22–25). It has been suggested that when eSCS electrodes are placed more laterally, targeting the dorsal spinal roots, further pain relief can be achieved (26,27). Furthermore, when electrodes are placed over the dorsal root ganglion (DRG), such as with DRG stimulation, the distal limbs can be more focally targeted, which is beneficial for reducing PLP (28,29).

The dorsal spinal cord and DRG are targets-of-interest because these structures undergo plastic changes with chronic and neuropathic pain. Repetitive activation of nociceptive fibers in the peripheral nerves resulting from the nerve transection induces windup in the spinal dorsal horn neurons, increasing their excitability (30,31). Furthermore, sprouting of axotomized nerve fibers in the dorsal horn contributes to allodynia and hyperalgesia (32,33). DRG neurons ectopically discharge and are hyperexcitable due to changes in ion channel expression and sprouting (34–36). An increase in spinal cord excitability has also been reported in the absence of sensation (37), following peripheral nerve injury (38), and in painful diabetic neuropathy (39–41).

Transcutaneous spinal cord stimulation (tSCS) is a non-invasive neuromodulation method that targets the dorsal spinal roots, similar to eSCS (42,43). To date, tSCS has been used to improve motor recovery after spinal cord injury (44–47) as well as to reduce spasticity (48–50). tSCS has not yet been tested as a therapy for chronic or neuropathic pain.

In this study, we elicited reflexes to determine if the spinal cord of people with a lower-limb amputation and PLP had altered excitability. We hypothesized that spinal reflexes would be hyperexcitable, indicated by lower thresholds to evoke the reflexes, because of the neuropathic

medRxiv preprint doi: https://doi.org/10.1101/2023.04.13.23288483; this version posted April 17, 2023. The copyright holder for this preprint (which was not certified by peer review) is the author/funder, who has granted medRxiv a license to display the preprint in perpetuity. All rights reserved. No reuse allowed without permission.

pain state. We applied tSCS each day for 5 days, targeting the dorsal roots corresponding to the distal limbs. We hypothesized that, after 5 days of tSCS, spinal reflex hyperexcitability and PLP would decrease.

MATERIALS AND METHODS

Participants

Three individuals with a transtibial amputation participated in this study (Table 1). We excluded individuals from this study if they were younger than 18 years of age, were pregnant, or had any of the following: implanted electronic devices, any serious disease, disorder, infection, or cognitive impairments, a history of spinal cord injury or diseases, including spinal cord injury, herniated disk, or myelopathy, or heart disease including arrhythmia. This study was approved by the Internal Review Board at Carnegie Mellon University (STUDY2021_00000343) and conducted in accordance with the Declaration of Helsinki. All participants provided written informed consent prior to their enrollment in the study. No participants had prior experience with tSCS. Once participant (Participant 1) had received 30 days of eSCS more than two years prior, as part of a study using eSCS to restore sensation in the missing limb (27). The study took place over 5 days in one week. Participants were instructed not to change their pain medication regimen during the study, which included gabapentin in all three participants.

Participant ID	Age	Gender	Time since amputation	Nature of amputation	Side of amputation
1	56-60	M	9 years	Traumatic	Left
2	36-40	W	3 months	Diabetic neuropathy	Right
3	46-50	M	5 years	Alcoholic neuropathy	Left

Table 1. Demographic information for research participants.

Eliciting Peripheral and Spinal Responses

To measure spinal cord excitability, we studied motor (M)-waves, F-waves, and posterior root-muscle (PRM) reflexes, which were recorded using electromyography (EMG) electrodes placed on the residual limb. Prior to placing the EMG electrodes, we prepared the skin on the residual limb using abrasive gel (Lemon Prep, Mavidon, USA), alcohol wipes (Braha Industries, USA) and conductive electrode gel (Signa Gel, Parker Laboratories BV, NL). We placed bipolar electromyography (EMG) electrodes (Dual foam Ag|AgCl electrode, 7/8”×1 5/8”, MVAP Medical Supplies, Thousand Oaks, USA) on the lateral gastrocnemius (LG), medial gastrocnemius (MG), tibialis anterior (TA), and vastus lateralis (VL) muscles and a high-density EMG electrode grid (large, 64 channel; TMSi, NL) across the putative gastrocnemius muscles (Figure 1a). The locations of these muscles were confirmed using palpation during attempted movements of the missing ankle. We positioned a ground electrode (4×5 cm pregelled Ag|AgCl Natus electrode; MVAP Medical Supplies, Thousand Oaks, USA) onto the patella of the residual limb. We recorded EMG data using the SAGA64+ (TMSi, NL) at a sampling rate of 4000 Hz and streamed the data into MATLAB (MathWorks, USA). We delivered stimulation using a DS8R stimulator with a firmware update to allow frequencies up to 10 kHz (Digitimer, UK). The stimulator was triggered using a PCIe 6353 I/O Device (National Instruments, USA), a BNC 2090A connector accessory (National Instruments, USA), and custom MATLAB code.

medRxiv preprint doi: https://doi.org/10.1101/2023.04.13.23288483; this version posted April 17, 2023. The copyright holder for this preprint (which was not certified by peer review) is the author/funder, who has granted medRxiv a license to display the preprint in perpetuity. All rights reserved. No reuse allowed without permission.

We elicited M-waves and F-waves by electrically stimulating the tibial nerve of the residual limb. We first confirmed the location of the tibial nerve using ultrasound imaging (Butterfly Network, Inc., Burlington, MA, USA), then placed electrodes (2 square 7/8”×7/8” Ag|AgCl foam electrodes; MVAP Medical Supplies, Thousand Oaks, USA) longitudinally in the popliteal fossa with approximately 1-2 cm spacing. Stimuli consisted of a 1-ms long monophasic, cathodic, square wave pulse. We varied the stimulation amplitude to determine the thresholds for the M-wave as well as the maximum amplitude of the M-wave (M_{MAX}). The M_{MAX} was at the stimulation amplitude past which the magnitude of the M-wave no longer increased. We evoked F-waves by stimulating supramaximally (51,52).

We elicited the PRM reflex in the residual limb by electrically stimulating the spinal dorsal roots using tSCS (42). We placed round adhesive electrodes (3.2 cm diameter; ValuTrode, Axelgaard Manufacturing Co. Ltd., USA) paravertebrally of the T12-L1 spinous processes (Figure 1a). The placement of the tSCS electrodes was chosen to specifically target the dorsal roots corresponding sensorimotor pathways innervating the distal leg muscles (53,54). We placed return electrodes on each anterior superior iliac spine (7.5×13 cm, ValuTrode, Axelgaard Manufacturing Co. Ltd., USA). We wrapped the participant’s torso using Coban wrap (6”, 3M, USA) and placed a small piece of foam (12×17 cm) between the tSCS electrodes and the back of the chair. These last steps were to ensure firm pressure was maintained on the stimulation site. The stimulation pulses to evoke the PRM reflex were the same as for the M-wave: a 1-ms long monophasic, cathodic, square wave pulse. For the purpose of evoking PRM reflexes in the residual limb, we stimulated through the tSCS electrode ipsilateral to the residual limb only. We determined the stimulation threshold for evoking a PRM reflex in the gastrocnemius muscles, followed by the maximum PRM reflex amplitude (PRM_{MAX}). The maximum PRM reflex amplitude was at either the stimulation amplitude past which the magnitude of the PRM reflex no longer increased or the maximum stimulation amplitude tolerated by the participant. In this study, we did not exceed a stimulation amplitude of 180 mA. Our primary muscles-of-interest were the MG and LG muscles. We recorded from the VL and TA muscles to guide tSCS electrode placement to ensure targeting of the distal muscles.

We varied the stimulation amplitude to obtain recruitment curves for the M-waves, F-waves, and PRM reflexes. Specifically, we stimulated 15 amplitudes between 5 mA below threshold and 10-15 mA above the M_{MAX} (or PRM_{MAX}; if tolerated or up to 180 mA) in a random order. Each amplitude was repeated four times and stimuli were delivered 10 s apart.

Pain Measures

Participants filled out the Groningen Questionnaire Problems after Leg Amputation (GQPLA) questionnaire, which is intended to gain insight into difficulties that may arise following a leg amputation (4). The GQPLA is a modified version of a similar questionnaire for people with upper-limb amputations (55). The GQPLA asks participants to describe their phantom sensations, PLP, and stump pain. It also characterizes changes in prosthesis use (Supplementary Table 1).

We performed the pain pressure threshold (PPT) test using an algometer (Wagner Instruments, Greenwich, CT, USA). The PPT test measures the minimum amount of pressure that the participant can tolerate at a specific location. We pushed the rubber tip (1 cm diameter) of the algometer onto the skin over muscle (not pushing on bone) on several locations of both the

medRxiv preprint doi: https://doi.org/10.1101/2023.04.13.23288483; this version posted April 17, 2023. The copyright holder for this preprint (which was not certified by peer review) is the author/funder, who has granted medRxiv a license to display the preprint in perpetuity. All rights reserved. No reuse allowed without permission.

residual and intact limbs (Table 2). The participant reported when the pressure became painful, at which point we removed the algometer and recorded the pressure magnitude.

Residual Limb	Intact Limb
Bottom of stump	Bottom of heel
Anterior 5 cm above stump	Ball of foot
Posterior 5 cm above stump	Dorsum of foot
Medial 5 cm above stump	Posterior ankle
Lateral 5 cm above stump	Mid-shin
Anterior 10 cm above stump	Mid-calf
Posterior 10 cm above stump	Mid-quad
Medial 10 cm above stump	Mid-hamstring
Lateral 10 cm above stump	
Mid-quad	
Mid-hamstring	

Table 2. Locations where the pain pressure threshold test was performed.

We asked participants to rate their PLP in the last 24 hours using a visual analog scale (VAS) from 0 and 10, where 0 indicated no pain at all, and 10 indicated the worst pain imaginable. Participants completed the short form McGill Pain Questionnaire (MPQ) to describe their pain prior to participation in the study as well as throughout the week. The MPQ evaluates the sensation, temporal changes, and strength of pain. The total MPQ score indicates the intensity and affect the pain has on their life.

Transcutaneous Spinal Cord Stimulation

We delivered bilateral tSCS for neuromodulation continuously for 30 minutes, with a break at 15 minutes to inspect the stimulation site. The tSCS consisted of 1 ms long pulses with a 10 kHz carrier frequency, delivered at 30 Hz (Figure 1a). We started with a low amplitude of stimulation (approximately 10-20 mA) and slowly increased the stimulation beyond PRM reflex threshold, according to the comfort of the participant.

Study Protocol

All data were collected while the participant sat comfortably in a chair. At the beginning of each day, the participant rated their PLP over the last 24 hours using the VAS. We marked the location of the stimulation and EMG electrodes with a permanent marker (Sharpie, Newell Brands, USA) to ensure consistent placement across the 5 days. Every day, we performed the M-wave, F-wave, and PRM reflex measures, followed by high-frequency tSCS for 30 minutes. At the beginning of the first and fifth days, the participant completed the MPQ and GQPLA, and we performed the PPT test. The complete study timeline is shown in figure 1b.

medRxiv preprint doi: https://doi.org/10.1101/2023.04.13.23288483; this version posted April 17, 2023. The copyright holder for this preprint (which was not certified by peer review) is the author/funder, who has granted medRxiv a license to display the preprint in perpetuity. All rights reserved. No reuse allowed without permission.

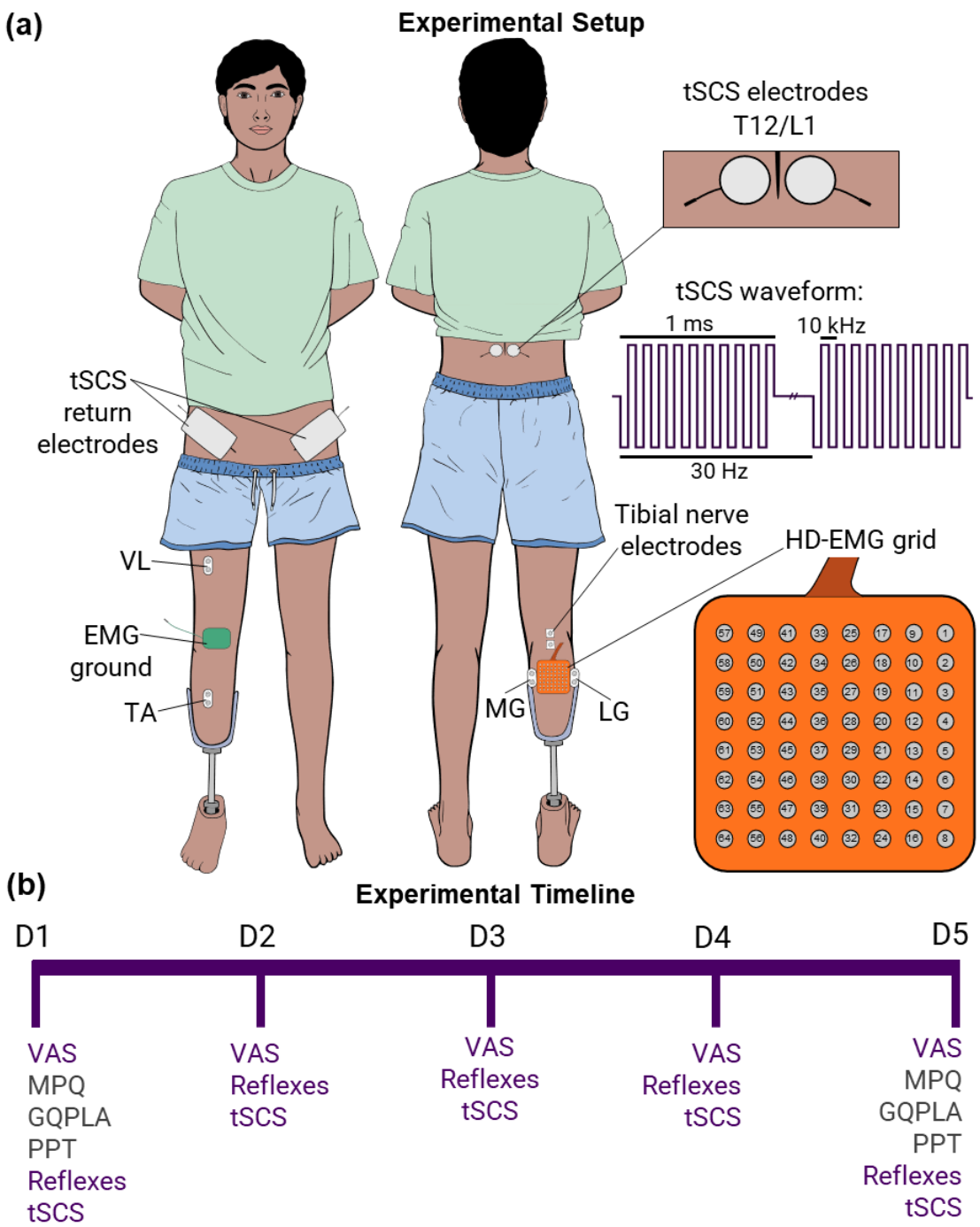

Figure 1: (a) Graphic of participant with a transtibial amputation with electrode placement indicated. Transcutaneous spinal cord stimulation (tSCS) electrodes were placed paraspinally of the T12/L1 vertebrae, and the return electrodes were placed on the anterior superior iliac spines. Bipolar electromyography (EMG) electrodes were placed on the vastus lateralis (VL), tibialis anterior (TA), medial gastrocnemius (MG), and lateral gastrocnemius (LG) muscles. A 64-channel high-density electromyography (HD-EMG) grid was placed on the putative gastrocnemius muscles. High-frequency tSCS consisted of 1 ms long pulses with a 10 kHz carrier frequency, delivered at 30 Hz. (b) Study timeline across the 5 days (D). VAS = visual analog scale; MPQ = McGill Pain Questionnaire; GQPLA = Groningen Questionnaire Problems after Leg Amputation; PPT = Pain Pressure Threshold test; Reflexes refers to both PRM reflexes, M-waves, and F-waves; tSCS refers to 30 minutes of high-frequency tSCS.

medRxiv preprint doi: https://doi.org/10.1101/2023.04.13.23288483; this version posted April 17, 2023. The copyright holder for this preprint (which was not certified by peer review) is the author/funder, who has granted medRxiv a license to display the preprint in perpetuity. All rights reserved. No reuse allowed without permission.

Analyses and Statistics

We tested for normality using the Shapiro–Wilk test and assessed the homogeneity of variance using Levene's test. A p-value < 0.05 was considered significant.

We removed the stimulus artefact in the EMG signals by interpolating between pre- and post-stimulus time intervals. For analyzing PRM reflexes, the interval was between 4 ms prior to and 6 ms after the stimulus onset. For analyzing M-waves and F-waves, the interval was between 4 ms prior to and 9 ms after the stimulus onset. The post-stimulus period was larger for the M-wave and F-wave analysis because this interval provided the clearest M-wave, but the M-wave was contaminated by the stimulus artefact; therefore, M-wave latency could not be accurately measured. All EMG data were filtered using a 2nd order Butterworth bandpass filter with cutoff frequencies at 20 Hz and 1999 Hz.

We defined the threshold for evoking a PRM reflex or M-wave as the lowest stimulation amplitude that elicited a response that was three standard deviations beyond the mean baseline (pre-stimulus) period and confirmed this visually. Grouped threshold data contain the mean threshold across all channels of the HD-EMG grid. We performed a linear correlation between the PRM reflex threshold for each electrode on the HD-EMG grid with its impedance value. We expressed reflex thresholds in units of charge (μC), obtained by multiplying the stimulation amplitude (in mA) by the pulse width (1 ms).

We determined the latency of the PRM and F-waves to be the time from the onset of the stimulation to the first inflection of the response. The first inflection was detected when the amplitude of the response exceeded two standard deviations beyond the mean baseline period. We measured the duration of the F-wave, which we defined as the time from the onset of the F-wave to the offset. We defined the offset as the time when the peak-to-peak amplitude of the response returned to baseline. To compare the PRM reflex thresholds over 5 days, we performed a one-way analysis of variance (ANOVA) with Bonferroni post-hoc tests.

We created recruitment curves for the PRM reflexes, M-waves, and F-waves by plotting the mean peak-to-peak amplitude of the response from each electrode on the HD-EMG grid as a function of stimulation amplitude. We determined the slope of the recruitment curve, or recruitment rate, for the PRM reflexes using the MATLAB function *findchangepts* to find the inflection points of the mean curve for each Participant. We set the parameters for the *findchangepts* function as follows: the maximum number of change points equal to two; the minimum allowable number of samples equal to two. The slope of the recruitment curve corresponded to the slope of the line between the inflection points across the steepest part of the curve. We calculated the F/M ratio by dividing the maximal peak-to-peak amplitude of the F-wave (F_{MAX}) by the M_{MAX}. We compared the change in the F/M ratio, F-wave latency and duration between Day 1 and Day 5 for each Participant using a t-test.

We determined the change in PPT over time by subtracting the PPT at each location on Day 1 from Day 5. We normalized the PPT at each location to the maximum PPT value recorded for each participant. We expressed the change in PPT on a scale between -1 and 1, where -1 indicated a maximal decrease in PPT, 1 indicated a maximal increase in PPT, and 0 indicated no change in PPT. We also compared the average PPT across all tested locations on each limb between day 1 and day 5 using a paired t-test. We used repeated measures ANOVA to compare the mean VAS score from all participants across the 5 days. A decrease in the VAS score by 50% and at least 1

medRxiv preprint doi: https://doi.org/10.1101/2023.04.13.23288483; this version posted April 17, 2023. The copyright holder for this preprint (which was not certified by peer review) is the author/funder, who has granted medRxiv a license to display the preprint in perpetuity. All rights reserved. No reuse allowed without permission.

point is considered clinically meaningful. We summated the responses from each subsection of the MPQ to obtain a total score. A clinically meaningful decrease in MPQ score is a 5-point decrease (56).

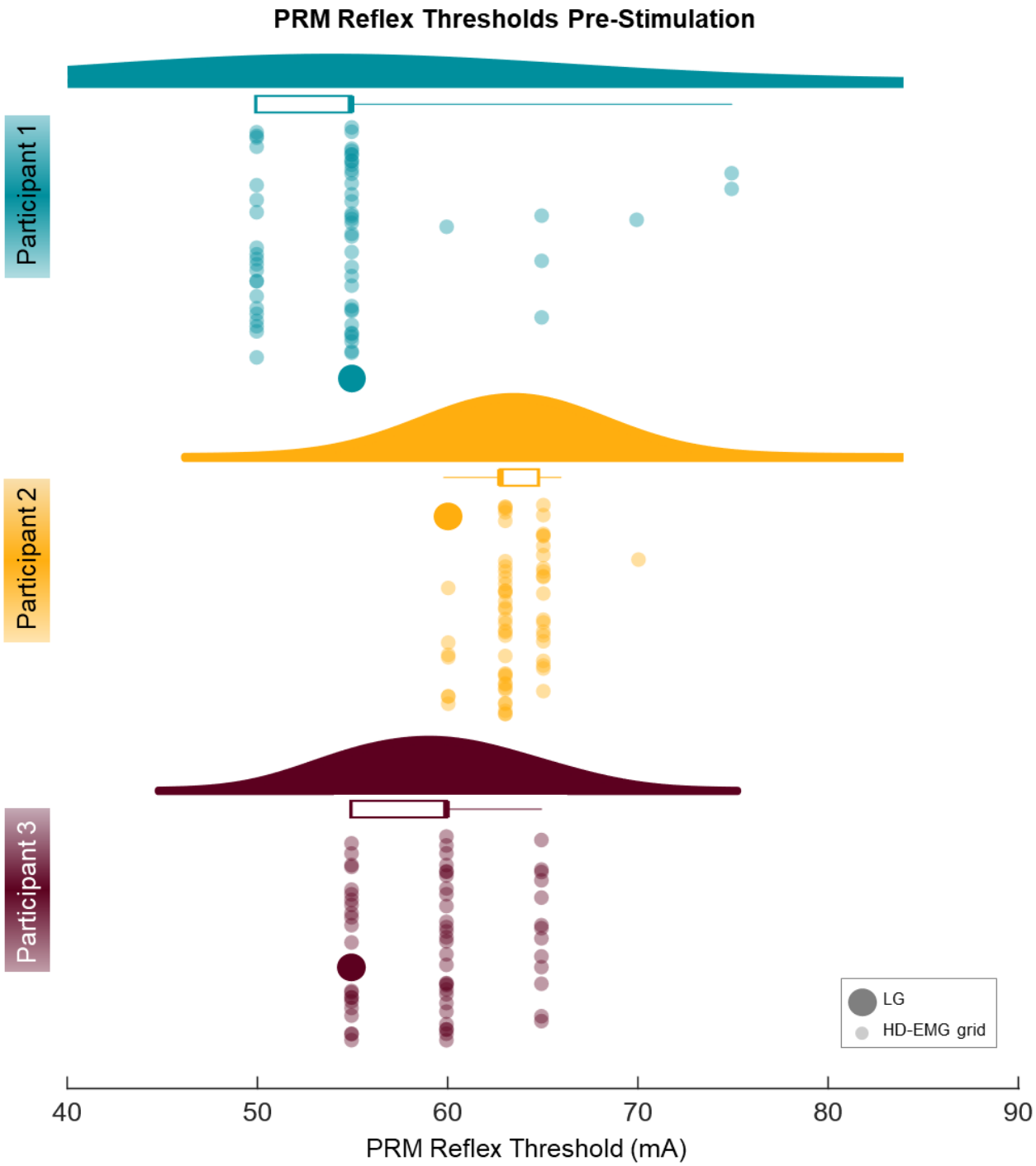

Figure 2. Distribution of stimulation amplitudes required to evoke a posterior root-muscle (PRM) reflex at each electrode on the high-density electromyography (HD-EMG) grid on the putative gastrocnemius muscles and a bipolar EMG recording from the lateral gastrocnemius (LG) muscle. Thresholds were obtained for each participant prior to the use of transcutaneous spinal cord stimulation.

medRxiv preprint doi: https://doi.org/10.1101/2023.04.13.23288483; this version posted April 17, 2023. The copyright holder for this preprint (which was not certified by peer review) is the author/funder, who has granted medRxiv a license to display the preprint in perpetuity. All rights reserved. No reuse allowed without permission.

RESULTS

Through the GQPLA, all participants reported experiencing leg pain prior to amputation, ranging from one week to one year in duration. All participants sought previous treatment for PLP and stump pain, including pain medications. Participants 1 and 3 reported some relief with their pain medications, but noted the relief was incomplete. Participant 1 underwent a scar revision surgery and a neuroma surgery and reported temporary relief from those procedures. Over the course of the study, there were no changes in prosthesis use by Participants 1 and 3. Both participants reported using their prosthesis daily, for 8 hours or more, and capable of walking distances of 0.5 miles or longer.

tSCS neuromodulation was well tolerated by the participants. There were no adverse events to report. The cessation of tSCS after 15 minutes to check on the skin at the stimulation site did not reveal any redness or irritation. Typically, the initial increase in stimulation amplitude was felt by the participant, and after a few seconds, their awareness of the stimulation subsided.

Small amplitude PRM reflexes were elicited in the VL and TA muscles in each Participant (Supplementary figure 1). However, the LG and MG muscles were the primary muscles-of-interest; therefore, our analyses focus on the evoked responses in the putative gastrocnemius muscles. Hoffman (H)-reflexes could not be elicited by stimulating the tibial nerve, limiting our analysis to M-waves and F-waves.

Recruitment of PRM Reflexes, M-Waves, and F-Waves Prior to tSCS

The mean PRM reflex thresholds from the HD-EMG grid on the gastrocnemius muscles prior to tSCS neuromodulation were 55.8 ± 8.0 μC, 63.4 ± 1.7 μC, and 59.3 ± 3.7 μC for Participants 1, 2, and 3, respectively (Figure 2; group mean = 59.5 ± 6.1 μC). There was some variability in the PRM reflex thresholds across the electrodes on the HD-EMG grid for Participant 1 (Supplementary Figure 2); however, the thresholds did not correlate with the electrode impedance (r = -6.9% for Participant 1; r = 41.2% for Participant 2; and r = 25.0% for Participant 3). The mean latency of the PRM reflexes was 20.2 (± 1.1) ms across all participants (Figure 3d).

The recruitment of the PRM reflexes was incomplete (Figure 3a,b); the PRM_{MAX} was never reached and was limited by the participants' tolerance to the stimulation amplitude. Participant 2 tolerated up to 160 mA on Day 1; therefore, it is unlikely that PRM_{MAX} would have been reached within the amplitude limit set in this study (180 mA). The rates of recruitment of the PRM reflexes were 0.32, 0.14, and 0.28 mV/μC for Participants 1, 2, and 3, respectively (Figure 3c; group mean = 0.25 ± 0.1 mV/μC). At 2.5 times the PRM reflex threshold, the peak-to-peak amplitudes of the PRM reflexes were 0.11 ± 0.05 mV (Figure 3e). PRM reflexes at 2.5 times threshold for each electrode on the HD-EMG grid for Participant 1 are shown in Supplementary Figure 3.

The recruitment curves from peripheral nerve stimulation show the expected sigmoid of the M-waves (Figure 4a,b). The latencies of the F-waves for Participants 1, 2, and 3 were 38.1 ± 1.5 ms, 44.8 ± 4.1 ms, and 44.4 ± 1.7 ms, respectively (Figure 4c), which are within normal range (51). The duration of the F-waves for Participants 1 and 3 were 14.0 ± 3.2 ms and 11.7 ± 2.2 ms, respectively, which are also within normal range (57). However, the duration of the F-wave for Participant 2 was 4.8 ± 1.6 ms, which is shorter than normal. F-waves were small in amplitude in all participants. Specifically, the F/M ratios were 4.27 ± 3.10, 1.19 ± 0.45, and 4.28 ± 1.02 for Participants 1, 2, and 3, respectively (Figure 4d). This means that on average, the peak-to-peak

medRxiv preprint doi: https://doi.org/10.1101/2023.04.13.23288483; this version posted April 17, 2023. The copyright holder for this preprint (which was not certified by peer review) is the author/funder, who has granted medRxiv a license to display the preprint in perpetuity. All rights reserved. No reuse allowed without permission.

amplitude of the F_{MAX} was less than 5% of the M_{MAX} and the amplitudes of the F-waves were smaller than normal (58,59).

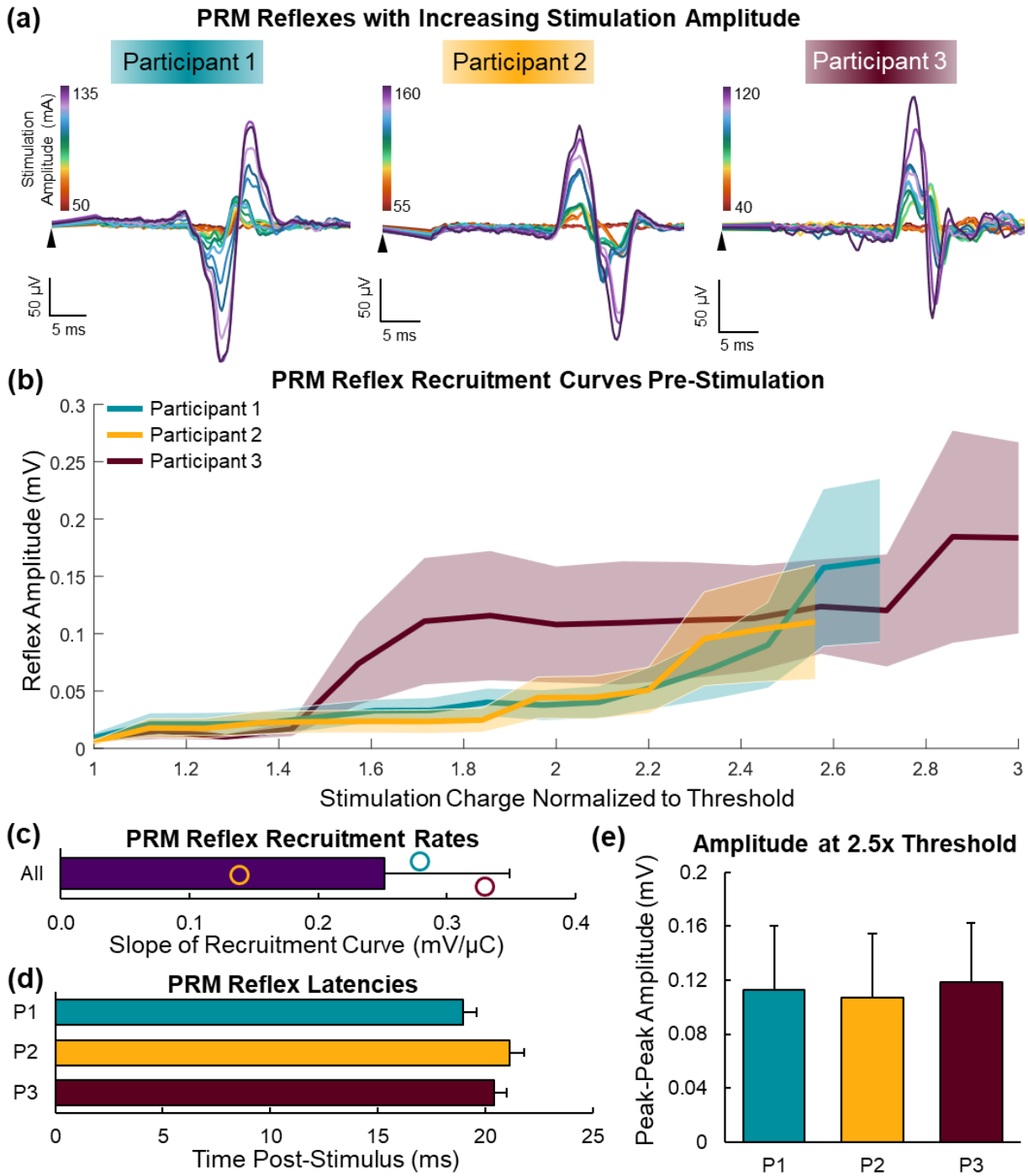

Figure 3. Recruitment of posterior root-muscle (PRM) reflexes prior to the use of transcutaneous spinal cord stimulation. (a) Examples of PRM reflexes from an electrode on the high-density electromyography (HD-EMG) grid as stimulation amplitude was increased. (b) Recruitment curves showing the peak-to-peak amplitude of the PRM reflexes as stimulation charge was increased, normalized to the threshold for evoking a PRM reflex for each participant. (c) Slope of the mean recruitment curve. (d) Mean (+ standard deviation (SD)) latency of the PRM reflex. (e) Mean (+ SD) peak-to-peak amplitude of the PRM reflexes when the stimulation amplitude was 2.5 times threshold. P = Participant.

medRxiv preprint doi: https://doi.org/10.1101/2023.04.13.23288483; this version posted April 17, 2023. The copyright holder for this preprint (which was not certified by peer review) is the author/funder, who has granted medRxiv a license to display the preprint in perpetuity. All rights reserved. No reuse allowed without permission.

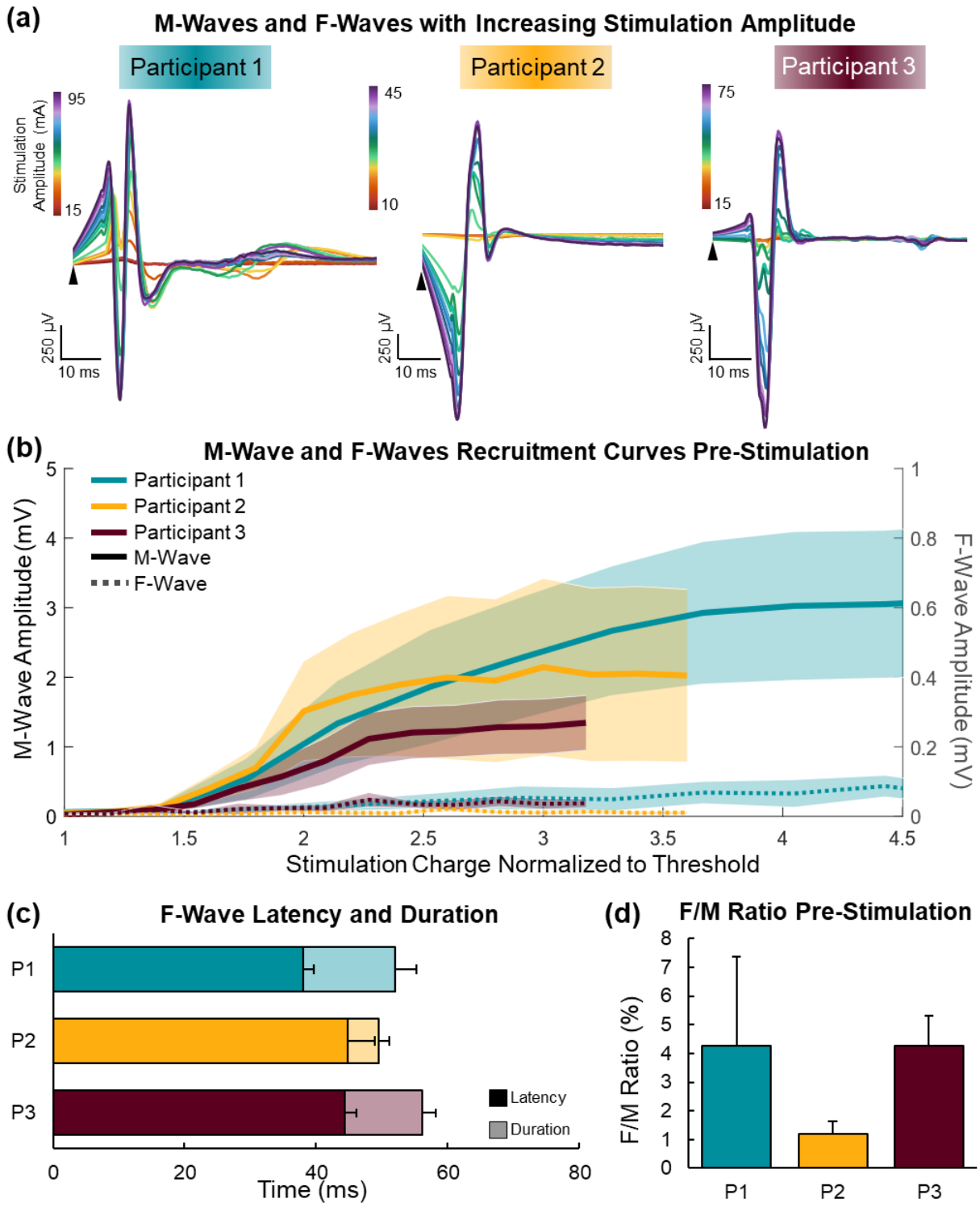

Figure 4. M-waves and F-waves prior to the use of transcutaneous spinal cord stimulation. (a) Examples of M-waves (first response) and F-waves (second, smaller response) from an electrode on the high-density electromyography (HD-EMG) grid as stimulation amplitude was increased. (b) Recruitment curves showing the peak-to-peak amplitude of the M-waves (left y-axis) and F-waves (right y-axis) as stimulation charge was increased, normalized to the threshold for evoking an M-wave for each participant. (c) Mean (+ standard deviation (SD)) latency (solid) and duration (semi-transparent) of the F-waves. (d) Mean (+ SD) ratio of the peak-to-peak amplitudes of the F-waves and M-waves. P = Participant.

medRxiv preprint doi: https://doi.org/10.1101/2023.04.13.23288483; this version posted April 17, 2023. The copyright holder for this preprint (which was not certified by peer review) is the author/funder, who has granted medRxiv a license to display the preprint in perpetuity. All rights reserved. No reuse allowed without permission.

tSCS Decreased PRM Thresholds

Throughout the 5 days of tSCS, PRM reflex thresholds for all participants decreased from 59.5 (± 6.1) to 38.6 (± 12.2) μC (Figure 5a). The PRM reflex thresholds on Day 1 were significantly higher compared to all other testing days ($p < 0.005$), and PRM reflex thresholds on Day 5 were significantly lower than on all other days ($p < 0.001$). According to the recruitment curves, the range of peak-to-peak amplitudes of the PRM reflexes were similar on Day 5 compared to Day 1 for Participants 1 and 3 only (Figure 5b). There was more than a 10-fold increase in the range of peak-to-peak amplitudes of the PRM reflexes for Participant 2. In fact, the recruitment rates for Participants 1 and 3 did not change over the 5 days, but for Participant 2, the recruitment rate increased from 0.14 to 1.63 mV/μC (Figure 5c). Furthermore, the peak-to-peak amplitude of the PRM reflexes at 2.5 times threshold did not change over the 5 days for Participants 1 and 3, but increased from 0.11 (± 0.05) mV to 0.60 (± 0.39) mV for Participant 2 (Figure 5d). The latencies of the PRM reflexes decreased significantly across the 5 days ($p < 0.001$; Day 1: 20.2 ± 1.1 ms; Day 5: 19.6 ± 1.1 ms; Figure 6a). The latencies of the PRM reflexes at both time points were within normal ranges (42).

The F/M ratio did not change significantly between Days 1 and 5 for any participants (Day 1: 3.2 ± 2.4; Day 5: 2.9 ± 1.5; $p = 0.11$; Figure 6b). Similarly, there were no significant changes in the latency of the F-wave across the 5-days for any participants (Day 1: 41.8 ± 3.9 ms; Day 5: 41.5 ± 3.3 ms; $p = 0.44$; Figure 6c). However, the duration of the F-waves decreased significantly between Days 1 and 5 (Day 1: 11.5 ± 4.1 ms; Day 5: 9.7 ± 3.1 ms; $p < 0.001$). Notably, very few electrodes on the HD-EMG grid detected an F-wave in Participant 2 on Day 1 (26/64 electrodes). However, on Day 5, F-waves were perceptible in 55 out of the 64 electrodes (Supplementary Figure 4). Furthermore, although the group data reflected a decrease in F-wave duration over the 5 days, there was a significant increase in F-wave duration in Participant 2 ($p < 0.001$; Figure 6c).

tSCS Reduced the Frequency of Stump Pain and PLP

Reponses from the GQPLA revealed that Participants 1 and 2 experienced phantom sensations a few times per day both before and during their participation in the study. Participant 3 reported a reduction in phantom sensations from a few times per hour to a few times during the week of the study. All participants reported feeling itching sensations, while individual phantom sensations included warmth, movement, electric sensations, touch, and abnormal position. Stump pain moderately affected all participants. Participant 1 had no change in the frequency of their stump pain throughout the study; however, Participants 2 and 3 reported reduced frequency of stump pain, from a few times per week to a few times per month and a few times per day to not at all, respectively. All participants reported a reduction in episodes of PLP. Participants 1 and 2 reported experiencing PLP a few times per day before the study, but only a few episodes during the week of the study. Participant 3 reported experiencing PLP a few times per hour before the study, and similarly only experiencing PLP a few times during the week of the study.

tSCS Increased Pain Pressure Threshold

Two Participants had increases in their pain pressure thresholds across several locations of their residual and intact limbs (Figure 7a). Both Participants had significant increases in their pain pressure thresholds on their residual limb (Participant 1: Day 1: 3.8 ± 2.6 lbf, Day 5: 10.4 ± 3.5 lbf, $p < 0.001$; Participant 2: Day 1: 7.0 ± 2.4 lbf, Day 5: 12.4 ± 7.6 lbf, $p = 0.018$) (Figure 7b). Participant 1 had a significant increase in pain pressure threshold on their intact limb (Day 1: 14.9 ± 3.4 lbf, Day 5: 19.1 ± 4.7 lbf, $p = 0.003$); however, Participant 2 did not (Day 1: 14.0 ± 5.7 lbf, Day 5: 15.0 ±

medRxiv preprint doi: https://doi.org/10.1101/2023.04.13.23288483; this version posted April 17, 2023. The copyright holder for this preprint (which was not certified by peer review) is the author/funder, who has granted medRxiv a license to display the preprint in perpetuity. All rights reserved. No reuse allowed without permission.

6.3 lbf, p = 0.62). Participant 3 was excluded from this analysis due to inconsistent use and timing of their pain medications on the testing days, which invalidated these results.

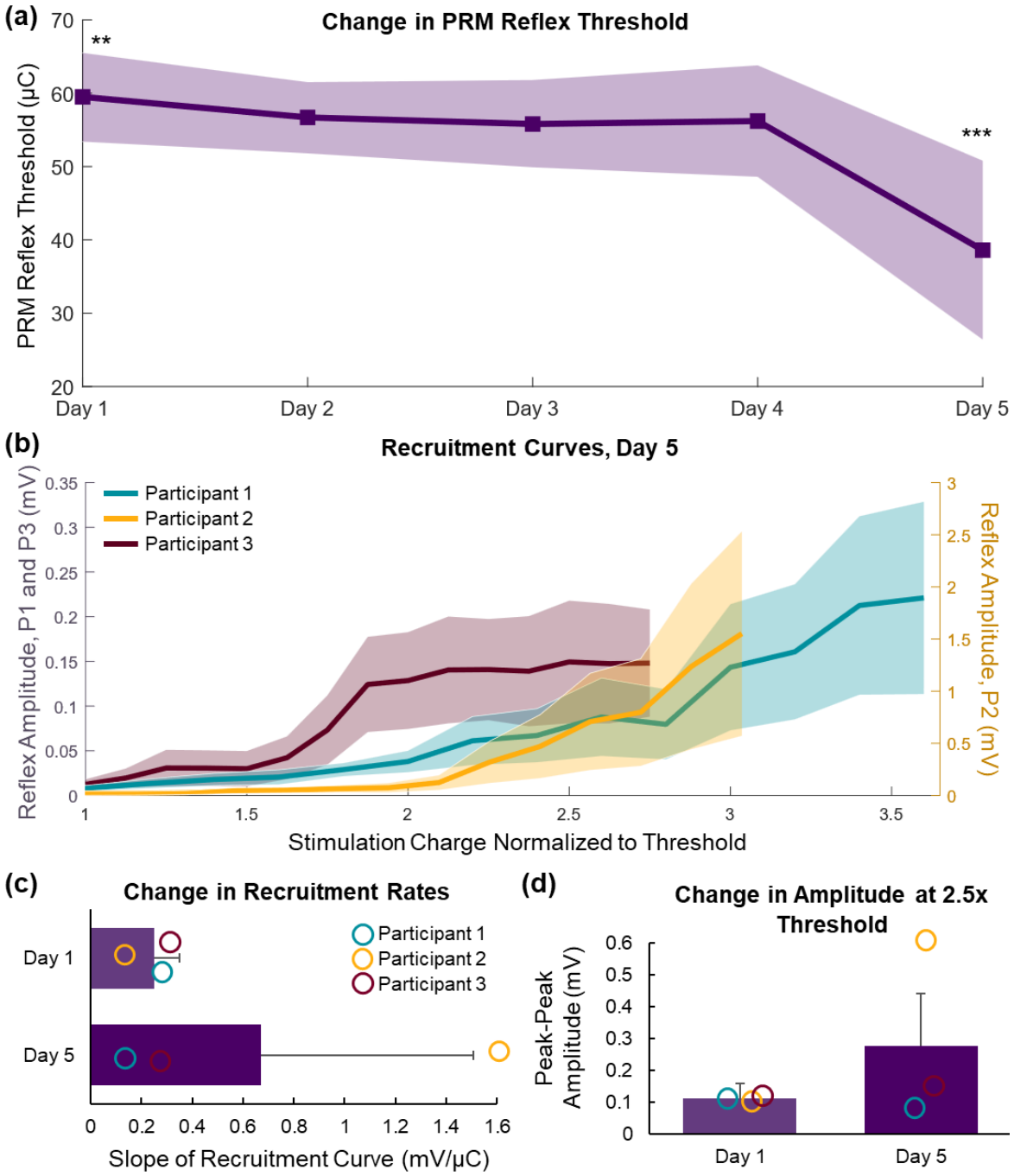

Figure 5. Change in posterior root-muscle (PRM) reflex recruitment over 5 days of transcutaneous spinal cord stimulation. (a) Mean (± standard deviation (SD)) change in amount of charge required to evoke a PRM reflex (threshold). (b) Recruitment curves from Day 5 showing the peak-to-peak amplitude of the PRM reflexes as stimulation charge was increased, normalized to the threshold for evoking a PRM reflex for each participant. PRM reflex amplitudes for Participants 1 (P1) and 3 (P3) are indicated by the left y-axis; PRM reflex amplitudes for Participant 2 (P2) are indicated by the right y-axis. (c) Mean (+ standard deviation (SD)) slope of the recruitment curves on Days 1 and 5. (d) Mean (+ SD) peak-to-peak amplitude of the PRM reflexes when the stimulation amplitude was 2.5 times threshold on Days 1 and 5. **p < 0.01; ***p < 0.001.

medRxiv preprint doi: https://doi.org/10.1101/2023.04.13.23288483; this version posted April 17, 2023. The copyright holder for this preprint (which was not certified by peer review) is the author/funder, who has granted medRxiv a license to display the preprint in perpetuity. All rights reserved. No reuse allowed without permission.

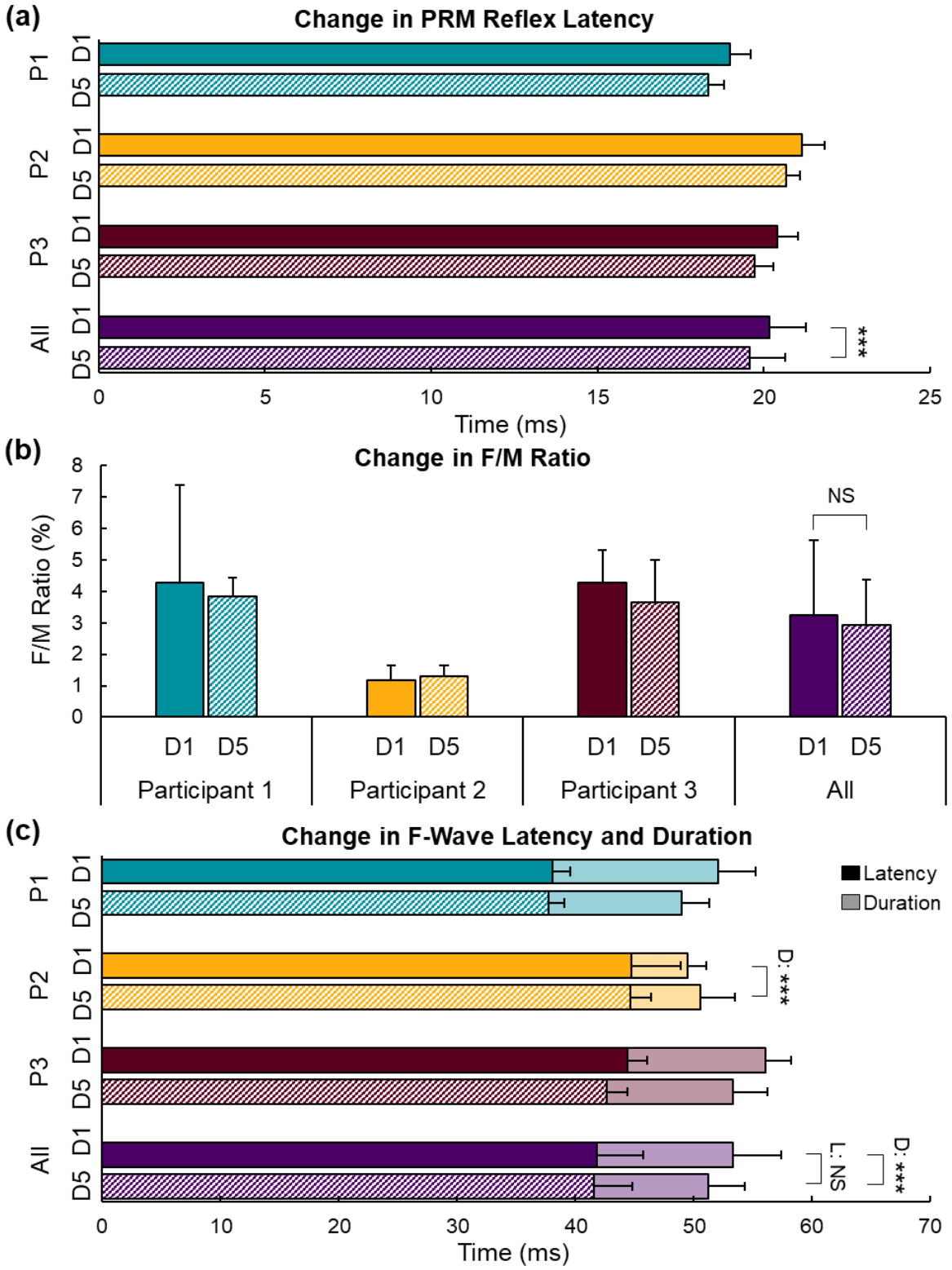

Figure 6. Changes in posterior root-muscle (PRM) reflexes, M-waves, and F-waves between Days 1 (D1) and 5 (D5) of using transcutaneous spinal cord stimulation for each participant (P) and the group (All). Mean (+ standard deviation) change in (a) PRM reflex latency, (b) ratio of F-wave and M-wave peak-to-peak amplitudes (F/M ratio), (c) F-wave latency (L; solid and diagonally striped) and duration (D; semi-transparent). NS = not significant; ***p < 0.001.

medRxiv preprint doi: https://doi.org/10.1101/2023.04.13.23288483; this version posted April 17, 2023. The copyright holder for this preprint (which was not certified by peer review) is the author/funder, who has granted medRxiv a license to display the preprint in perpetuity. All rights reserved. No reuse allowed without permission.

tSCS Reduced Pain Scores

Mean VAS scores rating the Participants' pain over the previous 24 hours decreased from 6.0 (± 2.0) on Day 1 to 4.5 (± 0.5) on Day 5 (Figure 8a). The reduction in VAS scores across the 5 days did not meet the clinically meaningful threshold and were not statistically significant (p = 0.56). All participants had clinically meaningful different MPQ scores between days 1 and 5. The MPQ for Participant 1 decreased from 39 to 26; Participant 2 decreased from 26 to 16; and Participant 3 decreased from 37 to 13 (Figure 8b). As a group, mean MPQ scores decreased from 34.0 (± 7.0) on Day 1 to 18.3 (± 6.8) on Day 5.

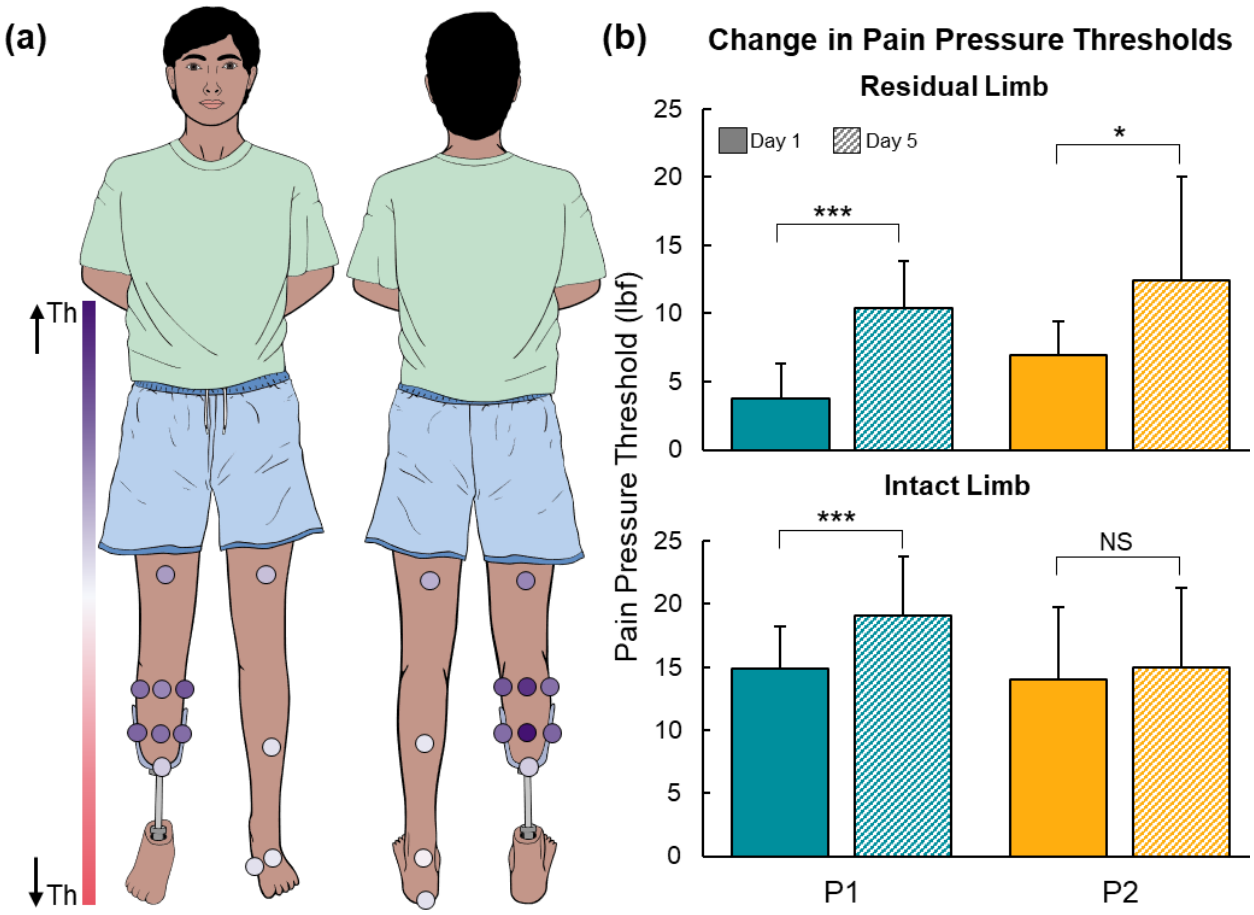

Figure 7. Change in pain pressure threshold (PPT) between Days 1 and 5 of using transcutaneous spinal cord stimulation for Participants 1 (P1) and 2 (P2). (a) Normalized changes in PPT at each location tested on the residual and intact limbs. (b) Mean (+ standard deviation) PPT from all sights tested on the residual limb (top) and intact limb (bottom) on Day 1 (solid) and Day 5 (diagonal lines). Th = threshold; NS = not significant; *p < 0.05; ***p < 0.001.

tSCS Evoked Sensory Percepts After a Recent Limb Amputation

Participant 2 had a leg amputation 3 months prior to the study and was not yet fitted for a prosthesis. During the continuous bilateral tSCS for neuromodulation on the first day, and every day thereafter, she reported feeling her missing foot touching the ground. In her own words, "My leg, the amputated one, feels like it's on the ground, it feels like it's comfortable. It feels like I have both feet touching the floor. It doesn't even feel like my foot's gone." The sensory percepts were present only during continuous tSCS, not during the brief pulses used for reflex testing. The Participant did not report feeling paraesthesias or other sensations in her intact limb.

medRxiv preprint doi: https://doi.org/10.1101/2023.04.13.23288483; this version posted April 17, 2023. The copyright holder for this preprint (which was not certified by peer review) is the author/funder, who has granted medRxiv a license to display the preprint in perpetuity. All rights reserved. No reuse allowed without permission.

DISCUSSION

Reflex Hypoexcitability with Phantom Limb Pain

Changes in spinal excitability have been characterized following peripheral nerve injury (38) and with diabetes (41,60), but has not been characterized following limb amputation. H-reflexes are prolonged or absent in diabetic neuropathy (60), but are hyperexcitable in painful diabetic neuropathy (39–41). Two of our Participants had a neuropathy prior to their amputation; diabetic and alcohol-induced neuropathy. In both diabetic neuropathy and alcohol-induced neuropathy, the sensory nerves are affected either by metabolic stress (diabetes) (61) or direct damage (alcohol) (62). We were unable to evoke H-reflexes in any of our participants, regardless of the presence of neuropathy. However, we were able to characterize spinal excitability using PRM reflexes and F-waves, which conduct along the motor nerves.

Prior to tSCS neuromodulation, PRM reflex thresholds were higher in our participants with transtibial amputations (59.5 ± 6.1 μC) than in neurologically intact individuals (35.6 ± 11.6 μC; n = 12) (42). The amplitudes of the PRM reflexes at 2.5 times threshold were 0.11 ± 0.05 mV, which is over 65 times smaller than in intact individuals (> 8 mV). The rate of recruitment of PRM reflexes in people with limb amputations (0.25 ± 0.1 mV/μC) was, again, smaller than in intact individuals (~0.4 mV/μC), especially Participant 2 (0.14 mV/μC), who also had diabetic neuropathy. The F-waves were extremely small in amplitude, and in the case of Participant 2, often absent or nearly imperceptible. The amplitudes of the F-waves in all participants were smaller than what has been reported in neurologically intact individuals (57–59). The latencies of the F-waves were all within normal range and did not change over time (51). The F-wave duration for Participant 2 was shorter than normal (57) but increased after 5 days of tSCS. F-wave amplitude and latency can indicate health and excitability of the motoneurons (57,63). Collectively, our results indicate that the motoneurons in people with a transtibial amputation may have reduced excitability, evident by the low amplitudes in all participants and the small duration in Participant 2.

We characterized PRM reflexes in people with limb amputation and PLP, with and without neuropathy. PRM reflexes were easily obtainable, unlike H-reflexes, in all participants. Therefore, PRM reflexes are a tool that can be used to investigate spinal excitability in populations where the sensory peripheral nerves may be inaccessible or damaged. Overall, prior to tSCS neuromodulation, PRM reflexes had high thresholds, low amplitudes, and low rates of recruitment, suggesting that these spinal reflexes were hypoexcitable. Despite being a neuropathic pain condition, the presence of PLP did not result in spinal hyperexcitability. This indicates that perhaps the limb amputation itself caused spinal hypoexcitability that exceeds any effects from PLP, or that PLP is unique from other chronic and neuropathic pain conditions.

Plasticity in Sensorimotor Pathways Following Limb Amputation

Following peripheral nerve injury or limb amputation, the primary sensory and motor cortices undergo remapping, where the affected regions have persistent but suppressed cortical representation (64,65). The extent of this cortical remapping correlates with the intensity of PLP, where more severe PLP results in more extensive remapping (66). Several mechanisms have been proposed to explain cortical remapping, including axonal sprouting in the primary somatosensory cortex (67), thalamus, and brainstem (68), the expansion of the receptive field in the thalamus (69,70), unmasking or disinhibition of inhibitory connections between somatotopic

medRxiv preprint doi: https://doi.org/10.1101/2023.04.13.23288483; this version posted April 17, 2023. The copyright holder for this preprint (which was not certified by peer review) is the author/funder, who has granted medRxiv a license to display the preprint in perpetuity. All rights reserved. No reuse allowed without permission.

regions (71), or unmasking of overlapping receptive fields in the primary somatosensory cortex (72). Evidence to support the preservation, but suppression, of the canonical topographic cortical map following a limb amputation stems from studies where the nervous system was stimulated and sensory percepts were evoked (64). Sensory percepts have been evoked in the missing limbs of people with amputations using electrical stimulation of the peripheral nerves, (73–77), spinal cord (27,78,79), and thalamus (69), as well as magnetic stimulation of the contralateral primary motor cortex (80,81). Collectively, it is likely that a loss of somatosensory input from an amputation results in a suppression of somatosensory pathways corresponding to the affected limb, and that stimulation, including tSCS, 'reawakens' or unmasks the sensorimotor nervous system.

Stimulating the Spinal Cord to Evoke Sensory Percepts

We have previously shown that eSCS can evoke sensory percepts in the missing hand (78) and foot (27) following upper- and lower-limb amputation, respectively. eSCS targeting the missing hand resulted in sensory percepts immediately (78); however, sensory percepts from eSCS targeting the missing foot were absent until approximately two weeks into the stimulation regime (27). All participants from both studies had chronic (> 2 years) amputations. In the current study, Participant 2, whose amputation was subacute (3 months), reported experiencing sensory percepts in her missing foot immediately following the onset of tSCS on the first day of testing. Participants 1 and 3, whose amputations were chronic, did not report any sensory percepts during tSCS. It is possible that if we were to deliver tSCS for more than 2 weeks, sensory percepts could be elicited, similar to eSCS. We may have been able to elicit sensory percepts using tSCS following a sub-acute amputation because the somatosensory pathways have not become as suppressed as in chronic amputations. Future studies will explore the potential of tSCS as a sensory neuroprosthesis to elicit sensory percepts following acute, sub-acute, and chronic amputations, as well as fully characterize the quality of the sensory percepts.

Differential Effects of tSCS on Reflex Recruitment in Sub-Acute Versus Chronic Amputation

Participant 2 exhibited more drastic changes in PRM and F-wave recruitment throughout the study. Initially, Participant 2 had the shallowest recruitment rate, smallest F/M ratio, and shortest F-wave duration. However, after 5 days of tSCS, Participant 2 had the steepest recruitment rate (by >10 times) and a significant increase in F-wave duration. This further supports our postulation that, following sub-acute amputation, the somatosensory pathways are not as suppressed as in chronic amputations, and can be excited using tSCS to produce earlier and more drastic changes to the somatosensory system.

medRxiv preprint doi: https://doi.org/10.1101/2023.04.13.23288483; this version posted April 17, 2023. The copyright holder for this preprint (which was not certified by peer review) is the author/funder, who has granted medRxiv a license to display the preprint in perpetuity. All rights reserved. No reuse allowed without permission.

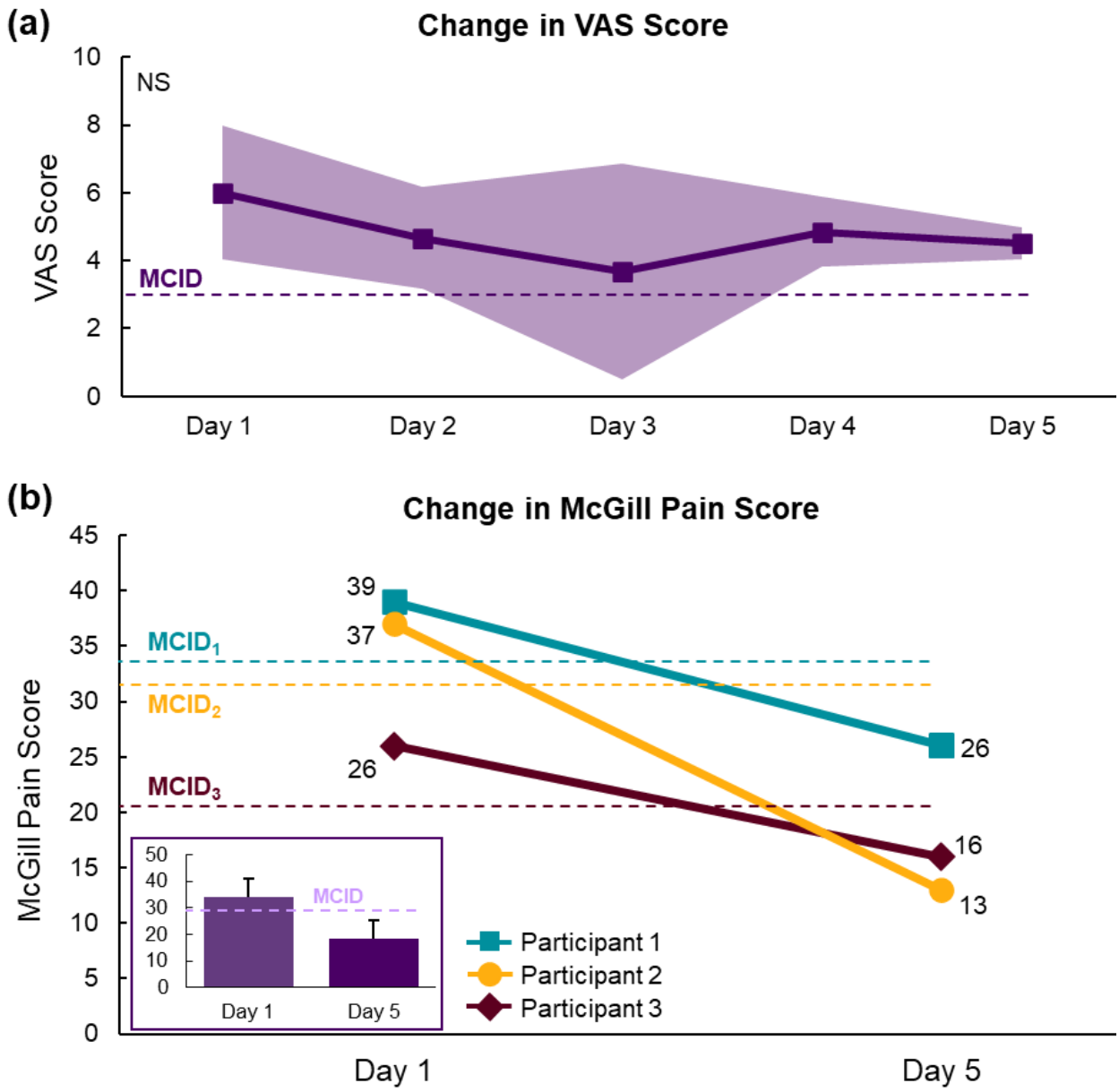

Figure 8. Change in pain scores across the 5 days of using transcutaneous spinal cord stimulation. (a) Mean (± standard deviation (SD)) visual analog scale (VAS) score across all 5 Days. (b) Scores from the McGill Pain Questionnaire on Days 1 and 5 for each Participant. Inset: Mean (+ SD) scores for all participants. MCID = minimal clinically-important difference; NS = not significant.

Study Limitations

Here, we demonstrated that tSCS may be an effective therapy for reducing PLP and stump pain in people with a transtibial amputation. Our proof-of-concept study examined how spinal reflexes and pain measures change following 5 days of tSCS neuromodulation. The participants maintained their pain medication regime, which included gabapentin. Gabapentin is a GABA analogue, which suppresses the nervous system (82) and may also suppress spinal reflexes, but this has yet to be elucidated. Their pain regimen did not change over the course of the study; therefore, the changes in reflex excitability throughout the study occurred regardless of their medication regime. Our results show significant and clinically meaningful changes in

medRxiv preprint doi: https://doi.org/10.1101/2023.04.13.23288483; this version posted April 17, 2023. The copyright holder for this preprint (which was not certified by peer review) is the author/funder, who has granted medRxiv a license to display the preprint in perpetuity. All rights reserved. No reuse allowed without permission.

participants' pain pressure threshold and MPQ score. A longer duration study may be able to capture a larger change in these measures, as well as a meaningful decrease in VAS score. Furthermore, there may be a retention of pain relief provided by tSCS that was not captured in the current study. Future studies will include a follow-up examination of spinal excitability and pain measures to quantify any lasting changes after the cessation of tSCS.

The participants in this study were heterogeneous; they differed in the nature of their amputation, presence of neuropathy, as well as time since amputation. Overall, we demonstrate that people with PLP have spinal hypoexcitability, and that tSCS can increase their spinal excitability and reduce their PLP and stump pain. However, there are individual differences in the extent of altered spinal excitability and changes in reflex recruitment following tSCS. Future work will further investigate the changes in spinal excitability and pain measures following tSCS and how they differ in people with versus without a neuropathy, as well as following acute, sub-acute, and chronic amputation. By explicitly investigating the effects of neuropathy and time post-amputation, the commencement and duration of treatment with tSCS may be optimized for maximal pain relief.

The current study did not include a cohort receiving sham stimulation. Any study investigating a treatment for pain must take the placebo effect into consideration. The placebo effect in this case refers to participants reporting pain relief because they know that the therapy is designed to relieve pain, and could confound any true pain relieving effects of the therapy (83). Pain treatment studies are heavily influenced by participants experiencing the placebo effect (84,85). To account for this, we chose outcome measures that were both subjective and objective. It is possible that the VAS and MPQ scores were influenced by the placebo effect because they rely on the participant subjectively rating their pain throughout the study. However, the changes in PPT and reflex thresholds and recruitment were objective measures, demonstrating that tSCS modulates spinal sensorimotor pathways and reduces hyperalgesia. Nonetheless, future studies should include a group receiving sham stimulation, which can be accomplished by turning stimulation on and slowly reducing the stimulation amplitude to sub-perceptual levels (86).

Clinical Utility and Comparison to Other Methods

As previously mentioned, neuromodulatory therapies that use electrical stimulation are often a last resort for treating PLP (7). TENS is better suited for treating stump pain (20,21), and eSCS and DRGS require a surgical implant. Here, we proposed a non-invasive method of modulating spinal networks to reduce PLP and stump pain. tSCS is a therapy that could be a more accessible intervention to those who cannot or do not want to undergo a surgical procedure. tSCS could also be used before eSCS or DRGS to determine if the patient will respond to a therapy that targets the dorsal roots. TENS, eSCS, and DRGS are thought to provide pain relief via the Gate Control Theory of Pain (87,88), in which the activation of large-diameter Aβ fibers inhibit activity in nociceptive C-fibers in the dorsal horn of the spinal cord (89,90). It is possible that tSCS also provides pain relief by activating similar pathways.

tSCS is easy to use, with few and commercially-available components. Anecdotes from our participants conveyed that the stimulation was tolerable and even unnoticeable after a few minutes. Furthermore, they expressed that they would be willing to use an at-home version of the system as long as the electrode placement could be streamlined. While the stimulation was well-tolerated by our participants, who all had intact sensation on their lower back, it is important to

medRxiv preprint doi: https://doi.org/10.1101/2023.04.13.23288483; this version posted April 17, 2023. The copyright holder for this preprint (which was not certified by peer review) is the author/funder, who has granted medRxiv a license to display the preprint in perpetuity. All rights reserved. No reuse allowed without permission.

be mindful that electrical stimulation can be uncomfortable for some, and that proper adhesion of the electrodes is important for maintaining comfort. It is also important to consider that contractions of the paraspinal muscles can cause discomfort and a more midline electrode placement can reduce this discomfort (42,91). We employed a high-frequency carrier of 10 kHz in our stimulation waveform because it has been proposed to be more comfortable than conventional 1 ms-long biphasic stimulation trains (45,47,92,93). However, we recently reported that the addition of a high-frequency carrier does not make tSCS more comfortable, and actually excites spinal reflex pathways less efficiently (42). Many prior studies testing tSCS to restore motor function and reduce spasticity used a conventional waveform (50,92,94). Both waveforms target the same reflex pathway (42), but future studies should be performed to ensure comfort during continuous stimulation with the conventional waveform in people with intact sensation.

CONCLUSIONS

The spinal cord is hypoexcitable in people with transtibial amputations who suffer from PLP, which differs from other chronic and neuropathic pain syndromes. Five days of tSCS reduced the frequency and intensity of stump pain and PLP. Furthermore, tSCS modulated spinal reflex pathways and increased their excitability towards that of neurologically intact individuals. Surprisingly, tSCS evoked sensory percepts in the missing limb of a participant with a sub-acute amputation, suggesting that tSCS could be used as a sensory neuroprosthesis. Overall, tSCS is a non-invasive and non-pharmacological neuromodulation method, offering a new hope for people with limb amputations suffering from PLP.

medRxiv preprint doi: https://doi.org/10.1101/2023.04.13.23288483; this version posted April 17, 2023. The copyright holder for this preprint (which was not certified by peer review) is the author/funder, who has granted medRxiv a license to display the preprint in perpetuity. All rights reserved. No reuse allowed without permission.

ACKNOWLEDGMENTS

We greatly appreciate the National Center of National Center for Neuromodulation (NC NM4R) at the Medical University of South Carolina (MUSC) for providing pilot funding for this study. We would like to thank Debbie Harrington, Casey Konopisos, and Alayna Schwerer for their assistance with the IRB protocol, clinical trial registration, and participant recruitment. We are grateful for the advice provided by Bailey Petersen regarding the placements of the tSCS and EMG electrodes. We would also like to thank Axelgaard for providing us with a suite of electrodes. Finally, we would like to thank our phenomenal research participants for their commitment to science and willingness to participate in this study.

FUNDING

Research reported in this publication was supported by pilot funding from the National Institutes of Health National Center of Neuromodulation for Rehabilitation, the National Center for Complementary and Integrative Health, the National Institute on Deafness and Other Communication Disorders, and the National Institute of Neurological Disorders and Stroke. NIH/NICHD Grant Number P2CHD086844 which was awarded to the Medical University of South Carolina. The contents are solely the responsibility of the authors and do not necessarily represent the official views of the NIH or NICHD.

This study was also funded by the Department of Mechanical Engineering and the Neuroscience Institute at Carnegie Mellon University.

CLINICAL TRIAL INFORMATION

The funding for this study was registered under clinical trial NCT04543786.

CONFLICTS OF INTEREST

DJW is a co-founder and shareholder of Reach Neuro, Inc.; DJW is a consultant and shareholder of Neuronoff, Inc.; DJW is a shareholder and scientific board member for NeuroOne Medical, Inc.; DJW is a shareholder of Bionic Power Inc., Iota Biosciences Inc., and Blackfynn Inc. The other authors declare no conflicts of interests in relation to this work.

medRxiv preprint doi: https://doi.org/10.1101/2023.04.13.23288483; this version posted April 17, 2023. The copyright holder for this preprint (which was not certified by peer review) is the author/funder, who has granted medRxiv a license to display the preprint in perpetuity. All rights reserved. No reuse allowed without permission.

REFERENCES

1. Ziegler-Graham K, MacKenzie EJ, Ephraim PL, Travison TG, Brookmeyer R. Estimating the Prevalence of Limb Loss in the United States: 2005 to 2050. 2008 Mar;89(3):422–9.
2. Geiss LS, Li Y, Hora I, Albright A, Rolka D, Gregg EW. Resurgence of Diabetes-Related Nontraumatic Lower-Extremity Amputation in the Young and Middle-Aged Adult U.S. Population. Diabetes Care. 2019;42(1):50–4.
3. Ephraim PL, Wegener ST, MacKenzie EJ, Dillingham TR, Pezzin LE. Phantom pain, residual limb pain, and back pain in amputees: results of a national survey. Arch Phys Med Rehabil. 2005 Oct;86(10):1910–9.
4. van der Schans CP, Geertzen JHB, Schoppen T, Dijkstra PU. Phantom pain and health-related quality of life in lower limb amputees. J Pain Symptom Manage. 2002 Oct;24(4):429–36.
5. Carlen PL, Wall PD, Nadvorna H, Steinbach T. Phantom limbs and related phenomena in recent traumatic amputations. Neurology. 1978 Mar;28(3):211–7.
6. Hsu E, Cohen SP. Postamputation pain: epidemiology, mechanisms, and treatment. J Pain Res. 2013;6:121–36.
7. Urits I, Seifert D, Seats A, Giacomazzi S, Kipp M, Orhurhu V, et al. Treatment Strategies and Effective Management of Phantom Limb-Associated Pain. Curr Pain Headache Rep. 2019 Jul 29;23(9):64.
8. Jensen TS, Krebs B, Nielsen J, Rasmussen P. Immediate and long-term phantom limb pain in amputees: incidence, clinical characteristics and relationship to pre-amputation limb pain. Pain. 1985 Mar;21(3):267–78.
9. Petersen BA, Nanivadekar AC, Chandrasekaran S, Fisher LE. Phantom limb pain: peripheral neuromodulatory and neuroprosthetic approaches to treatment. Muscle Nerve. 2019;59(2):154–67.
10. Padovani MT, Martins MRI, Venâncio A, Forni JEN. Anxiety, depression and quality of life in individuals with phantom limb pain. Acta Ortop Bras. 2015;23(2):107–10.
11. Chan BL, Witt R, Charrow AP, Magee A, Howard R, Pasquina PF, et al. Mirror therapy for phantom limb pain. N Engl J Med. 2007 Nov 22;357(21):2206–7.
12. Finn SB, Perry BN, Clasing JE, Walters LS, Jarzombek SL, Curran S, et al. A Randomized, Controlled Trial of Mirror Therapy for Upper Extremity Phantom Limb Pain in Male Amputees. Front Neurol. 2017;8:267.
13. Barbin J, Seetha V, Casillas JM, Paysant J, Pérennou D. The effects of mirror therapy on pain and motor control of phantom limb in amputees: A systematic review. Ann Phys Rehabil Med. 2016 Sep;59(4):270–5.
14. Park RH, Liston JM, Samuel AR, Forster GL, DeGeorge BR. Risk Factors for Prolonged Opioid Consumption in Lower Extremity Amputees. Plastic and Reconstructive Surgery – Global Open. 2022 Feb;10(2):e4026.
15. Davis RW. Phantom sensation, phantom pain, and stump pain. Arch Phys Med Rehabil. 1993 Jan;74(1):79–91.
16. Hu YS, Li YJ, Zhang XH, Zhang YQ, Ma K, Yu T. [A study on neurosurgical treatment for phantom limb pain]. Zhonghua Wai Ke Za Zhi. 2007 Dec 15;45(24):1668–71.
17. Tomycz ND, Moossy JJ. Follow-up 26 years after dorsal root entry zone thermocoagulation for brachial plexus avulsion and phantom limb pain. J Neurosurg. 2011 Jan;114(1):196–9.
18. Chalil A, Wang Q, Abbass M, Santyr BG, MacDougall KW, Staudt MD. Dorsal Root Entry Zone Lesioning for Brachial Plexus Avulsion Injuries: Case Series and Literature Review. Frontiers in Pain Research [Internet]. 2021 [cited 2023 Feb 2];2. Available from: https://www.frontiersin.org/articles/10.3389/fpain.2021.749801
19. Ruiz-Juretschke F, García-Salazar F, García-Leal R, Fernández-Carballal C, Iza B, Garbizu JM, et al. Treatment of neuropathic deafferentation pain using DREZ lesions; long-term results. Neurologia. 2011;26(1):26–31.
20. Mulvey MR, Radford HE, Fawkner HJ, Hirst L, Neumann V, Johnson MI. Transcutaneous electrical nerve stimulation for phantom pain and stump pain in adult amputees. Pain Pract. 2013 Apr;13(4):289–96.
21. Tilak M, Isaac SA, Fletcher J, Vasanthan LT, Subbaiah RS, Babu A, et al. Mirror Therapy and Transcutaneous Electrical Nerve Stimulation for Management of Phantom Limb Pain in Amputees - A Single Blinded Randomized Controlled Trial. Physiother Res Int. 2016 Jun;21(2):109–15.

medRxiv preprint doi: https://doi.org/10.1101/2023.04.13.23288483; this version posted April 17, 2023. The copyright holder for this preprint (which was not certified by peer review) is the author/funder, who has granted medRxiv a license to display the preprint in perpetuity. All rights reserved. No reuse allowed without permission.

22. Aiyer R, Barkin RL, Bhatia A, Gungor S. A systematic review on the treatment of phantom limb pain with spinal cord stimulation. Pain Manag. 2017 Jan;7(1):59–69.
23. Krainick JU, Thoden U, Riechert T. Spinal cord stimulation in post-amputation pain. Surg Neurol. 1975 Jul;4(1):167–70.
24. Krainick JU, Thoden U, Riechert T. Pain reduction in amputees by long-term spinal cord stimulation. Long-term follow-up study over 5 years. J Neurosurg. 1980 Mar;52(3):346–50.
25. Viswanathan A, Phan PC, Burton AW. Use of spinal cord stimulation in the treatment of phantom limb pain: case series and review of the literature. Pain Pract. 2010;10(5):479–84.
26. Bunch JR, Goldstein HV, Hurley RW. Complete coverage of phantom limb and stump pain with constant current SCS system: a case report and review of the literature. Pain Pract. 2015 Jan;15(1):E20-26.
27. Nanivadekar AC, Bose R, Petersen BA, Okorokova EV, Sarma D, Farooqui J, et al. Spinal cord stimulation restores sensation, improves function, and reduces phantom pain after transtibial amputation [Internet]. medRxiv; 2022 [cited 2022 Oct 5]. p. 2022.09.15.22279956. Available from: https://www.medrxiv.org/content/10.1101/2022.09.15.22279956v1
28. Eldabe S, Burger K, Moser H, Klase D, Schu S, Wahlstedt A, et al. Dorsal Root Ganglion (DRG) Stimulation in the Treatment of Phantom Limb Pain (PLP). Neuromodulation. 2015 Oct;18(7):610–6; discussion 616-617.
29. Esposito MF, Malayil R, Hanes M, Deer T. Unique Characteristics of the Dorsal Root Ganglion as a Target for Neuromodulation. Pain Med. 2019 01;20(Suppl 1):S23–30.
30. Woolf CJ. Evidence for a central component of post-injury pain hypersensitivity. Nature. 1983 Dec 15;306(5944):686–8.
31. Woolf CJ, Thompson SWN. The induction and maintenance of central sensitization is dependent on N-methyl-D-aspartic acid receptor activation; implications for the treatment of post-injury pain hypersensitivity states. Pain. 1991 Mar;44(3):293–9.
32. Melzack R, Coderre TJ, Katz J, Vaccarino AL. Central neuroplasticity and pathological pain. Ann N Y Acad Sci. 2001 Mar;933:157–74.
33. Woolf CJ, Shortland P, Coggeshall RE. Peripheral nerve injury triggers central sprouting of myelinated afferents. Nature. 1992 Jan 2;355(6355):75–8.
34. McLachlan EM, Jänig W, Devor M, Michaelis M. Peripheral nerve injury triggers noradrenergic sprouting within dorsal root ganglia. Nature. 1993 Jun;363(6429):543–6.
35. Vaso A, Adahan HM, Gjika A, Zahaj S, Zhurda T, Vyshka G, et al. Peripheral nervous system origin of phantom limb pain. Pain. 2014 Jul;155(7):1384–91.
36. Wall PD, Devor M. Sensory afferent impulses originate from dorsal root ganglia as well as from the periphery in normal and nerve injured rats. Pain. 1983 Dec;17(4):321–39.
37. Thompson CS, Hiller CE, Schabrun SM. Altered spinal-level sensorimotor control related to pain and perceived instability in people with chronic ankle instability. J Sci Med Sport. 2019 Apr;22(4):425–9.
38. Valero-Cabré A, Navarro X. H reflex restitution and facilitation after different types of peripheral nerve injury and repair. Brain Res. 2001 Nov 23;919(2):302–12.
39. Lee-Kubli CAG, Calcutt NA. Altered rate-dependent depression of the spinal H-reflex as an indicator of spinal disinhibition in models of neuropathic pain. Pain. 2014 Feb;155(2):250–60.
40. Marshall AG, Lee-Kubli C, Azmi S, Zhang M, Ferdousi M, Mixcoatl-Zecuatl T, et al. Spinal Disinhibition in Experimental and Clinical Painful Diabetic Neuropathy. Diabetes. 2017 May;66(5):1380–90.
41. Lee-Kubli C, Marshall AG, Malik RA, Calcutt NA. The H-Reflex as a Biomarker for Spinal Disinhibition in Painful Diabetic Neuropathy. Curr Diab Rep. 2018 23;18(1):1.
42. Dalrymple AN, Hooper CA, Kuriakose MG, Capogrosso M, Weber DJ. Using a high-frequency carrier does not improve comfort of transcutaneous spinal cord stimulation. J Neural Eng. 2023 Jan;20(1):016016.
43. Hofstoetter US, Freundl B, Binder H, Minassian K. Common neural structures activated by epidural and transcutaneous lumbar spinal cord stimulation: Elicitation of posterior root-muscle reflexes. PLoS ONE. 2018;13(1):e0192013.
44. Hofstoetter US, Hofer C, Kern H, Danner SM, Mayr W, Dimitrijevic MR, et al. Effects of transcutaneous spinal cord stimulation on voluntary locomotor activity in an incomplete spinal cord injured individual.

medRxiv preprint doi: https://doi.org/10.1101/2023.04.13.23288483; this version posted April 17, 2023. The copyright holder for this preprint (which was not certified by peer review) is the author/funder, who has granted medRxiv a license to display the preprint in perpetuity. All rights reserved. No reuse allowed without permission.

Biomedical Engineering / Biomedizinische Technik [Internet]. 2013 [cited 2020 Jan 14]; Available from: https://www.degruyter.com/view/j/bmte.2013.58.issue-s1-A/bmt-2013-4014/bmt-2013-4014.xml

45. Inanici F, Brighton LN, Samejima S, Hofstetter CP, Moritz CT. Transcutaneous Spinal Cord Stimulation Restores Hand and Arm Function After Spinal Cord Injury. IEEE Transactions on Neural Systems and Rehabilitation Engineering. 2021;29:310–9.
46. Keller A, Singh G, Sommerfeld JH, King M, Parikh P, Ugiliweneza B, et al. Noninvasive spinal stimulation safely enables upright posture in children with spinal cord injury. Nat Commun. 2021 Oct 6;12(1):5850.
47. Sayenko DG, Rath M, Ferguson AR, Burdick JW, Havton LA, Edgerton VR, et al. Self-Assisted Standing Enabled by Non-Invasive Spinal Stimulation after Spinal Cord Injury. J Neurotrauma. 2019 May 1;36(9):1435–50.
48. Hofstoetter US, Freundl B, Danner SM, Krenn MJ, Mayr W, Binder H, et al. Transcutaneous Spinal Cord Stimulation Induces Temporary Attenuation of Spasticity in Individuals with Spinal Cord Injury. J Neurotrauma. 2020 Feb 1;37(3):481–93.
49. Hofstoetter US, McKay WB, Tansey KE, Mayr W, Kern H, Minassian K. Modification of spasticity by transcutaneous spinal cord stimulation in individuals with incomplete spinal cord injury. J Spinal Cord Med. 2014 Mar;37(2):202–11.
50. Knikou M, Murray LM. Repeated transspinal stimulation decreases soleus H-reflex excitability and restores spinal inhibition in human spinal cord injury. PLoS ONE. 2019;14(9):e0223135.
51. Jerath N, Kimura J. F wave, A wave, H reflex, and blink reflex. Handb Clin Neurol. 2019;160:225–39.
52. Lee DH, Claussen GC, Oh S. Clinical nerve conduction and needle electromyography studies. J Am Acad Orthop Surg. 2004 Aug;12(4):276–87.
53. Calvert JS, Manson GA, Grahn PJ, Sayenko DG. Preferential activation of spinal sensorimotor networks via lateralized transcutaneous spinal stimulation in neurologically intact humans. J Neurophysiol. 2019 Nov 1;122(5):2111–8.
54. Krenn M, Toth A, Danner SM, Hofstoetter US, Minassian K, Mayr W. Selectivity of transcutaneous stimulation of lumbar posterior roots at different spinal levels in humans. Biomed Tech (Berl). 2013 Aug;58 Suppl 1.
55. Kooijman CM, Dijkstra PU, Geertzen JHB, Elzinga A, van der Schans CP. Phantom pain and phantom sensations in upper limb amputees: an epidemiological study. Pain. 2000 Jul 1;87(1):33–41.
56. Strand LI, Ljunggren AE, Bogen B, Ask T, Johnsen TB. The Short-Form McGill Pain Questionnaire as an outcome measure: test-retest reliability and responsiveness to change. Eur J Pain. 2008 Oct;12(7):917–25.
57. Nobrega JAM, Pinheiro DS, Manzano GM, Kimura J. Various aspects of F-wave values in a healthy population. Clinical Neurophysiology. 2004 Oct 1;115(10):2336–42.
58. Pereira M, Swash M, de Carvalho M. Exercise following immobility increases lower motor neuron excitability: F-wave and H-reflex studies. Neurophysiol Clin. 2022 Apr;52(2):147–56.
59. Pereira M, Swash M, de Carvalho M. Immobility and F-waves: Impact on lower motor neuron excitability. Muscle & Nerve. 2020;61(4):480–4.
60. Millán-Guerrero R, Trujillo-Hernández B, Isais-Millán S, Prieto-Díaz-Chávez E, Vásquez C, Caballero-Hoyos JR, et al. H-reflex and clinical examination in the diagnosis of diabetic polyneuropathy. J Int Med Res. 2012;40(2):694–700.
61. Feldman EL, Nave KA, Jensen TS, Bennett DLH. New Horizons in Diabetic Neuropathy: Mechanisms, Bioenergetics, and Pain. Neuron. 2017 Mar 22;93(6):1296–313.
62. Mellion M, Gilchrist JM, de la Monte S. Alcohol-related peripheral neuropathy: nutritional, toxic, or both? Muscle Nerve. 2011 Mar;43(3):309–16.
63. Kane NM, Oware A. Nerve conduction and electromyography studies. J Neurol. 2012 Jul;259(7):1502–8.
64. Makin TR, Amoruso E, Arribas EM, Buehler S, Dowdall L, Kieliba, P., et al. Phantom limbs and brain plasticity in amputees. In: Sherman, SM (ed), Oxford Research Encyclopedia of Neuroscience [Internet]. Oxford : Oxford University Press; 2020 [cited 2022 Sep 27]. p. 1–31. Available from: http://hdl.handle.net/2066/229290

medRxiv preprint doi: https://doi.org/10.1101/2023.04.13.23288483; this version posted April 17, 2023. The copyright holder for this preprint (which was not certified by peer review) is the author/funder, who has granted medRxiv a license to display the preprint in perpetuity. All rights reserved. No reuse allowed without permission.

65. Wesselink DB, van den Heiligenberg FM, Ejaz N, Dempsey-Jones H, Cardinali L, Tarall-Jozwiak A, et al. Obtaining and maintaining cortical hand representation as evidenced from acquired and congenital handlessness. Elife. 2019 Feb 5;8:e37227.
66. Gunduz ME, Pinto CB, Saleh Velez FG, Duarte D, Pacheco-Barrios K, Lopes F, et al. Motor Cortex Reorganization in Limb Amputation: A Systematic Review of TMS Motor Mapping Studies. Front Neurosci. 2020;14:314.
67. Florence SL, Taub HB, Kaas JH. Large-scale sprouting of cortical connections after peripheral injury in adult macaque monkeys. Science. 1998 Nov 6;282(5391):1117–21.
68. Jones EG, Pons TP. Thalamic and brainstem contributions to large-scale plasticity of primate somatosensory cortex. Science. 1998 Nov 6;282(5391):1121–5.
69. Davis KD, Kiss ZHT, Luo L, Tasker RR, Lozano AM, Dostrovsky JO. Phantom sensations generated by thalamic microstimulation. Nature. 1998 Jan;391(6665):385–7.
70. Jain N, Qi HX, Collins CE, Kaas JH. Large-scale reorganization in the somatosensory cortex and thalamus after sensory loss in macaque monkeys. J Neurosci. 2008 Oct 22;28(43):11042–60.
71. Li L, Gainey MA, Goldbeck JE, Feldman DE. Rapid homeostasis by disinhibition during whisker map plasticity. Proc Natl Acad Sci U S A. 2014 Jan 28;111(4):1616–21.
72. Wesselink DB, Sanders ZB, Edmondson LR, Dempsey-Jones H, Kieliba P, Kikkert S, et al. Malleability of the cortical hand map following a finger nerve block. Science Advances. 2022 Apr 22;8(16):eabk2393.
73. Anani A, Körner L. Discrimination of phantom hand sensations elicited by afferent electrical nerve stimulation in below-elbow amputees. Med Prog Technol. 1979 Jun 15;6(3):131–5.
74. Charkhkar H, Shell CE, Marasco PD, Pinault GJ, Tyler DJ, Triolo RJ. High-density peripheral nerve cuffs restore natural sensation to individuals with lower-limb amputations. J Neural Eng. 2018 Jul;15(5):056002.
75. Clippinger FW, Seaber AV, McElhaney JH, Harrelson JM, Maxwell GM. Afferent sensory feedback for lower extremity prosthesis. Clin Orthop Relat Res. 1982 Sep;(169):202–6.
76. D'Anna E, Petrini FM, Artoni F, Popovic I, Simanić I, Raspopovic S, et al. A somatotopic bidirectional hand prosthesis with transcutaneous electrical nerve stimulation based sensory feedback. Sci Rep. 2017 07;7(1):10930.
77. Raspopovic S, Capogrosso M, Petrini FM, Bonizzato M, Rigosa J, Di Pino G, et al. Restoring Natural Sensory Feedback in Real-Time Bidirectional Hand Prostheses. Science Translational Medicine. 2014 Feb 5;6(222):222ra19-222ra19.
78. Chandrasekaran S, Nanivadekar AC, McKernan G, Helm ER, Boninger ML, Collinger JL, et al. Sensory restoration by epidural stimulation of the lateral spinal cord in upper-limb amputees. Makin TR, Ivry RB, Makin TR, Perich MG, editors. eLife. 2020 Jul 21;9:e54349.
79. Nanivadekar AC, Chandrasekaran S, Helm ER, Boninger ML, Collinger JL, Gaunt RA, et al. Closed-loop stimulation of lateral cervical spinal cord in upper-limb amputees to enable sensory discrimination: a case study. Sci Rep. 2022 Oct 11;12(1):17002.
80. Bestmann S, Oliviero A, Voss M, Dechent P, Lopez-Dolado E, Driver J, et al. Cortical correlates of TMS-induced phantom hand movements revealed with concurrent TMS-fMRI. Neuropsychologia. 2006;44(14):2959–71.
81. Reilly KT, Sirigu A. The motor cortex and its role in phantom limb phenomena. Neuroscientist. 2008 Apr;14(2):195–202.
82. Rose MA, Kam PCA. Gabapentin: pharmacology and its use in pain management. Anaesthesia. 2002;57(5):451–62.
83. Colloca L. The Placebo Effect in Pain Therapies. Annu Rev Pharmacol Toxicol. 2019 Jan 6;59:191–211.
84. Finsen V, Persen L, Løvlien M, Veslegaard EK, Simensen M, Gåsvann AK, et al. Transcutaneous electrical nerve stimulation after major amputation. J Bone Joint Surg Br. 1988 Jan;70(1):109–12.
85. Kjær SW, Rice ASC, Wartolowska K, Vase L. Neuromodulation: more than a placebo effect? PAIN. 2020 Mar;161(3):491.
86. Rakel B, Cooper N, Adams HJ, Messer BR, Frey Law LA, Dannen DR, et al. A New Transient Sham TENS Device Allows for Investigator Blinding While Delivering a True Placebo Treatment. J Pain. 2010 Mar;11(3):230–8.

medRxiv preprint doi: https://doi.org/10.1101/2023.04.13.23288483; this version posted April 17, 2023. The copyright holder for this preprint (which was not certified by peer review) is the author/funder, who has granted medRxiv a license to display the preprint in perpetuity. All rights reserved. No reuse allowed without permission.

87. Graham RD, Bruns TM, Duan B, Lempka SF. Dorsal root ganglion stimulation for chronic pain modulates Aβ-fiber activity but not C-fiber activity: A computational modeling study. Clinical Neurophysiology. 2019 Jun;130(6):941–51.
88. Sivanesan E, Maher DP, Raja SN, Linderoth B, Guan Y. Supraspinal Mechanisms of Spinal Cord Stimulation for Modulation of Pain: Five Decades of Research and Prospects for the Future. Anesthesiology. 2019 Apr;130(4):651–65.
89. Gibson W, Wand BM, O'Connell NE. Transcutaneous electrical nerve stimulation (TENS) for neuropathic pain in adults. Cochrane Database Syst Rev. 2017 Sep 14;9:CD011976.
90. Melzack R, Wall PD. Pain mechanisms: a new theory. Science. 1965 Nov 19;150(3699):971–9.
91. Manson GA, Calvert JS, Ling J, Tychhon B, Ali A, Sayenko DG. The relationship between maximum tolerance and motor activation during transcutaneous spinal stimulation is unaffected by the carrier frequency or vibration. Physiological Reports. 2020;8(5):e14397.
92. Gad P, Gerasimenko Y, Zdunowski S, Turner A, Sayenko D, Lu DC, et al. Weight Bearing Over-ground Stepping in an Exoskeleton with Non-invasive Spinal Cord Neuromodulation after Motor Complete Paraplegia. Front Neurosci [Internet]. 2017 [cited 2020 Jan 14];11. Available from: https://www.frontiersin.org/articles/10.3389/fnins.2017.00333/full
93. Gerasimenko Y, Gorodnichev R, Moshonkina T, Sayenko D, Gad P, Reggie Edgerton V. Transcutaneous electrical spinal-cord stimulation in humans. Ann Phys Rehabil Med. 2015 Sep;58(4):225–31.
94. Hofstoetter US, Freundl B, Lackner P, Binder H. Transcutaneous Spinal Cord Stimulation Enhances Walking Performance and Reduces Spasticity in Individuals with Multiple Sclerosis. Brain Sci. 2021 Apr 8;11(4):472.

medRxiv preprint doi: https://doi.org/10.1101/2023.04.13.23288483; this version posted April 17, 2023. The copyright holder for this preprint (which was not certified by peer review) is the author/funder, who has granted medRxiv a license to display the preprint in perpetuity. All rights reserved. No reuse allowed without permission.

SUPPLEMENTARY FIGURES

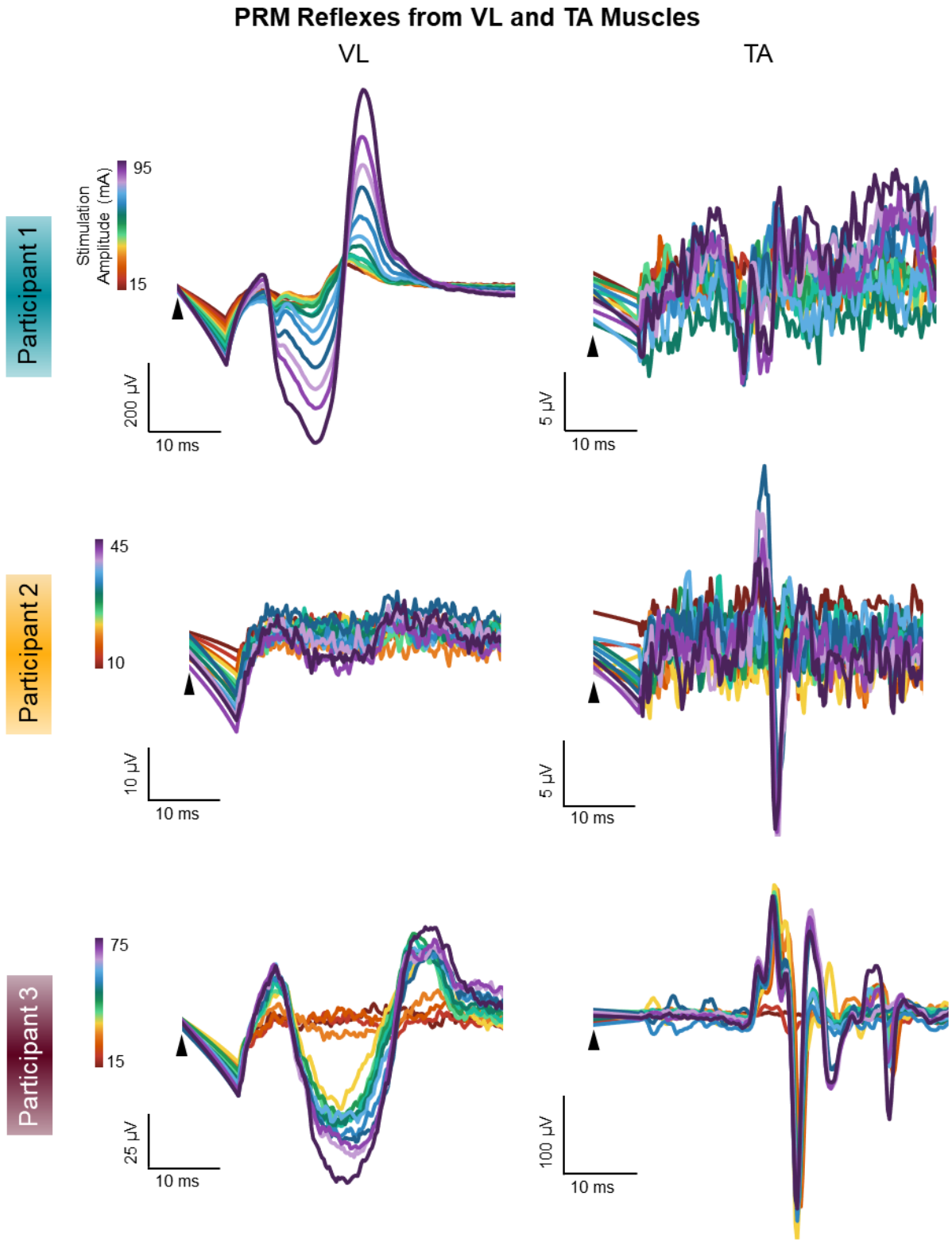

Supplementary Figure 1. Posterior root-muscle (PRM) reflexes recorded from the vastus lateralis (VL; left) and tibialis anterior (TA; right) muscles of each participant as stimulation amplitude was increased.

medRxiv preprint doi: https://doi.org/10.1101/2023.04.13.23288483; this version posted April 17, 2023. The copyright holder for this preprint (which was not certified by peer review) is the author/funder, who has granted medRxiv a license to display the preprint in perpetuity. All rights reserved. No reuse allowed without permission.

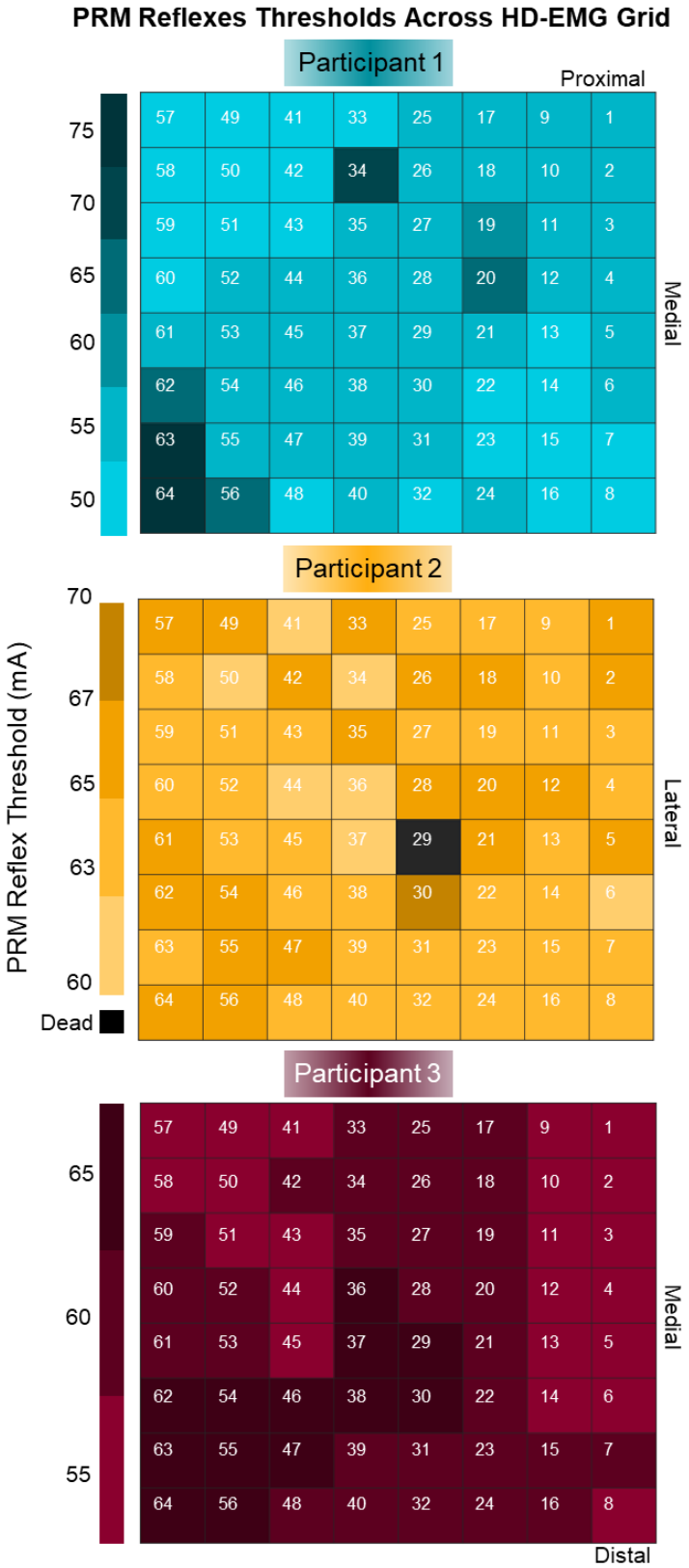

Supplementary Figure 2. Threshold stimulation amplitudes for evoking a posterior root-muscle (PRM) reflex for each electrode on the high-density electromyography (HD-EMG) grid for each participant. The medial and lateral orientations of the grids are dependent on which leg was amputated.

medRxiv preprint doi: https://doi.org/10.1101/2023.04.13.23288483; this version posted April 17, 2023. The copyright holder for this preprint (which was not certified by peer review) is the author/funder, who has granted medRxiv a license to display the preprint in perpetuity. All rights reserved. No reuse allowed without permission.



Supplementary Figure 3. Examples of posterior root-muscle (PRM) reflexes recorded at each electrode on the high-density electromyography (HD-EMG) grid evoked at a stimulation amplitude 2.5 times higher than the mean threshold amplitude for Participant 1.

medRxiv preprint doi: https://doi.org/10.1101/2023.04.13.23288483; this version posted April 17, 2023. The copyright holder for this preprint (which was not certified by peer review) is the author/funder, who has granted medRxiv a license to display the preprint in perpetuity. All rights reserved. No reuse allowed without permission.

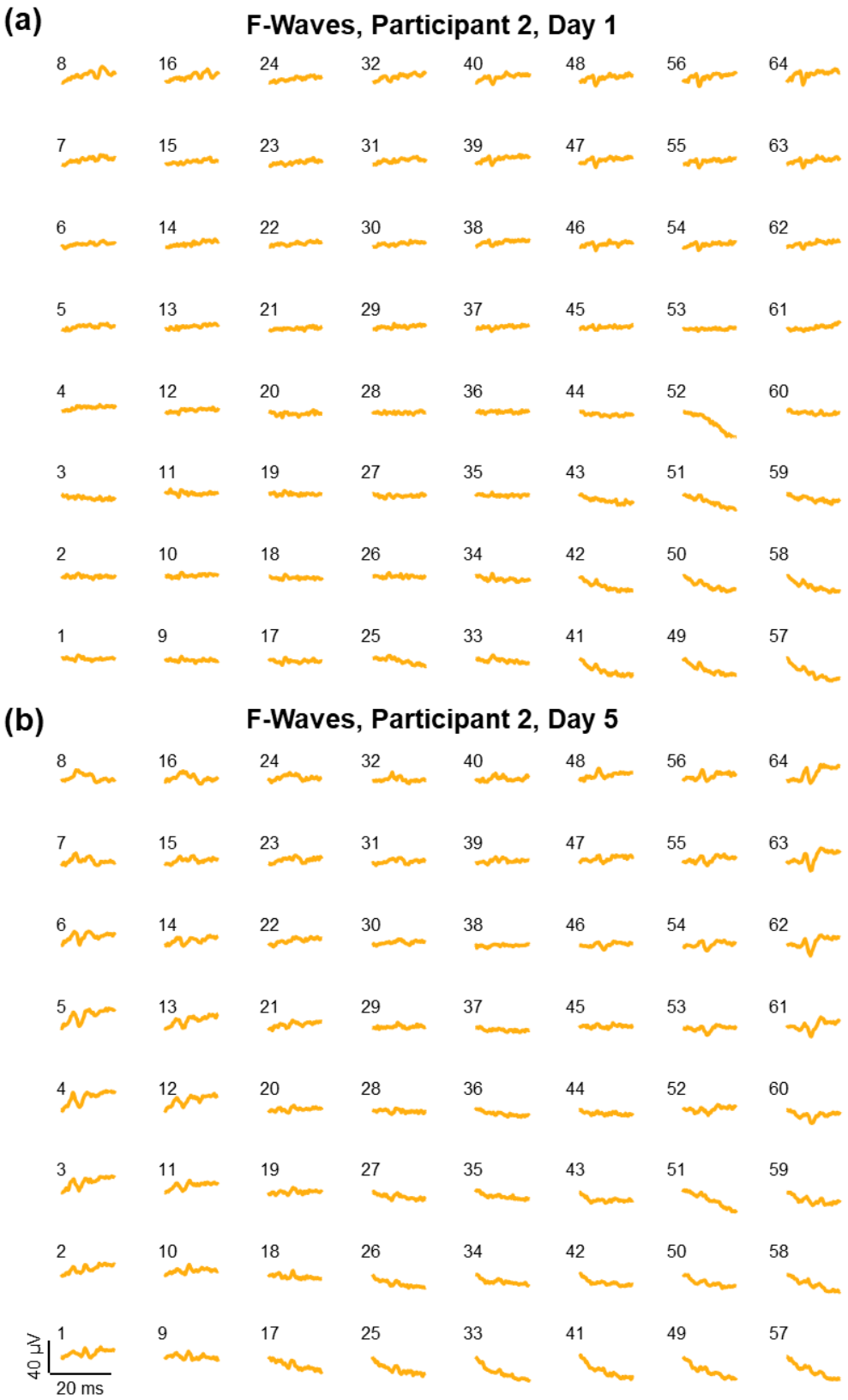

Supplementary Figure 4. Examples of F-waves recorded at each electrode on the high-density electromyography (HD-EMG) grid evoked at maximal stimulation amplitude for Participant 2 on Day 1 (a) and Day 5 (b).