

1 **Confirmation of the *MIR204* n.37C>T heterozygous variant as a cause of**
2 **chorioretinal dystrophy variably associated with iris coloboma, early-onset**
3 **cataracts and congenital glaucoma**

4
5 Jedlickova J. (1), Vajter M. (2), Barta T. (3), Black G. (4), Mares J. (5), Fichtl M. (2), Kousal
6 B. (2), Dudakova L. (1) and Liskova P. (1,2)

7
8
9
10 *1 Department of Paediatrics and Inherited Metabolic Disorders, First Faculty of Medicine,*
11 *Charles University and General University Hospital in Prague, Prague, Czech Republic*
12 *2 Department of Ophthalmology, First Faculty of Medicine, Charles University and General*
13 *University Hospital in Prague, Prague, Czech Republic*
14 *3 Department of Histology and Embryology, Faculty of Medicine, Masaryk University, Brno,*
15 *Czech Republic*
16 *4 Manchester Royal Eye Hospital, Oxford Road, Manchester, M13 9WL, UK*
17 *5 Department of Ophthalmology, Second Faculty of Medicine, Charles University and Motol*
18 *University Hospital, Prague, Czech Republic*

19
20
21
22
23
24 Corresponding author:

25 Petra Liskova, Prof.
26 Department of Paediatrics and Inherited Metabolic Disorders
27 General University Hospital and First Faculty of Medicine, Charles University
28 Ke Karlovu 2, Praha 2, 128 08, Prague, Czech Republic
29 Tel: +420 22496 7139, email: petra.liskova@lf1.cuni.cz

30
31
32 **ACKNOWLEDGEMENTS**

33 Funding: This publication was supported by MH CZ-DRO-VFN64165, NU20-07-00182, and
34 by national funds from the Ministry of Education, Youth and Sports under the European Joint
35 Program for Rare Diseases (Solve-RET 8F20004 No. 825575). PL and LD were also supported
36 by UNCE/MED/007 and JJ by SVV 26367/2017. TB was supported by the Czech Science
37 Foundation (GA21-08182S).

38
39
40 **CONFLICT OF INTEREST:** Authors declare no conflict of interest.

41 **ABSTRACT**

42 Four members of a three-generation family with early-onset chorioretinal dystrophy were
43 shown to be heterozygous carriers of the n.37C>T in *MIR204*. The identification of this
44 previously reported pathogenic variant confirms the existence of a distinct clinical entity caused
45 by a sequence change in *MIR204*. The chorioretinal dystrophy was variably associated with iris
46 coloboma, congenital glaucoma, and premature cataracts extending the phenotypic range of the
47 condition. In silico analysis of the n.37C>T variant revealed 713 novel targets. Additionally,
48 family members were shown to be affected by albinism resulting from biallelic pathogenic
49 *OCA2* variants.

50

51

52

53

54 **Key words:** *MIR204*, chorioretinal dystrophy, premature cataract, albinism, coloboma,
55 congenital glaucoma, *OCA2*

56 INTRODUCTION

57 Inherited retinal degenerations and major structural developmental eye disorders
58 (microphthalmia, anophthalmia, and coloboma) are a common cause of visual impairment in
59 childhood. One of the genes reported to be implicated in the development of these disorders is
60 *MIR204* (MIM *610942). Previously the n.37C>T variant, in the seed region of *MIR204*, was
61 found in 6 members from a five-generation family of white British descent and the associated
62 disease was termed “retinal dystrophy and iris coloboma with or without congenital cataract”
63 (RDICC, MIM #616722).¹

64 MicroRNAs (miRNAs) are short (20-24 nt) noncoding RNAs involved in post-
65 transcriptional regulation most commonly leading to translational inhibition or degradation of
66 the target mRNA.² *MIR204* is necessary for normal eye development including photoreceptor
67 differentiation and function. Morpholino-mediated knockdown of miR-204 in medaka fish
68 resulted in microphthalmia, abnormal lens formation, and altered dorsoventral patterning of the
69 retina with optic fissure coloboma.^{1,3}

70 In this study, we report a three-generation family with the occurrence of early-onset
71 chorioretinal dystrophy variably associated with iris coloboma, premature cataracts, and
72 congenital glaucoma in four members. Heterozygous variant n.37C>T in *MIR204* was detected.
73 In addition, molecular investigation resolved the presence of albinism in the spouse of the
74 proband and his three children by identifying *OCA2* pathogenic variants, including one
75 daughter with dual diagnosis.

76
77

78 METHODS

79 Sample collection and clinical examination

80 The study followed the tenets of the Declaration of Helsinki and was approved by the
81 Ethical review board of General University Hospital in Prague (reference number 412/20 S-
82 IV). All investigated subjects or their legal representatives provided informed consent with
83 examination and publishing of the results prior to the inclusion into the study.

84 Ocular examination included best corrected visual acuity (BCVA) measurements using
85 Snellen charts with extrapolation to decimal values, slit-lamp evaluation including funduscopy
86 and static automated perimetry (M-700, Medmont International, Vermont, Australia). Colour
87 fundus photography was obtained using Clarus 700 and/or FF 450 plus IR (Carl Zeiss Meditec
88 AG, Jena, Germany). Spectral domain optical coherence tomography (SD-OCT) was performed
89 using Spectralis (Heidelberg Engineering GmbH, Heidelberg, Germany). Severity of foveal

90 hypoplasia (grades 1-4) was assessed using morphological findings obtained by SD-OCT
91 according to a previously described scheme.⁴

92

93 **DNA extraction and variant description**

94 DNA was extracted using Gentra Puregene™ Blood Kit (Qiagen, Hilden, Germany) or
95 Oragene saliva kit (Oragene OG-300, DNA Genotek, Canada) according to the manufacturer's
96 instructions. Variant description followed the Human Genome Variation Society (HGVS)
97 guidelines.⁵ The pathogenicity of the detected variants was evaluated according to the American
98 College of Medical Genetics and Genomics (ACMG) and the Association for Molecular
99 Pathology recommendations.⁶

100

101 **Sequencing**

102 Exome sequencing was performed in the proband's daughter (individual III:4, Fig. 1)
103 and spouse (individual II:3, Fig. 1) using SureSelect Human All Exon V6 Kit (Agilent, Santa
104 Clara, California, USA), sequenced on a NovaSeq 6000 instrument (Illumina, San Diego, CA)
105 with 150 bp paired-end reads. Sequence reads were aligned against the hg19 version of the
106 human genome, using the Burrows-Wheeler Aligner (<http://bio-bwa.sourceforge.net/>). Variant
107 calling was performed with Genome Analysis Toolkit (version 4.2.6.1).⁷ Only rare variants (i.e.
108 minor allele frequency ≤ 0.001 as per gnomAD v2.1.1, v3.1.2)⁸ were further evaluated for
109 potential pathogenicity.

110 Genome sequencing was performed in the proband's spouse with the aim to search for
111 the second pathogenic variant in *OCA2*. NEBNext Ultra DNA library Prep kit with 150 bp
112 paired-end reads (Illumina) was used together with the Illumina NovaSeq 6000 sequencing
113 platform. Manual inspection of genome data in Integrative Genomics Viewer (IGV),⁹ allowed
114 for designing a set of primers to Sanger sequence the breakpoints of a detected structural
115 rearrangement in *OCA2*. Sanger sequencing was also used to track the segregation of
116 pathogenic variants. All primers used are listed in Supplementary Table 1 and Supplementary
117 Figure 1.

118

119 **miRNA target analysis**

120 To investigate the putative functional consequences of the n.37C>T variant on its target
121 genes, we applied miRNA target prediction tool miRDB (version 6.0).^{10,11} Both sequences WT
122 hsa-miR-204-5p (uuccuuugucauccaugccu) as well as n.37C>T hsa-miR-204-5p
123 (uuccuuugucauccaugccu) were submitted to the miRDB. The generated list of genes

124 including target scores for each variant (i.e. was used to create a heatmap (R version 4.1.2 and
125 pheatmap package). All the predicted targets have prediction scores between 50 and 100, which
126 are assigned by the computational algorithm. A predicted target with score >80 is considered
127 likely to be real. If the score is <60, it is recommended to provide additional supporting
128 evidence.

129 The functional annotation was generated by the Database for Annotation, Visualization
130 and Integrated Discovery (DAVID tool, version 2021)¹² using gene ontology annotation. Only
131 significant targets (p<0.001) were selected for the creation of the heatmap. The hairpin structure
132 was analysed using the RNAfold tool ([http://rna.tbi.univie.ac.at/cgi-
133 bin/RNAWebSuite/RNAfold.cgi](http://rna.tbi.univie.ac.at/cgi-bin/RNAWebSuite/RNAfold.cgi)).

134

135

136 **RESULTS**

137 ***MIR204 n.37C>T causes a distinct chorioretinal dystrophy***

138 We have identified a family with four members in three generations affected by
139 chorioretinal dystrophy variably associated with iris coloboma, early-onset cataracts, and
140 congenital glaucoma.

141 Exome sequencing showed that the youngest daughter of the proband (individual III:4,
142 Fig. 1) is a heterozygous carrier of the n.37C>T in *MIR204* (NR_029621.1), which has been
143 previously reported in one family.¹ Segregation analysis confirmed the presence of the n.37C>T
144 in *MIR204* in three other affected family members, i.e. the proband, his mother, and his oldest
145 daughter (Fig. 1). The variant was classified as pathogenic according to the ACMG criteria:
146 PS3_Strong (functional studies show a damaging effect), PS4_Supporting (prevalence of the
147 variant in affected individuals is significantly increased compared with controls, 2nd
148 independent occurrence), PM1_Supporting (variant is located in a well-established functional
149 domain), PM2_Supporting (extremely low-frequency in population databases), PP1_Moderate
150 (co-segregation with a disease in multiple affected family members, 5-6 meioses),
151 PP4_Moderate (patient's phenotype or family history is highly specific for a disease with a
152 single genetic aetiology).

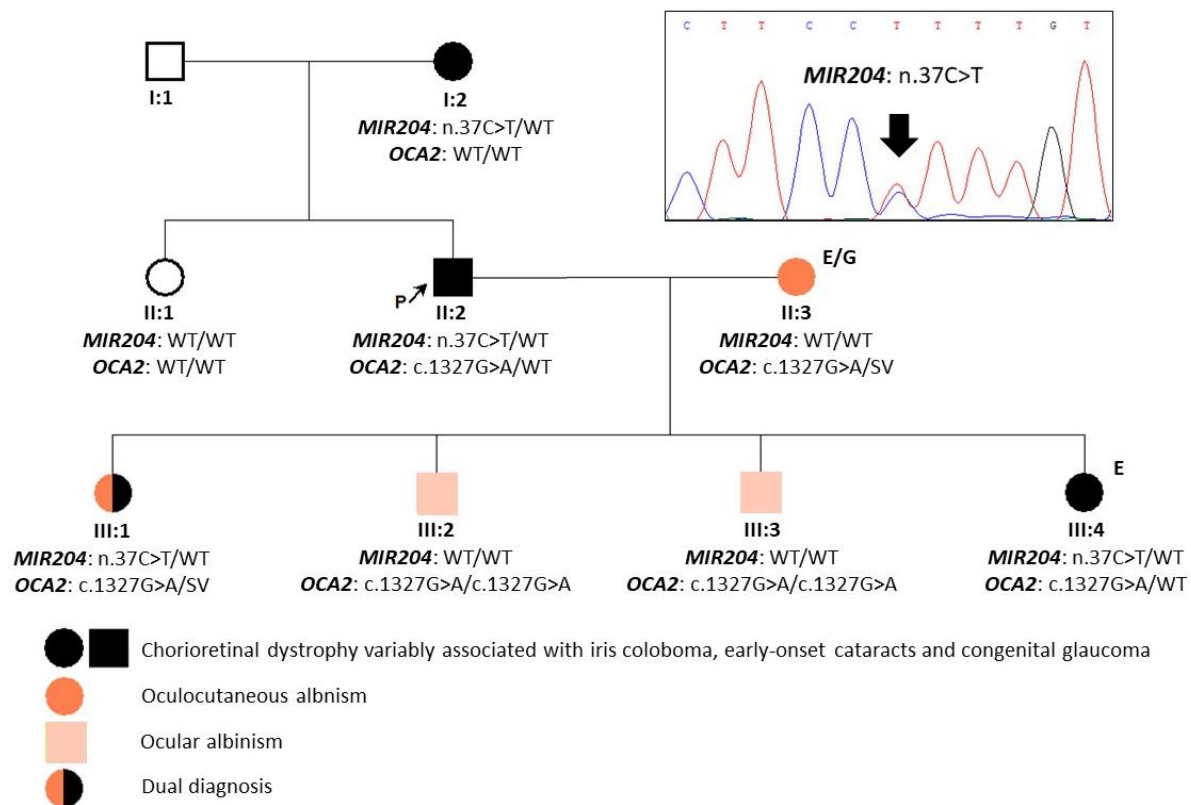
153 No rare variants evaluated as possibly pathogenic were identified in other genes
154 associated with developmental glaucoma and ocular coloboma in exome data of individual III:4
155 [PanelApp Ocular coloboma (Version 1.46) and Glaucoma (developmental) (Version 1.42)].¹³

156

157 ***Additional molecular genetic findings***

158 The spouse of the proband was found to be a compound heterozygote for the pathogenic
159 missense variant c.1327G>A p.(Val443Ile) in *OCA2* (NM_000275.3) and a large complex
160 pathogenic rearrangement, previously characterised in detail by Loftus et al.¹⁴ In brief, a 143 kb
161 inverted segment is reintroduced in intron 1 followed by an additional 184 kb deletion across
162 the same region, restoring exons 3–19 of *OCA2* to a copy-number neutral state. This variant is
163 defined by the HGVS nomenclature as
164 NC_000015.9:g.[28337021_28339403delins[CCTGGTTGTAGGTCTAACCTGGTTAGAAT
165 CA;28143225_28285967inv; C];[28119923_28303785del]. Loftus et al. suggested denoting
166 this structural variant (SV) as “143kb;184kb CxSV” allele. It has been predicted to generate an
167 mRNA transcript with novel splicing between exons 2 and 20, thus resulting in premature
168 truncation and a functionally null *OCA2* allele p.(Ser77Hisfs*7).¹⁴ The SV has been repeatedly
169 observed in compound heterozygosity with pathogenic variants in patients diagnosed with
170 albinism.¹⁴

171 Segregation analysis (Fig. 1) revealed that the proband is also a heterozygous carrier of
172 the c.1327G>A variant in *OCA2* which explained pseudodominance for albinism in this
173 particular family. The oldest daughter was shown to be a compound heterozygote for the
174 c.1327G>A inherited from the proband and the pathogenic *OCA2* SV inherited from her
175 mother, in addition to harbouring the n.37C>T in *MIR204*. Both sons had the *OCA2* c.1327G>A
176 in a homozygous state.



177

178 **Figure 1: Pedigree of the family and segregation of identified pathogenic variants in *MIR204* and**
 179 ***OCA2*.** NR_029621.1 and NM_000275.3 were taken as the reference sequences. E - exome
 180 sequencing; G - genome sequencing; SV - structural variant (*OCA2* “ 143kb;184kb CxSV” allele); WT
 181 - wild type.

182

183

184 ***Clinical features in the extended family***

185 The mother of the proband (individual I:2, Fig. 1) with no family history of ocular
 186 disease had bilateral retinal lesions, which were according to the available past medical records
 187 considered as a sequela of retinal toxoplasmosis in first decade of life. Due to gradual visual
 188 functions worsening, she started to attend school for the visually impaired in the adolescence.
 189 In her 30s she was diagnosed with a left eye cataract which was removed two years later. Upon
 190 clinical examination performed in her 70s, the patient was completely blind with no light
 191 perception. There was also cataract in the right eye, iris coloboma in the left eye, and advanced
 192 bilateral chorioretinal dystrophy (Table 1, Fig. 2A-D).

193 Clinical notes of the proband (individual II:2, Fig. 1) documented complaints about
 194 nyctalopia and bilateral retinal dystrophy misdiagnosed as congenital toxoplasmosis in
 195 adolescence. The manifestation of cataract is unknown, however available medical
 196 documentation described it as congenital. Bilateral cataract surgery was performed in his early
 197 20s. Serial measurements of BCVA showed gradual decline, with counting fingers in the right

198 eye and light projection in the left eye in the third decade of life (Table 1). When examined by
199 the authors, in his early 40s, there was a bilateral advanced chorioretinal atrophy (Fig. 2, Table
200 1).

201 The proband had four children. The youngest one, in early school age at the time of
202 clinical evaluation (individual III:4, Fig. 1), was noted to suffer from congenital glaucoma for
203 which she had been treated elsewhere. She underwent several antiglaucoma procedures in both
204 eyes (Table 1). Our examination revealed bilateral macular atrophic lesions with pigmented
205 edges. In addition, her fundus appeared pale bilaterally. There were no signs of premature
206 cataracts. She also developed band keratopathy in both eyes (Fig. 2G, H). BCVA was 0.06 and
207 light projection in the right and left eye, respectively.

208 The oldest child, (individual III:1, Fig. 1), was referred in adolescence with
209 oculocutaneous albinism. The clinical evaluation showed markedly low BCVA; 0.04 in the
210 right eye and 0.063 in the left eye, and advanced visual field constriction. SD-OCT revealed
211 absent foveal pit/depression and chorioretinal atrophy (Fig. 3). Fundus was hypopigmented
212 bilaterally but there were no focal lesions or pigment deposits.

213 The spouse of the proband (individual II:3, Fig. 1) had, similarly to her daughter, typical
214 oculocutaneous albinism characterised by pale skin, hair, eye lashes, iris translucency, fundus
215 hypopigmentation, with corresponding foveal hypoplasia and moderate decrease of BCVA
216 (Supplementary Fig. 2). Two sons of the proband, in the pre-teen and teenage years (individuals
217 III:2 and III:3, Fig. 1), reported no visual symptoms and correspondingly their uncorrected
218 visual acuity was 1.0 in both eyes. Slit-lamp examination did not reveal any anterior segment
219 pathology. There was a discreet fundus hypopigmentation and SD-OCT scans showed bilateral
220 foveal hypoplasia (grade 1) in both children (Supplementary Fig. 3).

221 Clinical findings of all the affected family members including BCVA at various time
222 points are summarised in Table 1.

Table 1: Clinical findings of affected individuals in the examined family

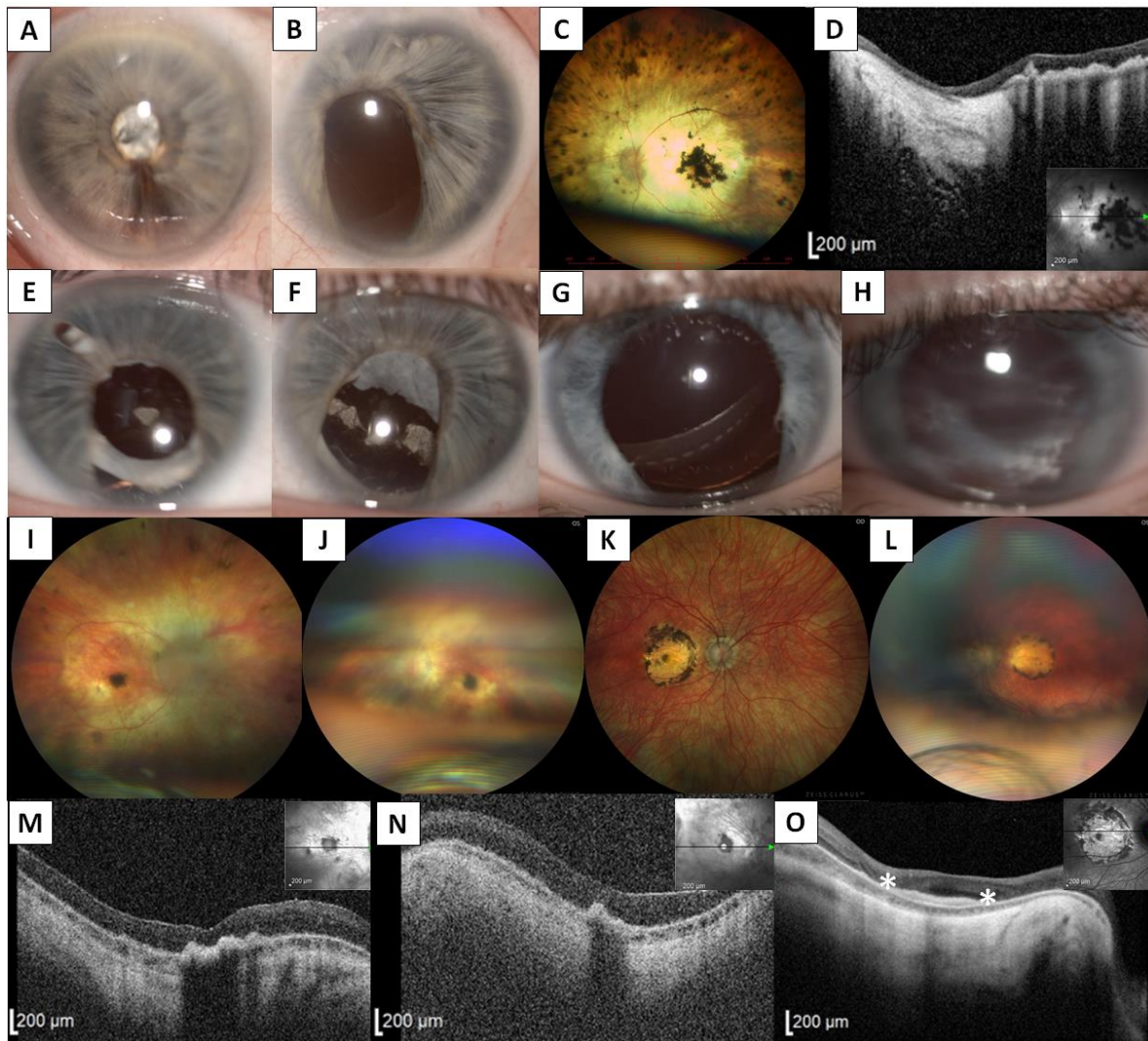
ID	Primary diagnosis	Age	BCVA RE (refraction)	BCVA LE (refraction)	Anterior segment	Posterior segment	Other	Surgical management
I:2	CRCCG	30s	LP	0.1 (-0.5 DS)	LE iris coloboma, BE early onset cataract	BE chorioretinal atrophy with central and peripheral RPE clumping	Night blindness, BE nystagmus	LE cataract surgery in her 30s
		70s	NLP	NLP				
II:2	CRCCG	10s	0.04 (-3.0 DS)	0.04 (-3.5 DS)	BE persistent pupillary membrane, BE iris coloboma, BE early onset cataract	BE chorioretinal atrophy with central and peripheral RPE clumping	Night blindness, BE nystagmus	RE cataract surgery in the 20s
		15s	0.04 (plan)	0.03 (plan)				
		25s	CF	LP				
		40s	LP	LP				
II:3	OCA2 (oculocutaneous)	40s	0.32 (+1.5 DS/-1.0 DC)	0.5 (+2.5 DS/-2.0 DC)	BE iris translucency	BE fundus hypopigmentation, BE foveal hypoplasia (grade 4)	BE nystagmus, white hair and very light-colored skin	None
III:1	CRCCG+OCA2 (oculocutaneous)	15s	0.04 (plan)	0.063 (plan)	BE iris translucency	BE fundus hypopigmentation, chorioretinal atrophy and irregular RPE distribution but no clumping, BE foveal hypoplasia (grade 4)	BE nystagmus, BE visual field constriction, white hair and very light-coloured skin	None
III:2	OCA2 (ocular)	10s	1.0 (plan)	1.0 (plan)	Normal	BE foveal hypoplasia (grade 1)	None	None
III:3	OCA2 (ocular)	10s	1.0 (plan)	1.0 (plan)	Normal	BE foveal hypoplasia (grade 1)	None	None
III:4	CRCCG	5-10 y	0.06 (-3.0 DS)	LP (-3.0 DS)	BE iris coloboma, LE band keratopathy	BE fundus hypopigmentation, BE atrophic lesion in the macula demarcated by pigmentary deposits	BE congenital glaucoma, BE nystagmus	BE CPC <1 y, RE TE <4 y, LE CPC 2x between 3-5 y, LE EDTA chelation <5 y

224

225

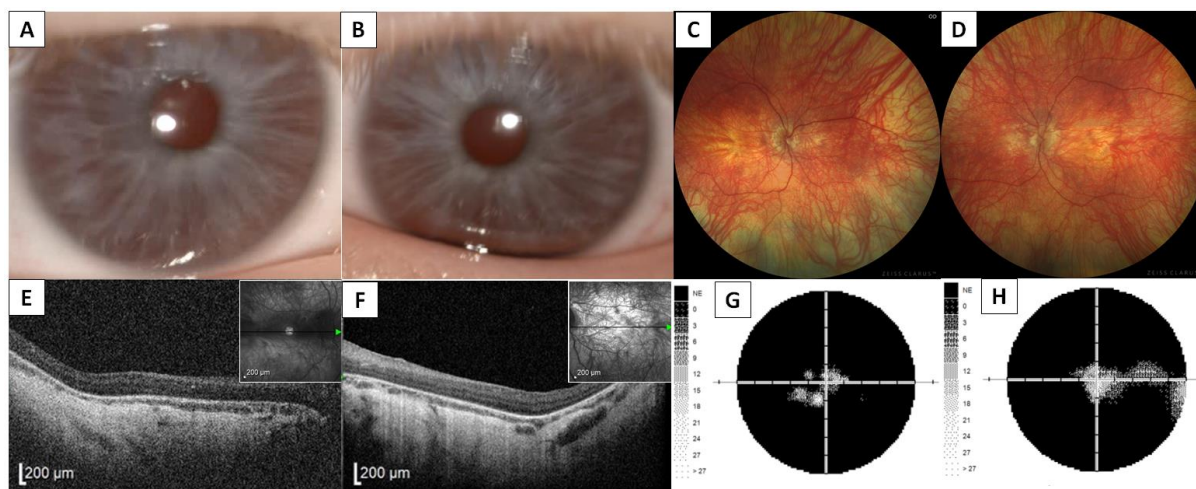
226

Abbreviations: BCVA - best corrected visual acuity; BE - both eyes; CF - counting fingers; CPC - cyclophotocoagulation; CRCCG - chorioretinal dystrophy variably associated with iris coloboma, early-onset cataract and congenital glaucoma; D - diopter; DC - diopter cylinder; DS - diopter sphere; EDTA - ethylenediaminetetraacetic acid; FH - foveal hypoplasia; LE - left eye; m - months; NLP - no light projection; RE - right eye; RPE - retinal pigment epithelium; TE - trabeculectomy; y - year



227

228 **Figure 2: Clinical findings in three family members with dominantly inherited chorioretinal dystrophy**
229 **variably associated with iris coloboma, congenital cataract, and glaucoma.** Anterior segment photography of
230 individual I:2 showing iris hypoplasia and intumescent cataract in the right eye (A), and iris hypoplasia with
231 coloboma and aphakia in the left eye (B). Left eye fundus photograph showing advanced chorioretinal atrophy with
232 pigment clumping in both the macula and retinal periphery (C) and corresponding transfoveal horizontal SD-OCT
233 scan documenting severe atrophy and thinning of the neurosensory retina and hyperplasia of the retinal pigment
234 epithelium (D). Anterior segment images of the proband (II:2) showing iris hypoplasia and coloboma in the right (E)
235 and left eye (F), and in individual III:4 documenting iris hypoplasia and coloboma in the right (G) and left eye (H).
236 Pale optic discs and advanced chorioretinal dystrophy manifesting as pale fundus with attenuated vessels, atrophic
237 lesion with pigmentary mottling in the macula, and occasional pigmentary deposits in the periphery in the right (I)
238 and left eye (J) in the proband. In comparison, his daughter (individual III:4) had a round lesion of chorioretinal
239 atrophy with pigmented edges in the macula disrupting the entire fovea in the right (K) and left (L) eye.
240 Corresponding transfoveal horizontal SD-OCT scans of the right (M) and left (N) eye of the proband document
241 chorioretinal atrophy, involving all retinal layers and subfoveal hyperplasia of the retinal pigment epithelium. SD-
242 OCT in the daughter also shows chorioretinal atrophy and subfoveal hyperreflective lesions corresponding to the
243 areas of subretinal fibrosis in the right eye (present between the asterisks) (O). The inserts in D, M, N, O provide a
244 cross-sectional plane. Retinal imaging quality is decreased in both the proband and his daughter due to nystagmus
245 and anterior segment findings.



246

247 **Figure 3: Clinical findings in individual III:1 with dual diagnosis of dominantly inherited chorioretinal**
248 **dystrophy variably associated with iris coloboma, congenital cataract and glaucoma and oculocutaneous**
249 **albinism.** Anterior segment photography documenting iris translucency, no iris coloboma and no cataract in the
250 right (A) and the left eye (B), respectively. Right (C) and left eye (D) wide-field fundus photography showing marked
251 diffuse hypopigmentation, without pigment clumping. Transfoveal horizontal SD-OCT scans of the right (E) and left
252 (F) eye documenting absence of foveal pit, loss of outer retinal layers and choroidal thinning. Static perimetry
253 revealed concentric visual field constriction with some preserved islands of perception in the right (G) and left
254 (H).

255

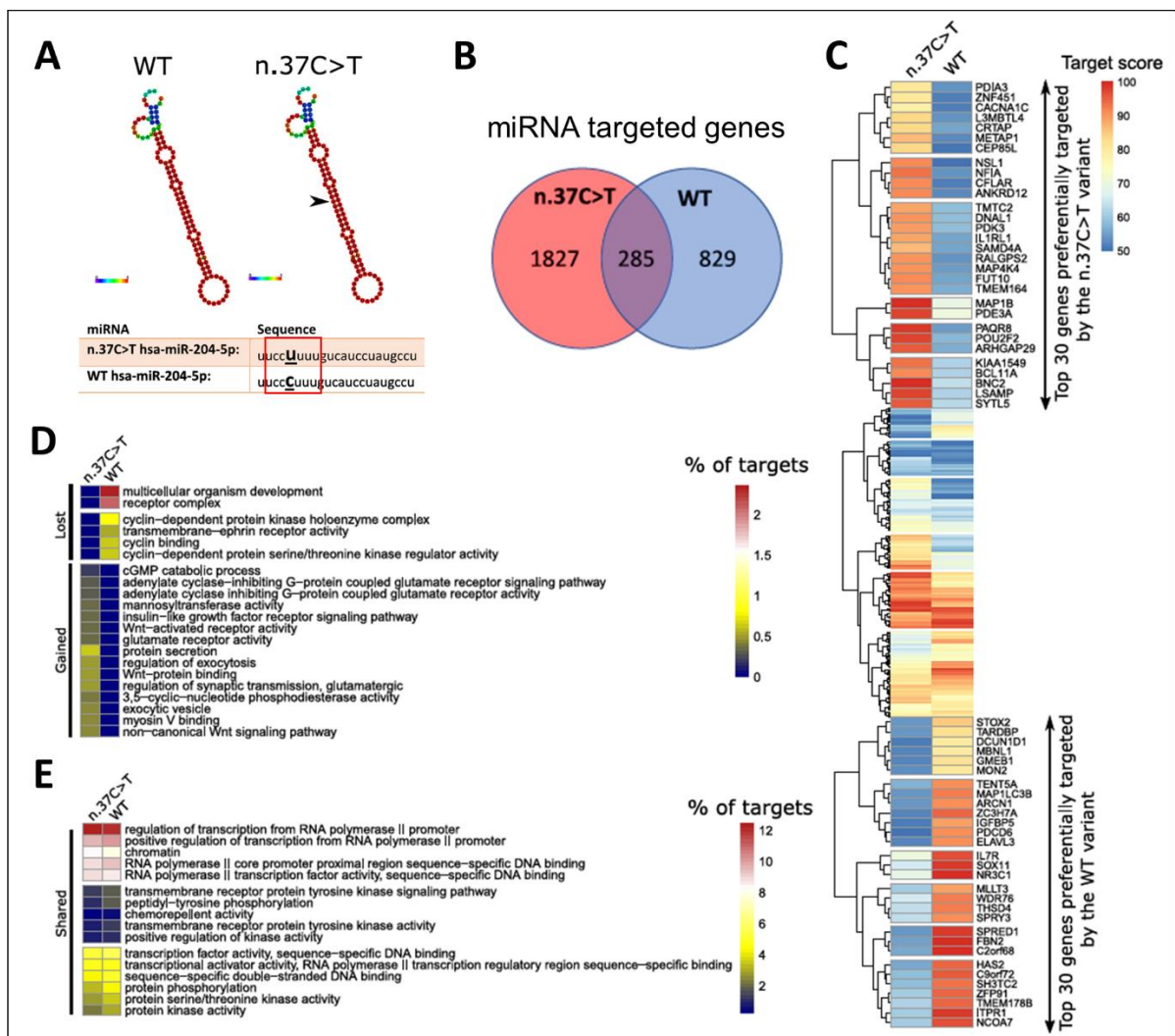
256 *In silico target prediction and functional annotation approach for the n.37C>T in MIR204*

257 Finally, we analysed the impact of the *MIR204* n.37C>T variant on the hairpin structure
258 and function using *in silico* target prediction and functional annotation approach. First, we
259 found no profound changes to the hairpin structure and composition introduced by the n.37C>T
260 (Fig. 4A), presumably having no or little impact on the preferential processing of the -3p or -
261 5p miRNA strands in the miRNA molecular machinery. The n.37C>T variant gives a rise to
262 the miRNA molecule (n.37C>T hsa-miR-204-5p) that possesses a change in its seed sequence
263 on the 4th position when compared to wild type (WT hsa-miR-204-5p) (Fig. 4A).

264 Since a change in a seed sequence may have a deep impact on miRNA target
265 recognition, potentially leading to a new gain-of-function mechanism of the mutated miRNA
266 molecule, we also aimed to analyse the effects of the n.37C>T on the predicted hsa-miR-204-
267 5p target genes. The miRNA molecule carrying the pathogenic variant may target 2112
268 mRNAs, compared to 1114 mRNAs of the WT, with 285 genes shared (Fig. 4B), indicating
269 that the n.37C>T variant not only introduces profound changes to preferential binding to
270 mRNA targets but also binds to novel mRNAs.

271 To reveal how much the point change affects binding to its targets, we analysed binding
272 scores for each shared mRNA target. The analysis revealed that the n.37C>T pathogenic variant
273 changes the miRNA binding preferences for the majority of shared target genes (Fig. 4C).
274 Given the striking alterations in the target preferences of the n.37C>T variant, we assessed *in*

275 *silico* its functional consequence on diverse molecular mechanisms. The functional annotation
 276 analysis suggests that the n.37C>T variant gains novel abilities to regulate crucial signalling
 277 pathways including canonical and non-canonical Wnt pathway, insulin-like growth factor
 278 pathway and G-protein coupled glutamate receptor pathway, while it loses the ability to directly
 279 regulate cell cycle via cell cycle-dependent protein kinases and cyclins (Fig. 4D). Additionally,
 280 the n.37C>T variant shares multiple functional annotation clusters with the WT variant,
 281 however, the number of target genes significantly differs (Fig. 4E).
 282



283
 284 **Figure 4: In silico analysis of the *MIR204* n.37C>T variant reveals profound changes to its target mRNAs**
 285 **and suggests a gain-of-function mechanism of *MIR204* variant.** Hairpin structure of WT and n.37C>T variant
 286 of the *MIR204*, as determined using the RNAfold tool. Black arrow shows the site of the single nucleotide change.
 287 Red square marks the seed sequence of *MIR204* (A). Number of predicted targets for both WT as well as n.37C>T
 288 variant, as determined using miRDB tool (B). Heatmap shows a comparison of the putative functional
 289 consequences of the n.37C>T and WT variant on target genes (C). Functional annotation of target genes of both
 290 *MIR204* variants, as determined using DAVID tool (D, E).

291 DISCUSSION

292 Reported pathogenic variants within miRNAs associated with Mendelian disorders are
293 rare. To date, four have been identified as a cause of human disease.^{15,16} Conte et al. implicated
294 a point variant in miRNA in inherited retinal dystrophy.¹ In this study, we confirm that the
295 n.37C>T variant in *MIR204* is disease-causing in the heterozygous state.

296 Clinical examination and available past medical notes of four affected members in the
297 second family identified worldwide showed that the only constant sign of *MIR204*-associated
298 disease is early-onset chorioretinal dystrophy which we were able to document in a school age
299 child. Interestingly, we observed central macular atrophy surrounded with retinal pigment
300 epithelium (RPE) resembling toxoplasmosis. Clinical notes indicated that similar lesions were
301 also found in the proband and his mother. An atrophic macular lesion with RPE clumping was
302 not detected in the daughter with the dual diagnosis of *MIR204*-associated chorioretinal
303 dystrophy and oculocutaneous albinism; it remains unclear how the intersection of these two
304 genetic defects influences retinal morphology. Nevertheless, in line with the presence of the
305 *MIR204* n.37C>T, her visual function was significantly worse than her mother in her 40s who
306 only had oculocutaneous albinism.

307 Coloboma was not a constant sign, although it was present in at least one eye of three
308 out of the four individuals carrying the n.37C>T in *MIR204*. The diagnosis of bilateral
309 congenital glaucoma, which was not described in the previously published family with *MIR204*
310 n.37C>T, led us to perform exome sequencing in the affected child. By excluding pathogenic
311 variants in genes associated with congenital glaucoma we propose congenital glaucoma as a
312 rare phenotypical sign of *MIR204*-associated disease, rather than a separate entity.

313 Changes in seed sequence, which is essential for the miRNA binding to the target
314 mRNA, may lead to binding disruption and/or alterations to premiRNA processing.^{16,17}
315 Notably, the expression of both premiRNA, as well as processed -3p/-5p forms of the *MIR204*
316 n.37C>T variant was not affected when compared to the wild type, suggesting that the mutation
317 does not alter premiRNA processing.¹ On the other hand, alterations in the seed sequence may
318 result in profound changes to the expression of the miRNA target genes and additionally lead
319 to binding to novel mRNAs representing the gain-of-function mechanism. The n.37C>T variant
320 likely leads to the gain-of-function mechanism by creating novel aberrant recognition sites in
321 genes not normally targeted by miR-204. This scenario is largely supported by the miRNA
322 target and functional annotation analyses performed in this study. Additionally, injection of the
323 n.37C>T *MIR204* variant into medaka fish embryo leads to severe ocular malformations
324 including retinal dystrophy.¹ Moreover, *MIR204* loss-of-function has been previously linked

325 to microphthalmia, abnormal lens development, eye coloboma, and defects in axon projections
326 of retinal ganglion cells in fish, highlighting the importance of the *MIR204* in eye development
327 and function.^{3,18,19} However, the precise molecular mechanism of the *MIR204*-associated
328 disease remains still unknown.

329 Another ocular condition running in the family was OCA2 presenting as
330 oculocutaneous form in the spouse and in one of the offspring who had a dual diagnosis.
331 Interestingly, she did not show atrophic lesions in the macula or RPE clumping. Two sons
332 shown to have OCA2 at molecular level presented with normal visual acuity, discrete fundus
333 hypopigmentation and foveal hypoplasia, which was only revealed by chance due to familial
334 investigation.

335 The *MIR204* belongs to the group of recently characterised retinal-specific miRNAs^{20,21}
336 regulating important processes in the retina including phototransduction cascade and
337 development of RPE, neural retina, ciliary body, and lens. Given the critical role of the *MIR204*
338 in the ocular development and function of the retina, it is not surprising that pathogenic variants
339 in the *MIR204* gene lead to severe eye defects. As the current screening methodology leaves
340 approximately 40% of patients with inherited retinal disorders undiagnosed, identification of
341 the molecular cause is one of the current challenges. In general, the pathogenic role of miRNAs
342 may have been significantly underestimated and could explain part of the missing heritability.²²

343

344

345 REFERENCES

- 346 1. Conte, I.; Hadfield, K.D.; Barbato, S.; Carrella, S.; Pizzo, M.; Bhat, R.S.; Carissimo, A.;
347 Karali, M.; Porter, L.F.; Urquhart, J., et al. MiR-204 is responsible for inherited retinal
348 dystrophy associated with ocular coloboma. *Proc Natl Acad Sci U S A* **2015**, *112*, E3236-
349 3245, doi:10.1073/pnas.1401464112.
- 350 2. Bartel, D.P. MicroRNAs: genomics, biogenesis, mechanism, and function. *Cell* **2004**, *116*,
351 281-297, doi:10.1016/s0092-8674(04)00045-5.
- 352 3. Conte, I.; Carrella, S.; Avellino, R.; Karali, M.; Marco-Ferreres, R.; Bovolenta, P.; Banfi, S.
353 miR-204 is required for lens and retinal development via Meis2 targeting. *Proc Natl Acad Sci*
354 *U S A* **2010**, *107*, 15491-15496, doi:10.1073/pnas.0914785107.
- 355 4. Thomas, M.G.; Kumar, A.; Mohammad, S.; Proudlock, F.A.; Engle, E.C.; Andrews, C.;
356 Chan, W.M.; Thomas, S.; Gottlob, I. Structural grading of foveal hypoplasia using spectral-
357 domain optical coherence tomography a predictor of visual acuity? *Ophthalmology* **2011**, *118*,
358 1653-1660, doi:10.1016/j.ophtha.2011.01.028.
- 359 5. den Dunnen, J.T.; Dalgleish, R.; Maglott, D.R.; Hart, R.K.; Greenblatt, M.S.; McGowan-
360 Jordan, J.; Roux, A.F.; Smith, T.; Antonarakis, S.E.; Taschner, P.E. HGVS Recommendations
361 for the Description of Sequence Variants: 2016 Update. *Hum Mutat* **2016**, *37*, 564-569,
362 doi:10.1002/humu.22981.
- 363 6. Richards, S.; Aziz, N.; Bale, S.; Bick, D.; Das, S.; Gastier-Foster, J.; Grody, W.W.; Hegde,
364 M.; Lyon, E.; Spector, E., et al. Standards and guidelines for the interpretation of sequence
365 variants: a joint consensus recommendation of the American College of Medical Genetics and

- 366 Genomics and the Association for Molecular Pathology. *Genet Med* **2015**, *17*, 405-424,
367 doi:10.1038/gim.2015.30.
- 368 7. McKenna, A.; Hanna, M.; Banks, E.; Sivachenko, A.; Cibulskis, K.; Kernysky, A.;
369 Garimella, K.; Altshuler, D.; Gabriel, S.; Daly, M., et al. The Genome Analysis Toolkit: a
370 MapReduce framework for analyzing next-generation DNA sequencing data. *Genome Res*
371 **2010**, *20*, 1297-1303, doi:10.1101/gr.107524.110.
- 372 8. Karczewski, K.J.; Francioli, L.C.; Tiao, G.; Cummings, B.B.; Alfoldi, J.; Wang, Q.; Collins,
373 R.L.; Laricchia, K.M.; Ganna, A.; Birnbaum, D.P., et al. The mutational constraint spectrum
374 quantified from variation in 141,456 humans. *Nature* **2020**, *581*, 434-443,
375 doi:10.1038/s41586-020-2308-7.
- 376 9. Robinson, J.T.; Thorvaldsdottir, H.; Winckler, W.; Guttman, M.; Lander, E.S.; Getz, G.;
377 Mesirov, J.P. Integrative genomics viewer. *Nat Biotechnol* **2011**, *29*, 24-26,
378 doi:10.1038/nbt.1754.
- 379 10. Chen, Y.; Wang, X. miRDB: an online database for prediction of functional microRNA
380 targets. *Nucleic Acids Res* **2020**, *48*, D127-D131, doi:10.1093/nar/gkz757.
- 381 11. Liu, W.; Wang, X. Prediction of functional microRNA targets by integrative modeling of
382 microRNA binding and target expression data. *Genome Biol* **2019**, *20*, 18,
383 doi:10.1186/s13059-019-1629-z.
- 384 12. Sherman, B.T.; Hao, M.; Qiu, J.; Jiao, X.; Baseler, M.W.; Lane, H.C.; Imamichi, T.; Chang,
385 W. DAVID: a web server for functional enrichment analysis and functional annotation of
386 gene lists (2021 update). *Nucleic Acids Res* **2022**, *50*, W216-221, doi:10.1093/nar/gkac194.
- 387 13. Martin, A.R.; Williams, E.; Foulger, R.E.; Leigh, S.; Daugherty, L.C.; Niblock, O.; Leong,
388 I.U.S.; Smith, K.R.; Gerasimenko, O.; Haraldsdottir, E., et al. PanelApp crowdsources expert
389 knowledge to establish consensus diagnostic gene panels. *Nat Genet* **2019**, *51*, 1560-1565,
390 doi:10.1038/s41588-019-0528-2.
- 391 14. Loftus, S.K.; Lundh, L.; Watkins-Chow, D.E.; Baxter, L.L.; Pairo-Castineira, E.; Nisc
392 Comparative Sequencing, P.; Jackson, I.J.; Oetting, W.S.; Pavan, W.J.; Adams, D.R. A
393 custom capture sequence approach for oculocutaneous albinism identifies structural variant
394 alleles at the OCA2 locus. *Hum Mutat* **2021**, *42*, 1239-1253, doi:10.1002/humu.24257.
- 395 15. Kawahara, Y. Human diseases caused by germline and somatic abnormalities in microRNA
396 and microRNA-related genes. *Congenit Anom (Kyoto)* **2014**, *54*, 12-21,
397 doi:10.1111/cga.12043.
- 398 16. Grigelioniene, G.; Suzuki, H.I.; Taylan, F.; Mirzamohammadi, F.; Borochowitz, Z.U.;
399 Ayturk, U.M.; Tzur, S.; Horemuzova, E.; Lindstrand, A.; Weis, M.A., et al. Gain-of-function
400 mutation of microRNA-140 in human skeletal dysplasia. *Nat Med* **2019**, *25*, 583-590,
401 doi:10.1038/s41591-019-0353-2.
- 402 17. Bhattacharya, A.; Cui, Y. Systematic Prediction of the Impacts of Mutations in MicroRNA
403 Seed Sequences. *J Integr Bioinform* **2017**, *14*, doi:10.1515/jib-2017-0001.
- 404 18. Avellino, R.; Carrella, S.; Pirozzi, M.; Risolino, M.; Salierno, F.G.; Franco, P.; Stoppelli, P.;
405 Verde, P.; Banfi, S.; Conte, I. miR-204 targeting of Ankrd13A controls both mesenchymal
406 neural crest and lens cell migration. *PLoS One* **2013**, *8*, e61099,
407 doi:10.1371/journal.pone.0061099.
- 408 19. Conte, I.; Merella, S.; Garcia-Manteiga, J.M.; Migliore, C.; Lazarevic, D.; Carrella, S.;
409 Marco-Ferreres, R.; Avellino, R.; Davidson, N.P.; Emmett, W., et al. The combination of
410 transcriptomics and informatics identifies pathways targeted by miR-204 during neurogenesis
411 and axon guidance. *Nucleic Acids Res* **2014**, *42*, 7793-7806, doi:10.1093/nar/gku498.
- 412 20. Fishman, E.S.; Han, J.S.; La Torre, A. Oscillatory Behaviors of microRNA Networks:
413 Emerging Roles in Retinal Development. *Front Cell Dev Biol* **2022**, *10*, 831750,
414 doi:10.3389/fcell.2022.831750.
- 415 21. Krol, J.; Busskamp, V.; Markiewicz, I.; Stadler, M.B.; Ribí, S.; Richter, J.; Duebel, J.; Bicker,
416 S.; Fehling, H.J.; Schubeler, D., et al. Characterizing light-regulated retinal microRNAs
417 reveals rapid turnover as a common property of neuronal microRNAs. *Cell* **2010**, *141*, 618-
418 631, doi:10.1016/j.cell.2010.03.039.
- 419 22. Xu, S. microRNAs and inherited retinal dystrophies. *Proc Natl Acad Sci U S A* **2015**, *112*,
420 8805-8806, doi:10.1073/pnas.1511019112.

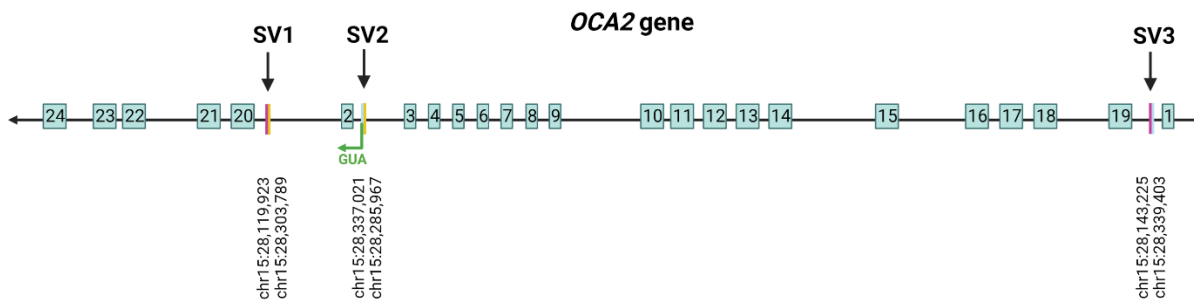
421 **Supplementary Table 1. Sequence of primers used for PCR and Sanger sequencing**

Primer	Forward (5'-3')	Reverse (5'-3')	Amplicon size (bp)
<i>MIR204</i>	CCCAATGCATTTGATGATGGT	TTGCAAGATGGTGGAGAAACAA	857
<i>OCA2 ex12</i>	CACTAATGAAAGGCTGCCTCTGT	CATGCACCTGAGAATGGAACC	299
<i>OCA2 SV1</i>	TTAACATGGGCCCTTAATGAGTT	TTGGGGGCTGAAATAGTGACA	210
<i>OCA2 SV2</i>	CGGCGAAACCTCGTCTCTACT	TGCCCCAAAATTGGATAACCT	212
<i>OCA2 SV3</i>	GCCTCAACAGTTCCCCAAAG	CCTGCCCTAGGCAAGTCAAG	216

422

423

424

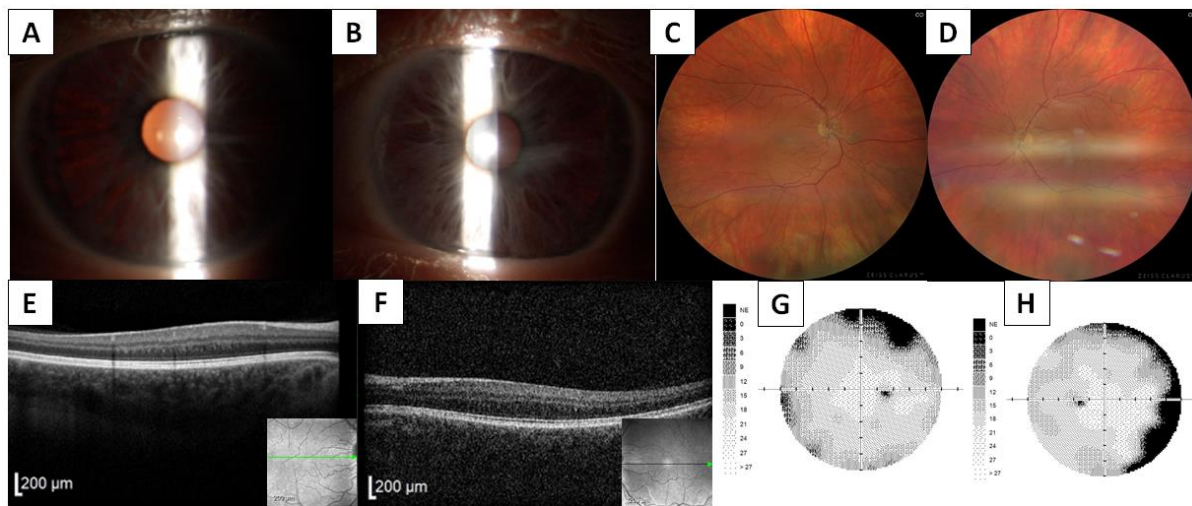


425

426

427 **Supplementary Figure 1. Reshuffled sequence of *OCA2* gene with primer positions indicated.**

428



429

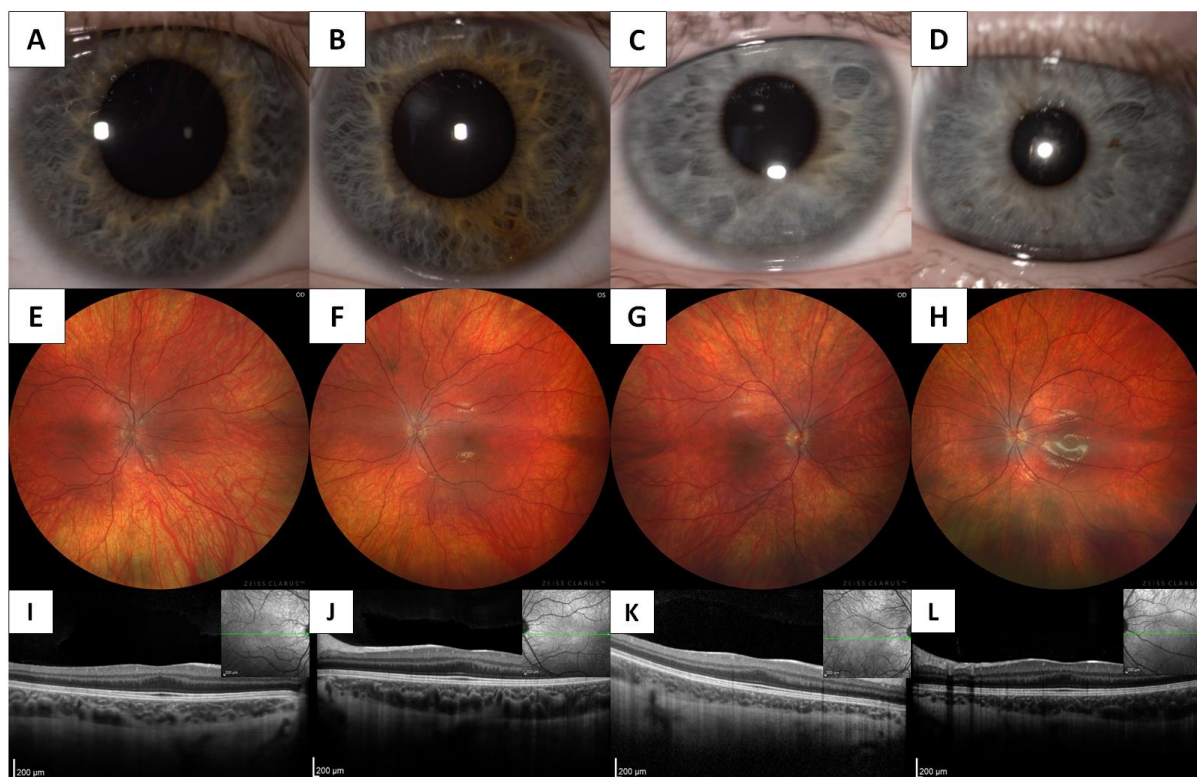
430 **Supplementary Figure 2: Clinical findings in individual II:3 with oculocutaneous form of albinism.** Anterior
431 segment photographs document iris transluency in the right (A) and in the left eye (B). Markedly hypopigmented
432 fundus in the right (C) and in the left eye (D), absence of a foveal pit in SD-OCT scans of the right (E) and left eye
433 (F) (horizontal scan line is provided in the inserts). The visual field in the right (G) and left (H) shows a mild non-
434 specific decrease of sensitivity.

435

436

437

438



439

440 **Supplementary Figure 3: Clinical findings in two family members with an ocular form of albinism.** Individuals
441 III:2 and III:3, respectively, have normal anterior segment appearance of the right (A, C) and left (B, D) eyes. Wide-
442 field fundus photography revealed discrete fundus hypopigmentation in the right (E, G) and left (F, H) eyes. Foveal
443 hypoplasia (grade 1 - shallow foveal pit) was detected by SD-OCT in the right (I, K) and left (J, L) eyes (a horizontal
444 scan line is provided in the inserts).