TITLE PAGE

A novel extra-venous pathway drains CSF from the subarachnoid space to thoracic duct: the CSF canalicular system. Implications for space-flight associated neuro-ocular syndrome.

AUTHOR

Joel E. Pessa MD FACS

INSTITUTION WHERE WORK WAS COMPLETED

University of Texas Medical School

Willed Body Program

Contact Information

Joel E. Pessa MD FACS

Private Practice Plastic Surgery

18 Florence Avenue, Arlington, Massachusetts. 02476

jepessa@gmail.com

ABSTRACT

A novel extravenous pathway is described that drains cerebrospinal fluid from the subarachnoid space to the thoracic duct. Cadaver dissection identifies the cerebrospinal fluid canalicular system as a series of channels that travel within the dural superior

sagittal sinus. The anatomic pathway is described in detail. The possible relationship to spaceflight associated neuro ocular syndrome is discussed.

TITLE

A novel extra-venous pathway drains CSF from the subarachnoid space to thoracic duct: the CSF canalicular system. Implications for space-flight associated neuro-ocular syndrome.

AUTHOR

Joel E. Pessa MD FACS

DISCLOSURE

The author does not have any financial interest in the outcome of this research, and does not report any conflict of interest. This research was self-funded.

INTRODUCTION

This paper describes the *cerebrospinal fluid (CSF) canalicular system* in the dural sagittal sinus and falx cerebri. It builds on the author's previous work and completes a novel extra-venous pathway for CSF drainage from the subarachnoid space to the thoracic duct.

CSF drainage by invaginations of the arachnoid meninges into superior sagittal sinus veins has been described (1-4). CSF is thought to flow from the subarachnoid space through protrusions of the arachnoid meninges into the venous superior sagittal sinus

(1-3). CSF is then filtered and drained by the vascular circulation. Macroscopic protrusions of arachnoid membrane are termed arachnoid granulations (1). These were first described by Antonio Paccioli (5). The anatomy and microanatomy of the superior sagittal sinus veins has been investigated (6-9).

The author's past work described the CSF canalicular system in the neck (10-13). CSF flow from the intracranial temporal fossa to the thoracic duct was documented by infra-red imaging (12). This *cervical* CSF canalicular system travels along the posterior internal jugular vein (Figures 1 and 2), and was initially identified by William Cruickshank and Paul Mascagni in 1786 and 1787 respectively (14, 15). It is interesting that Cruickshank, Mascagni, and Paccioli mischaracterized CSF vessels as being part of the lymphatic system, an error that was repeated throughout history.

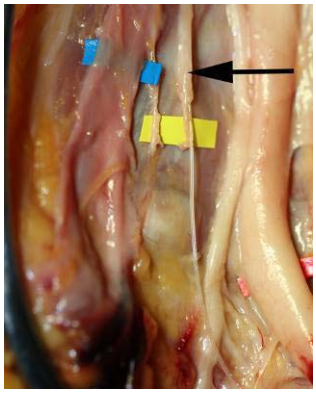

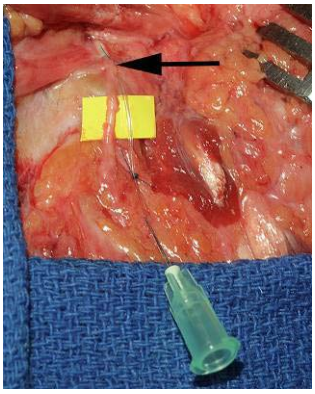

Figure 1. Left. The CSF canalicular system (on yellow tape) in the neck of a 60's year-old female specimen has been cannulated (arrow) for retrograde injection. This plexus of CSF channels travels in the adventitia of the internal jugular vein (above blue tape). The carotid artery and vagus nerve are seen.

Figure 2. Right. The *cervical* CSF canalicular system (on yellow tape) has been cannulated (arrow) for retrograde injection near the cranial base. The CSF canalicular system exits the temporal fossa through the CSF foramen.

Here we identify the CSF canalicular system traveling in the dural superior sagittal sinus. This completes an *extra-venous anatomic pathway* that enables CSF to drain from the subarachnoid space to the thoracic duct. Because this appears to be a gravity-dependent system, its possible relationship to neurological disorders such as spaceflight-associated neuro-ocular syndrome (SANS) is discussed.

MATERIALS AND METHODS

All cadaver work was performed at The University of Texas Southwestern Medical School Willed Body Program. The cadaver specimens were donated and available for research prior to the initiation of this study. The CSF canalicular system was dissected in 5 fresh human cadaver specimens. There were 4 male and 1 female cadavers with ages from 40-92 years (mean 86.5). All dissections were performed within 72 hours of death under institutional guidelines for human anatomic work. Anatomic work is excluded from IRB review. No identifying information was obtained except for decade of age and gender.

A modified cadaver preparation simplified dissection. We cannulated the carotid arteries with IV tubing (Baxter Pharmaceutical, Deerfield, Illinois). Bilateral carotid arteries were infused with 250 ccs of normal saline. No venous washout was done to facilitate identification of the venous superior sagittal sinus (Figure 3). Circumferential craniotomies were performed from just above the occipital protuberance posteriorly to the frontal sinuses anteriorly. Midline tethering by extra-dural lymphatic communications to subcutaneous tissue was approached by subperiosteal (epidural) dissection (11).
The venous superior sagittal sinus was irrigated to identify the CSF canalicular system. IR imaging was performed in one specimen to document continuity from the CSF canalicular system to its exit at the cranial base.

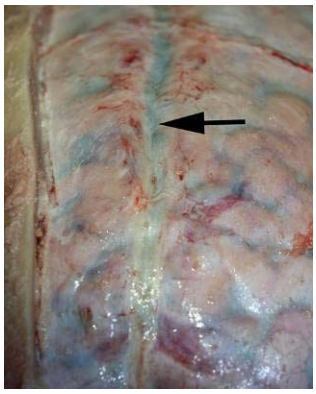

Figure 3. Cadaver preparation was modified to avoid venous washout. This enables the venous superior sagittal sinus (arrow) to be easily identified.

The CSF canalicular system was cannulated using 0.25mm silastic tubing (World Precision Instruments, Sarasota, Florida) and injected with 0.1ccs of indocyanine green (Sigma Aldrich, St. Louis, USA). Imaging was performed with the Leica neurosurgical operating microscope (Leica Microsystems, Wetzlar, Germany). A post-injection video was obtained.

RESULTS

The CSF canalicular system was identified in all dissections. Once the venous sagittal sinus is opened and blood evacuated, the CSF canalicular system is noted to lie posteriorly within the dural sagittal sinus (Figure 4). This CSF drainage system is separate and distinct from the venous network (Figure 4). It consists of a series of translucent channels that travel along the entire floor of the dural sagittal sinus (Figure 4). Internal diameter in the mid-cranium was 0.25mm.

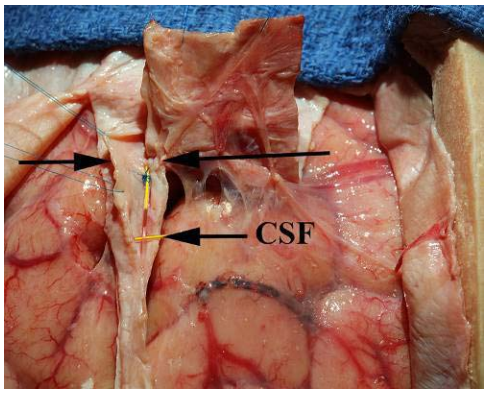

Figure 4. The venous superior sagittal sinus (arrows) has been opened and blood evacuated in this 90's year-old female specimen. The CSF canalicular system (CSF, arrow) lies deep within the dural superior sagittal sinus. It travels along the floor of the sinus, and communicates directly to the subarachnoid space via pores.

The CSF canalicular system opens from the subarachnoid space by a series of pores (Figure 5). These pores can be cannulated and enter this CSF drainage system.

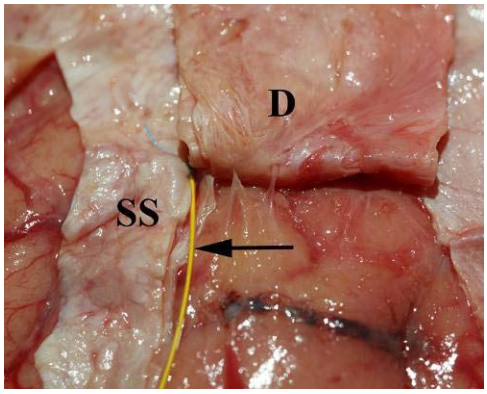

Figure 5. Pores in the superior sagittal sinus (SS) can be cannulated with 0.25mm silastic tubing (yellow tubing) from the subarachnoid space. Dura (D) has been elevated. These pores are distinct from arachnoid granulations.

The CSF canalicular system is distinct from arachnoid granulations that drain into the venous superior sagittal sinus. Careful dissection identifies the communications of arachnoid granulations into the venous system (Figure 6). The communication of

arachnoid granulations *into* the venous system is superficial to the CSF canalicular system (Figure 6).

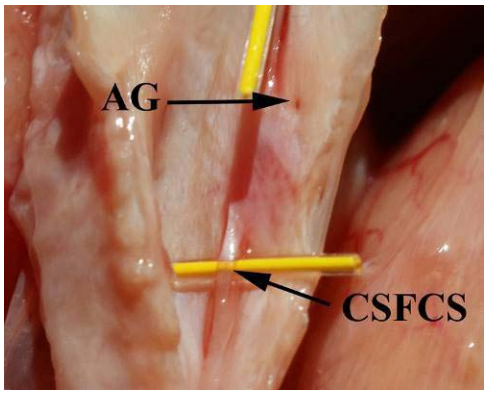

Figure 6. The venous superior sagittal sinus has been opened and blood was evacuated. The CSF canalicular system (CSFCS) lies deep within the dural sagittal sinus. Arachnoid granulations enter the *venous* superior sagittal sinus (AG, arrow) through pores directly into the veins. The CSF canalicular system lies deep to the venous system.

Flow within the CSF canalicular system was documented by IR imaging. Indocyanine green was injected into the CSF canalicular system. Imaging under visible light shows the posterior falx cerebri transected (Figure 7a). IR imaging confirms that dye flows from the superior dural sagittal sinus to the temporal fossa(Figure 7b).

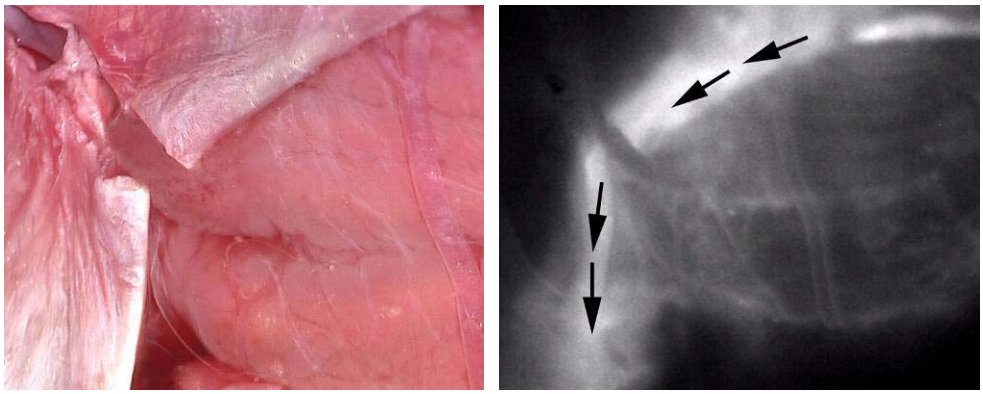

Figure 7a. Left. The CSF canalicular system was cannulated in the falx cerebri of a 50’s year-old male specimen and injected with indocyanine dye. The falx has been transected post-injection.

Figure 7b. Right. Infra-red imaging shows dye travels in the CSF canalicular system from the falx cerebri to the cranial base (arrows) in the temporal fossa. A video loop confirmed this anatomical path.

DISCUSSION

The present paper builds on the author's previous work and completes a novel extra-venous anatomic pathway for the drainage of CSF from subarachnoid space to thoracic duct (10-13). The main limitation of this study is that post-mortem research is unable to address the relative contribution of CSF drainage in the human brain by this system compared to CSF drainage via arachnoid granulations and the superior sagittal sinus veins (1-4). The answer to that question will require in-vivo animal studies.

The CSF canalicular system in the dural superior sagittal sinus was briefly introduced in 2017 (10). It is easily overlooked because it lies deep to the vein, and is buried within the connective tissue of the dura (Figure 4). Its presence was anticipated by the identification of an extra-venous CSF system in the neck (10-15). A proximal circuit had to exist, and it was only a matter of performing retrograde dissection (from inferior falx to sagittal sinus) to identify these CSF vessels within the sagittal sinus. In fact, it is easiest to duplicate these findings *if one begins distally in the falx cerebri*. The CSF canalicular system can be identified and traced proximally without confusion from the overlying venous system.

A basic concept of the CSF circulatory system is that CSF channels travel in close proximity to the vascular system. This is true in the sagittal sinus (adjacent to superior sagittal sinus vein); in the neck (within adventitia of internal jugular vein); and even with

the intra-cranial paravascular glymphatic vessels described by Iliff and others (16-18). The exception to this rule occurs in the peripheral nervous system where epineurial CSF channels described by Pessa are independent from both arteries and veins (12).

However, the CSF canalicular system is distinct and independent from the venous system. Dissection can show that arachnoid granulations enter the sagittal sinus veins superficial to the CSF canalicular system (Figure 6). The complete circuit drains from subarachnoid space to the thoracic duct (10-13). Both Cruickshank and Mascagni observed the cervical CSF canalicular system (vessels traveling along the posterior internal jugular vein) in 1786 and 1787 respectively (14, 15). Although both mis-characterized these vessels as lymphatics, their early work is confirmatory evidence of this system. Preliminary molecular characterization of the CSF canalicular system in 2 specimens is consistent with that reported for epineurial CSF channels in human peripheral nerves (13). Failure to express vascular biomarkers (CD 34 and CD105) further confirms this system is separate from the venous superior sagittal sinus.

The present work suggests several additional concepts as follows.

1. Previously, the terms “venous superior sagittal sinus” and “superior sagittal sinus” could be used interchangeably. It is now important to distinguish the *venous* superior sagittal sinus from the *CSF canalicular system* that travels in the posterior (deep) dural superior sagittal sinus (1-4). Two independent circulatory systems travel in the “superior sagittal sinus”.

2. The previous accepted description of the carotid sheath in anatomic literature stated that it contains 3 or 4 structures: carotid artery; internal jugular vein; sympathetic plexus;

and vagus nerve (1, 19). This description should be amended to include the CSF canalicular system that travels within the adventitia of the internal jugular vein (Figure 1).

3. Sappey's Rule, which states that any vessel draining into a lymphatic vessel characterizes that vessel as a lymphatic, should be amended (20). The human CSF circulatory system ultimately drains into the thoracic duct (10-15). However, CSF vessels are distinct from lymphatics. CSF vessels lack valves; do not co-locate lymphatic endothelial cell (LEC) or vascular biomarkers; and express the type-3 neurofilament protein vimentin typical of mesenchymal cell lineage. Sappey's Rule was useful prior to the advent of molecular biology. Amended, it could state that "vessels which communicate with lymphatics *may* be lymphatic in nature".

Disruption of CSF drainage is now linked to neurocognitive disease (21). A specific disorder is noted during prolonged space-flight and low gravity environments. Spaceflight-associated neuro-ocular syndrome (SANS) is associated with a constellation of findings that affect vision (22). Prolonged exposure to low gravity leads to optic disc edema, flattening of the ocular globe, and refractive errors (hyperopia). One theory suggests that SANS is related to changes in fluid shifts in the optic nerve and diminished CSF flow (23). Head-down tilt test has been described as an analogue to the condition of microgravity (24).

The CSF canalicular system suggests a possible explanation for SANS. The author described CSF channels in the human optic nerve, and animal experiments confirm CSF flow from lateral ventricles along the optic nerve (13, 25). The CSF canalicular system is gravity-dependent: microgravity leads to decreased outflow, and could account for disc

edema observed in this condition. The observation that ventricular size and basal ganglia volume (measured by MRI) increases during prolonged spaceflight is in agreement with dysregulation of the CSF canalicular system drainage by microgravity (26).

The relationship of the CSF canalicular system to spaceflight-associated neuro-ocular syndrome suggests a possible treatment. CSF shunting is invasive and perhaps not warranted. However, the application of centrifugal force (e.g. daily centrifuge training) would promote drainage from the superior sagittal sinus to the thoracic duct. This work provides another avenue for the investigation and possible treatment of SANS.

The CSF canalicular system is an overview of an extra-venous CSF drainage pathway from the subarachnoid space to the thoracic duct. Each part of this anatomy requires additional work. It could be anticipated that other parts of this system may exist, for example, in the inferior sagittal sinus. An animal model will need to be identified that enables function to be studied. Specifically, the contribution to CSF drainage by arachnoid granulations/venous sagittal sinus compared to CSF drainage by the CSF canalicular system needs to be evaluated. It is interesting, however, that the number and distribution of arachnoid granulations are highly variable (4). Neurons are exquisitely sensitive to changes in pressure, and one might hypothesize that a circulation as important as CSF drainage would exist as a privileged (i.e. independent of other circulations) and well-defined structure. Interested researchers are encouraged to duplicate these findings using the anatomical techniques described.

CONCLUSION

The CSF canalicular system is a novel extra-venous pathway for CSF drainage from the subarachnoid space to the thoracic duct. Disrupted CSF drainage in this system could be related to certain neurological conditions such as spaceflight-associated neuro-ocular syndrome.

REFERENCES

1. Clemente CD. Anatomy. A Regional Atlas of the Human Body. Baltimore-Munich: Urban and Schwarzenberg; 1987. Figure 633.

2. Huff T, Tadi P, Weisbrod LJ, Varacallo M. Neuroanatomy, Cerebrospinal Fluid. 2022 Sep 1. In: StatPearls [Internet]. Treasure Island (FL): StatPearls Publishing; 2022 Jan–. PMID: 29262203.

3. Shao Y, Sun JL, Yang Y, Cui QK, Zhang QL. Endoscopic and microscopic anatomy of the superior sagittal sinus and torcular herophili. J Clin Neurosci. 2009 Mar;16(3):421-4. doi: 10.1016/j.jocn.2008.02.024. Epub 2009 Jan 13. PMID: 19144524.

4. Radoš M, Živko M, Periša A, Orešković D, Klarica M. No Arachnoid Granulations-No Problems: Number, Size, and Distribution of Arachnoid Granulations from Birth to 80 Years of Age. Front Aging Neurosci. 2021 Jul 1;13:698865. doi: 10.3389/fnagi.2021.698865. PMID: 34276348; PMCID: PMC8280770.

5. Pacchionus A. Epistolaris de glandulis conglobatis durae meningis humani (Epistolary of the conglobatic glands of the human dural meninges). Rome: Franciso Buagni; 1705. Page 32.

6. Patchana T, Zampella B, Berry JA, Lawandy S, Sweiss RB. Superior Sagittal Sinus: A Review of the History, Surgical Considerations, and Pathology. Cureus. 2019 May 3;11(5):e4597. doi: 10.7759/cureus.4597. PMID: 31309022; PMCID: PMC6609282.

7. Letchuman V, Donohoe C. Neuroanatomy, Superior Sagittal Sinus. 2022 Jan 26. In: StatPearls [Internet]. Treasure Island (FL): StatPearls Publishing; 2022 Jan–. PMID: 31536222.

8. Tubbs RS, Loukas M, Louis RG Jr, Shoja MM, Acakpo-Satchivi L, Blount JP, Salter EG, Oakes WJ, Wellons JC 3rd. Anatomy of the falcine venous plexus. J Neurosurg. 2007 Jul;107(1):155-7. doi: 10.3171/JNS-07/07/0155. PMID: 17639885.

9. Visanji NP, Lang AE, Munoz DG. Lymphatic vasculature in human dural superior sagittal sinus: Implications for neurodegenerative proteinopathies. Neurosci Lett. 2018 Feb 5;665:18-21. doi: 10.1016/j.neulet.2017.11.001. Epub 2017 Nov 11. PMID: 29133178.

10. Pessa JE. Evidence suggests a novel cerebrospinal circulatory system exists in human nerves. MedRxiv doi.org/10.1101/2020.06.26.20141267.

11. Pessa JE, Kenkel JM, Heldermon CD. Periorbital and Temporal Anatomy, "Targeted Fat Grafting," and How a Novel Circulatory System in Human Peripheral Nerves and Brain May Help Avoid Nerve Injury and Blindness During Routine Facial Augmentation. Aesthet Surg J. 2017 Sep 1;37(8):969-973. doi: 10.1093/asj/sjx089. PMID: 28595323; PMCID: PMC5846697.

12. Pessa JE, Smith D, Sieber DA, Kenkel JM, Arbique G, Nahai F, Heldermon CD, Scott EW. The Value of Integrating Fluorescent Imaging and Immunohistochemistry for Future Anatomical Studies in Aesthetic Surgery: Lessons from the Cerebrospinal Fluid Circulatory System of Human Nerves and Brain. Aesthet Surg J. 2021 Sep 14;41(10):1197-1206. doi: 10.1093/asj/sjaa247. PMID: 32827254; PMCID: PMC8438645.

13. Pessa JE. Ventricular Infusion and Nanoprobes Identify Cerebrospinal Fluid and Glymphatic Circulation in Human Nerves. Plast Reconstr Surg Glob Open. 2022 Feb 17;10(2):e4126. doi: 10.1097/GOX.0000000000004126. PMID: 35198353; PMCID: PMC8856590.

14. Cruickshank WC. The anatomy of the adsorbing vessels of the human body. London, England: G. Nicoli; 1786.

15. Mascagni P. Vasorum Lymphaticorum Corporis Human. Siena, Italy: Pazzini Carli; 1787. Tabula XXVII.

16. Iliff JJ, Nedergaard M. Is there a cerebral lymphatic system? Stroke. 2013 Jun;44(6 Suppl 1):S93-5. doi: 10.1161/STROKEAHA.112.678698. PMID: 23709744; PMCID: PMC3699410.

17. Bohr T, Hjorth PG, Holst SC, Hrabětová S, Kiviniemi V, Lilius T, Lundgaard I, Mardal KA, Martens EA, Mori Y, Nägerl UV, Nicholson C, Tannenbaum A, Thomas JH, Tithof J, Benveniste H, Iliff JJ, Kelley DH, Nedergaard M. The glymphatic system: Current understanding and modeling. iScience. 2022 Aug 20;25(9):104987. doi: 10.1016/j.isci.2022.104987. PMID: 36093063; PMCID: PMC9460186.

18. Sheng J, Li Q, Liu T, Wang X. Cerebrospinal fluid dynamics along the optic nerve. Front Neurol. 2022 Aug 15;13:931523. doi: 10.3389/fneur.2022.931523. PMID: 36046631; PMCID: PMC9420993.

19. Garner DH, Kortz MW, Baker S. Anatomy, Head and Neck, Carotid Sheath. 2022 Apr 8. In: StatPearls [Internet]. Treasure Island (FL): StatPearls Publishing; 2022 Jan–. PMID: 30137861.

20. Sappey MPC. Anatomie, Physiologie, Pathologie des vaisseaux lympatiques consideres chez l'homme et les vertebre. Paris: A. Delahaye and E. Lecrosnier; 1874.

21. Sheng J, Li Q, Liu T, Wang X. Cerebrospinal fluid dynamics along the optic nerve. Front Neurol. 2022 Aug 15;13:931523. doi: 10.3389/fneur.2022.931523. PMID: 36046631; PMCID: PMC9420993.

22. Lee, A.G., Mader, T.H., Gibson, C.R. et al. Spaceflight associated neuro-ocular syndrome (SANS) and the neuro-ophthalmologic effects of microgravity: a review and an update. npj Microgravity **6**, 7 (2020). https://doi.org/10.1038/s41526-020-0097-9.

23. Yang JW, Song QY, Zhang MX, Ai JL, Wang F, Kan GH, Wu B, Zhu SQ. Spaceflight-associated neuro-ocular syndrome: a review of potential pathogenesis and intervention. Int J Ophthalmol. 2022 Feb 18;15(2):336-341. doi: 10.18240/ijo.2022.02.21. PMID: 35186696; PMCID: PMC8818462.

24. Ong J, Lee AG, Moss HE. Head-Down Tilt Bed Rest Studies as a Terrestrial Analog for Spaceflight Associated Neuro-Ocular Syndrome. Front Neurol. 2021 Mar 26;12:648958. doi: 10.3389/fneur.2021.648958. PMID: 33841315; PMCID: PMC8032981.

25. Pessa JE. In Nahai: The Art of Aesthetic Surgery. Nahai F, Nahai FR, Kenkel JM, Stevens WG, Adams WP Jr., Hunter JG. New York: Thieme; 2020.

26. Barisano G, Sepehrband F, Collins HR, Jillings S, Jeurissen B, Taylor JA, Schoenmaekers C, De Laet C, Rukavishnikov I, Nosikova I, Litvinova L, Rumshiskaya A, Annen J, Sijbers J, Laureys S, Van Ombergen A, Petrovichev V, Sinitsyn V, Pechenkova E, Grishin A, Zu Eulenburg P, Law M, Sunaert S, Parizel PM, Tomilovskaya E, Roberts DR, Wuyts FL. The effect of prolonged spaceflight on cerebrospinal fluid and perivascular spaces of astronauts and cosmonauts. Proc Natl Acad Sci U S A. 2022 Apr 26;119(17):e2120439119. doi: 10.1073/pnas.2120439119. Epub 2022 Apr 11. PMID: 35412862; PMCID: PMC9169932.

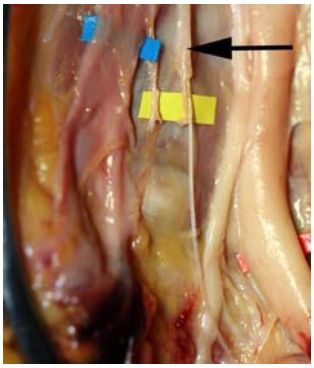

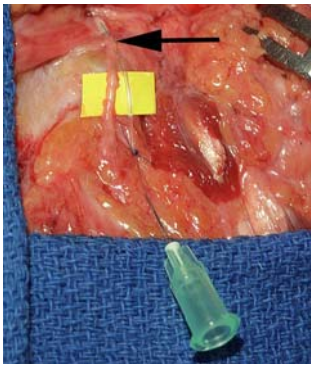

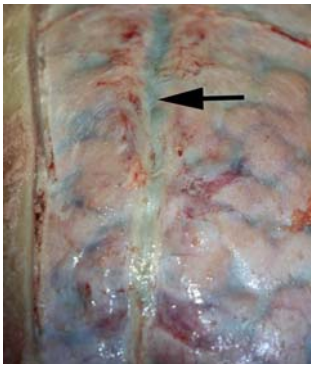

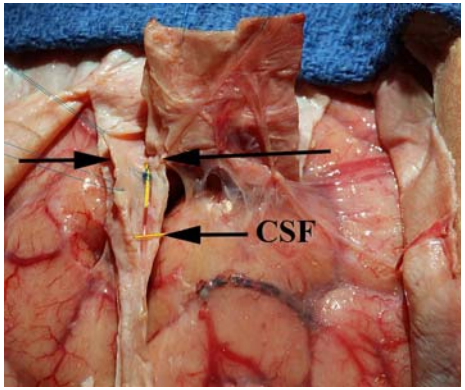
CSF

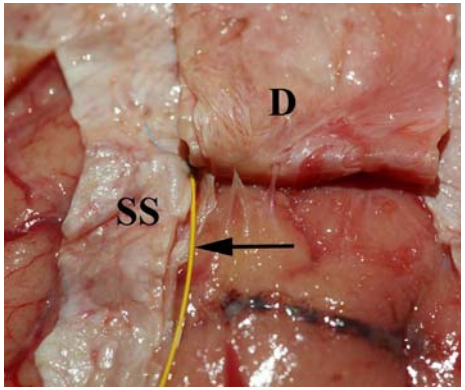
SS
D

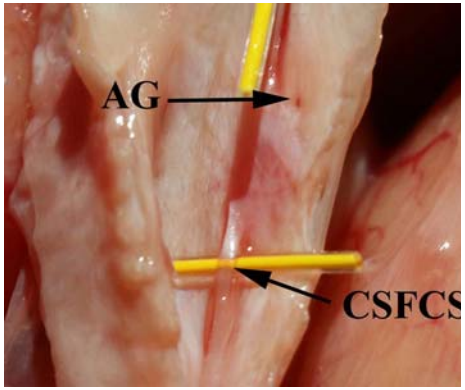
AG
CSFCS

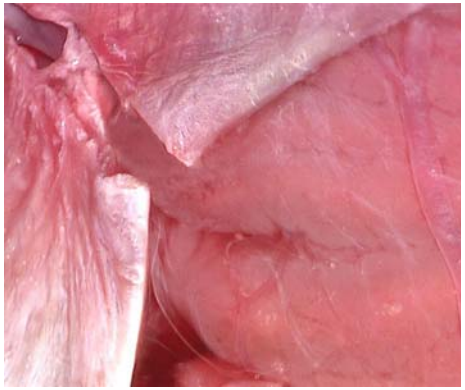

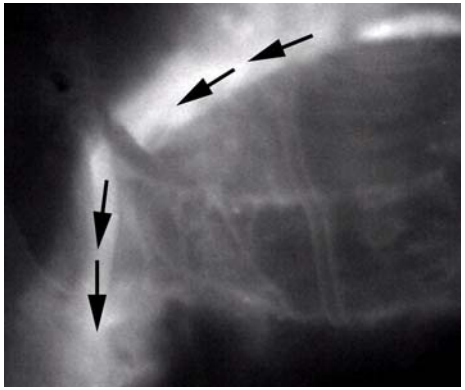

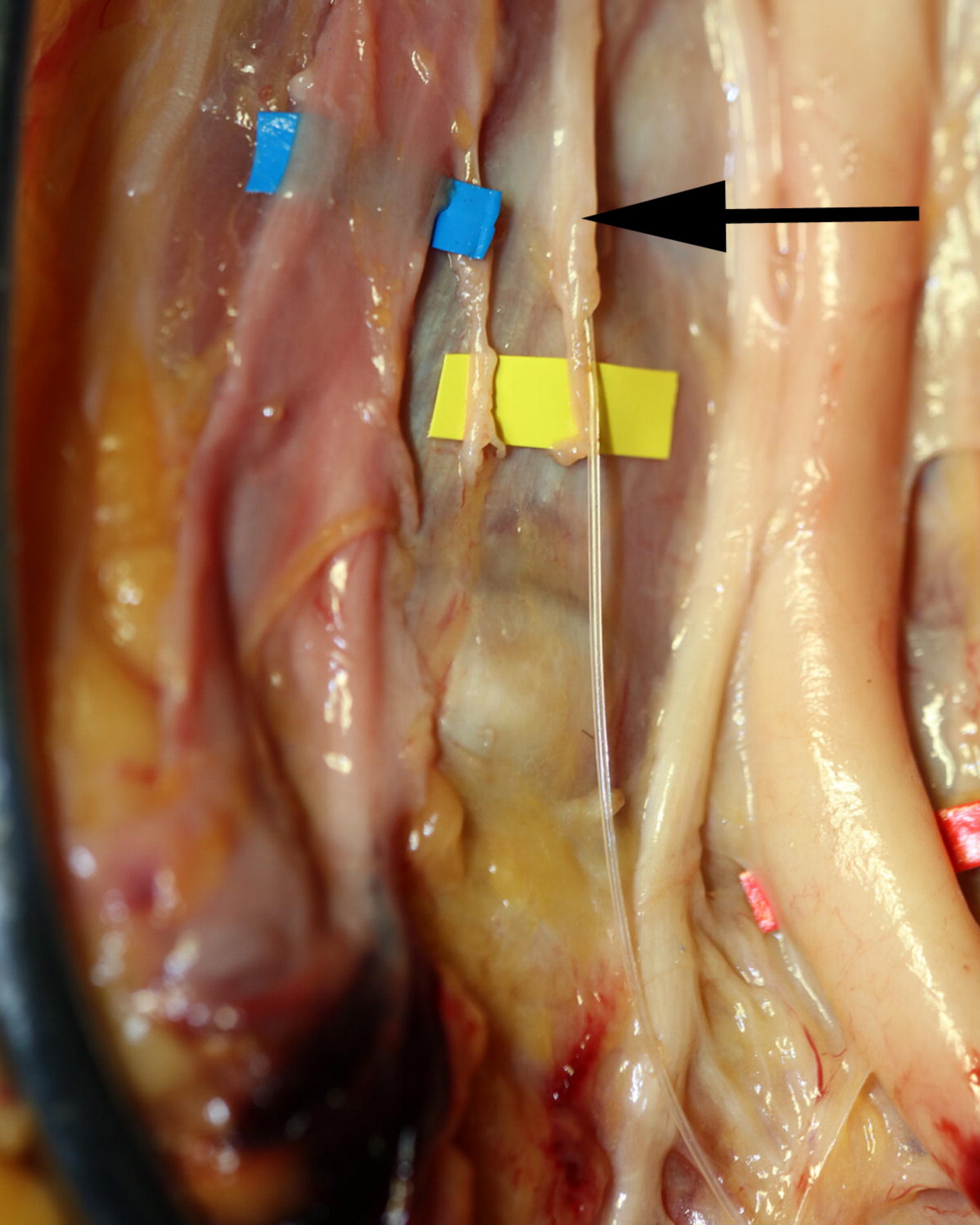

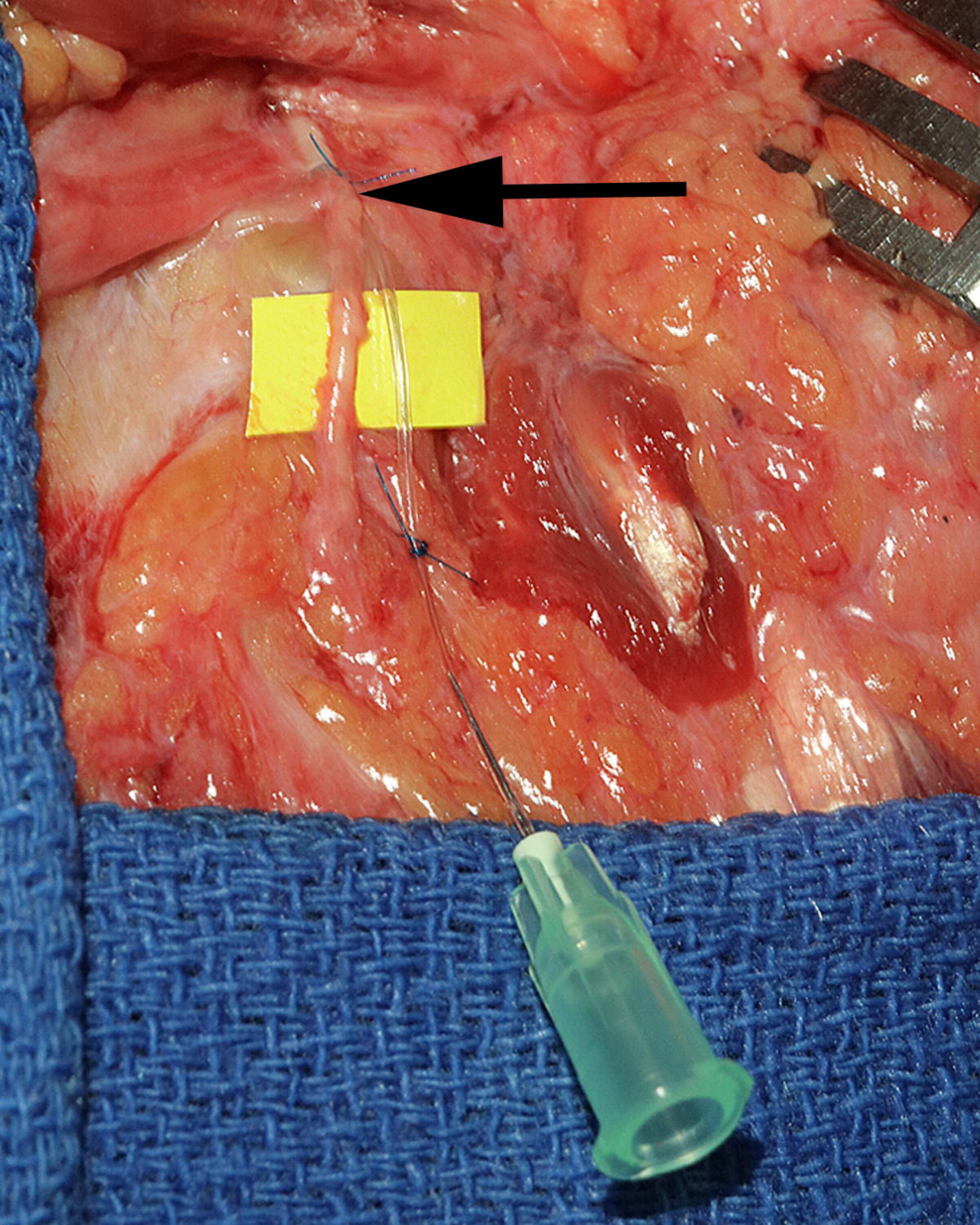

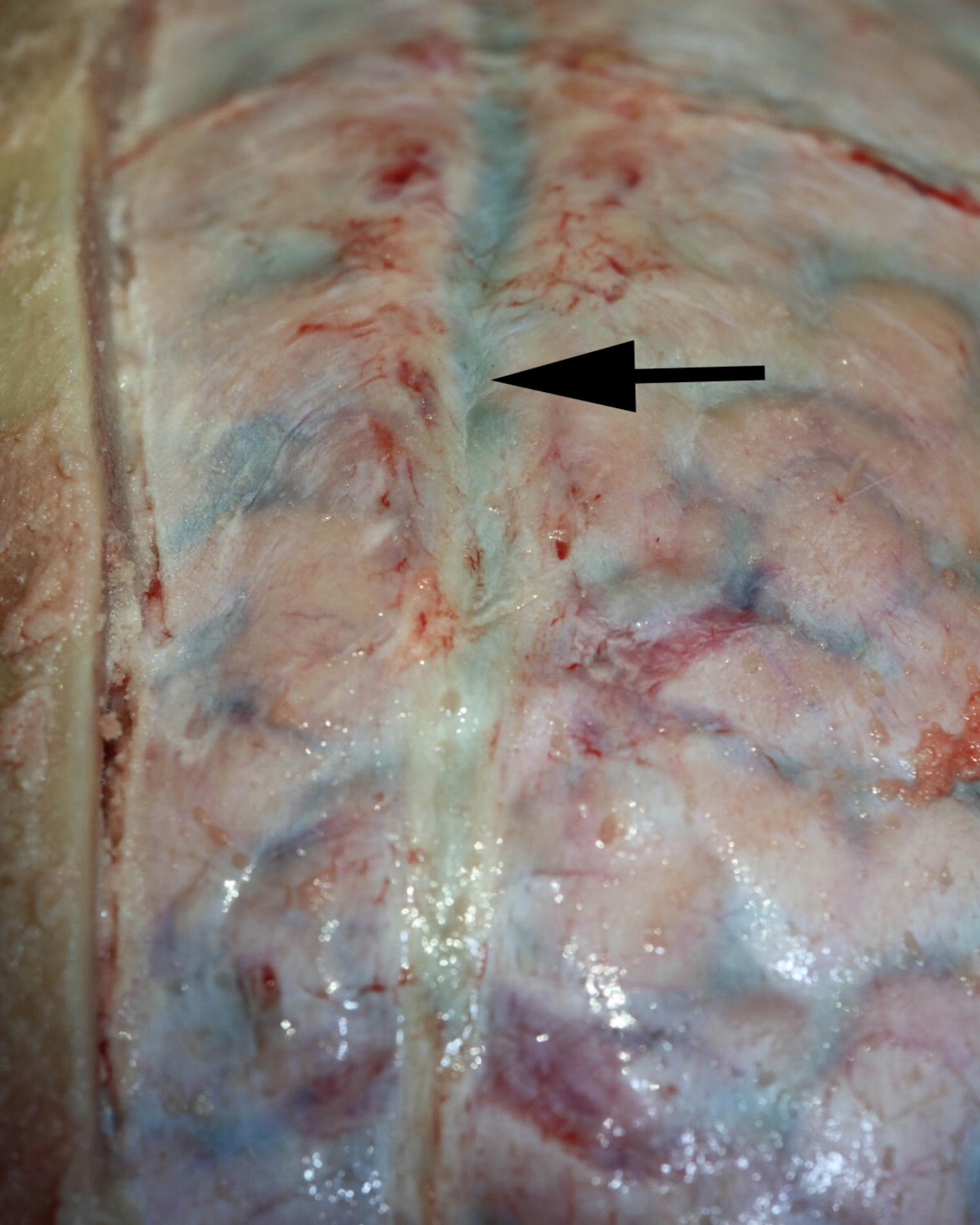

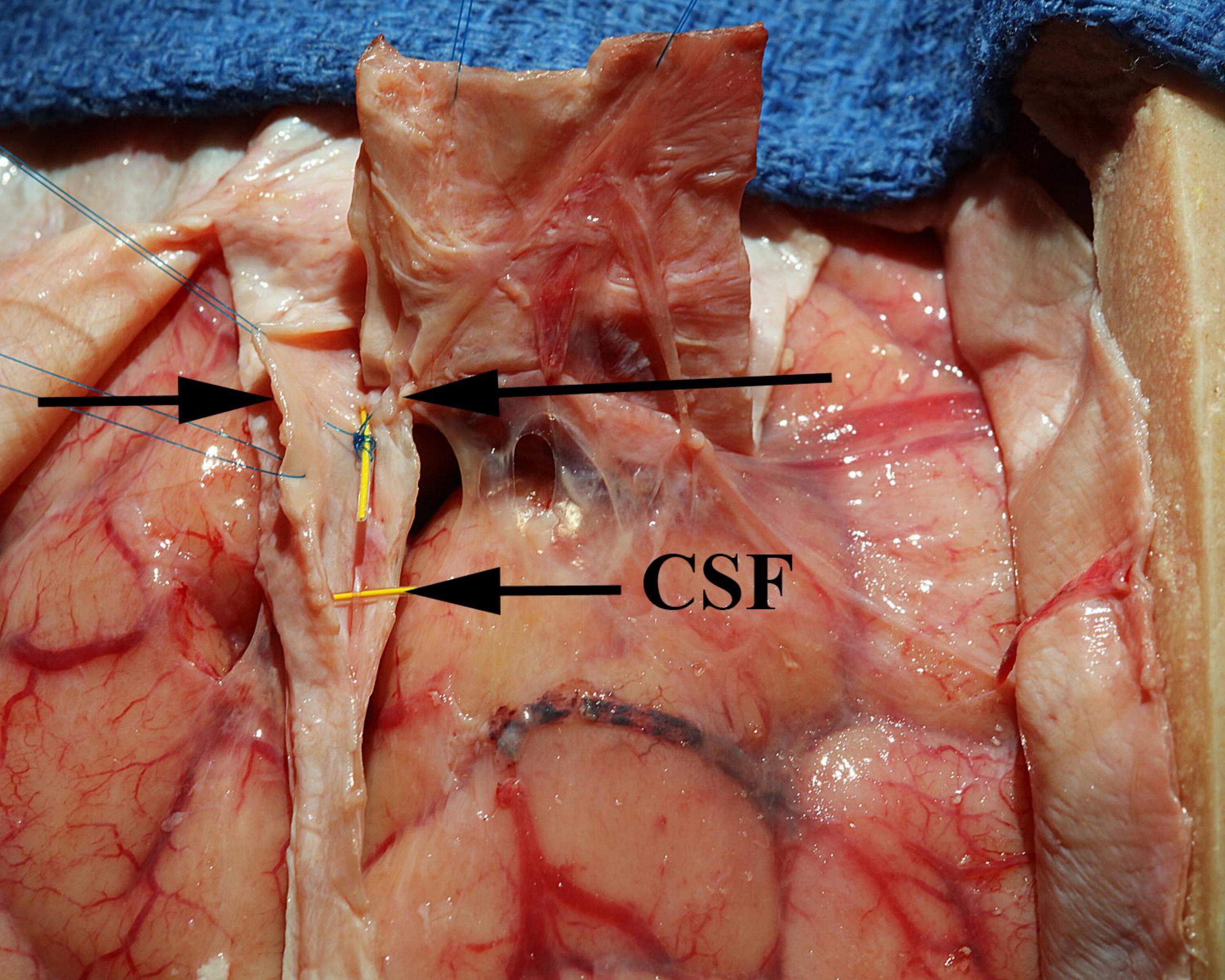
CSF

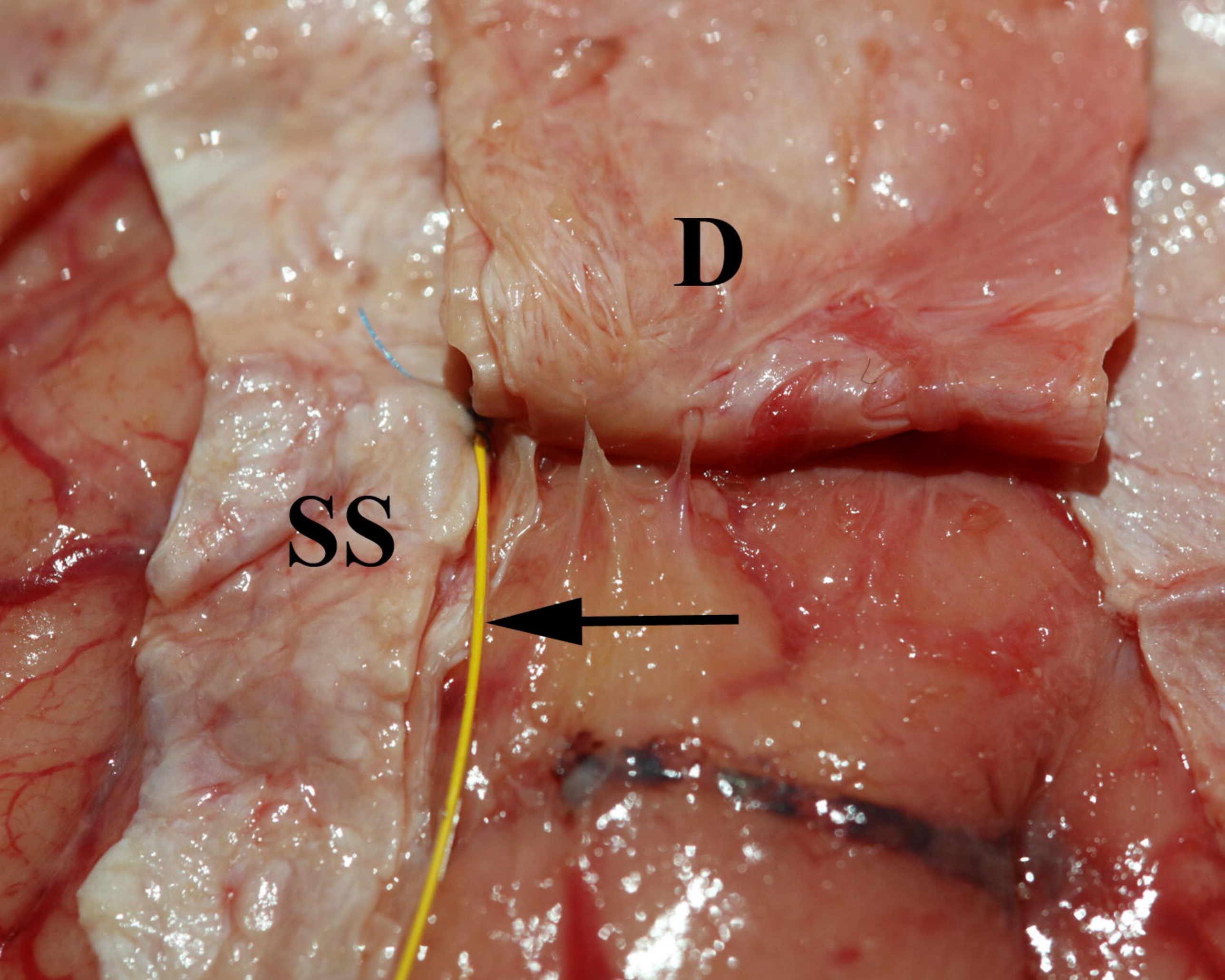
D
SS

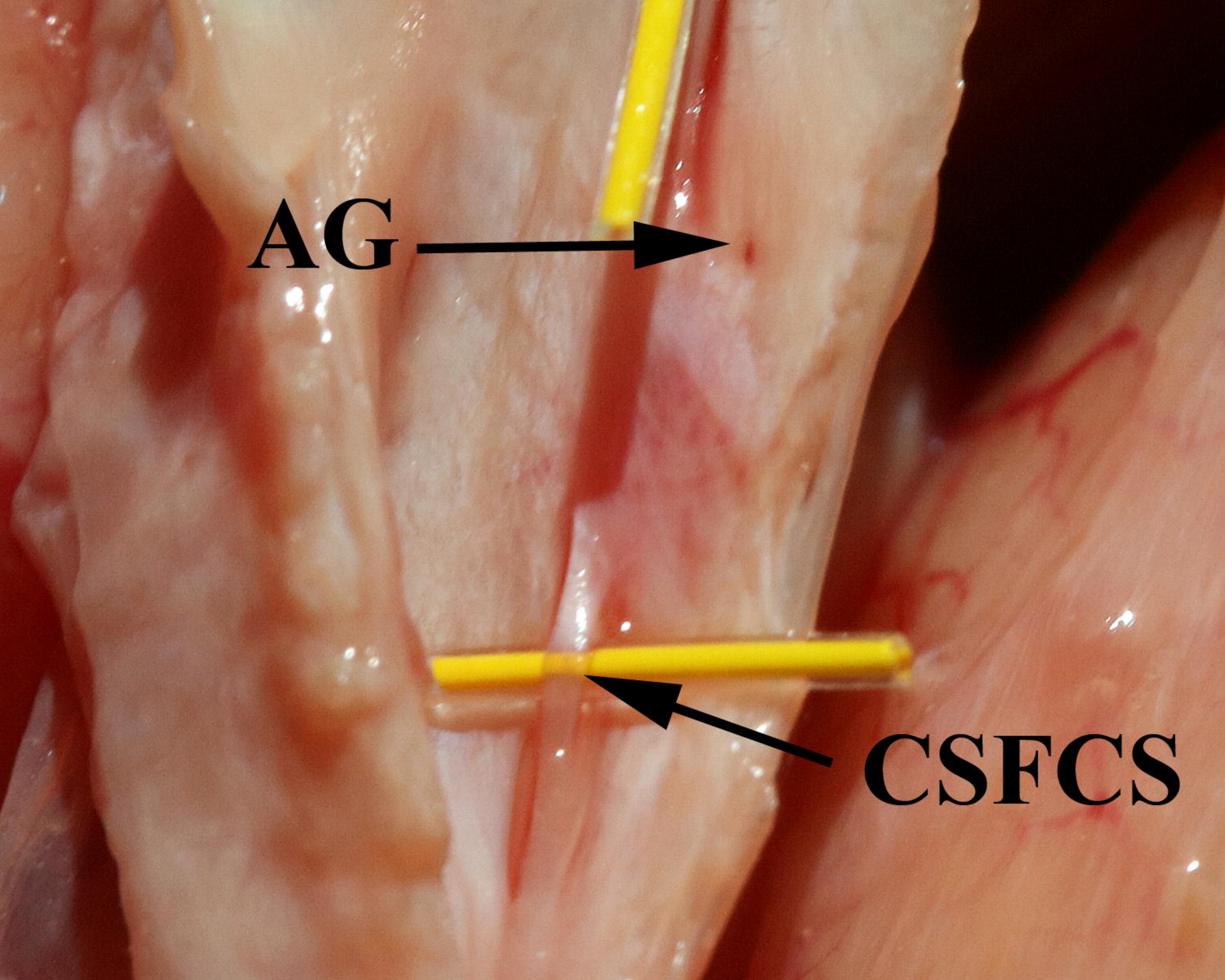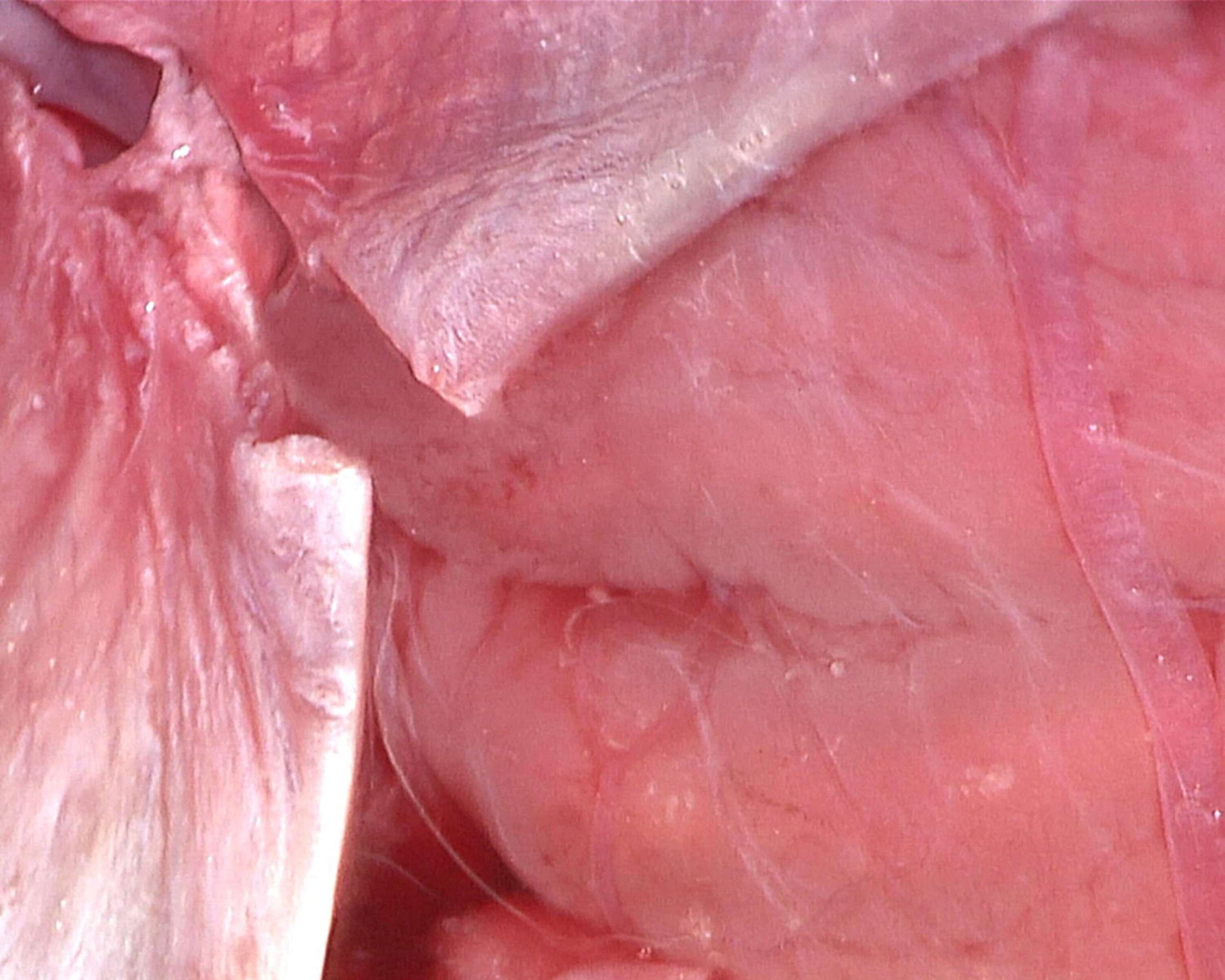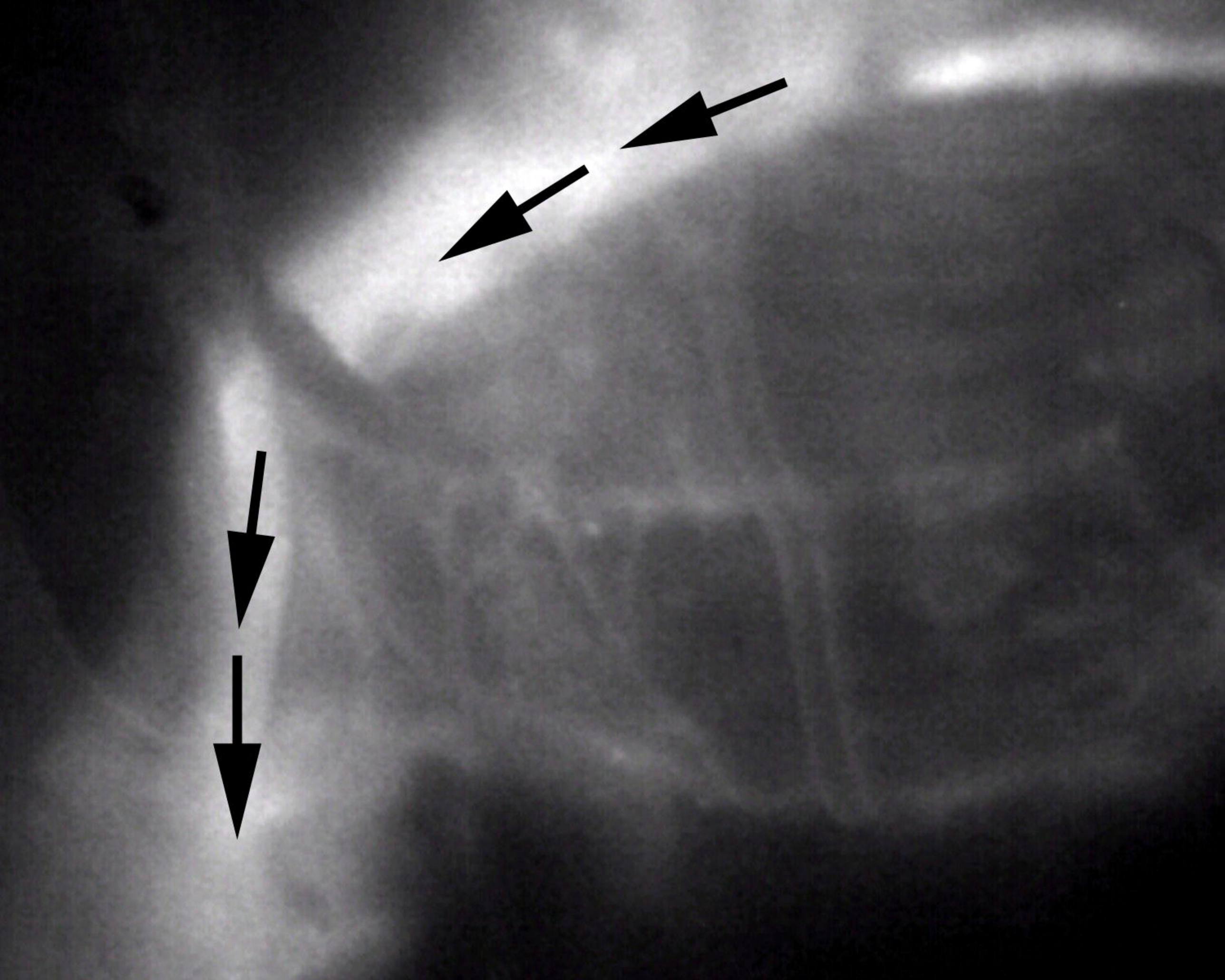
AG
CSFCS