Whether A Positive Response at approximately 4.5 ms in Auditory Brainstem Response Signifies Cochlear Nerve Deficiency in Infants?

Bei Li[123], Meiping Huang[123], Lu Yang[123], Xingyu Le[123], Haifeng Li[123], Yan Ren[123], Wentao Shi[123], Hao Wu[123], Zhiwu Huang[123] and Yun Li[123]

[1]Department of Otolaryngology-Head and Neck Surgery, Shanghai Ninth People's Hospital, Shanghai Jiao Tong University School of Medicine, China

[2]Hearing and Speech Center, Shanghai Ninth People's Hospital, Shanghai Jiao Tong University School of Medicine

[3]Shanghai Key Laboratory of Translational Medicine on Ear and Nose diseases

Financial disclosures/conflicts of interest: This work was supported by grants from the National Natural Science Foundation of China (grant 81700903 to BL), Clinical Research Plan of SHDC (shdc12020105) and Shanghai Key Laboratory of Translational Medicine on Ear and Nose Diseases (14DZ2260300). There are no conflicts of interest, financial, or otherwise.

All correspondence should be addressed to: Zhiwu Huang or Yun Li

Department of Otolaryngology-Head and Neck Surgery, Shanghai Ninth People's Hospital, Shanghai Jiao Tong University School of Medicine, NO.639 Road Zhizaoju, Shanghai, China. E-mail: huangzw086@163.com or liyuncmm@126.com

Abstract

Objectives: In the auditory brainstem response (ABR) tests, the regular V wave was absent, and a positive response at approximately 4.5 ms latency (IV' wave) was observed at high intensity level (80 to 95 dB) in some infants in our center. Those infants presenting the IV' wave was always diagnosed with cochlear nerve deficiency (CND). The profile of the IV' wave was summarized. The relationship between the IV' wave and CND was also explored.

Design: This was a retrospective study. The click ABR recordings of all infants who visited our center between February 2017 and December 2021 were reviewed. The inclusion criteria included profound hearing loss (ABR threshold > 95 dB) on at least one side. The exclusion criteria included age older than 36 months, tympanogram type B, specific ear trauma and infection history, other acquired hearing loss disease and no imaging examinations of the inner ear taken in our hospital. In total, 355 individuals were included. A total of 140 individuals had profound hearing loss in one ear, and 215 had profound hearing loss in both ears. Data were analyzed by ear and further grouped by CND diagnosis according to the inner ear imaging and IV' wave according to the click ABR recording.

Results: In the 355 patients, the IV' wave was observed in 53 ears. Of the 53 ears that presented with the IV' wave, 52 ears were diagnosed with CND. The other 76 ears were diagnosed with CND and showed no IV' wave. The positive predictive value of

the IV' wave for CND was 98.11%. The sensitivity of the IV' wave to CND was 40.63%. The amplitude of the IV' wave dropped significantly as the sound intensity decreased to 85 dB. The latency of the IV' wave ranged from 3.87 to 5.19 ms, averaged 4.58±0.189 ms at 95 dB, and barely prolonged as the sound intensity decreased.

Conclusions: Our study demonstrated that the regular V wave was absent and a 4.5 ms positive response was observed at high intensity level in the ABR tests in some infants. The IV' wave showed an excellent positive predictive value for CND. The IV' wave specifically presented in infants with CND has the potential to be a new indicator for the CND population.

Keywords: Auditory brainstem response, Cochlear nerve deficiency, Positive response at 4.5 ms, Profound hearing loss

INTRODUCTION

The auditory brainstem response (ABR) is probably the most widely used auditory evoked potential with clinical applications. The classic ABR is evoked by a 100-μs click of moderately high intensity level yielding several positive-to-negative waves within 10ms after stimulus onset. The individual waves are commonly labeled using Roman numerals. As a general rule, I, III, and V waves have mean latencies of 1.5, 3.5 and 5.5 ms, respectively in adults at moderately high intensity levels. Decreasing intensity level will subsequently cause a reduction of wave amplitudes and prolong latencies. When decreasing the intensity level, the earlier waves tend to drop out first, and V wave will often remain and prolong in latency when all other waves have disappeared (Hecox and Galambos 1974; Pratt et al. 1976). One of the primary clinical applications for the ABR is behavioral threshold estimation. The ABR have also been considered a primary functional measure of retrocochlear ear disease for several decades, such as the acoustic neuroma.

Universal newborn hearing screening programs have been implemented across China for over 20 years. The referred infants would be recommended to the referred centers and should be diagnosed by ABR tests within three months. Our center is one of the referral centers. We found that the regular V wave was absent, and a positive response at approximately 4.5 ms latency (IV' wave) was observed at the high sound intensity in some referred infants. In the further inner ear examinations, those infants were always diagnosed with cochlear nerve deficiency (CND) in the ear that

presented the IV' wave.

CND is a recognized cause of congenital sensorineural hearing loss (Casselman et al. 1997; Glastonbury et al. 2002). It includes cochlear nerve (CN) aplasia and CN hypoplasia. CND is mainly diagnosed by inner ear imaging examination, including high-resolution computed tomography (HRCT) and magnetic resonance imaging (MRI), and is typically defined as a small or absent CN in the internal auditory canal, as indicated by MRI. Although HRCT cannot visualize nerves, it can resolve the bony cochlear nerve canal (BCNC), which has also been reported to be narrower on average in ears with CN aplasia (Adunka et al. 2007; Miyasaka et al. 2010; Pagarkar et al. 2011).

In order to study the relationship between the IV' wave and CND, a retrospective study was designed. The click ABR waveforms were reviewed and the image information of all the individuals presenting the IV' wave was listed. A chi-squared test was applied. The profile of the IV' wave was further summarized, including latency and intensity-incidence.

MATERIALS AND METHODS

This was a retrospective study, and it was approved by the Translational Medicine Ethics Review Committee of Shanghai Ninth People's Hospital Affiliated to Shanghai Jiao Tong University, School of Medicine (SH9H-2022-T378-1). The click ABR waveforms of all referred infants who visited our center between February 2017 and December 2021 were reviewed. The details of the procedure and the stimulus

parameters of the click ABR tests are stated in Supplementary I. The inclusion criteria included profound hearing loss (ABR threshold > 95 dB) on at least one side. The exclusion criteria included age at the first visit older than 36 months, tympanogram type B, specific ear trauma and infection history, other acquired hearing loss disease, and no imaging examinations of the inner ear taken in our hospital.

Firstly, 877 ABR recordings that met the criteria were screened out. Subsequently, 46 follow-up recordings were excluded. Of the remaining 831 patients, 35 patients were excluded for a first visit age older than 36 months, 29 patients were excluded for tympanogram type B and 412 patients were excluded for lack of imaging examination in our hospital. Finally, 355 patients were included. The selected patients were sorted again by the time taking the ABR tests.

In the 355 patients, 140 individuals had profound hearing loss in one ear, of which 80 showed hearing loss in the left ear and 60 showed hearing loss in the right ear. A total of 215 individuals had profound hearing loss in both ears. In total, 570 ears were included. A total of 140 individuals only underwent HRCT, 46 individuals only underwent MRI and 169 individuals underwent both examinations.

Radiological results were based on reports reviewed by radiologists with more than five years of experience. The diagnostic criteria for CND are CN nerve smaller than the facial nerve on oblique sagittal images in the MRI or BCNC ≤1.5 mm in the HRCT.

All the data were analyzed by ear and were further grouped by IV' wave and CND diagnosis. The positive predictive value of the IV' wave for CND was

calculated. The features of the IV' wave was explored, including latency and intensity-incidence (threshold). In addition, there were seven individuals who presented wave IV' at the first visit and had a follow-up visit later. The ABR recordings were also compared and discussed.

Results

The profile of the IV' wave

In the ABR test, the regular V wave was absent, while the IV' wave was observed at the high intensity level (80 to 95 dB). The IV' wave amplitude dropped significantly as the sound intensity decreased to 85 dB. The latency of the IV' wave was barely prolonged as the sound intensity decreased. In the 570 ears, the IV' wave was observed in 53 ears. Twenty-six ears were observed on both sides of 13 individuals with profound bilateral hearing loss. Six ears were observed on only one side of six individuals with profound bilateral hearing loss. Twenty-one ears were observed in 21 individuals with unilateral profound hearing loss. The typical IV' waves of the 3 cases are shown in Figure 1. Seven individuals had a follow-up visit, and 6 of them still presented with the IV' wave. The latency of the IV' wave was calculated among all the ABR recordings of the individuals including the 6 follow-up visits. The latency of the IV' wave ranged from 3.87 to 5.19 ms, averaging 4.58 ± 0.189 ms at 95 dB.

FIGURE 1

Because of the rareness of the ABR recordings in lower sound intensity in

individuals with profound hearing loss. The intensity-incidence of the IV' wave for threshold estimation was calculated among the 62 ABR recordings in the 53 ears. At 95 dB, 100% of ears displayed the IV' wave (62/62). At 90 dB, 59% of ears displayed the IV' wave (36/61). At 85 dB, 33% of ears displayed the IV' wave (8/24). At 80 dB, 6% of ears displayed the IV' wave (2/33). At 70 dB, none of the ears displayed the IV' wave (0/2).

Follow-up of the IV' wave

The age of the individuals observed with the IV' wave ranged from 3 to 27 months. Seven individuals presented with the IV' wave at the first visit and had a follow-up visit later. The follow-up period ranged from 3 to 11 months. The waveform morphology of the IV' wave was slightly different depending on the different ABR recording systems. However, in the same ABR recording system, the waveform morphology of the IV' wave in the follow-up visit ABR recordings was similar to the previous waveforms. The IV' wave was only barely observed in one individual 11 months later. The testing age and IV' wave display side of all seven individuals are listed in Table 1. The ABR recordings of the seven patients are displayed in Supplementary II.

TABLE 1

The relationship between the IV' wave and CND

Of the 53 ears that presented with the IV' wave, 52 ears were diagnosed with CND. The remaining ear (individual) was diagnosed with large vestibular aqueduct syndrome accompanied by Mondini deformity. The other 76 ears were diagnosed with

CND and showed no IV' wave. A chi-squared test employing a 2 x 2 contingency table (Table 2) showed that the incidence of the IV' wave in the CND is highly unlikely to occur by chance ($p < 0.001$). The positive predictive value of the IV' wave for CND was 98.11%. The sensitivity of the IV' wave for identifying CND was 40.63%.

TABLE 2

The information and radiological results of the individuals presenting with the IV' wave is listed in Table 3. The CT and MRI images of the normal and abnormal inner ears are displayed in Figures 2 and 3, respectively.

TABLE 3

FIGURE 2

FIGURE 3

DISCUSSION

We reported a 4.5 ms positive response, while the regular V wave was absent at the high intensity level in the ABR tests in some referred infants. We tentatively summarized the features of the IV' wave. The latency of the IV' wave averaging 4.58±0.189 ms at 95 dB distinguished itself from the regular V wave. Other features of the IV' wave includes presenting only at the high intensity level, barely prolonged latency and significantly dropped amplitude at 85 dB. These features are similar to the vestibular evoked myogenic potentials.

The origin of the IV' wave remains unclear. Sometimes IV waves are invisible in

normal click-ABR recordings. In contrast to the adult-like ABR, the infant and toddler ABR has slightly greater low-frequency energy. Whether the IV' wave in our study is wave IV remains unclear. Wave IV is concluded to arises from midline brainstem structures, perhaps acoustic stria, trapezoid bodies, and the superior olivary complex (Møller 2006). Studies have indicated that the bandpass filter setting (300 to 3000 Hz) had an impact on the identification of the ABR wave, especially a better identification of wave IV on the contralateral side (Lettrem and Laukli 1995). However, wave IV was observed in the normal ABR with waves I to V in the study. In our study, the bandpass filter setting of the ABR test was 100 to 3000 Hz, and the ABR was recorded ipsilaterally. The IV' wave was observed without a regular V wave. As a result, the obversion of the IV' wave is probably unconnected to the frequency of the bandpass filter.

To the best of our knowledge, this is the first reported study of the special ABR waveform in infants with CND. Nowadays, ABRs are of high clinical relevance for objective analysis of hearing function, especially for screening for auditory neuropathy, acoustic neuroma, and central hearing loss (Lewis et al. 2015; Roeser et al. 2007), as well as possible in the future for assessing "hidden hearing loss" (Kujawa and Liberman 2009; Mehraei et al. 2016; Ridley et al. 2018). The IV' wave in our study showed an excellent positive predictive value to CND. However, previous studies have shown that the ABR has a reasonably short maturational time course, the various peaks undergo changes in amplitude and latency at different rates in the first few years of life, and it does not become adult-like until around three years of age

(Fria and Doyle 1984; Hecox and Burkard 1982; Salamy 1984). In our study, all ABR recordings were obtained in infants younger than three years old. The seven follow-up ABR recordings showed that the IV' wave was barely observed in one individual. Whether the IV' wave would be observed constantly in those infants until adulthood remains unknown. More studies of the IV' wave in CND children and adults are needed.

In our study, approximately 40% of CND ears presented the IV' wave. The IV' wave reported in our study might imply that the degree of nerve hypoplasia is less severe than that without the IV' wave and might result in a better outcome of cochlear implantation (CI). As a result, the CI outcome of patients diagnosed with bilateral CND with and without the IV' wave is worth exploring. Most children diagnosed with bilateral CND have severe-to-profound hearing loss and hence meet the audiological criteria for CI (Adunka et al. 2007). However, the outcomes of CI in patients with CND have been reported to be extremely variable (Degirmenci et al. 2022; Wu et al. 2015; Young et al. 2012; Zhang et al. 2012). Several authors have also stated that patients with CND have no chance to benefit from traditional CI and suggested direct stimulation of the cochlear nuclei by means of auditory brainstem implantation to improve auditory-verbal skills in such patients (Buchman et al. 2011; Colletti et al. 2001; Sennaroglu et al. 2009). For the same reason, once the infants are diagnosed with unilateral CND, if the hearing of the other ear is within normal, CI is just an alternative. To create an objective predictive model for the outcome of CI in patients with CND, indicators such as BCNC width (Chung et al. 2018), the area ratio of

vestibulocochlear nerve to facial nerve (Han et al. 2019), vestibulocochlear nerve area and the number of nerve bundles (Lu et al. 2022) were applied. However, all those indicators are based on imaging examinations. Freeman and Sennaroglu (Freeman and Sennaroglu 2018) noted that radiological examination had a rate of false positives, and the absence of a vestibulocochlear nerve does not mean that the nerve is not present. Therefore, those radiological distractions could also have a negative impact on the predictive model. The IV' wave specifically presented in the CND ears has the potential to be a new indicator for the CND population. The predictive accuracy of the models that applied both the IV' wave and the radiological indicator could be improved effectively.

CONCLUSION

Our study demonstrated a special ABR waveform with an absent of regular V wave and a positive response approximately 4.5 ms at the high intensity level in some referred infants. The IV' wave showed an excellent positive predictive value for CND. The IV' wave specifically presented in infants with CND has the potential to be a new indicator for the CND population.

REFERENCES

Adunka, O. F., Jewells, V., Buchman, C. A. (2007). Value of computed tomography in the evaluation of children with cochlear nerve deficiency. *Otol Neurotol, 28*, 597-604.

Buchman, C. A., Teagle, H. F., Roush, P. A., et al. (2011). Cochlear implantation in children with labyrinthine anomalies and cochlear nerve deficiency: implications for auditory brainstem implantation. *Laryngoscope, 121*, 1979-1988.

Casselman, J. W., Offeciers, F. E., Govaerts, P. J., et al. (1997). Aplasia and hypoplasia of the vestibulocochlear nerve: diagnosis with MR imaging. *Radiology, 202*, 773-781.

Chung, J., Jang, J. H., Chang, S. O., et al. (2018). Does the Width of the Bony Cochlear Nerve Canal Predict the Outcomes of Cochlear Implantation? *Biomed Res Int, 2018*, 5675848.

Colletti, V., Fiorino, F., Sacchetto, L., et al. (2001). Hearing habilitation with auditory brainstem implantation in two children with cochlear nerve aplasia. *Int J Pediatr Otorhinolaryngol, 60*, 99-111.

Degirmenci Uzun, E., Batuk, M. O., D'Alessandro, H. D., et al. (2022). Auditory perception in pediatric cochlear implant users with cochlear nerve hypoplasia. *Int J Pediatr Otorhinolaryngol, 160*, 111248.

Freeman, S. R., Sennaroglu, L. (2018). Management of Cochlear Nerve Hypoplasia and Aplasia. *Adv Otorhinolaryngol, 81*, 81-92.

Fria, T. J., Doyle, W. J. (1984). Maturation of the auditory brain stem response (ABR): additional perspectives. *Ear Hear, 5*, 361-365.

Glastonbury, C. M., Davidson, H. C., Harnsberger, H. R., et al. (2002). Imaging findings of cochlear nerve deficiency. *AJNR Am J Neuroradiol, 23*, 635-643.

Han, J. J., Suh, M. W., Park, M. K., et al. (2019). A Predictive Model for Cochlear Implant Outcome in Children with Cochlear Nerve Deficiency. *Sci Rep, 9*, 1154.

Hecox, K., Burkard, R. (1982). Developmental dependencies of the human brainstem auditory evoked response. *Ann N Y Acad Sci, 388*, 538-556.

Hecox, K. E., Galambos, R. L. J. A. o. O.-h., Surgery, N. (1974). Brain Stem Auditory Evoked Responses in Human Infants and Adults. *99*, 30-33.

Kujawa, S. G., Liberman, M. C. J. J. o. N. t. O. J. o. t. S. f. N. (2009). Adding Insult to Injury: Cochlear Nerve Degeneration after "Temporary" Noise-Induced Hearing Loss. *29*, 14077.

Lettrem, I., Laukli, E. (1995). Analog and digital filtering of ABR: ipsi- and contralateral derivations. *Ear Hear, 16*, 508-514.

Lewis, J. D., Kopun, J., Neely, S. T., et al. (2015). Tone-burst auditory brainstem response wave V latencies in normal-hearing and hearing-impaired ears. *138*, 3210.

Lu, S., Xie, J., Wei, X., et al. (2022). Machine Learning-Based Prediction of the Outcomes of Cochlear Implantation in Patients With Cochlear Nerve Deficiency and Normal Cochlea: A 2-Year Follow-Up of 70 Children. *Front*

Neurosci, 16, 895560.

Mehraei, G., Hickox, A. E., Bharadwaj, H. M., et al. (2016). Auditory brainstem response latency in noise as a marker of cochlear synaptopathy. *36*.

Miyasaka, M., Nosaka, S., Morimoto, N., et al. (2010). CT and MR imaging for pediatric cochlear implantation: emphasis on the relationship between the cochlear nerve canal and the cochlear nerve. *Pediatr Radiol, 40*, 1509-1516.

Møller, A. R. (2006). Hearing : anatomy, physiology, and disorders of the auditory system.

Pagarkar, W., Gunny, R., Saunders, D. E., et al. (2011). The bony cochlear nerve canal in children with absent or hypoplastic cochlear nerves. *Int J Pediatr Otorhinolaryngol, 75*, 764-773.

Pratt, H., Sohmer, H. J. A. O. (1976). Intensity and rate functions of cochlear and brainstem evoked responses to click stimuli in man. *212*, 85-92.

Ridley, C. L., Kopun, J. G., Neely, S. T., et al. (2018). Using Thresholds in Noise to Identify Hidden Hearing Loss in Humans. *Ear Hear, 39*, 829-844.

Roeser, R. J., Valente, M., Hosforddunn, H. (2007). Audiology Diagnosis.

Salamy, A. (1984). Maturation of the auditory brainstem response from birth through early childhood. *J Clin Neurophysiol, 1*, 293-329.

Sennaroglu, L., Ziyal, I., Atas, A., et al. (2009). Preliminary results of auditory brainstem implantation in prelingually deaf children with inner ear malformations including severe stenosis of the cochlear aperture and aplasia of the cochlear nerve. *Otol Neurotol, 30*, 708-715.

Wu, C. M., Lee, L. A., Chen, C. K., et al. (2015). Impact of cochlear nerve deficiency determined using 3-dimensional magnetic resonance imaging on hearing outcome in children with cochlear implants. *Otol Neurotol*, *36*, 14-21.

Young, N. M., Kim, F. M., Ryan, M. E., et al. (2012). Pediatric cochlear implantation of children with eighth nerve deficiency. *Int J Pediatr Otorhinolaryngol*, *76*, 1442-1448.

Zhang, Z., Li, Y., Hu, L., et al. (2012). Cochlear implantation in children with cochlear nerve deficiency: a report of nine cases. *Int J Pediatr Otorhinolaryngol*, *76*, 1188-1195.

Figure Legends

FIGURE 1. Examples of the IV' wave in 3 cases. A, Normal V wave present in the right ear and the IV' wave present in the left ear. B, The IV' wave presents bilaterally. C, The IV' wave is present in the right ear and no wave is present in the left ear

FIGURE 2. The normal and abnormal inner ear on high-resolution computed tomography imaging. A, Normal inner ear image with a click ABR threshold of 5 dB of the right ear. B, Bony cochlear nerve canal stenosis without inner ear malformations with profound hearing loss of the left ear. C, Incomplete partition type I with profound hearing loss of the left ear. D, Vestibular semicircular canal deformity with profound hearing loss of the left ear

FIGURE 3. The normal and abnormal cochlear nerve on oblique sagittal magnetic resonance imaging. A, Normal cochlear nerve image with a click ABR threshold of 0 dB of the right ear. B, Cochlear nerve hypoplasia with profound left ear hearing loss. C, Cochlear nerve absent with profound left ear hearing loss. CN: cochlear nerve; FN: facial nerve; IVN: inferior vestibular nerve; SVN: superior vestibular nerve

List of SDC

Supplemental Digital Content 1.docx

Supplemental Digital Content 2.pdf

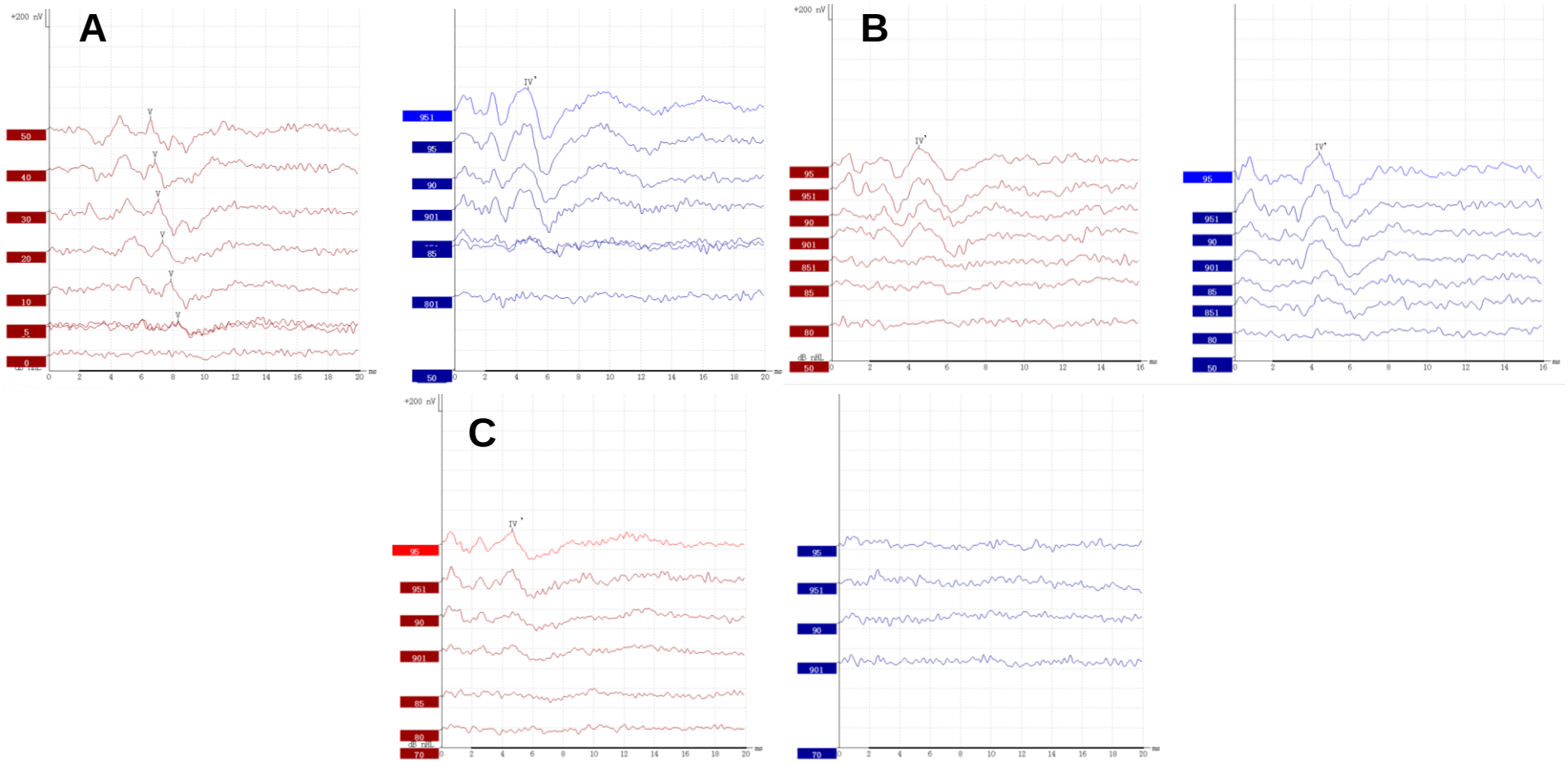
A
B
C
+200 nV
V
IV'
ms

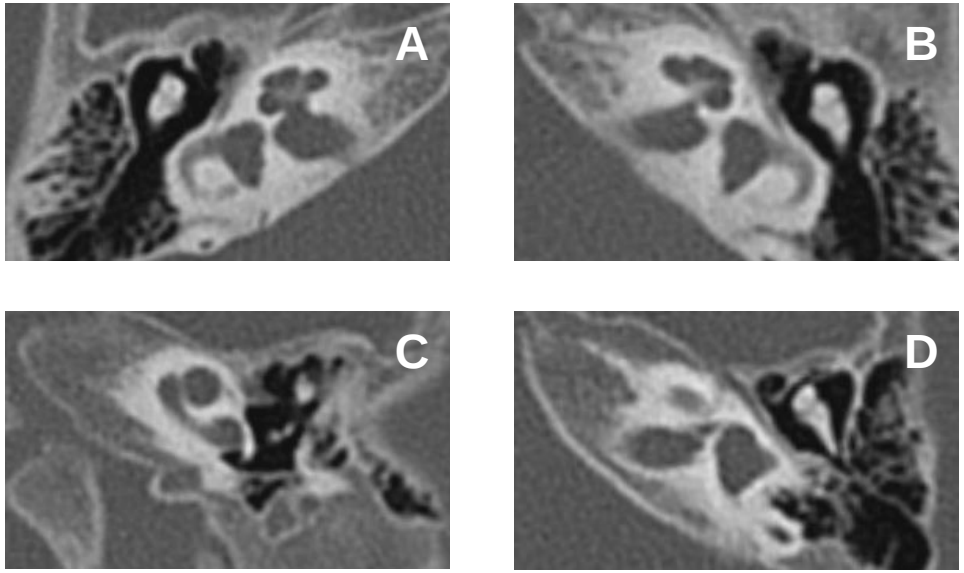
A
B
C
D

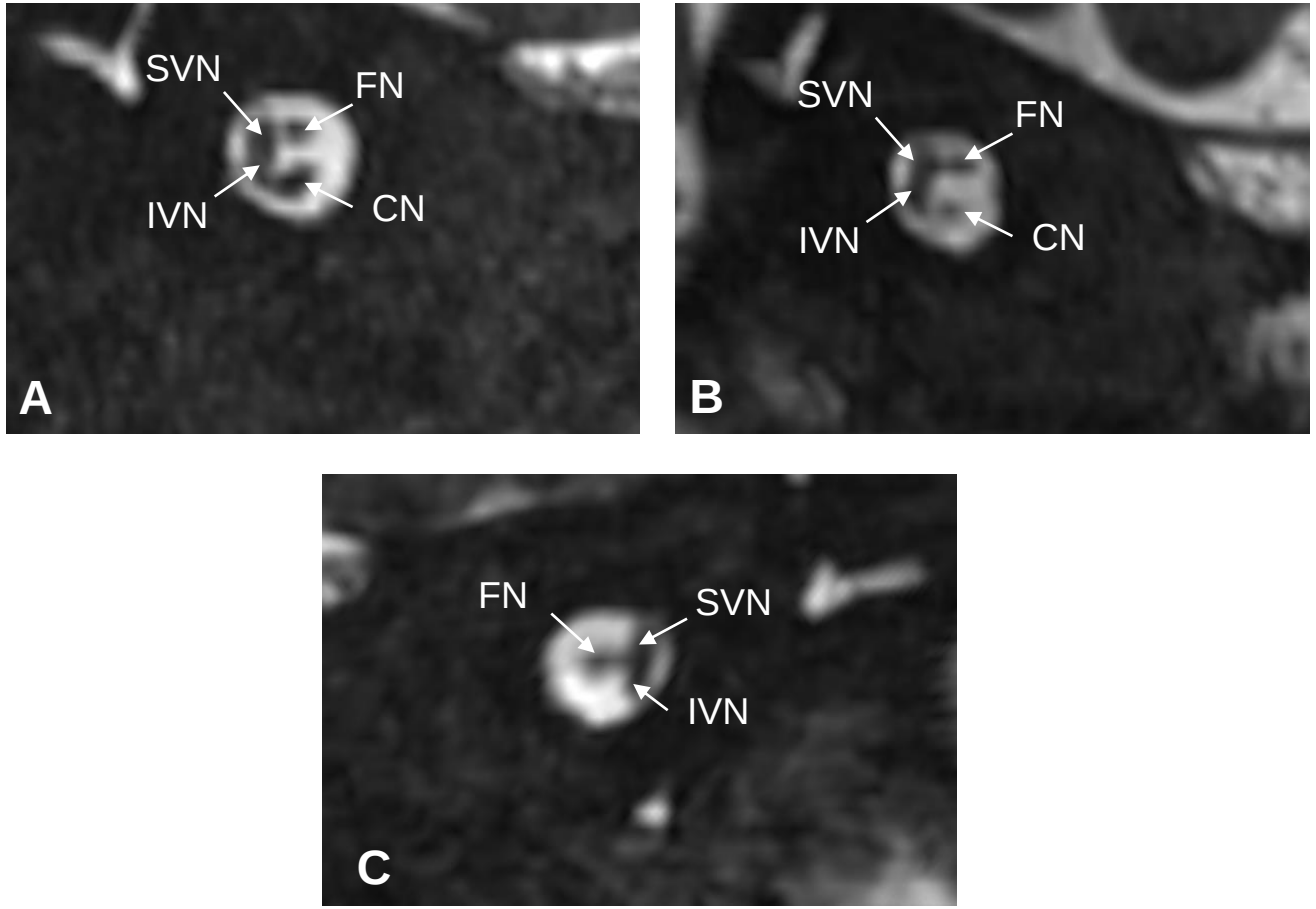
SVN
FN
IVN
CN
A
SVN
FN
IVN
CN
B
FN
SVN
IVN
C

Table 1. The testing age and the IV' wave display side of all seven individuals

First visit Age (months)	First visit IV' wave side	Follow-up Age (months)	Follow-up IV' wave side
12 ~ 18	Left	18 ~ 24	Left
0 ~ 6	Left	12 ~ 18	Left
0 ~ 6	Left	6 ~ 12	Left
0 ~ 6	Left	6 ~ 12	Left
6 ~ 12	Left	18 ~ 24	Left?
0 ~ 6	Both	6 ~ 12	Both
12 ~ 18	Both	18 ~ 24	Both

Table 2. A 2 x 2 contingency table for the numbers of ears showed profound hearing loss with and without IV' wave. A chi-squared test on this data suggests that the greater incidence of the IV' wave in the CND is statistically significant ($p < 0.001$)

Auditory Brainstem Response > 95	IV' wave Present	IV' wave Absent	Total
Cochlear nerve deficiency	52	76	128
No Cochlear nerve deficiency	1	441	442
Total	53	517	570

In the no cochlear nerve deficiency group with IV' wave absent, there were 347 ears showed no inner ear malformation, 41 ears showed enlarged vestibular aqueduct and 53 ears showed cochlear or vestibular malformation including 16 ears Michel deformity.

Table 3. The information and radiological results of the individuals presenting with the IV' wave

sex	PHL side / IV' wave side	Inner ear malformations		CN on MRI	
		R	L	R	L
M	L/L	/	BCNCS	-	-
F	L/L	/	BCNCS	/	Absent
F	L/L	/	BCNCS	/	Absent
M	B/R	BCNCS	BCNCS	-	-
M	L/L	/	BCNCS	-	-
M	R/R	BCNCS	/	-	-
F	L/L	/	BCNCS	/	Hypoplasia
F	L/L	/	BCNCS	/	Hypoplasia
M	B/B	BCNCS	BCNCS	Absent	Hypoplasia
F	L/L	/	BCNCS	/	Hypoplasia

M	B/L	Vestibular semicircular canal deformity	Vestibular semicircular canal deformity	-	-
F	B/B	BCNCS	BCNCS	Hypoplasia	Hypoplasia
M	B/B	BCNCS	BCNCS	Absent	Hypoplasia
F	R/R	BCNCS	/	-	-
F	L/L	/	BCNCS	-	-
M	L/L	/	BCNCS	-	-
F	B/B	BCNCS	BCNCS	Absent	Absent
M	B/L	BCNCS	BCNCS	Absent	Absent
F	L/L	/	BCNCS	-	-
M	B/R	BCNCS	BCNCS	Hypoplasia	Hypoplasia
M	B/L	BCNCS	BCNCS	-	-

M	L/L	/	IP-I, enlarged vestibular aqueduct	/	Hypoplasia
M	L/L	/	BCNCS	-	-
M	L/L	/	BCNCS	-	-
M	L/L	/	Vestibular semicircular canal deformity	-	-
F	L/L	/	BCNCS	/	Hypoplasia
M	L/L	/	BCNCS	-	-
F	B/B	BCNCS	BCNCS	Hypoplasia	Hypoplasia
F	B/B	BCNCS	BCNCS	Absent	Hypoplasia
F	B/B	BCNCS	BCNCS	Absent	Hypoplasia
F	B/B	BCNCS	BCNCS	Absent	Absent

M	B/R	BCNCS	BCNCS	-	-
F	B/B	BCNCS	BCNCS	Absent	Absent
F	B/B	BCNCS	BCNCS	Absent	Absent
F	B/B	BCNCS	BCNCS	Absent	Absent
M	B/B	BCNCS	BCNCS	Absent	Absent
F	R/R	BCNCS	/	-	-
M	L/L	/	BCNCS	-	-
M	B/B	BCNCS	BCNCS	Absent	Absent
F	R/L	BCNCS	/	Absent	/

PHL profound hearing loss, CN cochlear nerve, M male, F female, R right, L left, B both sides, BCNCS bony cochlear nerve canal stenosis, / not evaluated, - no data,

IP-I Incomplete partition type I