medRxiv preprint doi: https://doi.org/10.1101/2022.12.14.22283447; this version posted December 14, 2022. The copyright holder for this preprint (which was not certified by peer review) is the author/funder, who has granted medRxiv a license to display the preprint in perpetuity.

It is made available under a CC-BY 4.0 International license .

Long-term safety and efficacy of treating symptomatic, partial-thickness rotator cuff tears with fresh, uncultured, unmodified, autologous, adipose-derived regenerative cells isolated at the point of care: 40 months follow-up of a prospective, randomized, controlled, first-in-human clinical trial

Mark Lundeen[1], Jason L. Hurd[2], Matthew Hayes[3], Meredith Hayes[3], Tiffany R. Facile[4], John P. Furia[5], Nicola Maffulli[6,7,8], Christopher Alt[9,10,11], Eckhard U. Alt[9,11,12,13], Christoph Schmitz[10], David A. Pearce[4,12,14]*

[1] *Sanford Orthopedics & Sports Medicine Fargo, Fargo, ND, USA.*
[2] *Sanford Orthopedics & Sports Medicine Sioux Falls, Sioux Falls, SD, USA.*
[3] *Sanford Radiology Clinic, Sioux Falls, SD, USA.*
[4] *Sanford Health, Sioux Falls, SD, USA.*
[5] *SUN Orthopedics of Evangelical Community Hospital, Lewisburg, PA, USA.*
[6] *Department of Musculoskeletal Disorders, Faculty of Medicine and Surgery, University of Salerno, Salerno, Italy.*
[7] *Centre for Sports and Exercise Medicine, Barts and The London School of Medicine and Dentistry, Mile End Hospital, Queen Mary University of London, London, UK.*
[8] *School of Pharmacy and Bioengineering, Guy Hilton Research Centre, Keele University School of Medicine, Stoke on Trent, UK.*
[9] *InGeneron, Inc., Houston, TX, USA.*
[10] *Institute of Anatomy, Faculty of Medicine, LMU Munich, Munich, Germany.*
[11] *Isar Klinikum, Munich, Germany.*
[12] *Sanford School of Medicine, University of South Dakota, Sioux Falls, SD, USA.*
[13] *Heart and Vascular Institute, Department of Medicine, Tulane University Health Science Center, New Orleans, LA, USA.*
[14] *Sanford Research, Sioux Falls, SD, USA.*

Objective: Symptomatic, partial-thickness rotator cuff tears (sPTRCT) are problematic. Management of sPTRCT with fresh, uncultured, unmodified, autologous, adipose-derived regenerative cells (UA-ADRCs) isolated from lipoaspirate at the point of care is safe and leads to improved shoulder function without adverse effects. This study tested the hypothesis that management of sPTRCT with injection of UA-ADRCs is safe and more effective than injection of corticosteroid even in the long run.

Methods: Subjects who had completed a former randomized controlled trial were enrolled in the present study. At baseline these subjects had not responded to physical therapy treatments for at least six weeks, and were randomly assigned to receive respectively a single injection of an average 11.4×10^6 UA-ADRCs (n = 11) or a single injection of 80 mg of methylprednisolone (n = 5). Safety was assessed by rigorously documenting and evaluating treatment emergent adverse events. Efficacy was assessed using the ASES Total score, pain visual analogue scale (VAS) and RAND Short Form-36 Health Survey at 33.2 ± 1.0 (mean ± standard deviation) and 40.6 ± 1.9 months post-treatment. Proton density, fat-saturated, T2-weighted (PD FS T2), magnetic resonance imaging (MRI) of the index shoulder was performed at both study visits.

Results: There were no greater risks connected with injection of UA-ADRCs than those connected with injection of corticosteroid. The subjects in the UA-ADRCs group showed statistically significantly higher mean ASES Total scores than the subjects in the corticosteroid group. Treatment outcome could not be assessed using measurements of tear volume on MRI scans. On the other hand, PD FS T2 MRI scans at six months post-treatment allowed to "watch the UA-ADRCs at work". There was no relationship between treatment outcome and baseline data, including those data characterizing UA-ADRCs that can be collected with a clinical test.

Conclusions: The present study further supports treatment of sPTRCT with injection of UA-ADRCs.

Trial registration: Clinicaltrials.gov NCT04077190 (September 4, 2019).

Correspondence
David A. Pearce, PhD
Sanford Research
2301 E. 60th Street N.
Sioux Falls
SD 57104
USA
Phone: +1-605-312-6004
david.pearce@sanfordhealth.org

NOTE: This preprint reports new research that has not been certified by peer review and should not be used to guide clinical practice.

medRxiv preprint doi: https://doi.org/10.1101/2022.12.14.22283447; this version posted December 14, 2022. The copyright holder for this preprint (which was not certified by peer review) is the author/funder, who has granted medRxiv a license to display the preprint in perpetuity.

It is made available under a CC-BY 4.0 International license .

Abstract

Objective: Symptomatic, partial-thickness rotator cuff tears (sPTRCT) are problematic. Management of sPTRCT with fresh, uncultured, unmodified, autologous, adipose-derived regenerative cells (UA-ADRCs) isolated from lipoaspirate at the point of care is safe and leads to improved shoulder function without adverse effects. This study tested the hypothesis that management of sPTRCT with injection of UA-ADRCs is safe and more effective than injection of corticosteroid even in the long run.

Methods: Subjects who had completed a former randomized controlled trial were enrolled in the present study. At baseline these subjects had not responded to physical therapy treatments for at least six weeks, and were randomly assigned to receive respectively a single injection of an average 11.4×10^6 UA-ADRCs (n = 11) or a single injection of 80 mg of methylprednisolone (n = 5). Safety was assessed by rigorously documenting and evaluating treatment emergent adverse events. Efficacy was assessed using the ASES Total score, pain visual analogue scale (VAS) and RAND Short Form-36 Health Survey at 33.2 ± 1.0 (mean ± standard deviation) and 40.6 ± 1.9 months post-treatment. Proton density, fat-saturated, T2-weighted (PD FS T2), magnetic resonance imaging (MRI) of the index shoulder was performed at both study visits.

Results: There were no greater risks connected with injection of UA-ADRCs than those connected with injection of corticosteroid. The subjects in the UA-ADRCs group showed statistically significantly higher mean ASES Total scores than the subjects in the corticosteroid group. Treatment outcome could not be assessed using measurements of tear volume on MRI scans. On the other hand, PD FS T2 MRI scans at six months post-treatment allowed to "watch the UA-ADRCs at work". There was no relationship between treatment outcome and baseline data, including those data characterizing UA-ADRCs that can be collected with a clinical test.

Conclusions: The present study further supports treatment of sPTRCT with injection of UA-ADRCs.

Trial registration: Clinicaltrials.gov NCT04077190 (September 4, 2019).

Keywords UA-ADRCs; Safety; Shoulder disease; Stem cells; Stromal vascular fraction.

medRxiv preprint doi: https://doi.org/10.1101/2022.12.14.22283447; this version posted December 14, 2022. The copyright holder for this preprint (which was not certified by peer review) is the author/funder, who has granted medRxiv a license to display the preprint in perpetuity.

It is made available under a CC-BY 4.0 International license .

INTRODUCTION

Symptomatic, partial-thickness rotator cuff tear (sPTRCT) is a common cause of shoulder pain, loss of function and occupational disability [1-3]. Cadaveric and magnetic resonance imaging (MRI) studies reported the incidence of partial-thickness rotator cuff tears between 13% and 25%, with an increasing incidence with age [4-6]. The majority of sPTRCT cases are associated with aging, repetitive overhead use of the arm, sudden and forceful trauma, or a combination of these factors [1-3].

Current non-surgical and surgical treatment options to address sPTRCT do not offer the potential to naturally replace damaged tendon tissue and often do not improve clinical results. Subacromial injection of corticosteroids, among the most widely used nonoperative treatment options for sPTRCT [7], can provide short-term pain relief but may not modify the course of the disease [7]. Even worse, subacromial injection of corticosteroid bears the risk that a partial-thickness rotator cuff tear develops into a full-thickness rotator cuff tear [8]. A recent meta-analysis and a recent double-blinded, randomized controlled clinical trial (RCT) concluded that injections of platelet rich plasma might also not be beneficial in non-operative treatment of rotator cuff disease [9,10]. Surgical treatment of sPTRCT is generally successful among patients who, for a period of 3 to 6 months, unsuccessfully underwent conservative treatment modalities [2]. However, surgical intervention presents potential complications and a more lengthy recovery, and some authors have argued that results from these procedures may not exceed those obtained with conservative management [11].

A recent, first-in-human RCT [12] (hereafter: the former study) indicated that treatment of sPTRCT with fresh, uncultured, unmodified, autologous, adipose-derived regenerative cells (UA-ADRCs) isolated from lipoaspirate at the point of care is safe and leads to improved shoulder function without adverse effects. This study also showed that the risks associated with treating sPTRCT with UA-ADRCs were as low as those associated with injection of corticosteroid over 12 months post-treatment, with no serious adverse events observed for either treatment [12].

Unlike most other cell preparations currently under investigation for use in regenerative medicine (including cultured adipose derived stem cells (ADSCs), induced pluripotent stem cells, etc.) UA-ADRCs are not expanded in culture, and are therefore not exposed to potential, culture-related mechanic and oxidative stress that could affect their safety as a medicinal product [13]. Furthermore, UA-ADRCs do not share the risk of potentially developing tumors (reported for induced pluripotent stem cells) and immunological defensive reactions (reported for allogeneic adult stem cells) [14,15]. Only 0.001–0.1% of the total population of bone marrow nucleated cells represent mesenchymal stromal cells, whereas these cells can represent up to 12% of the total population of UA-ADRCs [16,17]. Additionally, harvesting adipose tissue is typically much less invasive than harvesting bone marrow [18].

A major limitation of the former study [12] was that subjects were not followed up beyond 12 months post-treatment. The present study tested the hypothesis that treatment of sPTRCT with injection of UA-ADRCs is safe and more effective than injection of corticosteroid even in the long run, with a minimum follow-up of 36 months.

METHODS

Study design

The present study was a long term follow-up study of a first-in-human, two center, prospective, open-label, randomized controlled trial [12]. Both the present study and the former study [12] were conducted at Sanford Orthopedics and Sports Medicine – Fargo (Fargo, ND, USA) (PI: M.L.) and Sanford Orthopedics and Sports Medicine – Sioux Falls (Sioux Falls, SD, USA) (principal investigator (PI): J.H.).

Fig. 1 shows the flow of subjects in the present study and the former study [12] according to the CONSORT statement [19].

Ethics

The former study [12] received Investigational Device Exemption (IDE) from the U.S. Food and Drug Administration (FDA) on September 23, 2016 (no. 16956), was registered at Clinicaltrials.gov on September 28, 2016 (ID NCT02918136), and received Institutional Review Board (IRB) approval of Sanford Health (Sioux Falls, SD, USA) on November 4, 2016 (Sanford IRB #3 registration number 00007985) in accordance with the Declaration of Helsinki. The first subject was enrolled in the former study [12] on January 04, 2017, and the last subject on April 21, 2017. The study was closed on November 7, 2019. After having received additional IRB approval from Sanford Health on November 07, 2019 (Sanford IRB #3 registration number STUDY00001869) to re-examine MRI scans, the former study [12] was re-opened on September 14, 2020.

The present study received IDE from the FDA on May 13, 2019, received IRB approval from WIRB Copernicus Group, Inc. (Olympia, WA, USA) on July 23, 2019 for study site Sanford USD Medical Center, Sioux Falls, SD, USA and on September 29, 29 for study site Sanford Orthopedic Sports Medicine Clinic, Fargo, ND, USA (IRB Tracking Number: 20191931), and was registered at Clinicaltrials.gov on September 4, 2019 (NCT04077190). The first subject was enrolled in the present study on November 21, 2019, and the last subject on March 20, 2020. The present study was closed on May 09, 2022.

medRxiv preprint doi: https://doi.org/10.1101/2022.12.14.22283447; this version posted December 14, 2022. The copyright holder for this preprint (which was not certified by peer review) is the author/funder, who has granted medRxiv a license to display the preprint in perpetuity.

It is made available under a CC-BY 4.0 International license .

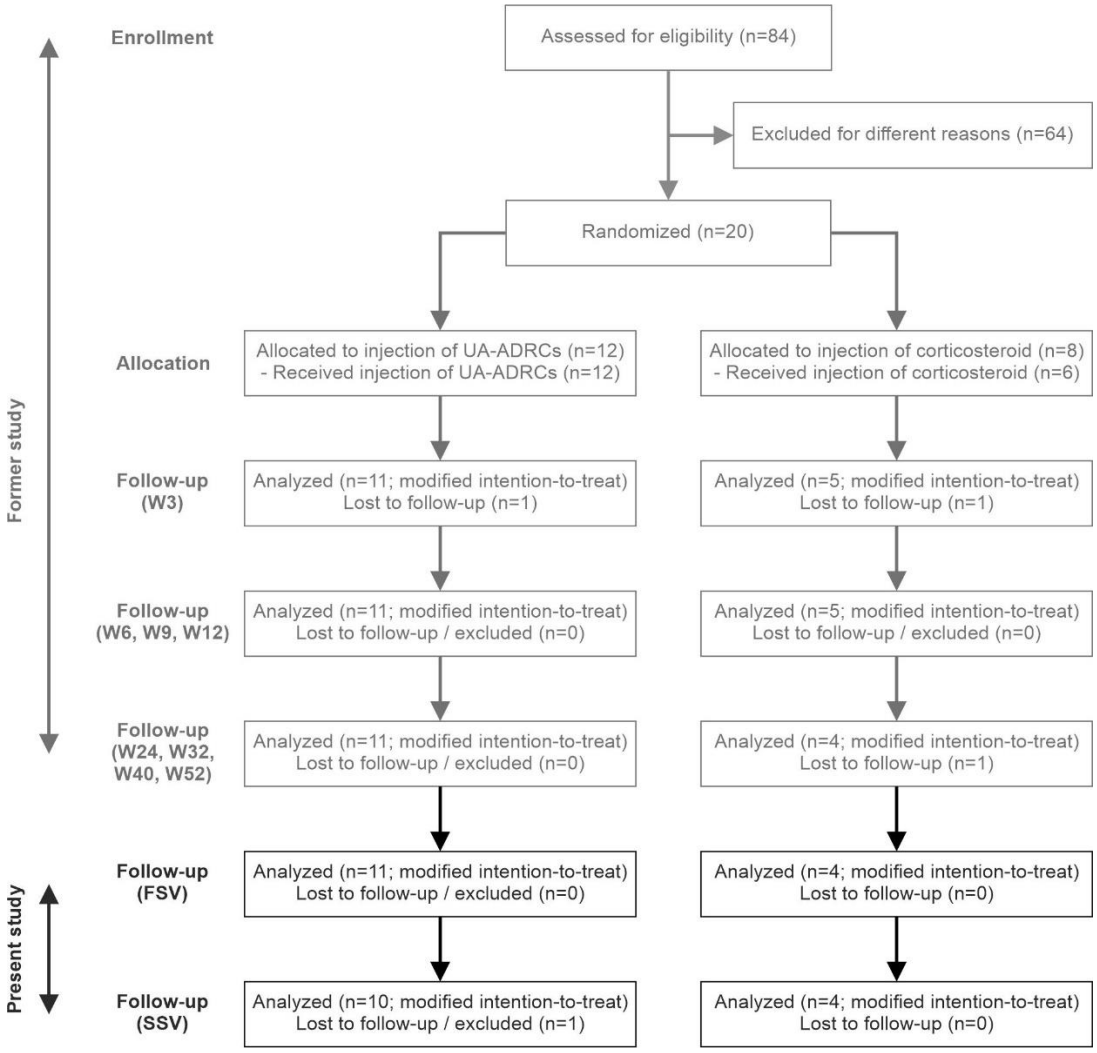

FIGURE 1. Flow of subjects in the present study and the former study [12] according to CONSORT [19]. Abbreviations: W3 / W6 / W9 / W12 / W24 / W32 / W40 / W52, study visits scheduled in the former study [12] at 3 / 6 / 9 / 12 / 24 / 32 / 40 / 52 weeks post-treatment; FSV, first study visit of the present study at 33.2 ± 1.0 (mean ± standard deviation) months post-treatment; SSV, second study visit of the present study at 40.6 ± 1.9 months post-treatment.

Participants, randomization and interventions

In brief, all the subjects enrolled in the former study [12] suffered from a sPTRCT of the supraspinatus tendon at baseline, had not responded to physical therapy treatments for at least six weeks, and were randomly assigned to receive respectively a single injection of an average 11.4×10^6 UA-ADRCs (in 5 mL liquid; mean cell viability: 88%) (n=11; modified intention-to-treat (mITT) population) (hereafter: UA-ADRCs group) or a single injection of 80 mg of methylprednisolone (40 mg/mL; 2 mL) plus 3 mL of 0.25% bupivacaine (n=5 in the former study [12]; n=4 in the present study; mITT population) (hereafter: corticosteroid group). The UA-ADRCs were isolated from lipoaspirate using the Transpose RT system (InGeneron) [15,20]. One subject in the corticosteroid group experienced progression of sPTRCT into a symptomatic, full-thickness rotator cuff tear during the former study [12] and was therefore not enrolled in the present study. For this reason, the baseline data of the subjects in the corticosteroid group enrolled in the present study (summarized in Table 1) slightly differ from the baseline data of those in the corticosteroid group provided in the former study [12].

medRxiv preprint doi: https://doi.org/10.1101/2022.12.14.22283447; this version posted December 14, 2022. The copyright holder for this preprint (which was not certified by peer review) is the author/funder, who has granted medRxiv a license to display the preprint in perpetuity.

It is made available under a CC-BY 4.0 International license .

TABLE 1

Characteristics of the subjects enrolled in the present study at baseline (modified intention-to-treat population).

Variable	UA-ADRCs group (n=11)	Corticosteroid group (n=4)
Age, years, median; mean (SD; min; max)	64.6; 62.3 (9.6; 40; 74)	59.0; 56.8 (7.6; 46; 63)
Woman, n (%)	3 (27.3)	0 (0)
Body weight, kg, median; mean (SD; min; max)	93.9; 88.6 (18.1; 51.6; 111.1)	113.9; 109.9 (25.7; 74.5; 133.7)
Body height, cm, median; mean (SD; min; max)	178; 176 (8.8; 157; 188)	178; 178 (4.8; 173; 185)
Body mass index, kg/m^2, median; mean (SD; min; max)	29.9; 28.4 (4.1; 20.8; 33.3)	35.7; 34.3 (7.9; 23.4; 42.3)
Affected shoulder, right (%)	9 (81.8)	2 (50.0)
ASES Total score, median; mean (SD; min; max)	56.7; 58.7 (19.2; 30; 92)	46.7; 47.1 (14.6; 30; 65)
VAS pain score, median; mean (SD; min; max)	5; 4.7 (2.8; 0; 8)	6; 5.8 (2.1; 3; 8)
SF-36 Total score, median; mean (SD; min; max)	604; 557 (134; 270; 695)	565; 547 (83; 432; 627)
Tear volume, mm^3, median; mean (SD; min; max)	47.3; 58.6 (37.4; 19.8; 128.9)	27.0; 25.1 (8.3; 14.6; 31.7)

Abbreviations: SD, standard deviation; min, minimum value; max, maximum value; VAS, visual analog scale; ASES, American Shoulder and Elbow Surgeons Standardized Shoulder Assessment Form [21]; VAS, visual analogue scale; SF-36, RAND Short Form-36 Health Survey [22].

Outcome measurements and assessments

According to the study protocol the primary endpoints of the present study were long-term safety as indicated through the rate of treatment emergent adverse events (TEAEs), and long-term efficacy of pain and function through American Shoulder and Elbow Surgeons Standardized Shoulder Assessment Form [21] (ASES Total score) and RAND Short Form-36 [22] (SF-36) health questionnaires between the UA-ADRCs group and the corticosteroid group. The secondary endpoint of the present study was long-term efficacy evaluated through MRI pre- and post-injection for the therapeutic intent to treat sPTRCT between the UA-ADRCs group and the corticosteroid group.

Adverse events in the present study and the former study [12] were defined as any untoward or unfavorable medical occurrence in a subject, including any abnormal sign, symptom or disease temporally associated with the subject's participation in these studies, whether or not considered related to the subject's participation in these studies.

In the former study [12], safety was assessed immediately after treatment and three weeks (W3), W6, W9, W12, W24, W32, W40 and W52 post-treatment; ASES Total score and SF-36 Total score were assessed at baseline (BL) and at W3, W6, W9, W12, W24, W32, W40 and W52 post-treatment; MRI was performed at BL and at W24 and W52 post-treatment.

In the present study, the primary and secondary endpoints were assessed at 33.2 ± 1.0 (mean ± standard deviation) months post-treatment (range, 30.7 – 34.7) (first study visit; FSV) and at 40.6 ± 1.9 months post-treatment (range, 36.5 – 44.7) (second study visit; SSV).

Analysis of MRI scans

Next to the determination of the partial-thickness tear size (calculated as ellipsoid volume), the proton density weighted, fat saturated, T2-weighted (PD FS T2) coronal MRI scans of all subjects who were enrolled in the present study were transferred in digital and fully anonymized form (compliant with the HIPAA regulation) [23] to C.S. who was only aware of the Subject IDs. Then, C.S. mounted these MRI scans as shown in Figs S1-S15 (**Figs S1-S21 and Tables S1-S21 are in the Appendix**), evaluated them and indicated hyperintense structures at the position of the supraspinatus tendon that were present at W24 post-treatment but not at baseline (yellow arrows in Figs S1-S7 and S9-S11). Afterwards, the files with the MRI scan montages and the indicated hyperintense structures were transferred in fully anonymized form (even without the Subject IDs) to M.H. and M.H., who performed an independent, blinded re-analysis of the hyperintense structures at the position of the supraspinatus tendon indicated by C.S.

Statistical analysis

Statistical analysis of the safety data included group-specific comparisons of the following variables: (i) total number of TEAEs, (ii) number of TEAEs experienced per subject, (iii) number of TEAEs classified as {mild / moderate / severe}, (iv) relationship of TEAEs to treatment classified as {not related / unlikely / possible / probable / definite} and (v) number of TEAEs classified as {mild and unlikely to be related to the investigated treatment / mild and possibly related to the investigated treatment / moderate and unlikely to be related to the investigated treatment / moderate and possibly related to the investigated treatment}. According to the protocol of the present study these comparisons were performed for the following time periods: from BL to W24 post-treatment (considering only data of the former study [12]), from BL to FSV in the present study, and from BL to SSV in the present study (each considering data of the present study and the former study [12]). Comparisons were performed using respectively Chi-square test or Chi-square test for trend.

Mean and standard error of the mean (SEM) of the ASES Total score, VAS pain score, SF-36 Total score and partial-thickness tear size were calculated. These calculations considered the data from all subjects enrolled in the former study [12] (i.e., n=11 in the UA-ADRCs group and n=5 in the corticosteroid group); missing data were imputed using the Last Observation Carried Forward (LOCF) approach [24]. Differences between the groups were tested using two-way repeated measures ANOVA, with subject-specific values obtained at BL, W24 and W52 post-treatment (data of the former study [12]) as well as at FSV and SSV (data of the present study) as matched data; values obtained during the

medRxiv preprint doi: https://doi.org/10.1101/2022.12.14.22283447; this version posted December 14, 2022. The copyright holder for this preprint (which was not certified by peer review) is the author/funder, who has granted medRxiv a license to display the preprint in perpetuity.

It is made available under a CC-BY 4.0 International license .

former study [12] at W3, W6, W9, W12, W32 and W40 post-treatment were not considered in the statistical analysis (as in the former study [12]). *Post hoc* Bonferroni tests were used for pairwise comparisons.

In all analyses, a p value < 0.05 was considered statistically significant. Calculations were performed using GraphPad Prism (Version 9.4.1 for Windows; GraphPad Software, San Diego, CA, USA).

RESULTS

Long-term safety of treating sPTRCT with injection of respectively UA-ADRCs or corticosteroid

The subjects in the UA-ADRCs group reported a total number of 58 TEAEs (35 TEAEs during the former study [12] and 23 TEAEs during the present study) (details in Table S1). The subjects in the corticosteroid group reported a total number of 25 TEAEs (12 TEAEs during the former study [12] and 13 TEAEs during the present study) (details in Table S2).

No TEAE that occurred during the present study and the former study [12] was classified as probably or definitely related to the investigated treatment. Furthermore, all severe TEAEs that occurred during the present study and the former study [12] were classified as not related to the investigated treatment.

All subjects reported experiencing at least one TEAE. The number of subjects who experienced 1 / 2 / 3 / 4 / 6 / 7 / 8 / 10 / 12 TEAEs in the present study and the former study [12] was 1 / 0 / 2 / 3 / 1 / 1 / 2 / 1 / 0 in the UA-ADRCs group (5.3 ± 2.7; median, 4) and 0 / 1 / 1 / 2 / 0 / 0 / 0 / 0 / 1 in the corticosteroid group (5.0 ± 1.8 (mean ± SEM); median, 4). These data were not significantly different between the groups (Chi-square test for trend; p = 0.778) (details in Table S3).

The number of TEAEs classified as {mild / moderate / severe} in the present study and the former study [12] was 38 / 16 / 4 in the UA-ADRCs group and 17 / 8 / 0 in the corticosteroid group. These data were not significantly different between the groups (Chi-square test for trend; p = 0.497) (details in Tables S4-S6).

The relationship of TEAEs to treatment classified as {not related / unlikely / possible / probable / definite} in the present study and the former study [12] was 48 / 6 / 4 / 0 / 0 in the UA-ADRCs group and 20 / 3 / 2 / 0 / 0 in the corticosteroid group. These data were not significantly different between the groups (Chi-square test; p = 0.956) (details in Tables S7-S9).

The number of TEAEs classified as {mild and unlikely to be related to the investigated treatment / mild and possibly related to the investigated treatment / moderate and unlikely to be related to the investigated treatment / moderate and possibly related to the investigated treatment} in the present study and the former study [12] was 4 / 3 / 2 /1 in the UA-ADRCs group and 3 / 0 / 0 / 2 in the corticosteroid group. These data were not significantly different between the groups (Chi-square test for trend; p = 0.757) (details in Table S10).

The four severe TEAEs that occurred in the UA-ADRCs group during the present study and the former study [12] were non ST elevation myocardial infarction, ST elevation myocardial infarction, ganglion cyst of the non-index shoulder, and pain in the index shoulder. None of these severe TEAEs were related to treatment (details in Tables S11-S13).

Long-term efficacy of treating sPTRCT with injection of respectively UA-ADRCs or corticosteroid

Four of the 11 subjects (36.4%) in the UA-ADRCs group and three of the five subjects (60.0%) in the corticosteroid group developed additional pathologies of the index shoulder (next to sPTRCT) and/or received additional treatments on the index shoulder (next to injection of respectively UA-ADRCs or corticosteroid) during the present or the former study [12]. In none of the 11 subjects (0%) in the UA-ADRCs group and two of the five subjects (40%) in the corticosteroid group these additional pathologies were considered treatment failure (details in Tables S14 and S15). After these events, individual data related to the efficacy of the investigated treatment were either missing or, if they had been collected after the event during the present study or the former study [12], unsuitable for assessing treatment outcome. These missing data were imputed using the LOCF approach [24].

The individual ASES Total scores, VAS pain scores and SF-36 Total scores as a function of time post-treatment are shown in Figs S16-S18; imputation of missing data is indicated in these figures. Eight of the 11 subjects (72.7%) in the UA-ADRCs group but only one of the five subjects (20%) in the corticosteroid group reached an individual ASES Total score of 90 at any time of the present study and the former study [12]. An ASES Total score of 100 (representing no pain and maximum function) was reached by five of the 11 subjects (45.5%) in the UA-ADRCs group but none of the five subjects (0%) in the corticosteroid group at any time of the present study and the former study [12].

Two-way repeated measures ANOVA showed significant improvement of the mean ASES Total score and the mean VAS pain score (but not the mean SF-36 Total score) over time, as well as a significant difference between the groups with respect to the mean ASES Total score (Fig. 2 and Tables S16-S18). Bonferroni's multiple comparisons test demonstrated that the subjects in the UA-ADRCs group had a significantly higher mean ASES Total score than the subjects in the corticosteroid group at 52 weeks post treatment (Table S16).

medRxiv preprint doi: https://doi.org/10.1101/2022.12.14.22283447; this version posted December 14, 2022. The copyright holder for this preprint **(which was not certified by peer review)** is the author/funder, who has granted medRxiv a license to display the preprint in perpetuity.

It is made available under a CC-BY 4.0 International license .

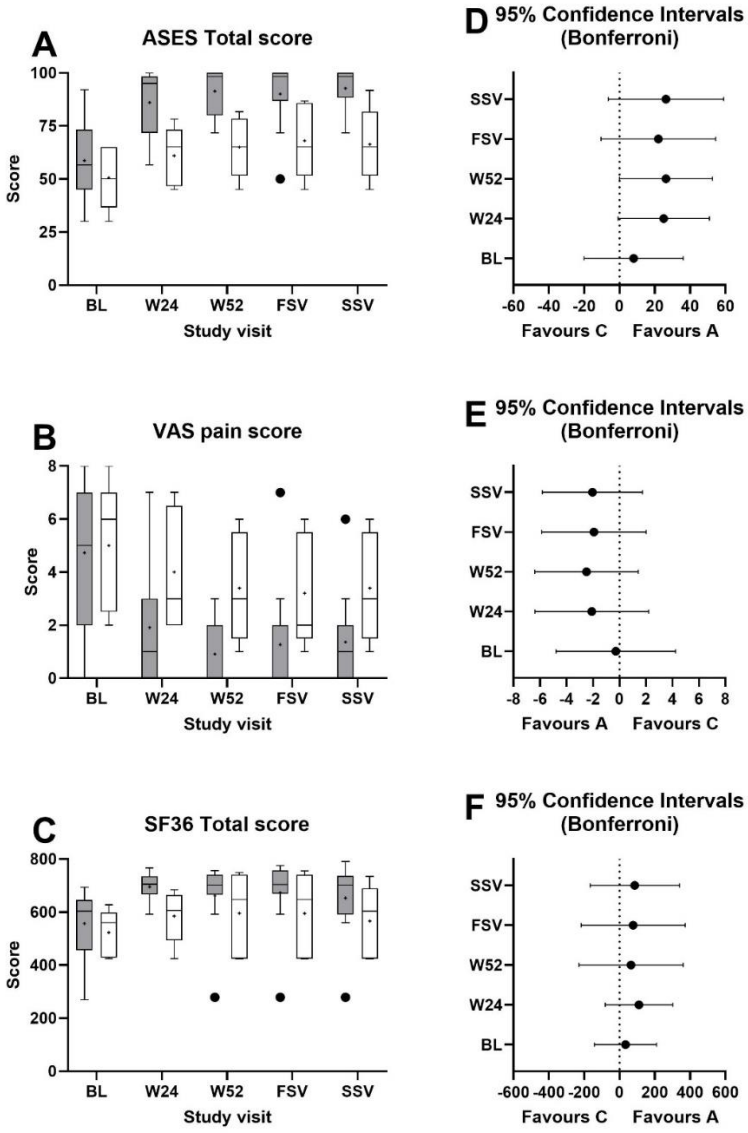

FIGURE 2. Tukey boxplots of (A) ASES Total score, (B) VAS pain score (collected together with the ASES score) and (C) SF-36 Total score of subjects treated with injection of respectively UA-ADRCs (gray bars) or corticosteroid (open bars) (imputation of missing data performed using the Last Observation Carried Forward approach). The corresponding 95% confidence intervals are shown in (D-F). Abbreviations: W24 / W52, study visits scheduled in the former study [12] at 24 and 52 weeks post-treatment; FSV, first study visit of the present study; SSV, second study visit of the present study; A, injection of UA-ADRCs; C, injection of corticosteroid.

Partial thickness rotator cuff tear size as a function of time after treatment with injection of respectively UA-ADRCs or corticosteroid

The individual tear size as a function of time post-treatment is shown in Fig. S19; imputation of missing data is indicated in this figure. Two-way repeated measures ANOVA showed no significant change in the mean tear size over time, as well as no significant difference between the groups (Fig. 3 and Table S19).

medRxiv preprint doi: https://doi.org/10.1101/2022.12.14.22283447; this version posted December 14, 2022. The copyright holder for this preprint (which was not certified by peer review) is the author/funder, who has granted medRxiv a license to display the preprint in perpetuity.

It is made available under a CC-BY 4.0 International license .

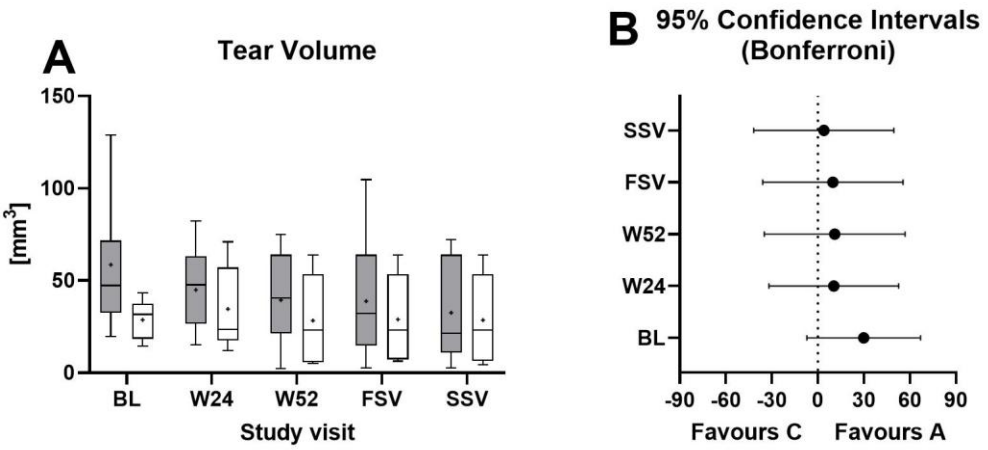

FIGURE 3. (A) Tukey boxplots of the tear volume measured on MRIs of subjects treated with injection of respectively UA-ADRCs (gray bars) or corticosteroid (open bars) (imputation of missing data performed using the Last Observation Carried Forward approach). The corresponding 95% confidence intervals are shown in (B). Abbreviations: W24 / W52, study visits scheduled in the former study [12] at 24 and 52 weeks post-treatment; FSV, first study visit of the present study; SSV, second study visit of the present study; A, injection of UA-ADRCs; C, injection of corticosteroid.

Detection of hyperintense structures on PD FS T2 coronal MRI scans of the index shoulder at the position of the supraspinatus tendon after injection of UA-ADRCs, but not after injection of corticosteroid, at 24 weeks post-treatment but not at baseline

The PD FS T2 coronal MRI scans of the index shoulder of 10 of 11 subjects (90.9%) in the UA-ADRCs group and none of the subjects (0%) in the corticosteroid group showed hyperintense structures at the position of the supraspinatus tendon at 24 weeks post-treatment but not at baseline. A representative example is shown in Fig. 4; all PD FS T2 coronal MRI scans of Subjects A1-A11 (injection of UA-ADRCs) and Subjects C1-C4 (injection of corticosteroid) are provided in Figs S1-S15. No MRI scans of Subject C5 are shown because this subject was not enrolled in the present study, and the study protocol did not allow to re-assess the MRI scans of this subject generated during the former study [12].

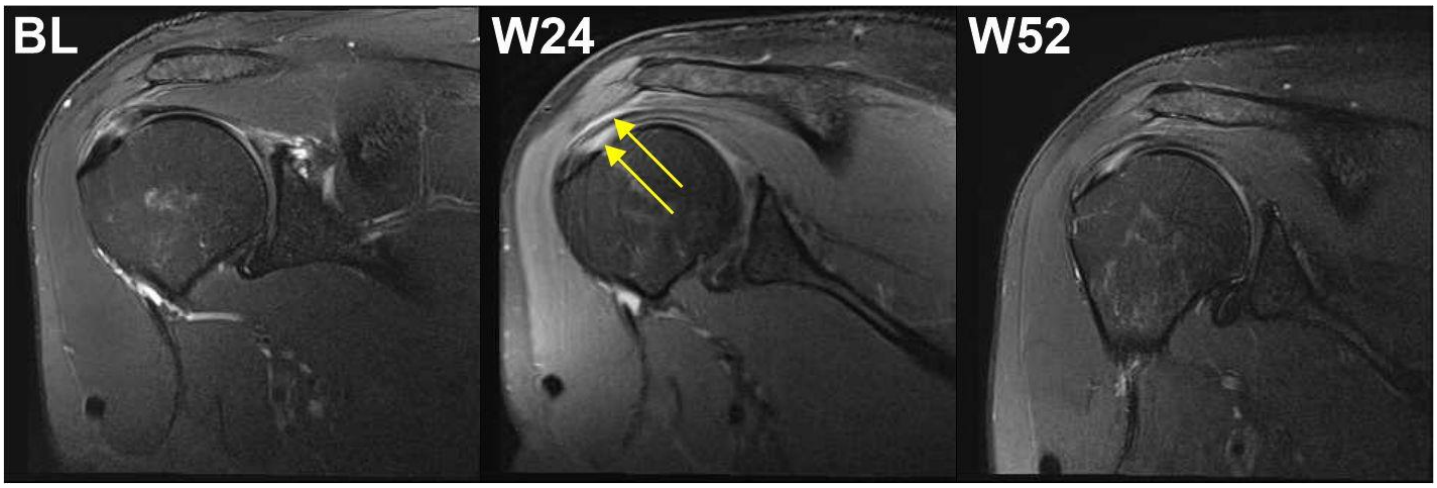

FIGURE 4. Proton density weighted, fat saturated, T2-weighted, coronal MRI scans of the index shoulder of Subject A4 (injection of UA-ADRCs), showing hyperintense structures at the position of the supraspinatus tendon at 24 weeks post-treatment (yellow arrows) but not at baseline. Abbreviations: BL, baseline; W24 / W52, study visits scheduled in the former study [12] at 24 and 52 weeks post-treatment.

No relationship between treatment outcome and baseline data

Supplementary Figures 22 and 23 show individual ASES Total scores as a function of time post-treatment together with individual data at baseline (ASES Total score, tear volume, age and body mass index, as well as (in case of subjects who were treated with injection of UA-ADRCs) cell yield and cell viability. No relationship between treatment outcome and

medRxiv preprint doi: https://doi.org/10.1101/2022.12.14.22283447; this version posted December 14, 2022. The copyright holder for this preprint (which was not certified by peer review) is the author/funder, who has granted medRxiv a license to display the preprint in perpetuity.

It is made available under a CC-BY 4.0 International license .

baseline data was found, including those data characterizing UA-ADRCs that can be collected with a clinical test.

DISCUSSION

To assess the relevance of the results of the present study in accordance with the current state of knowledge, Table 2 summarizes the essential details of all previously published clinical studies on the management of partial-thickness and full-thickness rotator cuff tears with stem cells [12,25-33]. In most of these studies, stem cells were applied to improve the outcome of surgical treatment. Furthermore, next to the former study [12], treatment of partial-thickness rotator cuff tears was only investigated in three other studies [30-32], and only three other studies were randomized controlled trials [28,32,33]. The mean number of subjects treated with stem cells in the studies listed in Table 2 (excluding the former study [12]) was 19.1 ± 5.0 (mean ± SEM) (median, 13.5; range, 7-45).

TABLE 2. Essential details of all published clinical studies on the management of rotator cuff tears with stem cells.

Reference	[25]	[26]	[27]	[28]	[29]	[30,31*]	[12]	[32]	[33]
Year of publication	2012	2014	2015	2016	2017	2018	2020	2022	2022
RCT	No	No	No	Yes	No	No	Yes	Yes	Yes
n (SCs / C)	14 / -	45 / -	8 / -	8 / 5	35 / 35	13 / 3+3	11 / 5	7 / 8	23 / 23
Tear type	n.s.	F	F	F	F	P	P	P	F
Only SCs	No	No	No	No	No	Yes	Yes	Yes	No
Type of SCs	BM	BM	BM	BM	UA-ADRCs	ADSCs	UA-ADRCs	ADSCs	MFF
Autologous SCs	Yes	Yes	Yes	Yes	Yes	Yes	Yes	No	Yes
Surgery adjunct	Yes	Yes	Yes	Yes	Yes	No	No	No	Yes
Arthroscopy	n/a	n/a	n/a	n/a	n/a	Yes	No	No	n/a
Stat Plan	No	Yes (b)	No	Yes (w)	Yes (b/w)	Yes (b)	Yes (b/w)	Yes (b/w)	Yes (b/w)
Follow-up	M12	M120	M6	M12	M28**	M6 / M24	M12	M24	M24
Outcome	n/a	n/a	n/a	***	No	n/a	Yes	No	Yes

Abbreviations: RCT, randomized controlled trial; n, number of subjects; SCs, stem cells; C, control treatment; n.s., not specified; F, full-thickness rotator cuff tears; P, partial-thickness rotator cuff tears; BM, bone marrow-derived mesenchymal stem cells; UA-ADRCs, fresh, uncultured, unmodified, autologous, adipose-derived regenerative cells; ADSCs, cultured adipose-derived stem cells; MFF, microfragmented fat; n/a, not applicable; Stat Plan, statistical analysis of differences between (b) and/or within (w) the groups to assess the therapeutic outcome achieved; M12 / M120 / M6 / M29 / M24, 12 / 120 / 6 / 29 / 24 months post-treatment; *, M24 follow-up study of [24]; **, 28.3 ± 3.8 months in the injection group and 28.8 ± 4.2 months in the conventional group; ***, this study was stopped due to adverse effects observed in both groups; most probably the reason was the use of a xenogenic scaffold (OrthADAPT Boimplant; Synovis Orthopedic & Woundcare Inc., Irvine, CA, USA) in both groups.

With respect to the long-term safety we evidenced that treatment of sPTRCT with injection of UA-ADRCs did not result in serious adverse events by 40.6 ± 1.9 months post-treatment. There were no greater risks connected with injection of UA-ADRCs than those connected with injection of corticosteroid in treatment of sPTRCT. In summary, the results of the present study suggest that the use of UA-ADRCs in subjects with sPTRCT is safe. The only other study listed in Table 2 (excluding the former study [12]) in which UA-ADRCs were applied [29] did not address the safety of the procedure.

Regarding the long-term efficacy we evidenced that the subjects in the UA-ADRCs group had significantly higher mean ASES total scores than the subjects in the corticosteroid group, with $p < 0.05$ in *post hoc* Bonferroni test at 52 weeks post-treatment (Table S16). This finding was in line with the finding of the former study [12] that treatment of sPTRCT with injection of UA-ADRCs leads to improved shoulder function. We hypothesize that the negative outcome (i.e., $p > 0.05$) of the *post hoc* Bonferroni test at the times of the first and second study visits of the present study was consequent to the small sample size. Using an adequate sample size of n=246 subjects an ongoing pivotal clinical trial is currently testing the hypothesis that treatment of sPTRCT with injection of UA-ADRCs is more effective than treatment of sPTRCT with injection of corticosteroid [34].

We would like to point to the following, additional results of the present study and the former study [12]: (i) The results obtained in the former study [12] after treatment of sPTRCT with injection of corticosteroid were in line with other studies which investigated the efficacy of treating sPTRCT with injection of corticosteroid [35-39] (details in Tables S20 and S21). (ii) Six subjects in the UA-ADRCs group but no subject in the corticosteroid group reached an ASES Total score of 100 over time after treatment (Fig. S16). Among these six subjects in the UA-ADRCs group, five reported an ASES Total score of 100 both at the end of the former study [12] and throughout the present study (Fig. S16). (iii) One subject in the corticosteroid group (Subject C5 in Figs S16-S18) developed a full thickness tear during the former study [12], and another subject in the corticosteroid group (Subject C4 in Figs S16-S18) developed pain in the index shoulder at 1.4 months post-treatment and was treated with another injection of corticosteroid at 7.4 months post-treatment during the former study [12]. In contrast, except for one subject in the UA-ADRCs group (Subject A9 in Figs S16-S18) who reported

medRxiv preprint doi: https://doi.org/10.1101/2022.12.14.22283447; this version posted December 14, 2022. The copyright holder for this preprint (which was not certified by peer review) is the author/funder, who has granted medRxiv a license to display the preprint in perpetuity.

It is made available under a CC-BY 4.0 International license .

an accident with involvement of the index shoulder at 1.0 months post-treatment, no subject in the UA-ADRCs group required additional treatment of the index shoulder during the former study [12]. (iv) No subject in the UA-ADRCs group required additional treatment during the present study because of failure of the initial index treatment. In summary, these results reinforce the general need to individually examine the clinical course after an initial treatment, and to identify all possible interfering influences that could have negatively impacted the success of the therapy under study. Furthermore, these results support our hypothesis that treatment of UA-ADRCs with injection of sPTRCT is effective, and is more effective than treatment of sPTRCT with injection of corticosteroid.

The only other published study to date that investigated treatment of sPTRCT with injection of stem cells without surgery found no benefit of injection of cultured adipose-derived stem cells (ADSCs) for 24 months post-treatment, and the results obtained after injection of ADSCs did not differ from the results obtained after injection of saline [32]. This negative result could have been caused by at least three circumstances: (i) the use of allogeneic cells, with the possible inability of new cells derived from the stem cells to integrate into the host tissue because of immunological incompatibility [14]; (ii) the need for culturing the cells, with the possible reduction of the life span of the cells by shortening the telomeres following repetitive cell divisions, and possible negative effects on the safety of the cells as a medicinal product [13]; and (iii) the selection of a single cell type, with the consequence of limited functionality of the cells [14,40]. All this is prevented by the use of fresh UA-ADRCs in the present study and the former study [12], and may explain the discrepancy between the negative result in [32] and the positive results in the present study and the former study [12].

It is beyond the scope of the present study to provide a comprehensive explanation why selection of stem cells (i.e., the use of cultured ADSCs or cultured MSCs in general) is inferior to the use of fresh UA-ADRCs in treatment of musculoskeletal pathologies. Here we report just three of the most important reasons: (i) unlike cultured ADSCs, fresh UA-ADRCs express those growth factors that are needed to stimulate cultured ADSCs towards tenogenic differentiation in culture [41]; (ii) these growth factors are expressed by M2 macrophages [42-45], and M2 macrophages are contained in the UA-ADRCs used in the present study and the former study [12,20], but are missing in any cultured stem cells; and (iii) M2 macrophages are mainly involved in anti-inflammatory responses [46,47], and the presence of M2 macrophages in UA-ADRCs may explain the very early treatment success observed after treating sPTRCT with UA-ADRCs in the former study [12], which cannot be explained by the formation of new tendon tissue (Fig. S16). In summary, there are a number of possible explanations of the discrepancy between the negative result in [32] and the positive results in the present study and the former study [12] with respect to treatment of sPTRCT with injection of stem cells.

Regarding the analysis of MRIs pre- and post-injection, we found no significant improvement of the mean tear volume over time, nor any significant difference between the results obtained after injection of UA-ADRCs and those obtained after injection of corticosteroid (Table S18). Of note, these findings are not in line with the results related to the long term efficacy (improvement in ASES Total score) outlined above. The main reason for this discrepancy may be the mechanisms of action of UA-ADRCs in tendon repair. Initially one could assume that UA-ADRCs would mainly fill the gap in the tendon tissue caused by a partial-thickness tear. However, the location of the hyperintense structures in PD FS T2 MRI scans at the position of the supraspinatus tendon present at 24 weeks post-treatment but not at baseline in 10 of the 11 subjects in the UA-ADRCs group (Figs S1-S11) and none of the subjects in the corticosteroid group (Figs S12-S15) indicate that this may not be the case. Rather, these hyperintense structures in PD FS T2 MRI scans may indicate formation of new tendon tissue following injection of UA-ADRCs in a different location than the original tear, possibly primarily following individual biomechanical requirements. This may explain why subjects who are suffering from sPTRCT experience fast (the former study [12]) and lasting (present study) recovery from pain and impaired function without disappearance of the rotator cuff tears on MRI scans even at 40 months post-treatment.

The presence of hyperintense structures in PD FS T2 MRI scans at the position of a tendon with partial-thickness tear a few months after injection of UA-ADRCs has only been reported in a recent single case report [48]. Without additional investigations, it is unclear whether these hyperintense structures in PD FS T2 MRI scans indeed represent formation of new tendon tissue. These investigations must be performed on biopsies of tendons with partial-thickness tear that were treated with injection of UA-ADRCs. On the other hand, there are two indications supporting the hypothesis that these hyperintense structures in PD FS T2 MRI scans indeed represent formation of new tendon tissue: (i) the analysis of the biopsy reported the recent case report [48] indicated newly formed tendon tissue which did not resemble scar tissue (the biopsy was taken at the position of the hyperintense structure found in the corresponding MRI scans ten weeks post-treatment); and (ii) this biopsy showed a dense network of newly formed microvessels next to the position of newly formed tendon tissue [48]. Blood flow in these newly formed microvessels may indeed explain the occurrence of hyperintense structures in PD FS T2 MRI scans after treatment of sPTRCT with injection of UA-ADRCs. Furthermore, the full or partial disappearance of these hyperintense structures in PD FS T2 MRI scans at 52 weeks post-treatment (Figs S1-S10) may indicate that tendon regeneration was complete, or almost complete, at this time.

In summary, the results of the present study indicate that treatment success after treating sPTRCT with UA-ADRCs cannot be assessed using measurements of tear volume on MRI scans. On the other hand, PD FS T2 MRI scans taken a

medRxiv preprint doi: https://doi.org/10.1101/2022.12.14.22283447; this version posted December 14, 2022. The copyright holder for this preprint (which was not certified by peer review) is the author/funder, who has granted medRxiv a license to display the preprint in perpetuity.

It is made available under a CC-BY 4.0 International license .

few months after treatment of sPTRCT with injection of UA-ADRCs may allow to "watch the UA-ADRCs at work". The latter finding may inform researchers about optimal times for taking biopsies in future research into the mechanisms of action of UA-ADRCs in tendon repair.

Based on the outcome of the analysis shown in Fig. S20 we hypothesize that individual treatment success after treating sPTRCT with injection of UA-ADRCs cannot be predicted based on the following, individual values at baseline: ASES Total score, tear volume, age and BMI, as well as on the cell yield and cell viability of the final cell suspension. This finding is important because it may render individual bedside testing of the final cell suspension in clinical use of UA-ADRCs irrelevant.

It is currently unknown whether individual treatment success after treating sPTRCT with injection of UA-ADRCs can be predicted using the colony forming unit (CFU) assay [15] and/or determination of cell surface markers using fluorescence-activated cell scanning [20]. In any case, these analyses take between several days (determination of surface markers) and more than two weeks (CFU assay). Thus, they are not suitable for clinical testing of the final cell suspension in clinical use of UA-ADRCs.

Limitations

The limitations of the present study are the same as the limitations of the former study [12]: only a small sample of subjects suffering from sPTRCT was investigated, only a limited number of clinical examination methods was applied, no power analysis was carried out, and neither the subjects nor the physicians who performed treatment and the assessors who performed baseline and follow-up examinations were blinded (only the physicians who analyzed the MRI scans were blinded). We believe that the ongoing clinical trial [21] will demonstrate with sufficient statistical power that treatment of sPTRCT with injection of UA-ADRCs is more effective than treatment of sPTRCT with injection of corticosteroid.

Conclusions

The present investigation further supports treatment of sPTRCT with injection of UA-ADRCs. Once this therapy is approved in the US, clinicians should consider injection of UA-ADRCs instead of injection of corticosteroids. In the long run treatment of sPTRCT with injection of UA-ADRCs may delay or even prevent surgical treatment of sPTRCT.

Funding

This study did not receive external funding.

Availability of data and materials

The datasets used and analyzed during the current study are available from the corresponding author on reasonable request, taking into account any confidentiality.

Authors' contributions

Mark Lundeen	Methodology, Investigation, Resources, Writing – Review & Editing,
Jason l. Hurd	Methodology, Investigation, Resources, Writing – Review & Editing,
Matthew Hayes	Methodology, Validation, Investigation, Resources, Writing – Review & Editing,
Meredith Hayes	Methodology, Validation, Investigation, Resources, Writing – Review & Editing,
Tiffany R. Facile	Conceptualization, Methodology, Resources, Data curation, Writing – Review & Editing, Project administration
John P. Furia	Writing – Review & Editing
Nicola Maffulli	Writing – Review & Editing
Christopher Alt	Conceptualization, Methodology, Validation, Formal analysis, Data curation, Writing – Review & Editing,
Eckhard U. Alt	Conceptualization, Methodology, Validation, Resources, Writing – Review & Editing, Supervision, Project administration, Funding acquisition
Christoph Schmitz	Conceptualization, Methodology, Formal analysis, Resources, Data curation, Writing – Original Draft, Visualization,
David A. Pearce	Conceptualization, Methodology, Resources, Data curation, Writing – Review & Editing, Supervision, Project administration, Funding acquisition

Consent for publication

We have obtained consent for publication.

Competing interests

C.A. is Director of Medical and Scientific Affairs of InGeneron, Inc. (Houston, TX, USA). E.U.A. is Executive Chair of InGeneron. C.S. is Advisory Medical Director of InGeneron. However, InGeneron had no role in study design, data collection and analysis, interpretation of the data, and no role in the decision to publish and write this manuscript. No other potential conflicts of interest relevant to this article were reported.

References

1. Matava MJ, Purcell DB, Rudzki JR. Partial-thickness rotator cuff tears. Am J Sports Med. 2005;33:1405-17.
2. Matthewson G, Beach CJ, Nelson AA, Woodmass JM, Ono Y, Boorman RS, et al. Partial thickness rotator cuff tears: current concepts. Adv Orthop. 2015;2015:458786.
3. Via AG, De Cupis M, Spoliti M, Oliva F. Clinical and biological aspects of rotator cuff tears. Muscles Ligaments Tendons J. 2013;3:70-9.
4. Cotton RE, Rideout DF. Tears of the humeral rotator cuff. J Bone Joint Surg. 1964;46:314-28.
5. Fukuda H. Partial-thickness rotator cuff tears: a modern view on Codman's classic. J Shoulder Elbow Surg. 2000;9:163-8.
6. Sher JS, Uribe JW, Posada A, Murphy BJ, Zlatkin MB. Abnormal findings on magnetic resonance images of asymptomatic shoulders. J Bone Joint Surg Am. 1995;77:10-5.
7. Coombes BK, Bisset L, Vicenzino B. Efficacy and safety of corticosteroid injections and other injections for management of tendinopathy: a systematic review of randomised controlled trials. Lancet. 2010;367:1751-67.
8. Ramírez J, Pomés I, Cabrera S, Pomés J, Sanmartí R, Cañete JD.

medRxiv preprint doi: https://doi.org/10.1101/2022.12.14.22283447; this version posted December 14, 2022. The copyright holder for this preprint (which was not certified by peer review) is the author/funder, who has granted medRxiv a license to display the preprint in perpetuity.

It is made available under a CC-BY 4.0 International license .

Incidence of full-thickness rotator cuff tear after subacromial corticosteroid injection: a 12-week prospective study. Mod Rheumatol. 2014;24:667-70.
9. Hurley ET, Hannon CP, Pauzenberger L, Fat DL, Moran CJ, Mullett H. Nonoperative treatment of rotator cuff disease with platelet-rich plasma: a systematic review of randomized controlled trials. Arthroscopy. 2019;35:1584-91.
10. Schwitzguebel AJ, Kolo FC, Tirefort J, Kourhani A, Nowak A, Gremeaux V, et al. Efficacy of platelet-rich plasma for the treatment of interstitial supraspinatus tears: a double-blinded, randomized controlled trial. Am J Sports Med. 2019;47:1885-92.
11. Kukkonen J, Joukainen A, Lehtinen J, Mattila KT, Tuominen EK, Kauko T, et al. Treatment of non-traumatic rotator cuff tears: A randomised controlled trial with one-year clinical results. Bone Joint J. 2014;96-B:75-81.
12. Hurd JL, Facile TR, Weiss J, Hayes M, Hayes M, Furia JP, et al. Safety and efficacy of treating symptomatic, partial-thickness rotator cuff tears with fresh, uncultured, unmodified, autologous adipose-derived regenerative cells (UA-ADRCs) isolated at the point of care: a prospective, randomized, controlled first-in-human pilot study. J Orthop Surg Res. 2020;15:122.
13. Cossu G, Birchall M, Brown T, De Coppi P, Culme-Seymour E, Gibbon S, et al. Lancet Commission: stem cells and regenerative medicine. Lancet. 2018;391:883-910.
14. Furia JP, Lundeen MA, Hurd JL, Pearce DA, Alt C, Alt EU, et al. Why and how to use the body's own stem cells for regeneration in musculoskeletal disorders: a primer. J Orthop Surg Res. 2022;17:36.
15. Winnier GE, Valenzuela N, Peters-Hall J, Kellner J, Alt C, Alt EU. Isolation of adipose tissue derived regenerative cells from human subcutaneous tissue with or without the use of an enzymatic reagent. PLoS One. 2019;14:e0221457.
16. Aust L, Devlin B, Foster SJ, Halvorsen YD, Hicok K, du Laney T, et al. Yield of human adipose-derived adult stem cells from liposuction aspirates. Cytotherapy. 2004;6:7-14.
17. Yu H, Lu K, Zhu J, Wang J. Stem cell therapy for ischemic heart diseases. Br Med Bull. 2017;121:135–54.
18. Zhu Y, Liu T, Song K, Fan X, Ma X, Cui Z. Adipose-derived stem cell: a better stem cell than BMSC. Cell Biochem Funct. 2008;26:664-75.
19. Boutron I, Altman DG, Moher D, Schulz KF, Ravaud P; CONSORT NPT Group. CONSORT statement for randomized trials of nonpharmacologic treatments: a 2017 update and a CONSORT extension for nonpharmacologic trial abstracts. Ann Intern Med. 2017;167:40-7.
20. Schmitz C, Alt C, Azares AR, Pearce DA, Facile TR, Furia JP, et al. The composition of adipose-derived regenerative cells isolated from lipoaspirate using a point of care system does not depend on the subject's individual age, gender, body mass index and ethnicity; https://www.preprints.org/manuscript/202209.0321/v2.
21. Angst F, Schwyzer HK, Aeschlimann A, Simmen BR, Goldhahn J. Measures of adult shoulder function: Disabilities of the Arm, Shoulder, and Hand Questionnaire (DASH) and its short version (QuickDASH), Shoulder Pain and Disability Index (SPADI), American Shoulder and Elbow Surgeons (ASES) Society standardized shoulder assessment form, Constant (Murley) Score (CS), Simple Shoulder Test (SST), Oxford Shoulder Score (OSS), Shoulder Disability Questionnaire (SDQ), and Western Ontario Shoulder Instability Index (WOSI). Arthritis Care Res. 2011;63 Suppl 11:S174-88.
22. Hays RD, Sherbourne CD, Mazel RM. The RAND 36-Item Health Survey 1.0. Health Econ. 1993;2:217-27.
23. Moore W, Frye S. Review of HIPAA, Part 2: limitations, rights, violations, and role for the imaging technologist. J Nucl Med Technol. 2020;48:17-23.
24. Salkind NJ (ed). Encyclopedia of Research Design. Thousand Oaks: SAGE Publications; 2010.
25. Ellera Gomes JL, da Silva RC, Silla LM, Abreu MR, Pellanda R. Conventional rotator cuff repair complemented by the aid of mononuclear autologous stem cells. Knee Surg Sports Traumatol Arthrosc. 2012;20:373-7.
26. Hernigou P, Flouzat Lachaniette CH, Delambre J, Zilber S, Duffiet P, Chevallier N, et al. Biologic augmentation of rotator cuff repair with mesenchymal stem cells during arthroscopy improves healing and prevents further tears: a case-controlled study. Int Orthop. 2014;38:1811-8.
27. Havlas V, Kotaška J, Koníček P, Trč T, Konrádová Š, Kočí Z, et al. Kultivovaných lidských autologních kmenových buněk kostní dřeně při rekonstrukci ruptury rotátorové manžety - studie bezpečnosti metody, předběžné výsledky [Use of cultured human autologous bone marrow stem cells in repair of a rotator cuff tear: preliminary results of a safety study]. Acta Chir Orthop Traumatol Cech. 2015;82:229-34. Czech.
28. Lamas JR, García-Fernández C, Tornero-Esteban P, Lópiz Y, Rodriguez-Rodriguez L, Ortega L, et al. Adverse effects of xenogenic scaffolding in the context of a randomized double-blind placebo-controlled study for repairing full-thickness rotator cuff tears. Trials. 2019;20:387.
29. Kim YS, Sung CH, Chung SH, Kwak SJ, Koh YG. Does an injection of adipose-derived mesenchymal stem cells loaded in fibrin glue influence rotator cuff repair outcomes? A clinical and magnetic resonance imaging study. Am J Sports Med. 2017;45:2010-8.
30. Jo CH, Chai JW, Jeong EC, Oh S, Kim PS, Yoon JY, et al. Intratendinous injection of autologous adipose tissue-derived mesenchymal stem cells for the treatment of rotator cuff disease: A first-in-human trial. Stem Cells. 2018;36:1441-50.
31. Jo CH, Chai JW, Jeong EC, Oh S, Yoon KS. Intratendinous injection of mesenchymal stem cells for the treatment of rotator cuff disease: A 2-year follow-up study. Arthroscopy. 2020;36:971-80.
32. Chun SW, Kim W, Lee SY, Lim CY, Kim K, Kim JG, et al. A randomized controlled trial of stem cell injection for tendon tear. Sci Rep. 2022;12:818.
33. Randelli PS, Cucchi D, Fossati C, Boerci L, Nocerino E, Ambrogi F, et al. Arthroscopic rotator cuff repair augmentation with autologous microfragmented lipoaspirate tissue is safe and effectively improves short-term clinical and functional results: A prospective randomized controlled trial with 24-month follow-up. Am J Sports Med. 2022;50:1344-57.
34. Hurd J. Autologous adult adipose-derived regenerative cell injection into chronic partial-thickness rotator cuff tears. ClinicalTrials.gov Identifier: NCT03752827; https://www.clinicaltrials.gov/ct2/show/NCT03752827.
35. Alvarez CM, Litchfield R, Jackowski D, Griffin S, Kirkley A. A prospective, double-blind, randomized clinical trial comparing subacromial injection of betamethasone and xylocaine to xylocaine alone in chronic rotator cuff tendinosis. Am J Sports Med. 2005;33:255-262.
36. von Wehren L, Blanke F, Todorov A, Heisterbach P, Sailer J, Majewski M. The effect of subacromial injections of autologous conditioned plasma versus cortisone for the treatment of symptomatic partial rotator cuff tears. Knee Surg Sports Traumatol Arthrosc. 2016;24:3787-92.
37. Cole B, Lam P, Hackett L, Murrell GAC. Ultrasound-guided injections for supraspinatus tendinopathy: corticosteroid versus glucose prolotherapy - a randomized controlled clinical trial. Shoulder Elbow. 2018;10:170-78.
38. Damjanov N, Barac B, Colic J, Stevanovic V, Zekovic A, Tulic G. The efficacy and safety of autologous conditioned serum (ACS) injections compared with betamethasone and placebo injections in the treatment of chronic shoulder joint pain due to supraspinatus tendinopathy: a prospective, randomized, double-blind, controlled

medRxiv preprint doi: https://doi.org/10.1101/2022.12.14.22283447; this version posted December 14, 2022. The copyright holder for this preprint **(which was not certified by peer review)** is the author/funder, who has granted medRxiv a license to display the preprint in perpetuity.

It is made available under a CC-BY 4.0 International license .

study. Med Ultrason. 2018;20:335-41.

39. Sari A, Eroglu A. Comparison of ultrasound-guided platelet-rich plasma, prolotherapy, and corticosteroid injections in rotator cuff lesions. J Back Musculoskelet Rehabil. 2020;33:387-96.
40. Andia I, Maffulli N, Burgos-Alonso N. Stromal vascular fraction technologies and clinical applications. Expert Opin Biol Ther. 2019;19:1289-1305.
41. Polly SS, Nichols AEC, Donnini E, Inman DJ, Scott TJ, Apple SM, et al. Adipose-derived stromal vascular fraction and cultured stromal cells as trophic mediators for tendon healing. J Orthop Res. 2019;37:1429-39.
42. Dai M, Sui B, Xue Y, Liu X, Sun J. Cartilage repair in degenerative osteoarthritis mediated by squid type II collagen via immunomodulating activation of M2 macrophages, inhibiting apoptosis and hypertrophy of chondrocytes. Biomaterials. 2018;180:91-103.
43. Liu Z, Kuang W, Zhou Q, Zhang Y. TGF-β1 secreted by M2 phenotype macrophages enhances the stemness and migration of glioma cells via the SMAD2/3 signalling pathway. Int J Mol Med. 2018;42:3395-403.
44. Lv J, Liu C, Chen FK, Feng ZP, Jia L, Liu PJ, et al. M2-like tumour-associated macrophage-secreted IGF promotes thyroid cancer stemness and metastasis by activating the PI3K/AKT/mTOR pathway. Mol Med Rep. 2021;24:604.
45. Spiller KL, Anfang RR, Spiller KJ, Ng J, Nakazawa KR, Daulton JW, et al. The role of macrophage phenotype in vascularization of tissue engineering scaffolds. Biomaterials. 2014;35:4477-88.
46. Yunna C, Mengru H, Lei W, Weidong C. Macrophage M1/M2 polarization. Eur J Pharmacol. 2020;877:173090.
47. Scala P, Rehak L, Giudice V, Ciaglia E, Puca AA, Selleri C, et al. Stem cell and macrophage roles in skeletal muscle regenerative medicine. Int J Mol Sci. 2021;22:10867.
48. Alt E, Rothoerl R, Hoppert M, Frank HG, Wuerfel T, Alt C, et al. First immunohistochemical evidence of human tendon repair following stem cell injection: a case report and review of literature. World J Stem Cells. 2021;13:944-70.

medRxiv preprint doi: https://doi.org/10.1101/2022.12.14.22283447; this version posted December 14, 2022. The copyright holder for this preprint **(which was not certified by peer review)** is the author/funder, who has granted medRxiv a license to display the preprint in perpetuity.

It is made available under a CC-BY 4.0 International license .

Appendix

Note: throughout this document the term "former study" refers to the following study:

Hurd JL, Facile TR, Weiss J, et al. Safety and efficacy of treating symptomatic, partial-thickness rotator cuff tears with fresh, uncultured, unmodified, autologous, adipose-derived regenerative cells (UA-ADRCs) isolated at the point of care: a prospective, randomized, controlled first-in-human pilot study. *J Orthop Surg Res* 2020;**15**:122.

Part 1 – Original MRI scans

medRxiv preprint doi: https://doi.org/10.1101/2022.12.14.22283447; this version posted December 14, 2022. The copyright holder for this preprint **(which was not certified by peer review)** is the author/funder, who has granted medRxiv a license to display the preprint in perpetuity.

It is made available under a CC-BY 4.0 International license .

FIGURE S1. *Proton density weighted, fat saturated, T2-weighted, coronal magnetic resonance imaging (MRI) scans of the index shoulder of Subject A1 treated with injection of ADRCs, generated during the former study and the present study.*

Panels A-L show the same (or nearly the same) image planes at different times, with Panels A showing the most ventral image plane and Panels L the most dorsal image plane.

The yellow arrows in Panels F_{W24}, G_{W24}, H_{W24}, I_{W24} and J_{W24} indicate a hyperintense structure at the position of the supraspinatus tendon that was found at 24 weeks post-treatment but not at baseline.

Abbreviations: BL, baseline; W24 / W52, 24 / 52 weeks post-treatment; M34 / M41, 34 / 41 months post-treatment.

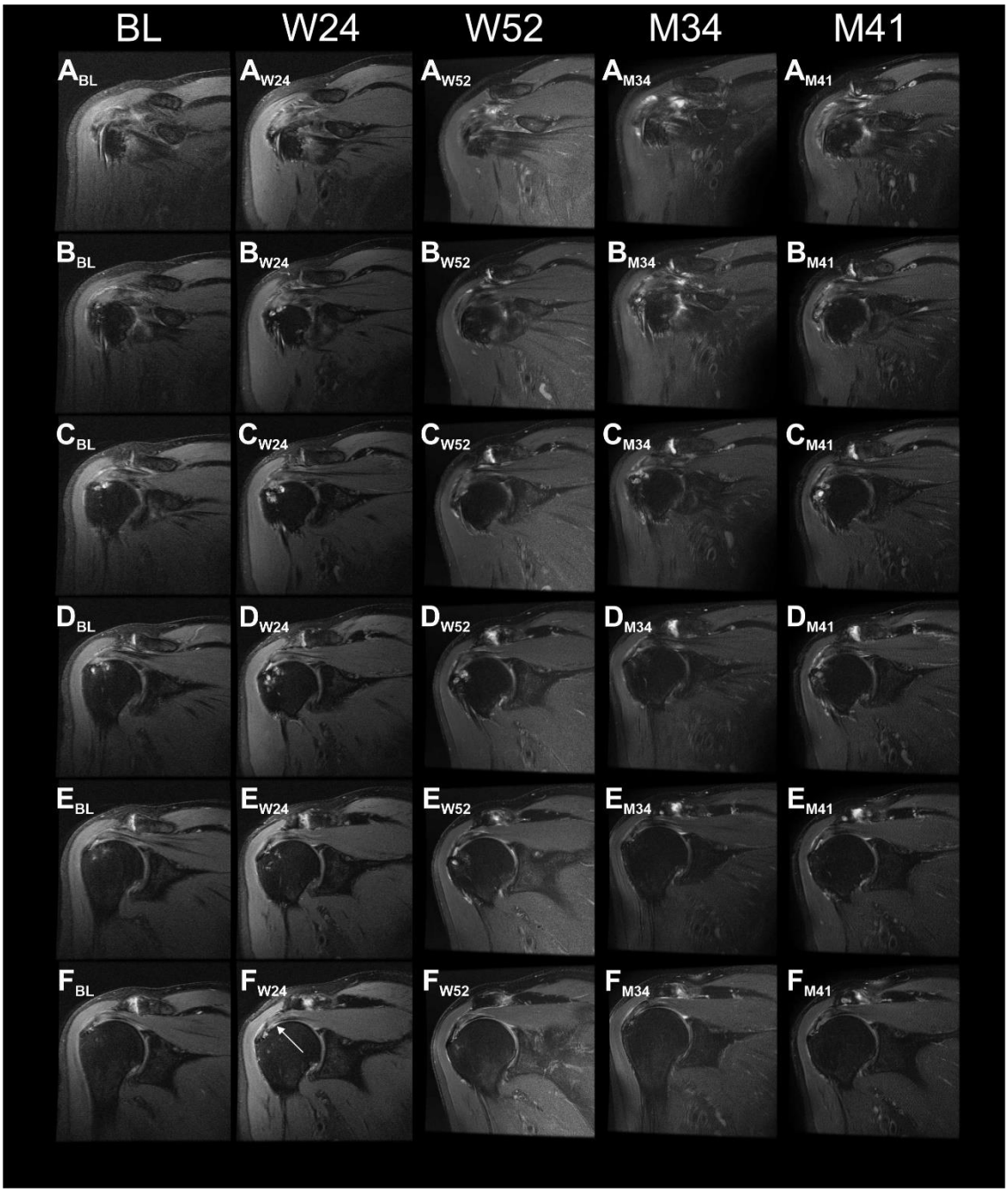

medRxiv preprint doi: https://doi.org/10.1101/2022.12.14.22283447; this version posted December 14, 2022. The copyright holder for this preprint **(which was not certified by peer review)** is the author/funder, who has granted medRxiv a license to display the preprint in perpetuity.

It is made available under a CC-BY 4.0 International license .

FIGURE S1 (cont.)

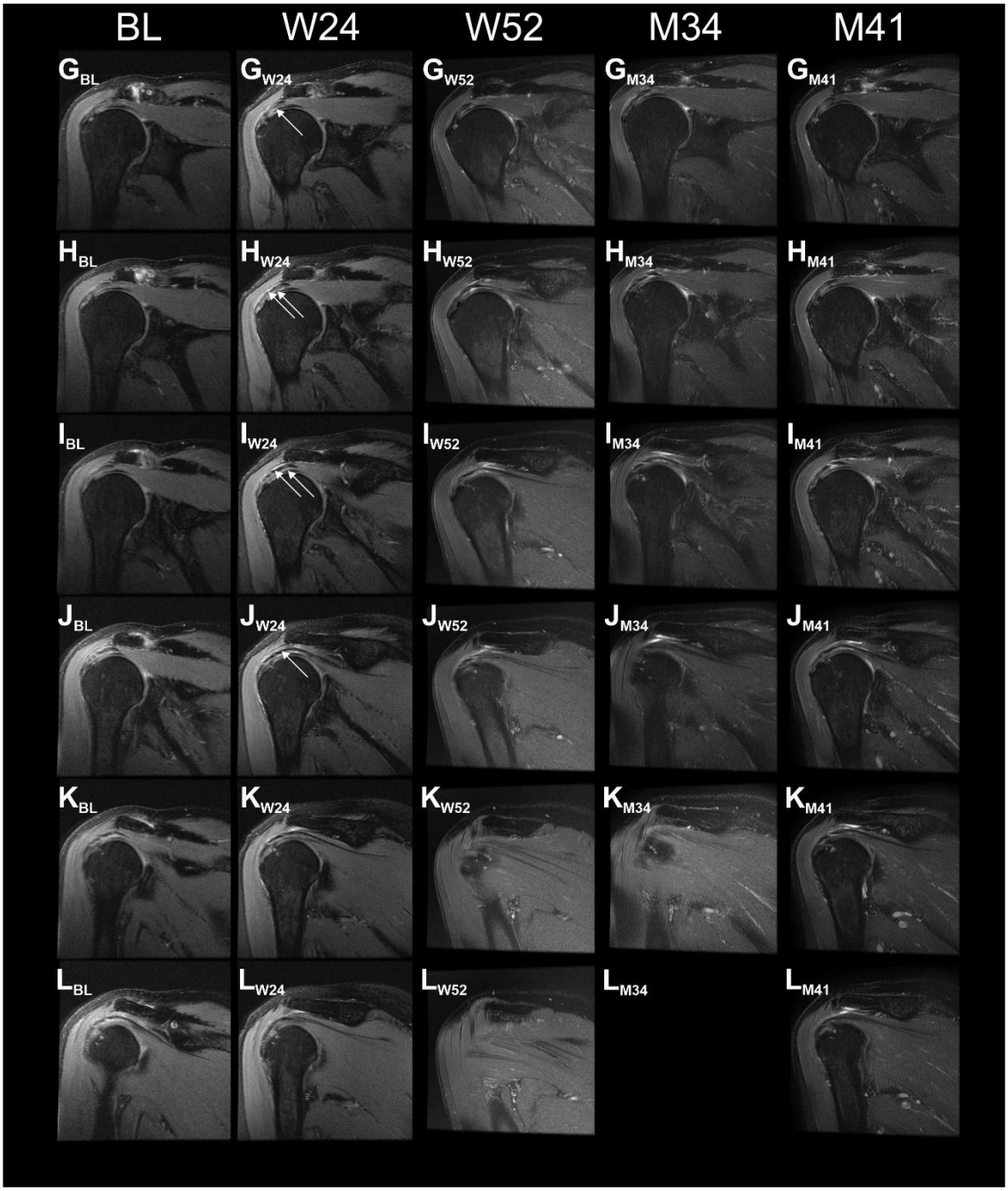

medRxiv preprint doi: https://doi.org/10.1101/2022.12.14.22283447; this version posted December 14, 2022. The copyright holder for this preprint **(which was not certified by peer review)** is the author/funder, who has granted medRxiv a license to display the preprint in perpetuity.

It is made available under a CC-BY 4.0 International license .

FIGURE S2. *Proton density weighted, fat saturated, T2-weighted, coronal magnetic resonance imaging (MRI) scans of the index shoulder of Subject A2 treated with injection of ADRCs, generated during the former study and the present study.*

Panels A-L show the same (or nearly the same) image planes at different times, with Panels A showing the most ventral image plane and Panels L the most dorsal image plane.

The yellow arrows in Panels G_{W24}, H_{W24} and I_{W24} indicate a hyperintense structure at the position of the supraspinatus tendon that was found at 24 weeks post-treatment but not at baseline.

Abbreviations: BL, baseline; W24 / W52, 24 / 52 weeks post-treatment; M33 / M41, 33 / 41 months post-treatment.

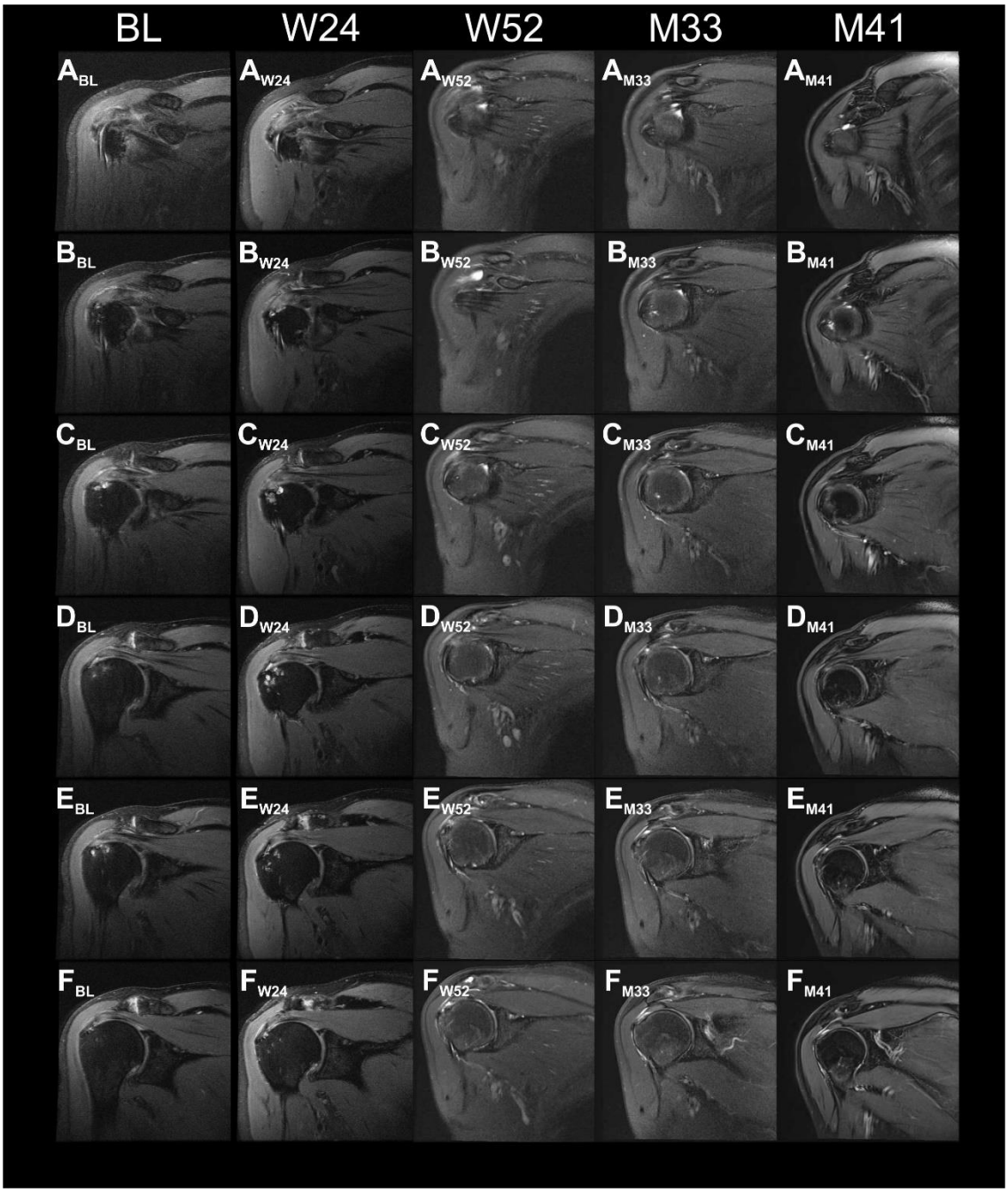

medRxiv preprint doi: https://doi.org/10.1101/2022.12.14.22283447; this version posted December 14, 2022. The copyright holder for this preprint **(which was not certified by peer review)** is the author/funder, who has granted medRxiv a license to display the preprint in perpetuity.

It is made available under a CC-BY 4.0 International license .

FIGURE S2 (cont.)

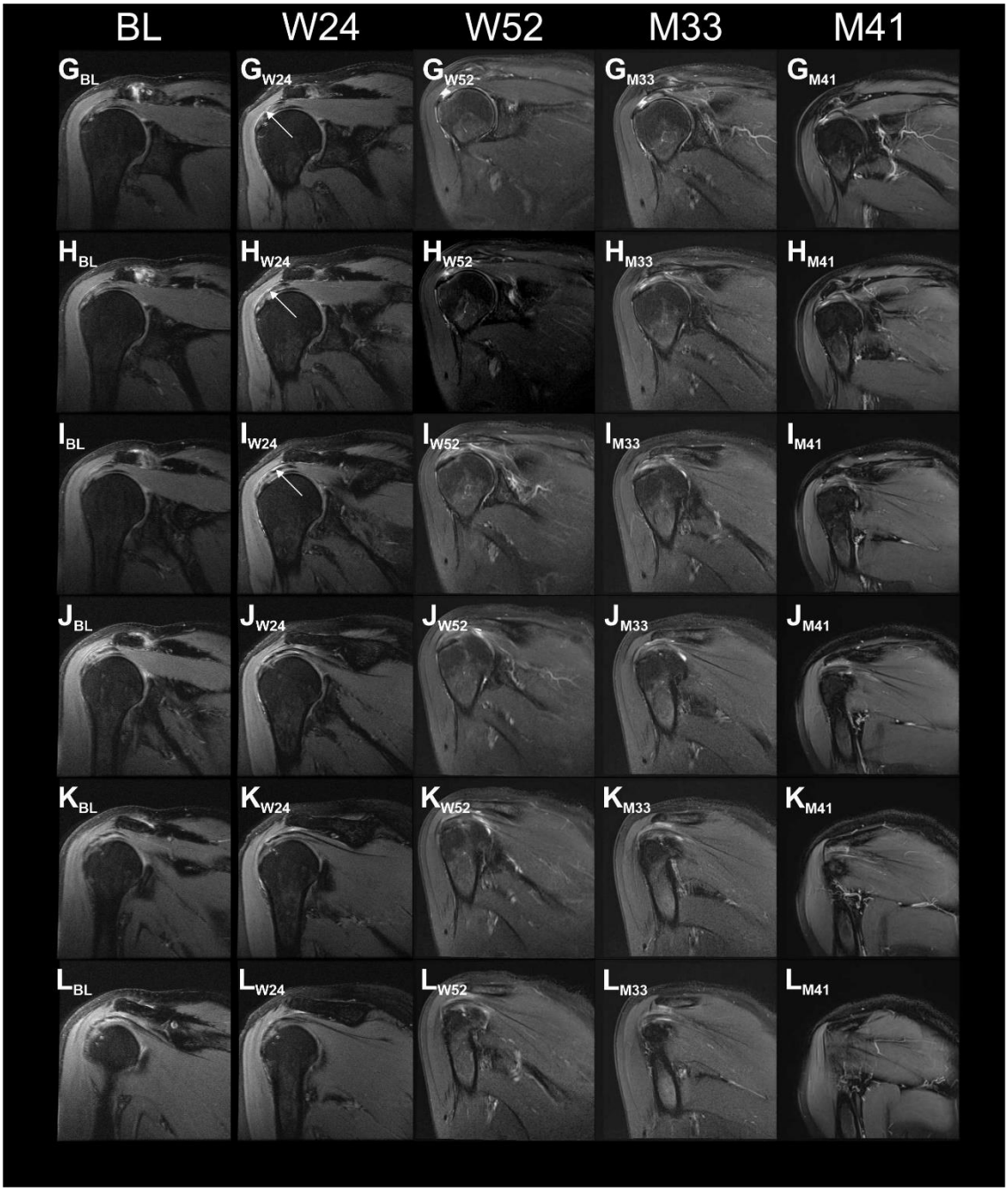

medRxiv preprint doi: https://doi.org/10.1101/2022.12.14.22283447; this version posted December 14, 2022. The copyright holder for this preprint **(which was not certified by peer review)** is the author/funder, who has granted medRxiv a license to display the preprint in perpetuity.

It is made available under a CC-BY 4.0 International license .

FIGURE S3. *Proton density weighted, fat saturated, T2-weighted, coronal magnetic resonance imaging (MRI) scans of the index shoulder of Subject A3 treated with injection of ADRCs, generated during the former study and the present study.*

Panels A-L show the same (or nearly the same) image planes at different times, with Panels A showing the most ventral image plane and Panels L the most dorsal image plane.

The yellow arrows in Panels C_{W24}, D_{W24}, E_{W24}, F_{W24}, G_{W24} and H_{W24} indicate a hyperintense structure at the position of the supraspinatus tendon that was found at 24 weeks post-treatment but not at baseline.

Abbreviations: BL, baseline; W24 / W52, 24 / 52 weeks post-treatment; M32 / M39, 32 / 39 months post-treatment.

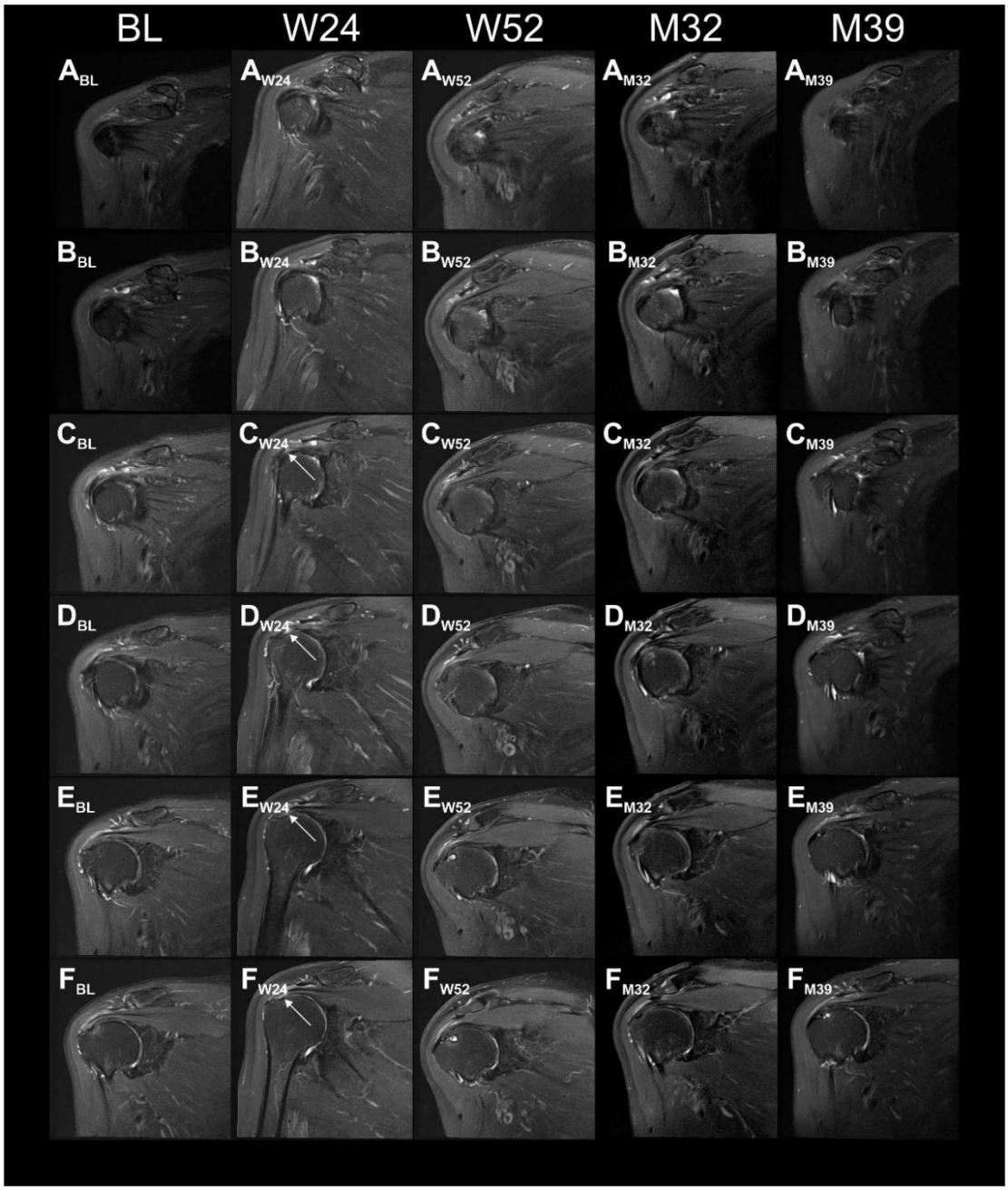

medRxiv preprint doi: https://doi.org/10.1101/2022.12.14.22283447; this version posted December 14, 2022. The copyright holder for this preprint **(which was not certified by peer review)** is the author/funder, who has granted medRxiv a license to display the preprint in perpetuity.

It is made available under a CC-BY 4.0 International license .

FIGURE S3 (cont.)

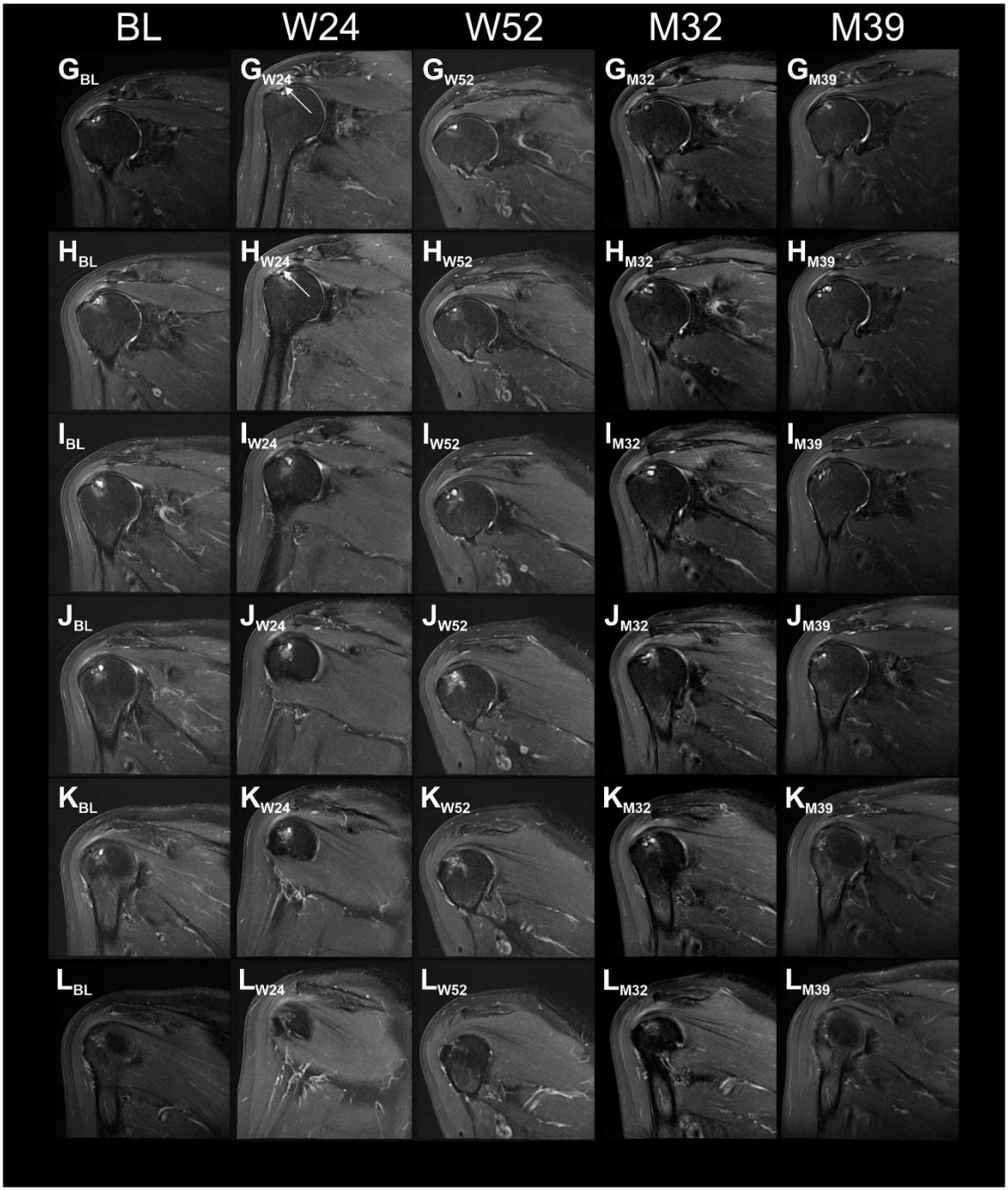

medRxiv preprint doi: https://doi.org/10.1101/2022.12.14.22283447; this version posted December 14, 2022. The copyright holder for this preprint **(which was not certified by peer review)** is the author/funder, who has granted medRxiv a license to display the preprint in perpetuity.

It is made available under a CC-BY 4.0 International license .

FIGURE S4. *Proton density weighted, fat saturated, T2-weighted, coronal magnetic resonance imaging (MRI) scans of the index shoulder of Subject A4 treated with injection of ADRCs, generated during the former study and the present study.*

Panels A-L show the same (or nearly the same) image planes at different times, with Panels A showing the most ventral image plane and Panels L the most dorsal image plane.

The yellow arrows in Panels F_{W24}, G_{W24}, H_{W24} and I_{W24} indicate a hyperintense structure at the position of the supraspinatus tendon that was found at 24 weeks post-treatment but not at baseline.

Abbreviations: BL, baseline; W24 / W52, 24 / 52 weeks post-treatment; M34, 34 months post-treatment (no MRI was performed during the second visit of Subject A7).

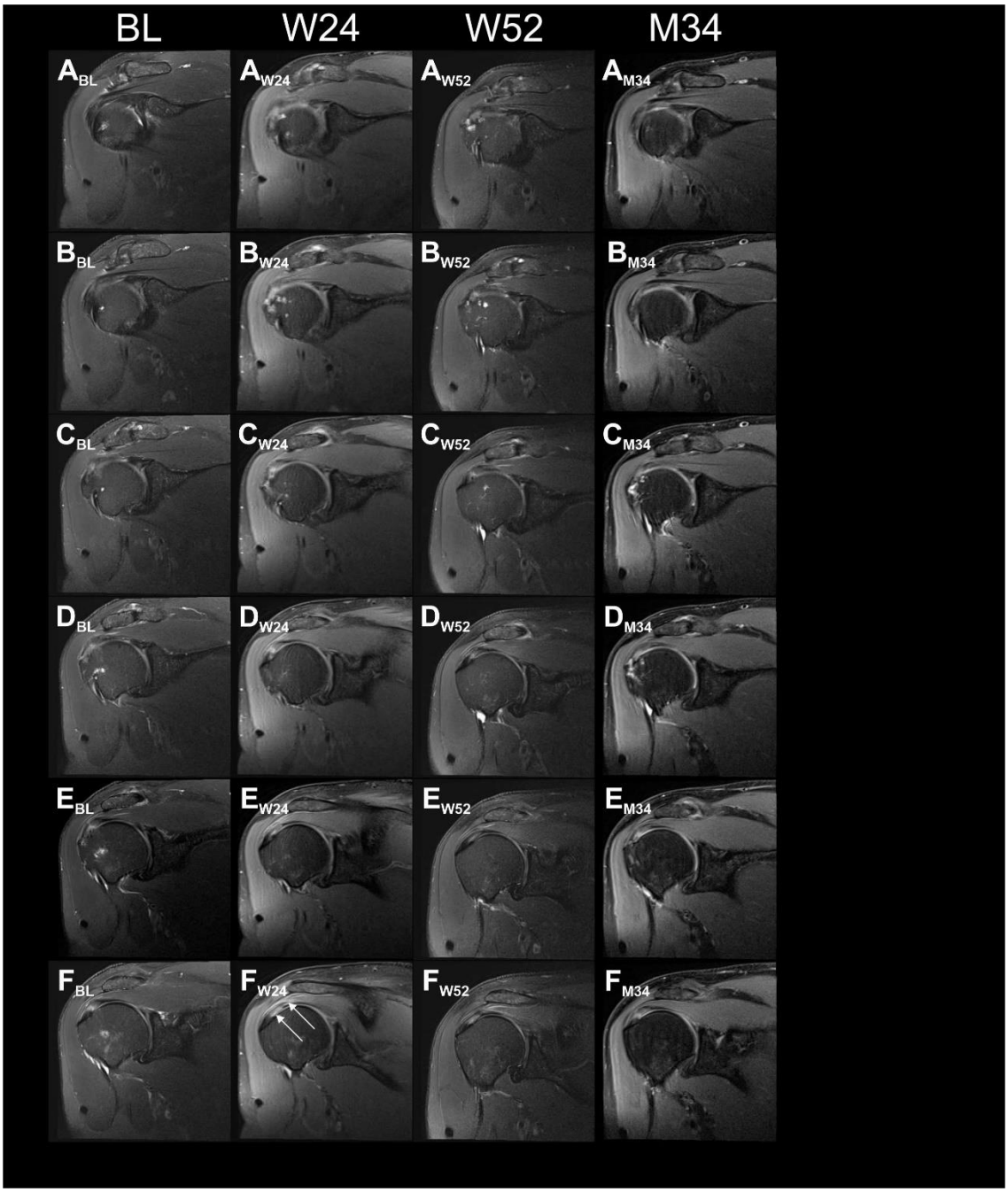

medRxiv preprint doi: https://doi.org/10.1101/2022.12.14.22283447; this version posted December 14, 2022. The copyright holder for this preprint **(which was not certified by peer review)** is the author/funder, who has granted medRxiv a license to display the preprint in perpetuity.

It is made available under a CC-BY 4.0 International license .

FIGURE S4 (cont.)

medRxiv preprint doi: https://doi.org/10.1101/2022.12.14.22283447; this version posted December 14, 2022. The copyright holder for this preprint **(which was not certified by peer review)** is the author/funder, who has granted medRxiv a license to display the preprint in perpetuity.

It is made available under a CC-BY 4.0 International license .

FIGURE S5. *Proton density weighted, fat saturated, T2-weighted, coronal magnetic resonance imaging (MRI) scans of the index shoulder of Subject A5 treated with injection of ADRCs, generated during the former study and the present study.*

Panels A-L show the same (or nearly the same) image planes at different times, with Panels A showing the most ventral image plane and Panels L the most dorsal image plane.

The yellow arrows in Panels B_{W24}, C_{W24}, D_{W24}, E_{W24}, F_{W24}, G_{W24} H_{W24}, I_{W24} and J_{W24} indicate a hyperintense structure at the position of the supraspinatus tendon that was found at 24 weeks post-treatment but not at baseline.

Abbreviations: BL, baseline; W24 / W52, 24 / 52 weeks post-treatment; M33 / M41, 33 / 41 months post-treatment.

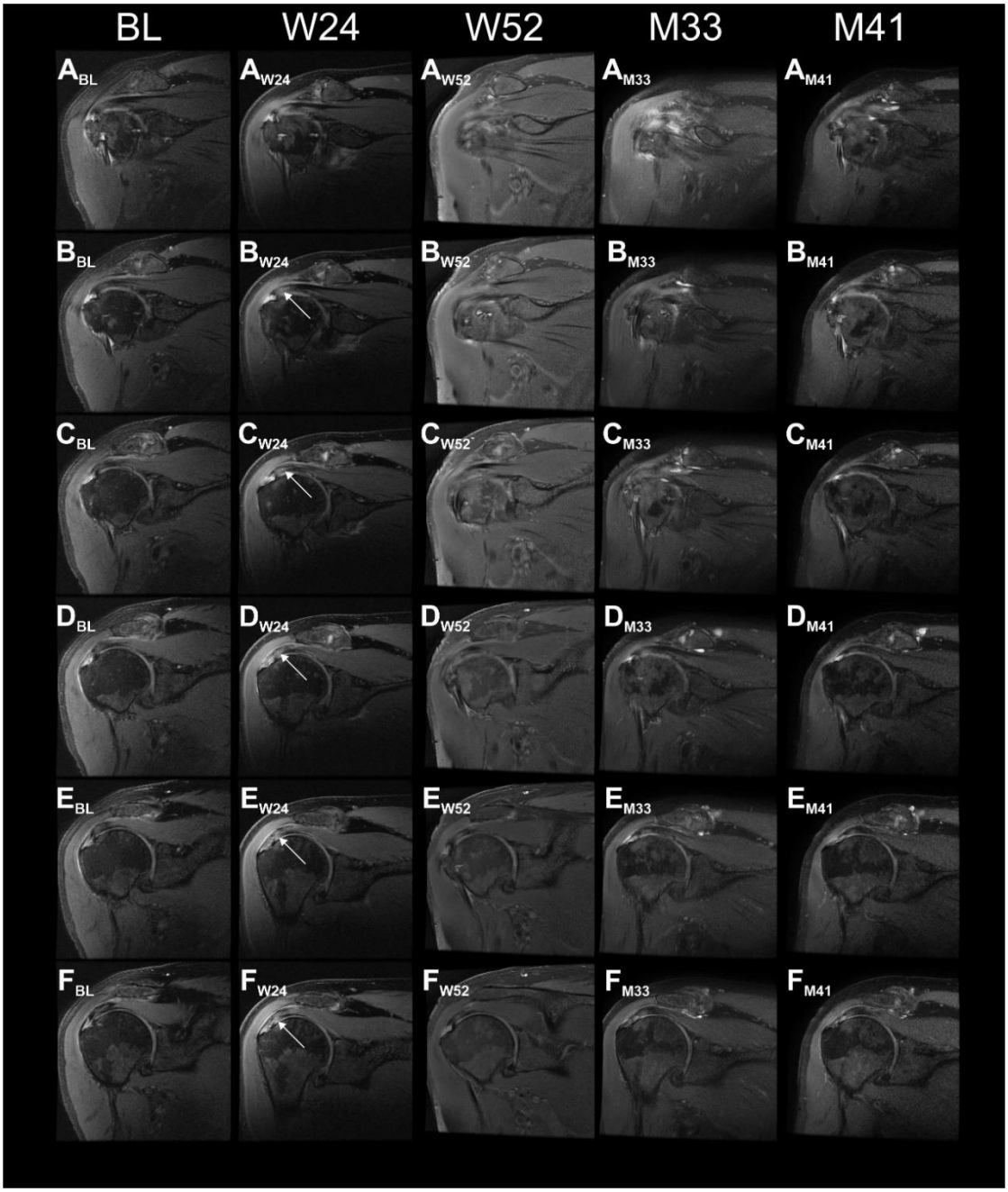

medRxiv preprint doi: https://doi.org/10.1101/2022.12.14.22283447; this version posted December 14, 2022. The copyright holder for this preprint **(which was not certified by peer review)** is the author/funder, who has granted medRxiv a license to display the preprint in perpetuity.

It is made available under a CC-BY 4.0 International license .

FIGURE S5 (cont.)

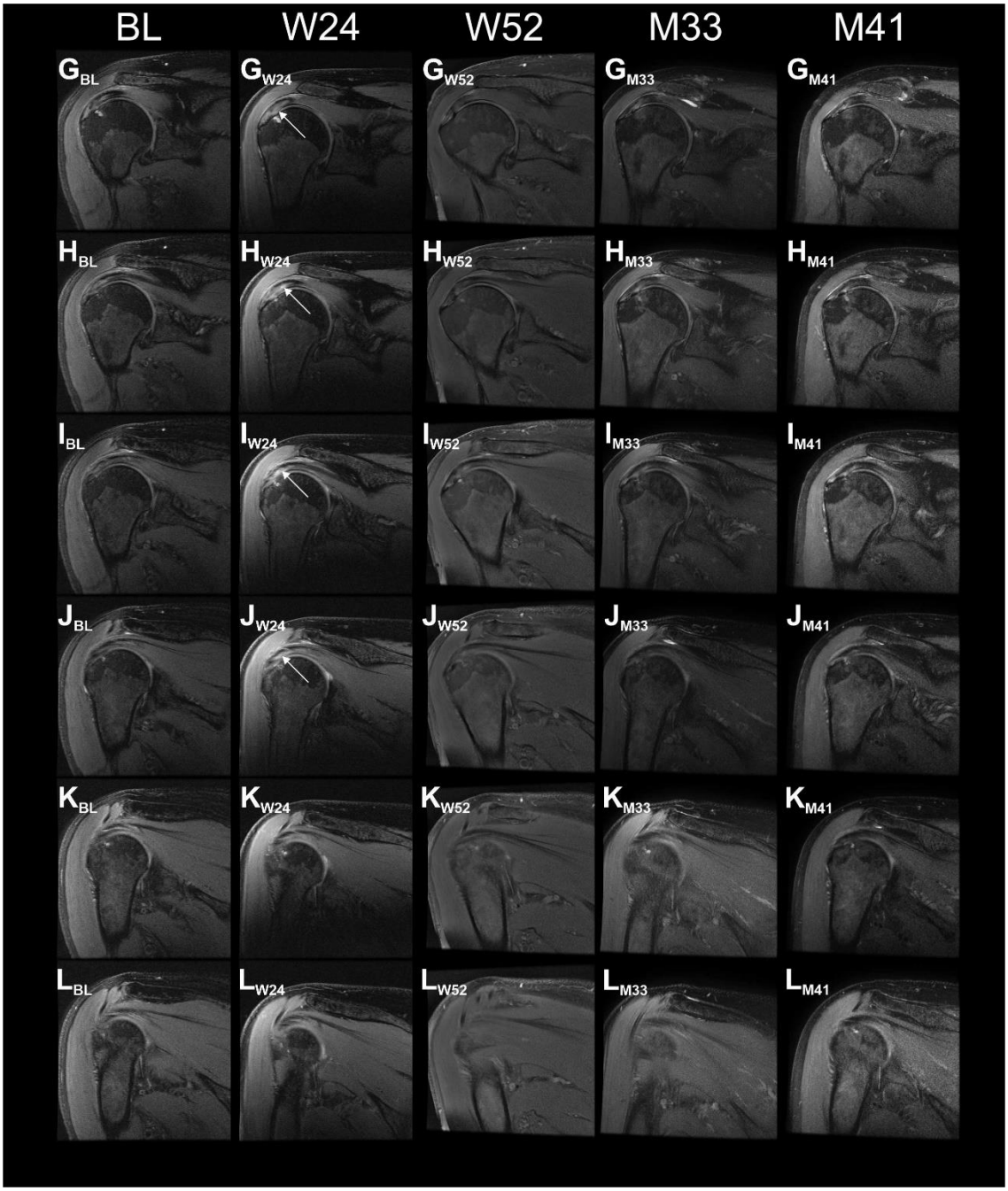

medRxiv preprint doi: https://doi.org/10.1101/2022.12.14.22283447; this version posted December 14, 2022. The copyright holder for this preprint **(which was not certified by peer review)** is the author/funder, who has granted medRxiv a license to display the preprint in perpetuity.

It is made available under a CC-BY 4.0 International license .

FIGURE S6. *Proton density weighted, fat saturated, T2-weighted, coronal magnetic resonance imaging (MRI) scans of the index shoulder of Subject A6 treated with injection of ADRCs, generated during the former study and the present study.*

Panels A-L show the same (or nearly the same) image planes at different times, with Panels A showing the most ventral image plane and Panels L the most dorsal image plane.

The yellow arrows in Panels D_{W24}, E_{W24} and F_{W24} indicate a hyperintense structure at the position of the supraspinatus tendon that was found at 24 weeks post-treatment but not at baseline.

Abbreviations: BL, baseline; W24 / W52, 24 / 52 weeks post-treatment; M33 / M41, 33 / 41 months post-treatment.

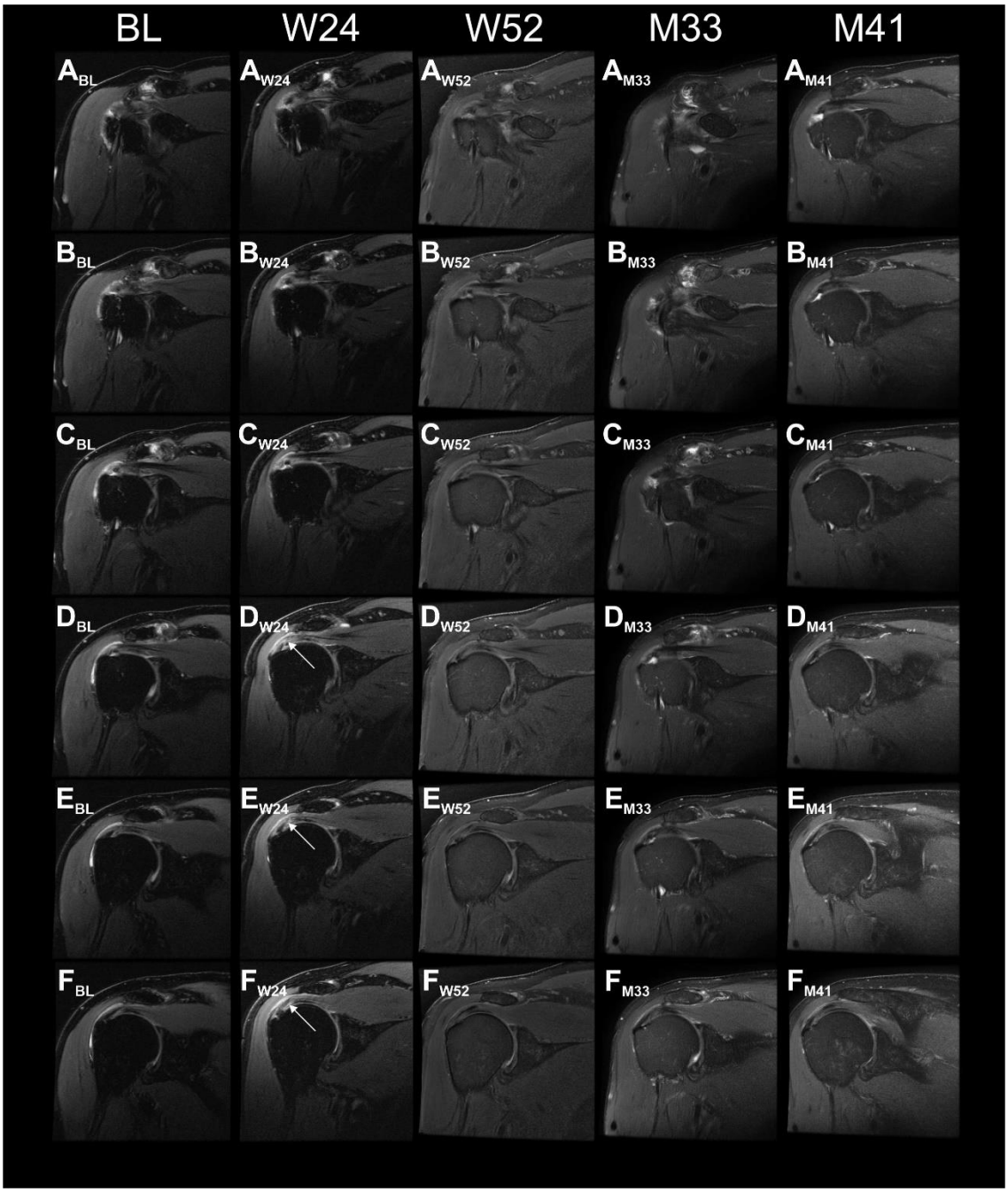

medRxiv preprint doi: https://doi.org/10.1101/2022.12.14.22283447; this version posted December 14, 2022. The copyright holder for this preprint **(which was not certified by peer review)** is the author/funder, who has granted medRxiv a license to display the preprint in perpetuity.

It is made available under a CC-BY 4.0 International license .

FIGURE S6 (cont.)

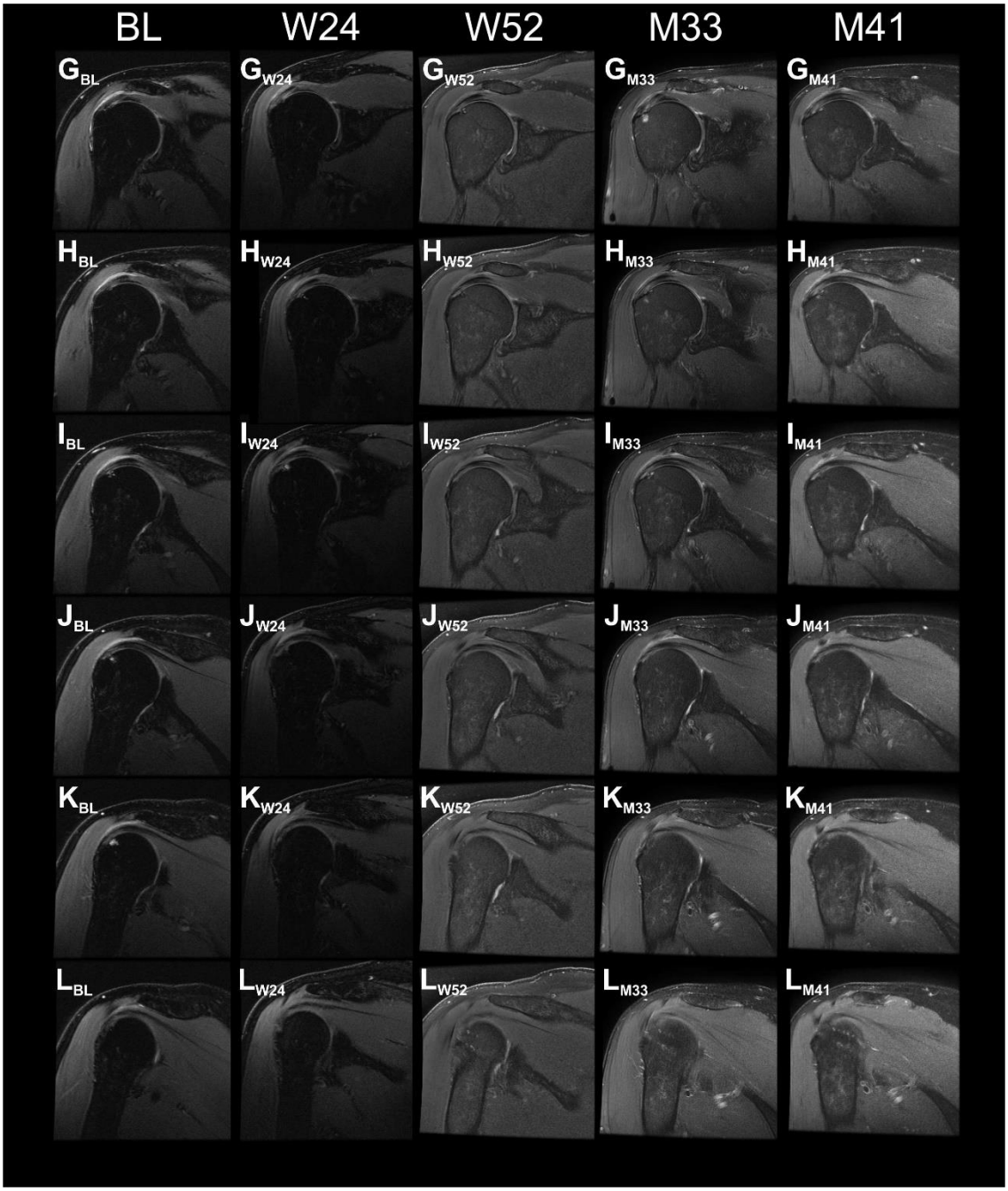

medRxiv preprint doi: https://doi.org/10.1101/2022.12.14.22283447; this version posted December 14, 2022. The copyright holder for this preprint **(which was not certified by peer review)** is the author/funder, who has granted medRxiv a license to display the preprint in perpetuity.

It is made available under a CC-BY 4.0 International license .

FIGURE S7. *Proton density weighted, fat saturated, T2-weighted, coronal magnetic resonance imaging (MRI) scans of the index shoulder of Subject A7 treated with injection of ADRCs, generated during the former study and the present study.*

Panels A-L show the same (or nearly the same) image planes at different times, with Panels A showing the most ventral image plane and Panels L the most dorsal image plane.

The yellow arrows in Panels H_{W24} and I_{W24} indicate a hyperintense structure at the position of the supraspinatus tendon that was found at 24 weeks post-treatment but not at baseline.

Abbreviations: BL, baseline; W24 / W52, 24 / 52 weeks post-treatment; M33 / M41, 33 / 41 months post-treatment.

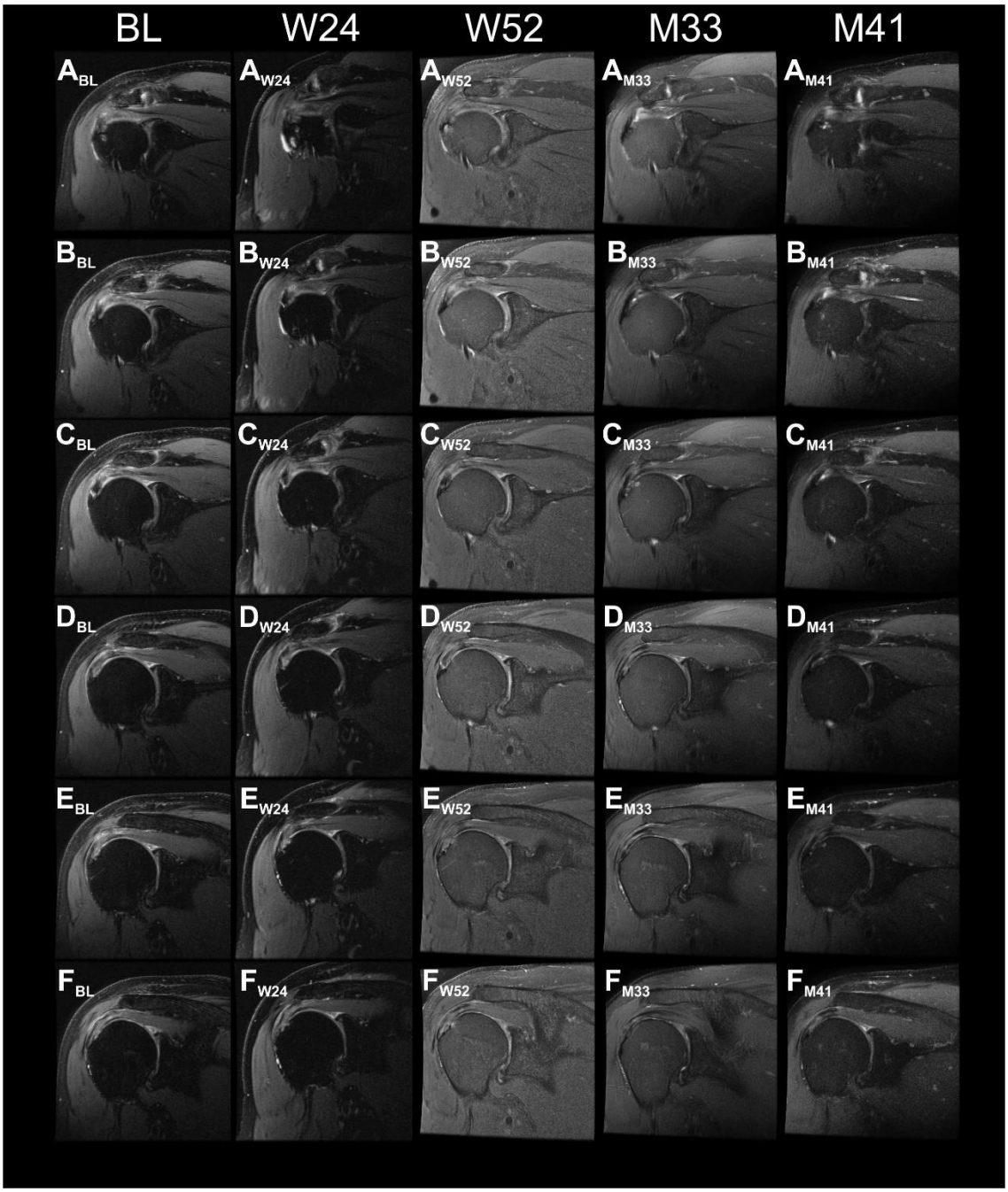

medRxiv preprint doi: https://doi.org/10.1101/2022.12.14.22283447; this version posted December 14, 2022. The copyright holder for this preprint **(which was not certified by peer review)** is the author/funder, who has granted medRxiv a license to display the preprint in perpetuity.

It is made available under a CC-BY 4.0 International license .

FIGURE S7 (cont.)

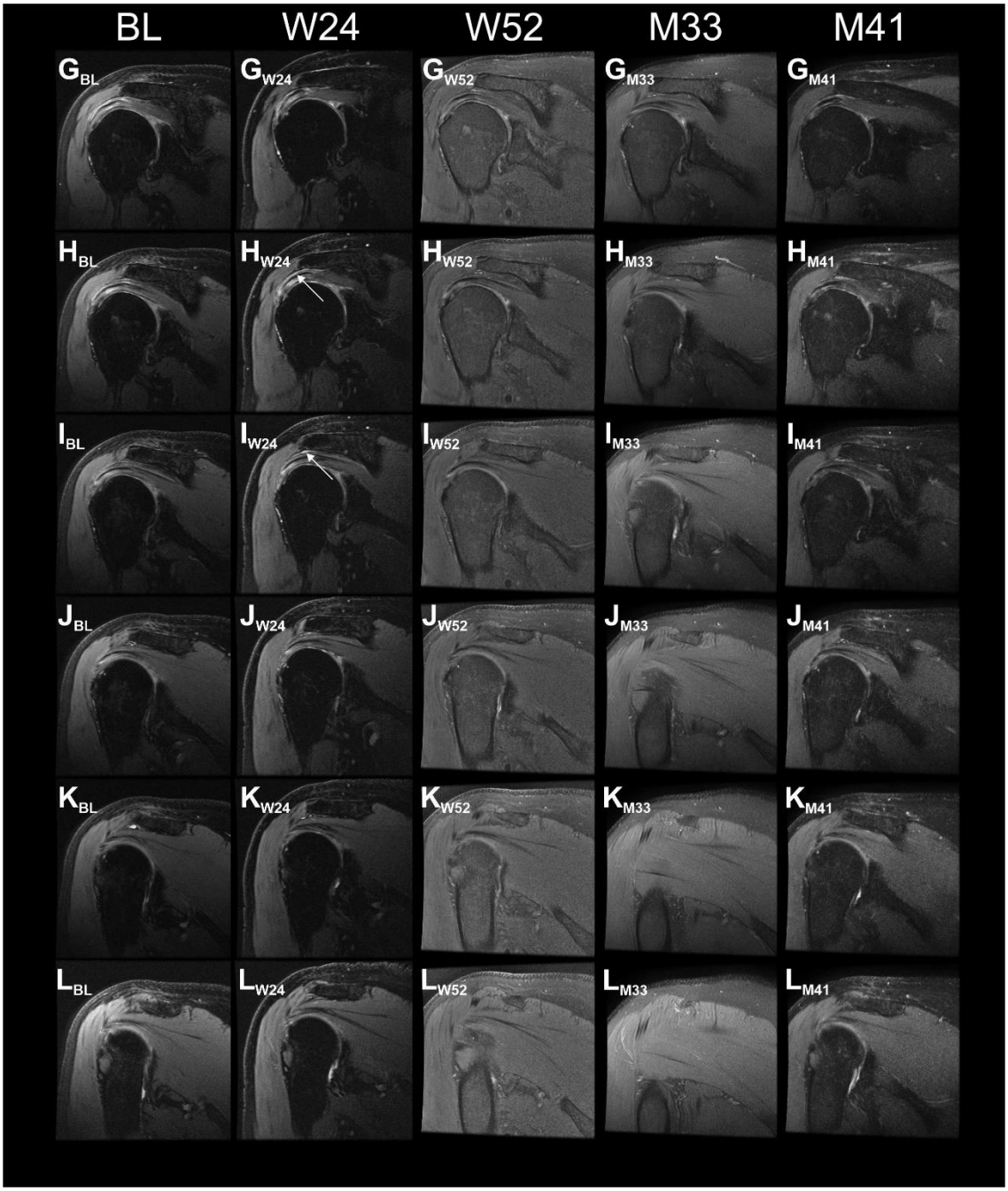

medRxiv preprint doi: https://doi.org/10.1101/2022.12.14.22283447; this version posted December 14, 2022. The copyright holder for this preprint **(which was not certified by peer review)** is the author/funder, who has granted medRxiv a license to display the preprint in perpetuity.

It is made available under a CC-BY 4.0 International license .

FIGURE S8. *Proton density weighted, fat saturated, T2-weighted, coronal magnetic resonance imaging (MRI) scans of the index shoulder of Subject A8 treated with injection of ADRCs, generated during the former study and the present study.*

Panels A-L show the same (or nearly the same) image planes at different times, with Panels A showing the most ventral image plane and Panels L the most dorsal image plane.

Abbreviations: BL, baseline; W24 / W52, 24 / 52 weeks post-treatment; M33 / M41, 31 / 39 months post-treatment.

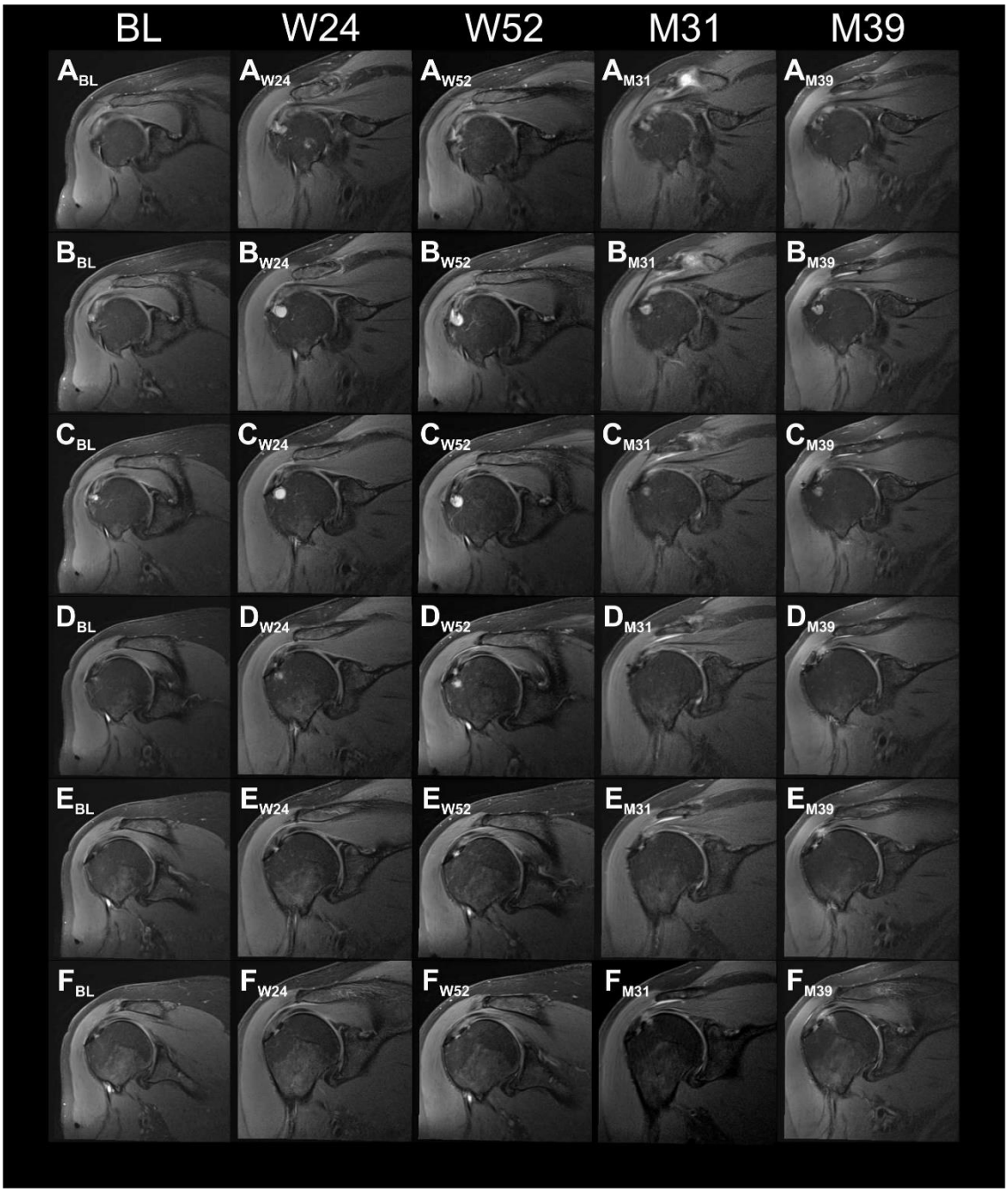

medRxiv preprint doi: https://doi.org/10.1101/2022.12.14.22283447; this version posted December 14, 2022. The copyright holder for this preprint **(which was not certified by peer review)** is the author/funder, who has granted medRxiv a license to display the preprint in perpetuity.

It is made available under a CC-BY 4.0 International license .

FIGURE S8 (cont.)

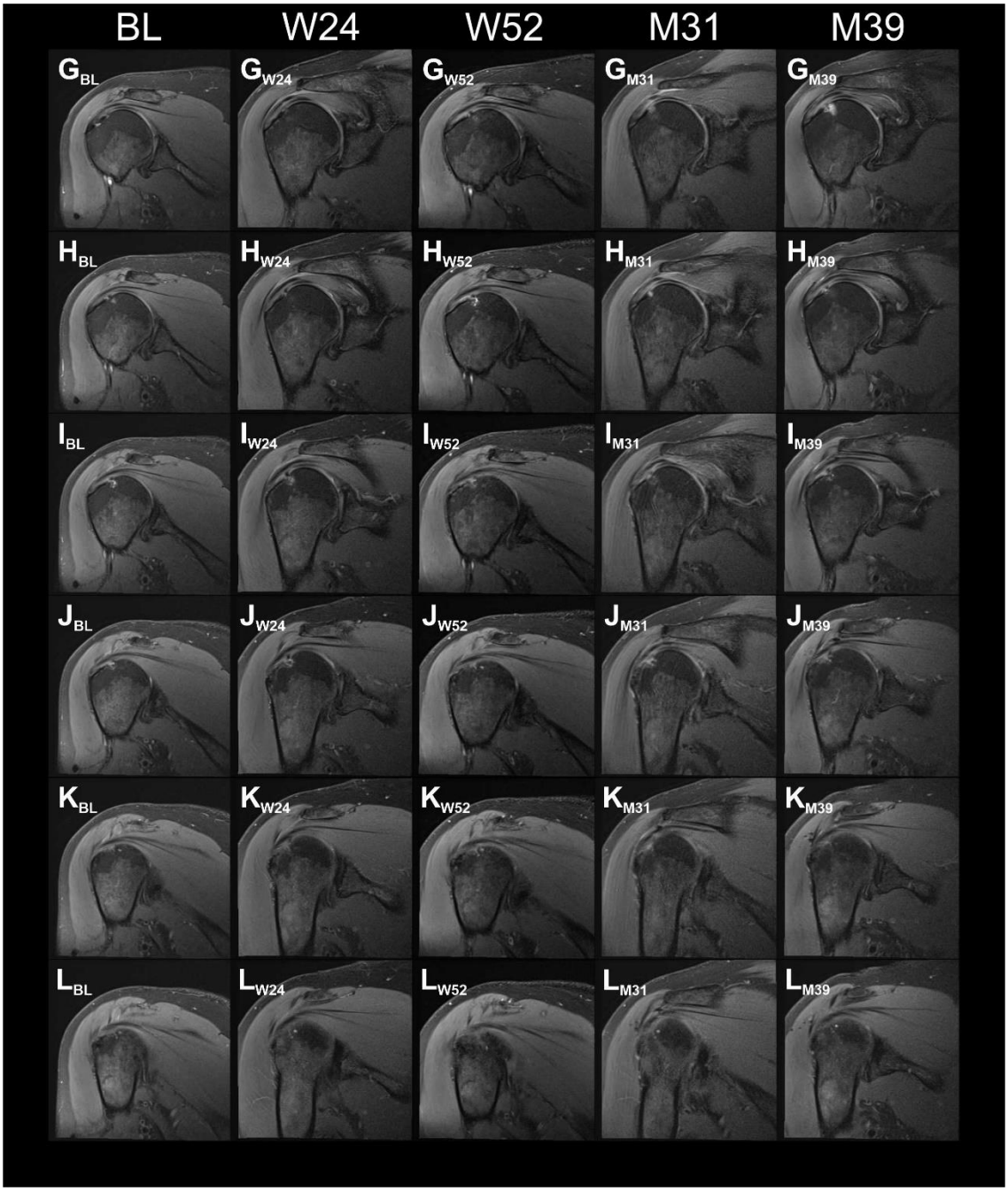

medRxiv preprint doi: https://doi.org/10.1101/2022.12.14.22283447; this version posted December 14, 2022. The copyright holder for this preprint **(which was not certified by peer review)** is the author/funder, who has granted medRxiv a license to display the preprint in perpetuity.

It is made available under a CC-BY 4.0 International license .

FIGURE S9. *Proton density weighted, fat saturated, T2-weighted, coronal magnetic resonance imaging (MRI) scans of the index shoulder of Subject A9 treated with injection of ADRCs, generated during the former study and the present study.*

Panels A-L show the same (or nearly the same) image planes at different times, with Panels A showing the most ventral image plane and Panels L the most dorsal image plane.

The yellow arrows in Panels B_{W24}, C_{W24} and D_{W24} indicate a hyperintense structure at the position of the supraspinatus tendon that was found at 24 weeks post-treatment but not at baseline.

Abbreviations: BL, baseline; W24 / W52, 24 / 52 weeks post-treatment; M33, 33 months post-treatment (no MRI was performed during the second visit of Subject A9).

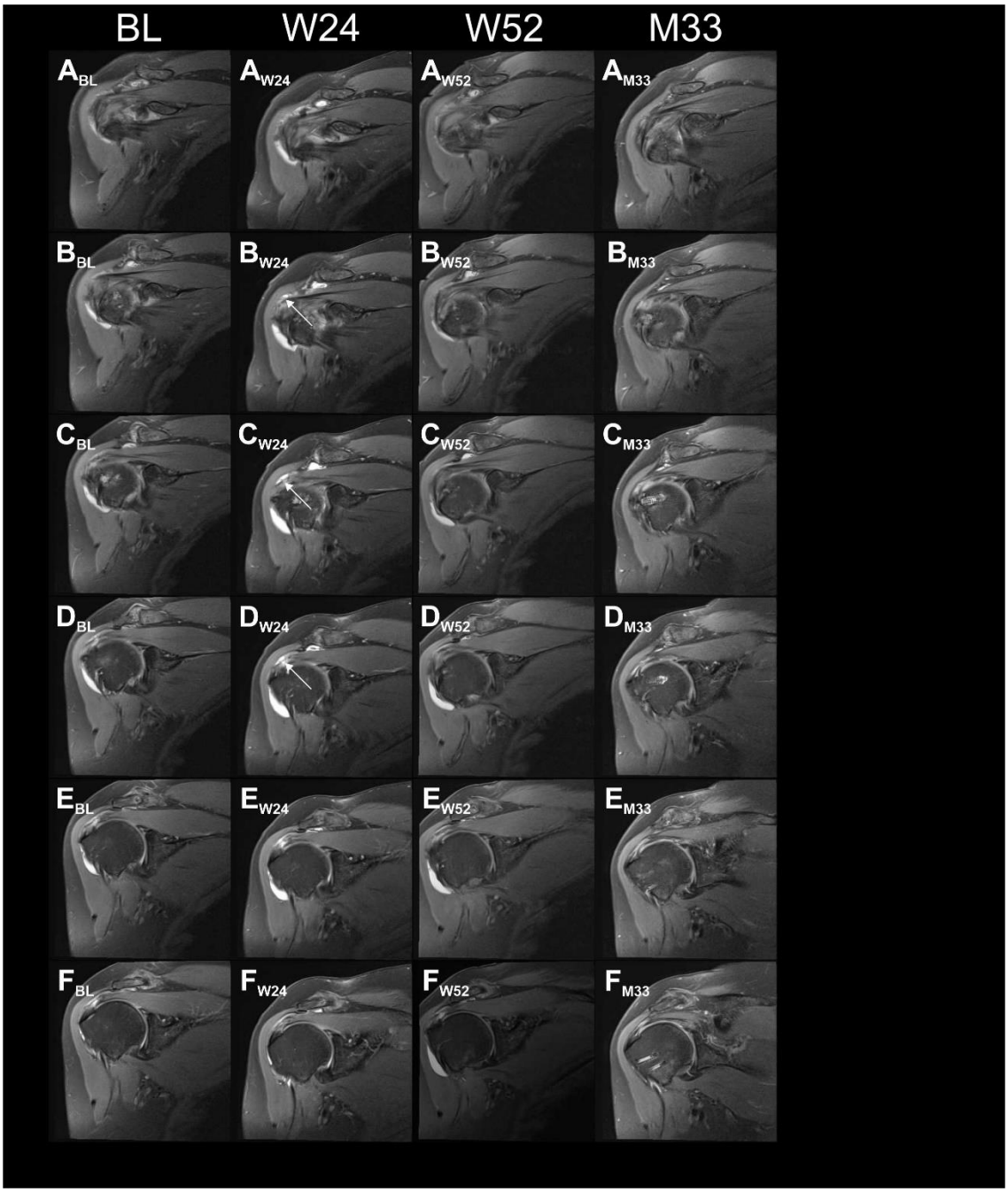

medRxiv preprint doi: https://doi.org/10.1101/2022.12.14.22283447; this version posted December 14, 2022. The copyright holder for this preprint **(which was not certified by peer review)** is the author/funder, who has granted medRxiv a license to display the preprint in perpetuity.

It is made available under a CC-BY 4.0 International license .

FIGURE S9 (cont.)

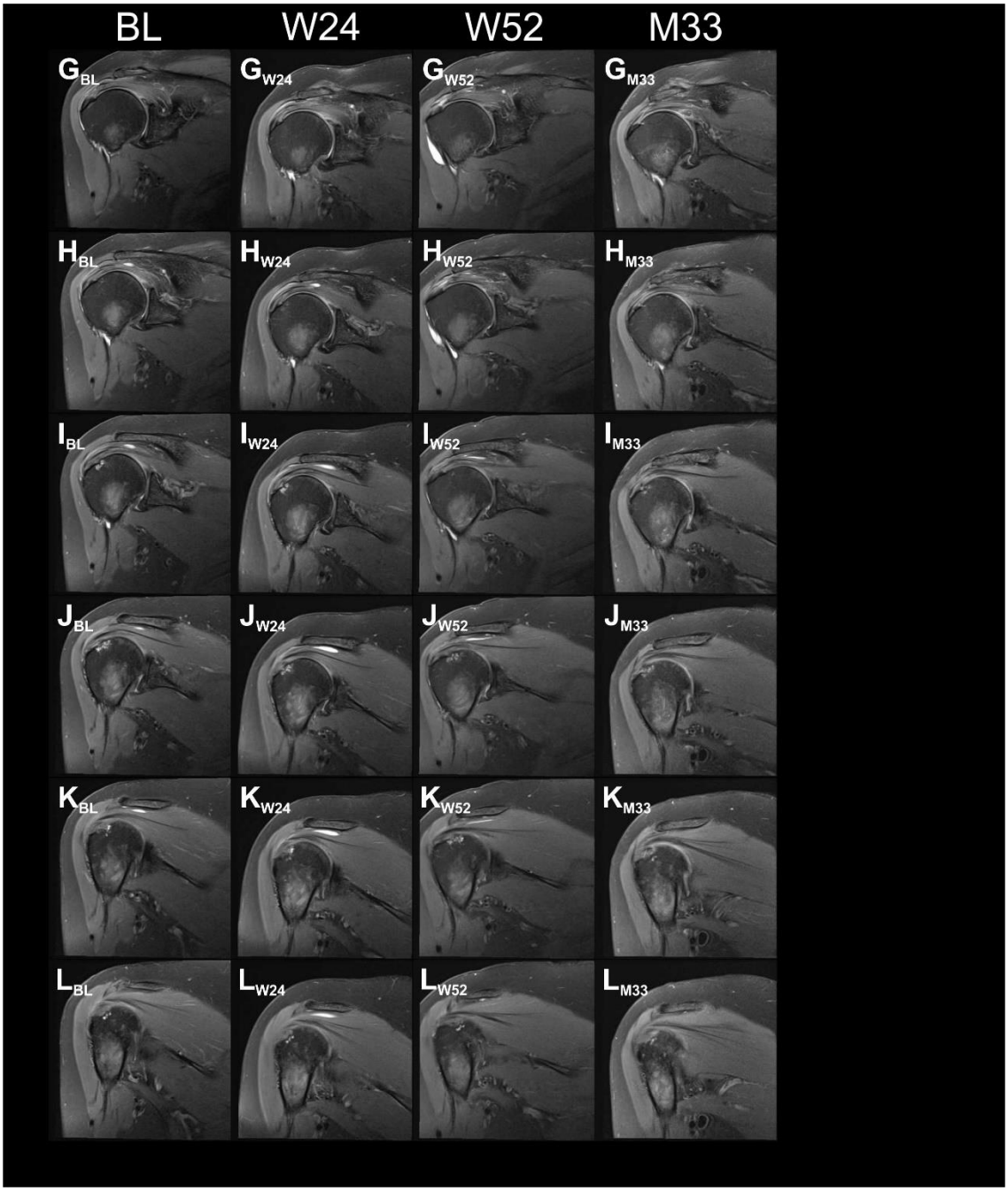

medRxiv preprint doi: https://doi.org/10.1101/2022.12.14.22283447; this version posted December 14, 2022. The copyright holder for this preprint **(which was not certified by peer review)** is the author/funder, who has granted medRxiv a license to display the preprint in perpetuity.

It is made available under a CC-BY 4.0 International license .

FIGURE S10. *Proton density weighted, fat saturated, T2-weighted, coronal magnetic resonance imaging (MRI) scans of the index shoulder of Subject A10 treated with injection of ADRCs, generated during the former study and the present study.*

Panels A-L show the same (or nearly the same) image planes at different times, with Panels A showing the most ventral image plane and Panels L the most dorsal image plane.

The yellow arrows in Panels C_{W24} and D_{W24} indicate a hyperintense structure at the position of the supraspinatus tendon that was found at 24 weeks post-treatment but not at baseline.

Abbreviations: BL, baseline; W24 / W52, 24 / 52 weeks post-treatment; M35 / M41, 35 / 41 months post-treatment.

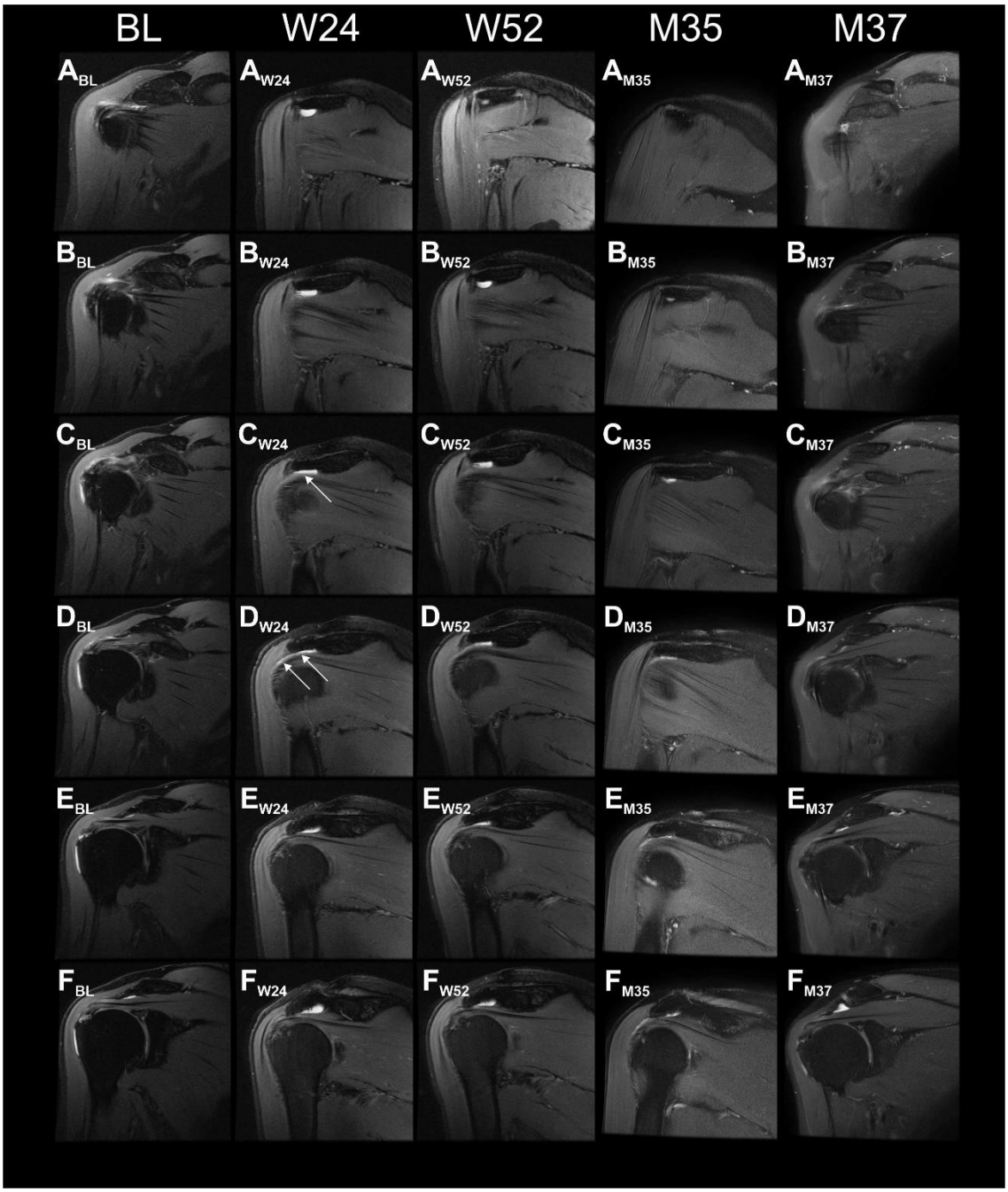

medRxiv preprint doi: https://doi.org/10.1101/2022.12.14.22283447; this version posted December 14, 2022. The copyright holder for this preprint **(which was not certified by peer review)** is the author/funder, who has granted medRxiv a license to display the preprint in perpetuity.

It is made available under a CC-BY 4.0 International license .

FIGURE S10 (cont.)

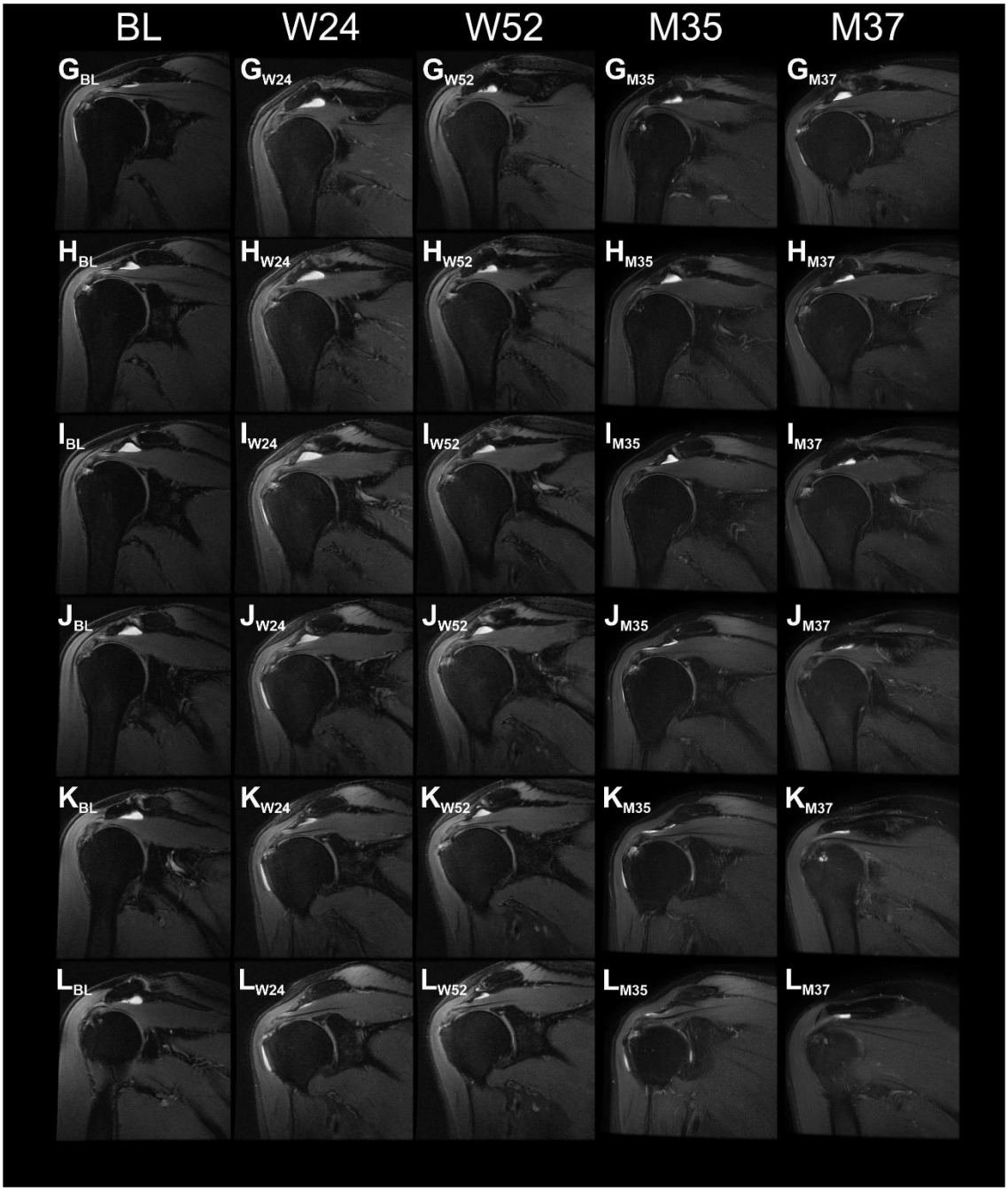

medRxiv preprint doi: https://doi.org/10.1101/2022.12.14.22283447; this version posted December 14, 2022. The copyright holder for this preprint **(which was not certified by peer review)** is the author/funder, who has granted medRxiv a license to display the preprint in perpetuity.

It is made available under a CC-BY 4.0 International license .

FIGURE S11. *Proton density weighted, fat saturated, T2-weighted, coronal magnetic resonance imaging (MRI) scans of the index shoulder of Subject A11 treated with injection of ADRCs, generated during the former study and the present study.*

Panels A-L show the same (or nearly the same) image planes at different times, with Panels A showing the most ventral image plane and Panels L the most dorsal image plane.

The yellow arrows in Panels C_{W24}, D_{W24}, H_{W24}, I_{W24}, J_{W24}, K_{W24} and L_{W24} indicate a hyperintense structure at the position of the supraspinatus tendon that was found at 24 weeks post-treatment but not at baseline.

Abbreviations: BL, baseline; W24 / W52, 24 / 52 weeks post-treatment; M33, 33 months post-treatment (note that no MRI was performed during the second visit of Subject A3).

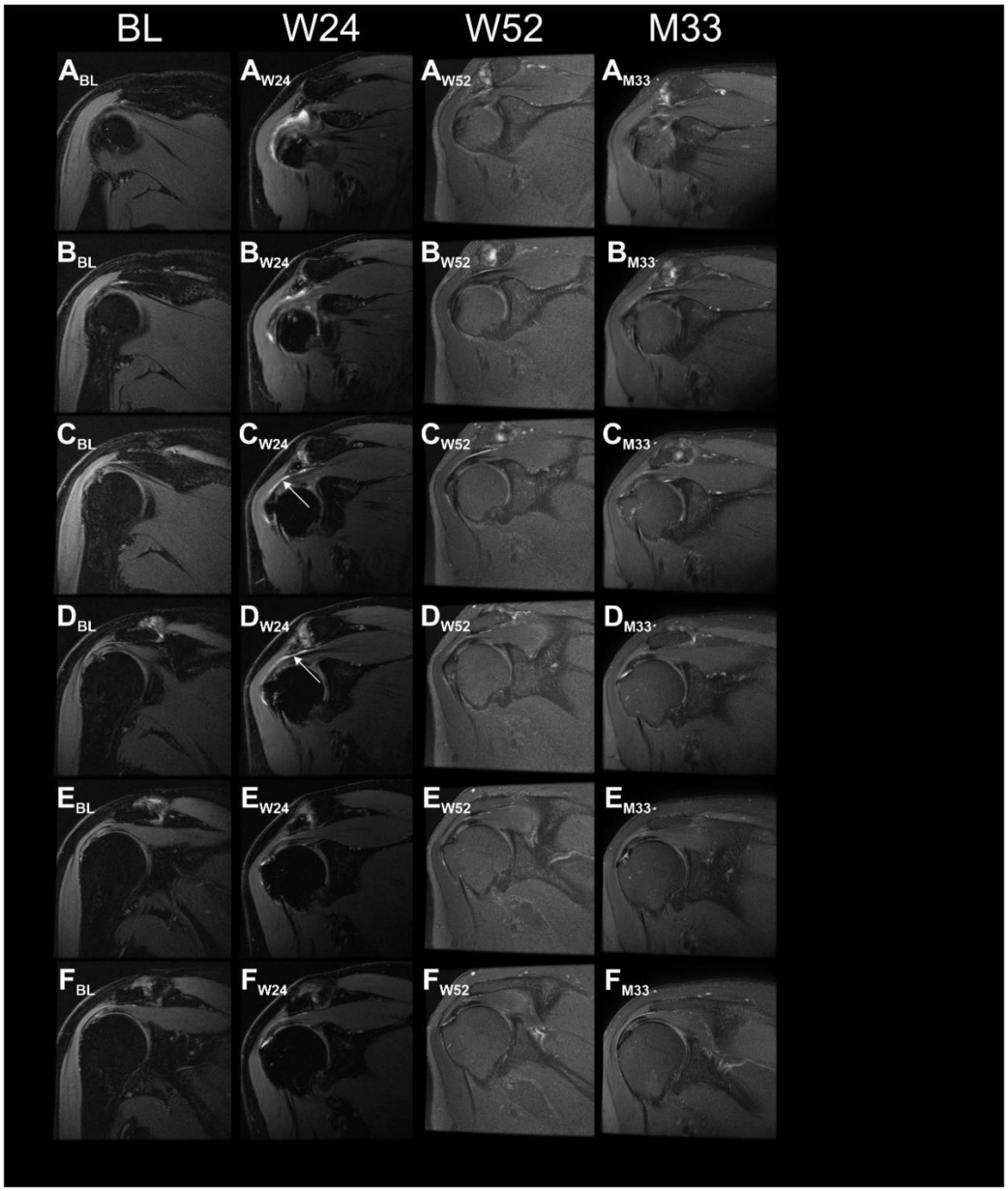

medRxiv preprint doi: https://doi.org/10.1101/2022.12.14.22283447; this version posted December 14, 2022. The copyright holder for this preprint **(which was not certified by peer review)** is the author/funder, who has granted medRxiv a license to display the preprint in perpetuity.

It is made available under a CC-BY 4.0 International license .

FIGURE S11 (cont.)

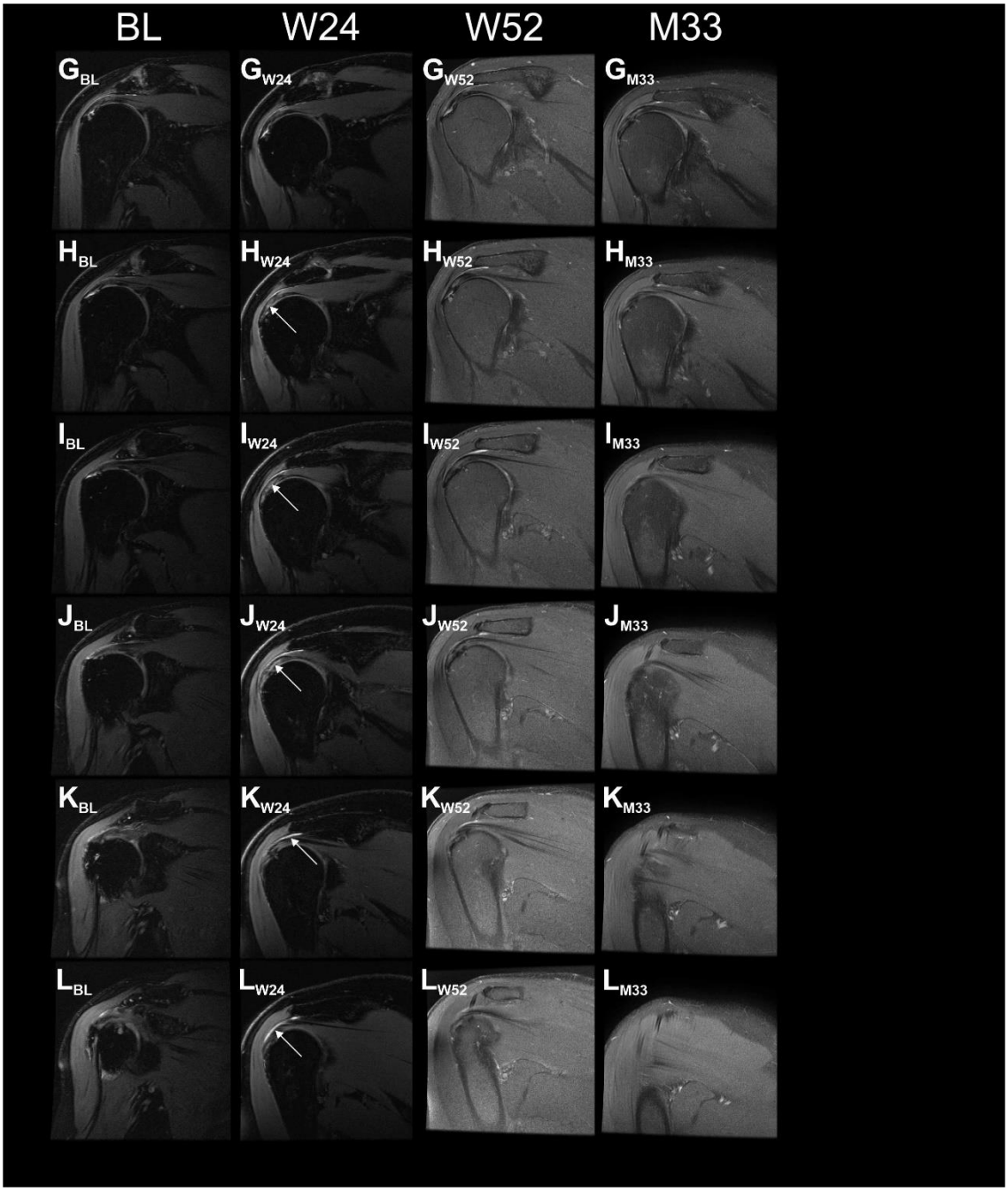

medRxiv preprint doi: https://doi.org/10.1101/2022.12.14.22283447; this version posted December 14, 2022. The copyright holder for this preprint **(which was not certified by peer review)** is the author/funder, who has granted medRxiv a license to display the preprint in perpetuity.

It is made available under a CC-BY 4.0 International license .

FIGURE S12. *Proton density weighted, fat saturated, T2-weighted, coronal magnetic resonance imaging (MRI) scans of the index shoulder of Subject C1 treated with injection of corticosteroid, generated during the former study and the present study.*

Panels A-L show the same (or nearly the same) image planes at different times, with Panels A showing the most ventral image plane and Panels L the most dorsal image plane.

Abbreviations: BL, baseline; W24 / W52, 24 / 52 weeks post-treatment; M33 / M41, 33 / 41 months post-treatment.

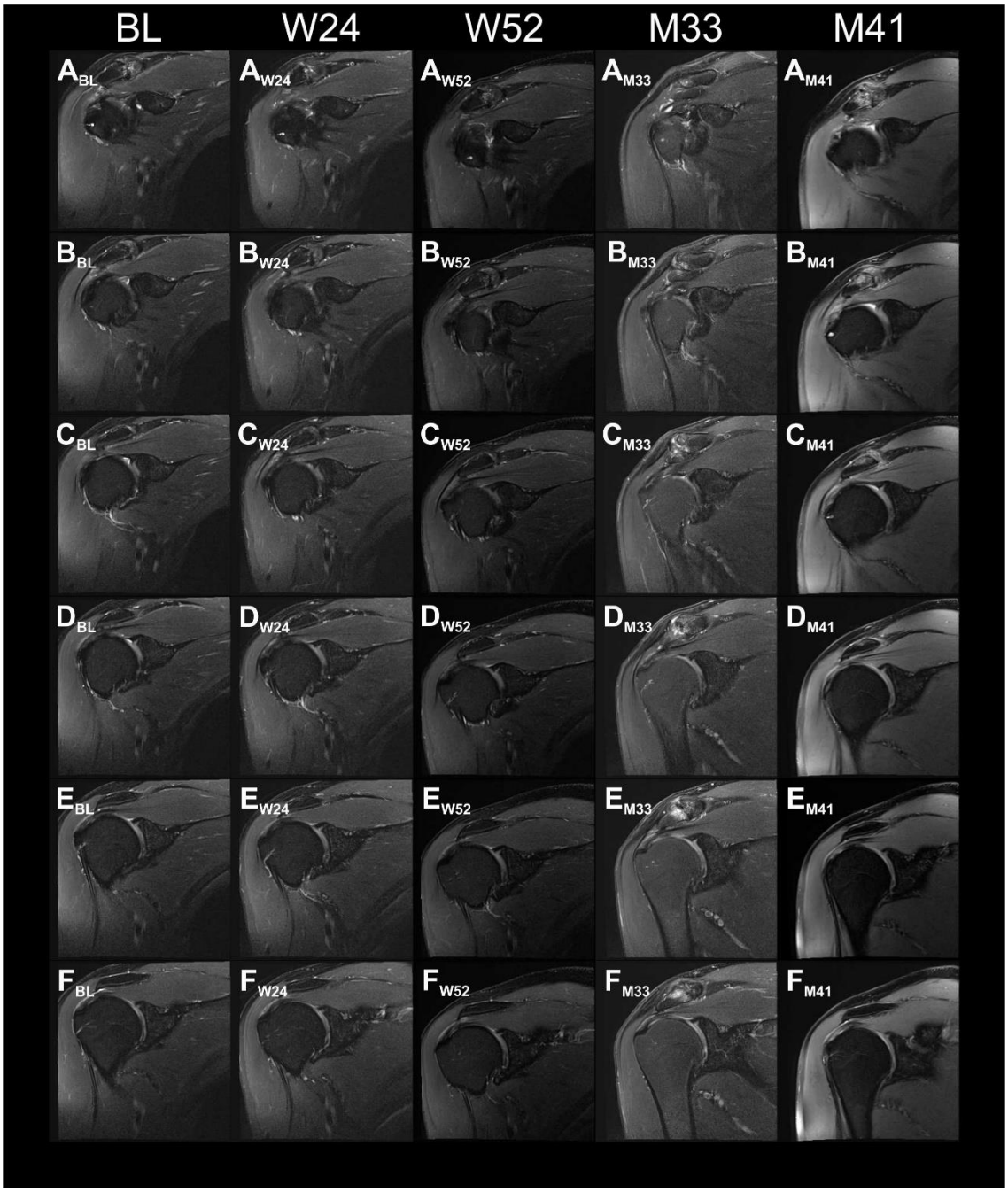

medRxiv preprint doi: https://doi.org/10.1101/2022.12.14.22283447; this version posted December 14, 2022. The copyright holder for this preprint **(which was not certified by peer review)** is the author/funder, who has granted medRxiv a license to display the preprint in perpetuity.

It is made available under a CC-BY 4.0 International license .

FIGURE S12 (cont.)

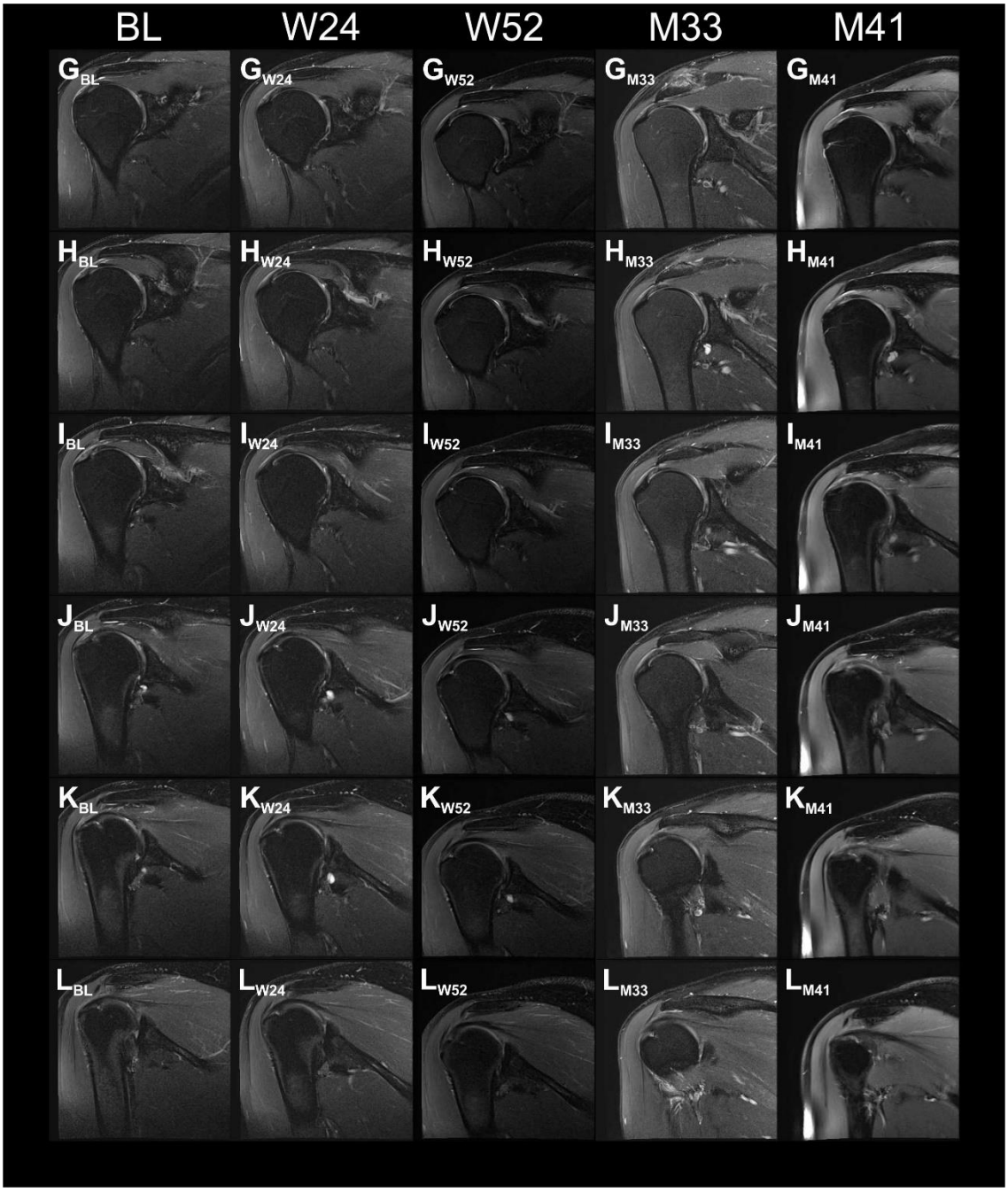

medRxiv preprint doi: https://doi.org/10.1101/2022.12.14.22283447; this version posted December 14, 2022. The copyright holder for this preprint **(which was not certified by peer review)** is the author/funder, who has granted medRxiv a license to display the preprint in perpetuity.

It is made available under a CC-BY 4.0 International license .

FIGURE S13. *Proton density weighted, fat saturated, T2-weighted, coronal magnetic resonance imaging (MRI) scans of the index shoulder of Subject C2 treated with injection of corticosteroid, generated during the former study and the present study.*

Panels A-L show the same (or nearly the same) image planes at different times, with Panels A showing the most ventral image plane and Panels L the most dorsal image plane.

Abbreviations: BL, baseline; W24 / W52, 24 / 52 weeks post-treatment; M34 / M42, 34 / 42 months post-treatment.

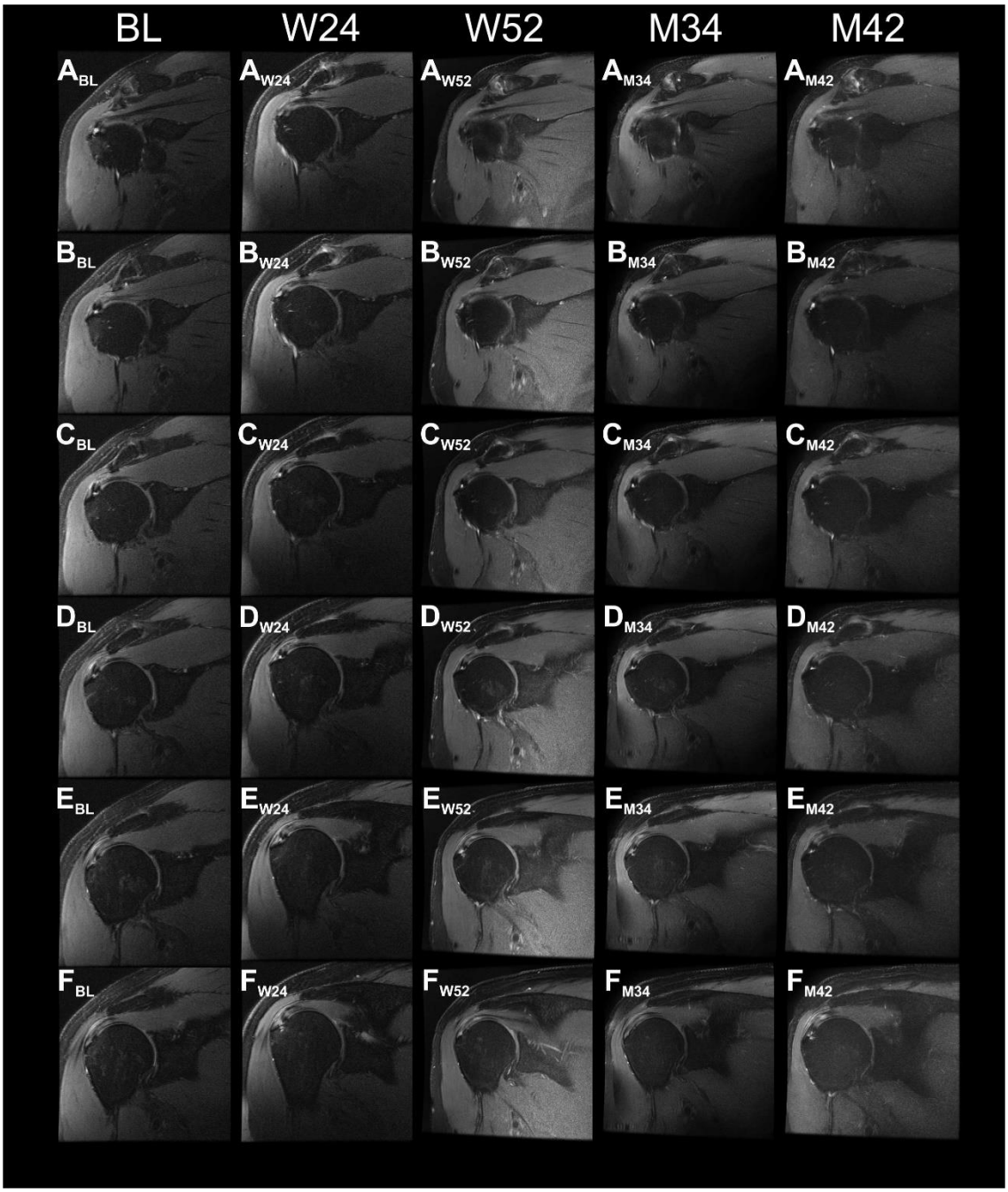

medRxiv preprint doi: https://doi.org/10.1101/2022.12.14.22283447; this version posted December 14, 2022. The copyright holder for this preprint **(which was not certified by peer review)** is the author/funder, who has granted medRxiv a license to display the preprint in perpetuity.

It is made available under a CC-BY 4.0 International license .

FIGURE S13 (cont.)

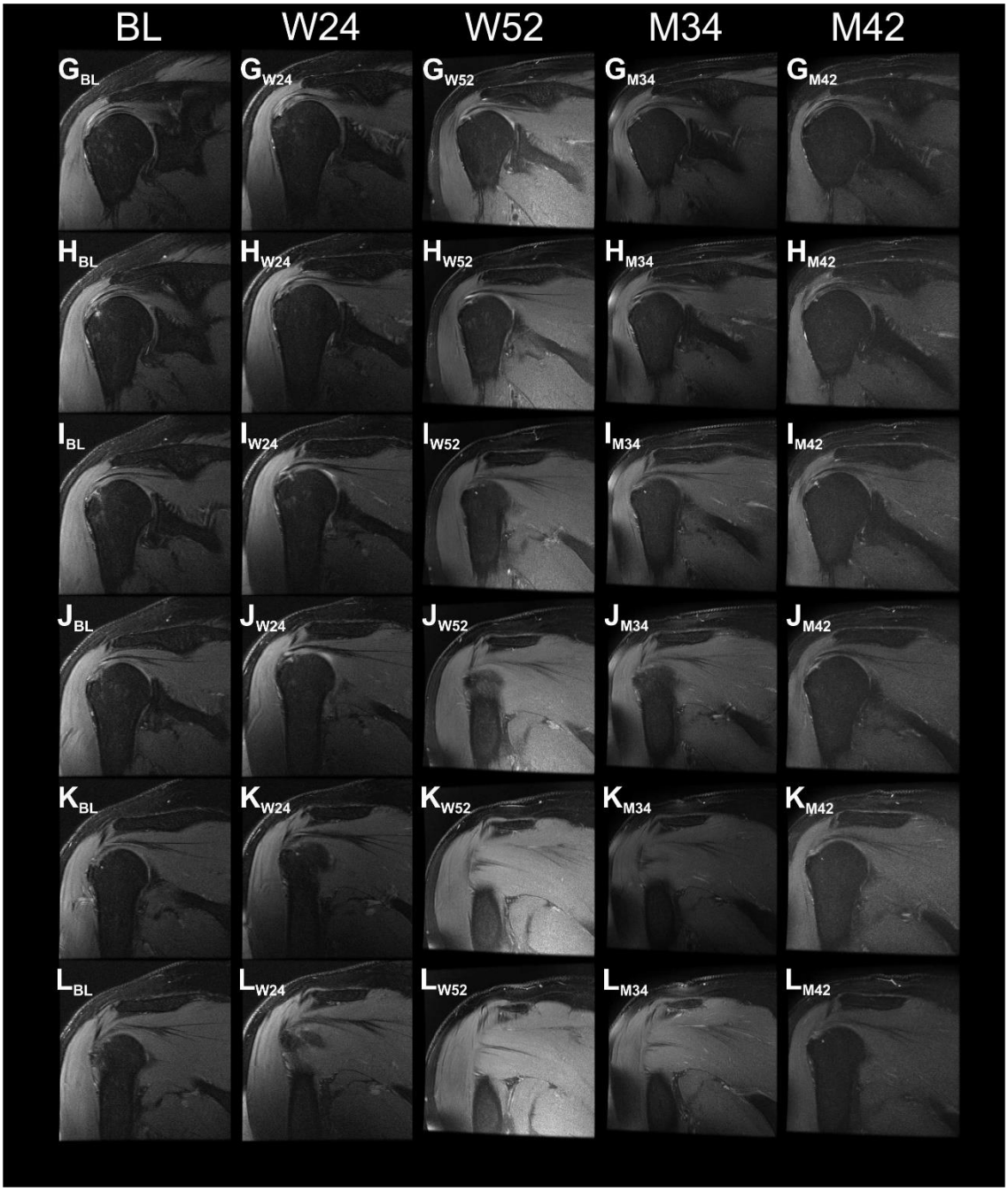

medRxiv preprint doi: https://doi.org/10.1101/2022.12.14.22283447; this version posted December 14, 2022. The copyright holder for this preprint **(which was not certified by peer review)** is the author/funder, who has granted medRxiv a license to display the preprint in perpetuity.

It is made available under a CC-BY 4.0 International license .

FIGURE S14. *Proton density weighted, fat saturated, T2-weighted, coronal magnetic resonance imaging (MRI) scans of the index shoulder of Subject C3 treated with injection of corticosteroid, generated during the former study and the present study.*

Panels A-L show the same (or nearly the same) image planes at different times, with Panels A showing the most ventral image plane and Panels L the most dorsal image plane.

Abbreviations: BL, baseline; W24 / W52, 24 / 52 weeks post-treatment; M33 / M41, 33 / 41 months post-treatment.

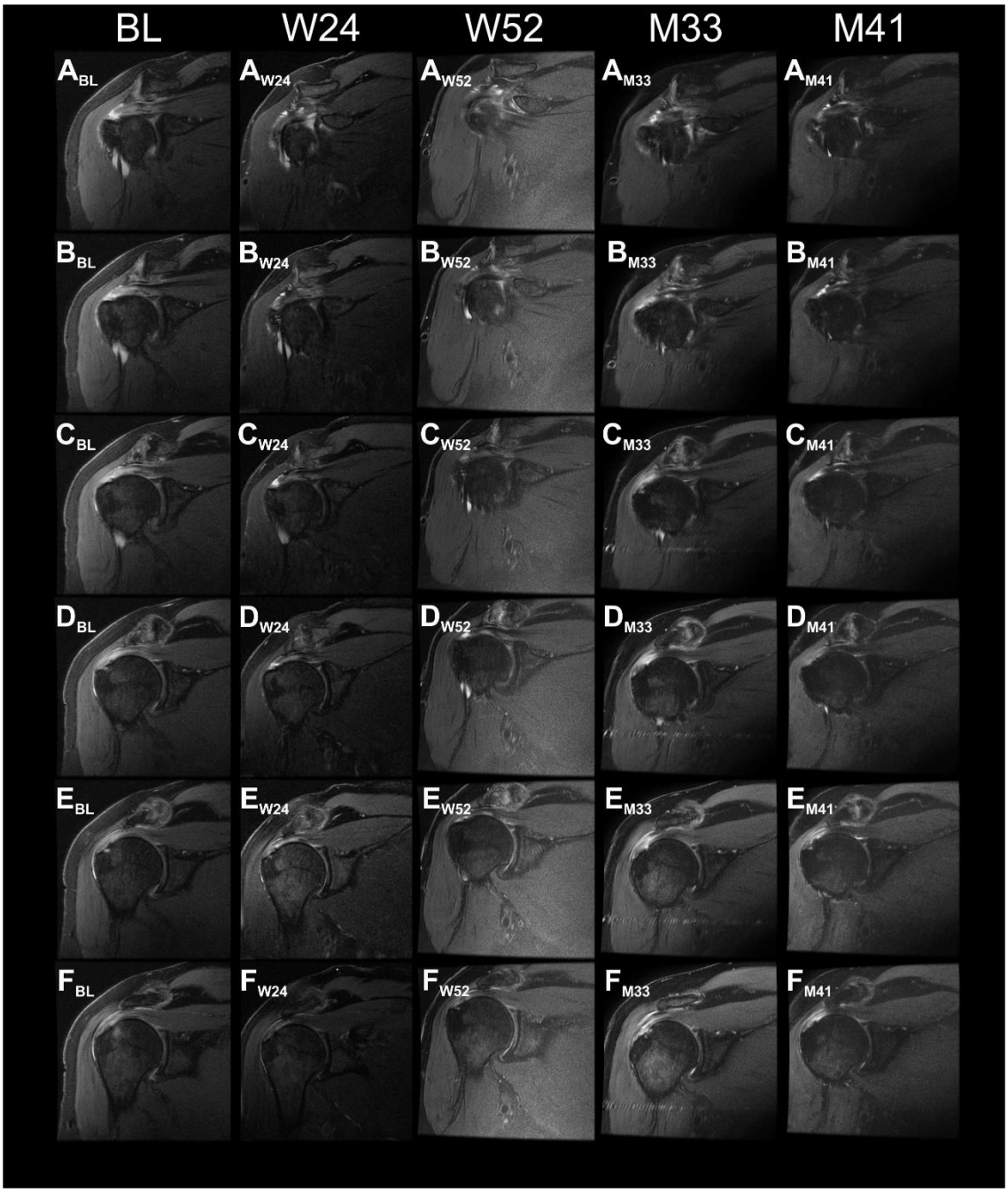

medRxiv preprint doi: https://doi.org/10.1101/2022.12.14.22283447; this version posted December 14, 2022. The copyright holder for this preprint **(which was not certified by peer review)** is the author/funder, who has granted medRxiv a license to display the preprint in perpetuity.

It is made available under a CC-BY 4.0 International license .

FIGURE S14 (cont.)

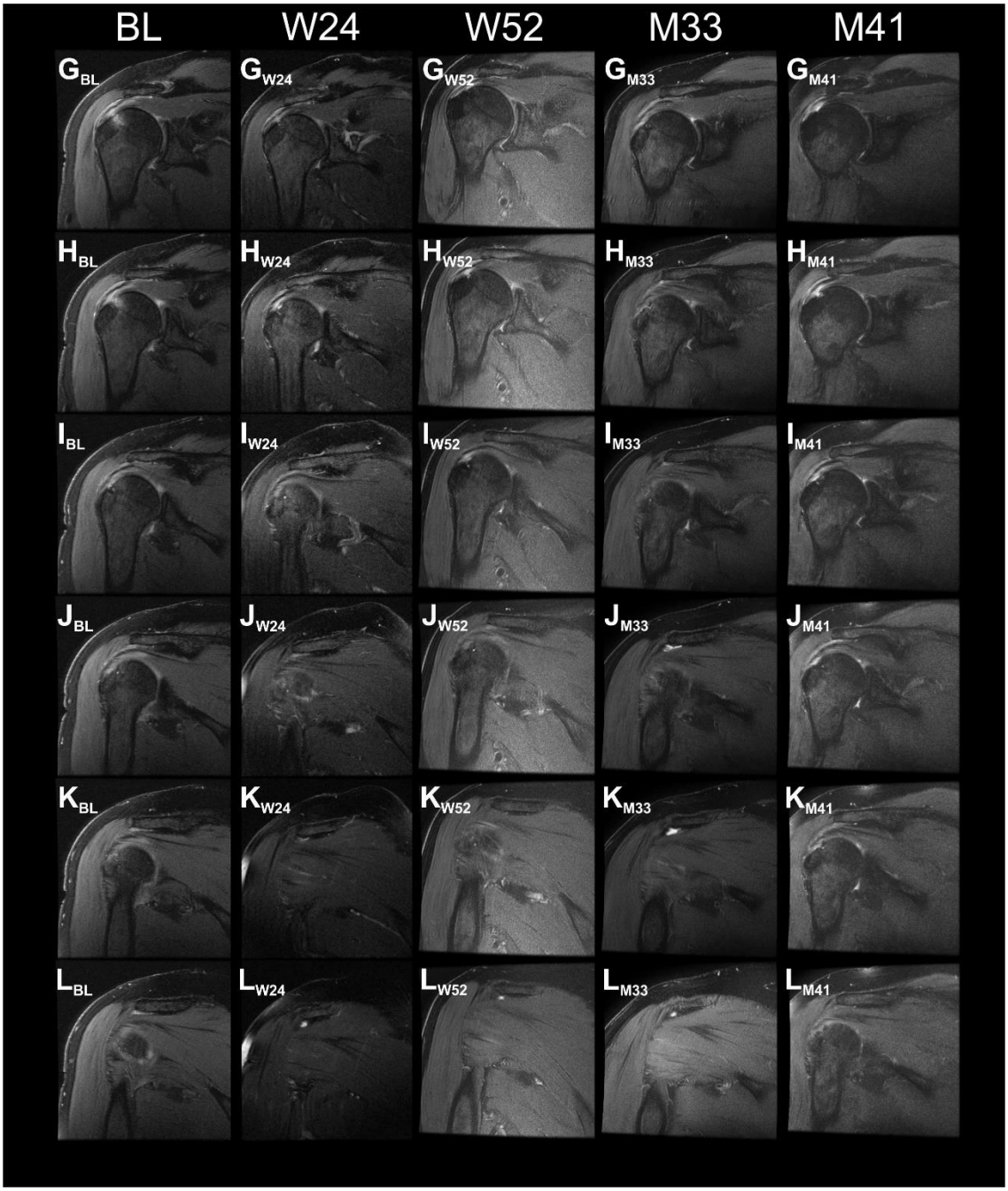

medRxiv preprint doi: https://doi.org/10.1101/2022.12.14.22283447; this version posted December 14, 2022. The copyright holder for this preprint **(which was not certified by peer review)** is the author/funder, who has granted medRxiv a license to display the preprint in perpetuity.

It is made available under a CC-BY 4.0 International license .

FIGURE S15. *Proton density weighted, fat saturated, T2-weighted, coronal magnetic resonance imaging (MRI) scans of the index shoulder of Subject C4 treated with injection of corticosteroid, generated during the former study and the present study.*

Panels A-L show the same (or nearly the same) image planes at different times, with Panels A showing the most ventral image plane and Panels L the most dorsal image plane.

Abbreviations: BL, baseline; W24 / W52, 24 / 52 weeks post-treatment; M35 / M40, 35 / 40 months post-treatment.

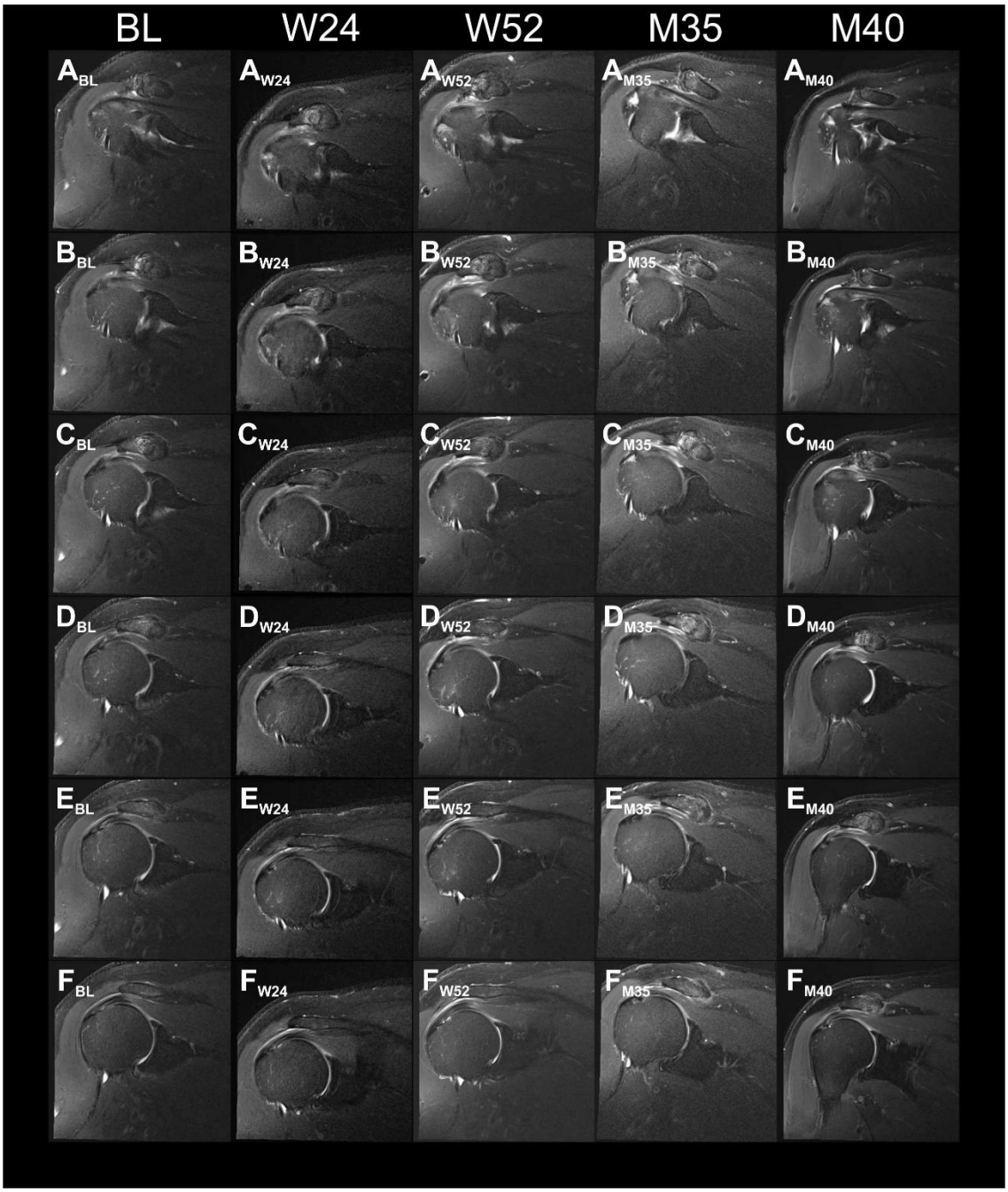

medRxiv preprint doi: https://doi.org/10.1101/2022.12.14.22283447; this version posted December 14, 2022. The copyright holder for this preprint **(which was not certified by peer review)** is the author/funder, who has granted medRxiv a license to display the preprint in perpetuity.

It is made available under a CC-BY 4.0 International license .

FIGURE S15 (cont.)

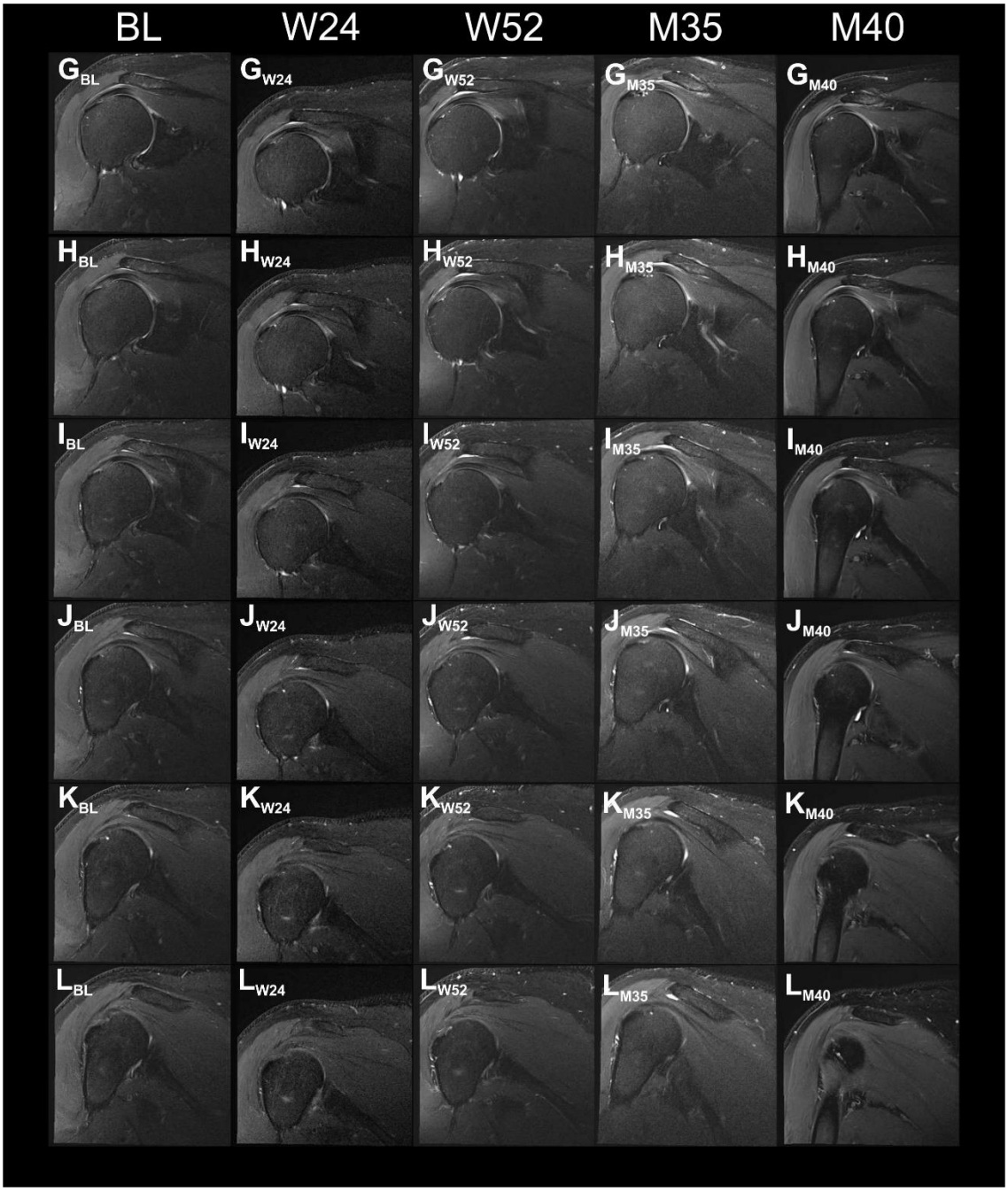

medRxiv preprint doi: https://doi.org/10.1101/2022.12.14.22283447; this version posted December 14, 2022. The copyright holder for this preprint (which was not certified by peer review) is the author/funder, who has granted medRxiv a license to display the preprint in perpetuity.

It is made available under a CC-BY 4.0 International license .

Part 2 – Treatment-emergent adverse events that occurred during the present study and the former study

2.1. Details of all treatment-emergent adverse events that occurred during the present study and the former study

Tables S1 and S2 provide details of all treatment emergent adverse events (TEAEs) reported in the present study and the former study, stratified by the relation to the investigated treatment, severity and month post-treatment during which the TEAEs occurred.

TABLE S1

Treatment-emergent adverse events reported by those subjects who were treated with injection of UA-ADRCs. Adverse events related to the index shoulder are given boldface.

Subject	M	Study	R	Severity	Descriptions/Comments
A11	0.1	F	Possible	Moderate	**Index arm pain[a]**
A3	0.0	F	Possible	Mild	Left mid-abdomen pain[a]
A5	0.0	F	Possible	Mild	Pain mid-abdomen[a]
A2	0.5	F	Possible	Mild	Cold[a]
A2	0.9	F	Unlikely	Moderate	Shortness of Breath[a]
A5	1.2	F	Unlikely	Moderate	Pulp necrosis with asymptomatic apical periodontitis Tooth #15[a]
A4	0.7	F	Unlikely	Mild	**Worsening index shoulder pain[a]**
A1	1.4	F	Unlikely	Mild	**Worsening index shoulder pain[a]**
A11	18.7	P	Unlikely	Mild	**Index shoulder pain[a]**
A1	25.5	P	Unlikely	Mild	**Index shoulder pain[a]**
A4	3.0	F	Not Related	Severe	Non ST elevation myocardial infarction[b]
A4	4.1	F	Not Related	Severe	ST elevation myocardial infarction[b]
A9	7.4	F	Not Related	Severe	**Index shoulder pain[b]**
A7	34.4	P	Not Related	Severe	Ganglion cyst of the non-index shoulder[b]
A7	1.3	F	Not Related	Moderate	Concussion
A6	1.9	F	Not Related	Moderate	Worsening tendonitis left wrist
A9	7.6	F	Not Related	Moderate	Bronchitis
A7	8.0	F	Not Related	Moderate	Esophageal dysphagia
A7	9.7	F	Not Related	Moderate	Chronic obstructive lung disease
A1	9.8	F	Not Related	Moderate	Diverticulitis
A7	12.0	F	Not Related	Moderate	Shortness of breath
A3	33.5	P	Not Related	Moderate	**Index shoulder pain[c]**
A4	34.2	P	Not Related	Moderate	Interstitial pneumonia
A8	34.9	P	Not Related	Moderate	Alcoholic relapse
A4	36.8	P	Not Related	Moderate	Right leg pain
A8	38.7	P	Not Related	Moderate	Dyspnea
A7	40.4	P	Not Related	Moderate	Muscle spasms
A9	-0.3	F	Not Related	Mild	Asthmatic bronchitis
A9	0.3	F	Not Related	Mild	Left knee pain
A8	0.6	F	Not Related	Mild	Dysuria
A9	1.0	F	Not Related	Mild	Contusion of right elbow
A3	1.1	F	Not Related	Mild	Worsening lower back pain
A7	1.6	F	Not Related	Mild	Sinusitis
A2	2.1	F	Not Related	Mild	Worsening allergic rhinitis
A7	2.8	F	Not Related	Mild	Abdominal discomfort

medRxiv preprint doi: https://doi.org/10.1101/2022.12.14.22283447; this version posted December 14, 2022. The copyright holder for this preprint **(which was not certified by peer review)** is the author/funder, who has granted medRxiv a license to display the preprint in perpetuity.

It is made available under a CC-BY 4.0 International license .

TABLE S1 (cont.)

Subject	M	Study	R	Severity	Descriptions/Comments
A11	3.9	F	Not Related	Mild	Left hand pain
A10	4.1	F	Not Related	Mild	Toenail thickening and discoloration
A10	4.1	F	Not Related	Mild	Seborrheic keratosis
A2	4.2	F	Not Related	Mild	Essential hypertension
A1	4.4	F	Not Related	Mild	Pharyngitis
A8	4.6	F	Not Related	Mild	Relapse of alcohol dependence
A11	4.6	F	Not Related	Mild	Staph infection of fourth ray
A7	5.5	F	Not Related	Mild	Acute pain left shoulder
A8	6.8	F	Not Related	Mild	Left foot pain
A11	31.4	P	Not Related	Mild	influenza
A9	32.7	P	Not Related	Mild	**Device material fragmentation in index shoulder[b]**
A10	34.1	P	Not Related	Mild	Epigastric pain
A4	34.3	P	Not Related	Mild	Sleep apnea
A9	35.7	P	Not Related	Mild	Bronchhitis
A11	36.7	P	Not Related	Mild	Sleep disturbance
A11	36.7	P	Not Related	Mild	Tinnitus
A11	36.7	P	Not Related	Mild	Hearing loss
A8	37.2	P	Not Related	Mild	Acute cystitis
A9	39.5	P	Not Related	Mild	Bursal hematoma left knee
A4	40.4	P	Not Related	Mild	Benign prostatic hyperplasia
A5	40.6	P	Not Related	Mild	Cataract
A5	40.9	P	Not Related	Mild	Back pain
A7	41,4	P	Not Related	Mild	Baclofen allergy

Abbreviations: UA-ADRCs, fresh, uncultured, unmodified, autologous, adipose-derived regenerative cells; M, month post-treatment when the treatment-emergent adverse event started; F, former study; P, present study; R, relation to the investigated treatment.

[a]*, outlined in detail in Table S8.*

[b]*, outlined in detail in Table S13.*

[c]*, this subject reported at 33.3 months post-treatment that he was doing very well until about 30.3 months post-treatment. At this time he moved into a new house and was doing a lot of work that involved repetitive use of his right (index) arm. He started to have increased pain in his right shoulder. Because of this he had a recent subacromial corticosteroid injection (i.e., before the first study visit). At the time of the first study visit he had no pain in his right shoulder.*

medRxiv preprint doi: https://doi.org/10.1101/2022.12.14.22283447; this version posted December 14, 2022. The copyright holder for this preprint **(which was not certified by peer review)** is the author/funder, who has granted medRxiv a license to display the preprint in perpetuity.

It is made available under a CC-BY 4.0 International license .

TABLE S2

Treatment-emergent adverse events reported by those subjects who were treated with injection of corticosteroid. Adverse events related to the index shoulder are given boldface.

Subject	M	Study	R	Severity	Descriptions/Comments
C4	1.4	F	Possible	Moderate	**Anterior pain in index shoulder[a]**
C2	1.6	F	Possible	Moderate	**Worsening index shoulder pain[a]**
C2	0.1	F	Unlikely	Mild	Pharyngitis[a]
C5[b]	2.1	F	Unlikely	Mild	**Worsening index shoulder pain[a]**
C3	5.2	F	Unlikely	Mild	**Worsening index shoulder pain[a]**
C3	1.0	F	Not Related	Moderate	Biceps tear at elbow
C2	5.4	F	Not Related	Moderate	Right upper broken tooth
C1	36.1	P	Not Related	Moderate	Multilevel lumbar degenerative disc disease
C2	38.2	P	Not Related	Moderate	Actinic keratoses
C2	38.2	P	Not Related	Moderate	Squamous cell carcinoma of skin, left neck
C2	38.2	P	Not Related	Moderate	Basal cell carcinoma, left inferior neck
C5[b]	0.7	F	Not Related	Mild	Coronary artery disease
C3	1.1	F	Not Related	Mild	Left finger sprain
C2	3.7	F	Not Related	Mild	Hip Pain
C1	4.8	F	Not Related	Mild	Chest pain
C2	4.8	F	Not Related	Mild	Cough
C2	32.3	P	Not Related	Mild	**Index shoulder pain[c]**
C4	32.3	P	Not Related	Mild	Upper respiratory infection
C3	34.9	P	Not Related	Mild	Benign skin lesion
C1	35.3	P	Not Related	Mild	Otitis media
C4	36.5	P	Not Related	Mild	Hypogammaglobulinemi[a]
C1	37.2	P	Not Related	Mild	**Index shoulder pain[d]**
C2	37.8	P	Not Related	Mild	Nausea
C2	40.5	P	Not Related	Mild	Lymphadenopathy
C2	40.5	P	Not Related	Mild	Atrial fibrillation

Abbreviations: M, month post-treatment when the treatment-emergent adverse event started; F, former study; P, present study; R, relation to the investigated treatment.

[a], outlined in detail in Table S9.

[b], this subject was enrolled in the former study but not in the present study.

[c], this subject fell off a ladder at 32.3 months post-treatment. He reported increased pain and discomfort and difficulty with overhead activity. An MRI performed during the second study visit at 33.3 months post-treatment revealed a full thickness tear of anterior superior fibers of the supraspinatus tendon. An MRI performed during the second study visit at 41.2 months post-treatment showed a near full thickness tear of the anterosuperior fibers of the supraspinatus tendon.

[d], this subject reported pain in his left shoulder at 37.2 months post-treatment that kept him awake at night; he was unable to sleep on his left side.

medRxiv preprint doi: https://doi.org/10.1101/2022.12.14.22283447; this version posted December 14, 2022. The copyright holder for this preprint (which was not certified by peer review) is the author/funder, who has granted medRxiv a license to display the preprint in perpetuity.

It is made available under a CC-BY 4.0 International license .

2.2. Statistical analysis of all treatment-emergent adverse events that occurred during the present study and the former study

The total number of TEAEs was 83, of which 58 (69.9%) occurred in the UA-ADRCs group and 25 (30.1%) in the corticosteroid group (Tables S1 and S2). Accordingly, the average number of TEAEs per subject was 5.3 ± 2.7 (mean ± standard error of the mean) in the UA-ADRCs group and 5.0 ± 1.8 in the corticosteroid group.

The distribution of these 83 TEAEs with regard to severity and relation to the investigated treatment was as follows: there were…

- four severe TEAEs (4.8%), none of which were related to the investigated treatment (all in the UA-ADRCs group),
- three moderate TEAEs probably related to the investigated treatment (3.6%) (one in the UA-ADRCs group and two in the corticosteroid group),
- three mild TEAEs probably related to the investigated treatment (3.6%) (all in the UA-ADRCs group),
- two moderate TEAEs unlikely to be related to the investigated treatment (2.4%) (all in the UA-ADRCs group),
- seven mild TEAEs unlikely to be related to the investigated treatment (8.4%) (four in the UA-ADRCs group and three in the corticosteroid group),
- 19 moderate TEAEs not related to the investigated treatment (22.9%), and
- 45 mild TEAEs not related to the investigated treatment (54.2%).

Table S3 shows group-specific numbers of subjects who experienced a certain number of TEAEs (between 0 and 12) in the present study and the former study.

TABLE S3

Group-specific numbers of subjects who experienced a certain number of treatment-emergent adverse events (between 0 and 12) in the present study and the former study.

TP	Group	Number of TEAEs												
		0	1	2	3	4	5	6	7	8	9	10	11	12
BL-W24	UA-ADRCs	0	1	5	3	2	0	0	0	0	0	0	0	0
BL-FSV	UA-ADRCs	0	1	3	2	3	0	1	1	0	0	0	0	0
BL-SSV	UA-ADRCs	0	1	0	2	3	0	1	1	2	0	1	0	0
BL-W24	C	0	2	1	1	0	1	0	0	0	0	0	0	0
BL-FSV	C	0	1	2	1	0	0	1	0	0	0	0	0	0
BL-SSV	C	0	0	1	1	2	0	0	0	0	0	0	0	1

Abbreviations: TP, time period; BL, baseline; W24, study visit scheduled in the former study at 24 weeks post-treatment; FSV, first study visit of the present study; SSV, second study visit of the present study; UA-ADRCs, treatment with a single injection of fresh, uncultured, unmodified, autologous, adipose-derived regenerative cells; C, treatment with a single injection of corticosteroid.

For all investigated time periods there was no statistically significant difference between the groups with regard to the numbers of subjects who experienced a certain number of TEAEs (between 0 and 12) in the present study and the former study (Chi-square test for trend):

- from baseline to W24 in the former study: $p = 0.809$,
- from baseline to the first study visit of the present study: $p = 0.488$, and
- from baseline to the second study visit of the present study: $p = 0.778$.

medRxiv preprint doi: https://doi.org/10.1101/2022.12.14.22283447; this version posted December 14, 2022. The copyright holder for this preprint **(which was not certified by peer review)** is the author/funder, who has granted medRxiv a license to display the preprint in perpetuity.

It is made available under a CC-BY 4.0 International license .

Table S4 shows group-specific numbers of TEAEs that were classified as {mild / moderate / severe} in the present study and the former study. Table S5 summarizes absolute numbers of all TEAEs reported in the present study and the former study, stratified by the relation to the investigated treatment, severity and time period during which the TEAEs occurred. Table S6 summarizes the corresponding mean numbers of TEAEs per subject in each group.

TABLE S4

Group-specific numbers of TEAEs that were classified as {mild / moderate / severe} in the present study and the former study .

TP	Group	Classification of TEAEs		
		Mild	Moderate	Severe
BL-W24	UA-ADRCs	21	5	2
BL-FSV	UA-ADRCs	25	10	3
BL-SSV	UA-ADRCs	38	16	4
BL-W24	C	8	4	0
BL-FSV	C	10	4	0
BL-SSV	C	17	8	0

Abbreviations: TP, time period; BL, baseline; W24, study visit scheduled in the former study at 24 weeks post-treatment; FSV, first study visit of the present study; SSV, second study visit of the present study; UA-ADRCs, treatment with a single injection of fresh, uncultured, unmodified, autologous, adipose-derived regenerative cells; C, treatment with a single injection of corticosteroid.

For all investigated time periods there was no statistically significant difference between the groups with regard to the numbers of TEAEs that were classified as {mild / moderate / severe} in the present study and the former study (Chi-square test for trend):

- from baseline to W24 in the former study: $p = 0.951$,
- from baseline to the first study visit of the present study: $p = 0.468$, and
- from baseline to the second study visit of the present study: $p = 0.497$.

TABLE S5

Absolute numbers of TEAEs reported in the present study and the former study, stratified by the relation to the investigated treatment, severity and time period during which the TEAEs occurred.

TP	Group	P-se	P-mo	P-mi	U-se	U-mo	U-mi	NR-se	NR-mo	NR-mi
BL-W24	UA-ADRCs	0	1	3	0	2	2	2	2	16
BL-FSV	UA-ADRCs	0	1	3	0	2	4	3	7	18
BL-SSV	UA-ADRCs	0	1	3	0	2	4	4	13	31
BL-W24	C	0	2	0	0	0	3	0	2	5
BL-FSV	C	0	2	0	0	0	3	0	2	7
BL-SSV	C	0	2	0	0	0	3	0	6	14

Abbreviations: TP, time period; BL, baseline; W24, study visit scheduled in the former study at 24 weeks post-treatment; FSV, first study visit of the present study; SSV, second study visit of the present study; UA-ADRCs, treatment with a single injection of fresh, uncultured, unmodified, autologous, adipose-derived regenerative cells; C, treatment with a single injection of corticosteroid; P, relation to the investigated treatment probable; U, relation to the investigated treatment unlikely; NR, no relation to the investigated treatment; se, severe, mo, moderate; mi, mild.

medRxiv preprint doi: https://doi.org/10.1101/2022.12.14.22283447; this version posted December 14, 2022. The copyright holder for this preprint (which was not certified by peer review) is the author/funder, who has granted medRxiv a license to display the preprint in perpetuity.

It is made available under a CC-BY 4.0 International license .

TABLE S6

Group-specific mean numbers of treatment-emergent adverse events per subject reported in the present study and the former study, stratified by the relation to the investigated treatment, severity and time period during which the TEAEs occurred.

TP	Group	P-se	P-mo	P-mi	U-se	U-mo	U-mi	NR-se	NR-mo	NR-mi
BL-W24	UA-ADRCs	0	0.09	0.27	0	0.18	0.18	0.18	0.18	1.45
BL-FSV	UA-ADRCs	0	0.09	0.27	0	0.18	0.36	0.27	0.64	1.64
BL-SSV	UA-ADRCs	0	0.09	0.27	0	0.18	0.36	0.36	1.18	2.82
BL-W24	C	0	0.40	0	0	0	0.60	0	0.40	1.00
BL-FSV	C	0	0.40	0	0	0	0.60	0	0.40	1.40
BL-SSV	C	0	0.40	0	0	0	0.60	0	1.20	2.80

Abbreviations: TP, time period; BL, baseline; W24, study visit scheduled in the former study at 24 weeks post-treatment; FSV, first study visit of the present study; SSV, second study visit of the present study; UA-ADRCs, treatment with a single injection of fresh, uncultured, unmodified, autologous, adipose-derived regenerative cells; C, treatment with a single injection of corticosteroid; P, relation to the investigated treatment probable; U, relation to the investigated treatment unlikely; NR, no relation to the investigated treatment; se, severe, mo, moderate; mi, mild.

Table S7 shows group-specific numbers of TEAEs that were classified as {not related / unlikely to be related / possibly related / probably related / definitely related} to the investigated treatment in the present study and the former study. Tables S8 and S9 summarize the individual courses of all TEAEs classified as {unlikely to be / possibly} related to the investigated treatment that occurred during the present study and the former study, experienced by those subjects who were treated with injection of UA-ADRCs (Table 8) and those subjects who were treated with injection of corticosteroid (Table S9).

TABLE S7

Group-specific numbers of TEAEs that were classified as {not related / unlikely to be related / possibly related / probably related / definitely related} to the investigated treatment in the present study and the former study.

TP	Group	Classification of TEAEs				
		not related	unlikely to be related	possibly related	probably related	pefinitely related
BL-W24	UA-ADRCs	20	4	4	0	0
BL-FSV	UA-ADRCs	28	6	4	0	0
BL-SSV	UA-ADRCs	48	6	4	0	0
BL-W24	C	7	3	2	0	0
BL-FSV	C	9	3	2	0	0
BL-SSV	C	20	3	2	0	0

Abbreviations: TP, time period; BL, baseline; W24, study visit scheduled in the former study at 24 weeks post-treatment; FSV, first study visit of the present study; SSV, second study visit of the present study; UA-ADRCs, treatment with a single injection of fresh, uncultured, unmodified, autologous, adipose-derived regenerative cells; C, treatment with a single injection of corticosteroid.

For all investigated time periods there was no statistically significant difference between the groups with regard to the numbers of TEAEs that were classified as {not related / unlikely to be related / possibly related / probably related / definitely related} to the investigated treatment in the present study and the former study (Chi-square test):

medRxiv preprint doi: https://doi.org/10.1101/2022.12.14.22283447; this version posted December 14, 2022. The copyright holder for this preprint **(which was not certified by peer review)** is the author/funder, who has granted medRxiv a license to display the preprint in perpetuity.

It is made available under a CC-BY 4.0 International license .

- from baseline to W24 in the former study: p = 0.672,
- from baseline to the first study visit of the present study: p = 0.802, and
- from baseline to the second study visit of the present study: p = 0.956.

TABLE S8

Individual courses of the treatment-related adverse events classified as {unlikely to be / possibly related} to the investigated treatment that occurred during the present study and the former study, experienced by those subjects who were treated with injection of UA-ADRCs.

M	Event
Subject A1: worsening index shoulder pain (first TEAE of Subject A1), classified as *mild* and *unlikely* related to the investigated treatment	
1.4	Subject woke up in the morning of this day with worsening pain in left (index) shoulder. The pain lasted about 4-6 hours and was then back to baseline. No action was taken by the subject to alleviate the pain.
Subject A1: index shoulder pain (second TEAE of Subject A1), classified as *mild* and *unlikely* related to the investigated treatment	
28.4	Subject reported development of pain in the lateral index (left) shoulder over the past few months. Pain was worse with lifting or overhead movement. The subject received a subacromial corticosteroid injection at this time.
32.9	Subject rated shoulder pain 3-4/10 during an office visit and received another subacromial corticosteroid injection.
34.7	Subject reported left shoulder pain 0/10 but expressed interest in proceeding with left shoulder rotator cuff repair during the next few months.
36.5	Subject reported that he started having left shoulder pain at night and treating with Tylenol as needed.
36.8	Subject underwent left shoulder arthroscopy with subacomial decompression and rotator cuff repair.
37.5	The coordinator followed up with the subject who reported that the left shoulder pain at night had resolved since surgery.
39.7	Subject reported a muscle knot in the left arm with pain during therapy and other times. Tissue massage, ultrasound and electrical stimulation did not help much. The subject exhausted post-op physical therapy sessions.
43.0	Subject transitioned to occupational therapy to continue work on the left shoulder for range of motion and strength.
Subject A2: cold (first TEAE of Subject A2), classified as *mild* and *possibly* related to the investigated treatment	
0.5	Subject reported cough and cold signs and symptoms. There was no fever. The subject took Airborn and Mucinex for a few days and both symptoms and cold went away.

medRxiv preprint doi: https://doi.org/10.1101/2022.12.14.22283447; this version posted December 14, 2022. The copyright holder for this preprint **(which was not certified by peer review)** is the author/funder, who has granted medRxiv a license to display the preprint in perpetuity.

It is made available under a CC-BY 4.0 International license .

TABLE S8 (cont.)

M	Event
Subject A2: shortness of breath (second TEAE of Subject A2), classified as *moderate* and *unlikely* related to the investigated treatment	
0.9	Subject was seen in the emergency room (ER) for shortness of breath on 03/29/2017. EKG, chest X'ray and laboratory tests were unremarkable. Prednisone, Aspirin, normal saline and Solumedrol were given during the ER visit. The subject was sent home with a 5 day course of prednisone.
1.4	Subject reported continuous shortness of breath.
2.0	Subject reported that shortness of breath was not resolved but improving.
2.7	Subject reported that the shortness of breath continued, but only with activity. The subject reported history of exercised induced asthma as a child.
4.0	A pulmonary function test did not show any abnormalities. There were symptoms of wheezing, chest tightness, sputum production and shortness of breath with conversation of a dyspnea on exertion. A bronchoscopy was scheduled.
4.3	A bronchoscopy showed left upper lobe narrowed/edematous likely with variable obstruction based on airflow and edema. There was increased pitting of airway based on airflow and edema. Bronchial washings sent for culture were positive for <10,000 CFU/mL *Streptococcus alpha*, which is consistent with normal respiratory flora.
4.5	The pulmonologist started on Amoxicillin x 7 days, Arnuity inhaler and Albuterol inhaler.
4.8	An echocardiogram was normal.
7.4	There was shortness of breath, decreased voice and chest wall tightness. A chest X-ray showed no change. Complete blood count and sedimentation rate were normal.
7.7	The symptoms of the subject were considered incompletely controlled asthma based on symptoms alone. Therapy with Breo Ellipta daily was started, and the subject was advised to use the Albuterol inhaler consistently. Furthermore, it was recommend to start Fexfofenadine for seasonal allergies to help control symptoms.
14.7	Subject reported via phone that shortness of breath was resolved with laryngoplasty surgery at 9.4 months post-treatment.
Subject A3: left mid-abdomen pain, classified as *mild* and *possibly* related to the investigated treatment	
0.0	Subject reported that he had intermittent pain since his liposuction procedure. There was minimal focal tenderness. The subject reported that he was getting better and was overall not concerned.
Subject A4: worsening index shoulder pain, classified as *mild* and *unlikely* related to the investigated treatment	
0.7	Subject reported that he went back to work. He is a truck driver and he noticed that since then his shoulder pain was worse.
Subject A5: mid-abdomen pain (first TEAE of Subject A5), classified as *mild* and *possibly* related to the investigated treatment	
0.0	Subject reported pain and swelling of the mid-abdomen for two days.
Subject A5: pulp necrosis with asymptomatic apical periodontitis Tooth #15 (second TEAE of Subject A5), classified as *moderate* and *unlikely* related to the investigated treatment	
1.2	A cone beam computed tomography scan showed a large lesion with significant bone loss. Thermal testing was unresponsive.
Subject A11: pain in the arm of the index shoulder (first TEAE of Subject A11), classified as *moderate* and *possibly* related to the investigated treatment	
0.1	Subject reported right arm pain, starting three days post shoulder injection.

medRxiv preprint doi: https://doi.org/10.1101/2022.12.14.22283447; this version posted December 14, 2022. The copyright holder for this preprint **(which was not certified by peer review)** is the author/funder, who has granted medRxiv a license to display the preprint in perpetuity.

It is made available under a CC-BY 4.0 International license .

TABLE 8 (cont.)

M	Event
	Subject A11: index shoulder pain (second TEAE of Subject A11), classified as *mild* and *unlikely* related to the investigated treatment
18.7	Subject reported worsening of pain in the index (right) shoulder. Pain experienced by the subject did not start for over a year after the target procedure and was most likely related to progression of other issues. In this regard the Principal Investigator (Dr. Lundeen) recalled that there was some discussion prior to target treatment about the eligibility of the subject and that there were some bony changes at baseline.
24.0	Arthroscopic examination revealed (i) a very small partial-thickness tearing at the far anterior border of the supraspinatus tendon, which extended approximately 10% to 15% through the substance of the tendon with no exposed footprint; (ii) Grade 2 chondromalacia involving the superolateral humeral head; (iii) unstable attachment site of the biceps tendon and labrum with some surrounding erythema at the synovium; (iv) a large anterior acromial osteophyte Type 2 bordering on Type 3; and (v) considerable degenerative change of the AC joint with a significant inferior osteophyte. On this basis the following surgical procedures were performed on the same day: (a) gentle debridement of partial-thickness tearing at the far anterior border of the supraspinatus tendon; (b) debridement of Grade 2 chondromalacia involving the superolateral humeral head; (c) debridement of the attachment site of the biceps tendon and labrum; (d) tenotomy of the biceps tendon; (e) resection of the subacromial bursa; (f) converting the large (Type 2 bordering on Type 3) anterior acromial osteophyte to Type 1 using a cutting block technique; and (g) distal clavicle excision removing approximately 1 cm of the lateral clavicle. According to the Principal Investigator (M.L.) there is no need to assess the situation of this subject during the present study as failure of the initial index treatment.

Abbreviations: UA-ADRCs, treatment with a single injection of fresh, uncultured, unmodified, autologous, adipose-derived regenerative cells; M, month post-treatment.

medRxiv preprint doi: https://doi.org/10.1101/2022.12.14.22283447; this version posted December 14, 2022. The copyright holder for this preprint **(which was not certified by peer review)** is the author/funder, who has granted medRxiv a license to display the preprint in perpetuity.

It is made available under a CC-BY 4.0 International license .

TABLE S9

Individual courses of the treatment-related adverse events classified as {unlikely to be / possibly} related to the investigated treatment that occurred during the present study and the former study, experienced by those subjects who were treated with injection of corticosteroid.

M	Event
Subject C2: worsening index shoulder pain, classified as *moderate* and *possibly* related to the investigated treatment.	
1.6	Subject reported musculoskeletal pain. Specifically, pain in the index shoulder fared up at times but then usually went back to baseline.
8.0	Subject reported that at this time his shoulder pain was back to its baseline.
Subject C2: pharyngitis, classified as *mild* and *unlikely* related to the investigated treatment	
0.1	Subject reported a sore throat for a few days, but did not take any medications for it. The sore throat went away on its own.
Subject C3: worsening index shoulder pain, classified as *mild* and *unlikely* related to the investigated treatment	
5.2	Subject stated definitely getting some pain in the index shoulder.
Subject C4: anterior pain in the index shoulder, classified as *moderate* and *possibly* related to the investigated treatment	
1.4	Subject complained of some anterior shoulder pain.
7.4	Subject received an additional corticosteroid injection into the index shoulder due to increased pain.
Subject C5 in the former study: worsening index shoulder pain, classified as *mild* and *unlikely* related to the investigated treatment.	
BL	MRI evaluation showed a partial-thickness tear of the supraspinatus tendon with the following dimensions: anterior-posterior extension, 9.5 mm; medial-lateral extension, 3.1 mm; tear depth, 2.8 mm; tear volume (calculated as volume of an ellipsoid), 43.2 mm^3.
5.2	Subject reported definitely getting some pain in the index shoulder.
7.3	MRI evaluation showed a full-thickness tear of the supraspinatus tendon with the following dimensions: anterior-posterior extension, 10.0 mm (+0.5 mm [i.e., 105%] compared to baseline); medial-lateral extension, 13.0 mm (+9.9 mm [i.e., 420%] compared to baseline); tear depth, 6.0 mm (+3.2 mm [i.e., 210%] compared to baseline); tear volume, 408.4 mm^3 (+365.2 mm^3 [i.e., 950%] compared to baseline). In addition, MRI evaluation showed a dislocation of the long biceps tendon as well as a subscapularis tear of the index shoulder, which was not observerd at baseline. The subject withdrew consent after **diagnosis of full-thickness tear of the supraspinatus tendon** to seek alternative therapies or sugery and, thus, was lost to follow-up. Efficacy data of this subject beyond the examination performed at 12 weeks post-treatment in the former study were not collected, and the subject was not enrolled into the present study.

Abbreviations: M, month post-treatment; BL, baseline.

medRxiv preprint doi: https://doi.org/10.1101/2022.12.14.22283447; this version posted December 14, 2022. The copyright holder for this preprint **(which was not certified by peer review)** is the author/funder, who has granted medRxiv a license to display the preprint in perpetuity.

It is made available under a CC-BY 4.0 International license .

Table S10 shows group-specific numbers of TEAEs that were classified as {mild and unlikely to be related to the investigated treatment / mild and possibly related to the investigated treatment / moderate and unlikely to be related to the investigated treatment / moderate and possibly related to the investigated treatment} in the present study and the former study.

TABLE S10

Group-specific numbers of TEAEs that were classified as {mild and unlikely to be related to the investigated treatment / mild and possibly related to the investigated treatment / moderate and unlikely to be related to the investigated treatment / moderate and possibly related to the investigated treatment} in the present study and the former study.

TP	Group	Classification of TEAEs			
		mild and unlikely to be related	mild and possibly related	moderate and unlikely to be related	moderate and possibly related
BL-W24	UA-ADRCs	2	3	2	1
BL-FSV	UA-ADRCs	4	3	2	1
BL-SSV	UA-ADRCs	4	3	2	1
BL-W24	C	3	0	0	2
BL-FSV	C	3	0	0	2
BL-SSV	C	3	0	0	2

Abbreviations: TP, time period; BL, baseline; W24, study visit scheduled in the former study at 24 weeks post-treatment; FSV, first study visit of the present study; SSV, second study visit of the present study; UA-ADRCs, treatment with a single injection of fresh, uncultured, unmodified, autologous, adipose-derived regenerative cells; C, treatment with a single injection of corticosteroid.

For all investigated time periods there was no statistically significant difference between the groups with regard to the numbers of TEAEs that were classified as {mild and unlikely to be related to the investigated treatment / mild and possibly related to the investigated treatment / moderate and unlikely to be related to the investigated treatment / moderate and possibly related to the investigated treatment} in the present study and the former study (Chi-square test for trend):

- from baseline to W24 in the former study: $p = 0.941$,
- from baseline to the first study visit of the present study: $p = 0.757$, and
- from baseline to the second study visit of the present study: $p = 0.757$.

medRxiv preprint doi: https://doi.org/10.1101/2022.12.14.22283447; this version posted December 14, 2022. The copyright holder for this preprint **(which was not certified by peer review)** is the author/funder, who has granted medRxiv a license to display the preprint in perpetuity.

It is made available under a CC-BY 4.0 International license .

2.3. Severe treatment emergent adverse events

Tables S11-S13 summarize the individual courses of the four severe TEAEs that occurred during the present study and the former study, all of which were classified as not related to the investigated treatment.

TABLE S11
Severe TEAE experienced by Subject A7 who was treated with UA-ADRCs.

M	Event
5.5	Subject reported acute pain in the left shoulder (i.e., not in the index shoulder). A subacromial bursitis impingement and a small undersurface tear of the rotator cuff were diagnosed, but no treatment was performed.
34.4	Subject was diagnosed with a **spinoglenoid notch cyst in the left shoulder (i.e., not in the index shoulder)** (**severe TEAE experienced by this subject**), discovered by MRI. Pain at times radiated up towards the neck, and at times down the arm with some pain all the way into the hand.
36.9	Arthroscopic decompression of the cyst and repair of the posterior capsulolabral tissue was performed.
37.4	Subject reported pain 4/10 and occasional use of Tylenol and ice, as well as use of a SlingShot immobilizer. There was still some swelling present at this time, but this was decreasing.
38.3	There was still some discomfort, together with slow progress in improvement of range of motion.
40.3	The pain was nearly resolved and restricted to holding the left arm at shoulder height for extended periods of time. External rotation was lacking about 10 degrees, and internal rotation was lacking about two to three interspace levels.
41.2	Subject reported that the stopped physical therapy due to increased pain when using heavy weights.

Abbreviations: UA-ADRCs, treatment with a single injection of fresh, uncultured, unmodified, autologous, adipose-derived regenerative cells; M, month post-treatment.

Data regarding the SAE of Subject A7 (this SAE occurred during the present study) was sent to the Institutional Review Board of the study site, the Data and Safety Monitoring Board of the present study and the U.S. Food and Drug Administration, and all noted that this SAE was not related to study treatment. The SAE was treated per standard of care.

medRxiv preprint doi: https://doi.org/10.1101/2022.12.14.22283447; this version posted December 14, 2022. The copyright holder for this preprint **(which was not certified by peer review)** is the author/funder, who has granted medRxiv a license to display the preprint in perpetuity.

It is made available under a CC-BY 4.0 International license .

TABLE S12

Severe TEAE experienced by Subject A9 who was treated with UA-ADRCs.

M	Event
1.0	Subject suffered from a **contusion of the right elbow (i.e., on the same side as the index shoulder) due to a fall on ice**. This TEAE was classified as mild and not related to the investigated treatment.
7.4	subject felt **some pain in the index shoulder and a little bit of weakness secondary to the pain (severe TEAE experienced by this subject).**
13.4	A surgical rotator cuff repair procedure was performed (note that this surgery of the index shoulder took place outside of the former study and the present study).
32.7	MRI examination showed a fragment of a broken anchor from a rotator cuff repair procedure performed on, which had lodged itself just above the superior labrum. This fragment of a broken anchor appeared to have found a quiet zone within the joint and was not impacting subject's performance or function in any way. No treatment was planned.

Abbreviations: UA-ADRCs, treatment with a single injection of fresh, uncultured, unmodified, autologous, adipose-derived regenerative cells; M, month post-treatment.

TABLE S13

Severe TEAEs experienced by Subject A4 who was treated with UA-ADRCs.

M	Event
3.0	Subject was diagnosed with a **non ST elevation myocardial infarction (first severe TEAE experienced by this subject)**. The subject had some recurring pain intermittently, but had been stable while awaiting catheter examination over the weekend. The decision to wait for catheter examination was due to platelet count of 50,000. Stress testing on the weekend indicated inferior ischemia.
3.1	ACE-inhibitor was stopped and i.v. fluids were given. Initially the subject was doing well, but developed chest pain when showering; ECG was suggestive of ST elevation. The subject was taken emergently to the catheter lab on the same day. Stents were placed in a previous vein graft to the right posterior descending artery (RPDA) and the native RPDA. The decision to split treatment into two procedures was due to concerns with his kidneys.
3.1	Stents were also placed in a previous vein graft to the lateral left anterior descending artery. The subject did well on the rest of his stay and was discharged a few days later. A cardiology follow up was planned. Atenolol was also stopped due to bradycardia concerns.
4.3	Subject had some feelings of fatigue and has noted some left sided chest discomfort and left arm pain into the antecubital area with walking and relieved with rest. Treatment with Imdur daily was started; a stress test was abnormal. The subject was diagnosed with a **ST elevation myocardial infarction (second severe TEAE experienced by this subject**).
4.6	A cardiac angiogram showed no lesions amenable to revascularization. Adjustments to current medications were performed.
6.3	A follow up doctor visit showed that the subject was symptomatically doing well with medication changes.

Abbreviations: UA-ADRCs, treatment with a single injection of fresh, uncultured, unmodified, autologous, adipose-derived regenerative cells; M, month post-treatment.

medRxiv preprint doi: https://doi.org/10.1101/2022.12.14.22283447; this version posted December 14, 2022. The copyright holder for this preprint **(which was not certified by peer review)** is the author/funder, who has granted medRxiv a license to display the preprint in perpetuity.

It is made available under a CC-BY 4.0 International license .

Part 3 – Scheduled study visits and availability of ASES Total score, VAS pain score and SF-36 Total score data

Table S14 lists the scheduled visits of the present study and the former study, during which the primary endpoint *long term efficacy of pain and function through ASES Shoulder Score and SF-36 health questionnaires* between the two groups was investigated, and indicates whether (+) or not (-) the corresponding subject developed additional pathologies of the index shoulder (next to symptomatic, partial-thickness rotator cuff tear) and/or received additional treatments on the index shoulder (next to injection of UA-ADRCs or corticosteroid) during either of these studies. The corresponding reasons are summarized in Table S15.

TABLE S14

Scheduled visits of the present study and the former study, during which the primary endpoint long term efficacy of pain and function through ASES Shoulder Score and SF-36 health questionnaires between the two groups was investigated, and indication whether (+) or not (-) the corresponding subject developed additional pathologies of the index shoulder (next to symptomatic, partial-thickness rotator cuff tear) and/or received additional treatments on the index shoulder (next to injection of UA-ADRCs or corticosteroid) during either of these studies. The remarks are outlined in Table S15.

Subject	Group	BL	W24	FSV	SSV	Remark
A1	UA-ADRCs	-	-	+	+	a
A2	UA-ADRCs	-	-	-	-	
A3	UA-ADRCs	-	-	+	+	b
A4	UA-ADRCs	-	-	-	-	
A5	UA-ADRCs	-	-	-	-	
A6	UA-ADRCs	-	-	-	-	
A7	UA-ADRCs	-	-	-	-	
A8	UA-ADRCs	-	-	-	-	
A9	UA-ADRCs	-	+	+	+	c
A10	UA-ADRCs	-	-	-	-	
A11	UA-ADRCs	-	-	+	+	d
C1	C	-	-	-	-	
C2	C	-	-	+	+	e
C3	C	-	-	-	-	
C4	C	-	-	+	+	f
C5	C	-	+	+	+	g

Abbreviations: UA-ADRCs, treatment with a single injection of fresh, uncultured, unmodified, autologous, adipose-derived regenerative cells; C, treatment with a single injection of corticosteroid; BL, baseline, W24, 24 weeks post-treatment in the former study, FSV / SSV, first / second study visit in the present study.

medRxiv preprint doi: https://doi.org/10.1101/2022.12.14.22283447; this version posted December 14, 2022. The copyright holder for this preprint **(which was not certified by peer review)** is the author/funder, who has granted medRxiv a license to display the preprint in perpetuity.

It is made available under a CC-BY 4.0 International license .

TABLE S15

Reasons why individual subjects enrolled in the present study and the former study developed additional pathologies of the index shoulder (next to symptomatic, partial-thickness rotator cuff tear) and/or received additional treatments on the index shoulder (next to injection of UA-ADRCs or corticosteroid) during either of these studies. The remarks refer to Table S14.

M	Event
Remark a in Table S14 – Subject A1	
28.4	Psubject reported development of pain in the lateral index (left) shoulder over the past few months. Pain was worse with lifting or overhead movement. The subject received a subacromial corticosteroid injection at this time.
32.9	Subject rated shoulder pain 3-4/10 and received another subacromial corticosteroid injection.
34.7	Subject reported left shoulder pain 0/10 but expressed interest in proceeding with left shoulder rotator cuff repair during the next few months.
36.5	Subject reported that he started having left shoulder pain at night and treating with Tylenol as needed.
36.8	Subject underwent left shoulder arthroscopy with subacomial decompression and rotator cuff repair.
37.5	The study coordinator followed up with the subject. The subject reported the left shoulder pain at night resolved since surgery.
39.7	Subject reported a muscle knot in left arm, with pain during therapy and other times. Tissue massage, ultrasound and electrical stimulation did not help much. The subject exhausted post-op physical therapy sessions.
40.1	Subject had a nonstudy visit, and notes from this nonstudy visit were used to complete concomitant medications and adverse events.
43.0	Subject transitioned to occupational therapy in order to continue work on the left shoulder for range of motion and strength.
Remark b in Table S14 – Subject A3	
33.3	Subject reported that he was doing very well until 30.3 months post-treatment. At this time the subject moved into a new house and was doing a lot of work that involved repetitive use of his right (index) arm. The subject started to have increased pain in his right shoulder. Because of this the subject had a recent subacromial corticosteroid injection (i.e., before the first study visit). At the time of the first study visit the subject had no pain in his right shoulder.
Remark c in Table S14 – Subject A9	
6.3	Subject reported a contusion of the right elbow due to fall on ice; the start date of this TEAE was at 1.0 month post-treatment.
7.4	Subject had some pain in the right (index) shoulder and a little bit of weakness secondary to the pain.
32.7	MRI showed a fragment of a broken anchor from a rotator cuff repair procedure performed at 13.4 months post-treatment, which had lodged itself just above the superior labrum. This fragment of a broken anchor appeared to have found a quiet zone within the joint and was not impacting subject's performance or function in any way. No treatment was planned.

medRxiv preprint doi: https://doi.org/10.1101/2022.12.14.22283447; this version posted December 14, 2022. The copyright holder for this preprint **(which was not certified by peer review)** is the author/funder, who has granted medRxiv a license to display the preprint in perpetuity.

It is made available under a CC-BY 4.0 International license .

TABLE S15 (cont.)

M	Event
Remark d in Table S14 – Subject A11	
18.7	Subject reported worsening of pain in the index (right) shoulder. Pain experienced by the subject did not start for over a year after the target procedure and was most likely related to progression of other issues. In this regard the Principal Investigator (Dr. Lundeen) recalled that there was some discussion prior to target treatment about the eligibility of the subject and that there were some bony changes at baseline.
24.0	Arthroscopic examination revealed (i) a very small partial-thickness tearing at the far anterior border of the supraspinatus tendon, which extended approximately 10% to 15% through the substance of the tendon with no exposed footprint; (ii) Grade 2 chondromalacia involving the superolateral humeral head; (iii) unstable attachment site of the biceps tendon and labrum with some surrounding erythema at the synovium; (iv) a large anterior acromial osteophyte Type 2 bordering on Type 3; and (v) considerable degenerative change of the AC joint with a significant inferior osteophyte. On this basis the following surgical procedures were performed on the same day: (a) gentle debridement of partial-thickness tearing at the far anterior border of the supraspinatus tendon; (b) debridement of Grade 2 chondromalacia involving the superolateral humeral head; (c) debridement of the attachment site of the biceps tendon and labrum; (d) tenotomy of the biceps tendon; (e) resection of the subacromial bursa; (f) converting the large (Type 2 bordering on Type 3) anterior acromial osteophyte to Type 1 using a cutting block technique; and (g) distal clavicle excision removing approximately 1 cm of the lateral clavicle. According to the Principal Investigator (M.L.) there is no need to assess the situation of this subject during the present study as failure of the initial index treatment.
Remark e in Table S14 – Subject C2	
32.3	Subject fell off a ladder. He reported increased pain and discomfort and difficulty with overhead activity.
33.3	An MRI revealed a full thickness tear of anterior superior fibers of the supraspinatus tendon.
41.2	A second MRI showed a near full thickness tear of the anterosuperior fibers of the supraspinatus tendon.
Remark f in Table S14 – Subject C4	
1.4	Subject complained of some anterior shoulder pain.
7.4	Subject received an additional corticosteroid injection into the index shoulder due to increased pain.
Remark g in Table S14 – Subject C5	
BL	MRI evaluation showed a partial-thickness tear of the supraspinatus tendon with the following dimensions: anterior-posterior extension, 9.5 mm; medial-lateral extension, 3.1 mm; tear depth, 2.8 mm; tear volume (calculated as volume of an ellipsoid), 43.2 mm^3.
5.2	Subject reported definitely getting some pain in the index shoulder.
7.3	MRI evaluation showed a full-thickness tear of the supraspinatus tendon with the following dimensions: anterior-posterior extension, 10.0 mm (+0.5 mm [i.e., 105%] compared to baseline); medial-lateral extension, 13.0 mm (+9.9 mm [i.e., 420%] compared to baseline); tear depth, 6.0 mm (+3.2 mm [i.e., 210%] compared to baseline); tear volume, 408.4 mm^3 (+365.2 mm^3 [i.e., 950%] compared to baseline). In addition, MRI evaluation showed a dislocation of the long biceps tendon as well as a subscapularis tear of the index shoulder, which was not observerd at baseline. The subject withdrew consent after **diagnosis of full-thickness tear of the supraspinatus tendon** to seek alternative therapies or sugery and, thus, was lost to follow-up. Efficacy data of this subject beyond the examination performed at 12 weeks post-treatment in the former study were not collected, and the subject was not enrolled into the present study.

Abbreviation: M, months post-treatment.

medRxiv preprint doi: https://doi.org/10.1101/2022.12.14.22283447; this version posted December 14, 2022. The copyright holder for this preprint **(which was not certified by peer review)** is the author/funder, who has granted medRxiv a license to display the preprint in perpetuity.

It is made available under a CC-BY 4.0 International license .

Part 4 – Efficacy data as a function of time post-treatment

FIGURE S16 *(on the next page). Individual ASES Total score data as a function of time post-treatment of subjects treated with injection of respectively UA-ADRCs (Subjects A1-A11) or corticosteroid (Subjects C1-C5).*

The data are arranged in descending order of individual treatment success (i.e., the data of the subjects with the hightest ASES Total score are shown in the top row of the left column (Subject A2 treated with injection of UA-ADRCs) and the right column (Subject C3 treated with injection of corticosteroid).

In the graphs…

- *green dots and green lines (Subjects A2, A4, A5, A6, A7, A8, A10, C1 and C3) indicate that all data of the present study and the former study were available and could be used for assessing treatment outcome,*
- *black dots and black lines (Subjects A1, A3, A11 and C2) indicate that all data of the former study were available and could be used for assessing treatment outcome, but in the time period between the former study and the present study there was an incidence that rendered the data of the present study unsuitable for assessing treatment outcome (reasons are indicated in the corresponding panels and outlined in detail in Table S15),*
- *red dots and red lines (Subjects A9, C4 and C5) indicate that there was an incidence during the former study that rendered a part of the data of the former study (and, thus, all data of the present study in case they were collected) unsuitable for assessing treatment outcome (reasons are indicated in the corresponding panels and outlined in detail in Table S15), and*
- *open dots and dashed lines (Subjects A1, A3, A9, A11, C2, C4 and C5) indicate imputation of missing data using the Last Observation Carried Forward approach.*

Abbreviations: A, accident affecting the index shoulder; C, injection of corticosteroid into the index shoulder; P, pain in the index shoulder; S, surgery of the index shoulder.

medRxiv preprint doi: https://doi.org/10.1101/2022.12.14.22283447; this version posted December 14, 2022. The copyright holder for this preprint **(which was not certified by peer review)** is the author/funder, who has granted medRxiv a license to display the preprint in perpetuity.

It is made available under a CC-BY 4.0 International license .

FIGURE S16 (cont.)

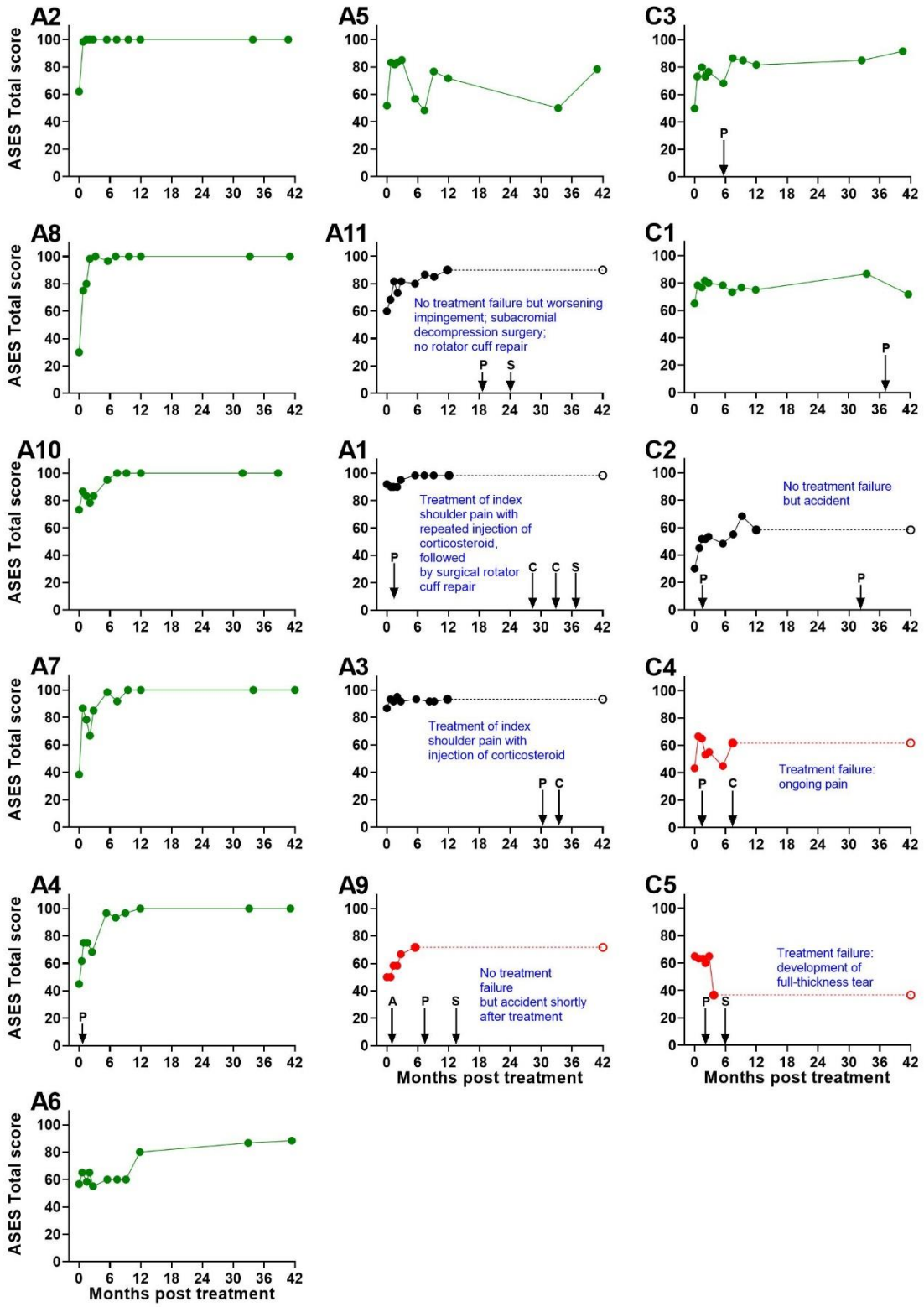

medRxiv preprint doi: https://doi.org/10.1101/2022.12.14.22283447; this version posted December 14, 2022. The copyright holder for this preprint **(which was not certified by peer review)** is the author/funder, who has granted medRxiv a license to display the preprint in perpetuity.

It is made available under a CC-BY 4.0 International license .

FIGURE S17 *(on the next page). Individual VAS pain score (collected together with the ASES score) as a function of time post-treatment of subjects treated with injection of respectively UA-ADRCs (Subjects A1-A11) or corticosteroid (Subjects C1-C5).*

The data are arranged in descending order of individual treatment success (i.e., the data of the subjects with the hightest ASES Total scores are shown in the top row of the left column (Subject A2 treated with injection of UA-ADRCs) and the right column (Subject C3 treated with injection of corticosteroid) (c.f. Figure 16).

In the graphs…

- *green dots and green lines (Subjects A2, A4, A5, A6, A7, A8, A10, C1 and C3) indicate that all data of the present study and the former study were available and could be used for assessing treatment outcome,*
- *black dots and black lines (Subjects A1, A3, A11 and C2) indicate that all data of the former study were available and could be used for assessing treatment outcome, but in the time period between the former study and the present study there was an incidence that rendered the data of the present study unsuitable for assessing treatment outcome (reasons are indicated in the corresponding panels and outlined in detail in Table S15),*
- *red dots and red lines (Subjects A9, C4 and C5) indicate that there was an incidence during the former study that rendered a part of the data of the former study (and, thus, all data of the present study in case they were collected) unsuitable for assessing treatment outcome (reasons are indicated in the corresponding panels and outlined in detail in Table S15), and*
- *open dots and dashed lines (Subjects A1, A3, A9, A11, C2, C4 and C5) indicate imputation of missing data using the Last Observation Carried Forward approach.*

Abbreviations: A, accident affecting the index shoulder; C, injection of corticosteroid into the index shoulder; P, pain in the index shoulder; S, surgery of the index shoulder.

medRxiv preprint doi: https://doi.org/10.1101/2022.12.14.22283447; this version posted December 14, 2022. The copyright holder for this preprint **(which was not certified by peer review)** is the author/funder, who has granted medRxiv a license to display the preprint in perpetuity.

It is made available under a CC-BY 4.0 International license .

FIGURE S17 (cont.)

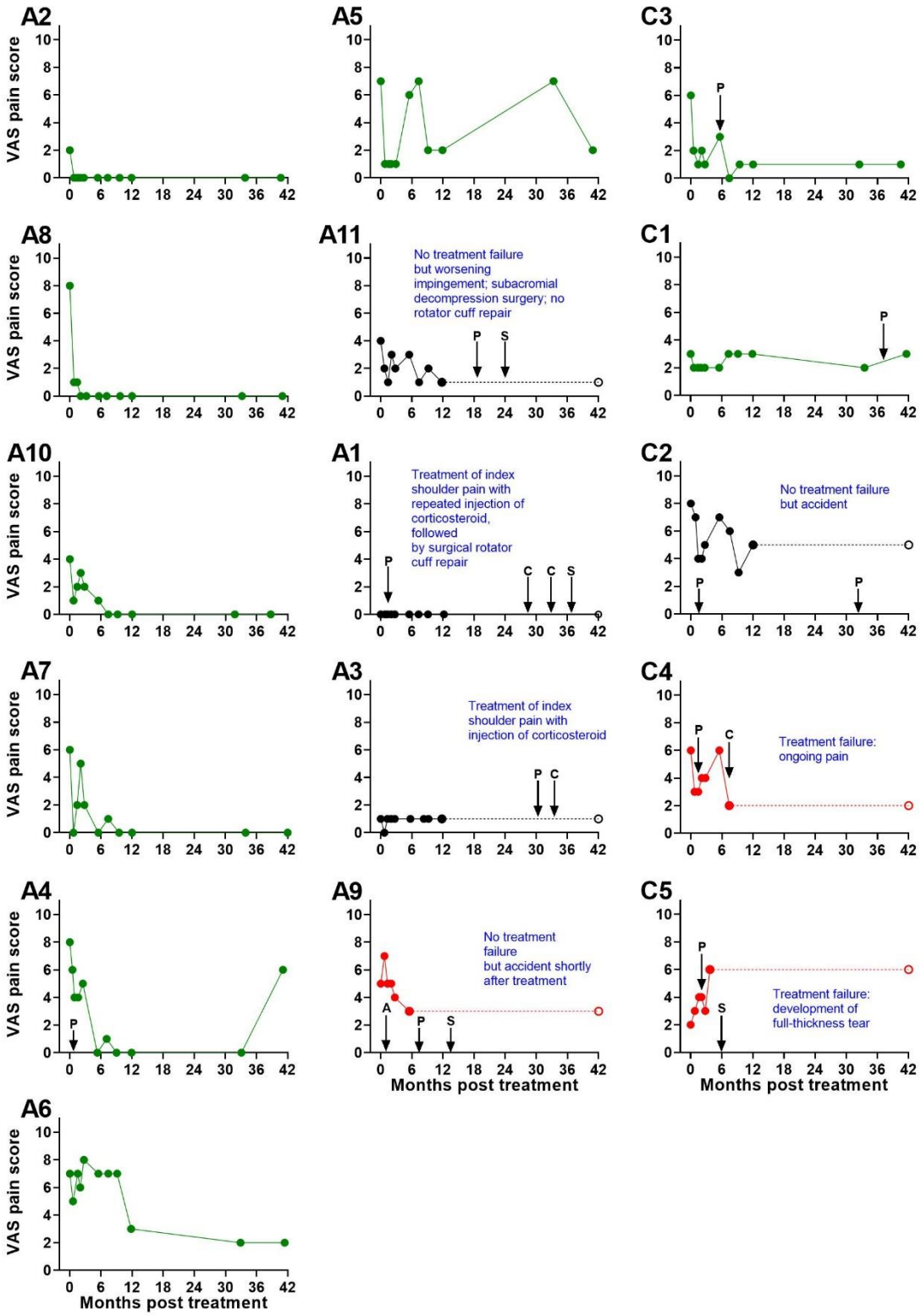

medRxiv preprint doi: https://doi.org/10.1101/2022.12.14.22283447; this version posted December 14, 2022. The copyright holder for this preprint **(which was not certified by peer review)** is the author/funder, who has granted medRxiv a license to display the preprint in perpetuity.

It is made available under a CC-BY 4.0 International license .

FIGURE S18 *(on the next page). Individual SF-36 Total score as a function of time post-treatment of subjects treated with injection of respectively UA-ADRCs (Subjects A1-A11) or corticosteroid (Subjects C1-C5).*

The data are arranged in descending order of individual treatment success (i.e., the data of the subjects with the hightest ASES Total scores are shown in the top row of the left column (Subject A2 treated with injection of UA-ADRCs) and the right column (Subject C3 treated with injection of corticosteroid) (c.f. Figure 16).

In the graphs…

- *green dots and green lines (Subjects A2, A4, A5, A6, A7, A8, A10, C1 and C3) indicate that all data of the present study and the former study were available and could be used for assessing treatment outcome,*
- *black dots and black lines (Subjects A1, A3, A11 and C2) indicate that all data of the former study were available and could be used for assessing treatment outcome, but in the time period between the former study and the present study there was an incidence that rendered the data of the present study unsuitable for assessing treatment outcome (reasons are indicated in the corresponding panels and outlined in detail in Table S15),*
- *red dots and red lines (Subjects A9, C4 and C5) indicate that there was an incidence during the former study that rendered a part of the data of the former study (and, thus, all data of the present study in case they were collected) unsuitable for assessing treatment outcome (reasons are indicated in the corresponding panels and outlined in detail in Table S15), and*
- *open dots and dashed lines (Subjects A1, A3, A9, A11, C2, C4 and C5) indicate imputation of missing data using the Last Observation Carried Forward approach.*

Abbreviations: A, accident affecting the index shoulder; C, injection of corticosteroid into the index shoulder; P, pain in the index shoulder; S, surgery of the index shoulder.

medRxiv preprint doi: https://doi.org/10.1101/2022.12.14.22283447; this version posted December 14, 2022. The copyright holder for this preprint **(which was not certified by peer review)** is the author/funder, who has granted medRxiv a license to display the preprint in perpetuity.

It is made available under a CC-BY 4.0 International license .

FIGURE S18 (cont.)

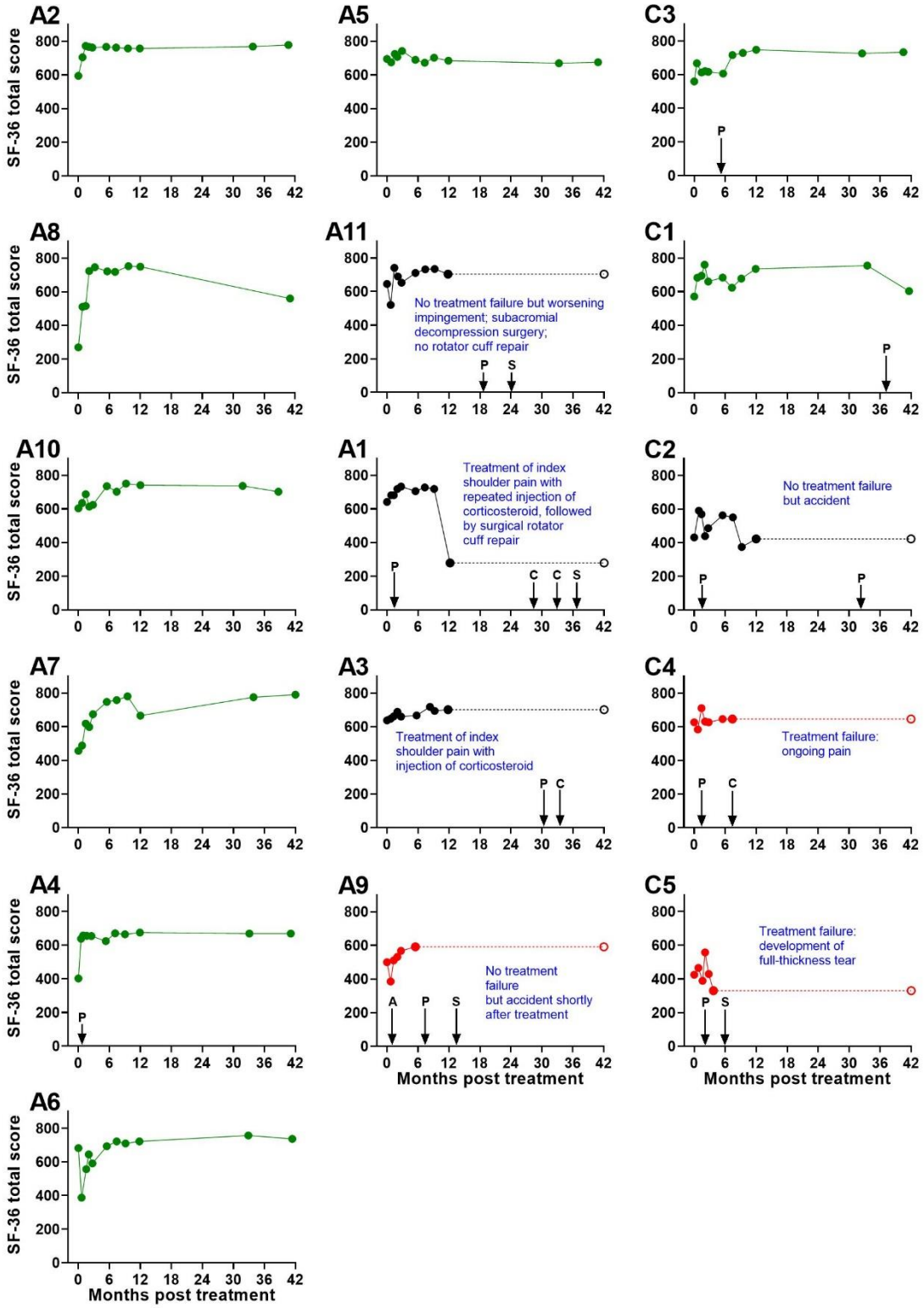

medRxiv preprint doi: https://doi.org/10.1101/2022.12.14.22283447; this version posted December 14, 2022. The copyright holder for this preprint **(which was not certified by peer review)** is the author/funder, who has granted medRxiv a license to display the preprint in perpetuity.

It is made available under a CC-BY 4.0 International license .

TABLE S16

Mean, standard error of the mean and median of the ASES Total score collected during the present study and the former study after treating subjects suffering from sPTRCT with injection of respectively UA-ADRCs or corticosteroid, and results of two-way repeated measures ANOVA of these data. $p_{Time} < 0.001$; $p_{Treatment} = 0.006$; $p_{Time \times Treatment} = 0.097$; $p_{Subject} < 0.001$.

Time point	Subjects treated with injection of UA-ADRCs		Subjects treated with injection of corticosteroid		D (U/C)	p_B
	Mean ± SEM	Median	Mean ± SEM	Median		
BL	58.7 ± 5.8	56.7	50.7 ± 6.7	50	+15.9%	>0.999
W24	86.1 ± 4.9	95	61.0 ± 6.3	65	+41.1%	0.058
W52	91.4 ± 3.5	98.3	65.0 ± 6.4	65	+40.6%	0.049
FSV	90.0 ± 4.8	98.3	68.0 ± 8.0	65	+32.4%	0.249
SSV	92.7 ± 3.0	98.3	66.3 ± 7.7	65	+39.8%	0.115

Abbreviations: sPTRCT, symptomatic, partial-thickness rotator cuff tear; UA-ADRCs, fresh, uncultured, unmodified, autologous, adipose-derived regenerative cells; D (U/C), ratio of mean values between the subjects in the UA-ADRCs group and the subjects in the corticosteroid group; p_B, result (p value) of Bonferroni's multiple comparisons test; SEM, standard error of the mean; BL, baseline; W24 / W52, study visits scheduled in the former study at 24 and 52 weeks post-treatment; FSV, first study visit of the present study; SSV, second study visit of the present study.

TABLE S17

Mean, standard error of the mean and median of the VAS pain score (collected together with the ASES Total score) collected during the present study and the former study[22] after treating subjects suffering from sPTRCT with injection of respectively UA-ADRCs or corticosteroid, and results of two-way repeated measures ANOVA of these data. $p_{Time} = 0.001$; $p_{Treatment} = 0.077$; $p_{Time \times Treatment} = 0.380$; $p_{Subject} < 0.001$.

Time point	Subjects treated with injection of UA-ADRCs		Subjects treated with injection of corticosteroid		D (U/C)	p_B
	Mean ± SEM	Median	Mean ± SEM	Median		
BL	4.7 ± 0.8	5	5.0 ± 1.1	6	-5.5%	>0.999
W24	1.9 ± 0.8	1	4.0 ± 1.1	3	-52.3%	0.722
W52	0.9 ± 0.4	0	3.4 ± 0.9	3	-73.3%	0.260
FSV	1.3 ± 0.7	0	3.2 ± 1.0	2	-60.2%	0.691
SSV	1.4 ± 0.6	1	3.4 ± 0.9	3	-59.9%	0.509

Abbreviations: sPTRCT, symptomatic, partial-thickness rotator cuff tear; UA-ADRCs, fresh, uncultured, unmodified, autologous, adipose-derived regenerative cells; D (U/C), ratio of mean values between the subjects in the UA-ADRCs group and the subjects in the corticosteroid group; p_B*, result (p value) of Bonferroni's multiple comparisons test; SEM, standard error of the mean; BL, baseline; W24 / W52, study visits scheduled in the former study[22] at 24 and 52 weeks post treatment; FSV, first study visit of the present study; SSV, second study visit of the present study.*

medRxiv preprint doi: https://doi.org/10.1101/2022.12.14.22283447; this version posted December 14, 2022. The copyright holder for this preprint **(which was not certified by peer review)** is the author/funder, who has granted medRxiv a license to display the preprint in perpetuity.

It is made available under a CC-BY 4.0 International license .

TABLE S18

Mean, standard error of the mean and median of the SF-36 Total score collected during the present study and the former study[22] after treating subjects suffering from sPTRCT with injection of respectively UA-ADRCs or corticosteroid, and results of two-way repeated measures ANOVA of these data. $p_{Time} = 0.093$; $p_{Treatment} = 0.180$; $p_{Time \times Treatment} = 0.859$; $p_{Subject} < 0.001$.

Time point	Subjects treated with injection of UA-ADRCs		Subjects treated with injection of corticosteroid		D (U/C)	p_B
	Mean ± SEM	Median	Mean ± SEM	Median		
BL	557 ± 40.4	603.7	523 ± 40.4	560	+6.5%	>0.999
W24	696 ± 15.7	705.5	585 ± 44.9	606.5	+18.9%	0.335
W52	661 ± 40.7	701.5	595 ± 72.2	647	+11.0%	>0.999
FSV	673 ± 42.7	703.5	595 ± 72.2	647	+13.0%	>0.999
SSV	653 ± 42.9	701.5	566 ± 72.0	603.5	+15.4%	>0.999

Abbreviations: sPTRCT, symptomatic, partial-thickness rotator cuff tear; UA-ADRCs, fresh, uncultured, unmodified, autologous, adipose-derived regenerative cells; D (U/C), ratio of mean values of the subjects in the UA-ADRCs group and the subjects in the corticosteroid group; p_B*, result (p value) of Bonferroni's multiple comparisons test; SEM, standard error of the mean; BL, baseline; W24 / W52, study visits scheduled in the former study[22] at 24 and 52 weeks post treatment; FSV, first study visit of the present study; SSV, second study visit of the present study.*

medRxiv preprint doi: https://doi.org/10.1101/2022.12.14.22283447; this version posted December 14, 2022. The copyright holder for this preprint **(which was not certified by peer review)** is the author/funder, who has granted medRxiv a license to display the preprint in perpetuity.

It is made available under a CC-BY 4.0 International license .

Part 5 – Analysis of MRI scans

FIGURE S19 *(on the next page). Individual tear size (calculated as ellipsoid volume) as a function of time post-treatment of subjects treated with injection of respectively UA-ADRCs (Subjects A1-A11) or corticosteroid (Subjects C1-C5).*

The data are arranged in descending order of individual treatment success (i.e., the data of the subjects with the hightest ASES Total scores are shown in the top row of the left column (Subject A2 treated with injection of corticosteroid) and the right column (Subject C3 treated with injection of UA-ADRCs) (c.f. Figure S16).

In the graphs…

- *green dots and green lines (Subjects A2, A4, A5, A6, A7, A8, A10, C1 and C3) indicate that all data of the present study and the former study were available and could be used for assessing treatment outcome,*
- *black dots and black lines (Subjects A1, A3, A11 and C2) indicate that all data of the former study were available and could be used for assessing treatment outcome, but in the time period between the former study and the present study there was an incidence that rendered the data of the present study unsuitable for assessing treatment outcome (reasons are indicated in the corresponding panels and outlined in detail in Table S15),*
- *red dots and red lines (Subjects A9, C4 and C5) indicate that there was an incidence during the former study that rendered a part of the data of the former study (and, thus, all data of the present study in case they were collected) unsuitable for assessing treatment outcome (reasons are indicated in the corresponding panels and outlined in detail in Table S15), and*
- *open dots and dashed lines (Subjects A1, A3, A9, A11, C2, C4 and C5) indicate imputation of missing data using the Last Observation Carried Forward approach.*

Abbreviations: A, accident affecting the index shoulder; C, injection of corticosteroid into the index shoulder; P, pain in the index shoulder; S, surgery of the index shoulder.

medRxiv preprint doi: https://doi.org/10.1101/2022.12.14.22283447; this version posted December 14, 2022. The copyright holder for this preprint **(which was not certified by peer review)** is the author/funder, who has granted medRxiv a license to display the preprint in perpetuity.

It is made available under a CC-BY 4.0 International license .

FIGURE S19 (cont.)

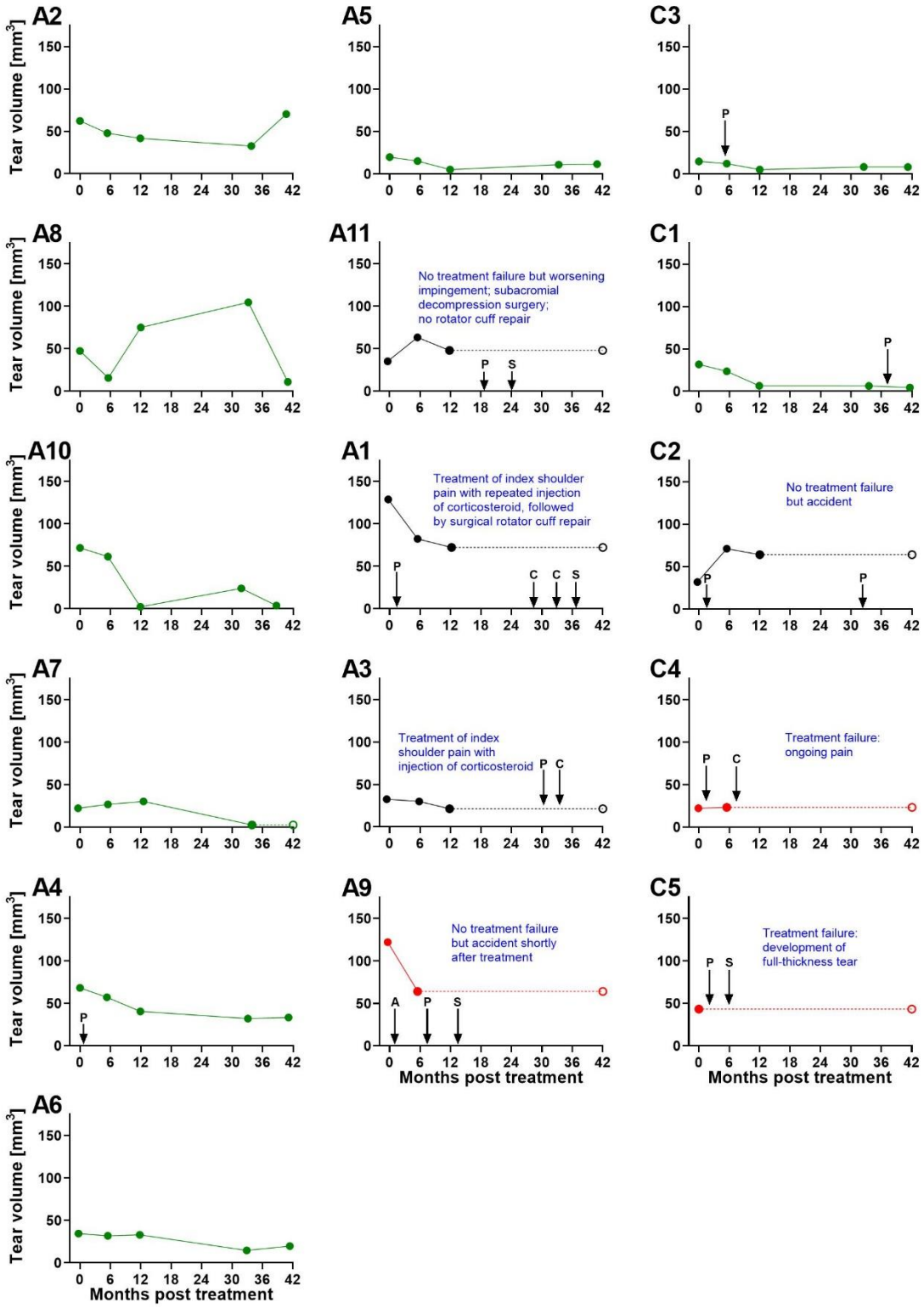

medRxiv preprint doi: https://doi.org/10.1101/2022.12.14.22283447; this version posted December 14, 2022. The copyright holder for this preprint **(which was not certified by peer review)** is the author/funder, who has granted medRxiv a license to display the preprint in perpetuity.

It is made available under a CC-BY 4.0 International license .

TABLE S19

Mean, standard error of the mean and median of the tear size (calculated as ellipsoid volume) collected during the present study and the former study[22] after treating subjects suffering from sPTRCT with injection of respectively UA-ADRCs or corticosteroid, and results of two-way repeated measures ANOVA of these data. $p_{Time} = 0.290$; $p_{Treatment} = 0.300$; $p_{Time \times Treatment} = 0.349$; $p_{Subject} < 0.001$.

Time point	Subjects treated with injection of UA-ADRCs		Subjects treated with injection of corticosteroid		D (U/C)	p_B
	Mean ± SEM [mm³]	Median [mm³]	Mean ± SEM [mm³]	Median [mm³]		
BL	58.6 ± 11.3	47.3	28.7 ± 4.8	31.7	+104%	0.151
W24	45.0 ± 6.8	47.7	34.6 ± 10.4	23.5	+30.2%	>0.999
W52	39.4 ± 7.4	40.5	28.4 ± 11.3	23.2	+38.9%	>0.999
FSV	38.8 ± 9.3	32.0	29.0 ± 11.0	23.2	+33.9%	>0.999
SSV	32.5 ± 8.1	21.3	28.6 ± 11.2	23.2	+13.8%	>0.999

Abbreviations: sPTRCT, symptomatic, partial-thickness rotator cuff tear; UA-ADRCs, fresh, uncultured, unmodified, autologous, adipose-derived regenerative cells; D (U/C), ratio of mean values of subjects in the UA-ADRCs group and subjects in the corticosteroid group; p_B*, result (p value) of Bonferroni's multiple comparisons test; SEM, standard error of the mean; BL, baseline; W24 / W52, study visits scheduled in the former study[22] at 24 and 52 weeks post treatment; FSV, first study visit of the present study; SSV, second study visit of the present study.*

medRxiv preprint doi: https://doi.org/10.1101/2022.12.14.22283447; this version posted December 14, 2022. The copyright holder for this preprint **(which was not certified by peer review)** is the author/funder, who has granted medRxiv a license to display the preprint in perpetuity.

It is made available under a CC-BY 4.0 International license .

Part 6 – Relationship between treatment outcome and baseline data

FIGURE S20 *(on the next pages). Individual ASES Total score as a function of time post-treatment, and individual data at baseline (ASES Total score, tear volume, age, body mass index, cell yield and cell viability) of the subjects who were treated with injection of UA-ADRCs (Subjects A1-A11).*

The data are arranged in descending order of individual treatment success (i.e., the data of the subject with the best treatment outcome (Subject A2) are shown in the top row).

In the graphs showing individual ASES Total scores as a function of time post-treatment…

- *green dots and green lines (Subjects A2, A4, A5, A6, A7, A8 and A10) indicate that all data of the present study and the former study were available and could be used for assessing treatment outcome,*
- *black dots and black lines (Subjects A1, A3 and A11) indicate that all data of the former study were available and could be used for assessing treatment outcome, but in the time period between the former study and the present study there was an incidence that rendered the data of the present study unsuitable for assessing treatment outcome (reasons are indicated in the corresponding panels and outlined in detail in Table S15), and*
- *red dots and red lines (Subject A9) indicate that there was an incidence during the former study that rendered a part of the data of the former study (and, thus, all data of the present study in case they were collected) unsuitable for assessing treatment outcome (reasons are indicated in the corresponding panel and outlined in detail in Table S15).*

In the graphs showing individual data at baseline (ASES Total score, tear volume, age, body mass index, cell yield and cell viability)…

- *the individual data of the subject whose ASES Total score as a function of time post-treatment is shown in the same row are given on the left ("Subject"), and*
- *the data of all subjects in the corticosteroid group are given on the right ("All"). The horizontal lines represent mean values.*

In addition, for each variable the subject treated with ADRCs with…

- *presumably the best prognosis (at baseline highest ASES Total score, smallest tear volume, youngest age and lowest body mass index, as well as highest cell yield and highest cell viability) is indicated with a green dot and green frame surrounding the corresponding data, and*
- *presumably the worst prognonis (at baseline lowest ASES Total score, largest tear volume, oldest age and highest body mass index, as well as lowest cell yield and lowest cell viability) is indicated with a red dot and red frame surrounding the corresponding data.*

Abbreviations: A, accident affecting the index shoulder; C, injection of corticosteroid into the index shoulder; P, pain in the index shoulder; S, surgery of the index shoulder.

medRxiv preprint doi: https://doi.org/10.1101/2022.12.14.22283447; this version posted December 14, 2022. The copyright holder for this preprint **(which was not certified by peer review)** is the author/funder, who has granted medRxiv a license to display the preprint in perpetuity.

It is made available under a CC-BY 4.0 International license .

FIGURE S20 (cont.)

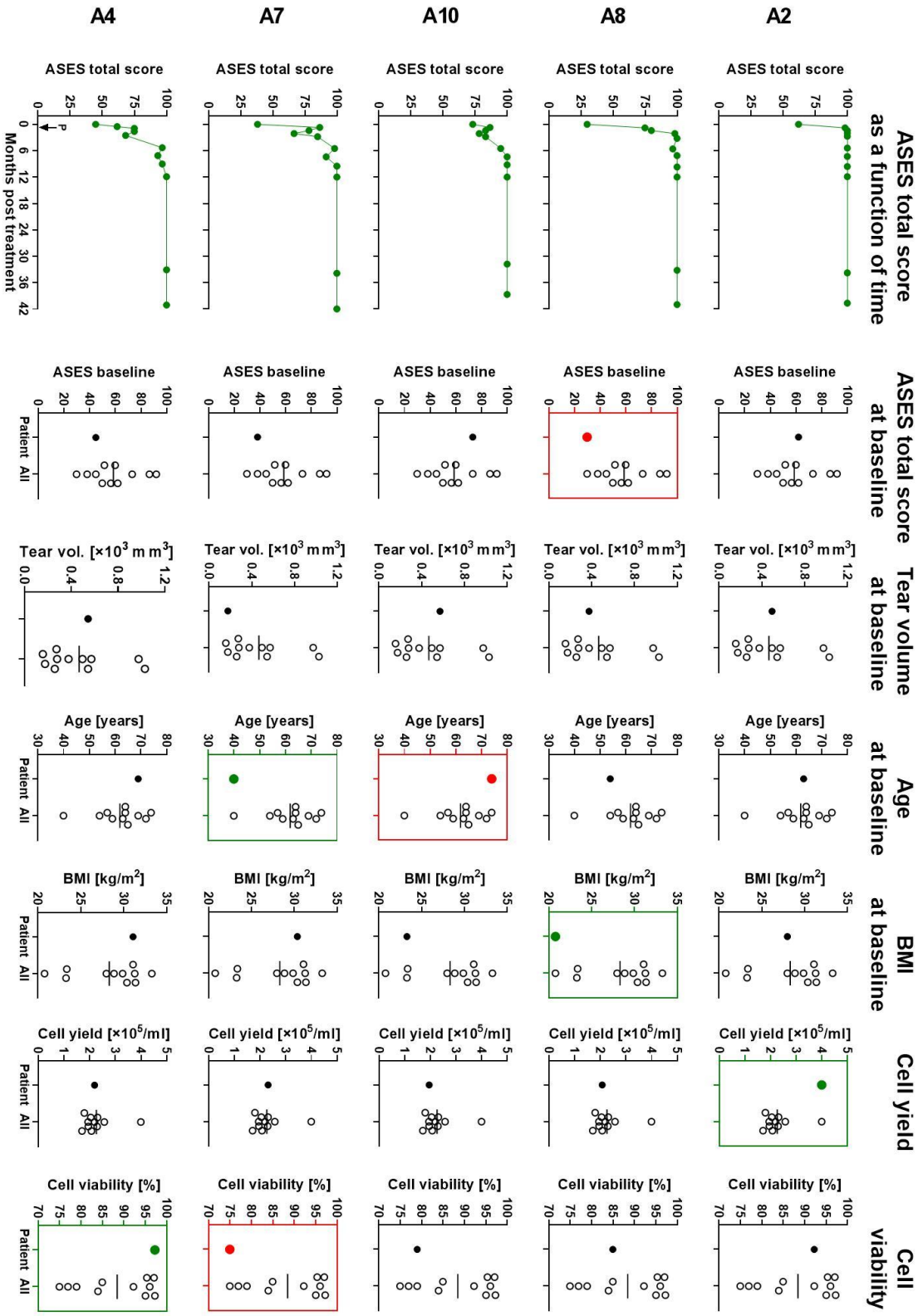

medRxiv preprint doi: https://doi.org/10.1101/2022.12.14.22283447; this version posted December 14, 2022. The copyright holder for this preprint **(which was not certified by peer review)** is the author/funder, who has granted medRxiv a license to display the preprint in perpetuity.

It is made available under a CC-BY 4.0 International license .

FIGURE S20 (cont.)

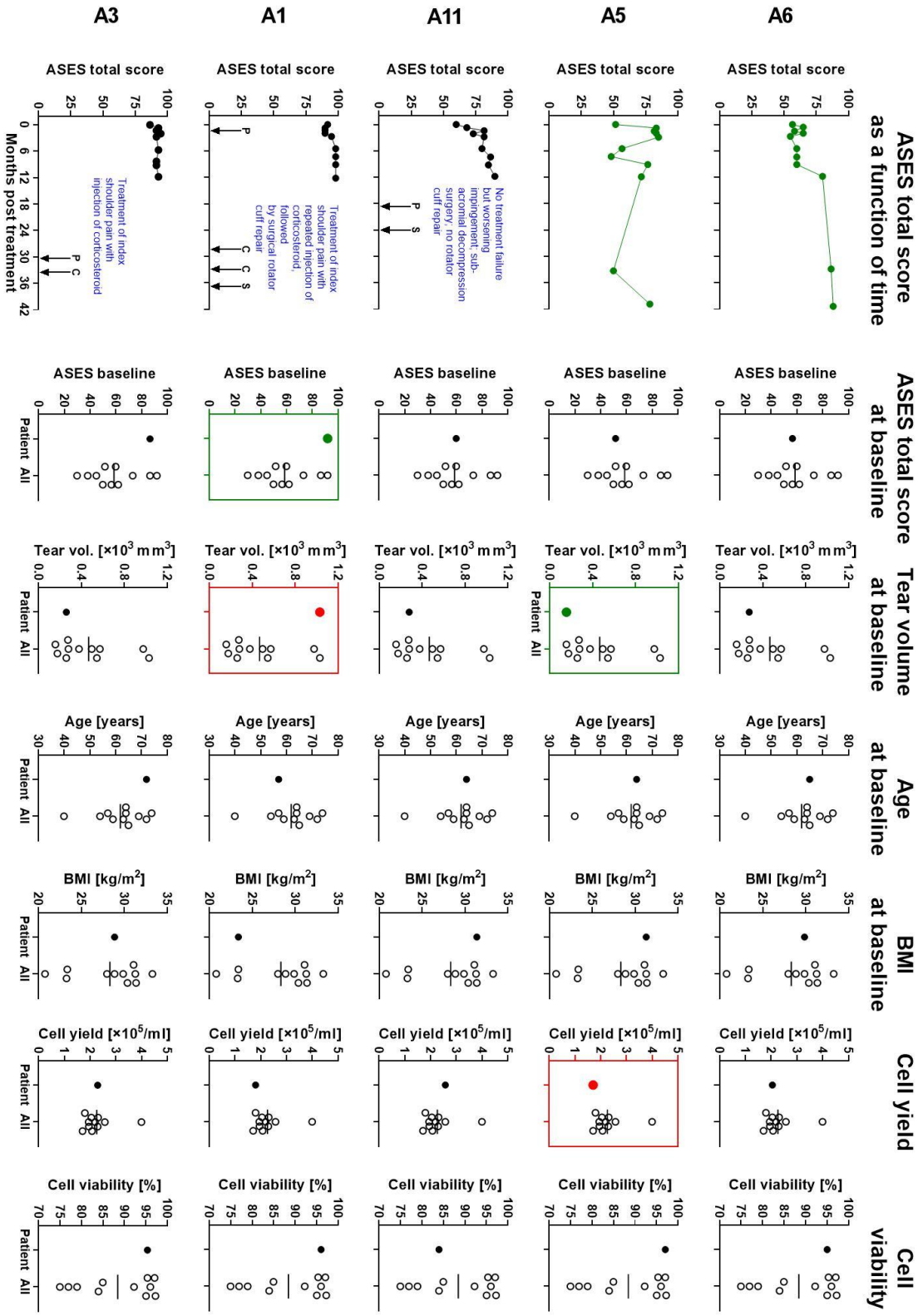

medRxiv preprint doi: https://doi.org/10.1101/2022.12.14.22283447; this version posted December 14, 2022. The copyright holder for this preprint **(which was not certified by peer review)** is the author/funder, who has granted medRxiv a license to display the preprint in perpetuity.

It is made available under a CC-BY 4.0 International license .

FIGURE S20 (cont.)

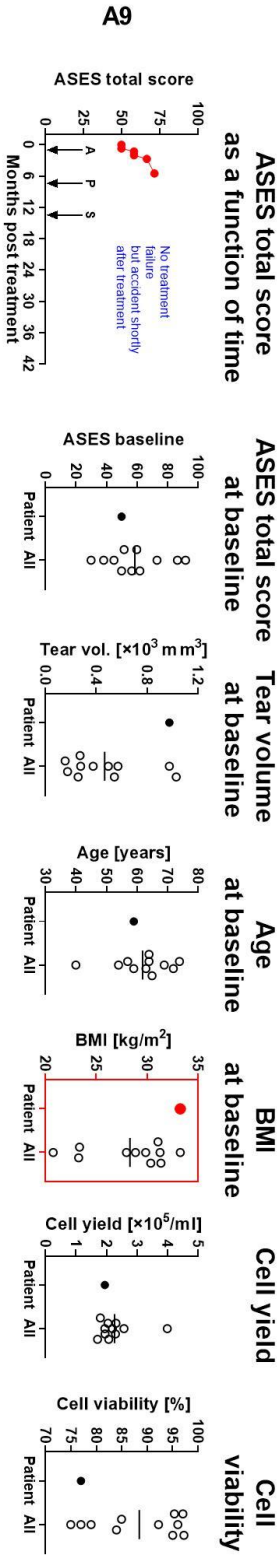

medRxiv preprint doi: https://doi.org/10.1101/2022.12.14.22283447; this version posted December 14, 2022. The copyright holder for this preprint **(which was not certified by peer review)** is the author/funder, who has granted medRxiv a license to display the preprint in perpetuity.

It is made available under a CC-BY 4.0 International license .

FIGURE S21 *(on the next page). Individual ASES Total score as a function of time post-treatment, and individual data at baseline (ASES Total score, tear volume, age and body mass index) of the subjects who were treated with corticosteroid.*

The data are arranged in descending order of individual treatment success (i.e., the data of the subject with the best treatment outcome (C3) are shown in the top row).

In the graphs showing individual ASES Total scores as a function of time post-treatment…

- *green dots and green lines (Subjects A2, A4, A5, A6, A7, A8 and A10) indicate that all data of the present study and the former study were available and could be used for assessing treatment outcome,*
- *black dots and black lines (Subjects A1, A3 and A11) indicate that all data of the former study were available and could be used for assessing treatment outcome, but in the time period between the former study and the present study there was an incidence that rendered the data of the present study unsuitable for assessing treatment outcome (reasons are indicated in the corresponding panels and outlined in detail in Table S15), and*
- *red dots and red lines (Subject A9) indicate that there was an incidence during the former study that rendered a part of the data of the former study (and, thus, all data of the present study in case they were collected) unsuitable for assessing treatment outcome (reasons are indicated in the corresponding panel and outlined in detail in Table S15).*

In the graphs showing individual data at baseline (ASES Total score, tear volume, age and body mass index)…

- *the individual data of the subject whose ASES Total score as a function of time post-treatment is shown in the same row are given on the left ("Subject"), and*
- *the data of all subjects in the corticosteroid group are given on the right ("All"). The horizontal lines represent mean values.*

In addition, for each variable the subject treated with corticosteroid with…

- *presumably the best prognosis (at baseline highest ASES Total score, smallest tear volume, youngest age and lowest body mass index) is indicated with a green dot and green frame surrounding the corresponding data, and*
- *presumably the worst prognonis (at baseline lowest ASES Total score, largest tear volume, oldest age and highest body mass index) is indicated with a red dot and red frame surrounding the corresponding data (note that this was not possible in case of the BMI at baseline because for Subject C5 no height was collected in the former study and, thus, no BMI could be calculated).*

Abbreviations: P, pain in the index shoulder; C, injection of corticosteroid into the index shoulder; S, surgery of the index shoulder.

medRxiv preprint doi: https://doi.org/10.1101/2022.12.14.22283447; this version posted December 14, 2022. The copyright holder for this preprint **(which was not certified by peer review)** is the author/funder, who has granted medRxiv a license to display the preprint in perpetuity.

It is made available under a CC-BY 4.0 International license .

FIGURE S21 (cont.)

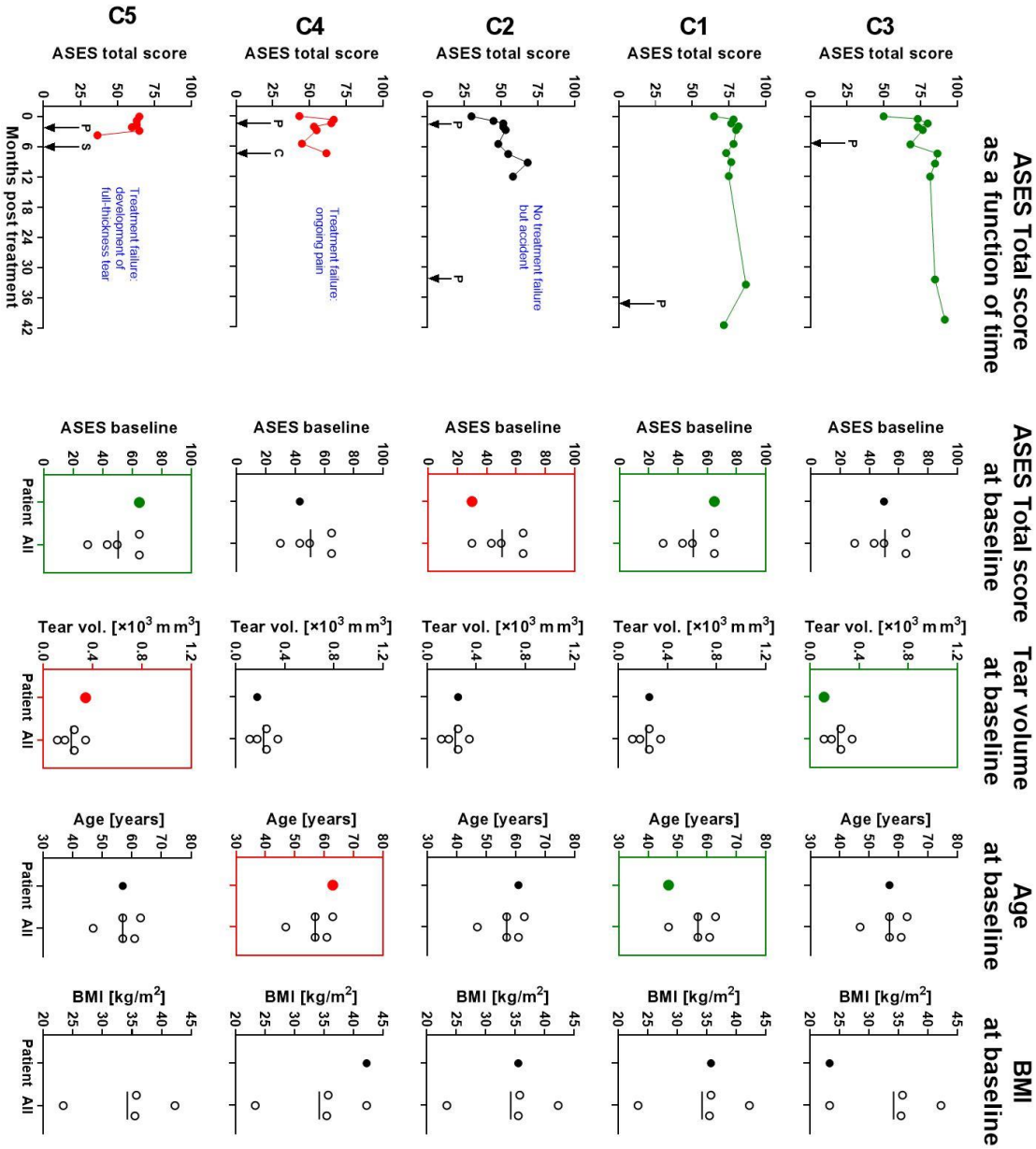

Part 7 – Comparison of the results obtained in the present study and the former study after treatment of sPTRCT with injection of corticosteroid with corresponding results of other studies in the literature

TABLE S20

Details of published studies that investigated the efficacy of treating partial-thickness rotator cuff tears with injections of corticosteroids. References are in the main text.

Study	Treatment	HE	HED	Additional injection of local anesthetic
[12]	2 mL 40 mg/ml methylprednisolone	5	1 x 400	3 mL of 0.25% bupivacaine
[35]	1 ml of 6 mg betamethasone	25	1 x 150	4 mL of 2% xylocaine
[36]	5 ml of 40 mg/ml triamcinolone acetonide*	5	1 x 1000 (?)[a]	--
[37]	1mL of 40 mg/mL methylprednisolone acetate	5	1 x 200	1mL of 1% lignocaine hydrochloride
[38]	7 mg betamethasone (3x, 1x/week)	25	3 x 175	--
[39]	2 mL of 40 mg/ml triamcinolone acetonide	5	1 x 400	2 mL of 1% lidocaine

Abbreviations: HE, hydrocortisone equivalent (https://clincalc.com/Corticosteroids/); HED, hydrocortisone equivalent dose [mg].
[a], incomplete description of dosage ("patients received a cortisone injection [Dermapharm Kenacort® 40 mg (triamcinolone acetonide, crystal suspension)] by means of a 5-ml syringe under aseptic conditions.").

TABLE S21

Results of the studies summarized in Table S20. References are in the main text.

Study	VAS pain score						ASES total score					
		BL		M6				BL		M6		
	n	Mean	SD	Mean	SD	Sig	n	Mean	SD	Mean	SD	Sig
[12]	5	41.2	24.7	39.0	29.4	>0.05	5	50.6	15.0	64.8	12.5	<0.05
[35]	30	54.8[a]	24	45.2	27.7	--	30	46.9	18.3	62.3	22.9	--
[36]	25	--	--	--	--	--	25	50.6	14	77.1	--	<0.01
[37]	19	1.8[b]	0.2	2.4[b]	0.3	0.24	--	--	--	--	--	--
[38]	16	65[c]	--	40[c]	--	--	--	--	--	--	--	--
[39]	33	56.3	9.3	37.7	14.1	<0.001	33	40.13	8.18	55.63	11	<0.001

Abbreviations: BL, baseline; M6, six months post baseline; n, number of subjects investigated; SD, standard deviation; Sig, level of significance (P values); --, not reported.
[a], pain with Neer impingement sign.
[b], scored on a five-point Likert scale (very bad, bad, poor, fair, good) and converted to a numerical score from 0 to 4;
[c], median data.