

Selective IgA₂ deficiency in a patient with small intestinal Crohn's disease

Pablo Canales-Herrerias^{1,2}, Yolanda Garcia-Carmona¹, Hadar Meringer^{1,2}, Gustavo Martinez-Delgado^{1,2}, Michael Tankelevich^{1,2}, Jean-Frederic Colombel^{1,2}, Charlotte Cunningham-Rundles¹, Andrea Cerutti^{1,3,4}, Saurabh Mehandru^{1,2}

¹Precision Immunology Institute, Icahn School of Medicine at Mount Sinai, New York, NY, USA. ²Henry D. Janowitz Division of Gastroenterology, Department of Medicine, Icahn School of Medicine at Mount Sinai, New York, NY, USA. ³Translational Clinical Research Program, Hospital del Mar Medical Research Institute (IMIM), Barcelona, Spain. ⁴Catalan Institute for Research and Advanced Studies (ICREA), Barcelona, Spain.

Address correspondence to: saurabh.mehandru@mssm.edu or aceutti@imim.es

Abstract

The human IgA response is composed of two structurally different subclasses termed IgA₁ and IgA₂. Compared to IgA₁, IgA₂ has a shorter hinge region, which makes it more resistant to bacterial proteases. IgA₁ is produced both systemically and in mucosal surfaces, whereas IgA₂ is mostly confined to the intestines. While the overall IgA response is known to be involved in intestinal homeostasis, the specific contribution of IgA₁ and IgA₂ remains largely unknown (Chen 2020). Selective IgA deficiency (SIgAD) is the most prevalent primary immune deficiency. About half of SIgAD cases are associated with heterogeneous but generally mild clinical manifestations. Anecdotal evidence of IgA₂ deficiency is available (van Loghem 1983, Ozawa 1986, Engström 1990), however no associations with clinical manifestations have been reported.

Here, we describe the occurrence of a selective IgA₂ deficiency in a patient (CD068) with small intestinal Crohn's disease (CD). The patient had undetectable IgA₂⁺ cells and secreted IgA₂ antibody in both intestine and circulation. Among other features, patient CD068 presented with duodenal and ileal inflammation. To our knowledge, this is the first case of IgA₂ deficiency with a potential link to IBD, which might shed new insights into potential IgA₂-specific functions.

Results

Small intestinal (ileal) and colonic biopsies were obtained from patient CD068 (male, 36-40 y/o) with history of duodenal, ileal, and perianal Crohn's Disease (CD). A cohort of healthy donors (n=22) and patients with IBD (n=40) served as controls (Tables S1-S2). Mucosal mononuclear cells and peripheral blood mononuclear cells (PBMCs) were characterized by flow cytometry (Figure 1A).

A complete absence of IgA₂⁺ plasma cells (PCs) was noted in the colon, ileum and peripheral blood of CD068, while IgA₁⁺ PCs were present throughout (Figures 1A, S2). Further, among CD19⁺IgD⁻IgM⁻CD27⁺ memory B cells, IgA₂-switched cells were absent in the ileum, colon and PBMCs of CD068 (Figure 1B).

To compare PCs from CD068 with those from additional IBD patients, we obtained colonic and ileal biopsies from a cohort of 8 UC patients, 6 CD patients, and 19 healthy donors (HDs), and performed flow cytometry on isolated cells (Figure 1C). When intestinal PC populations were analyzed, the frequency of ileal and colonic IgA₁⁺ PCs was comparable in IBD patients and HDs. Similarly, the frequency of IgA₁⁺ PCs from CD068 fell within the interval estimate for HDs (3 standard deviations around the mean). Conversely, a significant loss of IgA₂⁺ cells was detected in inflamed colonic areas from UC patients compared to HDs, which suggests that IgA₂ could have subclass-specific homeostatic functions. Although not significant, there was a trend for the loss of IgA₂⁺ cells in inflamed ileal tissues from CD patients. Together with the loss of IgA₂⁺ PCs, we found an expansion of non-IgA PCs in the same inflamed areas of ileum and colon of IBD patients compared to HDs, as suggested by previous reports (Castro-Dopico 2019, Uzzan 2022). The frequency of IgA⁻ PCs in CD068 was above the HD interval estimate in the ileum, consistent with the presence of inflammation in this tissue. Interestingly, a strong increase of IgA⁻ PCs was also seen in the uninfamed colon of CD068.

To confirm the loss of IgA₂⁺ cells in the gut mucosa, we used tissue immunofluorescence (IF) to stain for IgA₁⁺ and IgA₂⁺ cells. We did not find any IgA₂⁺ cells in the intestinal mucosa of CD068, while IgA₁⁺ cells were readily detected (Figure 1D). To exclude the possibility of lack of detection by our primary antibody, we stained tissue for IgA₁ and total IgA, and found that all IgA⁺ cells were also IgA₁⁺ in CD068. Next, we asked whether secreted antibodies lacked IgA₂ in patient CD068 and measured the concentration of serum IgA₂ by ELISA. While IgA₂ could be readily measured in HDs, no detectable IgA₂ was found in patient CD068 (Figure 1E). In addition, we compared circulating IgA₂ from CD068 with a cohort of 39 IBD patients (27 CD and 12 UC), and found detectable IgA₂ in the entire cohort, except CD068. Considering that IgA₂ is mostly produced in the intestinal mucosa, we also measured gut IgA₂ secretion. For this purpose, we used a biopsy

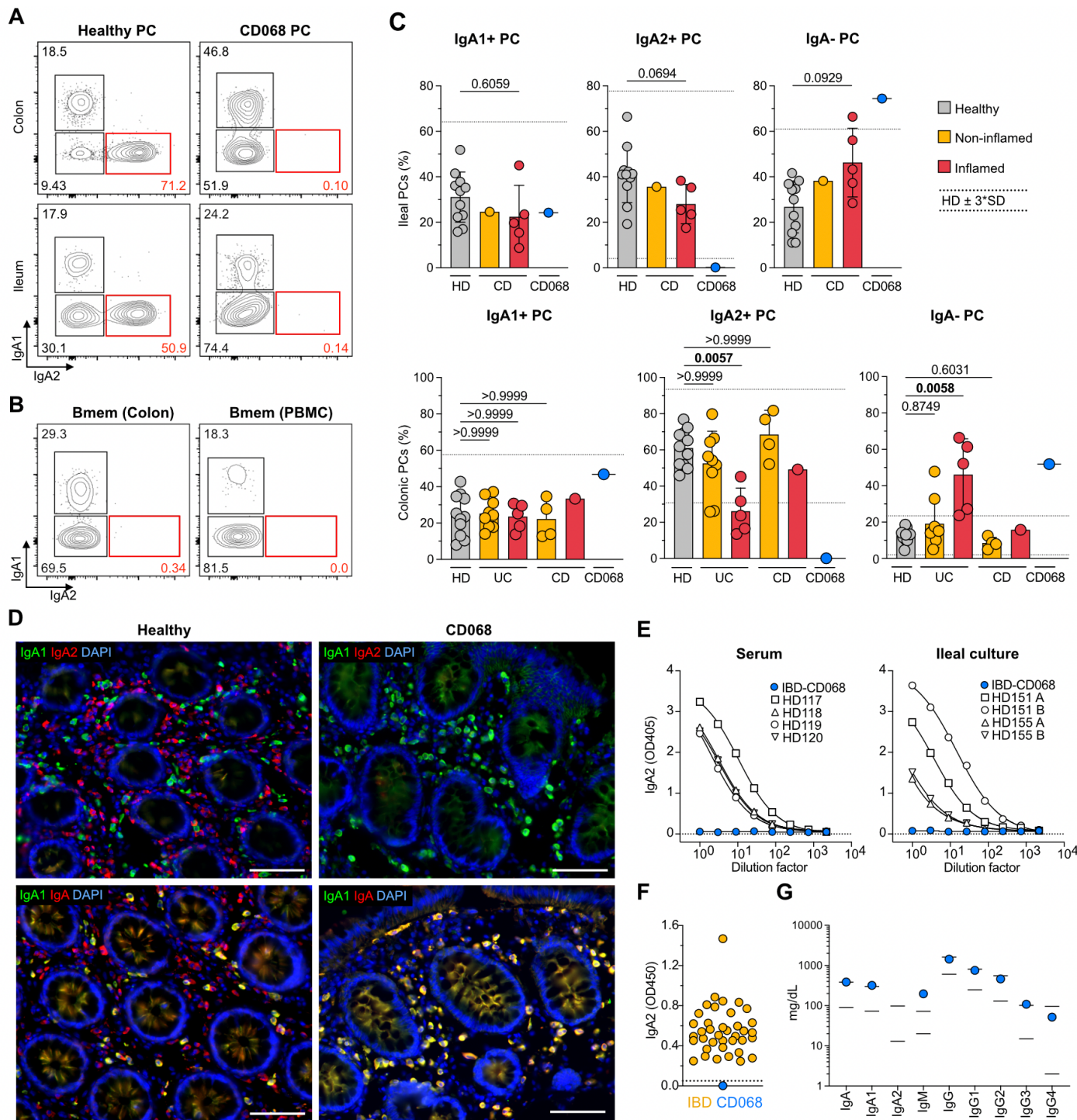


Figure 1. Selective IgA₂ deficiency in a patient with small intestinal CD. (A) Flow cytometric staining of IgA₁ and IgA₂ on intestinal lamina propria and circulating PCs from a representative control HD (left) and IBD patient CD068 (right). (B) Flow cytometric staining of IgA₁ and IgA₂ on memory B cells from colonic lamina propria (left) and peripheral blood (right) from IBD patient CD068. (C) Frequency of PCs from the mucosa of control HDs (gray), noninflamed IBD patients (yellow), inflamed IBD patients (red), and IBD patient CD068 (blue symbol). Ileal mucosal samples are represented in top panels and Colonic mucosal samples in lower panels. Mean and SD are shown. Interval estimate calculated as 3 X SD around the mean of control HDs. (D) Immunofluorescence staining of IgA₁ and IgA₂ (top) as well as IgA₁ and total IgA (bottom) from a representative control HD (left) and IBD patient CD068 (right). (E) ELISA of secreted IgA₂ from serum and ileal tissue culture supernatant of control HDs and IBD patient CD068 (blue symbol). (F) ELISA of secreted IgA₂ from plasma of UC and CD patients (yellow), and IBD patient CD068 (blue symbol). (G) Nephelometry of total serum immunoglobulin levels from control HDs (black lines indicate normal range) and IBD patient CD068 (blue symbol).

culture system to harvest tissue-derived antibodies (Mesin 2011). We found no detectable IgA₂ in biopsy culture supernatant from patient CD068, while we could detect it in biopsy culture supernatant from 4 HD samples. Furthermore, we measured the IgA coating profile of fecal microbiota, and found no IgA₂-coated bacteria in CD068, while IgA₂ coating was readily detected in HD microbiota (Figure S1). To establish if this phenotype was specific to IgA₂, we measured each antibody class and subclass in the serum from patient CD068. In contrast to IgA₂, which remained undetectable, the other antibody isotypes were detectable and comparable to the levels seen in HDs. Interestingly, circulating IgM from patient CD068 was more abundant than IgM from HDs, suggesting that the loss of IgA₂ was compensated for by IgM.

Next, we examined whether B cells from patient CD068 did not produce IgA₂ due to an intrinsic B cell defect and stimulated the patient's PBMCs *in vitro* for 10 days using CD40L and IL-2. While HDs induced both IgA₁⁺ and IgA₂⁺ PCs, no IgA₂⁺ PCs were induced by patient CD068 (Figure S2). Furthermore, a 407 gene panel for immune deficiency was used to examine genetic alterations (data not shown). No homozygous alterations were noted. The patient was found to have 7 variants of unknown significance in *AP3B1*, *C7*, *CCBE1*, *ITGB2*, *SAMD9*, *TCF3*, and *USB1*, and one pathogenic recessive mutation in *TCIRG1* (associated with autosomal recessive osteopetrosis).

Discussion

IgA is thought to be central to the maintenance of intestinal homeostasis and prevention of inflammation. Selective IgA deficiency (SIgAD) is often asymptomatic. Nevertheless, the prevalence of inflammatory bowel disease, especially CD, is higher among the SIgAD population (Ludvigsson 2014). Although patient CD068 did not lack IgA₁, there may be common mechanisms in the pathogenesis of SIgAD and IgA₂-deficiency-related inflammation, considering that IgA₂ is particularly abundant in the intestine.

Selective loss of IgA₁ associated with loss of IgG₂, IgG₄ and/or IgE was described in a few patients due to large homozygous gene deletions in the *IgCH* gene (van Loghem 1983). Loss of IgA₂ in serum was first reported in two members of one family (Zegers 1986); this isotype was also not expressed on lymphocytes even after B cell activation *in vitro*. Using genetic marker (Gm) allotyping, deletion of the $\alpha 2$ gene was proposed (Zegers 1986), however no gross deletions or rearrangements could be detected in these subjects (Oliviero 1986). Loss of IgA₂ by gene deletion was later documented in one patient, who also had loss of IgG₂ and IgG₄ due to homozygous deletions of the $\alpha 2$ and $\alpha 4$ genes (Bottaro 1989, Engstrom 1990). Patient CD068 had normal expression of IgG subclasses confirming no loss of these genes and suggesting a more restricted genetic loss or another mechanism for lack of IgA₂.

Although the functional differences between IgA₁ and IgA₂ remain unclear, these IgA subclasses possibly serve unique roles in the gut mucosa. For example, given its higher resistance to bacterial proteolysis, IgA₂ may be particularly important for preventing luminal microbes from reaching the epithelium, in a process called immune exclusion. Should this be the case, the lack of IgA₂ could increase the penetration capacity of commensal microbes across the gut epithelium. In support of this idea, a loss of IgA₂⁺ PCs in inflamed IBD tissue has been described previously (Kett 1987 & 1988, Boland 2020). The resulting pro-inflammatory environment would favor the induction of IgG⁺ PCs. Accordingly, an expansion of IgG⁺ PCs has been recently described in inflamed IBD tissue (Uzzan, 2022). Of note, IgG released by these pathological PCs would contribute to gut inflammation by delivering FcR-mediated pro-inflammatory signals to myeloid cells (Castro-Dopico 2019).

The small intestine is the largest reservoir of IgA⁺ PCs in the body (Bunker 2015) and contains a bacterial community that is more heavily coated by IgA than in the large intestine (Sterlin 2019). These properties could render the small intestine more susceptible to tissue injury in the context of impaired IgA production. Consistent with this possibility, mouse IgA deficiency has been linked to spontaneous inflammation of the small intestine (Nagaishi 2022); this inflammation was associated with dysbiosis of the local microbiota, which encompassed expansion of segmented filamentous bacteria. Similarly, human IgA₂ deficiency might unbalance the composition and/or function of the gut microbiota, leaving the small intestine particularly susceptible to inflammation. Although a causal relationship between the lack of IgA₂ and CD remains unproven, our study shows novel evidence that documents an association between IgA₂ deficiency (confirmed by multiple, orthogonal assays) and small bowel CD with atypical features (duodenal inflammation). Further studies aimed at dissecting the specific function and reactivity of gut IgA₁ and IgA₂ could lead to a better understanding of the contribution of IgA subclasses to IBD pathogenesis.

Author contributions

PC, SH and AC designed research. PC, YG, HM and GM performed research. PC analyzed data. PC, SM and AC wrote the manuscript.

Acknowledgments

We thank the patients who participated in the study. This work was supported by the following grants: Anonymous Donor (SM and JFC), NIH/NIDDK R01 123749 (SM).

Materials and Methods

Patients

Patients were recruited between 2019 and 2022 in the Inflammatory Bowel Disease Center, the Gastroenterology Department and the Digestive Endoscopy Unit at Mount Sinai Hospital, NY. In accordance with the institutional review board, the protocol was approved and informed consent was obtained from all patients. Detailed patient characteristics are included in Table S1 and S2. Patients enrolled in the study were asked to donate intestinal biopsies and blood. Biopsies were collected during colonoscopies planned for regular care.

Patient CD068 (male, 36-40 y/o) had abdominal pain and bleeding at age 16-20 and diagnosed with stricturing Crohn's disease. He had no medical history of respiratory tract infections, illnesses or hospitalizations. One parent has a history of pemphigus vulgaris; there was no history of consanguinity.

All patient IDs are internal to our laboratory and are used only for purposes of this research project.

Intestinal tissue processing

During colonoscopy, 8-12 biopsies from non-inflamed and/or inflamed regions of the descending colon and terminal ileum were collected with forceps directly into ice-cold RPMI and transported to the laboratory. All biopsies were processed within 3h of collection. Two consecutive rounds of dissociation were performed to remove the epithelium, each consisting of 20 min incubation (37°C, 215rpm) in 10ml HBSS (no calcium and magnesium) (Gibco) containing 5mM EDTA (Invitrogen), 100mM Hepes (Lonza) and 10% FBS, followed by 30s vortex and washing with HBSS. Biopsies were then transferred into 10ml of digestion media, made of RPMI (Gibco) containing 0.5mg/ml Collagenase IV (Sigma-Aldrich), 0.1mg/ml DNase-1 (Roche) and 1% FBS, and were incubated for 40 min (37°C, 215rpm). Biopsies were mechanically disrupted using a syringe needle, before two filtering and washing steps (RPMI) through 100µm and 40µm cell strainers. The single cell suspension was centrifuged (400G, 10 min) and resuspended in RPMI for downstream analysis.

Blood processing

Blood was drawn in EDTA tubes, transported to the lab at room temperature, and processed within 3h of collection. Blood was diluted with PBS 1X (Gibco) and gently overlaid on lymphocyte separation medium (MP Biomedicals). After centrifugation, mononuclear cells were recovered and washed two times with PBS. Serum was collected and immediately stored at -80°C.

Flow cytometry

After isolation from tissue, cells were incubated for 20min at 4°C in PBS containing a mix of staining antibodies. Cells were then

washed with PBS and fixed using PBS with 2% formaldehyde (ChemCruz) for 20 min, before washing with PBS. Cells were resuspended in PBS and acquired within 24h using LSR Fortessa (BD Bioscience). Data was analyzed using FlowJo v10 (FlowJo). A list of antibodies is displayed in Table S3.

Tissue immunofluorescence

Immunofluorescence staining was performed on formalin-fixed, paraffin-embedded intestinal tissue sections of 5µm thickness. Samples were deparaffinized through two 5 min xylene baths, followed by consecutive washes in solutions of decreasing concentration of ethanol in distilled water (100, 90, 80 and 70%), and two 5 min baths in PBS. Antigen retrieval was done using Dako antigen retrieval solution (Dako) and 15 min heating in pressure cooker, before washing 3x with PBS. Samples were blocked using 10% goat serum (Life technologies) or donkey serum (Southern Biotech) for 1h at room temperature. Primary antibodies were then added to the tissue in serum, and samples were incubated overnight at 4°C. Slides were washed with PBS, before adding secondary antibodies and DAPI, which were incubated for 1h at room temperature. Slides were washed with PBS and mounted using Fluoromount G (Electron Microscopy Sciences). A list of antibodies is included in Table S3. Tissue was visualized using a Nikon Eclipse Ni microscope and a Nikon DS-Qi2 camera.

ELISA

Maxisorp ELISA plates (Fischer scientific) were coated with anti-human IgA₂ antibody (Miltenyi) 1µg/ml in Bicarbonate buffer, and incubated for 1.5h at room temperature. After washing with PBS-Tween (PBST) (Sigma), blocking was done using PBST with 3% BSA during 1.5h at room temperature. Before being added to the plate, plasma and serum samples were diluted 1:100 in PBST-BSA, while tissue supernatant was diluted 1:3 in PBST-BSA. Serial dilutions (1:3) were made through the plate, and samples were incubated overnight at 4°C. Plates were washed 3x with PBST, and secondary anti- IgA₂-HRP (Southern Biotech) antibody was added and incubated 1.5h at room temperature. Finally, plates were washed with PBST and TMB substrate was added. Absorbance was measured at 450nm using a plate reader.

Tissue culture

During colonoscopy, biopsies were taken with forceps directly into ice-cold RPMI with 10x Antibiotic-Antimycotic (RPMI-AA) (Gibco), and transported to the lab on ice. Under sterile conditions, biopsies were rinsed on a cell strainer using RPMI-AA 10x. Biopsies were placed in pairs into 48-well plates with 1 ml RPMI-AA 10x per well, and kept from this point at 37°C with 5% CO₂. Culture medium was replaced every 2 days using pre-warmed RPMI-AA 2x. Recovered

culture medium was centrifuged 10min at 14000G and stored at -80°C.

Bacterial flow cytometry

Fecal pellets were dissolved in PBS at 100 mg/ml by vortexing. Fecal slurry was centrifuged 10min at 50G to remove large particles. Supernatant was filtered through a 40nm cell strainer and cells were then washed by centrifugation at 9000G and resuspension in washing buffer (PBS, 1% BSA, 2mM EDTA). Blocking was done using PBS +1% BSA +20% mouse serum, for 20min at 4°C. Cells were stained with anti-human IgA2-PE and anti-human IgA-APC for 30min at 4°C, before washing three times with washing buffer. Samples were stained with SYBR green before analysis by flow cytometry.

Immune globulin measurements

For patient CD068, serum immune globulins were IgG=1,435 (nl 603 - 1,613 mg/dl); IgA=387 (nl 90-386 mg/dl); and IgM= 197 (l n20 - 172 mg/dl). IgE=13 (6-495IU/ml). In terms of IgG subclasses, IgG1- 753 (248 - 810 mg/dL) IgG2 = 464(130 - 555 mg/dL) IgG3 = 108 (15 - 102 mg/dL); IgG4 = 52 (2 - 96 mg/dl). His IgA1 = 391.6 (73.2 - 301.2 mg/dL) mg /dl, and IgA2 = <0.5 (13.4 - 97.9 mg/dL).

Genetic Primary Immunodeficiency Panel

A primary immune deficiency panel of 407 genes was obtained with patient's consent (Invitae Corp, San Francisco CA).

In vitro B cell stimulation

For B cell activation, PBMCs were cultured in RPMI media (Gibco) supplemented with 10% FBS, the presence of CD40L (1µg/ml) (InvivoGen) plus IL-21 (100 ng/ml) (BioLegend) for 10 days. Cells were kept in 24-well plates at 37°C with 5% CO₂. After 10 days of culture, cells were analyzed by Flow cytometry, as indicated before.

References

1. Chen K, Magri G, Grasset EK, Cerutti A. Rethinking mucosal antibody responses: IgM, IgG and IgD join IgA. *Nat Rev Immunol.* 2020 Jul;20(7):427-441.
2. van Loghem E, Zegers BJ, Bast EJ, Kater L. Selective deficiency of immunoglobulin A2. *J Clin Invest.* 1983 Dec;72(6):1918-23.
3. Ozawa N, Shimizu M, Imai M, Miyakawa Y, Mayumi M. Selective absence of immunoglobulin A1 or A2 among blood donors and hospital patients. *Transfusion.* 1986 Jan-Feb;26(1):73-6.
4. Engström PE, Norhagen G, Bottaro A, Carbonara AO, Lefranc G, Steinitz M, Söder PO, Smith CI, Hammarström L. Subclass distribution of antigen-specific IgA antibodies in normal donors and individuals with homozygous C alpha 1 or C alpha 2 gene deletions. *J Immunol.* 1990 Jul 1;145(1):109-16.
5. Mesin L, Di Niro R, Thompson KM, Lundin KE, Sollid LM. Long-lived plasma cells from human small intestine biopsies secrete immunoglobulins for many weeks in vitro. *J Immunol.* 2011 Sep 15;187(6):2867-74.
6. Ludvigsson JF, Neovius M, Hammarström L. Association between IgA deficiency & other autoimmune conditions: a population-based matched cohort study. *J Clin Immunol.* 2014 May;34(4):444-51.
7. Chen K, Magri G, Grasset EK, Cerutti A. Rethinking mucosal antibody responses: IgM, IgG and IgD join IgA. *Nat Rev Immunol.* 2020 Jul;20(7):427-441.
8. van Loghem E, Zegers BJ, Bast EJ, Kater L. Selective deficiency of immunoglobulin A2. *J Clin Invest.* 1983 Dec;72(6):1918-23.
9. Ozawa N, Shimizu M, Imai M, Miyakawa Y, Mayumi M. Selective absence of immunoglobulin A1 or A2 among blood donors and hospital patients. *Transfusion.* 1986 Jan-Feb;26(1):73-6.
10. Engström PE, Norhagen G, Bottaro A, Carbonara AO, Lefranc G, Steinitz M, Söder PO, Smith CI, Hammarström L. Subclass distribution of antigen-specific IgA antibodies in normal donors and individuals with homozygous C alpha 1 or C alpha 2 gene deletions. *J Immunol.* 1990 Jul 1;145(1):109-16.
11. Mesin L, Di Niro R, Thompson KM, Lundin KE, Sollid LM. Long-lived plasma cells from human small intestine biopsies secrete immunoglobulins for many weeks in vitro. *J Immunol.* 2011 Sep 15;187(6):2867-74.
12. Ludvigsson JF, Neovius M, Hammarström L. Association between IgA deficiency & other autoimmune conditions: a population-based matched cohort study. *J Clin Immunol.* 2014 May;34(4):444-51.
13. Uzzan M, Martin JC, Mesin L, Livanos AE, Castro-Dopico T, Huang R, Petralia F, Magri G, Kumar S, Zhao Q, Rosenstein AK, Tokuyama M, Sharma K, Ungaro R, Kosoy R, Jha D, Fischer J, Singh H, Keir ME, Ramamoorthi N, Gorman WEO, Cohen BL, Rahman A, Cossarini F, Seki A, Leyre L, Vaquero ST, Gurunathan S, Grasset EK, Losic B, Dubinsky M, Greenstein AJ, Gottlieb Z, Legnani P, George J, Irizar H, Stojmirovic A, Brodmerkel C, Kasarkis A, Sands BE, Furtado G, Lira SA, Tuong ZK, Ko HM, Cerutti A, Elson CO, Clatworthy MR, Merad M, Suárez-Fariñas M, Argmann C, Hackney JA, Victora GD, Randolph GJ, Kenigsberg E, Colombel JF, Mehandru S. Ulcerative colitis is characterized by a plasmablast-skewed humoral response associated with disease activity. *Nat Med.* 2022 Apr;28(4):766-779.
14. Castro-Dopico T, Dennison TW, Ferdinand JR, Mathews RJ, Fleming A, Clift D, Stewart BJ, Jing C, Strongili K, Labzin LI, Monk EJM, Saeb-Parsy K, Bryant CE, Clare S, Parkes M,

- Clatworthy MR. Anti-commensal IgG Drives Intestinal Inflammation and Type 17 Immunity in Ulcerative Colitis. *Immunity*. 2019 Apr 16;50(4):1099-1114.e10.
15. Kett K, Brandtzaeg P. Local IgA subclass alterations in ulcerative colitis and Crohn's disease of the colon. *Gut*. 1987 Aug;28(8):1013-21.
16. Kett K, Brandtzaeg P, Fausa O. J-chain expression is more prominent in immunoglobulin A2 than in immunoglobulin A1 colonic immunocytes and is decreased in both subclasses associated with inflammatory bowel disease. *Gastroenterology*. 1988 Jun;94(6):1419-25.
17. Boland BS, He Z, Tsai MS, Olvera JG, Omilusik KD, Duong HG, Kim ES, Limary AE, Jin W, Milner JJ, Yu B, Patel SA, Louis TL, Tysl T, Kurd NS, Bortnick A, Quezada LK, Kanbar JN, Miralles A, Huylebroeck D, Valasek MA, Dulai PS, Singh S, Lu LF, Bui JD, Murre C, Sandborn WJ, Goldrath AW, Yeo GW, Chang JT. Heterogeneity and clonal relationships of adaptive immune cells in ulcerative colitis revealed by single-cell analyses. *Sci Immunol*. 2020 Aug 21;5(50): eabb4432.
18. Bunker JJ, Flynn TM, Koval JC, Shaw DG, Meisel M, McDonald BD, Ishizuka IE, Dent AL, Wilson PC, Jabri B, Antonopoulos DA, Bendelac A. Innate and Adaptive Humoral Responses Coat Distinct Commensal Bacteria with Immunoglobulin A. *Immunity*. 2015 Sep 15;43(3):541-53.
19. Sterlin D, Fadlallah J, Adams O, Fieschi C, Parizot C, Dorgham K, Rajkumar A, Autaa G, El-Kafsi H, Charuel JL, Juste C, Jönsson F, Candela T, Wardemann H, Aubry A, Capito C, Brisson H, Tresallet C, Cummings RD, Larsen M, Yssel H, von Gunten S, Gorochov G. Human IgA binds a diverse array of commensal bacteria. *J Exp Med*. 2020 Mar 2;217(3):e20181635.
20. Nagaishi T, Watabe T, Kotake K, Kumazawa T, Aida T, Tanaka K, Ono R, Ishino F, Usami T, Miura T, Hirakata S, Kawasaki H, Tsugawa N, Yamada D, Hirayama K, Yoshikawa S, Karasuyama H, Okamoto R, Watanabe M, Blumberg RS, Adachi T. Immunoglobulin A-specific deficiency induces spontaneous inflammation specifically in the ileum. *Gut*. 2022 Mar;71(3):487-496.
21. Zegers BJ, van Loghem E, Out T, et al. Familial deficiency of immunoglobulin IgA2. *Monogr Allergy*. 1986;20:195-202.
22. Oliviero S, DeMarchi M, Bast BJ, Zegers BJ, van Loghem E, de Lange G, Carbonara O. Molecular analysis of a case of IgA2 deficiency. *J Immunogenet*. 1986 Feb;13(1):3-9. doi: 10.1111/j.1744-313x.1986.tb01077.x.
23. Bottaro A, De Marchi M, De Lange G, Boccazzi C, Caldesi F, Gallina R, Carbonara AO. New types of multiple and single gene deletions in the human IgCH locus. *Immunogenetics*. 1989;29(1):44-8. doi: 10.1007/BF02341612. Erratum in: *Immunogenetics* 1989;29(3):224

Figure S1

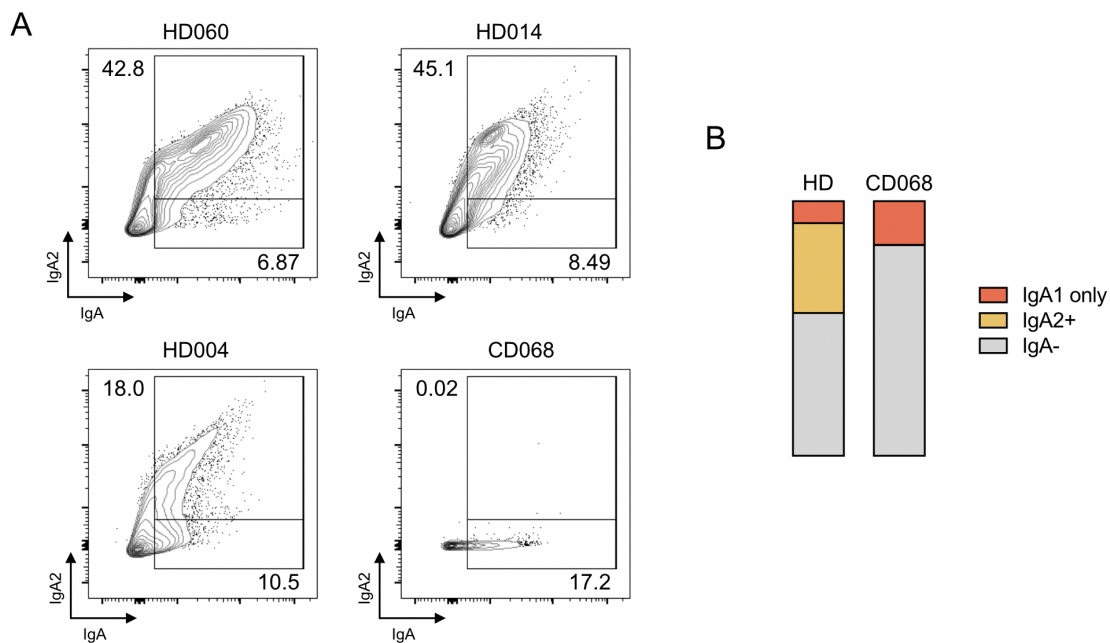


Figure S1. Profile of IgA coating on fecal microbiota. (A) Flow cytometric analysis of IgA⁺ and IgA₂⁺ microbiota from healthy donors and patient CD068. Cells were previously gated for SYBR green positivity. Frequency of IgA₂⁺ and IgA₁ only are indicated. (B) Average proportions of IgA₁ only, IgA₂⁺ and IgA⁻ cells are indicated for HDs and patient CD068.

Figure S2

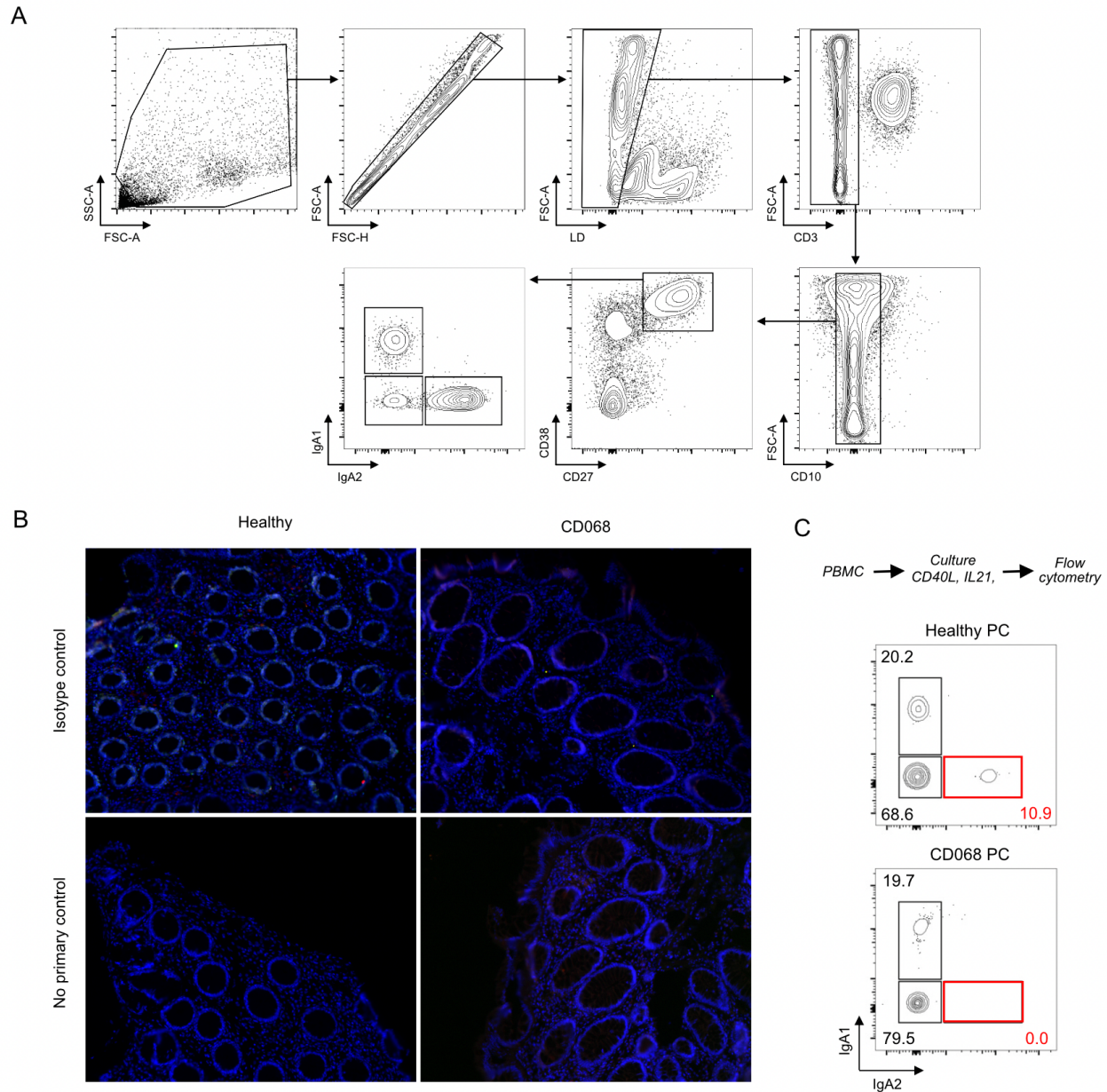


Figure S2. Unknown B cell-intrinsic defect in a patient with selective IgA₂ deficiency associated with small intestinal CD. (A) Gating strategy used to identify viable CD3⁺CD10⁺CD27⁺CD38^{high} PCs within colonic lamina propria mononuclear cells. (B) Immunofluorescence analysis of isotype controls or non-primary IgA₁ and IgA₂ controls in colonic tissue sections from a representative HD (left) or patient CD068. (C) Flow cytometric staining of IgA₁ and IgA₂ on PCs from PBMCs stimulated *in vitro* for 10 days with CD40L and IL-21. PCs were gated as in (A).

Table S1. Patient characteristics (where flow cytometry was performed)

Study number	Gender 0-female 1-male	Age range (years)	Duration of Disease	Previous IBD therapies	Concomitant IBD therapy	Comorbid illnesses (1 yes)	Non-IBD medications	Disease extent	Disease behavior
IBDCD066	0	41-45	1 month	none	none	1	ocrelizumab (MS), off for 1 year due to COVID	L3	B1+perianal
IBDCD067	0	16-20	2 years	none	none	0	none	L1+L4	B1
IBDCD068	1	36-40	19 years	5ASA, infliximab, s/p ICR, adalimumab	ustekinumab	0	none	L1+L4	B2
IBDCD070	1	21-25	6 months	none	none	0	none	L1	B1
IBDCD072	1	26-30	1.5 years	none	ustekinumab	0	none	L1	B1
IBDCD078	1	51-55	32 years	steroids, s/p ICR, and repeated SB surgeries	adalimumab	1	lamotrigine, cariprazine, sumatriptan, atorvastatin, propranolol, fenofibrate, eszopiclone, testosterone	L3	B2
IBDCD079	1	36-40	unknown	s/p ICR and colostomy > stoma reversal,	infliximab	0	none	L3	B2
IBDUC103	1	51-55	18 years	5ASA, steroids, infliximab, adalimumab, MTX, vedolizumab	tofacitinib	1	statin, clopidogrel vitamin D	E2, currently on remission	
IBDUC104	0	76-80	12 years	6MP	5ASA	1	amlodipine, valsartan, thiazide, statin, montelukast cetirizine	E3, currently on remission	
IBDUC108	1	36-40	4 years	prednisone	vedolizumab	1	atorvastatin, tamsulosin, PPI	E3, currently on remission	
IBDUC114	0	36-40	8 years	none	infliximab	0	none	E2, currently only mild proctitis	
IBDUC120	1	36-40	1 year	steroids	5ASA	0	none	E3, active moderate- severe in colon, the rest mild	
IBDUC124	0	31-35	1 year	steroids 5ASA vedolizumab	infliximab	1	rivaroxaban	E3 pancolitis	
IBDUC128	1	51-55	12 years	none	5ASA	0	none	E3 pancolitis	
UC316	1	31-35	7 years	none	5ASA	0	none	E2	
IBD011 (UC)	1	21-25	6 years	5ASA, infliximab, MTX	infliximab	0	none	left sided colitis (m/p UC and not CD)	
NV126	1	36-40				0	none		
NV127	1	56-60				1	losartan, thiazide, PPI (morbid obesity, OSA, HTN)		
NV128	1	76-80				1	aspirin, atorvastatin, losartan, thiazide, amlodipine (HTN, osteoarthritis, gait disorder)		
NV136	0	61-65				1	interferon beta1, metformin, sitagliptin, statin, losartan, aspirin (HTN hyperlipidemia, multiple sclerosis, diabetes, s/p CRC and hemicolectomy)		
NV137	0	51-55				1	bupropion, levothyroxine, statin		
NV138	0	46-50				0	none (s/p breast cancer)		
NV139	1	76-70				1	atorvastatin, candesartan, metformin, tamsulosin, rivaroxaban, gabapentin		
NV140	0	46-50				0	none		
NV143	1	46-50				1	amlodipine, metformin, irbesartan, statin		
NV144	1	16-20				1	PPI (eosinophilic esophagitis)		
NV146	0	36-40				0	none		
NV147	0	46-50				1	benztropine, aripiprazole (autism)		
NV148	1	66-70				0	aspirin preventive (no concomitant disease)		
NV168	1	56-60				1	PPI, atorvastatin, inhalers (dyslipidemia, GERD, OSA, COPD, prostate cancer)		
NV192	1	41-45				0	none		
NV193	0	76-80				1	aspirin, amlodipine, losartan, statin		
NV195	0	61-65				1	lisinopril, amlodipine, statin, PPI, thyroxine		
NV196	0	36-40				0	none		
NV197	0	36-40				0	s/p adenoid cystic carcinoma of hard palate 2018		
NV060	0	46-50				0	none		
NV014	1	41-45				0	none		
NV004	0	26-30				0	none		

Table S1. Abbreviations: 5ASA (5-aminosalicylic acid), s/p (status post), ICR (Ileocolonic resection), MTX (methotrexate), 6MP (mercaptopurine), PPI (proton pump inhibitor), OSA (obstructive sleep apnea), HTN (hypertension), CRC (colorectal cancer), GERD (gastroesophageal reflux disease), COPD (chronic obstructive pulmonary disease). All patient IDs are internal to our laboratory and are used only for purposes of this research project.

Table S2. Patient characteristics (where plasma was used for immunoglobulin quantification)

Study number	Gender 0-female 1-male	Age range (years)	Duration of Disease	Previous IBD therapies	Concomitant IBD therapy	Non-IBD medications	Disease extent	Disease behavior
IBDCD002	0	46-50	24 years	MTX, steroids, 5ASA, antibiotics, s/p ICR, infliximab	none (off meds d/t pancreatic cancer)	none	L3+4	B3
IBDCD007	1	41-45	18 years	5ASA, s/p surgery (ICR, segmental sigmoidectomy and takedown of vesical fistula), adalimumab, thiopurines, infliximab	ustekinumab (q4weeks)	none	L3	B3 + perianal fistula
IBD011 (UC)	1	21-25	4 years		5ASA	none	left sided colitis (m/p UC and not CD)	
IBDCD012	1	26-30	4 years	none	CDED nutrition, no medical therapy	none	L3	inflammatory + perianal fistula
IBDCD014	0	51-55	14 years	s/p ICR, infliximab, adalimumab	vedolizumab	levothyroxine, PPI	L3	B3
IBDCD015	1	36-40	24 years	5ASA, antibiotics, thiopurines, adalimumab, infliximab, previous surgical therapies	vedolizumab	none	L3	B2 stricturing + perianal
IBDCD016	0	46-50	6 years	5ASA	5ASA	none	L3	B2 stricturing + perianal
IBDCD017	0	31-35	17 years	s/p ileocectomy (X2), infliximab, adalimumab, ustekinumab	none	none	L3	penetrating
IBDCD020	0	56-60	50 years		thiopurines +5ASA	PPI	L2	stricturing
IBDCD022	1	31-35	15 years	surgery, certolizumab, infliximab, adalimumab, ustekinumab	adalimumab	none	L1+L4	Structuring + perianal
IBDCD027	0	41-45	16 years	5ASA, vedolizumab	infliximab	none	L3	B1+perianal
IBDCD029	0	46-50	19years	Surgery (right hemicolectomy, stoma and reversal)	vedolizumab	Lorazepam, simethicone	L3	B3
IBDCD030	0	21-25	14 years	infliximab, adalimumab, 6MP, vedolizumab, MTX, 5ASA antibiotics	prednisone	PPI	L2+L4 upper duodenum	B1
IBDCD032	1	21-25	22 years	5ASA	none	finasteride	L2	B1
IBDCD033	1	31-35	3 years	s/p ICR and sigmoidectomy, 6MP, infliximab	ustekinumab	none	L2	B3+perianal
IBDCD035	0	66-70	24years	5ASA, infliximab, s/p surgery (ileosigmoid fistula takedown, ileocolic resection, right colon resection, jejunocolic anastomosis, sigmoid resection)	adalimumab	levetiracetam, lorazepam, cholestyramine	L3+4	B3
IBDCD037	1	31-35	22 years	s/p ICR, 5ASA, 6MP, infliximab	adalimumab	none	L1	B2
IBDCD040	0	61-65	19 years	5asa	none	risedronate	L2	B3+perianal
IBDCD041	1	41-45	6 years	infliximab, 6MP, mongersen trial	ustekinumab	losartan	L3	B1
IBDCD042	0	31-35	6 years	infliximab, adalimumab, vedolizumab and tofacitinib	ustekinumab	none	L3	B2
IBDCD044	0	36-40	18 years	5ASA, azathioprine	infliximab	none	L2	B1+perianal
IBDCD056	1	36-40	7 years	adalimumab	none	none	L2	B2+perianal
IBDCD060	0	31-35	8 years	s/p ICR	none	none	L3	B2
IBDCD061	0	36-40	2 years	antibiotics, infliximab	adalimumab	lamotrigine	L3	B1+perianal
IBDCD062	1	31-35	20 years	mesalamine, antibiotics, steroids, infliximab	adalimumab	tadalafil	L3	B2
IBDUC001	0	66-70	25 years	5ASA, steroids	vedolizumab	amlodipine, raloxifene, PPI	E2 (now on remission)	
IBDUC036	0	46-50	1 year	none	5ASA	lamotrigine, levothyroxine, aripiprazole	E2	
IBDUC037	0	61-65	7 years	5ASA, steroids	vedolizumab	none	E2	
IBDUC040	0	31-35	10 years	steroids, infliximab, adalimumab, vedolizumab	ustekinumab	none	E3	
IBDUC041	1	51-55	10 years	5ASA infliximab	5ASA	metformin, insulin, lisinopril	E3	
IBDUC042	0	21-25	1 month	none	steroids	none	E3	
IBDUC044	1	36-40	23 years	5ASA, adalimumab, infliximab, azathioprine, prednisone	infliximab	none	E3	
IBDUC104	0	76-80	18 years	6MP, 5ASA	5ASA	Losartan, hydrochlorothiazide, atorvastatin, montelukast, amlodipine	E3	

Table S2. Abbreviations: MTX (methotrexate), 5ASA (5-aminosalicylic acid), s/p (status post), ICR (Ileocolonic resection), 6MP (mercaptopurine), CDED (Crohn's Disease Exclusion Diet), PPI (proton pump inhibitor), OSA (obstructive sleep apnea), HTN (hypertension), CRC (colorectal cancer), GERD (gastroesophageal reflux disease), COPD (chronic obstructive pulmonary disease). All patient IDs are internal to our laboratory and are used only for purposes of this research project.

Table S3. Antibodies used in the study

Flow cytometry				
Marker	Fluorochrome	Supplier	Catalog #	Clone
CD19	PE Cy7	Biolegend	363012	SJ25C1
CD27	PerCP Cy5.5	Biolegend	302819	O323
CD10	APC Cy7	Biolegend	312212	HI10a
CD38	APC	Biolegend	356606	HB-7
IgD	PB	Biolegend	348223	IA6-2
IgM	AF700	Biolegend	314538	MHM-88
CD45	PE Dazzle 594	Biolegend	304052	HI30
CD3	BV605	Biolegend	300460	UCHT1
IgA1	A488	Southern Biotech	9130-30	B3506B4
IgA2	PE	Miltenyi	130-100-316	IS11-21E11
Immunofluorescence				
Marker	Fluorochrome	Supplier	Catalog #	Clone
rabbit anti-human IgA1	pure	Abcam	ab193187	RM124
mouse anti-human IgA2	pure	Miltenyi	130-093-081	IS11-21E11
goat anti-human IgA	pure	Abcam	ab98550	polyclonal
goat anti-mouse	AF594	Abcam	ab150116	polyclonal
goat anti-rabbit	AF488	Abcam	ab150077	polyclonal
donkey anti-goat	AF594	Abcam	ab150132	polyclonal
donkey anti-rabbit	AF488	Abcam	ab150073	polyclonal