Early, low-dose hydrocortisone and near-term brain connectivity in extremely preterm infants

Sarah E. Dubner, MD[a], Lucy Rickerich, BS[b], Lisa Bruckert, PhD[a], Rocío Poblaciones, BS[a], Dawson Sproul, BS[b], Melissa Scala, MD[c], Heidi M. Feldman, MD, PhD[a], Katherine E. Travis, PhD[a]

Affiliations: [a]Division of Developmental-Behavioral Pediatrics, Department of Pediatrics, Stanford University, Stanford, California, United States; [b]Program in Human Biology, Stanford University, Stanford, California, United States; [c]Division of Neonatal and Developmental Medicine, Department of Pediatrics, Stanford University, Stanford, CA, United States.

Address correspondence to: Katherine E. Travis, Developmental-Behavioral Pediatrics, Stanford University School of Medicine, 3145 Porter Drive, MC 5395, Palo Alto, CA 94304, ktravis1@stanford.edu, 650-498-7690

Short title: Hydrocortisone and brain connectivity in preterm birth

Conflict of Interest Disclosures (includes financial disclosures): The authors have no conflicts of interest to disclose.

Funding/Support: All phases of this study were supported by the Society for Developmental Behavioral Pediatrics Research Grant to Sarah E. Dubner, and by the National Institutes of Health- *Eunice Kennedy Shriver* National Institute of Child Health and Human Development (K.E. Travis, PI; 5R00HD8474904; H.M. Feldman, PI; 2RO1- HD069150).

Role of Funder/Sponsor (if any): The NIH and SDBP had no role in the design and conduct of the study.

Data Sharing Statement: Deidentified data will be made available upon reasonable request made to the corresponding author.

Abbreviations: AFQ Automated Fiber Quantification, BPD Bronchopulmonary Dysplasia, dMRI diffusion magnetic resonance imaging, CSD constrained spherical deconvolution, CST corticospinal tract, EPI echoplanar imaging, FA fractional anisotropy, FOD fiber orientation dispersion, ILF inferior longitudinal fasciculus, LPCH Lucile Packard Children's Hospital, MD mean diffusivity, NICU neonatal intensive care unit, NP non-protocol, P protocol, PMA post-menstrual age, PT preterm, ROI region of interest, RTP Reproducible Tract Profiles, SCP superior cerebellar peduncle

Article Summary: This study examines brain microstructural connectivity among extremely preterm infants who did or did not receive protocolized hydrocortisone during the first ten days after birth.

What is Known on This Subject: Postnatal glucocorticoids to prevent bronchopulmonary dysplasia in extremely preterm infants have been associated with smaller cerebral and cerebellar brain volumes.

What this Study Adds: Low dose hydrocortisone in the first 10 days of life was not associated with significant differences in white matter microstructure in major cerebral and cerebellar pathways.

Contributors Statement Page:

Dr. Sarah Dubner conceptualized and designed the study, coordinated and supervised data collection, carried out the data analyses and interpretation, drafted the initial manuscript, and critically reviewed and revised the manuscript.
Lucy Rickerich collected data, performed initial data analyses, drafted the initial manuscript, and critically reviewed and revised the manuscript.
Dawson Sproul collected data and critically reviewed and revised the manuscript.
Rocio Poblaciones performed data analysis and critically reviewed and revised the manuscript.
Dr. Lisa Bruckert supervised and performed data analysis and critically reviewed and revised the manuscript.
Dr. Melissa Scala critically reviewed and revised the manuscript for important intellectual content.
Dr. Heidi M. Feldman conceptualized and designed the study and critically reviewed and revised the manuscript for important intellectual content.
Dr. Katherine E. Travis coordinated and supervised data collection, supervised analysis and critically reviewed and revised the manuscript for important intellectual content.

All authors approved the final manuscript as submitted and agree to be accountable for all aspects of the work.

ABSTRACT

Background and Objectives: Early postnatal steroid administration is a strategy to prevent bronchopulmonary dysplasia (BPD) in extremely preterm-born infants. The effect of low dose, early, postnatal hydrocortisone on brain white matter is unknown. This study assessed variation in connectivity metrics of major white matter pathways in the cerebrum and cerebellum at near-term gestational age among infants who did or did not receive a standardized regimen of hydrocortisone during the first 10 days of life.

Methods: Retrospective cohort study. Participants: Infants born < 28 weeks gestation, divided into 2 groups based on steroid protocol: Protocol group had 50%-150% of the protocol, 0.5mg/kg hydrocortisone twice daily for 7 days, followed by 0.5 mg/kg per day for 3 days (n=33) versus Non-Protocol, (0 to less than 50% protocol dose, n=22). Infants had near-term diffusion MRI (dMRI) as part of the clinical imaging protocol. We assessed group differences in dMRI mean fractional anisotropy (FA) and mean diffusivity (MD) across the corticospinal tract, inferior longitudinal fasciculus, anterior, middle, and posterior corpus callosum and superior cerebellar peduncle.

Results: The groups were well matched on gestational age, post-menstrual age at scan, total number of medical complications, incidence of BPD (i.e., needing O2 at 36 weeks), and incidence of necrotizing enterocolitis. No significant group differences were identified in mean FA or MD in any cerebral or cerebellar tract between the two groups.

Conclusion(s): Low dose, early, postnatal hydrocortisone was not associated with significant differences in white matter tract microstructure at near term gestational age.

INTRODUCTION

Bronchopulmonary dysplasia (BPD) is a severe complication of prematurity, characterized by chronic pulmonary inflammation. BPD is associated with cerebral palsy and poor neurodevelopmental outcomes.[1,2] Adverse outcomes in BPD have been attributed, in part, to local inflammation in the brain and to systemic inflammatory response.[3] Inflammation induces brain white matter alterations via damage to the white matter producing precursor cells, the pre-oligodendrocytes. Altered pre-oligodendrocyte maturation may affect white matter microstructure development, even in the apparent absence of gross injury on clinical MRI.[3] These white matter changes are detectable using advanced dMRI neuroimaging techniques.[4] Preterm (PT) infants who go on to develop BPD are proposed to have early hypo-responsiveness of the hypothalamic-pituitary-adrenal axis, are unable to secrete sufficient cortisol in response to inflammatory triggers at the time of PT birth, and thus have relative adrenal insufficiency.[5] Early hydrocortisone administration, soon after birth, as described in the PREMILOC study, is an intervention aimed at preventing BPD by addressing relative adrenal insufficiency.[6] In the PREMILOC study, survival without BPD was significantly improved in the treatment group (OR 1.48, 95%CI 1.02-2.16). No differences were reported in cerebral volumes of treated infants at near-term.[7] However, the effect of IV hydrocortisone on early white matter brain development, which has important links to neurodevelopment, remains unknown.

Potent glucocorticoids, such as dexamethasone, have been shown to deleterious effects on brain development.[8–10] Hydrocortisone is 25 times less potent than dexamethasone and mechanistically mimics naturally-occurring cortisol. Like other glucocorticoids, hydrocortisone may delay maturation of pre-oligodendrocytes, and confer an adverse effect on white matter development. However, hydrocortisone's reduction of systemic inflammation may result in less

damage to pre-oligodendrocytes than the infant would have otherwise experienced without treatment. How this balance of potential positive and negative effects plays out in the developing infant brain remains unclear. The safety of hydrocortisone with respect to brain development is crucial for deciding whether hydrocortisone should be used to prevent bronchopulmonary dysplasia.[6,11] Several studies examining postnatal hydrocortisone use in extremely preterm infants found no significant differences in cerebral volumes,[12–14] though one study[15] identified attenuated growth in cerebellar volumes in infants who received hydrocortisone in the neonatal period.

No studies to date have investigated the effects of early postnatal hydrocortisone on the microstructure of white matter brain tissue in preterm infants. The objective of this investigation was to assess differences in white matter microstructural metrics, as indexed by diffusion MRI metrics (dMRI) fractional anisotropy (FA) and mean diffusivity (MD), of major white matter circuits at near-term equivalent age between two groups of infants born extremely preterm (< 28 weeks gestational age) who received either early, low-dose hydrocortisone treatment per the PREMILOC protocol or did not receive protocol steroids. Based on the beneficial effects of hydrocortisone on the infant's inflammatory response, we hypothesized that protocol-treated infants would have higher FA and lower MD in the major cerebral and cerebellar white matter tracts compared to non-protocol infants.

METHODS

Participants: Children <28 weeks gestation at birth who were born at the Lucile Packard Children's Hospital (LPCH) Stanford NICU between May 1, 2016 and April 30, 2021 were eligible for this retrospective study. Exclusion criteria included evidence of genetic disorders or congenital brain anomalies. 98 infants underwent dMRI imaging near hospital discharge. Per

LPCH NICU protocol, MRIs were obtained when infants were stable in an open crib, requiring no more than low flow supplemental oxygen for respiratory support, and >34 weeks PMA. Sedation was not used, and scanning was performed during natural sleep. Infants were fed and swaddled in warm blankets and wore adhesive foam noise attenuators to reduce the sound from the scanner. Of these, n=43 infants were excluded for several reasons: received steroids outside the protocol time frame (n=11), MRI scan completed more than one month post-due date (n=1), T1-weighted scan issues (n = 1), incomplete diffusion scans (n = 10), diffusion scan quality issues (e.g., challenges with image processing due to low gray-white matter contrast n = 20). The final sample was 55 participants, shown in **Figure 1**.

Infants were categorized by steroid exposure into two groups: Protocol (P) or Non-Protocol (NP). From July 1, 2017 – December 31, 2019 infants born at < 28 weeks gestation were typically begun on early postnatal hydrocortisone following the PREMILOC protocol described by Baud et. al.[6]: starting on day of life 1, 1 mg/kg of hydrocortisone hemisuccinate per day divided into two doses per day for 7 days, followed by one dose of 0.5 mg/kg per day for 3 days. Discontinuation of, continuation of, additional, or later steroid administration was at the discretion of the treating clinician. The P group (n=33) received greater than 50% of the hydrocortisone protocol; 24 infants received the full hydrocortisone protocol; 5 additional infants who were started on the protocol received 50% to 99% of the total protocol dose due to doses held for hypertension (n=2), hyperglycemia (n=2), or missed doses (n=1); 4 additional infants received 101% to 150% of the total protocol dose, receiving the PREMILOC protocol plus additional hydrocortisone during the first 10 days of life. The NP group (n=22) qualified for the study and received less than 50% of the total protocol steroid dose; 16 infants had no steroid exposure; 6 additional infants began the protocol but did not complete it due to hyperglycemia

(n=4), hypertension (n=1), or improving respiratory status (n=1). None of the participants received more potent steroids, such as dexamethasone. Clinical variables were obtained via chart review. This retrospective study was approved by the Stanford University Institutional Review Board #IRB-44480.

MRI Acquisition:

The neuroimaging data collected as part of the routine scanner sequence for each infant that were used in this study include high-resolution T1- weighted anatomical MRIs and diffusion MRI data. MRI scans were acquired using a GE Discovery MR750 3.0T scanner equipped with either an 8-channel HD head coil (n = 59) or a 32-channel HD head coil (n = 13) (General Electric Healthcare, Little Chalfont, UK). No significant difference in FA and MD values were seen between head coil types in this cohort.

The MRI protocol included a 60-direction diffusion MRI scans with b-values (1,500sec/mm^2) collected with a multi-slice echoplanar imaging (EPI) protocol for rapid image acquisition (~3 min each, 6 min total) with two - six volumes at b=0. Diffusion MRI data were collected at 2.0mm^3 spatial resolution (2.0mm x 2.0mm x 2.0mm isotropic voxels). High-resolution T1-weighted scans were collected at ~1mm^3 spatial resolution. T1-weighted images were used as participant-specific anatomical references throughout the processing of diffusion MRI data.

Diffusion MRI analyses:

MRI data were managed and analyzed using a neuroinformatics platform (Flywheel.io). Diffusion MRI data preprocessing and tractography were performed using procedures implemented in Reproducible Tract Profiles (RTP) (https://github.com/vistalab/RTP-pipeline).[16,17] RTP consists of three main steps: (i) Structural processing and Region of Interest

(ROI) creation (ii) diffusion MRI preprocessing (RTP-preproc) and (iii) whole-brain tractography and tract segmentation (RTP-Pipeline). Detailed information for processing steps were described in detail by Lerma-Usabiaga et al.[16] and Liu et al.[17] We modified RTP to perform segmentation of the T1w image using Infant Freesurfer[18] (https://surfer.nmr.mgh.harvard.edu/fswiki/infantFS) to accommodate for the immature neonate brain. We substituted a neonatal template (Edinburgh Neonatal Atlas, ENA33)[19] with ROIs for tract identification and segmentation.

We performed the following diffusion image preprocessing steps (RTP-preproc): (i) data denoising with principal component analysis[20,21] and Gibbs ringing correction,[22] (ii) eddy current and motion correction,[23] (iii) and anatomical alignment of diffusion data to the average of the non-diffusion-weighted volumes, which were registered to the infant's high-resolution ac-pc aligned anatomical image using rigid body transformation. Diffusion preprocessing, modeling and tractography within RTP is largely based on software from FSL (https://fsl.fmrib.ox.ac.uk/fsl/fslwiki), MRTrix3 (https://www.mrtrix.org/) and Automated Fiber Quantification[24] (AFQ, https://github.com/yeatmanlab/AFQ). A full list of software dependencies can be found here (https://github.com/vistalab/RTP-pipeline/wiki).

The preprocessed diffusion MRI data output from RTP-preproc served as the input for diffusion metrics modeling, whole-brain tractography and tract segmentation in RTP-pipeline. White matter metrics were calculated based on the diffusion tensor model. We then used the constrained spherical deconvolution model (CSD),[25] with eight spherical harmonics (lmax = 8) to calculate fiber orientation distributions (FOD) for each voxel. CSD tractography and FA masks were adjusted for the immaturity of the neonatal brain to have FA mask thresholds of 0.15 with FOD of 0.08. The CSD FODs were used for diffusion MRI tractography, which consisted of

(i) Ensemble Tractography[26] to estimate the whole-brain white matter connectome. MRtrix3 was used to generate three candidate connectomes that varied in their minimum angle parameters (50°, 30°, 10°).[27] For each candidate connectome, a probabilistic tracking algorithm (iFOD2) was used with a step size of 1 mm, a minimum length of 10 mm, a maximum length of 200 mm, and an FOD stopping criterion of 0.04. (ii) Spherical-deconvolution Informed Filtering of Tractograms (SIFT) to improve the quantitative nature of the ensemble connectome by filtering the data such that the streamline densities match the FOD lobe integral. The resulting ensemble connectome retained 500,000 streamlines. (iii) Concatenation of the three candidate connectomes into one ensemble connectome. (iv) AFQ[24] to segment and refine the resulting whole-brain connectome of each child into the tracts of interest: the left and right corticospinal tract (CST), left and right inferior longitudinal fasciculus (ILF), left and right superior cerebellar peduncle (SCP), and the anterior, middle, and posterior segments of the corpus callosum (Anterior Frontal, Motor, Occipital).[28,29] **Figure 2** shows the ROIs and resulting tracts on a T1 image from a 26 3/7 week infant imaged at 38 2/7 weeks PMA. Mean tract FA and MD were calculated for the core tract area between defining ROIs.

Statistical Approach

Statistical analyses were conducted using the Statistical Package for the Social Sciences (SPSS version 28.0.1.1, IBM Corp., 2018). Statistical significance was set at $p < 0.05$. Adherence to the normal distribution of clinical and neurobiological data was assessed using the Shapiro–Wilk test. Based on normality, we used parametric tests for all associations. Descriptive statistics were used to characterize the sample. Chi-square or Fisher's Exact tests and two-tailed t-tests for independent samples were used to examine differences between Protocol (P) and Non-protocol (NP) on demographic variables. We analyzed the mean tract metrics FA and MD,

averaging left and right tract metrics and planned to use a False Discovery Rate (FDR) of 5% for zero-order associations to account for multiple comparisons.[30] In order to rule out the possibility that children who received some steroids in the non-protocol group or who received more or less than the full protocol in the protocol group altered the results, the analyses were repeated using only infants who had no steroids and the full course of steroids. The pattern of results was the same, therefore the results report all children.

RESULTS

Participant characteristics are shown in **Table 1**. By design, the NP group had significantly lower steroid exposure than the P group ($p < 0.001$). The groups were well matched on participant characteristics, with no significant differences in gestational age, sex, parent-reported race or ethnicity, antenatal steroid exposure, moderate to severe bronchopulmonary dysplasia[2], necrotizing enterocolitis or spontaneous intestinal perforation, culture positive sepsis, retinopathy of prematurity (any stage), severe intraventricular hemorrhage (grade 3 or 4), length of stay, or ultrasound findings, or MRI characteristics (all $p > 0.05$).

The proportion of infants with successful tracking was similar between the NP (0.75 ± 0.22) and P (0.84 ± 0.18) groups ($t = -1.58$, $p = 0.12$). Mean FA and MD for the average of the left and right tracts and for the anterior, middle, and posterior segments of the corpus callosum are shown in **Table 2**. There were no significant differences between the two groups in any metric in any tract. No significant differences between the protocol and non-protocol groups were identified after adjusting for post-menstrual age at scan, and medical complications. We repeated the analyses in the subset of children who received zero steroids or only the complete

steroid protocol and found no significant differences in mean FA or MD of white matter tracts (data not shown).

DISCUSSION

In this retrospective study of 55 extremely preterm born infants who did or did not receive a low-dose early postnatal treatment protocol of prophylactic hydrocortisone for BPD prevention, we report the first assessment of cerebral and cerebellar white matter tract microstructure. Contrary to our initial hypothesis, we identified no significant differences in white matter microstructural metrics at near-term gestational age.

The lack of group differences is encouraging. While we cannot conclusively determine that hydrocortisone has no effect on white matter microstructure in the cerebrum or cerebellum, any differences in this cohort were at best minor. These results suggest that hydrocortisone, when administered at low dosage during the first 10 days of life, may have minimal impact on white matter maturation at near-term age or were overwhelmed by other factors. While not directly comparable, we can place our findings in the context of prior studies assessing volumetric brain changes after postnatal hydrocortisone. Unlike studies of dexamethasone administration, most of the studies assessing hydrocortisone also identify no significant differences in regional brain volumes.[12–14,31] There is one exception, by Tam et al,[15] who identified differences in the change in cerebellar volume from soon after preterm birth until near term age. The attenuation in cerebellar growth for infants administered hydrocortisone was less pronounced than that for dexamethasone administration compared to infants who received no steroids. Combined with our findings, it may be that hydrocortisone effects on early brain development are primarily in non-white matter structures.

White matter development is dynamic and rapid in the first two years of life.[32,33] Clinically relevant white matter differences might be found at a different stage in development. If glucocorticoids decrease neuroinflammation, oligodendrocyte precursor cells may be spared injury and progress through a normal maturational trajectory. Looking beyond infancy into childhood or even young adulthood could reveal differences in ultimate microstructural organization and integrity. On the other hand, steroids themselves can disrupt oligodendrocyte precursor maturation, with higher potency steroids having a more pronounced effect. It is possible that, as was theorized by the PREMILOC study team, low-dose hydrocortisone may not cause alterations to oligodendrocyte precursor cell development in the same way that more potent and high-dose glucocorticoids do.[7,9,34] This explanation is consistent with recent research looking at brain outcomes related to hydrocortisone treatment. Studies looking at macroscopic brain injuries (PVL, IVH, brain lesions) and brain volume have indicated that hydrocortisone was not associated with adverse effects on brain, in contrast to the reduced brain volume and increased brain abnormalities seen with dexamethasone.[6,7,12]

Several limitations constrain interpretation of our findings. Infants were not randomized to control or treatment groups, but rather received the treatment as a function of timing of birth. There could have been bias in children who were started, but did not receive the complete steroid protocol. Six infants in this category had hydrocortisone discontinued or held due to hyperglycemia and three due to hypertension, suggesting that these children may not have had adrenal insufficiency and may have been physiologically more mature than infants who completed the protocol. Neonatal hyperglycemia after preterm birth has been associated with decreased apparent diffusion coefficient in white matter.[35] While there were no

differences in several major neonatal medical conditions in the two groups, this study was not powered to exhaustively account for the many factors that contribute to white matter development. Of 86 eligible infants who received non-protocol or protocol steroids during the study period, 31 (36%) had imaging that was unsuitable for tractography. dMRI processing pipelines are generally developed for mature brains which we adapted to use on infant brain scans. Gray-white matter differentiation is especially underdeveloped in the preterm brain, and likely limited the success of the pipeline. Additionally, the scans used in this study were obtained during clinical care without sedation and primarily intended for radiologist reading. Technicians reasonably prioritized the primary MRI sequences and made choices to minimize infant time in the scanner which may have impacted image availability and quality in some cases. In the face of the constraints of neonatal brain development and clinical imaging, our success in applying advanced, quantitative analytic methods is an important step in moving these methods from the research realm into the clinical sphere. While no significant differences were found based on hydrocortisone protocol exposure, automated, objective measures of brain structure have potential applications to assessing the effects of other treatment and to outcome prediction in preterm infants.

CONCLUSION

In this cohort of infants born extremely preterm, a 10-day treatment with early, low-dose hydrocortisone did not relate to differences in early white matter microstructure as indexed by FA and MD. Hydrocortisone treatment may have minimal impact on white matter maturation of the corpus callosum and early neurodevelopmental outcomes. The findings from this research are encouraging for the safety of early, low-dose hydrocortisone as a clinical

intervention to potentially reduce the incidence and severity of bronchopulmonary dysplasia.

References

1. Jobe A. The new bronchopulmonary dysplasia. *Current Opinion in Pediatrics*. 2011;23(2):167-172. doi:10.1097/MOP.0b013e3283423e6b

2. Jobe AH, Bancalari E. Bronchopulmonary Dysplasia. *American Journal of Respiratory and Critical Care Medicine*. 2001;163(7):1723-1729. doi:10.1164/ajrccm.163.7.2011060

3. Volpe JJ. Brain injury in premature infants: a complex amalgam of destructive and developmental disturbances. *Lancet Neurol*. 2009;8(1):110-124. doi:10.1016/S1474-4422(08)70294-1

4. Feldman HM, Yeatman JD, Lee ES, Barde LH, Gaman-Bean S. Diffusion tensor imaging: a review for pediatric researchers and clinicians. *Journal of developmental and behavioral pediatrics: JDBP*. 2010;31(4):346-356. doi:10.1097/DBP.0b013e3181dcaa8b

5. Watterberg KL, Scott SM. Evidence of Early Adrenal Insufficiency in Babies Who Develop Bronchopulmonary Dysplasia. *Pediatrics*. 1995;95(1):120-125.

6. Baud O, Maury L, Lebail F, et al. Effect of early low-dose hydrocortisone on survival without bronchopulmonary dysplasia in extremely preterm infants (PREMILOC): a double-blind, placebo-controlled, multicentre, randomised trial. *Lancet*. 2016;387(10030):1827-1836. doi:10.1016/S0140-6736(16)00202-6

7. Alison M, Tilea B, Toumazi A, et al. Prophylactic hydrocortisone in extremely preterm infants and brain MRI abnormality. *Arch Dis Child Fetal Neonatal Ed*. 2020;105(5):520-525. doi:10.1136/archdischild-2019-317720

8. Chang YP. Evidence for adverse effect of perinatal glucocorticoid use on the developing brain. *Korean J Pediatr*. 2014;57(3):101-109. doi:10.3345/kjp.2014.57.3.101

9. Huang WL, Dunlop SA, Harper CG. Effect of Exogenous Corticosteroids on the Developing Central Nervous System: A Review. *Obstetrical & Gynecological Survey*. 1999;54(5):336-342.

10. Noguchi KK. Glucocorticoid Induced Cerebellar Toxicity in the Developing Neonate: Implications for Glucocorticoid Therapy during Bronchopulmonary Dysplasia. *Cells*. 2014;3(1):36-52. doi:10.3390/cells3010036

11. Baud O, Trousson C, Biran V, et al. Association Between Early Low-Dose Hydrocortisone Therapy in Extremely Preterm Neonates and Neurodevelopmental Outcomes at 2 Years of Age. *JAMA*. 2017;317(13):1329-1337. doi:10.1001/jama.2017.2692

12. Benders MJNL, Groenendaal F, van Bel F, et al. Brain development of the preterm neonate after neonatal hydrocortisone treatment for chronic lung disease. *Pediatr Res*. 2009;66(5):555-559. doi:10.1203/PDR.0b013e3181b3aec5

13. Kersbergen KJ, de Vries LS, van Kooij BJM, et al. Hydrocortisone treatment for bronchopulmonary dysplasia and brain volumes in preterm infants. *J Pediatr*. 2013;163(3):666-671.e1. doi:10.1016/j.jpeds.2013.04.001

14. Parikh N, Kennedy K, Lasky R, McDavid G, Tyson J. Pilot randomized trial of hydrocortisone in ventilator-dependent extremely preterm infants: effects on regional brain volumes. *Journal of pediatrics*. 2013;162(4):685□690.e1. doi:10.1016/j.jpeds.2012.09.054

15. Tam EWY, Chau V, Ferriero DM, et al. Preterm cerebellar growth impairment after postnatal exposure to glucocorticoids. *Sci Transl Med*. 2011;3(105):105ra105. doi:10.1126/scitranslmed.3002884

16. Lerma-Usabiaga G, Mukherjee P, Perry ML, Wandell BA. Data-science ready, multisite, human diffusion MRI white-matter-tract statistics. *Scientific Data*. 2020;7(1):422. doi:10.1038/s41597-020-00760-3

17. Liu M, Lerma-Usabiaga G, Clascá F, Paz-Alonso PM. Reproducible protocol to obtain and measure first-order relay human thalamic white-matter tracts. *Neuroimage*. 2022;262:119558. doi:10.1016/j.neuroimage.2022.119558

18. Zöllei L, Iglesias JE, Ou Y, Grant PE, Fischl B. Infant FreeSurfer: An automated segmentation and surface extraction pipeline for T1-weighted neuroimaging data of infants 0-2 years. *Neuroimage*. 2020;218:116946. doi:10.1016/j.neuroimage.2020.116946

19. Blesa M, Serag A, Wilkinson AG, et al. Parcellation of the Healthy Neonatal Brain into 107 Regions Using Atlas Propagation through Intermediate Time Points in Childhood. *Front Neurosci*. 2016;10:220. doi:10.3389/fnins.2016.00220

20. Veraart J, Fieremans E, Novikov DS. Diffusion MRI noise mapping using random matrix theory. *Magnetic Resonance in Medicine*. 2016;76(5):1582-1593. doi:10.1002/mrm.26059

21. Veraart J, Novikov DS, Christiaens D, Ades-Aron B, Sijbers J, Fieremans E. Denoising of diffusion MRI using random matrix theory. *Neuroimage*. 2016;142:394-406. doi:10.1016/j.neuroimage.2016.08.016

22. Kellner E, Dhital B, Kiselev VG, Reisert M. Gibbs-ringing artifact removal based on local subvoxel-shifts. *Magn Reson Med*. 2016;76(5):1574-1581. doi:10.1002/mrm.26054

23. Andersson JLR, Sotiropoulos SN. An integrated approach to correction for off-resonance effects and subject movement in diffusion MR imaging. *NeuroImage*. 2016;125:1063-1078. doi:10.1016/j.neuroimage.2015.10.019

24. Yeatman JD, Dougherty RF, Myall NJ, Wandell BA, Feldman HM. Tract profiles of white matter properties: automating fiber-tract quantification. *PloS one*. 2012;7(11):e49790. doi:10.1371/journal.pone.0049790

25. Tournier JD, Calamante F, Connelly A. Robust determination of the fibre orientation distribution in diffusion MRI: non-negativity constrained super-resolved spherical deconvolution. *Neuroimage*. 2007;35(4):1459-1472. doi:10.1016/j.neuroimage.2007.02.016

26. Takemura H, Caiafa CF, Wandell BA, Pestilli F. Ensemble Tractography. *PLOS Computational Biology*. 2016;12(2):e1004692. doi:10.1371/journal.pcbi.1004692

27. Tournier JD, Smith R, Raffelt D, et al. MRtrix3: A fast, flexible and open software framework for medical image processing and visualisation. *Neuroimage*. 2019;202:116137. doi:10.1016/j.neuroimage.2019.116137

28. Dougherty RF, Ben-Shachar M, Deutsch GK, Hernandez A, Fox GR, Wandell BA. Temporal-callosal pathway diffusivity predicts phonological skills in children. *Proceedings of the National Academy of Sciences of the United States of America*. 2007;104(20):8556-8561. doi:10.1073/pnas.0608961104

29. Huang H, Zhang J, Jiang H, et al. DTI tractography based parcellation of white matter: application to the mid-sagittal morphology of corpus callosum. *Neuroimage*. 2005;26(1):195-205. doi:10.1016/j.neuroimage.2005.01.019

30. Benjamini Y, Hochberg Y. Controlling the False Discovery Rate: A Practical and Powerful Approach to Multiple Testing. *Journal of the Royal Statistical Society Series B (Methodological)*. 1995;57(1):289-300.

31. Rousseau C, Guichard M, Saliba E, Morel B, Favrais G. Duration of mechanical ventilation is more critical for brain growth than postnatal hydrocortisone in extremely preterm infants. *Eur J Pediatr*. Published online 2021. doi:10.1007/s00431-021-04113-z

32. Bruckert L, Shpanskaya K, McKenna ES, et al. Age-Dependent White Matter Characteristics of the Cerebellar Peduncles from Infancy Through Adolescence. *Cerebellum*. 2019;18(3):372-387. doi:10.1007/s12311-018-1003-9

33. Yeatman JD, Wandell BA, Mezer AA. Lifespan maturation and degeneration of human brain white matter. *Nat Commun*. 2014;5:4932. doi:10.1038/ncomms5932

34. Barres BA, Lazar MA, Raff MC. A novel role for thyroid hormone, glucocorticoids and retinoic acid in timing oligodendrocyte development. *Development*. 1994;120(5):1097-1108. doi:10.1242/dev.120.5.1097

35. Naseh N, Moreira NC, Vaz TF, et al. Early Hyperglycemia in Very Preterm Infants Is Associated with Reduced White Matter Volume and Worse Cognitive and Motor Outcomes at 2.5 Years. *NEO*. Published online September 15, 2022:1-8. doi:10.1159/000524923

Table 1. Participant Characteristics for the two groups, Non-Protocol, defined as less than 50% of the protocol steroid dose, and Protocol, defined as at least 50% of the protocol dose.

	Non-Protocol N = 22 Mean(SD) or n (%)	Protocol N = 33 Mean(SD) or n (%)	t(df) or χ2(df)	Cohen's d	p
Steroid Exposure (mg/kg)	0.51 (1.04) min = 0 max = 4.00	8.42 (1.19) min = 5.00 max = 11.00	-25.3 (53)	-6.95	<0.001
Birthweight	864 (162)	875 (171)	-0.24 (53)	-0.07	0.40
Gestational Age, weeks	26.3 (1.1)	26.6 (0.8)	-1.30 (53)	-0.36	0.20
Female	9 (41)	16 (49)	0.31 (1)		0.58
Race[a]					0.34
Asian/Pacific Islander	2 (9)	3 (9)			
Black or African American	1 (4)	0 (0)			
Other	13 (59)	12 (36)			
Patient Refused/ Unknown	5 (23)	14 (42)			
White	1 (4)	4 (12)			
Ethnicity[b]					0.092
Hispanic/Latino	11 (50)	7 (21)			
Non-Hispanic/Non-Latino	5 (23)	13 (39)			
Patient Refused/Unknown	6 (26)	13 (39)			
Antenatal Steroids[c]	18 (82)	32 (97)			0.14
Length of Stay, days	92.1 (21.3)	84.9 (15.6)	1.91 (25.9)	0.61	0.067
Discharge Weight, grams	2960 (768)	2815 (637)	1.17 (53)	0.32	0.25
Discharge PMA[d], weeks	39.4 (2.6)	38.8 (2.1)	1.60 (53)	0.44	0.12
Medical Complications					
BPD[e] (Moderate/Severe)	6 (27)	4 (12)			0.18
Necrotizing Enterocolitis	6 (27)	7 (21)	0.27 (1)		0.60
Sepsis	2 (9)	5 (15)			0.69
Retinopathy of Prematurity	12 (54)	18 (54)	0.00 (1)		1.00
Severe IVH[f]	3 (14)	2(6)			0.38
Periventricular Leukomalacia	0 (0)	0 (0)			
Cerebellar Hemorrhage	0 (0)	0 (0)			
Seizures	1 (5)	0 (0)			0.40
MRI Characteristics					
PMA[c] at Scan, weeks	37.1 (1.4)	36.5 (0.8)	1.92 (30.7)	0.58	0.065
MRI Head Coil					0.074
8	19 (86)	21 (64)			
32	3 (14)	12 (36)			

[a]Parent Reported race, Fisher's Exact Test for Non-White versus White
[b]Parent Reported ethnicity, Fisher's Exact Test for Non-Hispanic/Non-Latino vs Hispanic/Latino
[c]Birthing parent received any antenatal steroids, yes/no.
[d]PMA, Post-Menstrual Age

[e]Bronchopulmonary dysplasia as described by Jobe and Bancalari.[2]
[f]Intraventricular Hemorrhage

Table 2. Mean White Matter Tract Microstructural Metrics

White Matter Tract Metric	Non-Protocol Steroid Mean (SD)	Protocol Steroid Mean (SD)	t(df)	Cohen's d
FA				
Corticospinal Tract	0.29 (0.04) (n=18)	0.29 (0.05) (n=30)	-0.10 (46)	-0.030
Inferior Longitudinal Fasciculus	0.19 (0.03) (n=21)	0.19 (0.02) (n=33)	0.47 (52)	0.132
Superior Cerebellar Peduncle	0.20 (0.06) (n=21)	0.18 (0.05) (n=33)	1.85 (52)	0.52
Corpus Callosum				
Occipital	0.29 (0.07) (n=14)	0.29 (0.07) (n=22)	-0.031 (34)	-0.011
Motor	0.21 (0.03) (n=14)	0.21 (0.04) (n=23)	-0.035 (35)	-0.012
Anterior Frontal	0.22 (0.05) (n=15)	0.23 (0.05) (n=29)	-0.68 (42)	-0.22
MD				
Corticospinal Tract	1.15 (0.07) (n=18)	1.16 (0.07) (n=30)	-0.78 (46)	-0.23
Inferior Longitudinal Fasciculus	1.43 (0.14) (n=21)	1.43 (0.09) (n=33)	0.078 (52)	0.022
Superior Cerebellar Peduncle	1.16 (0.17) (n=21)	1.16 (0.16) (n=33)	-0.013 (52)	-0.004
Corpus Callosum				
Occipital	1.40 (0.07) (n=14)	1.44 (0.13) (n=22)	-1.08 (34)	-0.37
Motor	1.43 (0.12) (n=15)	1.41 (0.10) (n=23)	0.37 (35)	0.13
Anterior Frontal	1.44 (0.10) (n=15)	1.46 (0.10) (n=29)	-0.65 (42)	-0.21

FA, Fractional Aniostropy; MD, Mean Diffusivity

Figure Captions

Figure 1. Consort diagram of eligible and included infants

Figure 2. White Matter Tractography. A) Left and right Corticospinal Tract, B) Left and right Inferior Longitudinal Fasciculus C) Anterior frontal and occipital corpus callosum segments D) Motor corpus callosum segment. E) Left and right Superior Cerebellar Peduncle. Dashed lines represent Region of Interest locations. Colors indicate fiber direction: blue=inferior-superior; green=anterior-posterior, red=left-right.

Figure 1.

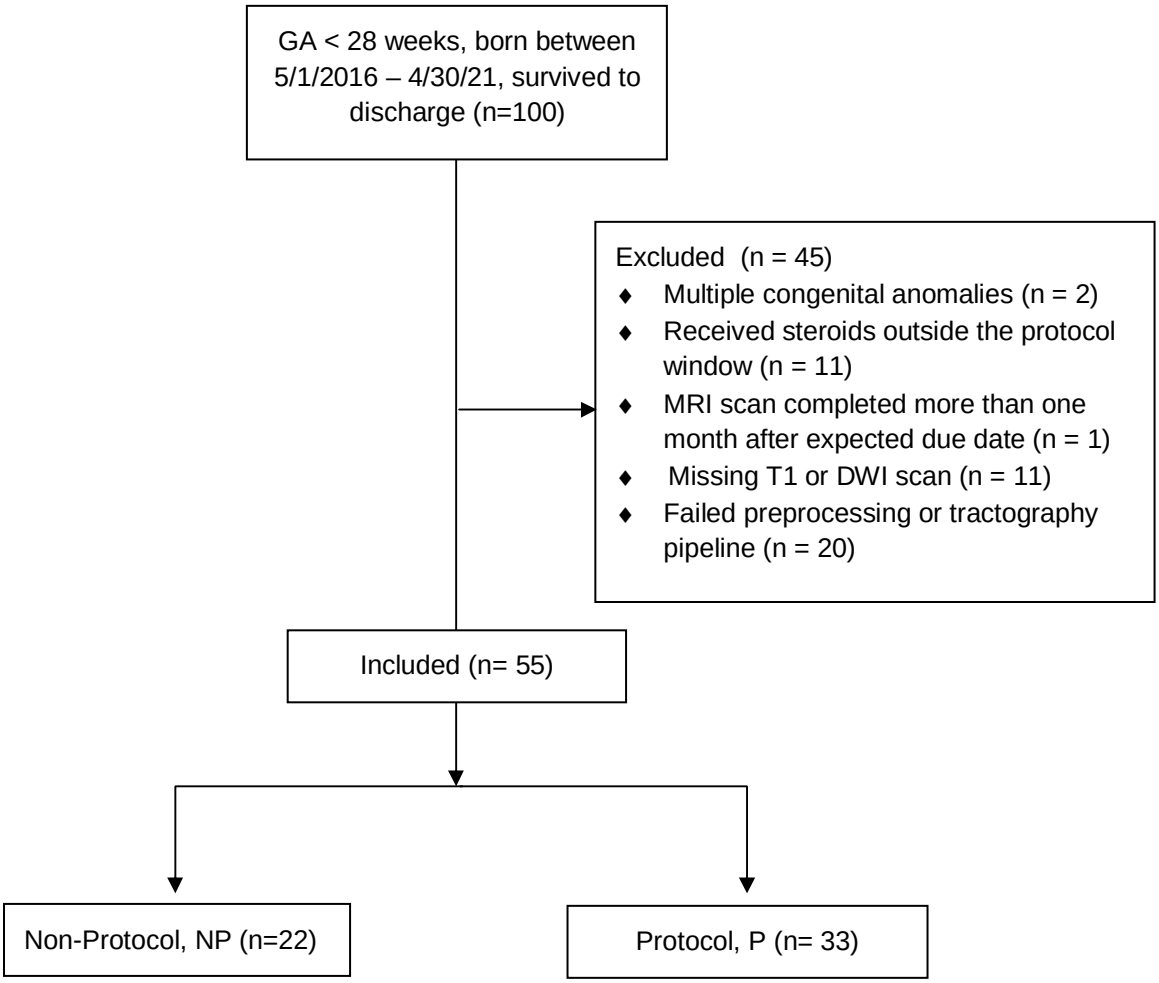
GA < 28 weeks, born between 5/1/2016 – 4/30/21, survived to discharge (n=100)
Excluded (n = 45)
Multiple congenital anomalies (n = 2)
Received steroids outside the protocol window (n = 11)
MRI scan completed more than one month after expected due date (n = 1)
Missing T1 or DWI scan (n = 11)
Failed preprocessing or tractography pipeline (n = 20)
Included (n= 55)
Non-Protocol, NP (n=22)
Protocol, P (n= 33)

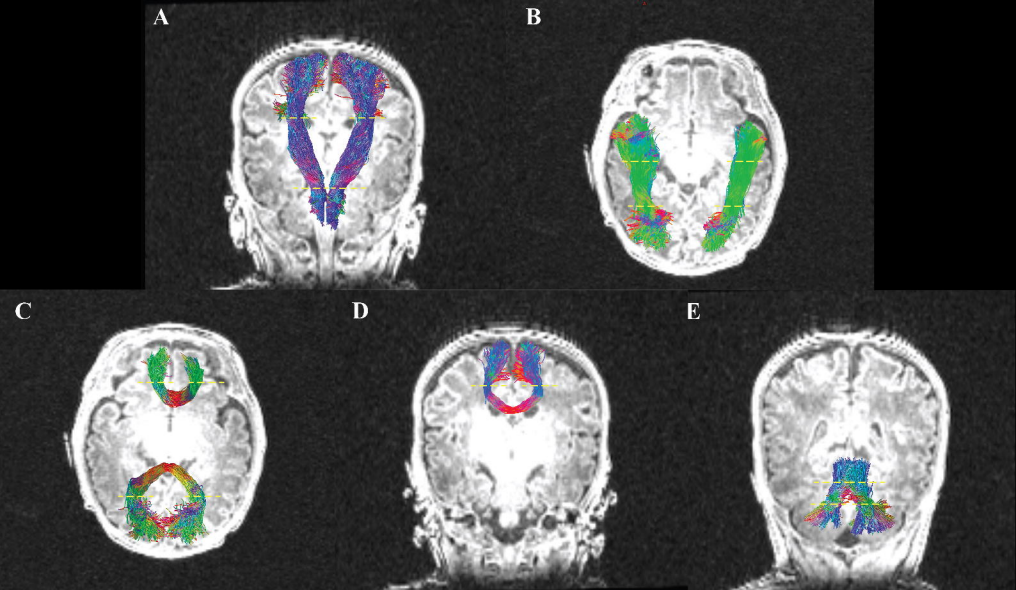
A
B
C
D
E