Image-localized Biopsy Mapping of Brain Tumor Heterogeneity: A Single-Center Study Protocol

Javier C. Urcuyo[1,2]*, Lee Curtin[1,2]*, Jazlynn M. Langworthy[1,2], Gustavo De Leon[1,2], Barrett Anderies[1,2], Kyle W. Singleton[1,2], Andrea Hawkins-Daarud[1,2], Pamela R. Jackson[1,2], Kamila M. Bond[1,2], Sara Ranjbar[1,2], Yvette Lassiter-Morris[1,2], Kamala R. Clark-Swanson[1,2], Lisa E. Paulson[1,2], Chris Sereduk[3], Maciej M. Mrugala[4,5], Alyx B. Porter[4,5], Leslie Baxter[6], Marcela Salomao[7], Kliment Donev[7], Miles Hudson[2], Jenna Meyer[2], Qazi Zeeshan[2], Mithun Sattur[2], Devi P. Patra[2], Breck A. Jones[2], Rudy J. Rahme[2], Matthew T. Neal[2], Naresh Patel[2], Pelagia Kouloumberis[2], Ali H. Turkmani[2], Mark Lyons[2], Chandan Krishna[2], Richard S. Zimmerman[2], Bernard R. Bendok[2], Nhan L. Tran[3], Leland S. Hu[8]**, Kristin R. Swanson[1,2]**

[1] Mathematical NeuroOncology Lab, Mayo Clinic, Phoenix AZ
[2] Neurosurgery, Mayo Clinic, Phoenix AZ
[3] Cancer Biology, Mayo Clinic, Phoenix AZ
[4] Neurology, Mayo Clinic, Phoenix AZ
[5] Oncology, Mayo Clinic, Phoenix AZ
[6] Neurophysiology, Mayo Clinic, Phoenix AZ
[7] Pathology, Mayo Clinic, Phoenix AZ
[8] Radiology, Mayo Clinic, Phoenix AZ
*contributed equally
**co-senior authors

ABSTRACT

Brain cancers pose a novel set of difficulties due to the limited accessibility of human brain tumor tissue. For this reason, clinical decision-making relies heavily on MR imaging interpretation, yet the mapping between MRI features and underlying biology remains ambiguous. Standard tissue sampling fails to capture the full heterogeneity of the disease. Biopsies are required to obtain a pathological diagnosis and are predominantly taken from the tumor core, which often has different traits to the surrounding invasive tumor that typically leads to recurrent disease. One approach to solving this issue is to characterize the spatial heterogeneity of molecular, genetic, and cellular features of glioma through the intraoperative collection of multiple image-localized biopsy samples paired with multi-parametric MRIs. We have adopted this approach and are currently actively enrolling patients for our 'Image-Based Mapping of Brain Tumors' study. Patients are eligible for this research study (IRB #16-002424) if they are 18 years or older and undergoing surgical intervention for a brain lesion. Once identified, candidate patients receive dynamic susceptibility contrast (DSC) perfusion MRI and diffusion tensor imaging (DTI), in addition to standard sequences (T1, T1Gd, T2, T2-FLAIR) at their presurgical scan. During surgery, sample locations are tracked using neuronavigation and genetic aberrations are later quantified through whole-exome and RNA sequencing. The collected specimens from this NCI-funded research study will be primarily used to generate regional maps of the spatial distribution of tumor cell density and/or treatment-related key genetic marker status across tumors, within clinically feasible time frames, to identify biopsy and/or treatment targets based on insight from the entire tumor makeup regional histologic and genetic makeup. This type of methodology, when delivered within clinically feasible time frames, has the potential to further inform medical decision-making by improving surgical intervention, radiation, and targeted drug therapy for patients with glioma. From October 1, 2017 to October 31, 2022, this study has enrolled 186 patients with 197 surgeries, of which 163 resulted in the successful collection of image-guided biopsy samples. A total of 995 biopsies have been collected of which 962 are image localized, with a mean of 5.90 image-localized samples per surgery.

INTRODUCTION

Capturing the biological heterogeneity within brain tumors is particularly challenging given the eloquent brain tissue in which these tumors live. Diffusely invasive gliomas are particularly challenging as there are always tumor cells left behind in the brain following any surgical intervention. Glioblastoma (GBM), the most aggressive form of glioma, is the most common primary brain malignancy among adults [1]. Despite aggressive medical intervention consisting of maximal surgical resection followed by concurrent chemoradiation and adjuvant temozolomide, this disease remains uniformly fatal, with a median survival rate of 14-16 months in patients with newly-diagnosed GBM [1–3] and 5-7 months in patients with recurrent GBM [1]. This poor prognosis is often a result of a major hallmark of GBM: profound intratumoral heterogeneity that contributes to treatment resistance and tumor recurrence.

Given the nexus of known intratumoral heterogeneity and the limitations of access to brain tumor tissue, there is an urgent need to leverage imaging to better inform our understanding of the biology at play across patients and within each patient's tumor. For example, the molecular composition of tumors is important, as different tumor cell subpopulations within and between patients can have different treatment sensitivities and implications for survival. For instance, IDH1/IDH2 and MGMT are prognostic markers of survival for gliomas [4,5]. Notably, mutation in IDH is thought to be uniform throughout a patient tumor [6,7], while MGMT status can vary with treatment status and location [8–10]. Other genetic alterations can arise, with multiple phenotypes present within the same tumor. For instance, the epidermal growth factor receptor (EGFR) gene can differ significantly in different regions of the tumor [11–14]. Similarly, EGFR-targeted therapies have mixed responses in patients [15,16]. Bulk transcriptional studies of GBM, derived from The Cancer Genome Atlas data, have revealed tumor subtypes that are associated with specific genetic alterations and patient survival [17,18]. These subtypes have been recapitulated on the level of individual cells, and profound genomic and phenotypic variability has been identified within individual patients [18–21]. These heterogeneities in key markers suggest that, although sufficient for diagnosis, clinical samples likely do not represent the full genetic and transcriptomic complexity of each tumor. It is important to have an accurate representation of the tumor throughout the clinical course of care, but opportunities for tissue collection are limited. This lack of tissue access has led to a heavy reliance on imaging to assess important clinical benchmarks such as surgical outcome, tumor size, and treatment response.

Image-localized biopsies have the potential to inform machine-learning models that connect image features to the heterogeneous tissue features of brain cancers. Previous work, such as predictions of tumor cell density [22–27] and EGFR amplification [12], have shown promise in this space. As we collect more image-localized biopsies, this dataset becomes more representative of the vast range of possible tumor compositions and imaging appearances, giving machine learning models the opportunity to become more robust. Such robust models have the potential to predict important tissue features of GBM through imaging alone on a patient-specific spatial basis, which would arm clinicians with the knowledge to provide more nuanced treatment and better stratify patients for clinical trials.

<u>Imaging-defined tumor regions drive clinical decisions</u> Currently, maximal safe surgical resection is the clinical gold standard. However, this is often determined with postoperative magnetic resonance imaging (MRI), particularly the T1-weighted MRI with gadolinium contrast (T1+C) [28,29]. Tissue sampling creates significant challenges for studying the clonal diversity of GBM. T1+C MRI represents the clinical standard for neuronavigation and routinely guides surgical biopsies and resection from the MRI enhancing core. Unfortunately, biopsies from the contrast-enhancing (CE) tumor regions fail to address the diverse molecularly-distinct subpopulations that extend beyond the enhancement into the surrounding non-enhancing (NE) parenchyma, which is visible on T2-weighted/Fluid-Attenuated Inversion Recovery (T2W/FLAIR) MRI [12]. These unresected NE tumor regions contribute to tumor recurrence and can have different cellular compositions and genetic signatures to that of enhancing regions [21,30,31]. Furthermore, T1+C MRI fails to localize cancer in the surrounding NE tumor region during radiation treatment (RT) planning, as non-tumoral edema typically appears visually indistinguishable from NE tumor. Most radiation oncologists must apply submaximal doses across the entire T2W/FLAIR volume, which delivers unnecessary radiation to the normal brain and risks undertreating NE tumor.

<u>Advanced multiparametric imaging provides deeper insights into tumor biology</u> Imaging techniques, such as advanced MRI, can quantitatively characterize tumor-induced physiological processes in the NE region of GBM. Unlike surgical sampling, MRI captures the entire tumor volume, including unresected NE regions and provides

a variety of complementary biophysical features (Figure 1). On T1+C MRI, enhancement indicates regions of disrupted blood brain barrier (BBB), while signal demarcates regions of high water content and tumoral edema in T2W/FLAIR. Advanced MRI features include tumor cell density on diffusion-weighted imaging (DWI) [32], white matter infiltration on diffusion tensor imaging (DTI) [33,34], and microvessel morphology on Dynamic Susceptibility-weighted contrast-enhanced perfusion MRI (DSC-pMRI) [35]. In addition, signal intensity values on structural MRIs are spatial representations of soft tissue anatomy. The textural patterns of neighboring voxel intensities provide further insight towards the potential tissue microstructure and phenotypic heterogeneity within the local microenvironment [36,37]. These complementary MRI features offer potential biomarkers of underlying genomic and transcriptomic status, and have been previously correlated with molecular profiles of GBM [12,38–45]. Further, quantification of the interactions amongst molecularly-distinct subpopulations, cellular subpopulation compositions and/or their diversity in the NE tumor region (often left behind following surgical interventions) can help improve future treatment strategies (such as adaptive therapy), under the realm of individualized oncology [46–48].

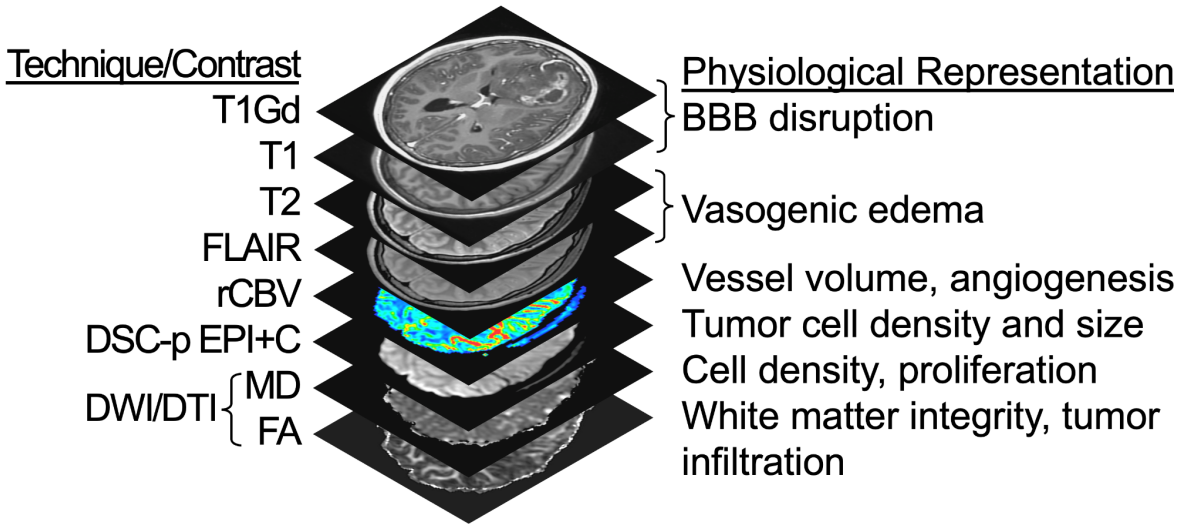

Figure 1: Multiparametric MRI techniques and contrasts*. Listed are the 8 different MRI sequences used in this study, along with their corresponding physiological representations. T1Gd = T1W signal increase on post-contrast imaging; FLAIR = Fluid-Attenuated Inversion Recovery; rCBV = Relative cerebral blood volume; DSC-pMRI = Dynamic susceptibility contrast perfusion MRI; EPI+C = T2*W signal loss (i.e., negative enhancement at ~5min post injection of 0.1 mmol/kg preload contrast injection); DWI = Diffusion weighted imaging; DTI = Diffusion tensor imaging; MD = Mean diffusivity (equivalent to apparent diffusion coefficient); FA = Fractional anisotropy.*

MATERIALS AND METHODS

The 'Image-Based Mapping of Brain Tumors' clinical protocol (IRB# 16-002424) is a minimal-risk study that aims to further characterize intratumoral heterogeneity of brain tumors. The study outlines our efforts towards collecting multiple image-guided biopsy samples as part of standard surgical approaches including samples dispersed in and around the abnormality seen on T1Gd MRI to allow for cross-annotation for relevant MRI features. We present an example set of biopsy locations for a single surgery in Figure 2. The data gathered through this study will be useful for countless research directions. The study's primary objectives are to identify relationships between imaging and a number of important tumor features, such as tumor cell density, genetic status, transcriptomic status, and molecular status. Secondary objectives include investigating associations amongst imaging, radiation dosimetry, tumor recurrence/treatment effect, and clinical outcome. Patient recruitment was initiated in October 2017 and enrollment is ongoing.

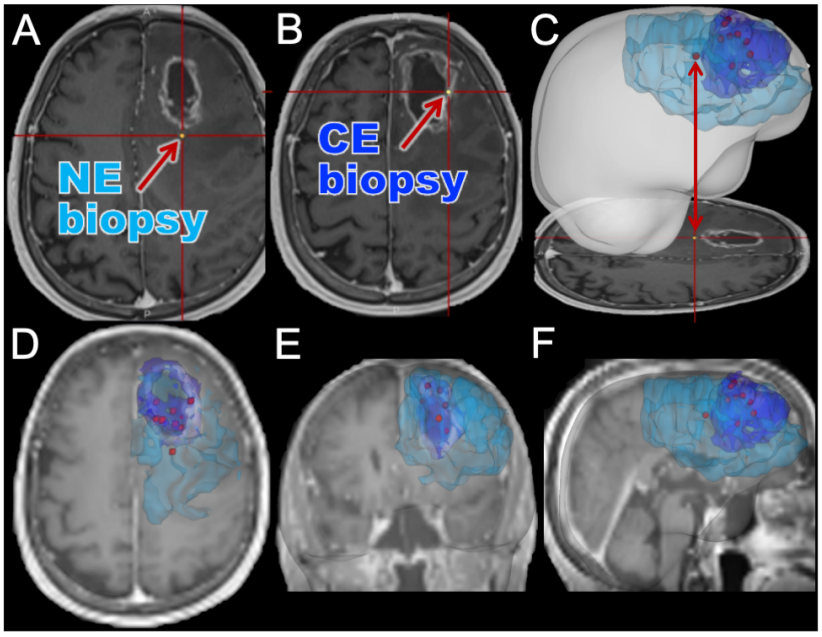

Figure 2: Illustrative example of biopsy locations annotated relative to imaging abnormalities. Here we show an example case where 9 image-localized biopsies were acquired from a patient. (A) An example screenshot from the intraoperative neuronavigation system of a non-enhancing (NE) biopsy sample. (B) An example screenshot from the intraoperative neuronavigation system of a contrast-enhancing (CE) biopsy sample. (C) A screenshot from intraoperative navigation is shown, highlighting the translation to a full three-dimensional rendering of segmented imaging abnormalities and biopsy locations. The segmented CE (dark blue) and NE (light blue) abnormalities are shown with biopsy locations (red). (D-F) MRI planes overlaid with segmentations and biopsy locations, highlighting the representative spread of biopsy locations that we can achieve. Although only the CE and NE regions are outlined here, we collect other multiparametric MRIs as well for the patients as shown in Figure 1.

INCLUSION AND EXCLUSION CRITERIA

Inclusion criteria for patient participation in the study are as follows:

- Age between 18 and 99 (inclusive)
- Undergoing diagnostic biopsy and/or surgical resection for a brain lesion

Exclusion criteria for patient participation in the study are as follows:

- Insufficient renal function: eGFR < 60 mg/min/1.72m^2 [49]
- Allergy to Gadolinium (Gd)
- Pregnant or nursing
- History of hemolytic anemia or asthma
- Inability to obtain informed written consent

PATIENT DEMOGRAPHICS AND SAMPLE COUNTS

This study has enrolled 186 patients with 163 surgeries that resulted in the successful collection of image-guided biopsy samples. A total of 995 biopsies have been collected of which 962 are image localized, with a mean of 5.90 samples per surgery. The mean age of these patients was 57.6 years old (ranging from 18-91). The self-reported sex breakdown is 109 males and 77 females with mean ages of 58.5 years (21-84) and 56.2 years (18-91), respectively. The self-reported racial and ethnic distribution of the cohort is largely white and non-Hispanic/Latino individuals (Figure 3, analogous sex-specific figures in Supplement 1). The samples collected in this study were largely acquired from patients with glioma and brain metastasis, although 9 patients had another type of brain lesion. We collected image-localized biopsies from 120 glioma surgeries, of which: 4 were grade I, 16 were grade II, 13 were grade III and 87 were grade IV. We collected image-localized biopsies from 34

surgeries for patients with cancers that had metastasized to the brain. See Figure 4 for further breakdowns such as tumor status and biopsy counts (analogous sex-specific figures can be found in Supplements 2 and 3).

Figure 3: Self-reported race (top) and ethnicity (bottom) in the patient cohort, which consists predominantly of patients reporting as white and not Hispanic/Latino. See Supplement 1 for sex-specific breakdowns.

Figure 4: Flowchart for enrollment, starting from the number of patients (N) who were approached for the study, to surgeries (S) and total number of biopsies collected (bx), stratified by grade and tumor status. The sum of S is 198 rather than 197, as one surgery led to both prospective and retrospective tissue. See Supplements 2 and 3 for sex-specific breakdowns. *One case included in the recurrent grade III group underwent a grade transformation.

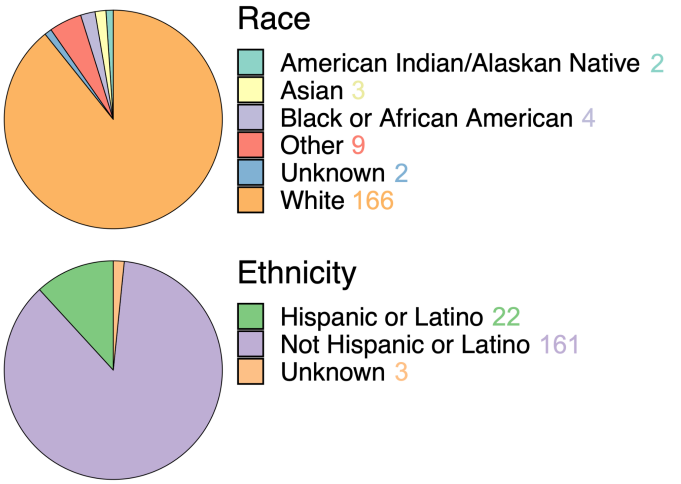

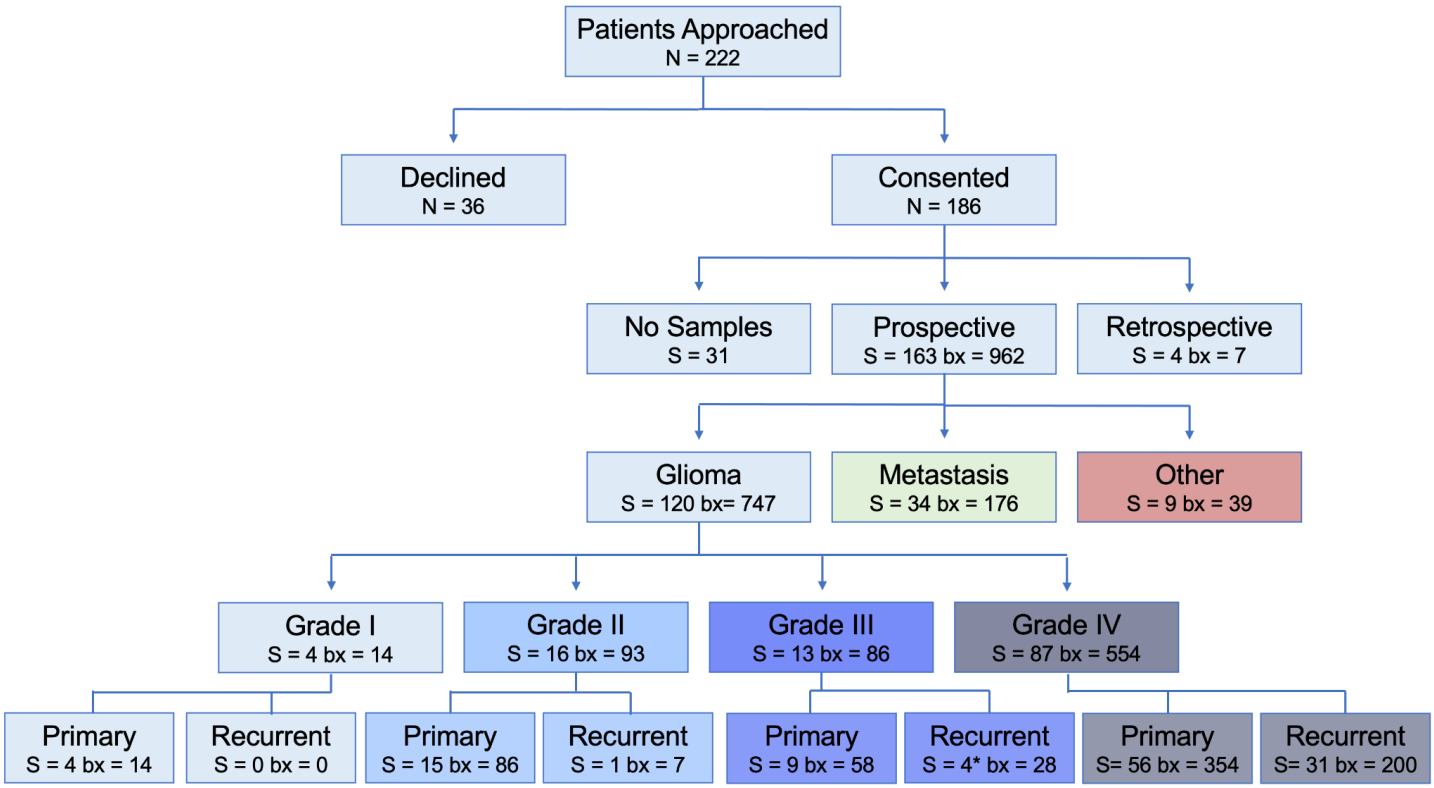

WORKFLOW

BEFORE SURGERY

Patients are identified through the institutional electronic medical records system (i.e., Epic Systems). Clinical schedules for MR scanners and operating rooms are checked daily for eligible participants. A study-specific multi-parametric imaging protocol is acquired prior to surgery for eligible patients. The imaging protocol includes T1-weighted (T1W), T1-weighted with gadolinium contrast (T1Gd), T2-weighted (T2W), T2W-fluid-attenuated inversion recovery (T2-FLAIR), diffusion tensor imaging (DTI), and dynamic susceptibility contrast (DSC) perfusion MRI (Figure 1). These imaging sequences are acquired prior to the collection of image-guided biopsy

samples and, in some instances, following the patient's diagnosis or treatment. In addition to MRI, other imaging modalities may be collected and reviewed, these include computed tomography (CT) and positron emission tomography (PET) imaging data collected as part of clinical practice or in conjunction with other imaging-based protocols.

Blood Collection

Blood is collected in up to two 10mL ethylenediamine tetraacetic acid (EDTA) tubes and the buffy coat is frozen. This blood collection is used for germline DNA comparisons to the respective tumors and occurs during a standard of care visit. If the patient has multiple standard-of-care lab visits, we may collect at any of those as long as the subject has not withdrawn informed consent.

Urine Collection

Urine is collected and stored at 4ºC to assess biomarkers (free circulating DNA/RNA) associated with therapy response. This may also be collected at any standard of care lab visits, as long as the subject has not withdrawn informed consent. Table 1 shows the timeline for the collection of all sections of this protocol.

Image-Localized Glioma Biopsy Protocol	Screening and Baseline	Day of Surgery	Post-Surgery follow-up	Routine Follow-up Visit
Schedule of Events	Up to 30 days before surgery	Day 0	Days 1-5	Days 30-45
Review Inclusion/Exclusion	X			
Obtained Informed Consent	X			
Imaging Protocol				
T1 with and without contrast	X		X	X
T2/FLAIR	X		X	X
DTI	X		X[1]	X[1]
Perfusion	X		X[1]	X[1]
Tissue Collection		X		
Blood Collection	X		X	X
Urine Collection	X		X	X
Clinical Data Collection	X	X	X	X
Screenshot Collection		X	X[2]	

X[1] - At the discretion of the principal investigators

X[2] - If screenshots are not collected on the day of surgery

Table 1: General schedule of events for this research study from patient identification to routine follow-up. Patient information beyond routine follow-up can also be collected. No additional modifications are made to the standard clinical care trajectory, unless the patient has another surgery.

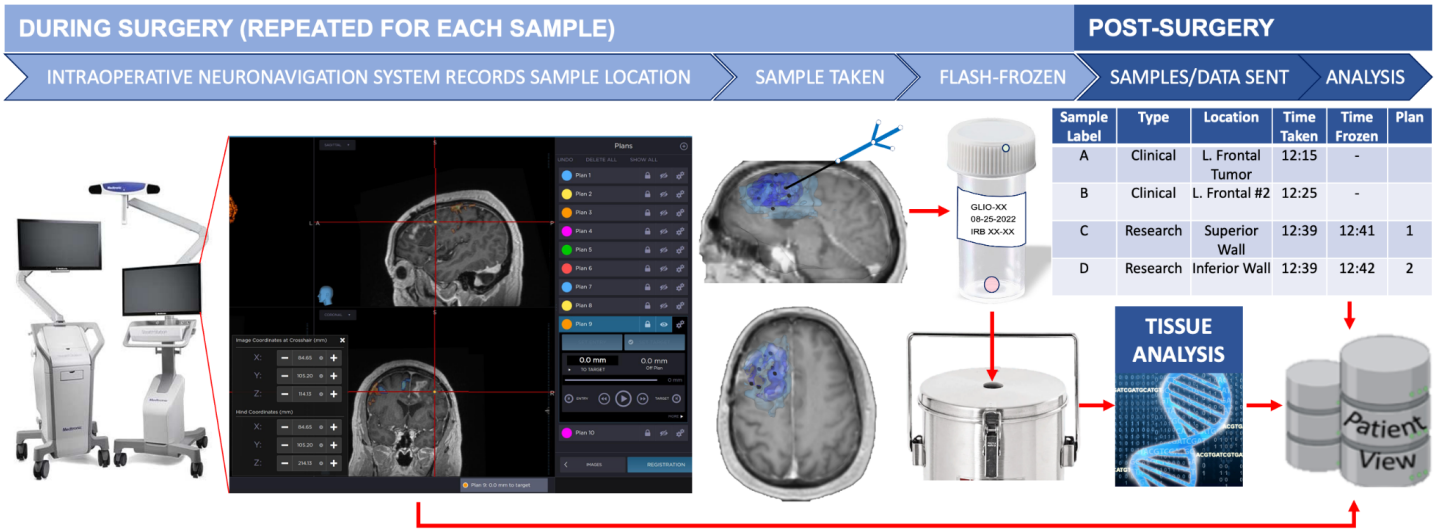

Figure 5: A schematic of our per-patient biopsy collection workflow. Additionally, patients may have samples collected at subsequent surgeries [50–53].

DURING SURGERY

During routine surgery, biopsies are obtained and the MRI location is recorded using an intraoperative neuronavigation system (Medtronic StealthStation 8, Minneapolis, MN) with additional screenshots taken (such as that in Figure 5) to further validate the coordinate location. At the beginning of this study, biopsies were frozen by the Surgical Pathology department. However, to reduce time to freezing of the tissue, flash-freezing was implemented in the operating room (OR) with Surgical Pathology as a backup, if necessary. This has significantly improved our success in achieving freezing tissue within 5 minutes of surgical extraction (Supplementary Figure 4).

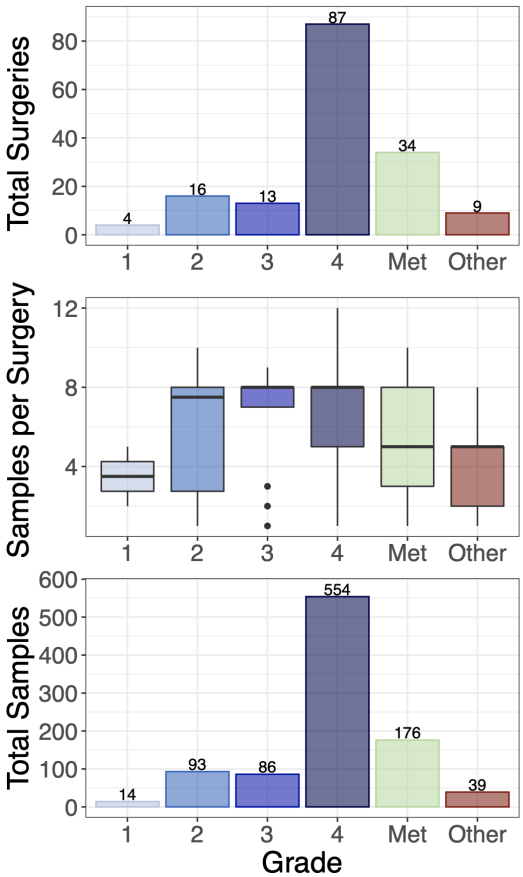

We collect multiple spatially-annotated stereotactic biopsies from the across the diversity of MRI-definable tumor regions in patients with glioma and metastatic brain tumors with a goal of 8 biopsies per surgery with a target of ≥250 mg/biopsy (see Figure 6). Tumor grade is assessed by a pathologist using corresponding clinical biopsy samples in line with standard conventions [54,55].

***Figure 6**: Overview of Image-Localized Biopsy Histology Distribution* **(Top)** Total number of surgeries with image-localized biopsies collected, broken down by grade (total of 163 surgeries). **(Middle)** Number of samples per surgery, broken down by grade. **(Bottom)** Total samples collected per grade (total of 962 samples).

Sample Collection

Screenshots taken for each research sample are extracted from the neuronavigation system and imported into our IRB-compliant database PatientView (Figure 5). Samples are time-stamped and designated an alphabetical letter to facilitate matching each sample to its corresponding screenshot and clinical notes in the electronic medical record. Samples collected are also cross-referenced with the Surgical Pathology department to confirm the number of biopsies collected, label accuracy, and overall quality assurance.

AFTER SURGERY

Imaging data is collected, coded, processed, and matched with the genetic and molecular data obtained from each biopsy. Post-processing analyses include registration, normalization, inhomogeneity correction, and feature extraction as described elsewhere [12,22,23]. Planned studies include the development of statistical models between imaging, various tissue characterizations (e.g. copy number variants, transcriptomic signatures, immunohistochemistry etc.), and clinical outcomes.

Tissue Handling

Each sample is delivered to the Surgical Pathology department after being flash-frozen in liquid nitrogen. The samples are stored in a -80ºC freezer until subsequent processing. Flash-frozen tissue is retrieved and embedded frozen in optimal cutting temperature (OCT) compound. Tissue is sectioned (e.g. target 10µm with the goal of up to 20 slides) in -20ºC cryostat (e.g., Microm-HM-550) utilizing a microtome blade. In the event of excess archived formalin-fixed paraffin-embedded (FFPE) tissue collected per the standard clinical protocol, retrospective tissue may be obtained (under the discretion of a neuropathologist) to undergo further tissue analysis (we aim to collect up to 100µm in FFPE scrolls). All specimens are also stained with hematoxylin and eosin (H&E) and reviewed by a neuropathologist to quantify tumor content. Tissue specimens may be submitted for subsequent genetic, molecular, or epigenetic analysis, including, but not exclusive to, next-generation sequencing, array-based comparative genomic hybridization (aCGH), exome sequencing, methylation analysis, and RNA sequencing.

Data abstraction, management, and availability

Details of the patient's clinical course, treatments, MRI images, pathologies, and treatment response are abstracted from the medical records system by IRB-approved staff and an anonymized data repository is distributed to the rest of the team for data analysis. Data is made accessible to all IRB-approved staff, but only the principal investigators, study coordinators, and research assistants have full rights to update data in our main data repository as they are responsible for ensuring the data quality and accuracy.

Biopsy-related data, including time of collection, specimen ID, neuronavigation information, and other notes are collected by two to three researchers during surgery in physical journals. These journals contain coded patient IDs with no patient health information. This data is transferred to a password-protected document with all relevant data for each patient, which is stored on a secure server that can only be accessed by IRB-approved researchers. Biopsy location data and image information is taken directly from the neuronavigation system using plans and time-stamped screenshots as previously described. The image data and screenshots are kept in deidentified patient folders on the secure server. Patient identifiers, demographic information, and sample data are collated in the main data repository.

Research data that documents, supports, and validates research findings will be made available after the main findings from the final research data set have been accepted for publication. In addition, if requested, data may be made available for sharing to qualified parties by the technology transfer office as soon as is reasonably possible, so long as such a request does not compromise intellectual property interests, interfere with publication, invade subject privacy, or betray confidentiality. Data that are shared will include standards and notations needed to interpret the data, following commonly accepted practices. Data requests may be initiated by contacting the lab through our website: www.mathematicalneurooncology.org.

Ethical considerations and declarations

The principal investigators are responsible for ensuring the IRB-approved study protocol is followed and for reporting any adverse events. The study protocol must be reviewed for renewal annually.

Safety considerations

Our study is not therapeutically interventional. This is a minimal-risk study as procedures are in line with standard clinical activities with only the possible addition of advanced imaging. The safety of the patient is our top priority and is monitored by the neurosurgeon as surgery is performed.

DISCUSSION

As with any clinical study, there are many potential limitations that must be considered. This study aims to retrieve multiple biopsies from a variety of locations spanning the diversity of MRI-defined tumor regions. While we have a goal of 8 samples per surgery, in some cases this sampling scheme is not possible. The operating neurosurgeon is responsible for evaluating the safety of biopsy collection and assessing any potential risk that may result from such collection. As a result, there is notable variability in the number and size of the collected specimens; however, this has helped define our study as a reasonable and pragmatic collection protocol.

Image-localization poses additional challenges. First, the neuronavigation system requires preoperative patient registration, resulting in a measurable registration error during surgery. Second, this process is reliant on preoperative imaging, which must be ordered by clinicians and, in some scenarios, is obtained up to three weeks prior to surgery. Further, such static images cannot account for intraoperative brain shift, a phenomenon where the brain fills the space of resected tissue. Unfortunately, this issue remains a universal challenge for image-localization during neurological surgery, and there is currently no standard procedure in place to accurately measure this change intraoperatively.

Another limitation is in the uniformity of available imaging and the related difficulty of consenting patients promptly. Patients are identified through our institution's patient scheduling systems (currently in EPIC, the electronic medical records system utilized at Mayo Clinic). Specifically, MRI and OR schedules are monitored for potential patients for the study. However, emergent patients who undergo imaging at short notice and immediately proceed with surgery may be missed or, if consented, may not have received the entire protocol of imaging before surgery. Since biopsy collections require research personnel, surgeries may also be missed if researchers' schedules do not permit attendance. Further, surgeries are not attended if there is increased risk to the patient (e.g. patient safety concerns from the neurosurgeon) or the research team (i.e., active COVID-19 diagnosis).

Although this data collection comes with challenges, many of these are typical during the integration of research into a clinical workflow. Neuronavigation has proven to be a useful clinical tool for surgical planning and intraoperative guidance. By utilizing neuronavigation for research, we can attain much greater insight into the inter- and intra-patient spatial heterogeneity of brain tumors and its imaging presentation.

Authors' Contributions

- Gustavo De Leon: manuscript conception
- Gustavo De Leon, Javier C. Urcuyo, Lee Curtin: manuscript preparation
- Javier C. Urcuyo, Lee Curtin, Gustavo De Leon, Jazlynn M. Langworthy: figure preparation, writing of manuscript and data management
- Barrett Anderies, Javier C. Urcuyo, Lee Curtin, Gustavo De Leon, Jazlynn M. Langworthy: Collection of tissue and biopsy coordinates
- Kyle W. Singleton, Andrea Hawkins-Daarud, Pamela R. Jackson, Sara Ranjbar: image processing
- Chris Sereduk, Nhan L. Tran, Marcela Salomao, Kliment Donev: biopsy tissue processing and storage
- Andrea Hawkins-Daarud, Kamila M. Bond: post-processing biopsy data
- Maciej M. Mrugała, Alyx B. Porter, Leslie C. Baxter: patient identification and follow-up
- Miles Hudson, Jenna Meyer, Qazi Zeeshan, Mithun Sattur, Devi P. Patra, Breck A. Jones, Rudy J. Rahme, Matthew T. Neal, Naresh Patel, Pelagia Kouloumberis, Ali H. Turkmani, Mark Lyons, Chandan Krishna, Richard S. Zimmerman, Bernard R. Bendok: Patient identification and biopsy collection
- Barrett Anderies, Andrea Hawkins-Daarud, Pamela R. Jackson, Kristin R. Swanson: protocol development, establishment and management
- Leland S. Hu: manuscript review, conception of image-localized biopsy protocol, development of imaging protocol, oversight of biopsies alignment, contributed to funding of biopsy team, oversight of image analysis, clinical PI of biopsy protocol
- Kristin R. Swanson: writing and review of manuscript, establishment of and management of overall biopsy team, contributed to funding and supervision of biopsy team, oversight of all protocol-related analyses, scientific PI of biopsy protocol

Acknowledgements: The authors gratefully acknowledge the funding that made this research possible from the NIH (R01NS060752, R01CA164371, U54CA143970, U54CA193489, U01CA220378, U54CA210180, U01CA250481), the James S. McDonnell Foundation, and the Ben and Catherine Ivy Foundation.

One might say "it takes a village" to achieve a successful protocol of this scope. This manuscript focuses on the establishment of our protocol, current/recent workflows, processes, and staffing that we have implemented. As such, the authors are truly grateful to the many additional contributions by other prior and current members of the biopsy collection team, including but not limited to:
Sample Collection: Ariana Afshari, Spencer Bayless, Ryan Hess, Julia Lorence, Reyna Patel, Lucas Paulson
Clinical Research Coordinators: Jessica Bauer, Regina Becker, Lysette Elsner, Crystal Harris, Morgan Hatlestead, Ashley Napier
Surgical Technologists: Darby Black, Heather Boles, Heather Hull, Angela Melloni, Jose Rocha, Briana Rodriguez
Clinical Nursing Staff: Nora J. Shaefer, Kaylee Curley, Hans Leitner DeCarlo, Deanna Dusek, Regina Formentin, Braden Hall, Nathan Nitzky, Melanie Parativo, Kenneth Rooth, Krystle Short, Matt Zumwalt Hulverson
Stealth Techs: Cara Burkholder, Albana Spahiu
Interventional Radiology Technologists: Jason Billings, Joel Dela Cruz, Emily Lange, Brandy Streeter, Patrick Vance
Surgical Pathology Staff: Bradley Atkins, Debra Keith, Phillip Hogan Jr, Rachel Matey, Lori Miller, Ashley Polzin, Jessica Williams
Clinical data abstraction: Sandra K. Johnston
Clinical research database integration/administration: Scott Whitmire
Other project management and design: Susan C. Massey
Image analysis: Cassandra R. Rickertsen and past and current members of the Image Analysis Team.

Potential Competing Interests: KRS and LSH are co-founders of Precision Oncology Insights Inc; Imaging Biometrics (medical advisory board: LSH); the remaining authors have no relevant conflicts of interest to disclose.

1. Ostrom QT, Cioffi G, Gittleman H, Patil N, Waite K, Kruchko C, et al. CBTRUS Statistical Report: Primary Brain and Other Central Nervous System Tumors Diagnosed in the United States in 2012-2016. Neuro Oncol. 2019;21: v1–v100.

2. Stupp R, Mason WP, van den Bent MJ, Weller M, Fisher B, Taphoorn MJB, et al. Radiotherapy plus concomitant and adjuvant temozolomide for glioblastoma. N Engl J Med. 2005;352: 987–996.

3. Stupp R, Taillibert S, Kanner A, Read W, Steinberg D, Lhermitte B, et al. Effect of Tumor-Treating Fields Plus Maintenance Temozolomide vs Maintenance Temozolomide Alone on Survival in Patients With Glioblastoma: A Randomized Clinical Trial. JAMA. 2017;318: 2306–2316.

4. Molenaar RJ, Verbaan D, Lamba S, Zanon C, Jeuken JWM, Boots-Sprenger SHE, et al. The combination of IDH1 mutations and MGMT methylation status predicts survival in glioblastoma better than either IDH1 or MGMT alone. Neuro Oncol. 2014;16: 1263–1273.

5. Kalkan R, Atli Eİ, Özdemir M, Çiftçi E, Aydin HE, Artan S, et al. IDH1 mutations is prognostic marker for primary glioblastoma multiforme but MGMT hypermethylation is not prognostic for primary glioblastoma multiforme. Gene. 2015;554: 81–86.

6. Juratli TA, Kirsch M, Robel K, Soucek S, Geiger K, von Kummer R, et al. IDH mutations as an early and consistent marker in low-grade astrocytomas WHO grade II and their consecutive secondary high-grade gliomas. J Neurooncol. 2012;108: 403–410.

7. Duncan CG, Barwick BG, Jin G, Rago C, Kapoor-Vazirani P, Powell DR, et al. A heterozygous IDH1R132H/WT mutation induces genome-wide alterations in DNA methylation. Genome Res. 2012;22: 2339–2355.

8. Parkinson JF, Wheeler HR, Clarkson A, McKenzie CA, Biggs MT, Little NS, et al. Variation of O6-methylguanine-DNA methyltransferase (MGMT) promoter methylation in serial samples in glioblastoma. J Neurooncol. 2007;87: 71–78.

9. Dunn J, Baborie A, Alam F, Joyce K, Moxham M, Sibson R, et al. Extent of MGMT promoter methylation correlates with outcome in glioblastomas given temozolomide and radiotherapy. Br J Cancer. 2009;101: 124–131.

10. Brandes AA, Franceschi E, Paccapelo A, Tallini G, De Biase D, Ghimenton C, et al. Role of Methylation Status at Time of Diagnosis and Recurrence for Patients with Glioblastoma: Clinical Implications. Oncologist. 2017;22: 432–437.

11. Szerlip NJ, Pedraza A, Chakravarty D, Azim M, McGuire J, Fang Y, et al. Intratumoral heterogeneity of receptor tyrosine kinases EGFR and PDGFRA amplification in glioblastoma defines subpopulations with distinct growth factor response. Proc Natl Acad Sci U S A. 2012;109: 3041–3046.

12. Hu LS, Ning S, Eschbacher JM, Baxter LC, Gaw N, Ranjbar S, et al. Radiogenomics to characterize regional genetic heterogeneity in glioblastoma. Neuro Oncol. 2017;19: 128–137.

13. Hu LS, Hawkins-Daarud A, Wang L, Li J, Swanson KR. Imaging of intratumoral heterogeneity in high-grade glioma. Cancer Lett. 2020. doi:10.1016/j.canlet.2020.02.025

14. Hu LS, Wang L, Hawkins-Daarud A, Eschbacher JM, Singleton KW, Jackson PR, et al. Uncertainty quantification in the radiogenomics modeling of EGFR amplification in glioblastoma. Sci Rep. 2021;11: 3932.

15. Hegi ME, Rajakannu P, Weller M. Epidermal growth factor receptor: a re-emerging target in glioblastoma. Curr Opin Neurol. 2012;25: 774–779.

16. Eskilsson E, Røsland GV, Solecki G, Wang Q, Harter PN, Graziani G, et al. EGFR heterogeneity and implications for therapeutic intervention in glioblastoma. Neuro Oncol. 2018;20: 743–752.

17. Verhaak RGW, Hoadley KA, Purdom E, Wang V, Qi Y, Wilkerson MD, et al. Integrated genomic analysis identifies clinically relevant subtypes of glioblastoma characterized by abnormalities in PDGFRA, IDH1, EGFR, and NF1. Cancer Cell. 2010;17: 98–110.

18. Wang Q, Hu B, Hu X, Kim H, Squatrito M, Scarpace L, et al. Tumor Evolution of Glioma-Intrinsic Gene Expression Subtypes Associates with Immunological Changes in the Microenvironment. Cancer Cell. 2017;32: 42–56.e6.

19. Patel AP, Tirosh I, Trombetta JJ, Shalek AK, Gillespie SM, Wakimoto H, et al. Single-cell RNA-seq highlights intratumoral heterogeneity in primary glioblastoma. Science. 2014;344: 1396–1401.

20. Neftel C, Laffy J, Filbin MG, Hara T, Shore ME, Rahme GJ, et al. An Integrative Model of Cellular States, Plasticity, and Genetics for Glioblastoma. Cell. 2019;178: 835–849.e21.

21. Gill BJ, Pisapia DJ, Malone HR, Goldstein H, Lei L, Sonabend A, et al. MRI-localized biopsies reveal subtype-specific differences in molecular and cellular composition at the margins of glioblastoma. Proc Natl Acad Sci U S A. 2014;111: 12550–12555.

22. Gaw N, Hawkins-Daarud A, Hu LS, Yoon H, Wang L, Xu Y, et al. Integration of machine learning and mechanistic models accurately predicts variation in cell density of glioblastoma using multiparametric MRI. Sci Rep. 2019;9: 10063.

23. Hu LS, Ning S, Eschbacher JM, Gaw N, Dueck AC, Smith KA, et al. Multi-Parametric MRI and Texture Analysis to Visualize Spatial Histologic Heterogeneity and Tumor Extent in Glioblastoma. PLoS One. 2015;10: e0141506.

24. Swanson KR, Bridge C, Murray JD, Alvord EC Jr. Virtual and real brain tumors: using mathematical modeling to quantify glioma growth and invasion. J Neurol Sci. 2003;216: 1–10.

25. Wang CH, Rockhill JK, Mrugala M, Peacock DL, Lai A, Jusenius K, et al. Prognostic Significance of Growth Kinetics in Newly Diagnosed Glioblastomas Revealed by Combining Serial Imaging with a Novel Biomathematical Model. Cancer Research. 2009. pp. 9133–9140. doi:10.1158/0008-5472.can-08-3863

26. Baldock AL, Ahn S, Rockne R, Johnston S, Neal M, Corwin D, et al. Patient-specific metrics of invasiveness reveal significant prognostic benefit of resection in a predictable subset of gliomas. PLoS One. 2014;9: e99057.

27. Jackson PR, Juliano J, Hawkins-Daarud A, Rockne RC, Swanson KR. Patient-specific mathematical neuro-oncology: using a simple proliferation and invasion tumor model to inform clinical practice. Bull Math Biol. 2015;77: 846–856.

28. Albert FK, Forsting M, Sartor K, Adams HP, Kunze S. Early postoperative magnetic resonance imaging after resection of malignant glioma: objective evaluation of residual tumor and its influence on regrowth and prognosis. Neurosurgery. 1994;34. doi:10.1097/00006123-199401000-00008

29. Brown TJ, Brennan MC, Li M, Church EW, Brandmeir NJ, Rakszawski KL, et al. Association of the extent of resection with survival in glioblastoma: A systematic review and meta-analysis. JAMA Oncol. 2016;2: 1460–1469.

30. Berens ME, Giese A. “...those left behind.” Biology and Oncology of Invasive Glioma Cells. Neoplasia. 1999. pp. 208–219. doi:10.1038/sj.neo.7900034

31. Bond KM, Curtin L, Hawkins-Daarud A, Urcuyo JC, De Leon G, Sereduk C, et al. Glioblastoma states are defined by cohabitating cellular populations with progression-, imaging- and sex-distinct patterns. bioRxiv. 2022. doi:10.1101/2022.03.23.485500

32. Ellingson BM, Malkin MG, Rand SD, Connelly JM, Quinsey C, LaViolette PS, et al. Validation of functional diffusion maps (fDMs) as a biomarker for human glioma cellularity. J Magn Reson Imaging. 2010;31: 538–

548.

33. Mekkaoui C, Metellus P, Kostis WJ, Martuzzi R, Pereira FR, Beregi J-P, et al. Diffusion Tensor Imaging in Patients with Glioblastoma Multiforme Using the Supertoroidal Model. PLoS One. 2016;11: e0146693.

34. Stadlbauer A, Ganslandt O, Buslei R, Hammen T, Gruber S, Moser E, et al. Gliomas: histopathologic evaluation of changes in directionality and magnitude of water diffusion at diffusion-tensor MR imaging. Radiology. 2006;240: 803–810.

35. Barajas RF Jr, Cha S. Benefits of dynamic susceptibility-weighted contrast-enhanced perfusion MRI for glioma diagnosis and therapy. CNS Oncol. 2014;3: 407–419.

36. Soni N, Priya S, Bathla G. Texture Analysis in Cerebral Gliomas: A Review of the Literature. AJNR Am J Neuroradiol. 2019;40: 928–934.

37. Molina D, Pérez-Beteta J, Luque B, Arregui E, Calvo M, Borrás JM, et al. Tumour heterogeneity in glioblastoma assessed by MRI texture analysis: a potential marker of survival. Br J Radiol. 2016;89: 20160242.

38. Price SJ, Jena R, Burnet NG, Hutchinson PJ, Dean AF, Peña A, et al. Improved delineation of glioma margins and regions of infiltration with the use of diffusion tensor imaging: an image-guided biopsy study. AJNR Am J Neuroradiol. 2006;27: 1969–1974.

39. Brown R, Zlatescu M, Sijben A, Roldan G, Easaw J, Forsyth P, et al. The use of magnetic resonance imaging to noninvasively detect genetic signatures in oligodendroglioma. Clin Cancer Res. 2008;14: 2357–2362.

40. Drabycz S, Roldán G, de Robles P, Adler D, McIntyre JB, Magliocco AM, et al. An analysis of image texture, tumor location, and MGMT promoter methylation in glioblastoma using magnetic resonance imaging. Neuroimage. 2010;49: 1398–1405.

41. Weber M-A, Henze M, Tüttenberg J, Stieltjes B, Meissner M, Zimmer F, et al. Biopsy targeting gliomas: do functional imaging techniques identify similar target areas? Invest Radiol. 2010;45: 755–768.

42. Hu LS, Eschbacher JM, Dueck AC, Heiserman JE, Liu S, Karis JP, et al. Correlations between perfusion MR imaging cerebral blood volume, microvessel quantification, and clinical outcome using stereotactic analysis in recurrent high-grade glioma. AJNR Am J Neuroradiol. 2012;33: 69–76.

43. Hu LS, Eschbacher JM, Heiserman JE, Dueck AC, Shapiro WR, Liu S, et al. Reevaluating the imaging definition of tumor progression: perfusion MRI quantifies recurrent glioblastoma tumor fraction, pseudoprogression, and radiation necrosis to predict survival. Neuro Oncol. 2012;14: 919–930.

44. Semmineh NB, Xu J, Skinner JT, Xie J, Li H, Ayers G, et al. Assessing tumor cytoarchitecture using multiecho DSC-MRI derived measures of the transverse relaxivity at tracer equilibrium (TRATE). Magn Reson Med. 2015;74: 772–784.

45. Gillies RJ, Kinahan PE, Hricak H. Radiomics: Images Are More than Pictures, They Are Data. Radiology. 2016;278: 563–577.

46. Gatenby RA, Silva AS, Gillies RJ, Roy Frieden B. Adaptive Therapy. Cancer Research. 2009. pp. 4894–4903. doi:10.1158/0008-5472.can-08-3658

47. Guo Z, Shu Y, Zhou H, Zhang W, Wang H. Radiogenomics helps to achieve personalized therapy by evaluating patient responses to radiation treatment. Carcinogenesis. 2015;36: 307–317.

48. Fathi Kazerooni A, Bakas S, Saligheh Rad H, Davatzikos C. Imaging signatures of glioblastoma molecular characteristics: A radiogenomics review. J Magn Reson Imaging. 2020;52: 54–69.

49. Outcomes KDI. KDIGO 2012 Clinical Practice Guideline for the Evaluation and Management of Chronic

Kidney Disease. 2013.

50. Institute NC, National Cancer Institute. National Human Genome Research Institute. Definitions. 2020. doi:10.32388/mrapt2

51. Medtronic. Surgical Navigation Systems - StealthStation. [cited 11 Nov 2022]. Available: https://www.medtronic.com/us-en/healthcare-professionals/products/neurological/surgical-navigation-systems/stealthstation.html

52. Southern Labware. [cited 11 Nov 2022]. Available: www.southernlabware.com

53. IVFSTORE. In: ivfstore.com [Internet]. [cited 11 Nov 2022]. Available: us.ivfstore.com/products/lab-line-thermo-flasks

54. Louis DN, Perry A, Reifenberger G, von Deimling A, Figarella-Branger D, Cavenee WK, et al. The 2016 World Health Organization Classification of Tumors of the Central Nervous System: a summary. Acta Neuropathol. 2016;131: 803–820.

55. Louis DN, Perry A, Wesseling P, Brat DJ, Cree IA, Figarella-Branger D, et al. The 2021 WHO Classification of Tumors of the Central Nervous System: a summary. Neuro Oncol. 2021;23: 1231–1251.