Title: Orbital Magnetic Resonance Imaging of Ocular Giant Cell Arteritis: A Systematic Review and Individual Participant Data Meta-Analysis

Authors: Konstanze V. Guggenberger, MD,[1*] Athanasios Pavlou, MD,[2*§] Quy Cao, PhD,[3] Ishaan J Bhatt, BS,[4] Qi N. Cui, MD, PhD,[5] Thorsten A. Bley, MD, PhD,[1] Hugh D. Curtin, MD,[6] Julien Savatovsky, MD,[7] Jae W. Song, MD, MS[2]

*These authors contributed equally.

1 Department of Radiology, University of Würzburg, Würzburg, Germany

2 Department of Radiology, University of Pennsylvania, Philadelphia, PA

3 Department of Biostatistics and Epidemiology, University of Pennsylvania, Philadelphia, PA

4 Drexel University College of Medicine, Philadelphia, PA

5 Department of Ophthalmology, Scheie Eye Institute, University of Pennsylvania, Philadelphia, PA

6 Department of Radiology, Massachusetts Eye and Ear, Harvard Medical School, Boston, MA

7 Department of Radiology, Fondation Ophtalmologique Adolphe de Rothschild, Paris France

§Current address: Department of Radiology and Nuclear Medicine, University of Maryland School of Medicine, Baltimore, MD

Corresponding Author:

Jae W. Song, MD, MS

Hospital of the University of Pennsylvania

3400 Spruce Street

Philadelphia, PA 19104

Tele: 215-349-8023

Fax: 215-662-3283

Email: jae.song@pennmedicine.upenn.edu

Abstract

Objectives: We conducted a systematic review and individual participant data meta-analysis of publications reporting the ophthalmologic presentation, clinical exam, and orbital MRI findings in ocular giant cell arteritis.

Methods: PubMed and Cochrane databases were searched up to January 16, 2022. Publications reporting patient-level data on patients with ophthalmologic symptoms, imaged with orbital MRI and diagnosed with biopsy-proven giant cell arteritis were included. Demographics, clinical symptoms, exam, lab, imaging, and outcomes data were extracted. Methodological quality and completeness of reporting of case reports were assessed.

Results: Thirty-two studies were included comprising 51 patients (females=24; median age, 76 years). Vision loss (78%) and headache (45%) were commonly reported visual and cranial symptoms. Ophthalmologic presentation was unilateral (41%) or bilateral (59%). Fundus examination most commonly showed disc edema (64%) and pallor (49%). Average visual acuity was very poor (2.28 logMAR ± 2.18). Diagnoses included anterior (61%) and posterior (16%) ischemic optic neuropathy, central retinal artery occlusion (8%) and orbital infarction syndrome (2%). On MRI, enhancement of the optic nerve sheath (53%), intraconal fat (25%), and optic nerve/chiasm (14%) was most prevalent. Among patients with monocular visual symptoms, 38% showed pathologic enhancement in the asymptomatic eye. Six of seven cases reported imaging resolution after treatment on follow-up MRIs.

Conclusions: Vision loss, pallid disc edema, and optic nerve sheath enhancement are the most common clinical, fundoscopic and imaging findings reported in patients diagnosed with ocular giant cell arteritis, respectively. MRI may detect subclinical inflammation in the asymptomatic eye and may be an adjunct diagnostic tool.

Keywords: Giant Cell Arteritis, Magnetic Resonance Imaging, Inflammation, Orbit, Optic Nerve

Key Points:

- Among 32 publications comprising 51 patients with biopsy-proven giant cell arteritis, vision loss, pallid disc edema, and optic nerve sheath enhancement were the most commonly reported clinical, fundoscopic and orbital MRI findings, respectively.
- Orbital MRI detected subclinical inflammation in the asymptomatic orbit in 38% of giant cell arteritis patients presenting with monocular visual symptoms.
- MRI may have a diagnostic role in patients with suspected giant cell arteritis and presenting with acute visual symptoms.

Abbreviations: GCA, giant cell arteritis; BB-MRI, black-blood MRI; TAB, temporal artery biopsy; VA, visual acuity

Introduction

Ocular manifestations among patients with giant cell arteritis (GCA), a systemic vasculitis mainly affecting medium-sized and large arteries, can lead to permanent visual impairment and irreversible blindness [1]. The reported annual incidence of GCA is approximately 19.8 per 100,000 persons aged 50 years or older [2; 3] and permanent vision loss occurs in approximately 15% to 20% of these patients [4-6]. Prompt diagnosis and treatment are imperative to prevent irreversible blindness. However, the wide spectrum of ophthalmic symptoms and nonspecific systemic symptoms as well as the possibility of occult GCA without systemic symptoms [7] can make the diagnosis challenging often requiring multispecialty care coordination and a temporal artery biopsy (TAB) [8].

Black blood magnetic resonance imaging (BB-MRI) of the scalp is increasingly being used to assess inflammation of the vessel walls of the temporal and occipital arteries to assist in the diagnosis of GCA [9]. Several studies also report orbital inflammatory findings on MRI in patients with GCA with postcontrast enhancement suggesting inflammation of the ophthalmic artery vessel walls [10], optic nerve sheath [8], intraconal fat [8; 11] and optic nerve/chiasm [8; 12]. These reports suggest MRI of the scalp and orbits could provide diagnostic information for patients with suspected GCA with ischemic optic neuropathy. However, the spectrum and prevalence of orbital MRI findings and ophthalmic symptoms in large cohorts of patients with ocular GCA have not been reported.

We performed a systematic review and individual participant data meta-analysis of the literature to determine the prevalence of orbital MR findings in the setting of ophthalmologic symptoms in patients diagnosed with biopsy-proven GCA. Given the rarity of this vasculitis and patients imaged by MRI, patient-level data from published case reports/series were extracted for analysis, a methodology used for rare diseases or when there is insufficient aggregate data for a good quality review per Cochrane guidelines [13; 14].

Methods

Search Strategy and Study Selection

This systematic review was conducted in accordance with the Preferred Reporting Items for Systematic Reviews and Meta-Analyses (PRISMA) guidelines and registered in Prospero (CRD42021254494). PubMed and Cochrane searches were conducted without foreign language restrictions on August 14, 2020 with an updated search performed on January 16, 2022. The search terms are provided in **Supplemental Table 1**. Manual review of the citations was performed. Publications were included if the study reported a patient diagnosed with biopsy-proven GCA, presented with visual symptoms, underwent MRI of the brain/orbits, included a description of any orbital imaging findings, and patient-level data could be extracted. Institutional review board approval or written informed consent was not required due to the literature-based nature of the study. No overlapping systematic review regarding our topic was found in the Cochrane Library.

Data extraction

Two independent reviewers (xx, xx; for blinded review) extracted the following data: study characteristics, number of patients with biopsy proven GCA, gender, age, presenting clinical signs/symptoms, ophthalmologic exam, MRI description, biopsied tissue, treatment and outcomes data. All study design types, including letters to the editor, conference abstracts, and case reports/series were included if individual data could be extracted. Corresponding authors were contacted to gather more data. Publications were evaluated for quality using a published Case Reports Critical Appraisal Tool (**Supplemental Table 2**) and completeness of reporting using the CARE guidelines [15; 16].

Statistical Analysis

Categorical variables are expressed in counts and percentages; continuous variables are expressed in means. Strength of agreement between two reviewers for study selection was calculated by an unweighted Cohen's κ. Visual acuity (VA) is a measure of the ability to discriminate 2 stimuli separated in space at

high contrast and is a measure of visual function. For quantitative analysis, Snellen VA was converted into the logarithm of the Minimum Angle of Resolution (logMAR), which is calculated as –log (decimal acuity), per convention in the ophthalmology literature [17; 18]. Higher values indicate poorer vision on the logMAR scale. Legal blindness is defined, in part, by VA less than or equal to 1.0 logMAR [19], while "0" on the logMAR scale indicates "no vision loss" (20/20 vision). The VA of patients with very low vision or complete blindness is typically classified using the semi-quantitative scale "counting fingers," "hand motion," "light perception," and "no light perception" and were assigned values of 2, 3, 4, and 5 on the logMAR scale, respectively. The average VA was reported per patient and per symptomatic orbit. SPSS v19 (IBM, Chicago, IL) was used for statistical analysis.

Results

Literature Search

Initial search yielded 157 studies, which were screened by 2 independent reviewers (xx, xx- for blinded review) with moderate agreement (κ=0.79, 95% CI 0.69-0.89, $p<0.0001$). Full-text screen was performed on 62 articles, from which 32 articles were qualitatively reviewed (**Figure 1**).

Data Synthesis

A total of 51 patients (males=27, females=24; median age=77 years (IQR 68.5, 81) [range 60-92 years]) were included in the analysis (**Supplemental Table 3**). **Figure 2A-B** shows the reported ophthalmologic symptoms/signs. Vision loss (78%, N=40/51) was the most commonly reported ophthalmologic symptom at initial presentation. Diplopia (20%, N=10/51) and orbital pain (10%, N=5/51) were also reported. On exam, an afferent pupillary defect (27%, N=14/51), reduced extraocular motility (16%, N=8/51), and proptosis (14%, N=7/51) were most commonly reported. Most common cranial symptom was headache (45%, N=23/51). When specified, headaches were temporal (64%), retro-orbital (27%), occipital (9%), or frontal (9%). Jaw claudication (20%, N=10/51), palpable temporal artery (18%, N=9/51), and scalp

tenderness (18%, N=9/51) were commonly reported. Constitutional symptoms included fatigue (20%, N=10/51), weight loss (20%, N=10/51), fever (14%, N=7/51), and anorexia (10%, N=5/51) (**Figure 2C**).

Upon initial presentation, visual symptoms were reported to be unilateral in 41% (N=21/51) (right eye, 52%; left eye, 48%) and bilateral in 59% (N=30/51) of patients. Among patients who reported bilateral visual symptoms, 20% (N=10/51) described sequential symptom onset. On ophthalmologic exam, VA was reported for both eyes in 63% of cases (N=32/51) with an average VA of 2.28 logMAR (SD ±2.18 logMAR). Among patients who presented with unilateral symptoms with reported VA (N=11), the average VA of the symptomatic eye was 2.04 logMAR (SD ±2.10 logMAR). Among patients who presented with bilateral/sequential symptoms with reported VA (N=23), the average VA was 2.91 logMAR (SD ±2.12 logMAR).

Fundus examinations were reported in 76% of cases (N=39/51). Disc findings included disc edema (64%, N=25/39), disc pallor (49%, N=19/39), disc hemorrhage (11%, N=4/39), and disc atrophy (5%, N=2/39). Other findings included cotton wool spots (10%, N=4/39), cherry red spot (5%, N=2/39), and vascular narrowing (5%, N=2/39). Reported diagnoses included anterior ischemic optic neuropathy (61%, N=31/51), posterior ischemic optic neuropathy (16%, N=8/51), and central retinal artery occlusion (8%, N=4/51). Orbital infarction syndrome was reported in 1 case as a result of absent filling of the right ophthalmic artery [20].

The erythrocyte sedimentation rate (ESR) and c-reactive protein (CRP) were elevated in 83% (N=33/40; normal considered <20 mm/hr) and 42% (N=11/26; normal considered <0.5mg/L) of reported cases, respectively. The ESR and CRP were both normal in 8% of cases (N=2/26) [21; 22]. Five cases reported platelet counts, with thrombocytosis (above 450 x 10^9/L) in 3 of the cases [23-25].

Orbital MR Imaging Findings

Neuroimaging included combined brain and orbit (76%, N=39/51) or only orbital MRIs (24%, N=12/51). Two studies used dedicated black blood MR imaging (BB-MRI) [22; 26]. Eleven cases reported the steroid-to-imaging time interval, which ranged between 1 day [22] and 12 months [11]. **Figure 3** shows the prevalence of reported pathologic MR signal detected in the orbit among patients diagnosed with ocular GCA (N=51) and a subgroup analysis among those who presented with vision loss (N=40). Pathologic enhancement on postcontrast T1-weighted imaging was the most commonly reported description with enhancement of the optic nerve sheath (53%, N=27/51), intraconal fat (25%, N=13/51), optic nerve/chiasm (14%, N=7/51), extraocular muscle (14%, N=7/51) and lacrimal gland (2%, N=1/51). When assessed, ophthalmic artery vessel wall enhancement was described in 10% (N=5/51) of cases. Diffusion restriction (8%, N=4/51)[20; 27-29] or T2/STIR hyperintensity (4%, N=2/51) [28; 30] of the optic nerve, diffusion restriction of the lacrimal gland (2%, N=1/51) [31], and enlargement of the extraocular muscle (2%, N=1/51) [21] were also reported. The optic nerve/chiasm showed any pathologic MR signal abnormality (e.g., postcontrast enhancement, T2-weighted/Short Tau Inversion Recovery (STIR), or diffusion restriction) in 25% (N=13/51) of cases of ocular GCA. Subgroup analyses with vision loss showed 30% (N=12/40) of cases revealed pathologic MR signal in the optic nerve/chiasm. **Figure 4A-F** illustrates representative MRI findings on a dedicated orbital MRI and BB-MRI from patients diagnosed with ocular GCA from the authors' institutions.

Concordance of Monocular Visual Symptoms and Orbital MRI Findings in the Ipsilateral Symptomatic versus Contralateral Asymptomatic Orbit

Subgroup analysis of patients presenting with monocular visual symptoms (N=21) showed pathologic MR signal of orbital structures in the symptomatic eye in 91% (N=19/21) of cases. The most commonly involved orbital structure was the optic nerve sheath (38%, N=8/21) [23; 29; 32-35] followed by the optic nerve/chiasm [24%, N=5/21; N=2 showed diffusion restriction [20; 29], N=1 showed STIR hyperintensity [30], and N=2 showed enhancement [8; 35]], intraconal fat (24%, N=5/21), extraocular muscles (19%, N=4/21), ophthalmic artery (19%, N=4/21), and lacrimal gland (10%, N=2/21).

Pathologic orbital MRI findings in the asymptomatic orbit in patients with monocular visual symptoms were also reported in 38% (N=8/21) of cases (**Figure 5**). The most common pathologically enhancing orbital structures on MRI in the asymptomatic orbit among patients with monocular vision loss were the optic nerve sheath (24%, N=5/21), intraconal fat (14%, N=3/21), and ophthalmic artery (14%, N=3/21).

Pathologic Orbital MR Enhancement in GCA patients Without Visual Symptoms

Two studies included cases that showed orbital MR findings in patients without visual symptoms/signs. Donaldson et al reported 3 TAB proven cases of GCA in patients without visual symptoms but with bilateral ophthalmic artery vessel wall enhancement [34]. These patients reportedly presented with cranial symptoms of GCA (e.g., headaches, scalp tenderness, jaw claudication).

Geiger et al reported 10 TAB proven cases of GCA in patients without visual symptoms, among which 4 showed bilateral ophthalmic artery enhancement and 2 showed unilateral ophthalmic artery enhancement; the remaining 4 cases showed no ophthalmic artery enhancement [26].

Diagnosis and Outcomes

The reported time-interval from presentation until diagnosis ranged from 2 weeks [23] to 3 months [21]. A diagnosis of GCA was confirmed by TAB (90%, N=46/51), extraocular muscle (2%) [21], or optic nerve sheath (2%) [36] biopsies. One study reported “biopsy-proven” but did not specify what tissue was biopsied [32]. In one case, bilateral TABs were reported to be negative but positive in the extraocular muscles [21].

Clinical outcomes were reported in 48% of the cases. Follow-up ranged from 7 days [35] to 3 months [37]. When reported, ophthalmologic outcomes improved (9%), remained stable (33%), or worsened (7%)

at follow-up. Seven cases reported follow-up MR exams, among which 6 cases [21; 25; 30; 35; 37; 38] reported resolution and 1 case [39] reported no improvement.

In 24% (N=12/51) of cases, treatment was delayed due to misclassification. Alternative diagnoses included sinusitis, lymphoma, optic neuritis, non-arteritic ischemic optic neuropathy/transient ischemic attack/embolism, infectious conjunctivitis, episcleritis, diabetic neuropathy, and infectious orbital cellulitis.

Quality and Completeness of Reporting

A critical appraisal checklist for case reports and the CARE (Case Report) Guideline was used to assess the quality and the reporting completeness of case reports (**Supplemental Figure 1A-B**), respectively [15; 16]. Reporting the "clinical findings and timeline" was most complete (100%) and "patient perspective" was not fulfilled in any publication. "Informed consent" was obtained in 19% of publications.

Discussion

We summarize patient-level data from case reports/series of patients diagnosed with biopsy-proven giant cell arteritis, presenting with visual symptoms, and imaged by orbital MRI. Vision loss was the most common presenting ophthalmologic symptom. On orbital MRI, enhancement of the optic nerve sheath, intraconal fat and optic nerve/chiasm were the most common pathologic imaging findings. When assessed, imaging also revealed enhancement of the ophthalmic artery vessel walls in 10% of cases. Moreover, among 38% of patients with monocular visual symptoms, the contralateral asymptomatic eye also revealed pathologic enhancement. These results add to the literature by informing clinicians about

the range of orbital imaging manifestations for this vasculitis as well as suggesting a potential diagnostic role for MR imaging in patients with ocular giant cell arteritis.

Thrombosis of the posterior ciliary arteries (PCA) is a hallmark of GCA [40]. Vision loss occurs secondary to ischemic infarction of the optic nerve or the retina due to thrombosis by granulomatous inflammation of the PCA or the central retinal artery, respectively. In a prospective cohort of 66 biopsy proven GCA patients with vision loss, fluorescein angiography revealed occlusion of the PCAs or moderate to marked delay in perfusion of the choroidal vascular bed [1]. The frequent involvement of the medial and lateral long PCAs, which course parallel to the optic nerve sheath, could explain optic nerve sheath and intraconal fat enhancement on imaging. Reports of isolated optic nerve sheath enhancement raise the possibility of inflamed vessels within the perioptic subarachnoid space, which may be below the spatial resolution of MR imaging. Scanning electron microscopy studies on autopsy specimens report arachnoid trabeculae and septae that divide this perioptic subarachnoid space through which lymphatic and blood vessels traverse [41]. Optic nerve enhancement may be explained by involvement of the central retinal or cilioretinal artery. Finally, inflamed branches of the internal carotid artery (ophthalmic segment) or proximal ophthalmic artery could explain chiasmal enhancement. In fact, studies report variable intracranial internal carotid artery vessel wall enhancement in patients with GCA [22]. Attention to the anatomy of orbital pathologic enhancement may yield information about orbital vascular territories and aid with risk-stratification.

Interestingly, 38% of cases with monocular visual symptoms also revealed enhancement of the optic nerve sheath (24%), intraconal fat (14%), and ophthalmic artery (14%) in the asymptomatic orbit. This result suggests imaging may detect subclinical ischemia. Hayreh et al reported that among 27 of 85 prospectively recruited GCA patients presenting with simultaneous vision loss, fundus exams revealed evidence of older changes in the contralateral eye as well as the newly involved eye [42]. Patients may not become aware of partial unilateral vision loss until the second eye is also affected, which may result

in a presentation of simultaneous rather than sequential vision loss [42]. The incidence of sequential versus simultaneous vision loss likely depends on when the GCA diagnosis is made and how soon the patient is evaluated. In our review, one case reported unilateral vision loss and optic disc blurring only in the symptomatic eye despite bilateral optic nerve sheath enhancement on MRI [33]. A negative fundus exam in the setting of positive MRI findings in the asymptomatic eye raises the possibility of early ischemic changes and possibly developing posterior ischemic optic neuropathy, a less common etiology of vision loss in GCA. Given that a primary goal for treating ocular GCA is preserving vision in the asymptomatic eye, MRI may have an adjunct diagnostic role to the fundus exam.

The role of orbital MRI for evaluating suspected cranial GCA is an area of future investigation. The European League Against Rheumatism recommends the use of imaging for diagnosing and monitoring GCA. BB-MRI can evaluate the scalp artery vessel walls if ultrasound is not available or inconclusive [43]. In the presence of visual symptoms, a comprehensive MRI assessment of both orbits in addition to BB-MRI for scalp artery imaging could be valuable in the acute setting. However, in the absence of visual symptoms, the role of orbital MRI as a screening tool for diagnosis is unclear and may not be cost-effective. Additional areas of future investigation include whether MRI could help determine when corticosteroids/immunomodulatory treatments could be tapered, if MRI can detect relapse or whether MRI has a prognostic role for determining ophthalmologic outcomes. Several cases [21; 30; 35; 37; 38] reported resolution of pathologic enhancement on orbital MRI and improvement in visual function/symptoms while another case [25] reported no visual functional improvement despite imaging resolution. Alternatively, optical coherence tomography/-angiography can image the retinal layer and assess microvascular changes, respectively. These tools may be more precise in determining ocular GCA outcomes and visual potential by evaluating the association between capillary flow density and retinal nerve fiber layer thickness over time [44; 45]. These questions are areas of future prospective investigations.

There are limitations to this study. First, a selection bias in the cases that underwent brain/orbital MR imaging likely resulted in an overestimation in the prevalence of pathologic orbital findings. Orbital MRIs are not commonly performed in patients with suspected cranial GCA, especially in the absence of ophthalmologic symptoms. Moreover, few institutions may have access to MRIs, particularly in the emergency department. Nevertheless, a summary of the reported cases provides new knowledge about the spectrum of orbital imaging findings in patients with ocular GCA and adds to the literature about the potential role of MRI in patients with ocular GCA. Second, TAB is an imperfect gold standard for the diagnosis of GCA [46]. As biopsy proven GCA was an inclusion criterion for this review, the true prevalence of pathologic orbital imaging findings in ocular GCA may not be accurate. Third, patients diagnosed with GCA but without visual symptoms may not have been imaged with an orbital MRI; this subgroup was not an inclusion criterion of this study. Hence, the true prevalence of pathologic orbital findings in cranial GCA, with or without ophthalmic symptoms, is not established in this review. Fourth, the ophthalmologic work-up and reporting of ocular examinations varied, limiting the completeness of data extraction. Attempts to contact authors were made with variable success. Fifth, the MRI protocol was not detailed in most reports. Variations in pulse sequences and image interpretation may limit accuracy. Moreover, most studies did not use high spatial resolution BB-MRI and likely were not able to evaluate the ophthalmic artery vessel walls. A purpose of this study therefore is to highlight the importance of evaluating orbital anatomy in suspected GCA cases with ophthalmologic symptoms.

In conclusion, we present individual-participant level data on orbital MRI findings in patients with biopsy proven ocular giant cell arteritis. Vision loss is a severely debilitating complication of ocular giant cell arteritis, which can be minimized or prevented if recognized early and treated promptly. Understanding the spectrum of orbital MRI findings in these cases is important for the radiologist as scalp black-blood MRI, which can include the orbital anatomy, is becoming increasingly adopted clinically in the diagnostic evaluation of these patients.

Acknowledgements: This work is supported by the American Heart Association Career Development Award 938082 (JWS) and NIH/NEI K08EY029765 (QNC). Dr. Jae W. Song is the guarantor of this study.

References

1 Hayreh SS, Podhajsky PA, Zimmerman B (1998) Ocular manifestations of giant cell arteritis. Am J Ophthalmol 125:509-520

2 Salvarani C, Gabriel SE, O'Fallon WM, Hunder GG (1995) The incidence of giant cell arteritis in Olmsted County, Minnesota: apparent fluctuations in a cyclic pattern. Ann Intern Med 123:192-194

3 Chandran AK, Udayakumar PD, Crowson CS, Warrington KJ, Matteson EL (2015) The incidence of giant cell arteritis in Olmsted County, Minnesota, over a 60-year period 1950-2009. Scand J Rheumatol 44:215-218

4 Saleh M, Turesson C, Englund M, Merkel PA, Mohammad AJ (2016) Visual Complications in Patients with Biopsy-proven Giant Cell Arteritis: A Population-based Study. J Rheumatol 43:1559-1565

5 Ji J, Dimitrijevic I, Sundquist J, Sundquist K, Zöller B (2017) Risk of ocular manifestations in patients with giant cell arteritis: a nationwide study in Sweden. Scand J Rheumatol 46:484-489

6 González-Gay MA, García-Porrúa C, Llorca J et al (2000) Visual manifestations of giant cell arteritis. Trends and clinical spectrum in 161 patients. Medicine (Baltimore) 79:283-292

7 Costello F, Zimmerman MB, Podhajsky PA, Hayreh SS (2004) Role of thrombocytosis in diagnosis of giant cell arteritis and differentiation of arteritic from non-arteritic anterior ischemic optic neuropathy. Eur J Ophthalmol 14:245-257

8 D'Souza NM, Morgan ML, Almarzouqi SJ, Lee AG (2016) Magnetic resonance imaging findings in giant cell arteritis. Eye (Lond) 30:758-762

9 Bley TA, Wieben O, Uhl M, Thiel J, Schmidt D, Langer M (2005) High-resolution MRI in giant cell arteritis: imaging of the wall of the superficial temporal artery. AJR Am J Roentgenol 184:283-287

10 Mohammed-Brahim N, Clavel G, Charbonneau F et al (2019) Three Tesla 3D High-Resolution Vessel Wall MRI of the Orbit may Differentiate Arteritic From Nonarteritic Anterior Ischemic Optic Neuropathy. Invest Radiol 54:712-718

11 AlShaker S, Shemesh AA, Margolin E (2018) Enhancement of optic nerve sheath in AAION: a case of visual recovery in fulminant GCA. Can J Ophthalmol 53:e236-e239

12 Lee AG, Eggenberger ER, Kaufman DI, Manrique C (1999) Optic nerve enhancement on magnetic resonance imaging in arteritic ischemic optic neuropathy. J Neuroophthalmol 19:235-237

13 Nambiema A, Sembajwe G, Lam J et al (2021) A Protocol for the Use of Case Reports/Studies and Case Series in Systematic Reviews for Clinical Toxicology. Front Med (Lausanne) 8:708380

14 Tierney JF SL, Clarke M (2022) Chapter 26: Individual Partcipant Data. In: Higgins JPT TJ, Chandler J, Cumpston M, Li T, Page MJ, Welch VA (editors), (ed) Cochrane Handbook for Systematic Reviews of Interventions version 63. Cochrane

15 Gagnier JJ, Kienle G, Altman DG, Moher D, Sox H, Riley D (2014) The CARE guidelines: consensus-based clinical case report guideline development. J Clin Epidemiol 67:46-51

16 Joanna Briggs Institute (2017) JBI Checklist for Case Reports. The Joanna Briggs Institute, www.joannabriggs.org. Available via https://jbi.global/sites/default/files/2019-05/JBI_Critical_Appraisal-Checklist_for_Case_Reports2017_0.pdf. Accessed November 10, 2022 2022

17 Holladay JT (2004) Visual acuity measurements. J Cataract Refract Surg 30:287-290

18 Kniestedt C, Stamper RL (2003) Visual acuity and its measurement. Ophthalmol Clin North Am 16:155-170, v

19 Virgili G, Acosta R, Bentley SA, Giacomelli G, Allcock C, Evans JR (2018) Reading aids for adults with low vision. Cochrane Database Syst Rev 4:Cd003303
20 Kim DD, Budhram A, Pelz D, MacDonald M (2016) Teaching NeuroImages: Orbital infarction syndrome from giant cell arteritis. Neurology 87:e269
21 Lee AG, Tang RA, Feldon SE et al (2001) Orbital presentations of giant cell arteritis. Graefes Arch Clin Exp Ophthalmol 239:509-513
22 Gospe SM, 3rd, Amrhein TJ, Malinzak MD, Bhatti MT, Mettu P, El-Dairi MA (2021) Magnetic Resonance Imaging Abnormalities of the Optic Nerve Sheath and Intracranial Internal Carotid Artery in Giant Cell Arteritis. J Neuroophthalmol 41:54-59
23 Liu KC, Chesnutt DA (2013) Perineural optic nerve enhancement on magnetic resonance imaging in giant cell arteritis. J Neuroophthalmol 33:279-281
24 Emami S, Howarth D, Margolin E (2021) Giant Cell Arteritis Presenting as Bilateral Optic Perineuritis in an African Man. J Neuroophthalmol 41:e149-e152
25 Tashiro T, Tsujimoto A, Nakamura N (2021) [Ischemic optic neuropathy despite pulse methylprednisolone therapy in a giant cell arteritis patient with perineural optic nerve enhancement]. Rinsho Shinkeigaku 61:851-855
26 Geiger J, Ness T, Uhl M et al (2009) Involvement of the ophthalmic artery in giant cell arteritis visualized by 3T MRI. Rheumatology (Oxford) 48:537-541
27 Ross M, Bursztyn L, Superstein R, Gans M (2017) Multiple Cranial Nerve Palsies in Giant Cell Arteritis. J Neuroophthalmol 37:398-400
28 Albarrak AM, Mohammad Y, Hussain S, Husain S, Muayqil T (2018) Simultaneous bilateral posterior ischemic optic neuropathy secondary to giant cell arteritis: a case presentation and review of the literature. BMC Ophthalmol 18:317
29 Biotti D, Savatovski J, Bidot S et al (2011) Diffusion MR imaging of the optic nerve in a patient with giant-cell arteritis and vertebral artery vasculitis. Eur Neurol 66:83-84
30 Garcia-Porrua C, Santamarina R, Armesto V, Gonzalez-Gay MA (2005) Magnetic resonance imaging in optic neuritis due to giant cell arteritis. Arthritis Rheum 53:313-314
31 Heraud A, Zmuda M, Lecler A (2018) Lacrimal Gland Ischemia due to Giant Cell Arteritis. Ophthalmology 125:1233
32 Garcia-Porrua C, Pego-Reigosa R, Armesto V, Gonzalez-Gay MA (2003) Neovascularization around the optic nerve in giant cell arteritis. Arthritis Rheum 49:737-738
33 Kornberg MD, Ratchford JN, Subramaniam RM, Probasco JC (2015) Giant cell arteritis mimicking infiltrative leptomeningeal disease of the optic nerves. BMJ Case Rep 2015
34 Donaldson L, Nanji K, Rebello R, Khalidi NA, Rodriguez AR (2020) Involvement of the intracranial circulation in giant cell arteritis. Can J Ophthalmol 55:391-400
35 Hittinger M, Berlis A, Pfadenhauer K (2015) Inflammatory Pseudo-tumour Orbitae (PTO): An Atypical Manifestation of Giant Cell Arteritis (GCA). Clin Neuroradiol 25:411-414
36 Morgenstern KE, Ellis BD, Schochet SS, Linberg JV (2003) Bilateral optic nerve sheath enhancement from giant cell arteritis. J Rheumatol 30:625-627
37 Joelson E, Ruthrauff B, Ali F, Lindeman N, Sharp FR (2000) Multifocal dural enhancement associated with temporal arteritis. Arch Neurol 57:119-122
38 Nassani S, Cocito L, Arcuri T, Favale E (1995) Orbital pseudotumor as a presenting sign of temporal arteritis. Clin Exp Rheumatol 13:367-369
39 Choi JH, Shin JH, Jung JH (2019) Arteritic Anterior Ischemic Optic Neuropathy Associated with Giant-Cell Arteritis in Korean Patients: A Retrospective Single-Center Analysis and Review of the Literature. J Clin Neurol 15:386-392
40 Hayreh SS (2021) Giant cell arteritis: Its ophthalmic manifestations. Indian J Ophthalmol 69:227-235

41 Killer HE, Laeng HR, Flammer J, Groscurth P (2003) Architecture of arachnoid trabeculae, pillars, and septa in the subarachnoid space of the human optic nerve: anatomy and clinical considerations. Br J Ophthalmol 87:777-781
42 Hayreh SS (1991) Ophthalmic features of giant cell arteritis. Baillieres Clin Rheumatol 5:431-459
43 Dejaco C, Ramiro S, Duftner C et al (2018) EULAR recommendations for the use of imaging in large vessel vasculitis in clinical practice. Ann Rheum Dis 77:636-643
44 Gaier ED, Gilbert AL, Cestari DM, Miller JB (2018) Optical coherence tomographic angiography identifies peripapillary microvascular dilation and focal non-perfusion in giant cell arteritis. Br J Ophthalmol 102:1141-1146
45 Chen JJ, AbouChehade JE, Iezzi R, Jr., Leavitt JA, Kardon RH (2017) Optical Coherence Angiographic Demonstration of Retinal Changes From Chronic Optic Neuropathies. Neuroophthalmology 41:76-83
46 Ashton-Key MR, Gallagher PJ (1992) False-negative temporal artery biopsy. Am J Surg Pathol 16:634-635

Figures:

Figure 1: Literature Search Flowchart

PubMed and Cochrane databases were searched and yielded 157 articles from which 32 met inclusion and exclusion criteria.

Figure 2: Clinical Ophthalmologic and Cranial Symptoms and Exam Signs at Initial Presentation

A) Prevalence of ophthalmologic clinical symptoms B) ophthalmologic exam signs and C) cranial and systemic symptoms in patients with biopsy proven giant cell arteritis with visual symptoms.

Figure 3: Prevalence of Reported Pathologic MR Signal of Orbital Structures in Patients with Ocular Giant Cell Arteritis

Prevalence of pathologic MR signal (e.g., postcontrast enhancement, T2-weighted/STIR hyperintensity, or diffusion restriction) of orbital structures on MRI in patients with biopsy proven giant cell arteritis among all ocular GCA patients and subgroup presenting with vision loss are shown.

Abbreviations: GCA, giant cell arteritis; STIR, short tau inversion recovery; MRI, magnetic resonance imaging

Figure 4: Example Orbital and Black-Blood MR Images of Patients with Ocular Giant Cell Arteritis

(A) Axial T1-weighted postcontrast fat suppressed image shows avid enhancement of the intraorbital fat (arrowheads) and ophthalmic arteries (white arrows). The right superficial temporal artery also showed vessel wall enhancement (black arrow).

(B) Coronal T1-weighted postcontrast fat suppressed image of the same patient shows enhancement of the optic nerve sheath (arrowheads). Enhancement of the temporalis muscle (black arrows) and subcutaneous fat of the scalp associated with the frontal branches of the superficial temporal arteries (white arrows) was also present.

(C) Axial high spatial resolution BB-MRI imaging revealed vessel wall enhancement of the ophthalmic arteries (arrowheads). Insets show orthogonal images of the thickened and enhancement ophthalmic artery vessel walls (arrowheads), bilaterally.

(D) Sagittal-oblique high spatial resolution BB-MRI of the right optic nerve shows enhancement of the optic nerve sheath (arrowheads) and ophthalmic artery vessel walls (arrow).

(E) Axial T1-weighted postcontrast fat suppressed image shows enhancement of the left optic nerve head (arrowhead), left optic nerve sheath (black arrow), and bilateral intraconal fat (white arrows).

(F) Axial T1-weighted postcontrast fat suppressed image shows enhancement and asymmetric enlargement of the right lacrimal gland (arrowhead), which also showed focal diffusion restriction (inset, arrowhead). Enhancement of the bilateral intraconal fat (white arrows) were present as well as linear enhancement that tracked along the right anterior ethmoidal artery (black arrow).

Abbreviations: BB-MRI, black-blood MRI; T1w, T1-weighted postcontrast; DWI, diffusion weighted imaging

Figure 5: Orbital MRI findings in Patients with Ocular Giant Cell Arteritis and Monocular Visual Symptoms

Prevalence of pathologic MR signal of orbital structures in the symptomatic versus asymptomatic eye is shown.

Figure 1

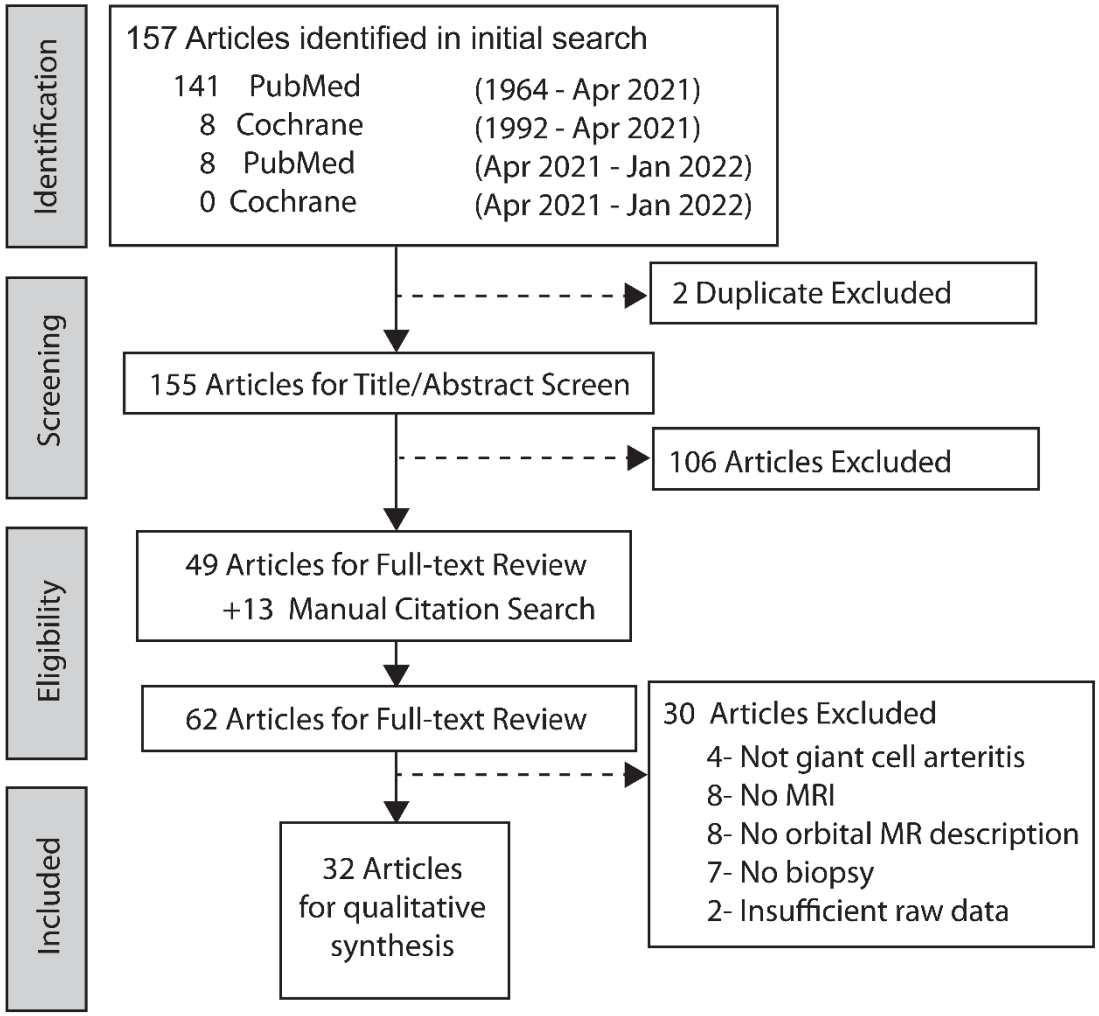
Identification
157 Articles identified in initial search
141 PubMed (1964 - Apr 2021)
8 Cochrane (1992 - Apr 2021)
8 PubMed (Apr 2021 - Jan 2022)
0 Cochrane (Apr 2021 - Jan 2022)
2 Duplicate Excluded
Screening
155 Articles for Title/Abstract Screen
106 Articles Excluded
Eligibility
49 Articles for Full-text Review
+13 Manual Citation Search
62 Articles for Full-text Review
30 Articles Excluded
4- Not giant cell arteritis
8- No MRI
8- No orbital MR description
7- No biopsy
2- Insufficient raw data
Included
32 Articles for qualitative synthesis

Figure 2

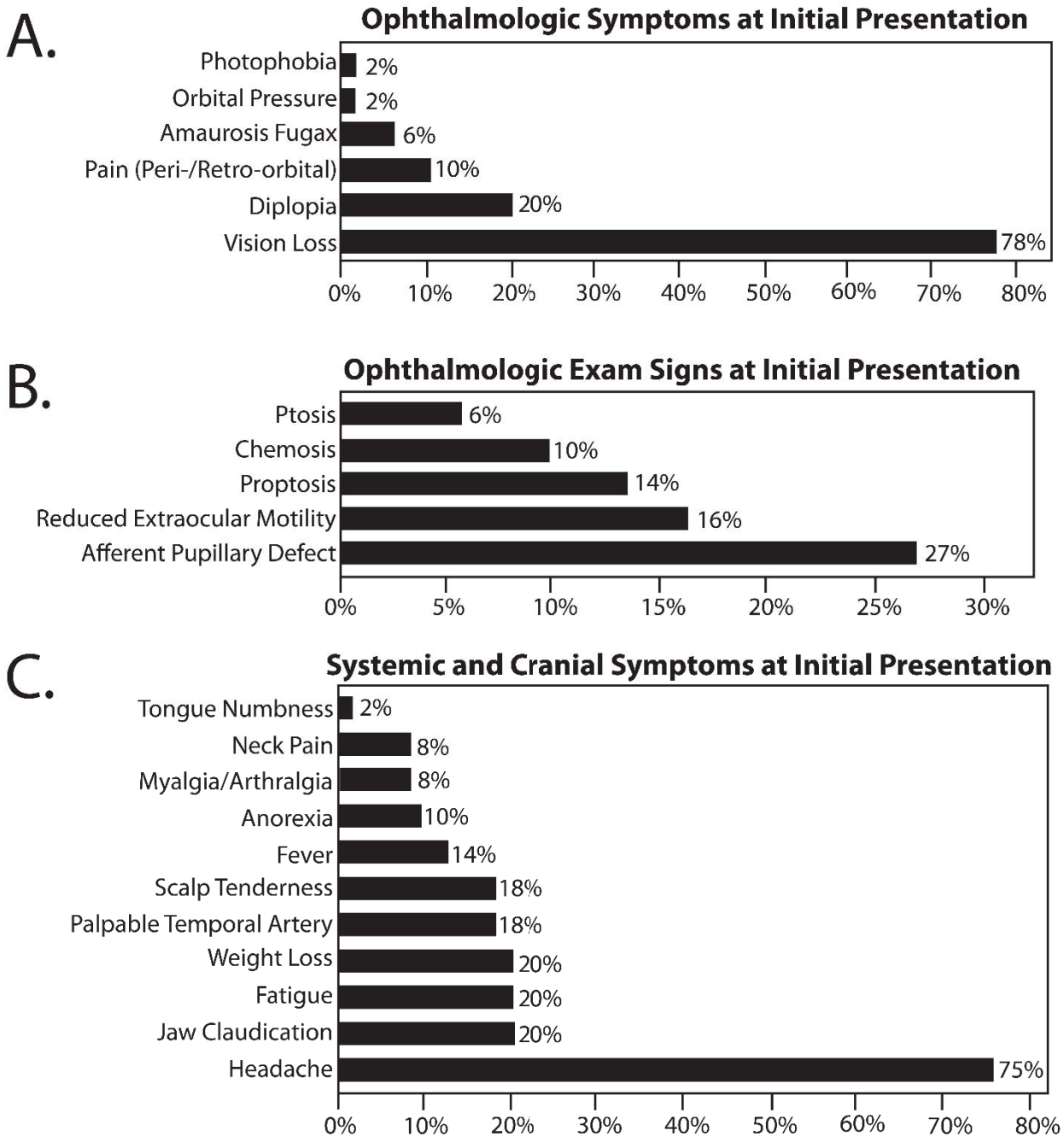
A.
Ophthalmologic Symptoms at Initial Presentation
Photophobia 2%
Orbital Pressure 2%
Amaurosis Fugax 6%
Pain (Peri-/Retro-orbital) 10%
Diplopia 20%
Vision Loss 78%
0% 10% 20% 30% 40% 50% 60% 70% 80%
B.
Ophthalmologic Exam Signs at Initial Presentation
Ptosis 6%
Chemosis 10%
Proptosis 14%
Reduced Extraocular Motility 16%
Afferent Pupillary Defect 27%
0% 5% 10% 15% 20% 25% 30%
C.
Systemic and Cranial Symptoms at Initial Presentation
Tongue Numbness 2%
Neck Pain 8%
Myalgia/Arthralgia 8%
Anorexia 10%
Fever 14%
Scalp Tenderness 18%
Palpable Temporal Artery 18%
Weight Loss 20%
Fatigue 20%
Jaw Claudication 20%
Headache 75%
0% 10% 20% 30% 40% 50% 60% 70% 80%

Figure 3

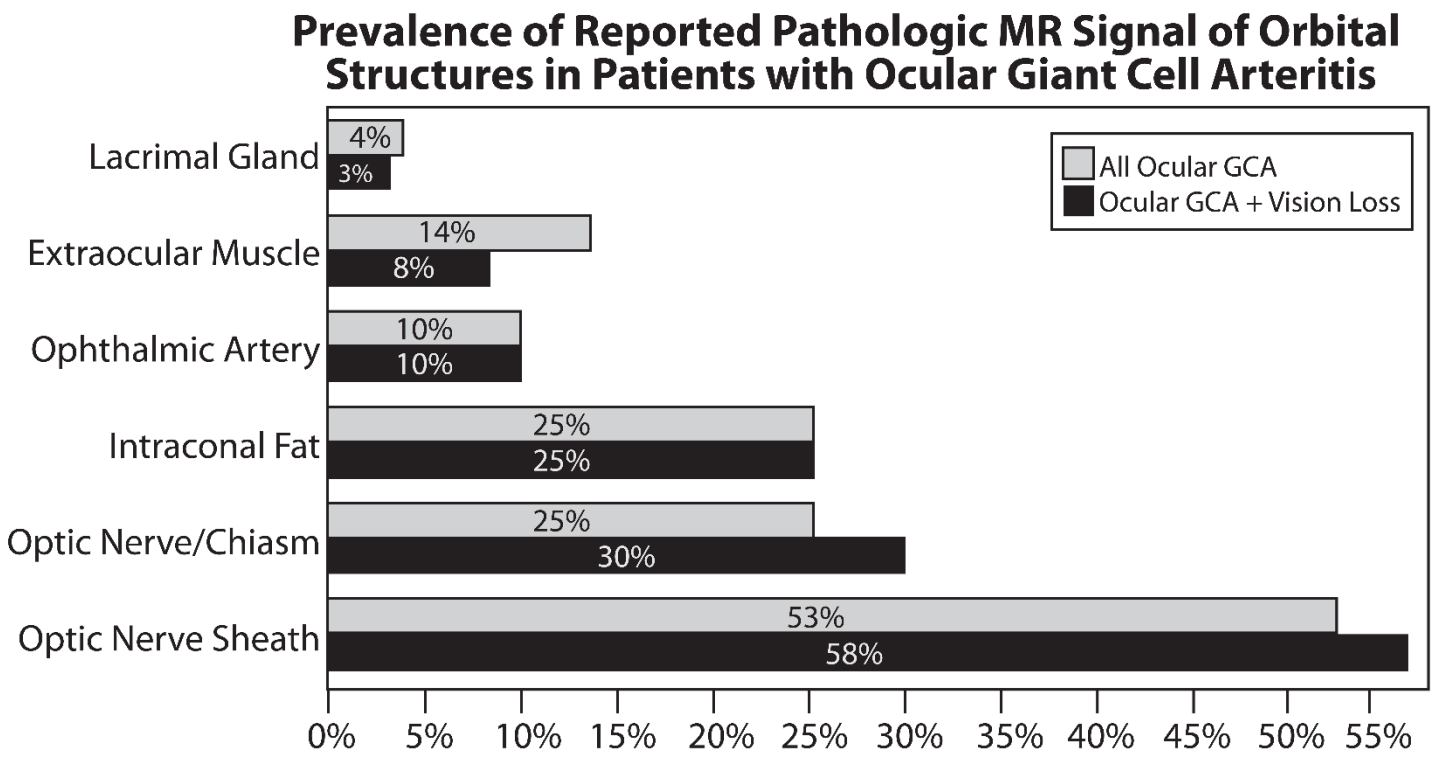
Prevalence of Reported Pathologic MR Signal of Orbital Structures in Patients with Ocular Giant Cell Arteritis
All Ocular GCA
Ocular GCA + Vision Loss
Lacrimal Gland
4%
3%
Extraocular Muscle
14%
8%
Ophthalmic Artery
10%
10%
Intraconal Fat
25%
25%
Optic Nerve/Chiasm
25%
30%
Optic Nerve Sheath
53%
58%
0%
5%
10%
15%
20%
25%
30%
35%
40%
45%
50%
55%

Figure 4

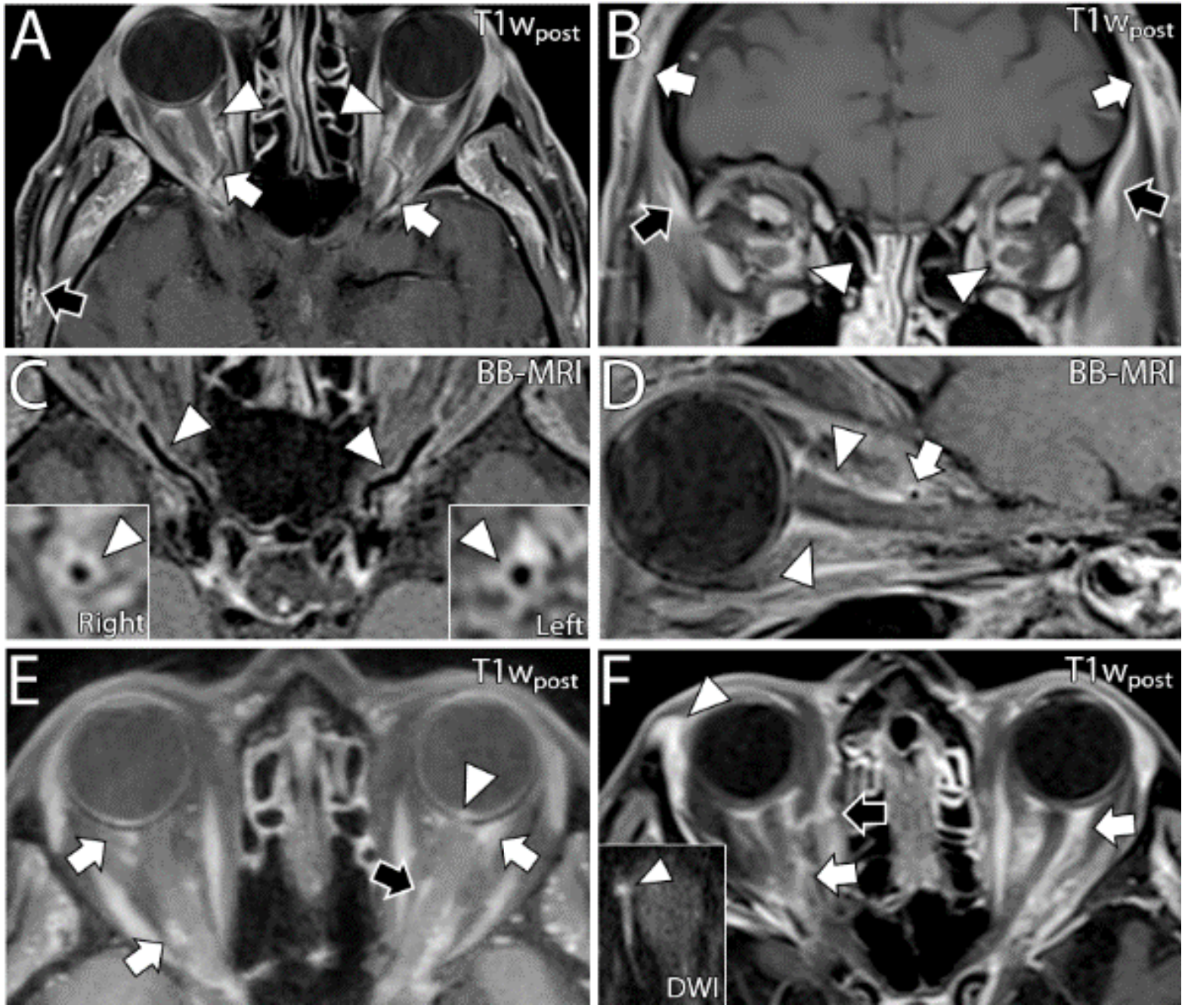
A
T1Wpost
B
T1Wpost
C
BB-MRI
Right
Left
D
BB-MRI
E
T1Wpost
F
T1Wpost
DWI